

We are IntechOpen, the world's leading publisher of Open Access books Built by scientists, for scientists

6,900

Open access books available

185,000

International authors and editors

200M

Downloads

Our authors are among the

154

Countries delivered to

TOP 1%

most cited scientists

12.2%

Contributors from top 500 universities



WEB OF SCIENCE™

Selection of our books indexed in the Book Citation Index
in Web of Science™ Core Collection (BKCI)

Interested in publishing with us?
Contact book.department@intechopen.com

Numbers displayed above are based on latest data collected.
For more information visit www.intechopen.com



Transcatheter Aortic Valve Implantation: State of the Art

Alice Le Huu, Rony Atoui and Dominique Shum-Tim

*Divisions of Cardiac Surgery and Surgical Research, Department of Surgery,
McGill University Health Center, Montreal,
Canada*

1. Introduction

In the last century, medical innovation has revolutionized human lives and the management of medical diseases. Conditions which were once considered untreatable are now managed and even cured. Consequently, life expectancy has dramatically increased. The aging population brings about new challenges and pathologies that must be addressed with different approaches. As the body ages, so does the heart, bringing aortic stenosis to the forefront of valvular heart disease. It is estimated that 4.6% of patients over the age of 75 years old suffer from aortic stenosis (Nkomo et al., 2006). Traditionally, there were three modalities of treatment: conservative medical management, balloon valvuloplasty, and surgical aortic valve replacement (AVR). Long considered to be the gold-standard for aortic valve stenosis, surgical intervention provided a functional valve with acceptable mortality rates. However, the risks of surgical intervention increase dramatically depending on a patient's comorbidities. Accordingly, high-risk patients were often relegated to medical management or balloon valvuloplasty. Conservative management has yielded extremely disappointing results. Patients who underwent balloon valvuloplasty in conjunction with medical treatment had a 44-37.2% mortality rate within a year. In addition, conservative management is associated with a high rate of restenosis. Medical management alone resulted in an unacceptable 25% mortality in one year (Nkomo et al., 2006; Ben-Dor et al., 2010). Despite these staggering statistics, the Euro Heart Survey suggested that approximately 30% of patients suffering from severe aortic stenosis were not treated with surgical intervention (Lung et al., 2003). A significant portion of these patients are refused surgery because they are deemed to have elevated surgical risks. Considering the natural history of the pathology, patients who were refused for surgery suffer considerable morbidity and mortality. Even with maximum medical therapy, the future for these patients appeared bleak.

Fortunately, the advent of transcatheter aortic valve implantation (TAVI), has led to new options for non-surgical candidates. As early as 1965, an article describing a catheter-mounted valve replacement for temporary relief of aortic insufficiency in an animal (Davies H., 1965). After more than three decades of development, Cribier et al. (2002) successfully implanted a percutaneous prosthetic heart valve in a 57-year-old man. The patient, who was moribund due to numerous medical conditions, showed significant clinical and echocardiographic improvement after the valve had been implanted. Although he eventually

succumbed to his multiple comorbidities, his last transesophageal echocardiography demonstrated a functional aortic valve (Webb et al., 2009). A landmark success, this intervention was followed by a flurry of developments which resulted in considerable refinement of the procedure. This would culminate in increased safety, efficiency, and physician familiarity with the intervention. It is now estimated that over 15,000 patients worldwide have undergone a TAVI procedure (Geisbusch et al., 2010).

2. Patient selection

With any medical procedure, whether it is aortic valve replacement or medical treatment, the key to a favorable outcome is appropriate patient selection. By virtue of its recent development, access to TAVI remains restricted. Presently, TAVI is offered only to patients with symptomatic, critical aortic stenosis who have been deemed unsuitable for AVR. Evaluating a patient as inoperable depends on many factors, which include patient comorbidities, the surgeon's experience, and the institution in which the surgeon practices. Subtle details may influence a physician's judgment, which renders it difficult to provide a standard definition of a non-surgical candidate. With this limitation in mind, many institutions qualify patients with a logistic EuroScore calculated $\geq 20\%$ or an STS (Society of Thoracic Surgery) predicted mortality risk score $\geq 10\%$ as high-risk (Bande et al., 2010). Although not included in these two scoring systems, other criteria often cited when deeming a patient high-risk include: calcified porcelain aorta, chest wall deformities, cancer, cirrhosis with portal hypertension, neurological dysfunction, perceived frailty, severe chronic obstructive disease, previous cardiac surgery, severe cerebrovascular disease, low ejection fraction, and untreatable coronary artery disease (Saia et al., 2010). Traditionally, a bicuspid valve is considered a contraindication to TAVI. Due to its elliptical rather than circular shape, TAVI may result in a morphologically distorted valve and increased incidence of perivalvular leaks. Consequently, valve durability may be compromised. Recently published experience with 11 bicuspid TAVI demonstrated decreased gradients across the valve, and increased valve area. Two patients had moderate leaks. Although interesting, these results did not address the fundamental concern of TAVI in bicuspid valves related to their durability (Wijesinghe et al., 2010).

Once patients are deemed inoperable, they must be carefully screened before proceeding to TAVI. In many centers, candidates are evaluated by a multidisciplinary committee consisting of cardiologists, cardiac surgeons, and cardiac anesthesiologists. Therefore, patients are evaluated on a case-by-case basis. Broad exclusion criteria may include dementia, life expectancy of less than 1 year, severely incapacitating neurological dysfunction, thoracic aneurysm, and a low likelihood of benefitting from the procedure (Shareghi et al., 2007). However, these selection parameters are subject to the discretion of each individual committee, and remain obscure. As TAVI becomes more prevalent, it will most certainly entail the development of specific guidelines to help orient physicians.

A patient's anatomy is crucial in the selection process. The preoperative screening tests are similar in many centers. Transthoracic echocardiography and a coronary angiogram are standard. From a purely logistic point of view, a patient with an aortic annulus diameter < 18 mm or > 26 mm may be excluded due to limited availability of valve sizes (Webb et al., 2009). However, this exclusion is likely to be attenuated in the coming years as a wider range of valve sizes are developed. Computer tomography of the thorax, abdomen, and

pelvis are done to delineate the anatomy of the patient. For technical considerations, the presence of torturous, severely diseased femoral or subclavian arteries may not be amenable to percutaneous TAVI. When available, some centers use three-dimensional reconstruction of the aortic root to detect calcifications, femoral stenosis, kinking, and aortic dissection (Geisbusch et al., 2010). While helpful, reconstructions are not essential to the screening process.

Absolute contraindications to TAVI are few, but include intolerance of anticoagulation and bleeding diathesis. There is a lack of consensus on the ideal strategy, but many centers use dual antiplatelet therapy: a loading dose of aspirin (325 mg) and clopidogrel (300-600 mg), followed by clopidogrel (75 mg) for 6 months and aspirin (81 mg) indefinitely (Gurvitch et al., 2010). Other exclusion criteria include the presence of a ventricular or atrial clot and active endocarditis.

3. Design of the device

Currently, two types of percutaneous valves dominate the market: the SAPIEN Valve manufactured by Edwards Life Sciences (Irvine, CA, USA) and the CoreValve produced by Medtronic, Inc. (Minneapolis, MN, USA). Each valve has unique properties and indications for implantation.

The SAPIEN model is a trileaflet bovine valve mounted on a cobalt-chromium stent; it is a balloon-expandable prosthesis. Designed for antegrade, retrograde, or transapical delivery, the valve is deployed by balloon expansion into a subcoronary position. The prosthetic valve uses the native calcified valve to anchor itself (Eltchaninoff et al., 2008). There are three sizes available: 23 mm, 26 mm, and 29 mm, with a 20-mm size in development (Bande et al., 2010). Presently, the SAPIEN valve employs the Novoflex delivery system, which allows the valve to be delivered via an 18F and 19F introducer sheath for a 23-mm and 26-mm valve, respectively (Lange et al., 2007).

The Medtronic CoreValve, is used worldwide but has yet to be approved in North America and Japan. The CoreValve is a trileaflet bioprosthetic porcine valve which is mounted onto a self-expanding nitinol frame. The nitinol stent has 3 portions: an upper portion which serves to anchor the device to the ascending aorta, a central component of the stent engineered to avoid obstructing the coronary ostium, and a lower portion of the stent which rests on the annulus. The CoreValve system is believed to adapt to non-circular anatomies. Two sizes are available: 22 mm and 29 mm; the valve requires an 18F introducer sheath (Bande et al., 2010). Designed for retrograde delivery, it is implanted using a transfemoral or subclavian approach; however, successful transapical implantation has been reported.

4. Methods of approach

Presently, three approaches for TAVI are used: transfemoral, transapical, and subclavian. Selecting the proper approach involves integrating patient characteristics with technical considerations. The preferred access remains the transfemoral approach. Using this access, the Novaflex delivery system requires arteries to be 6.0 to 6.5 mm in diameter. Similarly, the CoreValve requires 6.0 to 7.0 mm arteries in order to accommodate the catheter-mounted aortic valve. The size of the introducer sheath used is dictated by patient anatomy, primarily the size of the femoral artery for access and the diameter of the valve required to fit the annulus. Depending on the sheath used, surgical exposure and closure of the femoral artery

may be needed. In other cases, a smaller catheter may require only a vascular closure device, and thus negate the need of a surgical team (Eltchaninoff et al., 2008). A heavily calcified arterial system with numerous tortuosities may not be amenable to access. In addition, patients who have had extensive vascular surgery are usually not suited to this approach. The transfemoral is considered to be a relatively safe method of access. However, reported complications include formation of retroperitoneal hematoma, iliac or femoral artery pseudoaneurysms, and stenosis or occlusion induced by a vascular closure device. According to Philipp et al. (2009), the majority of these complications are managed conservatively, or with endovascular intervention.

Typically, the transapical approach will be used when the iliofemoral approach is not feasible. For this approach, the SAPIEN valve is used because it is approved for antegrade delivery. The procedure is done in a hybrid suite with the guidance of transesophageal echocardiography and fluoroscopy. Under, under general anesthesia, a 6 to 8 cm anterolateral thoracotomy incision is made to expose the pericardium. Once open, temporary pacing wires are attached and a suitable puncture site in the left ventricular apex is identified. Two orthogonal U-shaped pledgeted sutures are placed in the myocardium before a needle puncture is done, followed by the insertion of a guide wire to the ascending aorta. The catheter is then increased in size to allow for balloon valvuloplasty. Once complete, the sheath size is increased to accommodate the delivery system, and the transcatheter valve is deployed. At the end of the procedure, at the discretion of the surgeon, a drain may be left in place. This method of delivery is much more invasive than the iliofemoral approach and is linked to significant complications. This may include pericarditis, tamponade, pneumothorax, and the formation of a false aneurysm at the apex of the heart (Al-Attar et al., 2009). Injury to the mitral valve using this approach is also a particular concern due to its anatomic proximity. In addition, recovery time is more extensive. Pain at the thoracotomy site is not negligible and can result in respiratory debilitation in frail and elderly patients, culminating in prolonged hospitalization.

Recently, the trans-subclavian approach has been developed as an alternative to the transapical approach. A technique described by Petronio et al. (2010) consists of surgical exposure of the subclavian artery, followed by arterial puncture between purse-string sutures. A 6F catheter is inserted, and the 18F catheter commonly used for the transfemoral approach is placed over a guide wire. It is then threaded through the subclavian artery and into the ascending aorta. Once in place, the catheter mounted valve is implanted using the same method as for the transfemoral approach. Concerns exist over the security of the trans-subclavian method. Of particular interest are patients who have had their internal mammary used in a coronary artery bypass graft. It is unclear whether this approach can safely preserve flow through the graft during implantation of the valve. By rapidly withdrawing the 18F catheter, the Petronio et al. (2010) team was able to avoid all signs of myocardial ischemia. Caution must be exercised in the interpretation of this data, as the sample size (8 patients) was quite small. Other considerations concerning the trans-subclavian approach include direct injury to the brachial plexus and damage secondary to hematoma formation. Perhaps because of its recent development, this method appears to be used less frequently than the transfemoral approach. It is usually considered a second option when the transfemoral anatomy is unsuitable for access. As the number of TAVI procedures increase, familiarity with the trans-subclavian approach will rise, and it will become more frequently employed.

Comparisons between the three methods of delivery remain in their infancy. The studies have used small sample sizes, and do not offer direct comparisons between the methods of delivery, nor were the patients randomized between the methods of approach. The trend is to favor a transfemoral approach, and, when this is not possible, to opt for a transapical approach. In theory, a transapical approach requires mechanical ventilation and general anesthesia, which renders it less desirable.

5. Outcome

Initial results from TAVI are very encouraging, albeit of a small scale. However, in recent years, large-scale studies support the assertion that TAVI is a viable treatment option for aortic stenosis. The most important study to date is the PARTNER trial, a North American multicenter trial with 2 main cohorts, run by Leon et al. (2010). Surgical candidates were randomized to TAVI or conventional aortic valve replacement (Cohort A). Patients who were deemed non-operable (358 patients) were randomized to TAVI and medical therapy (including balloon valvuloplasty: cohort B). The patients all underwent TAVI through a transfemoral approach, and were followed for up to one year post-procedure. The results of cohort B were recently published. TAVI was shown to be superior for all of the hard endpoints, including death at one year: 30.7% for TAVI compared with 71.6% for standard therapy. Patients who underwent the procedure demonstrated significantly increased freedom from symptoms associated with their valvular disease: 74.8% compared with 42.0% (Leon et al., 2010). This study is unequivocal proof that TAVI is superior to conventional medical management. The results from this randomized trial are in accordance with other studies. Gurvitch et al. (2010), sought to elucidate the long-term outcome of TAVI patients by following a cohort of 70 individuals over a period of 3 years. Survival after 1 year (excluding 11 patients that died within 30 days of the procedure and 8 patients with failed valve implantation) was 81%. Studies with mixed delivery approaches (transfemoral, transapical, and subclavian), yielded mortality rates between 5.4%-11.3% after 30 days (Gurvitch et al., 2010; Petronio et al., 2010). However, with cohort studies, it is difficult to compare the mortality rate with conventional medical treatment. Indirect comparisons can be made with published estimates of mortality, which ranges from 51%-62% in symptomatic patients after 1 year (Bach et al., 2007). The totality of the data suggests that in patients who are refused surgery, TAVI is superior to medical management.

Aside from mortality and freedom from symptoms, another important determinant of outcome is the durability of the transcatheter valves. Studies indicate that the TAVI device is quite durable. Gurvitch et al. (2010) suggests that the valve appears to be structurally normal, with very little incidence of degeneration at 3 years. Valve function appears to decrease over the years, quantified by a slight decrease in calculated valve area and an increase in valve gradient, estimated by the authors at 0.06% cm² per year. It is unclear whether these changes will be clinically significant. Due to its relatively recent development, the durability of the valve will be known only in the near future. It is important to note that surgically replaced aortic valves also show signs of degeneration, tearing, and calcification. The durability of surgically replaced valves compared to TAVI will only be known in years to come.

The presence of aortic insufficiency after TAVI is another important criterion of success. Unfortunately, this endpoint is exceedingly difficult to qualify because of the subjective

nature of echographic findings. Notoriously operator-dependent, this issue is magnified when exams are completed by different physicians and technicians in a range of institutions. Nevertheless, the PARTNER trial found moderate or severe paravalvular aortic insufficiency in 11.8% of patients after 30 days, and 10.5% at 1 year (Leon et al., 2010). The amount of aortic regurgitation remained stable in patients after one year, did not seem to progress, and was generally well tolerated by the patients. Similarly, Gurvitch et al. (2010) determined that 6% of their patients had moderate aortic regurgitation, with no incidences of severe regurgitation. The clinical significance of these echographic findings is yet to be determined. The stability of the aortic insufficiency over time will be the key determinant of the relevance of this finding.

6. Complications

As with any other medical procedure, there are risks associated with TAVI. The most concerning complication is the risk of stroke. The culprits behind the neurological event are multifold. Atheroma in the aorta, dislodged during TAVI, may play a significant role. In addition, during TAVI many patients undergo balloon valvuloplasty, which is likely to dislodge microemboli of calcium to the cerebrovascular system. The TAVI procedure, with the self-expanding valve or manual positioning of the valve, is also traumatic to the original valve. This provides another possible source of emboli. Despite encouraging results in terms of crude outcomes such as death and freedom from repeat hospitalization, the optimism for this procedure is tempered by the risk of cerebral ischemia. The PARTNER trial found the incidence of stroke to be 5% compared with 1.1% in the medically treated group (Leon et al., 2010). Similarly, Gurvitch et al. (2010) documented a risk of 8.6% after 3 years. Even more alarming, Kahlert et al. (2010) followed 32 patients who underwent TAVI (either the SAPIEN or CoreValve), to discover the effect on their neurological status. Neurological assessment and cognitive function were assessed through the National Institute Health Stroke Scale (NIHSS) along with a Mini Mental State Examination (MMSE). In conjunction with these clinical exams, patients received preoperative and postoperative MRIs. In 84% of the patients, significant multiple and diffuse emboli were discovered on the MRIs. The investigators were unable to find a clinical correlation between the radiologic images and patients' symptoms. However, the NIHSS and the MMSE are crude methods of measuring cognitive function. Subtle changes in memory and cognitive function may be much more evident in a younger, healthier individual with fewer comorbidities. Further research must be completed on the neurological impact of TAVI before it can be offered to patients who are surgical candidates.

The need for pacemaker insertion following TAVI is also well documented. A study by Khawaja et al. (2011) quoted a rate of 33.3% requiring pacemaker insertion in the 30 days following the procedure. The study found that patients were most often susceptible to developing left bundle branch block. After studying the CoreValve, the authors reasoned that the skirt of the valve (depending on the position after the deployment) will lie in close proximity to the left bundle branch, which entails conduction abnormalities. The old valve is not excised and the placement of the CoreValve on top of the remnants may lead to compression of conduction structures.

Dislocation or migration of the valve during implantation is mentioned in several case reports. In a patient population of 212, Geisbusch et al. (2010) reported an incidence of 10%

dislocation during implantation, while Rhodes-Cabu et al. (2010) had a rate of 2%. Management of this complication primarily consists of retrieving the valve in the ascending aorta and reimplanting it. However, patients with this complication had significantly higher rates of stroke, ischemia, or renal failure than did patients whose first implantation was successful (Geisbusch et al., 2010). Although this complication is documented in other papers, this study on the CoreValve reveals it to be quite frequent. It is probable that valve dislocation is a common occurrence; however, it is not well documented in large trials as a potential source of morbidity. In addition, in cohort studies which involve databases, this information is more difficult to obtain, and is thus excluded from analysis.

Other complications include vascular-related injuries as such as dissection, perforations, ruptures, and hematomas, as well as cardiac-related issues such as aortic root rupture, mitral valve injury, tamponade, and injury to the left ventricle apex.

7. Future prospects

Preliminary data on transcatheter aortic valve implantation is very promising. It also highlights the importance of a dedicated multidisciplinary team consisting of a cardiac surgeon, interventional cardiologist, echocardiographer, cardiac anesthesiologist, perfusionist, and scrub team. As with any new technology, more research needs to be completed before its role in the management of aortic stenosis can be clearly delineated. At present, it is clearly superior to medical management, and offers non-surgical patients a viable option. However, its use in patients who are surgical candidates is likely to be tempered by several limiting factors. Of primary importance is the increased risk of cerebral ischemia during this procedure, that seems to persist overtime even after the placement of TAVI. By virtue of its delivery system and implantation mechanism, it will be very difficult to minimize thromboembolic events. In older, frail patients with many co-morbidities, TAVI may be an acceptable alternative. New generation of sutureless surgically implantable prosthetic valves are another surgical options in development (Perseval S valve by Sorin). These valves are designed to be implanted after the calcified aortic valve is surgically removed. This will theoretically diminish the potential of ongoing embolic risks that were observed in current TAVI reported by the PARTNER trial (Miller, 2011). Without the need to suture the prosthetic valve onto the aortic annulus, the valve would be quicker to implant and result in decreased cardio-pulmonary bypass time (O'Brien et al., 1998). Consequently, these sutureless valves may be more suitable for patients with intermediate risk profile, in whom a shorter cardio-pulmonary bypass time may be beneficial. Ongoing accumulation of experience and longer term follow-up are underway to assess the clinical application of this new generation of surgically implantable sutureless valve in many cardiac centers. In a younger patient, however, where mortality associated with surgical aortic valve replacement is very low, traditional surgical management is indicated.

Another area of interest is the durability of TAVI. The valve's ability to expand to fit the aortic root may be detrimental to its long-term use. It remains questionable whether this type of valve is suitable for implantation when the patient's life expectancy is beyond ten to fifteen years. Unfortunately, this data will be available only several years from now.

Currently, many questions remain unanswered. The TAVI technique is still in its infancy compared with traditional surgical and medical management of aortic stenosis, which has undergone rigorous investigation. For surgical valve replacement, there are clear indications

and guidelines on the timing and management of replacement. Data on proper management of TAVI patients are lacking, including basic premises such as anticoagulation and management in conjunction with other heart pathologies. Aortic stenosis rarely exists as a single entity, and ischemic heart disease often coexists with this pathology. Initial data on the role of concomitant coronary artery disease and TAVI is conflicting. Dewey et al. (2010) reported increased mortality in patients with coronary artery disease undergoing TAVI, while Masson et al. (2010) found that this factor did not affect mortality. These are conflicting reports and illustrate that the application of TAVI in complex clinical situations remains obscure. More research must be completed to properly define the role of TAVI in the treatment of aortic stenosis.

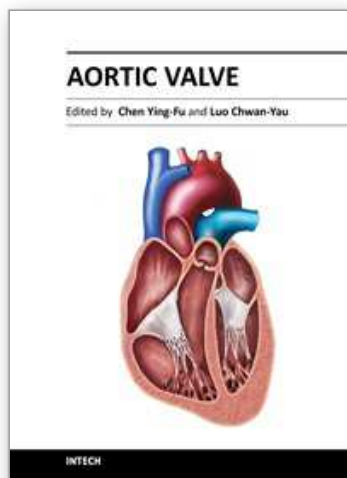
It is undeniable that the advent of TAVI has provided physicians with an important tool for treating aortic valve disease. In non-surgical, high-risk patients, the technology may mean freedom from considerable mortality and morbidity. The therapeutic potential of this technology is astonishing; however, expectations must be tempered by caution.

8. References

- Al-Attar N, Ghodbane W, Himbert D, Rau C, Raffoul R, Messika-Zeitoun D, Brochet E, Vahanian A & Nataf P. (2009) Unexpected Complications Of Transapical Aortic Valve Implantation. *Annals of Thoracic Surgery* Vol. 88, pp. 90-94, ISSN 0003-4975
- Bach DS, Cimino N & Deeb MG. (2007) Unoperated Patients with Severe Aortic Stenosis. *Journal of the American College of Cardiology*. Vol. 50, pp. 2018-2019 ISSN 0735-1097
- Bande M, Michev I, Sharp A, Chieffo A & Colombo A. (2010). Percutaneous Transcatheter Aortic Valve Implantation: Past Accomplishments, Present Achievements and Applications, Future Perspectives. *Cardiology in Review*. Vol. 18, pp. 111-124, ISSN 1061-5377
- Dewey TM, Brown DL, Herbert MA, Culica D, Smith CR, Leon MB, Svensson LG Tuzcu M, Webb JG, Cribier A & Mack MJ. (2010). Effect Of Concomitant Coronary Artery Disease On Procedural and Late Outcomes Of Transcatheter Aortic Valve Implantation. *The Annals of Thoracic Surgery*. Vol. 89, pp. 758-767 ISSN 0003-4975
- Eltchaninoff H, Zajarias A & Tron C. (2008). Transcatheter Aortic Valve Implantation: Technical Aspects, Results and Indications. *Archives Cardiovascular Disease*. Vol. 101, pp. 126-132, ISSN 1875-2136
- Geisbusch S, Bleiziffer S, Mazzitelli D, Ruge H, Bauernschmitt R & Lange R. (2010). Incidence and Management of CoreValve Dislocation During Transcatheter Aortic Valve Implantation. *Circulation: Cardiovascular Intervention*. Vol. 3, pp. 531-536, ISSN 1941-7640
- Gurvitch R, Wood DA, Tay EL, Leipsic J, Ye J, Lichtenstein SV, Thompson CR, Carere RG, Wijesinghe N, Nietlispach F, Boone RH, Lauck S, Cheung A & Webb JG. (2010). Transcatheter Aortic Valve Implantation: Durability of Clinical and Hemodynamic Outcomes Beyond 3 Years in a Large Patient Cohort. *Circulation*. Vol. 122, pp. 1319-1327, ISSN 0009-7322
- Kahlert P, Knipp SC, Schlamann M, Thielmann M, Al-Rashid F, Weber M, Johansson U, Wendt D, Jakob HG, Forsting M, Sack S, Erbel R & Eggebrecht H. (2010). Silent and Apparent Cerebral Ischemia After Percutaneous Transfemoral Aortic Valve Implantation: A Diffuse-Weighted Magnetic Resonance Imaging Study. *Circulation*. Vol. 121, pp. 870-878 ISSN 0009-7322

- Khawaja MZ, Rajani R, Cook A, Khavandi A, Moynagh A, Chowdhary S, Spence SM, Brown S, Khan SQ, Walker N, Trivedi U, Hutchinson N, De Belder AJ, Moat N, Blackman DJ, Levy RD, Manoharan G, Roberts D, Khogali SS, Crean P, Brecker SJ, Baumbach A, Mullen M, Laborde JC & Hildick-Smith D. (2011). Permanent Pacemaker Insertion After CoreValve Transcatheter Aortic Valve Implantation: Incidence and Contributing Factors (the UK CoreValve Collaborative). *Circulation*. Vol. 123, pp. 951-960 ISSN 0009-7322
- Lange R, Schreiber C, Gotz W, Hettich I, Will A, Libera P, Laborde JC & Beurnschmitt R. (2007). First Successful Transapical Aortic Valve Implantation With the CoreValve Revalving System: A Case Report. *Heart Surgery Forum*. Vol. 10, E478-E479 ISSN 1522-6662
- Leon MB, Smith CR, Mack M, Miller DC, Moses JW, Svensson LG, Tuzcu EM, Webb JG, Fontana GP, Makkar RR, Brown DL, Block PC, Guyton RA, Pichard AD, Bavaria JE, Herrmann HC, Douglas PS, Petersen JL, Akin JJ, Anderson WN, Wang D & Pocock S; PARTNER Trial Investigators. (2010). Transcatheter Aortic-Valve Implantation For Aortic Stenosis In Patients Who Cannot Undergo Surgery. *New England Journal of Medicine*. Vol. 17, pp. 1597-607 ISSN 0028-4793
- Masson JB, Lee M, Boone RH, Al Ali A, Bugami SA, Hamburger J, Mancini J, Ye J, Cheung A, Humphries KH, Wood J, Nietlispach F & Webb JG. (2010). Impact Of Coronary Artery Disease On Outcomes After Transcatheter Aortic Valve Implantation. *Catheterization and Cardiovascular Intervention*. Vol. 76, pp. 165-173 ISSN 1522-1946
- Miller, C. (2011). "Late-breaking Clinical Trial: Frequency and Severity of Neurologic Events after Aortic Valve Replacement or Transcatheter Aortic Valve Implantation in High Surgical Risk Patients with Aortic Stenosis: The PARTNER Trial Stroke Substudy," American Association for Thoracic Surgery 91st Annual Meeting, Philadelphia, Pennsylvania
- O'Brien MF, Gardner MA, Garlick RB, Davison MB, Thomson HL, Burstow DJ. (1998). The Cryolife-O'Brien stentless aortic porcine xenograft valve. *Journal of Cardiac Surgery* Vol. 13, pp. 376-385 ISSN 0886-0440
- Petronio AS, De Carlo M, Bedogoni F, Marzocchi A, Klugmann S, Maisano F, Ramondo A, Ussia GP, Etti F, Poli A, Brambilla N, Saia F, De Marco F & Colombo A. (2010). Safety and Efficacy of the Subclavian Approach For the Transcatheter Aortic Valve Implantation with the CoreValve Revalving System. *Circulation: Cardiovascular Intervention*. Vol. 3, pp. 359-366 ISSN 1941-7640
- Philipp K, Al-Rashid F, Weber M, Wendt D, Heine T, Kottenberg E, Thielmann M, Kühl H, Peters J & Heinz JG. (2009). Vascular Access Site Complications After Percutaneous Transfemoral Aortic Valve Implantation. *Herz*. Vol. 5, pp. 398-408, ISSN 0340-9937
- Saia F, Marrozzini C, Dall'Ara G, Russo V, Martin-Suarez S, Ortolani P, Palmerini T, Taglieri N, Bordoni B, Pilato E, Di Bartolomeo R, Branzi A & Marzocchi A. (2010). How Many Patients With Severe Symptomatic Aortic Stenosis Excluded For Cardiac Surgery Are Eligible For Transcatheter Heart Valve Implantation? *Journal of Cardiovascular Medicine (Hagerstown)*. Vol. 10, 727-732 ISSN 1558-2027
- Shareghi S, Rasouli L, Shavelle DM, Burstein S & Matthews RV. (2007). Current Results Of Balloon Aortic Valvuloplasty In High Risk Patients. *Journal of Invasive Cardiology*. Vol. 19, pp. S37-S42 ISSN 1042-3931

- Webb J, Altwegg L, Boone RH, Cheung A, Ye J, Lichenstein S, Lee M, Masson JB, Thompson C, Moss R, Carere R, Munt B, Nietlispach F & Humphries K. (2009). Transcatheter Aortic Valve Implantation: Impact On Clinical and Valve-Related Outcome. *Circulation*. Vol. 119, pp. 3009-3016 ISSN 0009-7322
- Wijesinghe N, Ye J, Rodés-Cabau J, Cheung A, Velianou JL, Natarajan MK, Dumont E, Nietlispach F, Gurvitch R, Wood DA, Tay E, Webb JG. (2010). Journal American College Cardiology: Cardiovascular Interventions. Volume 3, 1122-1125 ISSN: 1936-8798



Aortic Valve

Edited by Prof. Chen Ying-Fu

ISBN 978-953-307-561-7

Hard cover, 350 pages

Publisher InTech

Published online 09, December, 2011

Published in print edition December, 2011

Much has evolved in the field of aortic valve disease because of the increase in knowledge in the last decade, especially in the area of its management. This book "Aortic Valve" is comprised of 18 chapters covering basic science, general consideration of aortic valve disease, infective endocarditis, aortic sclerosis and aortic stenosis, bioprosthetic valve, transcatheter aortic valve implantation and a special section on congenital anomalies of the aortic valve. We hope this book will be particularly useful to cardiologists and cardiovascular surgeons and trainees. We also believe that this book will be a valuable resource for radiologists, pathologists, cardiovascular anesthesiologists, and other healthcare professionals who have a special interest in treating patients with aortic valve disease. We are certain that information in this book will help to provide virtually most new areas of aortic valve disease that will be employed in the current era.

How to reference

In order to correctly reference this scholarly work, feel free to copy and paste the following:

Alice Le Huu, Rony Atoui and Dominique Shum-Tim (2011). Transcatheter Aortic Valve Implantation: State of the Art, Aortic Valve, Prof. Chen Ying-Fu (Ed.), ISBN: 978-953-307-561-7, InTech, Available from: <http://www.intechopen.com/books/aortic-valve/transcatheter-aortic-valve-implantation-state-of-the-art>

INTech
open science | open minds

InTech Europe

University Campus STeP Ri
Slavka Krautzeka 83/A
51000 Rijeka, Croatia
Phone: +385 (51) 770 447
Fax: +385 (51) 686 166
www.intechopen.com

InTech China

Unit 405, Office Block, Hotel Equatorial Shanghai
No.65, Yan An Road (West), Shanghai, 200040, China
中国上海市延安西路65号上海国际贵都大饭店办公楼405单元
Phone: +86-21-62489820
Fax: +86-21-62489821

© 2011 The Author(s). Licensee IntechOpen. This is an open access article distributed under the terms of the [Creative Commons Attribution 3.0 License](https://creativecommons.org/licenses/by/3.0/), which permits unrestricted use, distribution, and reproduction in any medium, provided the original work is properly cited.

IntechOpen

IntechOpen