

# We are IntechOpen, the world's leading publisher of Open Access books Built by scientists, for scientists

6,900

Open access books available

185,000

International authors and editors

200M

Downloads

Our authors are among the

154

Countries delivered to

TOP 1%

most cited scientists

12.2%

Contributors from top 500 universities



WEB OF SCIENCE™

Selection of our books indexed in the Book Citation Index  
in Web of Science™ Core Collection (BKCI)

Interested in publishing with us?  
Contact [book.department@intechopen.com](mailto:book.department@intechopen.com)

Numbers displayed above are based on latest data collected.  
For more information visit [www.intechopen.com](http://www.intechopen.com)



# Clinical Management of Thyroid Nodules in the Areas of Various Iodine Supply

Dorota Słowińska-Klencka<sup>1</sup>, Bożena Popowicz<sup>1</sup>,  
Stanisław Sporny<sup>2</sup> and Mariusz Klencki<sup>1</sup>

<sup>1</sup>*Department of Morphometry of Endocrine Glands, Medical University of Lodz,*

<sup>2</sup>*Department of Dental Pathomorphology, Medical University of Lodz  
Poland*

## 1. Introduction

The thyroid nodules constitute an important diagnostic problem mainly because various benign lesions must be distinguished from malignant neoplasms. This problem is of particular importance in endemic and postendemic areas where there are a lot of patients with multiple thyroid nodules. In such areas the majority of thyroid lesions is non-neoplastic and develop usually when diffuse goitre transforms into nodular one (Laurberg et al., 2010, Słowińska-Klencka et al., 2002, 2008). Other non-neoplastic thyroid lesions may develop due to thyroiditis (acute thyroiditis, de Quervain disease, and autoimmune chronic thyroiditis). The frequency of revealing thyroid cancer – in comparison to malignancies in other organs – is relatively low. On the other hand, it is the most common cancer of endocrine glands, and the incidence of thyroid cancer is continuously increasing (Hughes et al., 2011; Sipos & Mazzaferri, 2010). This increase is partly related to the improvements to efficacy of preoperative diagnostics, but whatever is the nature of the observed higher incidence of the thyroid cancer it focuses the interests of physicians. It should be stressed that epidemiological assessments based on clinical data do not reflect the true incidence of the thyroid cancer, as it is found in as much as 30% of cadavers if the thyroid is serially examined during autopsy (Fukanaga & Yatani, 1975; Harach et al., 1985). In majority of such cases these cancers are subclinical papillary microcancers (with diameters below 10 mm) that are usually not diagnosed in alive patients. However, recently it has been shown that cytological examination of small thyroid lesions reveals invasive cancers (with the presence of cancer cells in lymph nodes and infiltration of the thyroid capsule) with a surprisingly high frequency (Chow et al., 2003; Kang et al., 2004; E.K. Kim et al., 2002; Lin et al., 2005; Nam-Goong et al., 2004; Papini et al., 2002, Słowińska-Klencka et al., 2008).

## 2. Influence of iodine supply on epidemiology of the thyroid lesions

Thyroid nodules can be revealed by palpation in 4–7% of adult patients in the areas of sufficient iodine supply, and in 10–15% in the areas of mild to moderate iodine deficiency (Hegedüs 2004; Knudsen et al., 2000; Tunbridge et al., 1977). The use of ultrasound (US)

imaging raises ten times the rate of discovering thyroid lesions in comparison with palpatory examination (Ezzat et al., 1994; Tan et al., 1995). Many of these lesions do not exceed 10 mm in diameter. That increase poses diagnostic challenges particularly in endemic areas or areas with newly corrected iodine supply. We showed that, in such an area, focal lesions were found in the thyroid glands of nearly 80% of the examined patients, and the frequency of multinodular goitre, irrespective of the size of lesions, was considerably high – above 77%. Between infracentimetric nodules, found in more than 40% of all examined persons, the percentage of multiple lesions was even higher – above 80% (Słowińska-Klencka et al., 2008). This constitutes a major difference in comparison with countries with high iodine supply, where the thyroid lesions more frequently occur as single nodules (Feldt-Rasmussen, 2001; Frates et al. 2006; D.L. Kim 2008; E.K. Kim et al., 2002; Słowińska-Klencka et al., 2002).

The differences in iodine supply influence also the incidence of various pathological lesions in the thyroid (Laurberg et al. 2010). In endemic areas patients with nodular goitre and follicular neoplasms predominate. The introduction of iodine prophylaxis is related to a gradual decline in the occurrence of non-neoplastic nodular goitre as well as of follicular neoplasms; on the other hand, papillary cancer is diagnosed more frequently (Feldt-Rasmussen, 2001; Lind et al., 1998; Schmid 1989; Słowińska-Klencka et al., 2002; Solymosi et al., 2002). It should be remembered that the observed increase in the relative frequency of papillary carcinoma is partly attributed to the improving effectiveness of routine preoperative and postoperative morphological diagnostics that usually parallels introduction of iodine prophylaxis. It leads to more frequent revealing of papillary microcarcinoma and proper diagnosing of the follicular variant of papillary carcinoma without erroneous classification of such tumours into follicular carcinomas. The data from Sweden do not suggest any enhancing effect of iodisation on papillary carcinoma, since the increases in the incidence of such type of cancer were similar in both iodine-deficient and iodine-sufficient areas (Pettersson et al., 1996). Moreover, the correction of iodine deficiency rates virtually coincided in highly developed countries with the spread of thyroid ultrasound and biopsy, which have made diagnosis of clinically silent thyroid carcinoma more frequent. Thus, even though the incidence of thyroid carcinoma rose, the prognosis has significantly improved due to a shift towards differentiated forms of thyroid carcinomas that are diagnosed at earlier stages (Feldt-Rasmussen, 2001).

On the other hand, countries with high iodine supply are characterised by higher incidence of the thyroid autoimmune diseases, and especially of chronic thyroiditis. Our studies, carried to monitor side-effects of the introduction of iodine prophylaxis in Poland, showed that the occurrence of autoimmune stigmata in thyroid cytological smears were gradually increasing as iodine prophylaxis became more effective (Fig. 1) (Słowińska-Klencka et al., 2002; 2006). Similar observations were reported in a study from Greece by Doufas et al., (1999) and from Argentina by Harach & Williams (1995) (although during much longer intervals before and after introduction of iodine prophylaxis). It is believed that iodine intake might modulate the activity (and/or clinical expression) of thyroid autoimmune diseases in genetically susceptible individuals, but there is no evident proof that the amount of iodine intake - at least when in the range between iodine deficiency and full physiological doses - is involved in the de novo triggering of thyroid autoimmunity.

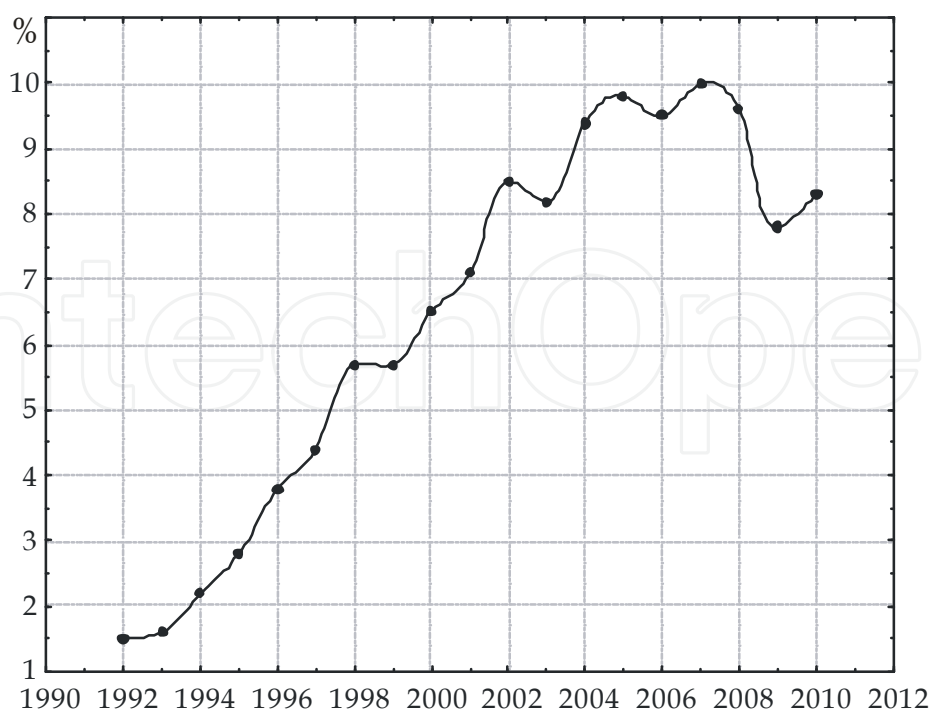


Fig. 1. The occurrence of chronic thyroiditis in cytological results in years 1992-2010 in one diagnostics centre in Poland. House-hold salt iodization was initiated in early 90's and in 1997 obligatory model of iodine prophylaxis (30 mg KI/kg of salt) was introduced.

### 3. Basic rules for diagnosing thyroid nodules

The need for an effective differential diagnostics of focal lesions in the thyroid comes from the necessity of an early diagnosis of thyroid cancer that even as a small lesion may show extrathyroidal invasiveness. The basic examination used for that purpose is fine-needle aspiration biopsy (FNAB). During the past years, many reports have been published indicating the usefulness of FNAB in the diagnosis of thyroid nodules. Fine-needle aspiration biopsy is a quick and, at the same time, the most sensitive examination in diagnosing thyroid nodules. The main advantages of FNAB are: the possibility of selecting patients for prompt surgical treatment, low invasiveness, and relatively low cost of examination (Faquin et al. 2011; Gharib et al., 2010; Lewis et al. 2009; Seningen et al., 2011). The management of thyroid nodule is usually based on cytological result which should always be interpreted together with other clinical data, mainly those related to the risk of cancer in the nodule. The clinical indications of the increased risk of cancer include: presence of hard painless nodule with diminished mobility (especially if the nodule causes hoarseness, dysphagia or dyspnoea), quick growth of the lesion as well as enlargement of the lymph nodes in the neck (Gharib et al., 2010; Wada et al., 2003). There are also other features of some importance in clinical suspicion of malignancy in a nodule: male sex, patient's age below 15-20 or above 60-70, history positive for neck irradiation or prolonged hyperstimulation of the thyroid with TSH (Belfiore et al., 1992; Hegedüs 2004; Kumar et al.; 1999; Samann et al., 1987; Schneider & Sarne, 2005). Familial history of thyroid cancer is of particular importance in relation to medullary cancer (MTC) as well as papillary cancer (PTC) (Kloos et al., 2009; Nose, 2011; Stoffer et al., 1986). The diagnosis of chronic thyroiditis is also of importance as it is considered to facilitate development of lymphoma of the

thyroid. Some investigators also believe that chronic thyroiditis is related to higher risk of papillary cancer (Azizi et al., 2011; Boi et al., 2005; Gul et al., 2010; Mukasa et al., 2011; Ruggiero et al., 2005; Shih et al., 2008; Singh et al., 1999; Słowińska-Klencka et al., 2006).

For proper interpretation of cytological smears it is also necessary to analyse the thyroid function and possible antithyroid treatment, as well as other laboratory results (like calcitonin serum concentration). Imaging examinations and oncological history (with possible chemo- and radiotherapy) should also be considered (Słowińska-Klencka et al., Gharib et al, 2010).

#### **4. Role of ultrasound imaging in diagnostics of thyroid nodules**

The thyroid ultrasonography (US) is the most common imaging examination of the gland. It allows to determine the precise size of the thyroid and to reveal non-palpable focal lesions. Despite of this, according to endocrine societies (American Thyroid Association – ATA, American Association of Clinical Endocrinologists – AACE and European Thyroid Association – ETA) guidelines, US is not recommended as a screening examination for patients without clinical data for the increased risk of cancer or clinical suspicion for any thyroid disease (Gharib et al, 2010).

Until recently, US was used in Europe more frequently than in the United States, and similarly US was more commonly used in Europe as a support to FNAB (Bennedbæk, 1999; Bennedbæk & Hegedüs 2000; Bonnema et al., 2000, 2002). At present it is proved that US assistance improves the diagnostic efficiency of FNAB in relation to both small and large, palpable lesions (Cesur et al., 2006). US allows to detect features suggestive of malignant growth and select the lesions to be recommended for FNAB. It also makes it possible to select the area of lesion optimal for FNAB (i.e. solid part free of areas of necrosis) and to choose the right gauge and length of the biopsy needle (Gharib et al., 2010). Because of its low invasiveness and possibility of multiple repeating in a patient, US is also useful for the assessment of goitre treatment effectiveness (both surgical and conservative) (Quadbeck et al., 2002). US examination is also used for diagnosing developmental disorders of the thyroid. In the cases of thyroid malignancy it allows to assess the completeness of thyroidectomy and the presence of possible local recurrence, as well as to control local lymph nodes (Frasoldati et al., 2003; Gharib et al., 2010; Hegedüs, 2001; Rago et al., 1998; Wong & Ahuja, 2005). It should be stressed that US does not allow by itself to differentiate between benign and malignant thyroid lesions (Gharib et al., 2010; Hegedüs, 2001).

##### **4.1 Role of ultrasound imaging in selection of thyroid lesions for FNAB – A new approach**

The precise indications for FNAB of thyroid lesions are still being investigated. The main criteria considered include sonographic features of nodules like the size, shape and echogenicity of lesions, the vascular pattern in Doppler imaging, the presence of microcalcifications and appearance of lesion's borders (Alexander et al., 2004; Frates et al., 2005; Gharib et al., 2010; Nam-Goong et al., 2004; Papini et al., 2002; 12–16; Tae et al., 2007). Current recommendations on the diagnostics of thyroid nodules take into consideration the similar frequency of revealing thyroid cancer in FNAB of small vs. large nodules (Berker et al., 2008; Nam-Goong et al., 2004; Papini et al., 2002), palpable vs. non-palpable nodules (Papini et al., 2002; Popowicz et al., 2009; Hagag et al., 1998) as well as solitary vs. multiple



nodules (Belfiore et al., 1992; Frates et al., 2006). In consequence, the recommendations focus on US features related to the increased risk of malignancy, and not on the size nor palpability of the nodule, which were important criteria in the previous recommendations. Interestingly, attention is paid to US features allowing to identify invasive cancers including those growing in very small lesions. Some recent papers have brought convincing data on the high percentage of carcinomas (some of them with extrathyroidal invasion) in small lesions subjected to FNAB (Kang et al., 2004; E.K. Kim et al., 2002; S.J. Kim et al., 2003; Leenhardt et al., 1999; Lin et al., 2005; Nam-Goong et al., 2004; Papini et al., 2002). The majority of these reports come from the countries with natural high iodine supply (Japan, Korea) or those with long-established iodine prophylaxis. However, our data from the post-endemic region confirm these observations. In our material, the frequency of revealed small and large cancers was proportional to the frequency of the biopsied nodules of each size class, and approx. 1/3 of cytologically revealed thyroid microcancers metastasized to lymph nodes (Słowińska-Klencka et al., 2008).

Analysis of the reported studies justifies division of the known US features suggestive of malignancy into 2 groups of high and low specificity.

The highly specific US features in selection of thyroid lesions for FNAB include:

1. features of metastasis in the lymph nodes;
2. features of the thyroid capsule (or neighbouring organs) invasion;
3. microcalcifications (small, intranodular, punctate, hyperechoic spots with scanty or no posterior acoustic shadowing).

The features of lower specificity include:

1. irregular or microlobulated margins;
2. more tall (anteroposterior) than wide (transverse) shape;
3. marked hypoechogenicity;
4. chaotic arrangement or intranodular vascular images.

It should be stressed that the assessment of these features is yet not enough standardized, and because of their qualitative or semi-quantitative nature their reproducibility is not satisfactory (especially when sonographer lacks experience).

According to our observations and some other studies, there are differences in sensitivity and specificity of these features in respect of nodule size (Popowicz et al., 2008; Mazzaferri & Sipos, 2008). The influence of epidemiological situation (mainly iodine supply) on the specificity and sensitivity of these features is also underestimated.

The most sensitive feature of malignancy is hypoechogenicity, both for small and large lesions. Unfortunately, the specificity of this feature is low, especially in small nodules – majority of benign lesions (especially the small ones) is hypoechoic (Moon et al., 2008; Cappelli et al., 2006, 2007; Chan et al., 2003; Frates et al., 2005, 2006; E.K. Kim et al., 2002; Leenhardt et al., 1999; Lyshchik et al., 2005; Nam-Goong et al., 2004; Papini et al., 2002). Interestingly, in our material, all invasive microcarcinomas (with the signs of extrathyroidal growth or with spread to lymph nodes) were hypoechoic in the US examination (Popowicz et al., 2009). The role of hypoechogenicity, in revealing aggressive variants of microcarcinomas, was also indicated by Barbaro et al. (2005).

The most specific single feature is the presence of microcalcifications in the lesion (Cappelli et al., 2006, 2007; Chan et al., 2003; Frates et al., 2005, 2006; Iannuccilli et al., 2004; E.K. Kim et al., 2002; Moon et al., 2008; Nam-Goong et al., 2004; Papini et al., 2002; Rago et al., 2007). It increases tenfold the risk of cancer, but the sensitivity of this feature is low, particularly in

group of nodules not exceeding 10 mm (Popowicz et al., 2009). Similar results were obtained by Moon et al., (2008).

Less but still significantly predictive is the shape index (Alexander et al., 2004; Berker et al., 2008; Cappelli et al., 2006; E.K. Kim et al., 2002; Moon et al., 2008). Our analysis shows that the features describing the shape of lesion are useful mainly in the diagnostics of small nodules (Popowicz et al., 2009). Similar results with respect to the ratio of long to short axis of a lesion were reported by Berker et al. (Berker et al., 2008). The shape of larger lesions is a less sensitive feature probably because such lesions are more frequently partially cystic, and as such are more spherical even if benign.

With respect to the assessment of blood flow pattern, the published opinions are contradictory with some reporting that Doppler US is helpful (Papini et al., 2002; Moon et al., 2008; Cappelli et al., 2007; Chan et al., 2003; Lyshchik et al., 2005; Levine, 2006), and others reporting that Doppler US did not satisfactory improve diagnostic accuracy (Nam-Goong et al., 2004; Frates et al., 2003; Iannuccilli et al., 2004; Rago et al., 1998). Even though the logistic analysis of regression allows classification of intranodular vascular pattern as an independent feature suggesting malignancy, the OR is several times lower than for other features (Cappelli et al., 2007).

It is difficult to apprehend the role of lesion's borders assessment because there are significant differences in the definition of suspected appearance of borders. Some researchers, such as Nam-Gong et al., (2004), suggested that ill-defined nodules were important for predicting malignancies, while others (E.K. Kim et al., 2002, Cappelli et al., 2006, 2007 and Kang et al., 2004) suggested that irregular margins were important. Moreover, some authors reported that the presence of blurred margins was not significantly linked to malignancy of lesions (Leenhardt et al., 1999; Frates et al., 2006; Iannuccilli et al., 2004), or that well-defined margins were a common sonographic feature in papillary carcinomas (Chan et al., 2003).

Up to now, any single criterion of selecting lesions for FNAB was not found to be satisfactory. The analysis of usefulness of feature combinations brought diverse results, both in terms of specificity and sensitivity of such a set of features, and the possible reduction in the number of performed FNABs. This reduction is of particular importance in endemic areas where it determines economic effectiveness of cytological examination. Because of high predominance of benign thyroid lesions in such areas, the number of performed FNABs is very high in relation to the number of revealed cancers.

The current recommendations try to relate the indications for FNAB to predictive value of particular features and the size of lesion: the lower predictive value of a feature, the larger lesion that should be selected for FNAB (Gharib et al., 2010). However, in the setting of endemic goitre it is very difficult, if not impossible, to follow the recommendation to examine all solid hypoechoic lesions of diameter above 1 cm. Large number of such lesions makes their further selection a must. Thus it is important to underline the role of US examination in prioritization of lesions. In the cases of multiple thyroid nodules it is advisable to biopsy those lesions which are positive for a highly specific feature and those positive for several features of lower value.

The available recommendations suggest the number of lesions that should be biopsied in order to satisfactory exclude the risk of malignancy in the multiple nodular goitre (according to ATA/AACE/ETA - 2 lesions, and according to Polish recommendations, relating to postendemic area - 3-4 lesions) (Gharib et al., 2010; Sporny et al., 2010). However, such

suggestions are the results of experts' consensus. There are few studies addressing this issue (Frates et al. 2006), and the mean number of lesions in goitre to be examined differs significantly between iodine rich and iodine deficient areas. Anyway it is justified to subject lesions to FNAB in the order resulting from the predictive value and number of positive US features.

In this context it should be mentioned that current recommendations indicate also negative features, i.e. those which allow to resign from biopsy. It is justified not to perform FNAB in the cases of purely cystic nodules, spongiform nodules, or autonomic nodules in patient with low TSH levels (Bonavita et al., 2009; Gharib et al., 2010).

The current recommendations underline the necessity of proper selection of the area within examined lesions that should be biopsied. In the case of cystic-solid lesions it is indicated to biopsy the solid part and to evaluate any fluid evacuated from the cystic part. Our experience shows that the use of cytological centrifuge for preparation of fluid significantly lowers the percentage of non-diagnostic outcomes (Słowińska-Klencka et al. 2004). In the case of solid lesions the biopsy of central part should be avoided as there is higher probability of necrosis in that area. In the case of large nodules it is recommended to perform at least 2 aspirations from various areas of the lesion.

#### **4.2 Role of ultrasound imaging in diagnostics of thyroid lesions of size < 5 mm**

The current recommendations distinguish the category of lesions of diameter below 5 mm. It is indicated to monitor such lesions with US examinations including the evaluation of features that can be helpful in revealing invasive microcancers or in making decision of FNAB. Such recommendation is based on several rationales: lower accuracy of US features evaluation in such small lesions, higher probability of missing lesion during aspiration (especially in dorsal location of lesion), and lower clinical aggressiveness of cancers smaller than 5 mm (Mazzaferri & Sipos, 2008). Obviously, there are exceptions related to particular indications for FNAB including: extrathyroidal growth of nodule (extracapsular invasion, lymph nodes involvement or metastases); positive history of neck irradiation in childhood or adolescence; papillary thyroid cancers, medullary thyroid cancers, or multiple endocrine neoplasia type 2 in first-degree relatives; previous thyroid surgery for cancer; increased calcitonin levels in the absence of interfering factors (Berker et al., 2008; Mazzaferri & Sipos, 2008; D.W. Kim et al., 2009; Kwak et al., 2008). Among features suggestive of the increased risk of invasive papillary cancer in lesion there are: shaping of the thyroid capsule by lesion or lesion abutting the capsule, and features of the lymph nodes involvement (Kwak et al., 2008; Ito & Miyauchi, 2009). It should be stressed that predictive value of the latter is very diverse, and the highest specificity is found for the presence of calcifications or cystic degeneration (relating to areas of necrosis) in the lymph nodes (Leboulleux et al., 2007; Sipos, 2009). Some investigators suggest that such data from US examination may be also useful in the selection of optimal treatment strategy, and according to Ito et al., (2003, 2009) careful US examinations of patients with small nodules may even allow refraining from surgical treatment in some cases of papillary microcancers. However, such management is not recommended by ATA, AACE nor ETA.

### **5. Efficacy of FNAB of thyroid nodules in the areas of various iodine supply**

The above mentioned differences between areas of various iodine supply in the incidence of thyroid nodules, their solitary and multiple occurrence, as well as distribution of particular



pathological lesions, significantly affect the efficacy of preoperative diagnoses of thyroid nodules.

Our group performed one of few studies on the effectiveness of FNAB of thyroid nodules in areas with newly corrected iodine supply. It was a retrospective analysis of US examination and FNAB on a large series of thyroid glands, performed in a single diagnostic centre. The analysis included the outcomes of FNABs performed in years 1985-2010, and obligatory iodine prophylaxis using household salt iodized with 30 mg KI/kg was established in Poland in 1997. Earlier, iodine prophylaxis was carried out with numerous discontinuations from 1930s until 1980, when it was dropped. In the years 1992-1993, a nationwide study performed in about 20 000 schoolchildren, showed that Poland was an area of mild or moderate iodine deficiency (Szybiński & Żarnecki, 1993). About this time salt iodization was partially reintroduced and iodine supply gradually increased. Reevaluation of iodine status of Polish population in early 2000s proved the efficacy of iodine prophylaxis by showing normalization of ioduria, rapid decrease in the incidence of goitre in schoolchildren and lowering the percentage of newborns with transient hyperthyrotropinemia ( $TSH > 5 \text{ mU/L}$ ) (Szybiński et al., 2008).

In total nearly 40,000 FNAB results were analysed, and in more than 6000 patients those results were verified by histopathological examination. It was found that in endemic areas the number of performed FNABs was very high in relation to the number of revealed cancers, despite of adhering to the recommendations for selection of lesions for FNAB. This is a consequence of high incidence of multiple mostly benign lesions. As a result, the frequency of outcomes in the category of benign lesions is higher than in iodine-rich areas. The suspicious or malignant lesions constitute  $< 10\%$  of all cytological results (Słowińska-Klencka et al., 2002, 2008) while in areas of a long-term normal iodine supply this percentage reaches 20-30% (D.L. Kim et al., 2008; Nam-Goong et al., 2004). Moreover, in endemic or post-endemic areas the rate of malignant lesions in post-operative histopathological examination is relatively low. In our material, such rate was only 7% while in areas of high iodine supply it is several times higher. This difference results from a high number of patients in iodine-deficient areas who are referred to a surgeon not because of the suspicious FNAB outcome – only about 20% of the patients in our series – but because of large multinodular goitre, notwithstanding the benign outcome of FNAB (Słowińska-Klencka et al., 2008).

### **5.1 Efficacy of selection of thyroid nodules for FNAB in areas of various iodine supply**

In endemic areas it is more difficult to select lesions that should be biopsied, and the probability of wrong selection affects especially small lesions. Small nodules are usually accompanied by other, often larger lesions, which are more frequently chosen for FNAB. As a result, the efficacy of preoperative diagnoses of small carcinomas in endemic areas is significantly lower than in the case of larger malignant tumours (Popowicz et al., 2009; Słowińska-Klencka et al., 2008). These differences are deepened by the fact that in the areas of iodine sufficiency the reported percentages of false negative (FN) results are falsely lowered, as FNAB outcomes are frequently verified not against histopathological examination but clinical follow-up. In such areas patients with cytologically diagnosed benign lesions, without goitre are not usually surgically treated, and as a result there may be some misdiagnosed cases of thyroid microcarcinomas in that group of patients (Theoharis et al., 2009). In endemic areas many patients are subjected to thyroidectomy because of large

multinodular goitre and then some microcancers are revealed in lesions that were not selected for FNAB nor even identified in US examination.

In respect to described differences, in the regions of a high number of patients with multinodular goitre, it seems reasonable to use more powerful and rigorous criteria for selecting lesions for FNAB. Such criteria should allow to optimize the number of performed FNABs in relation to the number of revealed cancers and, in particular, should allow to diagnose invasive cancers. Our study showed that some indolent cancers, which probably never become aggressive, were revealed, but some invasive microcancers were missed (Popowicz et al., 2009; Słowińska-Klencka et al., 2008). It could be helpful to use the more specific set of features for diagnosing invasive thyroid carcinoma but an optimal definition of such a set is still being sought. E.K. Kim et al., (2002) reported that reduction number of performed FNABs by 47%, with 94% sensitivity and 66% specificity, could be achieved by selecting lesions fulfilling the shape criterion or those with microcalcifications, irregular or microlobulated margins or marked hypoechogenicity (relative to the strap muscles in the neck). Those data come from areas of high-iodine supply and low incidence of multinodular goitre. In our material from the area of recently corrected iodine supply, it was found that similar reduction in the number of performed FNABs is possible on the condition of exclusion of hypoechogenicity from the set of selection criteria. Examination of lesions more tall than wide only, or those with microcalcification or solitary ones, would allow limitation of the number of biopsies by 50% while keeping sensitivity above 80%. However, it would increase the risk of misdiagnosing small invasive thyroid cancers (in our material all invasive small cancers were hypoechoic) (Popowicz et al., 2009). It is possible that application of 'marked hypoechogenicity' feature would allow avoidance of that risk. In our material the achieving of above 90% sensitivity in the group of small lesions (<10 mm) was possible if all hypoechoic nodules or those with suspected shape were selected for FNAB. Such selection could lower the number of performed biopsies by 28%. The addition of all solitary nodules and all nodules with microcalcifications would not increase the number of examinations significantly, but would allow for biopsying 98% of malignant lesions (Popowicz et al., 2009). Similar results were reported by other authors who used the selection criteria as the shape of lesions jointly with other features from the US examination as the selection criteria. Cappelli et al., (2006) showed that 99% sensitivity can be achieved by aspiration of lesions more tall than wide and possessing at least two of the following features: hypoechogenicity, blurred margins and calcifications. The authors claimed that by applying such criteria, the number of performed FNABs could be lowered by 28%.

Most diagnostic algorithms suggest performing FNAB for solid, hypoechoic lesions with diameters over 10 mm, even in the absence of any other features suggesting the increased risk of cancer (Baloch et al., 2008; Gharib et al., 2010; Layfield et al., 2010). But in the case of large multinodular goitre, it is necessary to select large lesions for biopsy as well. Our studies showed that in the case of large nodules, the usefulness of sonographic features in selecting lesions for FNAB was less satisfactory than in the case of small ones. The sensitivity of selection of nearly 84% could be achieved by biopsying all hypoechoic or containing microcalcifications nodules or with the positive shape index, which would lower the number of FNAB by more than 55% (Popowicz et al., 2009).

It is also worth mentioning that in the majority of the reports, the influence of nodule size on the optimal set of features for selecting lesions for FNAB was not investigated. Only Cappelli et al., (2006) observed that the associations of US features with malignancy were

similar in groups of large and small lesions. On the other hand, Lyshchik et al., (2005) and Berker et al., (2008) found that the usefulness of sonographic features in selecting lesions for FNAB in the group of larger nodules was lower than in the group of smaller ones, and that for thyroid nodules larger than 15 mm (Lyshchik) or than 10 mm (Berker) the only reliable criterion of cancer was hypoechogenicity. Moon et al., (2008) reported that a set of US features suggestive of malignancy (i.e. the presence of at least one of the findings including taller than wide shape, speculated margin, hypoechogenicity and the presence of calcifications) showed lower sensitivity and higher specificity for nodules >10 mm than for smaller nodules, which is in concordance with our data.

The discussed epidemiological differences may also attribute to the observed differences in the frequency of obtaining non-diagnostic material from small lesions. The data on the efficacy of FNAB in obtaining diagnostic cellular material from small thyroid lesions are equivocal. Some reports suggest that the smaller the size of aspirated lesion the higher the rate of inadequate specimens (Cesur et al., 2006; Lee et al., 2006; Sahin et al., 2006). Other reports from Japan and Korea suggest that if the staff performing FNAB of the thyroid is experienced enough, it is possible to aspirate reliably even very small lesions – with diameters of 2–3 mm (D.W. Kim, et al., 2009; Nam-Goong et al., 2004; Yang et al., 2002). In these Asian countries, specialists more often diagnose very small thyroid lesions which – because of the specific epidemiological situation – less frequently coexist with other larger lesions but are microcarcinomas more frequently than in the countries with low iodine supply.

## **5.2 Influence of iodine status of population on clinical interpretation of cytological results**

The proper selection of lesions for biopsy is one of the important components influencing the effectiveness of this examination. Another is an epidemiological situation of examined populations which affects the incidences of follicular lesions (follicular adenomas and carcinomas as well as hyperplastic nodules in nodular goitre) and papillary cancers (Feldt-Rasmussen, 2001; Słowińska-Klencka et al., 2002).

FNAB does not allow for differentiation among certain forms of nodular goitre, follicular adenoma, follicular carcinoma and frequently also follicular variant of papillary carcinoma of the thyroid. This problem is the main limitation of FNAB diagnostics, especially in endemic regions. Consequently, in clinical practice, the cytological diagnoses of ‘follicular neoplasm’ and, especially, of ‘Hürthle cell tumour’ are frequently regarded as an indication for surgical treatment. However in the areas of long-term iodine deficiency, the consideration of ‘follicular neoplasms’ results as an indicator of malignancy yields a significant increase in false positive results. In our material, in which ‘follicular neoplasm’ corresponds more frequently to non-neoplastic hyperplastic nodules or follicular adenoma than to thyroid cancers, such interpretation puts false positive results in range 10–12% (Słowińska-Klencka et al., 2002, 2008). This is the reason for low positive predictive value of FNAB in such areas. In iodine-rich areas ‘follicular neoplasm’ diagnosis corresponds more frequently to follicular variant of papillary cancer.

Follicular cancer constituted 30% of all malignant tumours found in postoperative histopathological examination in patients who underwent FNAB at our centre before introduction of salt iodization, while 10 years later that percentage dropped to 6–7%. Parallel decrease in frequency of follicular adenoma was also observed. Papillary cancer constituted

about 45% of all malignant tumours in the first period and 75% in the second one (Słowińska-Klencka et al., 2002, 2008). Such marked changes over relatively short time may be attributed not only to the increased iodine supply but also to erroneous classification of follicular variant of papillary cancer in the earlier period. As it was already mentioned, an introduction of iodine prophylaxis is often accompanied by the increased interest in the thyroid diseases what improves the standards of histopathological examination. Analysis of the cytological results in our centre over the discussed period showed the gradual decrease in frequency of cytological results, applying to ‘follicular neoplasm’, while the frequency of diagnoses of oxyphilic variant of those neoplasms remained nearly constant (Fig. 2).

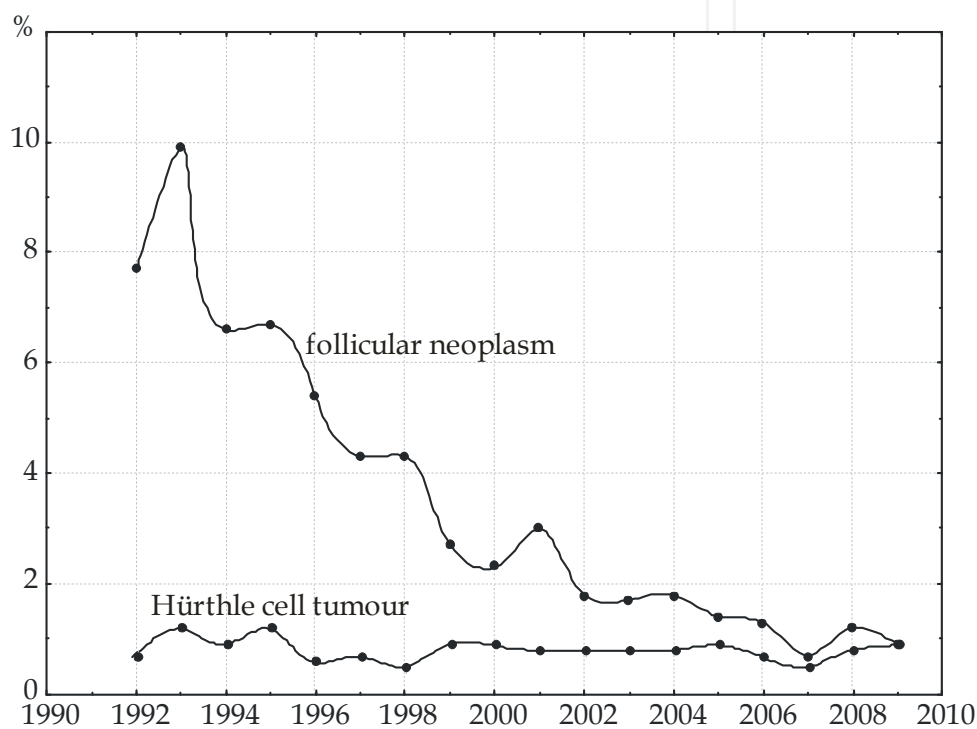


Fig. 2. The occurrence of cytological diagnoses of follicular neoplasm and Hürthle cell tumour

Interestingly, in the analysed period the risk of revealing cancer in postoperative histopathological examination in nodules diagnosed cytologically as ‘follicular neoplasm’ dropped from above 15% to below 8%. Those lesions more frequently were found to be hyperplastic nodules in histopathological examination. The decrease in occurrence of cancers in lesions with cytological diagnosis of ‘follicular neoplasm’ was more pronounced than the decrease in frequency of formulating this cytological diagnosis (Słowińska-Klencka et al., 2002, 2008). It should be kept in mind that such lowering of the risk of cancer is transient. In regions of recently established iodine prophylaxis the risk of thyroid cancer in a lesion described in FNAB as ‘follicular neoplasm’ is lower than in regions of constant sufficient iodine supply, where thyroid nodules are rarer but more frequently malignant (Baloch et al., 2002; Mihai et al., 2009).

Our data also show that if ‘follicular neoplasm’ in cytological outcome was assumed as a negative result with respect to cancer diagnosis it would cause a twofold increase in the number of undiagnosed cancers >10 mm and only 15% increase in the case of



infracentimetric cancers. Thus, it seems that in the regions of recently normalized iodine supply, in patients with such cytological outcome the surgical treatment may be postponed only in the case of small lesions (Słowińska-Klencka et al., 2008).

Other reports also show that the size of lesion is important feature in the assessment of probability of thyroid cancer in patients with cytological diagnosis of follicular neoplasm. Lubitz et al., (2010), Mihai et al., 2009; Schlinkert et al., (1997) and Tuttle et al., (1998) indicate that the size above 4 cm is significant; Baloch et al., (2002) - above 3 cm.

Concluding, it is reasonable to individualize indications for surgical treatment – particularly in countries with similar to Polish epidemiological situation, where the risk of cancer in lesion diagnosed as ‘follicular neoplasm’ is relatively low (<10%). It seems that in such cases small lesions can be treated conservatively providing the strict clinical follow-up is assured with US monitoring. It should be stressed that even in such areas the risk of cancer in the case of cytological diagnosis of ‘Hürthle cell neoplasm’ is high and reaches 20-30% (Słowińska-Klencka et al., 2002). The similar data on the difference in the risk of cancer between cytologically diagnosed follicular and oxyphilic neoplasms were reported by Sangalli et al., (2006) and Baloch et al., (2002). Thus, in our opinion, if FNAB outcome suggests ‘Hürthle cell tumour’ indications for surgical treatment are stronger. On the other hand, Pu et al., (2006), Sorrenti et al., (2009) and Theoharis et al., 2009 found no difference between such lesions regarding the rate of malignancy. However, Sorrenti et al., (2009) correctly mentions that more aggressive cancers tend to occur in patients with ‘Hürthle cell neoplasm’ than in persons with ‘follicular neoplasm’ diagnosed cytologically.

### **5.3 New classification of thyroid FNAB results - the impact on frequency of particular diagnoses from follicular lesions in postendemic area**

The most recent recommendations for diagnostics of thyroid nodules permit centres with specific experience in thyroid cytology to divide diagnoses of follicular lesions into ‘follicular lesion of undetermined significance’ and ‘follicular neoplasm’ categories (Baloch et al., 2008; Gharib et al., 2010; Layfield et al., 2010). This distinction separates 2 cytologic groups at different risk for thyroid malignancy. At our centre similar distinction was introduced earlier – in some cases the cytopathologist tried to determine more precisely the benign character of the lesion by formulating the result as ‘follicular neoplasm – probably adenoma’ (Słowińska-Klencka et al., 2002). However, the current guidelines of National Institute of Cancer (NCI) assume wider definition of this particular diagnostic category. According to NCI ‘follicular lesion of undetermined significance’ is a heterogeneous category, which reflects the difficulty in the cytological diagnosis of the follicular lesions of the thyroid. It includes cases in which the cytomorphological findings are not representative of a benign lesion such as a hyperplastic / adenomatoid nodule, yet the degree of cellular or architectural atypia is not sufficient to render an interpretation of follicular neoplasm / suspicious for a follicular neoplasm or suspicious for malignancy. This diagnosis may also be used in thyroid FNAB specimens that are less than optimal due to limited cellularity, poor fixation and obscuring blood (Baloch et al., 2008; Layfield et al., 2010). The main reason for using this diagnostic category was to recommend a repeated FNAB in 3-12 months for these cases rather than surgical excision. The correlation of FNAB outcomes with the results of subsequent US examinations, or radio-nucleotide uptake studies may be helpful in improving the positive predictive value of that ‘indeterminate’ category.



We assessed the influence of the application of new classification of the thyroid cytological outcomes in postendemic area in respect to follicular lesions from which monomorphic thyroid follicular cells (tfc) (comprising oxyphilic cells) arranged in three-dimensional groups including microfollicles were aspirated. The analysis covered 2 periods: year 2009 and the period between May 2010 and February 2011. In the later period new classification of thyroid FNAB outcomes was used that was based on NCI classification with exclusion of cases with low cellularity from “follicular lesion of undetermined significance” subgroup. It was found that in both examined periods incidence of aspirates with monomorphic tfc was similar: 4.5% and 4.4% respectively. However the introduction of the subcategory of “follicular lesion of undetermined significance” significantly decreased the percentage of FNAB outcomes without diagnostic conclusion ( $p<0.0001$ ,  $\chi^2$  test) (Table 1). Thus, it seems that the introduction of this new category of FNAB results makes it easier for endocrinologists to choose proper therapeutic options, especially in postendemic areas.

2009		V 2010 - II 2011	
Cytological results	No/%	Cytological results	No/%
Monomorphic tfc without conclusion	168/72.1%	Monomorphic tfc without conclusion - usually low cellularity smears	66/30.4%
Benign follicular nodule	10/4.3%	Benign follicular nodule	4/1.8%
Follicular neoplasm probably benign	6/2.6%	Follicular lesion of undetermined significance	106/48.9%
Follicular neoplasm	21/9.0%	Suspicious for a follicular neoplasm	21/9.7%
Follicular neoplasm Hürthle cell type probably benign	0/0.0%	Follicular lesion of undetermined significance Hürthle cell type	3/1.4%
Follicular neoplasm Hürthle cell type	28/12.0%	Suspicious for a follicular neoplasm Hürthle cell type	17/7.8%
Number of follicular lesions	233/100.0%	Number of follicular lesions	217/100.0%

Table 1. Comparison of cytological outcomes from thyroid nodules, where monomorphic tfc dominated in aspirates, formulated in 2 periods: year 2009 and between May 2010 and February 2011. In the later period new classification of thyroid FNAB outcomes was used.

Also Theoharis et al., (2009) found that the new approach of reporting thyroid FNA proposed by the NCI is advantageous in patients who may harbor a follicular or Hürthle cell neoplasm as it allows the reporting cytopathologists to express their level of concern of the possibility of an underlying malignancy to guide subsequent patient management.

**5.4 Increased incidence of Hashimoto disease in endemic areas and the risk of FNAB false results**

As it was already mentioned, the increase in iodine supply in endemic area is related to the increase in the incidence of chronic thyroiditis. It significantly affects the efficacy of morphological diagnostics of the thyroid. Noticeable anisocytosis of follicular cells observed in some cases of chronic thyroiditis can lead to an increased number of false positive (FP) results of FNAB. Additionally, marked hypoechogenecity and heterogeneity of the thyroid in US

scans poses difficulties in revealing any focal lesions. Another important issue is a coincidence of papillary cancer and chronic thyroiditis, which is indicated by numerous investigators, and makes cytological diagnostics of patients with Hashimoto disease even more challenging (Azizi et al., 2011; Cipolla et al., 2005; Gul et al., 2010; Liu et al., 2001; Mukasa et al., 2011; Ruggiero et al., 2005; Shih et al., 2008; Singh et al., 1999; Słowińska-Klencka et al., 2006).

In our material the frequency of papillary carcinoma diagnosed in postoperative histopathological examination was higher in the group of patients with cytologically confirmed chronic thyroiditis than in the group of patients with non-inflammatory benign lesion found in FANB (Słowińska-Klencka et al., 2006). There are also reports indicating the relation between the increased titres of antithyroid antibodies and the increased probability of obtaining FANB outcome which suggests or confirms thyroid malignancy (Boi et al., 2005). It was also shown that the risk of thyroid cancers is positively correlated to TSH levels even in its normal range (Boelaert et al., 2006, 2009), and chronic thyroiditis is main reason for the increase of TSH levels. Even without judging whether chronic thyroiditis facilitates the growth of papillary cancer, or rather lymphocytic infiltration is a kind of response to growing tumour, it can be concluded that patients with Hashimoto disease should be followed-up with a particular attention (Gul et al., 2010; Okayasu et al., 1995). It should be also kept in mind that chronic thyroiditis is regarded as a risk factor for malignant lymphoma of the thyroid (Holm et al., 1985; Matsuzuka et al., 1995).

### **5.5 Differences in statistical approach to the evaluation of FNAB efficacy**

The differences described above in epidemiological situations of examined populations result in significant differences in the reported data on FP and false negative (FN) results, as well as sensitivity (from 65 to 98%) and specificity (from 72 to 100%) of the thyroid FNAB (Gharib et al., 2010). Another important source of these differences comes from the statistical approaches to the evaluation of FNAB data, which vary among authors, thus making the reported results hardly comparable (Słowińska-Klencka et al., 2002). Some authors exclude the so-called intermediate results (differently defined) from statistical analysis, while others exclude only the specific cases (e.g. exclusion from FP result, cases corresponding to follicular adenoma in histopathological examination or exclusion from FN results cases of papillary microcarcinomas incidentally found in postoperative histopathological examination) (Cap et al., 1999; La Rosa et al., 1991). This problem is further discussed in the papers by Lewis et al., (2009) and Theoharis et al., (2009).

There is a general agreement that in regions of endemic goitre (with an increased incidence of follicular neoplasms), a high number of FP results should be accepted and negative results should be optimised (Papanicolaou Society of Cytopathology, 1996). FN results may delay the institution of appropriate treatment. On the other hand, it should be kept in mind that the real rate of FN results of FNAB could be masked by the relatively high percentage of patients with cytologically diagnosed benign lesions who are not surgically treated, while differentiated carcinoma need not progress for years.

## **6. Rules of monitoring benign lesions – Its efficacy in relation to iodine supply**

Cytological diagnosis of benign lesion is related to very low risk of malignancy (1-2% in the case of US-guided FNAB), on condition that such diagnosis is formulated only if smears

satisfy strict quality criteria (Gharib et al., 2010). Assuming that these criteria were followed and the aspirated material was obtained from the examined lesion, there is no need to repeat FNAB unless changes in US image or other clinical data suggest the otherwise. It should be remembered that clinical decisions based on such cytological diagnosis should be limited to that particular lesion, and cannot be extended on other lesions. In the presence of any doubts it is justified to repeat FNAB after 6-12 months especially in lesions presenting some US features suggestive of malignancy (Kwak et al., 2010).

Opponents against performing control FNABs even in the cases of non-progressing nodule, indicate that such examination usually does not significantly change the cytological category of examined lesion, it lowers economic efficiency of thyroid diagnostics, and it unnecessarily stimulates the fear of cancer in patient (Aguilar et al., 1998; Lucas et al., 1995; Merchant et al., 2000). On the other hand, there are proponents of control FNABs, who indicate that 1-3 control FNABs lower the risk of false negative results related to missing examined lesion (particularly small or dorsally located) (Flanagan et al., 2006; Gabalec et al., 2009; Hamburger 1987; Illouz et al. 2007; Orlandi et al. 2005). Some investigators suggest to perform follow-up FNA only in a selected group of patients with clinically suspicious symptoms (Chehade et al., 2001; Erdogan et al., 1998; Oertel et al., 2007; van Roosmalen et al., 2010).

Analysis of our material showed that performing one control FNAB increases diagnostic efficacy of cytological examination in respect to diagnosing cancer. Next control FNABs do not change the cytological category of examined lesion if no US/clinical signs of progression are observed (Słowińska-Klencka et al., 2001). In the case of very long follow-up (10 years or more), it seems less rational to limit the number of performed FNABs to 1 or 2, but there are no recommendations addressing this question.

If quality criteria of smears are not satisfied FNAB should be classified as non-diagnostic. With such cytological outcome decision on surgical treatment must be based on the presence of clinical features suggesting the increased risk of cancer. If conservative treatment is undertaken, next biopsy should be performed within 3-12 months. Interpretation of non-diagnostic biopsy should include clinical context as some thyroid diseases are related to difficulties in obtaining material satisfying all quality criteria (e.g. chronic thyroiditis, colloid nodule). If two subsequent examinations give non-diagnostic material then an individual clinical assessment of the risk of cancer in the evaluated lesion should be performed. It seems that solid lesions should be more readily treated surgically while mixed, cystic-solid lesions may be observed (with possibility of surgical treatment in future). According to British Thyroid Association [BTA] (2007) guidelines, clinical attention should be increased if there are blood cells and histiocytes in smear and thyroid follicular cells are absent. BTA advises to regard such smears as more suspicious than those without follicular cells but with dominating colloid. According to our data, the frequency of histopathologically diagnosed neoplasms (both malignant and benign) in solid lesions is higher in the case of lesions from which non-diagnostic material was obtained twice in comparison with lesions that showed diagnostic material in the repeated (second) FNAB. No similar difference was noted in relation to malignant neoplasms only. However, the risk of diagnosing cancer in postoperative examination was higher than in lesions with diagnostic cytological outcome (classified as benign) – about 7% vs. 2%, respectively (Słowińska-Klencka et al., 2004). Others reported similar data (Orija et al., 2007). There is a general agreement that 'pure cystic' lesions should be treated conservatively because of low risk of malignancy.

Additional difficulty in areas of iodine deficiency is related to follow-up of multiple thyroid nodules which can be easily misidentified in control ultrasound examinations. As indications for FNAB are based on US features of revealed lesions, it is very important to clearly describe in US report as many identified lesions as possible, with precise description of their location, size and features used for selection to FNAB. The US report should not be limited to the description of a dominant lesion, and report of US-guided FNAB should allow to identify biopsied lesion in other diagnostic centre (Gharib et al., 2010). It is advisable to attach to FNAB result the US report with description of lesions that have been biopsied. Such joined report allows to compare US features of lesions during control examination. This is particularly important in endemic areas where it may be difficult to identify lesion among many others in multiple nodular goitre.

## 7. Conclusions

In the endemic areas the typical ultrasound criteria for selection of lesions for FNAB are inefficient. The number of performed FNABs is very high in relation to the number of revealed cancers, but in spite of this, some invasive cancers are missed. On the other hand, some indolent cancers, which probably never become aggressive, are revealed. In the regions of a high number of patients with multinodular goitre, it seems reasonable to use more powerful and rigorous criteria for selecting lesions for FNAB that would allow to improve diagnostic and economic effectiveness of biopsy. Such criteria must include features with higher predictive value instead of or along with features with high sensitivity but low specificity (like nodule hypoechogenicity).

In iodine-deficient areas in order to increase the chances of early detection of small invasive cancers, it seems particularly reasonable to follow up small lesions revealed in the thyroid with repeated US examinations. That allows detection of any significant changes in lesion image and lesion relationship with the thyroid capsule as well as evaluation of lymph nodes in the neck.

While clinically interpreting the results of cytological examination, the iodine status of examined population should be considered. Changes in the iodine status of a given population promptly influence the clinical significance of particular cytological results. In such circumstances, special attention is advised from both the cytologist and the thyroidologist.

Concluding, the clinical management of thyroid nodules in areas of high, sufficient or inadequate iodine supply is not fully comparable.

## 8. References

- Aguilar, J.; Rodriguez, J.M.; Flores, B.; Sola, J.; Bas, A.; Soria, T.; Ramirez, P. & Parrilla, P. (1998). Value of repeated fine-needle aspiration cytology and cytologic experience on the management of thyroid nodules. *Otolaryngology Head and Neck Surgery* Vol.119, No.1, (July 1998), pp. 121-124, ISSN 1916-0216
- Alexander, E.K.; Marqusee, E.; Orcutt, J.; Benson, C.B.; Frates, M.C.; Doubilet, P.M.; Cibas, E.S.; & Atri, A. (2004). Thyroid nodule shape and prediction of malignancy. *Thyroid*, Vol.14, No.11, (2004), pp. 953-958, ISSN 2042-0072
- Azizi, G. & Malchoff, C.D. (2011). Autoimmune thyroid disease: a risk factor for thyroid cancer. *Endocrine Practice*, Vo.17, No.2, (March 2011), pp. 201-209, ISSN 1530-891X



- Baloch, Z.W.; Fleisher, S.; LiVolsi, V.A. & Gupta P.K. (2002) Diagnosis of “follicular neoplasm”: a gray zone in thyroid fine-needle aspiration cytology. *Diagnostic Cytopathology*, Vol.26, No.1, (January 2002), pp. 41–44, ISSN 8755-1039
- Baloch, Z.W.; LiVolsi, V.A.; Asa, S.L.; Rosai, J.; Merino, M.J.; Randolph, G.; Vielh, P.; DeMay, R.M.; Sidawy, M.K. & Frable WJ. (2008). Diagnostic terminology and morphologic criteria for cytologic diagnosis of thyroid lesions: a synopsis of the National Cancer Institute Thyroid Fine-Needle Aspiration State of the Science Conference. *Diagnostic Cytopathology*, Vol.36, No.6, (June 2008), pp. 425–437, ISSN 8755-1039
- Barbaro, D.; Simi, U.; Meucci, G.; Lapi, P.; Orsini, P. & Pasquini, C. (2005). Thyroid papillary cancers: microcarcinoma and carcinoma, incidental cancers and non-incidental cancers – are they different diseases? *Clinical Endocrinology*, Vol.63, No.5, (November 2005), pp. 577–5781, ISSN 0300-0664
- Belfiore, A.; La Rosa, G.L.; La Porta, G.A.; Giuffrida, D.; Milazzo, G.; Lupo, L.; Regalbuto, C. & Vigneri, R. (1992). Cancer risk in patients with cold thyroid nodules: relevance of iodine intake, sex, age, and multinodularity. *The American Journal of Medicine*, Vol.93, No.4, (October 1992), pp. 363–369, ISSN 0002-9343
- Bennedbæk, F.N.; Perrild, H. & Hegedüs, L. (1999). Diagnosis and treatment of the solitary thyroid nodule. Results of a European survey. *Clinical Endocrinology*, Vol.50, No.3, (1999), pp. 357–363, ISSN 0300-0664
- Bennedbæk, F.N. & Hegedüs, L. (2000). Management of the solitary thyroid nodule: results of a North American survey. *Journal of Clinical Endocrinology and Metabolism*, Vol.85, No.7, (July 2000), pp. 2493–2498, ISSN 0021-972X
- Berker, D.; Aydin, Y.; Ustun, I.; Gul, K.; Tutuncu, Y.; Isik, S.; Delibasi, T. & Guler, S. (2008). The value of fine-needle aspiration biopsy in subcentimeter thyroid nodules. *Thyroid*, Vol.18, No.6, (June 2008), pp. 603–608, ISSN 2042-0072
- Boelaert, K. (2009). The association between serum TSH concentration and thyroid cancer. *Endocrine Related Cancer*, Vol.16, No.4, (December 2009), pp. 1065–1072, ISSN 1351-0088
- Boi, F.; Lai, M.L.; Marziani, B.; Minerba, L.; Faa, G. & Mariotti, S. (2005). High prevalence of suspicious cytology in thyroid nodules associated with positive thyroid autoantibodies. *European Journal of Endocrinology*, Vol.153, No.5, (November 2005), pp. 637–642, ISSN 0804-4643
- Bonavita, J.A.; Mayo, J.; Babb, J.; Bennett, G.; Oweity, T.; Macari, M. & Yee, J. (2009). Pattern recognition of benign nodules at ultrasound of the thyroid: which nodules can be left alone? *AJR. American Journal of Roentgenology*, Vol.193, No.1, (July 2009), pp. 207–213, ISSN 0361-803X
- Bonnema, S.J.; Bennedbæk, F.N.; Wiersinga, W.M. & Hegedüs, L. (2000). Management of the nontoxic multinodular goitre: a European questionnaire study. *Clinical Endocrinology*, Vol.53, No.1, (July 2000), pp. 5–12, ISSN 0300-0664
- Bonnema, S.J.; Bennedbæk, F.N.; Ladenson, P.W. & Hegedüs, L. (2002). Management of the nontoxic multinodular goiter: a North American survey. *Journal of Clinical Endocrinology and Metabolism*, Vol.87, No.1, (January 2002), pp. 112–127, ISSN 0021-972X
- Cap, J.; Ryska, A.; Rehorkova, P.; Hovorkova, E.; Kerekes, Z. & Pohnetalova, D. (1999). Sensitivity and specificity of the fine needle aspiration biopsy of the thyroid:



- clinical point of view. *Clinical Endocrinology*, Vol.51, No.4, (October 1999), pp. 509–515, ISSN 0300-0664
- Cappelli, C.; Castellano, M.; Pirola, I.; Gandossi, E.; De Martino, E.; Cumetti, D.; Agosti, B. & Rosei, E.A. (2006). Thyroid nodule shape suggests malignancy. *European Journal of Endocrinology*, Vol.155, No.1, (July 2006), pp. 27–31, ISSN 0804-4643
- Cappelli, C.; Castellano, M.; Pirola, I.; Cumetti, D.; Agosti, B.; Gandossi, E. & Rosei, E.A. (2007). The predictive value of ultrasound findings in the management of thyroid nodules. *Quarterly Journal of Medicine*, Vol.100, No.1, (January 2007), pp. 29–35, ISSN 1460-2725
- Cesur, M.; Corapcioglu, D.; Bulut, S.; Gursoy, A.; Yilmaz, A.E.; Erdogan, N. & Kamel, N. (2006). Comparison of palpation-guided fine-needle aspiration biopsy to ultrasound-guided fine-needle aspiration biopsy in the evaluation of thyroid nodules. *Thyroid*, Vol.16, No. 6, (June 2006), pp. 555–561, ISSN 2042-0072
- Chan, B.K.; Desser, T.S.; McDougall, I.R.; Weigel, R.J. & Jeffrey, R.B. Jr. (2003). Common and uncommon sonographic features of papillary thyroid carcinoma. *Journal of Ultrasound in Medicine*, Vol.22, No.10, (October 2003), pp. 1083–1090, ISSN 0278-4297
- Chehade, J.M.; Silverberg, A.B.; Kim, J.; Case, C. & Mooradian, A.D. (2001). Role of repeated fine-needle aspiration of thyroid nodules with benign cytologic features. *Endocrine Practice*, Vol.7, No.4, (July/August 2001), pp. 237–243, ISSN 1530-891X
- Chow, S.M.; Law, S.C.; Chan, J.K.; Au, S.K.; Yau, S. & Lau, W.H. (2003). Papillary microcarcinoma of the thyroid - Prognostic significance of lymph node metastasis and multifocality. *Cancer*, Vol.98, No.1, (July 2003), pp. 31–40, ISSN 1097-0142
- Cipolla, C.; Sandonato, L.; Graceffa, G.; Fricano, S.; Torcivia, A.; Vieni, S.; Latteri, S. & Latteri, M.A. (2005). Hashimoto thyroiditis coexistent with papillary thyroid carcinoma. *The American Surgeon*, Vol.71, No.10, (October 2005), pp. 874–878, ISSN 0003-1348
- Doufas, A.G.; Mastorakos, G.; Chatziioannou, S.; Tseleni-Balafouta, S.; Piperlingos, G.; Boukis, M.A.; Mantzos, E.; Caraiskos, C.S.; Mantzos, J.; Alevizaki, M. & Koutras, D.A. (1999). The predominant form of non-toxic goiter in Greece is now autoimmune thyroiditis. *European Journal of Endocrinology*, Vol.140, No.6, (June 1999), pp. 505–511, ISSN 0804-4643
- Erdogan, M.F.; Kamel, N.; Aras, D.; Akdogan, A.; Baskal, N. & Erdogan, G. (1998). Value of re-aspiration in benign nodular thyroid disease. *Thyroid*, Vol.8, N.12, (December 1998), pp. 1087–1090, ISSN 2042-0072
- Ezzat, S.; Sarti, D.A.; Cain, D.R. & Braunstein, G.D. (1994). Thyroid incidentalomas. Prevalence by palpation and ultrasonography. *Archives of Internal Medicine*, Vol.154, No.16 (August 1994), pp. 1838–1840, ISSN 0003-9926
- Faquin, W.C. & Baloch, Z.W. (2010). Fine-needle aspiration of follicular patterned lesions of the thyroid: Diagnosis, management, and follow-up according to National Cancer Institute (NCI) recommendations. *Diagnostic Cytopathology* Vol.38, No.10, (October 2010), pp. 731–739, ISSN 8755-1039
- Feldt-Rasmussen, U. (2001). Iodine and cancer. *Thyroid*, Vol.11, No.5, (May 2001), pp.483–485, ISSN 2042-0072

- Flanagan, M.B.; Ohori, N.P.; Carty, S.E. & Hunt, J.L. (2006). Repeat thyroid nodule fine-needle aspiration in patients with initial benign cytologic results. *American Journal of Clinical Pathology*, Vol.125, No.5, (May 2006), pp. 698–702, ISSN 0002-9173
- Frasoldati, A.; Pesenti, M.; Gallo, M.; Caroggio, A.; Salvo, D. & Valcavi, R. (2003). Diagnosis of neck recurrences in patients with differentiated thyroid carcinoma. *Cancer*, Vol.97, No.1, (January 2003), pp. 90-96, ISSN 1097-0142
- Frates, M.C.; Benson, C.B.; Doubilet, P.M.; Cibas, E.S. & Marqusee, E. (2003). Can color Doppler sonography aid in the prediction of malignancy of thyroid nodules? *Journal of Ultrasound in Medicine*, Vol.22, No.2, (February 2003), pp. 127–131, ISSN 0278-4297
- Frates, M.C.; Benson, C.B.; Charboneau, J.W.; Cibas, E.S.; Clark, O.H.; Coleman, B.G.; Cronan, J.J.; Doubilet, P.M.; Evans, D.B.; Goellner, J.R.; Hay, I.D.; Hertzberg, B.S.; Intenzo, C.M.; Jeffrey, R.B.; Langer, J.E.; Larsen, P.R.; Mandel, S.J.; Middleton, W.D.; Reading, C.C.; Sherman, S.I. & Tessler, F.N. (2005). Management of thyroid nodules detected at US: Society of Radiologists in Ultrasound consensus conference statement. *Radiology*, 2005 237, No.3, (December 2005), pp. 794–800, ISSN 0033-8419
- Frates, M.C.; Benson, C.B.; Doubilet, P.M.; Kunreuther, E.; Contreras, M.; Cibas, E.S.; Orcutt, J.; Moore, F.D.Jr.; Larsen, P.R.; Marqusee, E. & Alexander, E.K. (2006). Prevalence and distribution of carcinoma in patients with solitary and multiple thyroid nodules on sonography. *Journal of Clinical Endocrinology and Metabolism*, 2006 91, No.9, (September 2006), pp. 3411–3417, ISSN 0021-972X
- Fukunaga, F.H. & Yatani, R. (1975). Geographic pathology of occult thyroid carcinomas. *Cancer*, Vol. 36, No.3, (September 1975), pp. 1095-1099, ISSN 1097-0142
- Gabalec, F.; Cáp, J.; Ryska, A.; Vasátko, T. & Ceeová, V. (2009). Benign fine-needle aspiration cytology of thyroid nodule: to repeat or not to repeat? *European Journal of Endocrinology*, Vol.161, No.6, (December 2009), pp. 933-937, ISSN 0804-4643
- Gharib, H.; Papini, E.; Paschke, R.; Duick, D.S.; Valcavi, R.; Hegedüs, L. & Vitti, P. (2010) American Association of Clinical Endocrinologists, Associazione Medici Endocrinologi, and European Thyroid Association medical guidelines for clinical practice for the diagnosis and management of thyroid nodules. AACE/AME/ETA Task Force on Thyroid Nodules. *Endocrine Practice*, Vol.16, (Suppl 1), (May/June 2010), pp. 1-43, ISSN 1530-891X
- Gul K, Dirikoc A, Kiyak G, Ersoy PE, Ugras NS, Ersoy R, Cakir B. (2010). The association between thyroid carcinoma and Hashimoto's thyroiditis: the ultrasonographic and histopathologic characteristics of malignant nodules. *Thyroid*, Vol.20, No.8, (August 2010), pp. 873-878, ISSN 2042-0072
- Hagag, P.; Strauss, S. & Weiss, M. (1998). Role of ultrasound-guided fine-needle aspiration biopsy in evaluation of nonpalpable thyroid nodules *Thyroid*, Vol.8, No.11, (November 1998), pp. 989–995, ISSN 2042-0072
- Hamburger, J.I. (1987). Consistency of sequential needle biopsy findings for thyroid nodules. *Archives of Internal Medicine*, Vol.147, No.1, (January 1987), pp. 97–99, ISSN 0003-9926
- Harach, H.R.; Franssila, K.O. & Wasenius V.M. (1985). Occult papillary carcinoma of the thyroid. A "normal" finding in Finland. A systematic autopsy study. *Cancer*, Vol.56, No.3, (November 1985), pp. 531-538, ISSN 1097-0142

- Harach, H.R. & Williams, E.D. (1995). Thyroid cancer and thyroiditis in the goitrous region of Salta, Argentina, before and after iodine prophylaxis. *Clinical Endocrinology*, Vol.43, No.6, (December 1995), pp. 701–706, ISSN 0300-0664
- Hegedüs, L. (2004). The thyroid nodule. *New England Journal of Medicine*, 2004 351 pp. 1764–1771, ISSN 0028-4793
- Hegedüs, L. (2001). Thyroid ultrasound. *Endocrinology and Metabolism Clinics of North America*, Vol.30, No.2, (June 2001), pp. 339-360, ISSN 0889-8529
- Holm, L.E.; Blomgren, H. & Löwhagen, T. (1985). Cancer risks in patients with chronic lymphocytic thyroiditis. *New England Journal of Medicine*, Vol.312, No.10, (March 1985), pp. 601-604, ISSN 0028-4793
- Hughes, D.T.; Haymart, M.R.; Miller, B.S.; Gauger, P.G. & Doherty, G.M. (2011). The most commonly occurring papillary thyroid cancer in the United States is now a microcarcinoma in a patient older than 45 years. *Thyroid*, Vol.21, No.3, (March 2011), pp. 231-236, ISSN 2042-0072
- Iannuccilli, J.D.; Cronan, J.J. & Monchik, J.M. (2004). Risk for malignancy of thyroid nodules as assessed by sonographic criteria: the need for biopsy. *Journal of Ultrasound in Medicine*, Vol.23, No.11, (November 2004), pp. 1455–1464, ISSN 0278-4297
- Illouz, F.; Rodien, P.; Saint-André, J.P.; Triau, S.; Laboureaux-Soares, S.; Dubois, S.; Vielle, B.; Hamy, A. & Rohmer, V. (2007). Usefulness of repeated fine-needle cytology in the follow-up of non-operated thyroid nodules. *European Journal of Endocrinology*, Vol.156, No.3, (March 2007), pp. 303-308, ISSN 0804-4643
- Ito, Y.; Uruno, T.; Nakano, K.; Takamura, Y.; Miya, A.; Kobayashi, K.; Yokozawa, T.; Matsuzuka, F.; Kuma, S.; Kuma, K. & Miyauchi, A. (2003). An observation trial without surgical treatment in patients with papillary microcarcinoma of the thyroid. *Thyroid*, Vol.13, No.4, (April 2003), pp. 381–387, ISSN 2042-0072
- Ito, Y. & Miyauchi, A. (2009). Prognostic factors and therapeutic strategies for differentiated carcinomas of the thyroid. *Endocrine Journal*, Vol.56, No.6, (December 2009), pp. 177–192, ISSN 0918-8959
- Kang, H.W.; No, J.H.; Chung, J.H.; Min, Y.K.; Lee, M.S.; Lee, M.K.; Yang, J.H. & Kim, K.W. (2004). Prevalence, clinical and ultrasonographic characteristics of thyroid incidentalomas. *Thyroid*, Vol.14, No.1, (January 2004), pp. 29-33, ISSN 2042-0072
- Kim, D.L.; Song, K.H. & Kim, S.K. (2008). High prevalence of carcinoma in ultrasonography – guided fine needle aspiration cytology of thyroid nodules. *Endocrine Journal*, Vol.55, No.1, (March 2008), pp. 135–142, ISSN 0918-8959
- Kim, D.W.; Lee, E.J.; Kim, S.H.; Kim, T.H.; Lee, S.H.; Kim, D.H. & Rho, M.H. (2009). Ultrasound-guided fine-needle aspiration biopsy of thyroid nodules: comparison in efficacy according to nodule size. *Thyroid*, Vol.19, No.1, (January 2009), pp. 27-31, ISSN 2042-0072
- Kim, E.K.; Park, C.S.; Chung, W.Y.; Oh, K.K.; Kim, D.I.; Lee, J.T. & Yoo, H.S. (2002). New sonographic criteria for recommending fine-needle aspiration biopsy of nonpalpable solid nodules of the thyroid. *AJR. American Journal of Roentgenology*, Vol.178, No.3, (March 2002), pp. 687–691, ISSN 0361-803X
- Kim, S.J.; Kim, E.K.; Park, C.S.; Chung, W.Y.; Oh, K.K. & Yoo, H.S. (2003). Ultrasound guided fine-needle aspiration biopsy in nonpalpable thyroid nodules: is it useful in infracentimetric nodules? *Yonsei Medical Journal*, 2003 44, No.4, (August 2003), pp. 635–640, ISSN 0513-5796

- Kloos, R.T.; Eng, C.; Evans, D.B.; Francis, G.L.; Gagel, R.F.; Gharib, H.; Moley, J.F.; Pacini, F.; Ringel, M.D.; Schlumberger, M. & Wells, S.A.Jr. (2009). Medullary thyroid cancer: management guidelines of the American Thyroid Association. American Thyroid Association Guidelines Task Force, *Thyroid*, Vol.19, No.6, (Jun 2009), pp. 565-612, ISSN 2042-0072
- Knudsen, N.; Perrild, H.; Christiansen, E.; Rasmussen, S.; Dige-Petersen, H. & Jorgensen, T. (2000). Thyroid structure and size and two year follow-up of solitary cold thyroid nodules in an unselected population with borderline iodine deficiency. *European Journal of Endocrinology*, Vol.142, No.3, (March 2000), pp. 224-230, ISSN 0804-4643
- Kumar, H.; Daykin, J.; Holder, R.; Watkinson, J.C.; Sheppard, M.C. & Franklyn, J.A. (1999). Gender, clinical findings, and serum thyrotropin measurements in the prediction of thyroid neoplasia in 1005 patients presenting with thyroid enlargement and investigated by fine-needle aspiration cytology. *Thyroid*, Vol.9, No.11, (November 1999), pp. 1105-1109, ISSN 2042-0072
- Kwak, J.Y.; Kim, E.K.; Youk, J.H.; Kim, M.J.; Son, E.J.; Choi, S.H. & Oh, K.K. (2008). Extrathyroid extension of well-differentiated papillary thyroid microcarcinoma on US. *Thyroid*, Vol.18, No.6, (June 2008), pp. 609-614, ISSN 2042-0072
- Kwak, J.Y.; Koo, H.; Youk, J.; Kim, M.J.; Moon, H.J.; Son, E.J. & Kim, E.K. (2010). Value of US correlation of a thyroid nodule with initially benign cytologic results. *Radiology*, Vol.254, No.1, (January 2010), pp. 292-300, ISSN 0033-8419
- La Rosa, G.L.; Belfiore, A.; Giuffrida, D.; Sicurella, C.; Ippolito, O.; Russo, G. & Vernerì, R. (1991). Evaluation of the fine needle aspiration biopsy in the preoperative selection of cold thyroid nodules. *Cancer*, Vol.67, No.8, (April 1991), pp. 2137-2141, ISSN 1097-0142
- Laurberg P, Cerqueira C, Ovesen L, Rasmussen LB, Perrild H, Andersen S, Pedersen IB, Carlé A. (2010). Iodine intake as a determinant of thyroid disorders in populations. *Best Practice and Research Clinical Endocrinology and Metabolism*, Vol.24, No.1, (February 2010), pp. 13-27, ISSN 1521-690X
- Layfield, L.J.; Cibas, E.S. & Baloch, Z. (2010). Thyroid fine needle aspiration cytology: a review of the National Cancer Institute state of the science symposium. *Cytopathology*, Vol.21, No.2, (April 2010) pp. 75-85, ISSN 0956-5507
- Leboulleux, S.; Girard, E.; Rose, M.; Travagli, J.P.; Sabbah, N.; Caillou, B.; Hartl, D.M.; Lassau, N.; Baudin, E. & Schlumberger M. (2007). Ultrasound criteria of malignancy for cervical lymph nodes in patients followed up for differentiated thyroid cancer. *Journal of Clinical Endocrinology and Metabolism*, Vol.92, No.9, (September 2007), pp. 3590-3594, ISSN 0021-972X
- Lee, J.; Rhee, Y.; Lee, S.; Ahn, C.W.; Cha, B.S.; Kim, K.R.; Lee, H.C.; Kim, S.I.; Park, C.S. & Lim, S.K. (2006). Frequent aggressive behaviors of thyroid microcarcinomas in Korean patients. *Endocrine Journal*, Vol.53, No.5, (October 2006), pp. 627-632, ISSN 0918-8959
- Leenhardt, L.; Hejblum, G.; Franc, B.; Fediaevsky, L.D.; Delbot, T.; Le Guillouezic, D.; Menegaux, F.; Guillausseau, C.; Hoang, C.; Turpin, G. & Aurengo, A. (1999). Indications and limits of ultrasound-guided cytology in the management of nonpalpable thyroid nodules. *Journal of Clinical Endocrinology and Metabolism*, 1999 Vol.84, No.1, (January 1999), pp. 24-28, ISSN 0021-972X



- Levine, R.A. (2006). Value of Doppler ultrasonography in management of patients with follicular thyroid biopsy specimens. *Endocrine Practice*, 2006 12 pp. 270-274, ISSN 1530-891X
- Lewis CM, Chang KP, Pitman M, Faquin WC, Randolph GW. (2009) Thyroid fine-needle aspiration biopsy: variability in reporting. *Thyroid*, Vol.19, No.7, (July 2009) pp. 717-723, ISSN 2042-0072
- Lin, J.D.; Chao, T.C.; Huang, B.Y.; Chen, S.T.; Chang, H.Y. & Hsueh, C. (2005). Thyroid cancer in the thyroid nodules evaluated by ultrasonography and fine-needle aspiration cytology. *Thyroid*, 2005 15 pp. 708-717, ISSN 2042-0072
- Lind, P.; Langsteger, W.; Molnar, M.; Gallowitsch, H.J.; Mikosch, P. & Gomez, I. (1998). Epidemiology of thyroid diseases in iodine sufficiency. *Thyroid*, 1998 8 pp. 1179-1183, ISSN 2042-0072
- Liu, L.H.; Bakhos, R. & Wojcik, E.M. (2001). Concomitant papillary thyroid carcinoma and Hashimoto's thyroiditis. *Seminars in diagnostic pathology*, Vol.18, No.2, (May 2001), pp. 99-103, ISSN 0740-2570
- Lubitz, C.C.; Faquin, W.C.; Yang, J.; Mekel, M.; Gaz, R.D.; Parangi, S.; Randolph, G.W.; Hodin, R.A. & Stephen AE. (2010). Clinical and cytological features predictive of malignancy in thyroid follicular neoplasms. *Thyroid*, Vol.20, No.1, (January 2010), pp. 25-31, ISSN 2042-0072
- Lucas, A.; Llatjo's, M.; Salinas, I.; Reverter, J.; Pizarro, E. & Sanmarti, A. (1995). Fine-needle aspiration cytology of benign nodular thyroid disease. Value of re-aspiration. *European Journal of Endocrinology*, Vol.132, No.6, (June 1995), pp. 677-680, ISSN 0804-4643
- Lyshchik, A.; Drozd, V.; Demidchik, Y. & Reiners, C. (2005). Diagnosis of thyroid cancer in children: value of gray-scale and power Doppler US. *Radiology*, Vol.235, No.2, (May 2005), pp. 604-613, ISSN 0033-8419
- Matsuzuka, F.; Miyauchi, A.; Katayama, S. & Narabayashi I. (1995). Clinical aspects of primary thyroid lymphoma: diagnosis and treatment based on our experience of 119 cases. *Thyroid*, 1995; Vol.3, No.2, (Summer 1995), pp. 93-99, ISSN 2042-0072
- Mazzaferrri, E.L. & Sipos, J. (2008). Should all patients with subcentimeter thyroid nodules undergo fine-needle aspiration biopsy and preoperative neck ultrasonography to define the extent of tumor invasion? *Thyroid*, Vol.18, No.6, (June 2008), pp. 597-602, ISSN 2042-0072
- Merchant, S.H.; Izquierdo, R. & Khurana, K.K. (2000). Is repeated fineneedle aspiration cytology useful in the management of patients with benign nodular thyroid disease? *Thyroid*, Vol.10, No.6, (June 2000), pp. 489-492, ISSN 2042-0072
- Mihai, R.; Parker, A.J.; Roskell, D. & Sadler, G.P. (2009) One in four patients with follicular thyroid cytology (THY3) has a thyroid carcinoma. *Thyroid*, Vol.19, No.1, (January 2009), pp. 33-37, ISSN 2042-0072
- Moon, W.J.; Jung, S.L.; Lee, J.H.; Na, D.G.; Baek, J.H.; Lee, Y.H.; Kim, J.; Kim, H.S.; Byun, J.S. & Lee, D.H. (2008). Benign and malignant thyroid nodules: US differentiation – multicenter retrospective study. *Radiology*, Vol.247, No.3, (June 2008), pp. 762-770, ISSN 0033-8419
- Mukasa, K.; Noh, J.Y.; Kunii, Y.; Matsumoto, M.; Sato, S.; Yasuda, S.; Suzuki, M.; Ito, K. & Ito, K. (2011). Prevalence of malignant tumors and adenomatous lesions detected




- by ultrasonographic screening in patients with autoimmune thyroid diseases. *Thyroid*, Vol.21, No.1, (January 2011), pp. 37-41, ISSN 2042-0072
- Nam-Goong, I.S.; Kim, H.Y.; Gong, G.; Lee, H.K.; Hong, S.J.; Kim, W.B. & Shong, Y.K. (2004). Ultrasonography-guided fine-needle aspiration of thyroid incidentaloma: correlation with pathological findings. *Clinical Endocrinology*, 2004; 60, No.1, (January 2004), pp. 21-28, ISSN 0300-0664
- Nosé, V. (2011). Familial thyroid cancer: a review. *Modern Pathology*, Vol.24, Suppl 2 (April 2011), pp. 19-33 ISSN 0893-3952
- Oertel, Y.C.; Miyahara-Felipe, L.; Mendoza, M.G. & Yu, K. (2007). Value of repeated fine needle aspirations of the thyroid: an analysis of over ten thousands FNA's. *Thyroid*, Vol.17, No.11, (November 2007), pp. 1061-1066, ISSN 2042-0072.
- Okayasu, I.; Fujiwara, M.; Hara, Y.; Tanaka, Y. & Rose, N.R. (1995). Association of chronic lymphocytic thyroiditis and thyroid papillary carcinoma. A study of surgical cases among Japanese, and white and African Americans. *Cancer*, Vol.11, No.3, (December 1995), pp. 2312-2318, ISSN 1097-0142
- Orija, I.B.; Piñeyro, M.; Biscotti, C.; Reddy, S.S. & Hamrahian, A.H. (2007). Value of repeating a nondiagnostic thyroid fine-needle aspiration biopsy. *Endocrine Practice*, Vol.13, No.7, (November/December 2007), pp 735-742, ISSN 1530-891X
- Orlandi, A.; Puscar, A.; Capriata, E. & Fideleff, H. (2005). Repeated fine-needle aspiration of the thyroid in benign nodular thyroid disease: critical evaluation of long-term follow-up. *Thyroid*, Vol.15, No.3, (March 2005), pp. 274-278, ISSN 2042-0072
- The Papanicolaou Society of Cytopathology Task Force on Standards of Practice. Guidelines of the Papanicolaou Society of Cytopathology for the examination of fine-needle aspiration specimens from thyroid nodules. *Modern Pathology*, Vol.9, No.6, (June 1996), pp. 710-715, ISSN 0893-3952
- Papini, E.; Guglielmi, R.; Bianchini, A.; Crescenzi, A.; Taccogna, S.; Nardi, F.; Panunzi, C.; Rinaldi, R.; Toscano, V. & Pacella, C.M. (2002). Risk of malignancy in nonpalpable thyroid nodules: predictive value of ultrasound and color-Doppler features. *Journal of Clinical Endocrinology and Metabolism*, Vol.87, No.5, (May 2002), pp. 1941-1946, ISSN 0021-972X
- Pettersson, B.; Coleman, M.P.; Ron, E. & Adami, H.O. (1996). Iodine supplementation in Sweden and regional trends in thyroid cancer incidence by histopathologic type. *International Journal of Cancer*, Vol.65, No.1, (January 1996), pp. 13-19, ISSN 0898-6924
- Popowicz, B.; Klencki, M.; Lewiński, A. & Słowińska-Klencka, D. (2009). The usefulness of sonographic features in selection of thyroid nodules for biopsy in relation to the nodule's size. *European Journal of Endocrinology*, Vol.161, No.1, (January 2009), pp. 103-111, ISSN 0804-4643
- Pu, R.; Yang, J.; Wasserman, P.G.; Bhuiya, T.; Griffith, K.A. & Michael, C.W. (2006). Does Hurthle cell lesion-neoplasm predict malignancy more than follicular lesion-neoplasm on thyroid fine-needle aspiration? *Diagnostic Cytopathology* Vol.34, No, pp. 330-334, ISSN 8755-1039
- Quadbeck, B.; Pruellage, J.; Roggenbuck, U.; Hirche, H.; Janssen, O.E.; Mann, K. & Hoermann, R. (2002). Long-term follow-up of thyroid nodule growth. *Experimental and Clinical Endocrinology and Diabetes*, Vol.110, No.7, (October 2002), pp. 348-354, ISSN 0947-7349

- Rago, T.; Vitti, P.; Chiovato, L.; Mazzeo, S.; De Liperi, A.; Miccoli, P.; Viacava, P.; Bogazzi, F.; Martino, E. & Pinchera, A. (1998). Role of conventional ultrasonography and color flow-Doppler sonography in predicting malignancy in 'cold' thyroid nodules. *European Journal of Endocrinology*, Vol.138, No.1, (January 1998), pp. 41-46, ISSN 0804-4643
- Rago, T.; Di Coscio, G.; Basolo, F.; Scutari, M.; Elisei, R.; Berti, P.; Miccoli, P.; Romani, R.; Faviana, P.; Pinchera, A. & Vitti, P. (2007). Combined clinical, thyroid ultrasound and cytological features help to predict thyroid malignancy in follicular and Hupsilonnrthle cell thyroid lesions: results from a series of 505 consecutive patients. *Clinical Endocrinology*, Vol.66, No.1, (January 2007), pp. 13-20, ISSN 0300-0664
- van Roosmalen, J.; van Hemel, B.; Suurmeijer, A.; Groen, H.; Ruitenbeek, T.; Links, T.P. & Plukker, J.T. (2010) Diagnostic value and cost considerations of routine fine-needle aspirations in the follow-up of thyroid nodules with benign readings. *Thyroid*, Vol.20, No.12, (December 2010), pp. 1359-1365, ISSN 2042-0072
- Ruggiero, F.P.; Fraunhoffer, E. & Stack, Jr.B.C. (2005). Thyroid Lymphoma: A Single Institution's Experience. *Otolaryngology Head and Neck Surgery* Vol.133, No6, 888-896, ISSN 0194-5998
- Sahin, M.; Sengul, A.; Berki, Z.; Tutuncu, N.B. & Guvener, N.D. (2006). Ultrasound-guided fine-needle aspiration biopsy and ultrasonographic features of infracentimetric nodules in patients with nodular goiter: correlation with pathological findings. *Endocrine Pathology*, Vol.17, No.1, (Spring 2006), pp. 67-74, ISSN 1046-3976
- Sangalli, G.; Serio, G.; Zampatti, C.; Bellotti, M. & Lomuscio, G. (2006). Fine needle aspiration cytology of the thyroid: a comparison of 5469 cytological and final histological diagnoses. *Cytopathology*, Vol.17, No.5, (October 2006), pp. 245-250, ISSN 0956-5507
- Schlinkert, R.T.; van Heerden, J.A.; Goellner, J.R.; Gharib, H.; Smith, S.L.; Rosales, R.F. & Weaver, A.L. (1997). Factors that predict malignant thyroid lesions when fine-needle aspiration is "suspicious for follicular neoplasm." *Mayo Clinic Proceedings* Vol.72, No.10 (October 1997), pp. 913-916, ISSN 0025-6196
- Schmid, K.W. (1989). Clinicopathologic management of tumors of the thyroid gland in an endemic goiter area; combined use of preoperative fine needle aspiration biopsy and intraoperative frozen section. *Acta Cytologica*, 1989 33, No.1, (February 1989), pp. 27-30, ISSN 0001-5547
- Schneider, A.B. & Sarne, D.H. (2005). Long-term risks for thyroid cancer and other neoplasms after exposure to radiation. *Nature Clinical Practice. Endocrinology & Metabolism*, Vol.1, No.2, (December 2005), pp. 82-91, ISSN 1745-8366
- Seningen, J.L.; Nassar, A. & Henry, M.R. (2011). Correlation of thyroid nodule fine-needle aspiration cytology with corresponding histology at Mayo Clinic, 2001-2007: An institutional experience of 1,945 cases. *Diagnostic Cytopathology* Vol.39, No5, (May 2011), pp. in press, ISSN 8755-1039
- Shih ML, Lee JA, Hsieh CB, Yu JC, Liu HD, Kebebew E, Clark OH, Duh QY. (2008). Thyroidectomy for Hashimoto's thyroiditis: complications and associated cancers. *Thyroid*, Vol.18, No.7, (July 2008), pp. 729-34, ISSN 2042-0072
- Sidawy, M.K.; Del Vecchio, D.M. & Knoll, S.M. (1997). Fine-needle aspiration of thyroid nodules. Correlation between cytology and histology and evaluation discrepant

- cases. *Cancer Cytopathology*, Vol.81, No.4, (August 1997), pp. 253–259, ISSN 1934-662X
- Singh, B.; Shaha, A.R.; Trivedi, H.; Carew, J.F.; Poluri, A. & Shah, J.P. (1999). Coexistent Hashimoto's thyroiditis with papillary thyroid carcinoma: impact on presentation, management, and outcome. *Surgery*, Vol.126, No.6, (December 1999), pp. 1070-1076, ISSN 0039-6060
- Sipos, J.A. (2009). Advances in ultrasound for the diagnosis and management of thyroid cancer. *Thyroid*, Vol.19, No.12, (December 2009), pp. 1363-1372, ISSN 2042-0072
- Sipos, J.A. & Mazzaferri, E.L. (2010) Thyroid cancer epidemiology and prognostic variables. *Clinical Oncology*, Vol.22, No.6, (August 2010), pp. 395-404, ISSN 0936-6555
- Słowińska-Klencka, D.; Klencki M. & Lewiński A. (2001). Fine needle aspiration biopsy of the thyroid – routine control of benign nodules. *Proceedings of 5th European Congress of Endocrinology*, Turin, Italy, June, 2001
- Słowińska-Klencka, D.; Klencki, M.; Sporny, S. & Lewinski, A. (2002). Fine needle aspiration biopsy of the thyroid in an area of endemic goitre: influence of restored sufficient iodine supplementation on the clinical significance of cytological results. *European Journal of Endocrinology*, Vol.146 No.1, (January 2002), pp. 19–26, ISSN 0804-4643
- Słowińska-Klencka, D.; Klencki, M.; Sporny, S.; Popowicz, B.; Lewiński, A. (2003). Cytologic appearance of toxic nodular goiter after thyrostatic treatment. A karyometric study. *Analytical and Quantitative Cytology and Histology*, Vol. 25, No.1, (February 2003), pp. 39-46, ISSN 0884-6812
- Słowińska-Klencka, D.; Sporny, S.; Klencki, M. & Lewiński, A. (2004). Nondiagnostic cytological outcome of thyroid biopsy and risk of thyroid malignancy. *Endocrine Pathology*, 2004; 15, No.1, (Spring 2004), pp. 65–75, ISSN 1046-3976
- Słowińska-Klencka D, Sporny S, Klencki M, Popowicz B, Lewiński A. (2006). Chronic thyroiditis--current issue in the cytological diagnostics of the thyroid gland. *Endokrynologia Polska - Polish Journal of Endocrinology*, Vol.57, No.4, (July/August 2006), pp. 299-306, ISSN 0423-104X
- Słowińska-Klencka, D.; Popowicz, B.; Lewiński, A. & Klencki, M. (2008). The fine-needle aspiration biopsy efficacy of small thyroid nodules in the area of recently normalized iodine supply. *European Journal of Endocrinology*, Vol.159, No.6, (December 2008), pp. 747–754, ISSN 0804-4643
- Solymosi, T.; Toth, G.L.; Gal, I.; Sajgo, C. & Szabolcs, I. (2002). Influence of iodine intake on the diagnostic power of fine-needle aspiration cytology of the thyroid gland. *Thyroid*, Vol.12, No.8, (August 2002), pp. 719–723, ISSN 2042-0072
- Sorrenti, S.; Trimboli, P.; Catania, A.; Ullisse, S.; De Antoni, E. & D'Armiento, M (2009). Comparison of malignancy rate in thyroid nodules with cytology of indeterminate follicular or indeterminate Hürthle cell neoplasm. *Thyroid*, Vol.19, No.4, (April 2009), pp. 355-360, ISSN 2042-0072
- Sporny, S.; Lange, D.; Sygut, J.; Kulig, A.; Olszewski, W.; Słowińska-Klencka, D.; Jarząb, B. (2010). Diagnosis and treatment of thyroid cancer – Polish guidelines. Part I. Diagnostics of nodular goitre and fine needle aspiration biopsy. *Endokrynologia Polska - Polish Journal of Endocrinology*, Vol.61, No.5, (September/October 2010), pp. 522-542, ISSN 0423-104X

- Szybinski, Z. & Zarnecki, A. (1993). Prevalence of goiter, iodine deficiency and iodine prophylaxis in Poland. The results of the nation-wide study. *Endokrynologia Polska – Polish Journal of Endocrinology*, Vol.44, No.3, pp. 373–388, ISSN 0423-104X
- Szybinski, Z.; Golkowski, F.; Buziak-Bereza, M.; Trofimiuk, M.; Przybylik- Mazurek, E.; Huszno, B.; Bandurska-Stankiewicz, E.; Bar-Andziak, E.; Dorant, B.; Kinalska, I.; Lewinski, A.; Klencki, M.; Rybakowa, M.; Sowinski, J.; Szewczyk, L.; Szponar, L. & Wasik, R. (2008). Effectiveness of the iodine prophylaxis model adopted in Poland. *Journal of Endocrinological Investigation*, Vol.31, No.4, (April 2008), pp. 309–313, ISSN 0391-4097
- Tae, H.J.; Lim, D.J.; Baek, K.H.; Park, W.C.; Lee, Y.S.; Choi, J.E.; Lee, J.M.; Kang, M.I.; Cha, B.Y.; Son, H.Y.; Lee, K.W. & Kang, S.K. (2007). Diagnostic value of ultrasonography to distinguish between benign and malignant lesions in the management of thyroid nodules. *Thyroid*, Vol.17, No.5 (May 2007), pp. 461–466, ISSN 2042-0072
- Tan, G.H.; Gharib, H. & Reading, C.C. (1995). Solitary thyroid nodule. Comparison between palpation and ultrasonography. *Archives of Internal Medicine*, Vol.155, No.22, (December 1995), pp. 2418–2423, ISSN 0003-9926
- Theoharis, C.; Schofield, K.; Hammers, H.; Udelsman, R. & Chhieng, D.C. (2009). The Bethesda Thyroid Fine-Needle Aspiration Classification System: Year 1 at an Academic Institution. *Thyroid*, Vol.19, No.11, (November 2009), pp. 1215–1223, ISSN 2042-0072
- Tunbridge, W.M.; Evered, D.C.; Hall, R.; Appleton, D.; Brewis, M.; Clark, F.; Evans, J.G.; Young, E.; Bird, T. & Smith, P.A. (1997). The spectrum of thyroid disease in a community: the Whickham survey. *Clinical Endocrinology*, 1977 7, No.6, (December 1977), pp. 481–493, ISSN 0300-0664
- Tuttle, R.M.; Lemar, H. & Burch, H.B. (1998) Clinical features associated with an increased risk of thyroid malignancy in patients with follicular neoplasia by fine-needle aspiration. *Thyroid* Vol.8, No5. (May 1998), pp. 377–383, ISSN 2042-0072
- Wada, N.; Duh, Q.Y.; Sugino, K.; Iwasaki, H.; Kameyama, K.; Mimura, T.; Ito, K.; Takami, H. & Takanashi, Y. (2003). Lymph node metastasis from 259 papillary thyroid microcarcinomas: frequency, pattern of occurrence and recurrence, and optimal strategy for neck dissection. *Annals of Surgery*, Vol.237, No.3, (March 2003), pp. 399–407, ISSN 0003-4932
- Wong, K.T. & Ahuja, A.T. (2005). Ultrasound of thyroid cancer. *Cancer Imaging*, Vol.5, No.5, (December 2005), pp. 157–166, ISSN 1740-5025
- Yang, G.C.; LiVolsi, V.A. & Baloch, Z.W. (2002). Thyroid microcarcinoma: fine needle aspiration diagnosis and histologic follow-up. *International Journal of Surgical Pathology*, Vol.10, No.2, (April 2002), pp. 133–139, ISSN 1066-8969





## **Contemporary Aspects of Endocrinology**

Edited by Dr. Evanthia Diamanti-Kandarakis

ISBN 978-953-307-357-6

Hard cover, 454 pages

**Publisher** InTech

**Published online** 30, November, 2011

**Published in print edition** November, 2011

This book aims to provide readers with a general as well as an advanced overview of the key trends in endocrine disorders. While covering a variety of topics ranging from thyroid carcinogenesis and pituitary adenomas to adrenal tumors and metabolic bone disease, this book also focuses on more specific issues not yet fully elucidated (e.g. the molecular pathways involved in thyrotropin beta gene regulation or monogenic phosphate balance disorders). Readers of different fields and background will have the opportunity to update their knowledge and more importantly to clarify areas of uncertainty and controversies in several topics of endocrine disorders.

### **How to reference**

In order to correctly reference this scholarly work, feel free to copy and paste the following:

Dorota Słowińska-Klencka, Bożena Popowicz, Stanisław Sporny and Mariusz Klencki (2011). Clinical Management of Thyroid Nodules in the Areas of Various Iodine Supply, Contemporary Aspects of Endocrinology, Dr. Evanthia Diamanti-Kandarakis (Ed.), ISBN: 978-953-307-357-6, InTech, Available from: <http://www.intechopen.com/books/contemporary-aspects-of-endocrinology/clinical-management-of-thyroid-nodules-in-the-areas-of-various-iodine-supply>

**INTECH**  
open science | open minds

### **InTech Europe**

University Campus STeP Ri  
Slavka Krautzeka 83/A  
51000 Rijeka, Croatia  
Phone: +385 (51) 770 447  
Fax: +385 (51) 686 166  
[www.intechopen.com](http://www.intechopen.com)

### **InTech China**

Unit 405, Office Block, Hotel Equatorial Shanghai  
No.65, Yan An Road (West), Shanghai, 200040, China  
中国上海市延安西路65号上海国际贵都大饭店办公楼405单元  
Phone: +86-21-62489820  
Fax: +86-21-62489821



© 2011 The Author(s). Licensee IntechOpen. This is an open access article distributed under the terms of the [Creative Commons Attribution 3.0 License](https://creativecommons.org/licenses/by/3.0/), which permits unrestricted use, distribution, and reproduction in any medium, provided the original work is properly cited.

IntechOpen

IntechOpen