

We are IntechOpen, the world's leading publisher of Open Access books Built by scientists, for scientists

6,900

Open access books available

186,000

International authors and editors

200M

Downloads

Our authors are among the

154

Countries delivered to

TOP 1%

most cited scientists

12.2%

Contributors from top 500 universities



WEB OF SCIENCE™

Selection of our books indexed in the Book Citation Index
in Web of Science™ Core Collection (BKCI)

Interested in publishing with us?
Contact book.department@intechopen.com

Numbers displayed above are based on latest data collected.
For more information visit www.intechopen.com



Efficacy of the Pediatric Colonoscope Used as a Push Enteroscope

Francisco Pérez-Roldán,
Pedro González-Carro and María Concepción Villafáñez-García
*Hospital General La Mancha-Centro; Alcázar de San Juan
Spain*

1. Introduction

Numerous advances have recently been made in endoscopy for both diagnosis and treatment of gastrointestinal diseases. However, these advances have taken little account of the small bowel, as access by endoscopy is often difficult. With the advent of push endoscopy in 1971, the proximal jejunum could be examined to about 50 cm from the ligament of Treitz. The subsequent introduction of videoendoscopy combined with an overtube enabled us to examine the whole jejunum. The most recent discoveries—capsule endoscopy and double-balloon enteroscopy—have improved our ability to examine the small intestine. Capsule endoscopy has provided us with a new challenge, namely, how to diagnose and treat the lesions found. Hospitals with a small bowel unit in which double-balloon enteroscopy and push endoscopy are available can provide an effective solution in a large percentage of cases. In hospitals where these techniques are not available, lesions identified in the jejunum must be resolved using non-balloon enteroscopy. Colonoscopy is a well-known alternative, although its rigidity and caliber prevent it from advancing smoothly through the jejunum. An intermediate solution could be found in the pediatric colonoscope, which is smaller in cross-section and more flexible and has a working channel that enables therapy to be administered.

In this chapter, we describe the different diagnostic therapeutic approaches to lesions of the small bowel. We also examine the application of endoscopy, including the possibilities offered by the pediatric colonoscope in the diagnosis and treatment of lesions found using capsule endoscopy.

2. Radiological examination of the small bowel

The small bowel is the longest part of the digestive tract; however, it is the least examined using radiological techniques. Although simple in structure—it is a tube of regular caliber with fairly constant folds—examination is problematic due to its length and motility, the lower incidence of small bowel disease, frequent overlapping between loops, and the difficulty in differentiating between a healthy bowel and a diseased one.

Originally, the small bowel could only be examined using radiological techniques, some of which were barium-based. These techniques have improved over the years. Below we describe the methods used to date.

1. *Intestinal transit.* Today, barium-based examination of the small intestine is limited by the huge advances made in enteroscopy, especially capsule endoscopy, which has made it possible to examine sections of the digestive tract that were previously inaccessible. Nevertheless, intestinal transit can sometimes provide us with important information. It is used exclusively for diagnosis, and findings must be confirmed by histology or other techniques.

Contrast can be administered in 2 ways:

- Orally, with a single contrast.
- Using enteroclysis: Contrast is introduced via a tube in the distal duodenum to obtain faster and more uniform opacification, thus increasing the technique's sensitivity (Figure 1). The contrast may be single or double (barium and methylcellulose or air). The latter has been of little use in the small intestine due to its poor diagnostic yield.

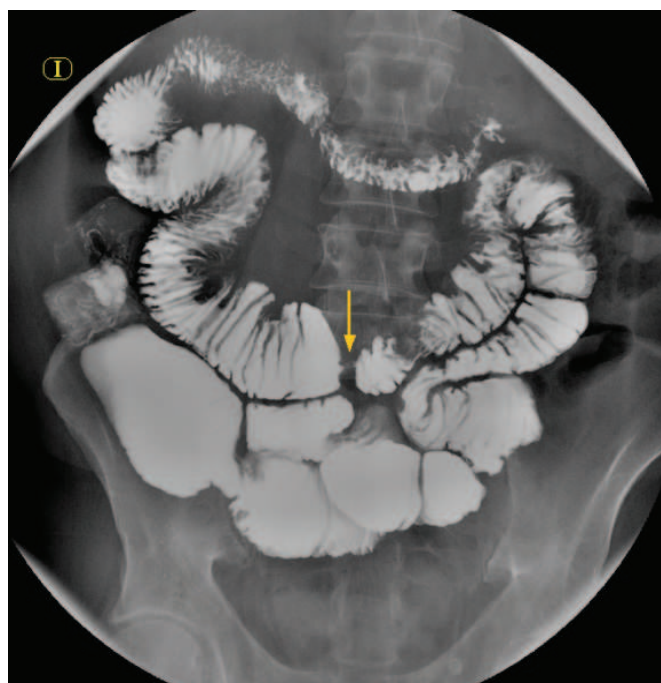


Fig. 1. Jejunal stenosis (arrow) in a patient with Crohn disease

Currently, the indications for a contrast study of the small intestine are as follows:

- Before capsule endoscopy (only if stenosis is suspected)
- Diagnosis of extension and follow-up of inflammatory diseases (especially Crohn disease)
- Monitoring of celiac disease
- Obstructive disease of the small intestine, including volvulus and stenosis
- Examination of the anatomy of the small intestine after resection
- Diagnosis of diverticula, hernias, or intestinal tumors
- Study of enteral fistulas
- Other less well-defined indications, such as undiagnosed abdominal pain and malabsorption. The contraindications for barium-based techniques are those of any radiologic study, namely, pregnancy, lack of patient cooperation, and allergy to contrasts.

2. *Computed tomography enterography and computed tomography enteroclysis.* These techniques are dedicated examinations of the small bowel that allow the detection of both vascular lesions and tumors. Computed tomography-based techniques optimize luminal distension by enabling larger volumes of neutral oral contrast to be administered via a peroral or nasojejunal tube, thereby providing optimal visualization of mucosal detail and vasculature. It is also possible to evaluate wall thickness. In addition, uptake of intravenous contrast enables us to characterize tissues and lesions. An additional advantage of computed tomography enterography is that it can identify small bowel strictures/obstruction prior to capsule endoscopy and provide important information on luminal and extraluminal findings that cannot be detected on capsule endoscopy. Moreover, computed tomography enables us to perform invasive diagnostic and therapeutic procedures such as fine-needle aspiration, biopsy, and percutaneous drainage.
3. *Magnetic resonance imaging.* Magnetic resonance imaging is based on the magnetic properties of the protons of water molecules and lipids, which act as small magnets that line up in the magnetic field of the device when a radiofrequency pulse is applied, thus generating 2 signals of differing intensity (T1 and T2). As the images take some time to be acquired, movement, including respiration, can produce artifacts. The lumen must be well distended, either by direct enteral infusion of contrast (magnetic resonance-enteroclysis) or ingestion of large volumes of contrast. Interest in magnetic resonance imaging for evaluation of the small bowel is growing, due to the absence of ionizing radiation, the excellent contrast resolution, direct multiplanar acquisition, and the use of non-nephrotoxic intravenous contrast. Nevertheless, magnetic resonance imaging does not provide clear advantages in most diseases of the digestive tract.
4. *Abdominal angiography.* The use of arteriography for the study of digestive disorders has been partly superseded by advances in other, less invasive imaging techniques, such as computed tomography angiography or magnetic resonance angiography. However, it continues to be indicated and is difficult to replace, especially for therapeutic purposes. The current indications in the small bowel are as follows:
 - Uncontrollable gastrointestinal bleeding due to therapeutic failure or failure to locate the bleeding source or impossibility of applying endoscopy. Angiography enables hemostatic therapy to be administered (vasoactive substances, particle embolization, balloon-catheter occlusion)
 - Acute mesenteric ischemia. Therapy can also be administered, namely, embolectomy, fibrinolysis, and perfusion of substances to treat vascular spasm.The contraindications for this technique are those which are typical of radiologic examinations, as well as allergy to iodine contrast and the risk of severe shock.
5. *Abdominal ultrasound.* Ultrasound represents a huge advance in the diagnosis and treatment of digestive diseases. The technique is harmless, fast, inexpensive, and examiner-dependent. It is indicated mainly for examination of solid organs involved in digestive disorders, especially the liver, biliary tract, spleen, and pancreas. In the digestive tract, ultrasound provides scant and indirect information on extrinsic and wall disorders. However, it does enable us to evaluate wall morphology and thickness, caliber, compressibility, and peristalsis. The most characteristic ultrasound sign in gastrointestinal disease is the so-called pseudokidney sign or target sign, which is composed of an echogenic center (intestinal content) surrounded by a hypoechoic halo corresponding to a thickened intestinal wall. This sign is specific and can result

from inflammatory abnormalities (neoplastic or other). In pediatric patients, the technique reveals conditions such as concentric pyloric stenosis and intussusception, in which ultrasound findings alone are characteristic and diagnostic.

3. Video capsule endoscopy

Video capsule endoscopy is a noninvasive technique that has proven effective for the evaluation of patients with suspected small bowel bleeding. It enables the whole small bowel to be examined. Several studies have shown its superiority over more conventional methods, including barium x-ray. Capsule endoscopy is currently considered the procedure of choice in small bowel diseases. However, this technique has a series of limitations that have yet to be resolved, namely, the real significance of findings and false negatives, and that it is only diagnostic (Figure 2).

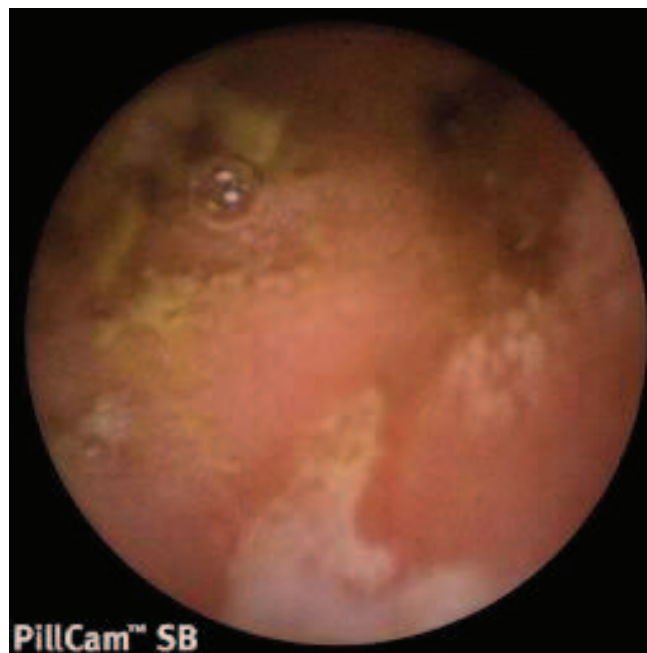

Fig. 2. Geographic ulcer in the ileum surrounded by edema suggestive of Crohn disease

As the diagnostic potential of this technique and treatment options have become clearer, its indications have varied and now include the following:

- Gastrointestinal hemorrhage of unknown origin
- Tumors
- Crohn disease
- Polyposis and polyps (Peutz-Jeghers syndrome and familial adenomatous polyposis)
- Malabsorption, celiac disease, and lymphoma
- Further study of findings in other imaging techniques
- Gastroenteropathy induced by nonsteroidal anti-inflammatory drugs

The patient must be well prepared in order to ensure good image quality: 8 hours' fasting, low-residue diet during the days before the procedure, and antifoam solutions and bowel cleansing solutions (increasingly recommended). Complications are exceptional and no deaths have been reported. The main complications include inability to swallow the capsule (in which case it must be inserted using an endoscope), contact with pyriform sinuses,

contact with the esophagus or a bronchus, delay in evacuating the stomach, retention in an afferent loop, retention in lesions of the small intestine (stenosis, diverticula, tumors), or malfunctioning capsule (short recording time, interference by magnetic sources, or error in the images due to disconnection of a sensor).

Capsule endoscopy makes it possible to examine the whole small bowel, and several studies have shown its superiority over other more conventional modalities, including barium x-ray. However, this technique is not completely reliable, and a series of limitations have yet to be resolved, including the real significance of specific findings and false negatives attributable to the presence of food and liquid residue, the lack of distension or propulsion, and rapid passage through large segments. The main drawback of capsule endoscopy is that it is exclusively diagnostic, with limited capacity for locating the lesion accurately and no options for biopsy or therapeutic procedures.

4. Endoscopic methods for examination of the small intestine

Although numerous advances have recently been made in endoscopy for diagnosis and treatment of gastrointestinal diseases, they have taken little account of the small bowel, as access by endoscopy is often difficult. The most recent discoveries—capsule endoscopy, double-balloon enteroscopy, and spiral enteroscopy—have improved our ability to examine the small bowel. Capsule endoscopy has given rise to a new challenge, namely, how to diagnose and treat the lesions found. In this section, we describe the different methods used to perform enteroscopy, from the earliest to the most recent.

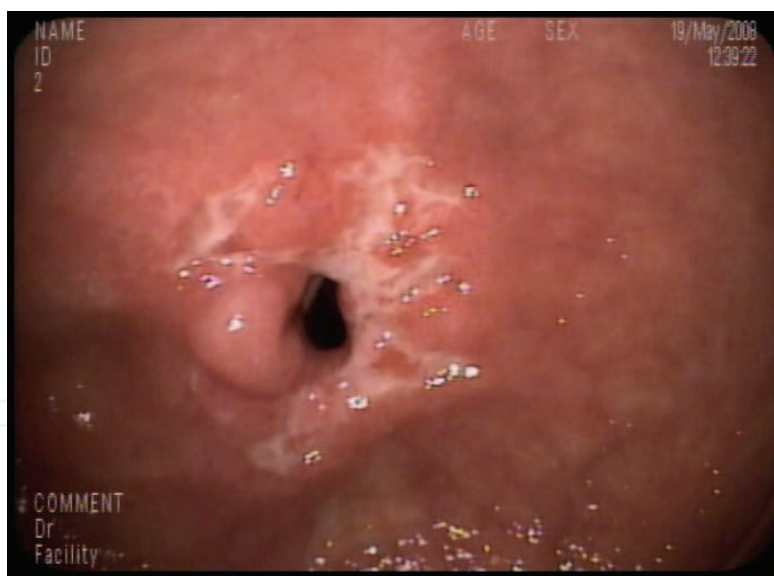


Fig. 3. Jejunal stenosis in a patient with Crohn disease. Geographic ulcers at the level of the stenosis

Push Enteroscopy. For several years, push enteroscopy has been the most widely used and effective procedure for direct examination of the intestinal mucosa. It comprises a 200-cm-long endoscope and a 2.8-mm working channel. One of its limitations is that it only allows us to visualize the proximal and medial jejunum, leaving much of the small intestine unexplored. In order to progress, smooth and intermittent aspiration maneuvers are necessary to avoid suction artifacts on the mucosa. Minimal insufflation should be applied

due to the risk of overdistension and greater formation of loops. The technique identifies fewer lesions than upper and lower endoscopy, as the small bowel is less commonly affected by disease (Figure 3); therefore, the indications should be carefully selected in order to achieve diagnostic yield, and more importantly, therapeutic yield. The mucosa is usually more visible on withdrawal, during which the distance reached relative to the angle of Treitz is better appreciated.

Balloon-assisted enteroscopy.

- a. *Double-balloon enteroscopy.* Double-balloon enteroscopy represents a huge advance. In theory, the whole small bowel can be examined, biopsies taken, and treatment administered, or, if this is not possible, the lesion can be marked. The technique comprises a thin enteroscope with a special flexible overtube, at the distal end of which 2 balloons are attached. These balloons are inflated and deflated by continuous pressure control, and both instruments can be pushed forward or withdrawn. The technique makes it possible to reach more distal sections of the small bowel, although it rarely manages to reach the terminal ileum; therefore, enteroscopy requires the combination of the antegrade and retrograde approaches for an examination of the whole bowel. Double-balloon enteroscopy is considered a safe and well-tolerated technique for the diagnosis and treatment of small bowel diseases, with a working channel ranging in size from 2.2 mm to 2.8 mm.

The technique is contraindicated in patients who have recently undergone digestive surgery and in those with perforated viscus, life-threatening hemodynamic instability, and severe respiratory insufficiency. The most common complications are cardiopulmonary abnormalities, bacteremia, hemorrhage, pancreatitis, dissected aortic aneurysm, volvulus, and incarcerated inguinal hernia. At present, double-balloon enteroscopy is used mainly to administer therapy after capsule endoscopy, except when it is contraindicated.

- b. *Single-balloon enteroscopy.* Single-balloon enteroscopy is the latest balloon-assisted endoscopic technique for the evaluation and management of small bowel disorders. It involves inserting a balloon catheter through the working channel of a colonoscope and moving the endoscope progressively along the small intestine by inflating and deflating the balloon. This technique has proven safe and effective, and in some cases (up to 25%) has made it possible to perform a complete enteroscopy. The earliest versions involved an enteroscope with a 2.8-mm working channel; however, more recently, a pediatric colonoscope with a wider working channel (3.2 mm) has been used, with no reduction in insertion depth. Compared with double-balloon enteroscopy, this technique presents fewer complications, enables a complete enteroscopy to be performed in a lower percentage of patients, and has a similar or wider working channel.

Spiral enteroscopy. Spiral enteroscopy allows for advancement and withdrawal of the enteroscope through the small bowel by using clockwise and counterclockwise movements, respectively. The distal end of the overtube is positioned 25 cm from the tip of the enteroscope and locked into place. The system is then advanced to the ligament of Treitz with gentle rotation. The collar is subsequently unlocked, and the enteroscope is advanced past the ligament of Treitz. The overtube is then advanced using clockwise rotation until pleating of the small bowel no longer occurs over the enteroscope. The enteroscope is then unlocked and advanced to facilitate further advancement into the small bowel. In order to ease withdrawal of the enteroscope, the overtube is rotated in a counterclockwise direction.

Insertion depth is 262 ± 57 cm and the examination takes an average of 35 minutes. This endoscopic modality also allows the use of therapeutics, including biopsy, hemostatic agents, and polypectomy (working channel of 2.8 mm). Only minor complications of sore throat and minimal mucosal trauma have been reported to date and no perforations. Some studies compare this approach with double-balloon enteroscopy and show that the latter has a higher diagnostic yield. In addition, this technique requires 2 endoscopists, one to turn the overtube and the other to push the endoscope. It is important to remember that the overtube contains latex—as do the balloons in balloon-assisted enteroscopy—and therefore represents an added risk in patients with latex allergy.

Intraoperative enteroscopy. Intraoperative enteroscopy by insertion of an endoscope through 1 or more enterotomies to examine the whole small bowel has a high diagnostic yield, identifying lesions in 70-100% of patients. The technique commences once the surgeon has performed a laparotomy to gain access to the small bowel. Once the small bowel is exposed, 2 or more enterotomies are made and the colonoscope is inserted with the surgeon's help. Intraoperative enteroscopy makes it possible to examine the whole small bowel, although the assistance of a surgeon is necessary. It is limited by its high morbidity (intestinal wall hematoma, mesenteric hemorrhage, prolonged ileus, intestinal ischemia, and perforation) and is therefore reserved for patients with persistent bleeding and high transfusional requirements in whom diagnosis cannot be established by other means (Figure 4). A variation of the technique involves oral insertion of the enteroscope during surgery, which makes it possible to visualize 93% of the ileum and establish a diagnosis in almost 60% of cases. Its drawback is the considerable operative morbidity in a relatively high proportion of cases (serosal tear or mesenteric vein avulsion).

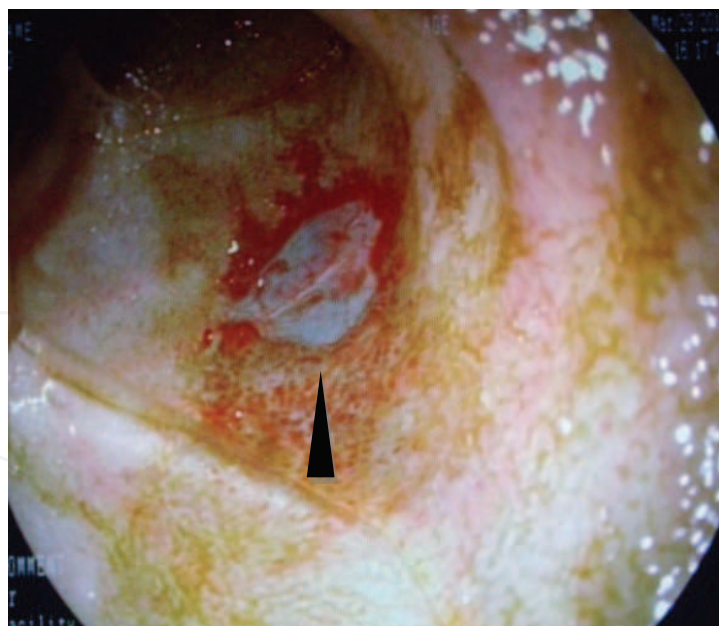


Fig. 4. Ileal ulcer (arrow) with completely denuded submucosa

5. Push enteroscopy performed using a pediatric colonoscope

Capsule endoscopy can be used to examine the small bowel for the indications presented above. However, it is exclusively a diagnostic technique; therapy must be administered

using single-balloon or double-balloon enteroscopy or spiral enteroscopy. These new endoscopes are flexible and generally have a 2.8-mm working channel that partially collapses after passing through several loops, thus making it difficult to insert commercially available catheters. In addition, they are not universally available. An alternative in the case of proximal lesions of the small bowel (mainly the jejunum) is to use a pediatric colonoscope with a 3.2-mm channel, which makes it easy to insert even metal prostheses or the catheters habitually used in colonoscopy. The caliber of the standard working channel is 2.8 mm (2.2 mm in the diagnostic double-balloon enteroscope). Another advantage of this type of colonoscope is that it is more flexible and manageable than a standard colonoscope, enabling us to reach more distal parts of the jejunum.

Therefore, a pediatric colonoscope with a 3.2-mm working channel can be used as a push enteroscope to treat jejunal lesions. We can use any type of catheter applied in colonoscopy (this does not need to be longer, as is the case with standard push enteroscopy) and we can insert sclerotherapy needles to mark the lesions identified and the furthest point reached. Hemoclips can also be used for this purpose. If necessary, ink marks can be visualized using capsule endoscopy, and clips are easily identified on a plain radiograph (Figure 5) or can be palpated by the surgeon.

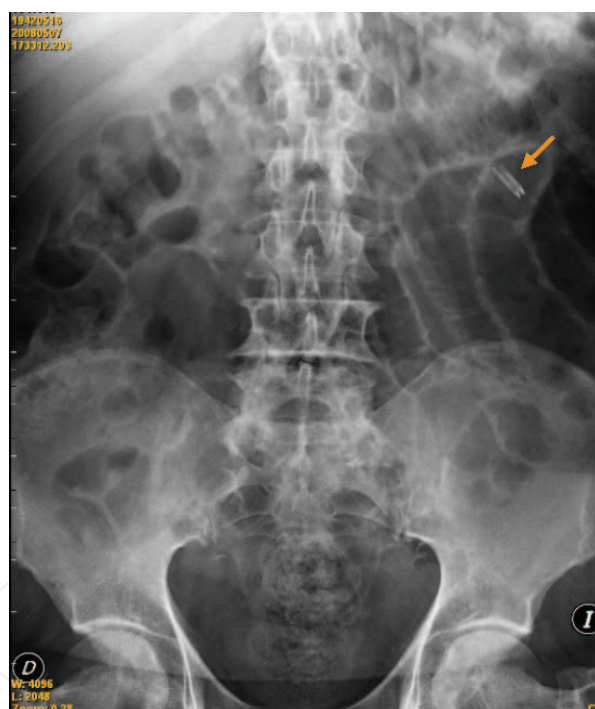


Fig. 5. Note the 2 hemoclips (arrow) marking the distance reached with the pediatric colonoscope

Our experience shows that diagnosis is not always consistent: capsule endoscopy did not reveal the lesions we expected to find in the section examined or there were no identifiable lesions. Push endoscopy using a pediatric colonoscope, on the other hand, made it possible to identify the lesions to be treated (argon plasma, hydropneumatic dilation), take biopsy specimens to provide an accurate diagnosis (stenosis caused by Crohn disease, jejunal carcinoma in patients with celiac disease), and, importantly, mark the bowel (hemoclips or Indian ink) in order to locate lesions or the most distal point reached.

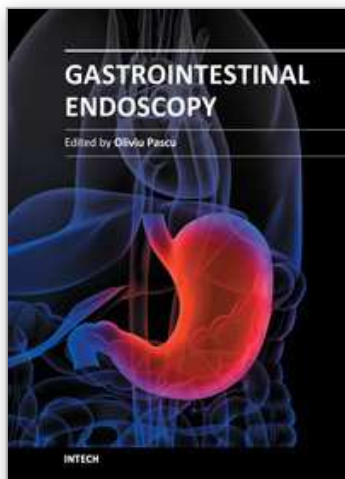
6. Summary

Capsule endoscopy is the technique of choice for examination of the small bowel. Several options are available for treatment, including balloon-assisted enteroscopy or spiral enteroscopy. A pediatric colonoscope enables us to perform the examination using conventional push enteroscopy (50 cm from the angle of Treitz), take biopsy specimens, administer endoscopic treatment of the lesions found, and mark lesions using standard clinical techniques. It has the advantages that it can be performed in selected patients at any hospital without the need for advanced technology and enables metallic prostheses to be inserted.

7. References

- Hiratsuka H. Endoscopic diagnosis in the small intestine. *Stomach Intestine* 1972; 7: 1679-85.
- Yamamoto H, Kita H. Enteroscopy. *J Gastroenterol* 2005; 40:555-562.
- Nolan DJ. The true yield of small-intestinal barium study. *Endoscopy* 1997; 29: 447-53.
- Dixon PM, Roulston ME, Nolan DJ. The small bowel enema: a ten year review. *Clin Radiol* 1993; 47: 46-8.
- Zamboni GA, Raptopoulos V. CT Enterography. *Gastrointest Endosc Clin N Am* 2010; 20: 347-66.
- Dave-Verma H, Moore S, Singh A, Martins N, Zawacki J. Computed tomographic enterography and enteroclysis: pearls and pitfalls. *Curr Probl Diagn* 2008; 37: 279-87.
- Baker ME, Einstein MD, Veniero JC. Computed tomography enterography and magnetic resonance enterography: the future of small bowel imaging. *Clin Colon Rectal Surg* 2008; 21: 193-212.
- Filder JL, Guimaraes L, Einstein DM. MR imaging of small bowel. *Radiographics* 2009; 29: 1811-25.
- Geboes K, Geboes KP, Maleux G. Vascular anatomy of the gastrointestinal tract. *Best Pract Res Clin Gastroenterol* 2001; 15: 1-14.
- Scheible W, Goldberger LE. Diagnosis of small bowel obstruction: the contribution of diagnostic ultrasound. *Am J Roentgenol* 1979; 133: 685-8.
- Liao Z, Gao R, Xu C, Li ZS. Indications and detection, completion, and retention rates of small-bowel capsule endoscopy: a systematic review. *Gastrointest Endosc* 2010; 71: 280-6.
- Van Gossum A, Ibrahim M. Video capsule endoscopy: what is the future?. *Gastroenterol Clin North Am* 2010; 39: 807-26.
- Hayat M, Axon AT, O'Mahony S. Diagnostic yield and effect on clinical outcomes of push enteroscopy in suspected small-bowel bleeding. *Endoscopy* 2000; 32: 369-72.
- Gómez Rodríguez BJ, Ortiz Moyano C, Romero Castro R, Caunedo Álvarez A, Hernández Durán MD, Hergueta Delgado P, et al. Diagnostic yield of 335 push video-enteroscopies. *Rev Esp Enferm Dig* 2006; 98(2): 82-92.
- Pérez-Cuadrado E, Más P, Hallal H, Shanabo J, Muñoz E, Ortega I, et al. Double-balloon enteroscopy: a descriptive study of 50 explorations. *Rev Esp Enferm Dig* 2006; 98(2): 73-81.

- Ross A, Mehdizadeh S, Tokar J, Leighton JA, Kamal A, Chen A, et al. Double balloon enteroscopy detects small bowel mass lesions missed by capsule endoscopy. *Dig Dis Sci* 2008; 53: 2140-3.
- Lo SK, Mehdizadeh S. Therapeutic uses of double-balloon enteroscopy. *Gastrointest Endosc Clin N Am* 2006; 16: 363-76.
- Matsumoto T, Moriyama T, Esaki M, Nakamura S, Iida M. Performance of antegrade double-balloon enteroscopy: comparison with push enteroscopy. *Gastrointest Endosc* 2005; 62: 392-8.
- Tsujikawa T, Saitoh Y, Andoh A, Imaeda H, Hata K, Minematsu H, et al. Novel single-balloon enteroscopy for diagnosis and treatment of small intestine : preliminary experiences. *Endoscopy* 2008; 40: 11-5.
- Kawamura T, Yasuda K, Tanaka K, Uno K, Ueda M, Sanada K, et al. Clinical evaluation of a newly developed single-balloon enteroscope. *Gastrointest Endosc* 2008; 68: 1112-6.
- Akerman PA, Agrawal D, Chen W, Cantero D, Avila J, Pangtay J. Spiral enteroscopy: a novel method of enteroscopy by using the Endo-Ease discovery SB overtube and a pediatric colonoscope. *Gastrointest Endosc* 2009; 69: 327-32.
- Frieling T, Heise J, Sassenrath W, Hülsdonk A, Kreysel C. Prospective comparison between double-balloon enteroscopy and spiral enteroscopy. *Endoscopy* 2010; 42: 885-8.
- Schulz HJ, Schmidt H. Intraoperative enteroscopy. *Gastrointest Endosc Clin N Am* 2009; 19: 371-9.
- Kopáková M, Bures J, Vykouril L, Hladík P, Simkovic D, Jon B, Ferko A, Tachecí I, Rejchrt S. Intraoperative enteroscopy: ten years' experience at a single tertiary center. *Surg Endosc* 2007; 21: 1111-6.
- Pérez Roldán F, González Carro P, Legaz Huidobro ML, Roncero García-Escribano O, Ynfante Ferrús M, Aoufi S, Sánchez-Manjavacas Muñoz N, Ruiz Carrillo F. Efficacy of pediatric colonoscopy used as push enteroscopy in the management of capsule endoscopy findings . *Rev Esp Enferm Dig* 2009; 101:468-576.



Gastrointestinal Endoscopy

Edited by Prof. Oliviu Pascu

ISBN 978-953-307-385-9

Hard cover, 272 pages

Publisher InTech

Published online 19, July, 2011

Published in print edition July, 2011

Endoscopy has had a major impact in the development of modern gastroenterology. By using different data it provided a better understanding of pathogenic mechanisms, described new entities and changed diagnostic and therapeutic strategies. Meanwhile, taking advantage of many technical advances, endoscopy has had a developed spectacularly. Video-endoscopes, magnification, confocal and narrow-band imaging endoscopes, endoscopic ultrasounds and enteroscopes emerged. Moreover, endoscopy has surpassed its function as an examination tool and it became a rapid and efficient therapeutic tool of low invasiveness. InTech Open Access Publisher selected several known names from all continents and countries with different levels of development. Multiple specific points of view, with respect to different origins of the authors were presented together with various topics regarding diagnostic or therapeutic endoscopy. This book represents a valuable tool for formation and continuous medical education in endoscopy considering the performances or technical possibilities in different parts of the world.

How to reference

In order to correctly reference this scholarly work, feel free to copy and paste the following:

Francisco Pérez-Roldán, Pedro González-Carro and María Concepción Villafáñez-García (2011). Efficacy of the Pediatric Colonoscope Used as a Push Enteroscope, *Gastrointestinal Endoscopy*, Prof. Oliviu Pascu (Ed.), ISBN: 978-953-307-385-9, InTech, Available from: <http://www.intechopen.com/books/gastrointestinal-endoscopy/efficacy-of-the-pediatric-colonoscopy-used-as-a-push-enteroscopy>

INTech
open science | open minds

InTech Europe

University Campus STeP Ri
Slavka Krautzeka 83/A
51000 Rijeka, Croatia
Phone: +385 (51) 770 447
Fax: +385 (51) 686 166
www.intechopen.com

InTech China

Unit 405, Office Block, Hotel Equatorial Shanghai
No.65, Yan An Road (West), Shanghai, 200040, China
中国上海市延安西路65号上海国际贵都大饭店办公楼405单元
Phone: +86-21-62489820
Fax: +86-21-62489821

© 2011 The Author(s). Licensee IntechOpen. This is an open access article distributed under the terms of the [Creative Commons Attribution 3.0 License](https://creativecommons.org/licenses/by/3.0/), which permits unrestricted use, distribution, and reproduction in any medium, provided the original work is properly cited.

IntechOpen

IntechOpen