

We are IntechOpen, the world's leading publisher of Open Access books Built by scientists, for scientists

6,900

Open access books available

186,000

International authors and editors

200M

Downloads

Our authors are among the

154

Countries delivered to

TOP 1%

most cited scientists

12.2%

Contributors from top 500 universities



WEB OF SCIENCE™

Selection of our books indexed in the Book Citation Index
in Web of Science™ Core Collection (BKCI)

Interested in publishing with us?
Contact book.department@intechopen.com

Numbers displayed above are based on latest data collected.
For more information visit www.intechopen.com



Pharmacological Therapy for Recurrent Obscure Gastrointestinal Bleeding

Javier Molina-Infante,
Gema Vinagre-Rodriguez and Miguel Fernandez-Bermejo
*Department of Gastroenterology,
Hospital San Pedro de Alcantara, Caceres,
Spain*

1. Introduction

Obscure gastrointestinal bleeding (OGIB) is defined as occult or overt bleeding of unknown origin that persists or recurs despite negative primary radiological and endoscopic studies. It can be classified into two different clinical forms: obscure-overt OGIB, defined as visible passage of blood (ie, melena or hematochezia) and obscure-occult OGIB, manifested by iron-deficiency anemia or positive fecal occult blood test without other evidence of bleeding.¹

Since the source of bleeding is not readily identifiable by upper GI endoscopy and colonoscopy, OGIB is therefore, by definition, recurrent. Approximately, 5% of GI bleeding occurs between the ligament of Treitz and the ileocecal valve. Angiodysplasias of the small bowel account for 30% to 40% of OGIB and are the most common source of bleeding in patients over 60 years.^{1,2} They can be found as a primary disease or a gastrointestinal manifestation of systemic diseases such as hereditary haemorrhagic telangiectasia (HHT), von Willebrand (vW) disease, cardiac valvular disease, radiation enteritis, end-stage renal disease, portal hypertension, connective tissue diseases or vasculitis. Other causes include non-steroidal anti-inflammatory drugs enteropathy, inflammatory bowel disease, small bowel tumors (ie, leiomyomas, carcinoid, lymphomas, adenocarcinomas), Meckel's diverticulum or Dieulafoy's lesion.

Over the last decade, the diagnostic yield and therapeutic capabilities of small bowel endoscopy have dramatically changed with the development of video capsule endoscopy and deep enteroscopy systems (single balloon, double balloon or spiral). Nonetheless, the diagnostic yield is 75% at best combining both techniques, so a quarter of patients lack a diagnosis of the source of bleeding despite exhaustive evaluation and may be at high risk of rebleeding.¹ Additionally, a variable percentage of patients with a diagnosis may not respond to endoscopic therapy or may not be tributary to aggressive endoscopic or surgical management due to severe comorbidities or diffuse distribution of lesions throughout the GI tract. In this particular subset of patients, medical therapy is commonly required to stop, or at least, ameliorate bleeding, which usually leads to high transfusional requirements, exacerbations of medical conditions and subsequent hospital admissions. Indications for medical therapy in OGIB, as approved in the latest American Gastroenterology Association technical review, are listed in Table 1.²

1.	Patients who are not candidates or do not respond to endoscopic, surgical or interventional radiological therapy.
2.	Diffuse vascular lesions in the small bowel or extended to upper or lower segments.
3.	Relative inaccessible location of lesions for endoscopy.
4.	Unknown source of bleeding.

Table 1. Indications for pharmacological therapy in OGIB

The aim of this chapter is to give an overview of current scientific evidence supporting the use of pharmacological therapy in these, often difficult to treat, OGIB patients. The standard diagnostic and therapeutic approach involving endoscopic and radiological techniques, the management of concomitant antiplatelet and anticoagulant drugs and the supportive care of anemia in OGIB patients, are described elsewhere. Up to date, data regarding pharmacological agents for OGIB are scarce and exclusively based on case reports and small uncontrolled studies. The available evidence suggests a potential role for pharmacological therapy as an adjunctive measure in patients with either multiple comorbidities or in whom lesions are inaccessible or refractory to endoscopic therapy. However, their clinical utility remains to be proven in randomized controlled trials. Similarly, the appropriate dose and schedule required for long-term therapy are also unknown. The different pharmacological agents used for OGIB reported in the literature are listed in Table 2.

Hormonal therapy
Somatostatin analogues
Octreotide
Long acting release (LAR) octreotide
Lanreotide
Antiangiogenic drugs
Thalidomide
Lenalidomide
Bevacizumab
Miscellaneous
Antifibrinolytics (aminocaproic acid, tranexamic acid)
Danazol
Desmopressin
Recombinant activated factor VII
Tamoxifen
Non selective beta-blockers

Table 2. Pharmacological agents used in OGIB

Depending on the type of bleeding
Life-threatening: vasoactive medication, rFVIIa
Depending on the source of bleeding
Angiodysplasias: long-acting somatostatin analogues, antiangiogenic drugs (thalidomide, lenalidomide)
Hereditary hemorrhagic telangiectasia: antifibrinolytics, tamoxifen, antiangiogenic drugs (thalidomide, bevacizumab)
Portal hypertension: beta-blockers
von Willebrand disease: desmopressin, vW factor, antifibrinolytics

Table 3. Suggested therapeutic algorithm for pharmacological therapy in OGIB

2. Hormonal therapy

Estrogen-progesterone combination was proposed for OGIB because of preliminary reports of improvement of epistaxis in patients with HHT during pregnancy and further relapse in the puerperium.³ Its effect, which is not immediate, seems to be estrogen dose-dependent and acts by enhancing microvascular circulation, coagulation, and vascular endothelial integrity. The most common combination schedule has been ethynil estradiol 0.01-0.05 mg and noresthisterone 1-3 mg.⁴ This therapy should be used over six-month periods with pauses to reduce the incidence of adverse effects, mostly due to the estrogen component (vascular thrombosis, gynecomastia and loss of libido in men, breast tenderness and vaginal bleeding in women). However, the two largest placebo-controlled studies addressing the impact of hormonal therapy on GI bleeding from angiodysplasias failed to demonstrate any significant benefit. In the first study, patients with out-of-reach bleeding small-bowel angiodysplasias were treated using high-dose estrogens, estrogen-progesterone or placebo, but no statistical improvement of transfusion requirements was observed amongst the groups.⁵ Additionally, in the second study, the authors failed to identify any significant effect of hormonal therapy compared to placebo in 72 non-cirrhotic patients bleeding from documented angiodysplasia⁶. This latter study, however, has setbacks such as the use of low doses of ethynil estradiol and the exclusion of patients with vascular ectasia associated to cirrhosis and HHT. Overall, the effectiveness of hormonal therapy remains unclear and both negative controlled trial results and serious and frequent side effects strongly limit its use in OGIB. Recent reports on the effectiveness of other agents with an improved safety profile displace hormonal therapy as first-line therapeutic option for OGIB.

3. Somatostatin analogues

In 1993, octreotide was first reported for the treatment of bleeding small bowel angiodysplasias, in a small series of three patients successfully treated for 10 to 40 months.⁷ The rationale for the use of somatostatin analogues is based on its effects on splanchnic circulation, as they induce a marked reduction of portal and mesenteric blood flow mediated through inhibition of vasodilator peptides. Additionally, experimental studies have shown that octreotide has antiangiogenic effects, by downregulation of vascular

endothelial growth factor (VEGF).⁸ In fact, a study reported endoscopic resolution of angiodysplastic lesions after treatment with octreotide, albeit the effect was not quantified.⁹ Interestingly, a more recent study showed that a 3-month-treatment of long-acting release (LAR) octreotide 20 mg once a month in cirrhotic patients decreased significantly both the hepatic venous pressure gradient and VEGF in hepatic venous blood.¹⁰ Other potential mechanisms of action of somatostatin analogues in OGIB, although more controversial, are by increasing vascular resistance and improving platelet aggregation.

Octreotide is, by far, the most studied somatostatin analogue in OGIB. However, recent studies are focusing on long-acting intramuscular (LAR octreotide) or subcutaneous (lanreotide) formulations, which have the great advantage of a once monthly administration. A recent meta-analysis, which included three prospective studies, aimed at evaluating the effectiveness of conventional and depot somatostatin analogues for bleeding vascular malformations, showed an average clinical response rate of 76%.¹¹ Despite the small sample size of the studies included and the heterogeneity in the dose and molecular forms of the medication, these results are encouraging and a trial of somatostatin analogues is warranted, especially in patients in whom endoscopic therapy has failed, with inaccessible lesions or unknown source of bleeding. Its good safety profile, when compared with other pharmacological agents such as hormonal therapy or thalidomide, is another meaningful advantage. Nonetheless, randomized controlled trials are needed to confirm this data.

3.1 Octreotide

Octreotide can be administered intravenously (50 µg per hour) or subcutaneously (50-100 µg b.i.d or t.i.d). Its main disadvantage for long-term therapy is the need of parenteral administration several times a day, owing to its short half-life (90-120 minutes). Octreotide has been reported successful in stopping GI bleeding from angiodysplasia in multiple case reports and small series, both in acute and chronic bleeding.

To date, the most solid evidence is obtained in two prospective cohort studies, the latter comparing the results to historical controls. The former included 17 patients, (of whom 6 were cirrhotic), with chronic bleeding from angiodysplasias. 7 patients had isolated angiodysplasias, whereas other 7 had diffuse lesions in upper and lower segments of the GI tract and 3 watermelon stomach.⁹ Octreotide was given subcutaneously (100 µg t.i.d) for 6 months. More than half of the patients (10/17) achieved complete remission without further iron or transfusion requirements, whereas a transient improvement was observed in another 4 patients. Of note, octreotide lead subjectively to disappearance or reduction of the number, size and colour of the vascular malformations on follow-up endoscopy. The second study included 32 patients with acute or chronic bleeding due to GI angiodysplasias, which were treated with octreotide 50 µg b.i.d for a 1-2 yr period.¹² Cirrhotic patients were excluded. Treatment failure (rebleeding or iron deficiency anemia during follow-up) was significantly higher in the controls cohort (48%) in comparison with the octreotide cohort (23%). A significant decrease in iron requirements, but not in hemoglobin or transfusion requirements, was also observed in the octreotide arm. Adverse effects in both studies were uncommon and mild, including diarrhea, constipation, hyperglycemia or gallbladder stones.

3.2 Long-acting release (LAR) octreotide

Several case reports and small series have recently revealed the efficacy of a depot formulation of octreotide (LAR octreotide) for severe OGIB, either of unknown origin or

related to diffuse small bowel angiodysplasias.¹³⁻¹⁸ LAR octreotide is administered intramuscularly monthly, which makes it an attractive and comfortable therapy on an outpatient basis.

Two small prospective uncontrolled series have been published using LAR octreotide. In the first study, 13 patients with chronic GI bleeding due to angiodysplasias were treated with octreotide LAR 10 mg per month and followed for at least 1 year.¹⁹ Nine out of the thirteen patients (69%) did not require further blood or iron supplementation, and partial improvement was also observed in another patient. The second study addressed the response to octreotide LAR 20 mg per month in a cohort of 11 elderly patients with multiple comorbidities and severe OGIB, mostly related to small-bowel diffuse angiodysplasia (72%).²⁰ Median follow-up was 15 months (5-48). Only 2 out of 11 patients (18%) remained free of transfusions. However, a significant decrease in the need of red cell packets (14 (9-49) vs 4 (0-9), p 0.002) and in hospital stay due to GI bleeding (27 days (10-99) vs 7 days (0-23), p <0.001) during the first year of treatment was observed. These less promising results were perhaps due to a higher proportion of patients on anticoagulation or antiplatelet therapy, which was not withdrawn at study inclusion. Furthermore, the patients included in this study had more severe GI bleeding as shown by higher transfusional requirements.

The main disadvantage of this drug formulation is its high cost, ranging from 785 euros (10mg) to 1300 euros (30 mg) monthly. However, it may be cost-effective in very specific difficult to treat patients, only tributary to conservative management, with higher transfusional requirements and repeat admissions.

3.3 Lanreotide

The main advantage of lanreotide over LAR octreotide is its subcutaneous administration, avoiding painful intramuscular injections and their inherent risk for complication in anticoagulated or cirrhotic patients. Up to date, there is only a case report on the successful use of lanreotide in a patient with severe OGIB due to universal portal hypertension stigmata in stomach, small bowel and colon.²¹ After a successful response to octreotide at a dose of 100 µg twice a day, the patient was given lanreotide, administered at dose of 60 mg, subcutaneously, on a monthly basis. This drug achieved complete remission of bleeding during 15 months of follow-up.

4. Antiangiogenic drugs

4.1 Thalidomide

Thalidomide is a drug with powerful immunomodulatory, anti-inflammatory and antiangiogenic effects, banned in the 1960s because of its teragenocyticity. However, it has been recently reintroduced for the treatment of leprosy, multiple myeloma and a variety of tumors. Over the last decade, thalidomide has gained interest as a therapeutic tool for OGIB. The rationale for its use in bleeding GI angiodysplasias is based on the inhibition of VEGF-dependent angiogenesis. It is administered orally at a variable dose of 100-300 mg per day, usually during a 3-month course due to adverse effects.

Thalidomide has been reported to be effective in controlling refractory severe bleeding from small bowel angiodysplasia, bleeding portal hypertensive gastropathy and enteropathy, radiation-induced proctitis and Crohn's disease.²²⁻²⁹ Thalidomide, at a dose of 100 mg per day for three months, controlled OGIB in a case series of 3 patients with chronic bleeding from small-bowel angiodysplasia evidenced by capsule endoscopy.³⁰ Repeat capsule

endoscopy after therapy revealed a substantial reduction in lesion number, size and colour intensity. Of note, the response was sustained for a median of 34 months despite discontinuation of the drug. Due to its antiangiogenic property, thalidomide may not only lead to cessation of bleeding but also to prevention of further angiodysplasia formation. More recently, two small prospective series, involving 3 and 7 patients, respectively, have confirmed the utility of thalidomide for bleeding small-bowel angiodysplasia.^{31,32} However, a high rate of discontinuation was observed in these series (1/3 and 4/7, respectively), owing to intolerable side effects (fatigue, peripheral neuropathy, dizziness, urticarial rash). The main drawback of thalidomide is its frequent side effects, although these are mostly minor (fatigue, somnolence, constipation, dizziness, peripheral neuropathy). Nonetheless, fatal complications such as acute liver failure have been reported.³³ In addition, the risk of thromboembolic events associated with thalidomide should be considered in OGIB patients. Overall, thalidomide is an effective drug for refractory bleeding GI angiodysplasia. Taking into account its numerous side effects, it seems cautious to save thalidomide for OGIB refractory to both endoscopic therapy and a trial of somatostatin analogues, albeit a head-to-head comparison is required to validate this algorithm.

4.2 Lenalidomide

Lenalidomide is an antiangiogenic drug commonly used for multiple myeloma. It has two major advantages over thalidomide: a more powerful antiangiogenic effect and a lower toxicity profile. Its use in the context of life-threatening bleeding due to gastrointestinal angiodysplasia in a patient suffering from HHT, in whom thalidomide was effective but had to be stopped because of severe neuropathy has been recently reported³⁴. Lenalidomide successfully controlled bleeding and the patient remained free of either gastrointestinal bleeding or drug symptoms. However, although lenalidomide is more effective and better tolerated than thalidomide, further studies are warranted to evaluate its role in refractory OGIB. On the other hand, lenalidomide is 10 times more expensive than thalidomide and dosing should be carefully titrated owing to severe bone marrow suppression, much higher than that described for thalidomide.

4.3 Bevacizumab

Recently, a growing number of reports on the use of VEGF antagonist bevacizumab in HHT have led to outstanding improvement in GI bleeding episodes, reductions in cardiac output and liver size, even obviating the need for liver transplantation in a single patient.^{35,36} This benefit has been also proven for recurrent epistaxis, administering bevacizumab intravenously, injected locally or sprayed topically to the nasal mucosa.^{37,38}

5. Miscellaneous drugs

5.1 Antifibrinolytics

Aminocaproic acid is a powerful inhibitor of the fibrinolytic system that blocks conversion of plasminogen to plasmin when used at low doses. There is only one isolated report in which it was effective in the management of epistaxis from arteriovenous malformations in two patients with HHT at a dose of 1.5 g twice a day, although it was not clear whether concomitant gastrointestinal bleeding was present.³⁹

Tranexamic acid is a synthetic lysine analog that inhibits the conversion of plasmin to fibrinogen, with less antifibrinolytic power than aminocaproic acid. Tranexamic acid has

been proven useful for chronic bleeding from angiodysplasias in patients with end-stage renal failure and bleeding gastric antral vascular ectasia in cirrhosis.⁴⁰⁻⁴² A systematic review on the use of tranexamic acid for upper GI bleeding was recently published.⁴³ Although it seemed to reduce overall mortality, there were no significant differences regarding bleeding, surgery or transfusion requirements. Of note, tranexamic acid did not increase thromboembolic risk. Therefore, the current evidence does not support routine use of tranexamic acid in clinical practice. The main risk derived from the use of antifibrinolytics is thrombosis, so thrombophilia should be ruled out before prescribing them. Adverse events associated to ACA and tranexamic acid may be frequent, and the use of these drugs is not supported by randomized controlled trials, which makes antifibrinolytics a last option for OGIH.

5.2 Danazol

Danazol is an anti-gonadotropin drug with weak androgenic activity that blocks pituitary secretion of FSH and LH, leading to ectopic and normal endometrial tissue atrophy. It has been widely used for endometriosis and uterine bleeding disorders. Anecdotal reports suggest a partial improvement with danazol in patients with gastrointestinal bleeding and HHT,⁴⁴⁻⁴⁶ although cosmetic stigmata (acne, hair loss, mild hirsutism) and uncommon but severe adverse effects (intracranial hypertension, peliosis hepatitis, thrombosis, seizures) leave danazol to a secondary role in OGIH, when other therapies have failed.

5.3 Desmopressin

Desmopressin is a synthetic analog of the antidiuretic hormone vasopressin that lacks vasopressor activity. It increases vW factor and factor VIII levels, and also enhances hemostasis in patients with defective platelet function. It is indicated as a hemostatic therapy for patients with hemophilia A and von Willebrand's disease, and can be administered intravenously, subcutaneously, or by intranasal spray. An isolated report showed a benefit of intravenous desmopressin for life-threatening gastrointestinal bleeding in a patient with HHT and vW factor deficiency, allowing elective colectomy and bleeding resolution⁴⁷.

5.4 Recombinant activated factor VIIa

Recombinant activated human factor VII (rFVIIa) is a drug that strongly promotes hemostasis, and is currently indicated for hemophiliac A and B patients with antibody inhibitors to coagulation factors VIII or IX, congenital deficiency of factor VII, and Glanzmann's thromboasthenia. This drug has been used anecdotically for stopping hemorrhage, with or without hematological disorders, in massive or uncontrollable bleeding at multiple GI and non GI locations. Its short half-life of 2 hours requires frequent boluses or continuous infusion to achieve hemostasis, and it can induce definite control of bleeding or be a bridge until a causal therapy can be provided. It has been mainly used in cirrhotic patients with acquired coagulation factor deficiencies, especially in variceal and non-variceal upper GI hemorrhage related to cirrhosis or acute liver failure.^{48,49} Albeit preliminary results showed that it might have a beneficial effect for advanced cirrhotic patients with variceal bleeding, a randomized placebo controlled trial failed to demonstrate a significant benefit of rFVIIa for controlling variceal bleeding or preventing rebleeding in these patients.⁵⁰ Thus, the use of rFVIIa should be carefully individualized in cirrhotic patients and it is not recommended in the routine clinical practice.

This drug has been proven useful in other settings as well. In a series of 11 unselected patients with upper GI haemorrhage, half of them related to liver disease, rFVIIa stopped the bleeding in 7 patients and markedly reduced it in other 2 patients.⁵¹ Other successful indications relating severe GI bleeding have been refractory bleeding after endoscopic sphincterotomy in patients with preexisting coagulopathy,⁵² severe recurrent GI bleeding due to multiple GI angiodysplasias in a patient with vW disease,⁵³ massive colonic bleeding⁵⁴ or exsanguinating bleeding due to Mallory-Weiss tear.⁵⁵ Of note, no thromboembolic events were reported in the aforementioned trials or series. However, secondary myocardial and cerebrovascular infarctions have been described while using factor VIIa.^{56,57} As such, it is important to stress once more that the use of this drug should always be carefully individualized.

5.5 Tamoxifen

In a recent randomized, double-blind placebo controlled trial, the efficacy of antiestrogen therapy (Tamoxifen) was evaluated in patients with epistaxis due to HHT.⁵⁸ There was a significant reduction in the frequency of epistaxis in the tamoxifen-treated group, frequently associated to a rise in haemoglobin or a reduction in transfusion requirements. As previously mentioned in the case of bevacizumab, a potential therapeutic role for GI bleeding in HHT patients warrants further research.

5.6 Non-selective beta-blockers

These drugs aim to control hemorrhage by reducing gastrointestinal blood flow due to splanchnic vasoconstriction and reduction of cardiac output in cirrhotic patients with portal hypertension. Its proven benefit for secondary prophylaxis of bleeding portal hypertensive gastropathy in two randomized controlled trials led to the consensus recommendation that beta-blockers should be used for chronic bleeding once the acute episode of bleeding is controlled.^{59,60}

6. References

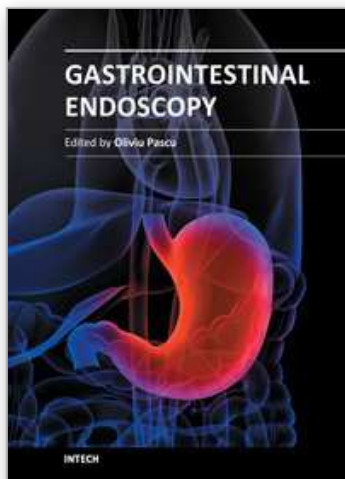
- [1] ASGE Standards of Practice Committee, Fisher L, Lee Krinsky M, Anderson MA, et al. The role of endoscopy in the management of obscure GI bleeding. *Gastrointest Endosc* 2010;72:471-9.
- [2] Zuckerman GR, Prakash C, Ashkin MP, et al AGA technical review: evaluation and management of occult and obscure gastrointestinal bleeding. *Gastroenterology* 2000;118:20.
- [3] Harrison DF. Use of estrogen in treatment of familial hemorrhagic telangiectasia. *Laryngoscope* 1982;92: 314-20.
- [4] Van Cutsem E, Rutgeerts P, Vantrappen G. Treatment of bleeding gastrointestinal vascular malformations with oestrogen-progesterone. *Lancet* 1990;335:953-5.
- [5] Lewis B, Salomon P, Rivera-MacMurray S, et al. Does hormonal therapy have any benefit for bleeding angiodysplasia?. *J Clin Gastroenterol* 1992;15: 99-103.
- [6] Junquera F, Feu F, Papo M, et al. A multicenter, randomized, clinical trial of hormonal therapy in the prevention of rebleeding from gastrointestinal angiodysplasia. *Gastroenterology* 2001; 121:1073-9.

- [7] Rossini FP, Arrigoni A, Pennazio M. Octreotide in the treatment of bleeding due to angiodysplasia of the small intestine. *Am J Gastroenterology* 1993;88:1424-7.
- [8] Luerosaki M, Saeger W, Abe T, et al. Expression of vascular endothelial growth factor in growth hormone-secreting pituitary adenomas: special reference to the octreotide management. *Neurol Res* 2008;30:518-2.
- [9] Nardone G, Rocco A, Balzano T, et al. The efficacy of octreotide therapy in chronic bleeding due to vascular abnormalities of the gastrointestinal tract. *Aliment Pharmacol Ther* 1999;13: 1429-36.
- [10] Spahr L, Giostra E, Frossard JL, et al. A 3-month course of long-acting repeatable octreotide (Sandostatin LAR) improves portal hypertension in patients with cirrhosis: a randomized controlled study. *Am J Gastroenterol* 2007;102:1397-405.
- [11] Brown C, Subramanian V, Wilcox CM, et al. Somatostatin analogues in the treatment of recurrent bleeding from gastrointestinal vascular malformations: an overview and systematic review of prospective observational studies. *Dig Dis Sci* 2010;55:2129-34.
- [12] Junquera F, Saperas S, Videla S, et al. Long-term efficacy of octreotide in the prevention of recurrent bleeding from gastrointestinal angiodysplasia. *Am J Gastroenterol* 2007; 102:254-60.
- [13] Orsi P, Guatti-Zuliani C, Okolicsanyi L. Long-acting octreotide is effective in controlling rebleeding angiodysplasia of the gastrointestinal tract. *Dig Liver Dis* 2001;33:330-4.
- [14] Tamagno G, Mioni R, De Carlo E, et al. Effects of a somatostatin analogue in occult gastrointestinal bleeding: a case report. *Dig Liver Dis* 2004;36:843-6.
- [15] Krikis N, Tziolamos K, Perifanis V, et al. Treatment of recurrent gastrointestinal haemorrhage in a patient with von Willebrand's disease with octreotide LAR and propranolol. *Gut* 2005;54: 171.
- [16] Molina-Infante J, Perez-Gallardo B, González-García G, et al. Octreotide LAR for severe obscure-overt gastrointestinal haemorrhage in high-risk patients on anticoagulation therapy. *Gut* 2007;56:447.
- [17] Boesby L, Christensen NJ, Kristensen LO. Somatostatin analogues in the treatment of bleeding GI-angiodysplasias. *Ugeskr Laeger* 2008;170:958.
- [18] Almadi M, Ghali PM, Constantin A, et al. Recurrent obscure gastrointestinal bleeding: dilemmas and success with pharmacological therapies. Case series and review. *Can J Gastroenterol* 2009; 23:625-31.
- [19] Scaglione G, Pietrini L, Russo F, et al. Long-acting octreotide as rescue therapy in chronic bleeding from gastrointestinal angiodysplasia. *Aliment Pharmacol Ther* 2007;26:935-42.
- [20] Molina-Infante J, Perez-Gallardo B, Hernandez-Alonso M, et al. Octreotide long acting release for severe obscure gastrointestinal haemorrhage in elderly patients with serious comorbidities. *Med Clin (Barc)* 2009;133:667-70.
- [21] Hutchinson JM, Jennings JS, Jones RL. Long-acting somatostatin therapy in obscure-overt gastrointestinal bleeding in noncirrhotic portal hypertension: a case report and literature review. *Eur J Gastroenterol Hepatol* 2010;22:754-8.
- [22] Shurafa M, Kamboj G. Thalidomide for the treatment of bleeding angiodysplasias. *Am J Gastroenterol* 2003;98:221-2.
- [23] Bauditz J, Schachschal G, Wedel S, et al. Thalidomide for treatment of severe intestinal bleeding. *Gut* 2004;53:609-12.

- [24] Karajeh MA, Hurlstone DP, Stephenson TJ, et al. Refractory bleeding from portal hypertensive gastropathy: a further novel role for thalidomide therapy?. *Eur J Gastroenterol Hepatol* 2006;18:545-8.
- [25] Craanen ME, van Triest B, Verjehien RH, et al. Thalidomide in refractory haemorrhagic radiation induced proctitis. *Gut* 2006;55:1371-2.
- [26] Hirri HM, Green PJ, Lindsay J. Von Willebrand's disease and angiodysplasia treated with thalidomide. *Haemophilia* 2006;12:285-6.
- [27] De Konig DB, Drenth JP, Friederich P, et al. Thalidomide for the treatment of recurrent gastrointestinal blood loss due to intestinal angiodysplasias. *Ned Tijdschr Geneesk* 2006;150:1994-7.
- [28] Kirhkan SA, Lindley KJ, Elawad MA, et al. Treatment of multiple small bowel angiodysplasias causing severe life-threatening bleeding with thalidomide. *J Pediatr Gastroenterol Nutr* 2006;42:585-7.
- [29] Jimenez-Saenz M, Romero-Vazquez J, Caunedo-Alvarez J, et al. Beneficial effects and reversión of vascular lesions by thalidomide in a patient with bleeding portal hypertensive enteropathy. *Dig Liver Dis* 2010;42:232-3.
- [30] Bauditz J, Lochs H, Voderholzer W. Macroscopic appearance of intestinal angiodysplasias under antiangiogenic treatment with thalidomide. *Endoscopy* 2006;38:1036-9.
- [31] Dabak V, Kuriakose P, Kamboj G, et al. A pilot study of thalidomide in recurrent GI bleeding due to angiodysplasias. *Dig Dis Sci* 2008;53:1632-5.
- [32] Kamalaporn P, Saravanan R, Cirocco M, et al. Thalidomide for the treatment of chronic gastrointestinal bleeding from angiodysplasias: a case series. *Eur J Gastroenterol Hepatol* 2009;21:1347-50.
- [33] Hamadani M, Benson DM Jr, Copelan EA. Thalidomide-induced fulminant hepatic failure. *Mayo Clin Proc* 2007;82:638.
- [34] Bowcock SJ, Patrick HE. Lenalidomide to control gastrointestinal bleeding in hereditary haemorrhagic telangiectasia: potential implications for angiodysplasias?. *Br J Haematol* 2009;146:220-2.
- [35] Flieger D, Hainke S, Fischbach W. Dramatic improvement in hereditary hemorrhagic telangiectasia after treatment with the vascular endothelial growth factor (VEGF) antagonist bevacizumab. *Ann Hematol* 2006;85:631.
- [36] Mitchell A, Adams LA, MacQuillan G, et al. Bevacizumab reverses need for liver transplantation in hereditary hemorrhagic telangiectasia. *Liver Transpl* 2008;14:210-3.
- [37] Bose P, Holter JL, Selby GB. Bevacizumab in hereditary hemorrhagic telangiectasia. *N Engl J Med* 2009;361:931.
- [38] Karnezis TT, Davidson TM. Efficacy of intranasal bevacizumab (Avastin) treatment in patients with hereditary hemorrhagic telangiectasia-associated epistaxis. *Laryngoscope* 2011;121:636-8.
- [39] Saba HI, Morelli GA, Logrono LA. Brief report: Treatment of bleeding in hereditary hemorrhagic telangiectasia with aminocaproic acid. *N Engl J Med* 1994; 330:1789.
- [40] Philips MD. Stopping bleeding in hereditary telangiectasia. *N Engl J Med* 1994; 330:1822-1823.

- [41] Vujkovic B, Lavre J, Sabovic M. Successful treatment of bleeding from colonic angiodysplasias with tranexamic acid in a hemodialysis patient. *Am J Kidney Diseases* 1998;3:536-538.
- [42] McCormick PA, Ooi H, Crosbie O. Tranexamic acid for severe bleeding gastric antral vascular ectasia in cirrhosis. *Gut* 1998;42:750-2.
- [43] Gluud LL, Klingenberg SL, Langholz SE. Systematic review: tranexamic acid for upper gastrointestinal bleeding. *Aliment Pharmacol Ther* 2008;27:752-8.
- [44] Haq AU, Glass J, Netchvolodoff CV, et al. Hereditary hemorrhagic telangiectasia and danazol. *Ann Intern Med* 1988; 109:171.
- [45] Korzenik J, Topazian M, Burdge C, et al. Danazol in the treatment of GI hemorrhage secondary to hereditary hemorrhagic telangiectasia (abstract). *Gastroenterology* 1995; 108:A297.
- [46] Longacre AV, Gross CP, Gallitelli M, et al. Diagnosis and management of gastrointestinal bleeding in patients with haemorrhagic hereditary telangiectasia. *Am J Gastroenterol* 2003;98:59-63.
- [47] Quitt M, Froom P, Veisler A, et al. The effect of desmopressin on masive gastrointestinal bleeding in hereditary telangiectasia unresponsive to treatment with cryoprecipitate. *Arch Intern Med* 1990;150:1744-6.
- [48] Romero-Castro R, Jimenez-Saenz M, Pellicer-Bautista M, et al. Recombinant-activated factor VII as hemostatic therapy in eight cases of severe hemorrhage from esophageal varices. *Clin Gastroenterol Hepatol* 2004;2:78-84.
- [49] Bosch J, Thabut D, Bendtsen F, et al. Recombinant factor VIIa for upper gastrointestinal bleeding in patients with cirrhosis: a randomized, double-blind trial. *Gastroenterology* 2004; 127:1123-30.
- [50] Bosch J, Thabut D, Albillos A, et al. Recombinant factor VIIa for varicela bleeding in patients with advanced cirrosis: a randomized, controlled trial. *Hepatology* 2008;47:1604-14.
- [51] Vilstrup H, Markiewicz M, Biesma D, et al. Recombinant activated factor VIIa in an unselected series of cases with upper gastrointestinal bleeding. *Thromb Res* 2006;118:595-601.
- [52] Romero-Castro R, Jimenez-Saenz M, Pellicer-Bautista F, et al. Refractory bleeding after endoscopic sphincterotomy: a new indication for recombinant factor VII therapy?. *Am J Gastroenterol* 2004;99:2063-5.
- [53] Meijer K, Peters FT, van der Meer J. Recurrent severe bleeding from gastrointestinal angiodysplasia in a patient with von Willebrand's disease, controlled with recombinant factor VIIa. *Blood Coagul Fybrinolysis* 2001;12:211-3.
- [54] Mitchell JG, Speake WJ, Russell NK, et al. Recombinant factor VIIa: a useful tool for life-threatening colonic bleeding: a case report. *Dis Colon Rectum* 2007;50:2238-40.
- [55] Shah K, Banerjee D, Gambhir RP, et al. Mallory-Weiss tear: use of recombinant factor VII for exsanguinating bleed. *Trop Gastroenterol* 2009;30:226-7.
- [56] Basso IN, Keeling D. Myocardial infarction following recombinant activated factor VII in a patient with type 2A von Willebrand disease. *Blood Coagul Fybrinolysis* 2005; 15: 503-4.

- [57] Alkyldiz M, Turan I, Ozutemiz O, et al. A cerebrovascular event after single-dose administration of recombinant factor VIIa in a patient with esophageal variceal bleeding. *Dig Dis Sci* 2006;51:1647-9.
- [58] Yaniv E, Preis M, Hadar T, et al. Antiestrogen therapy for hemorrhagic hereditary telangiectasia: a double-blind placebo controlled trial. *Laryngoscope* 2009;119:284-8.
- [59] de Francis R. Evolving consensus in portal hypertension. Report of the Baveno IV consensus workshop on methodology of diagnosis and therapy in portal hypertension. *J Hepatol* 2005; 43:167-76.
- [60] Ripoll C, Garcia-Tsao G. The management of portal hypertensive gastropathy and gastric antral vascular ectasia. *Dig Liver Dis* 2011;43:345-51.



Gastrointestinal Endoscopy

Edited by Prof. Oliviu Pascu

ISBN 978-953-307-385-9

Hard cover, 272 pages

Publisher InTech

Published online 19, July, 2011

Published in print edition July, 2011

Endoscopy has had a major impact in the development of modern gastroenterology. By using different data it provided a better understanding of pathogenic mechanisms, described new entities and changed diagnostic and therapeutic strategies. Meanwhile, taking advantage of many technical advances, endoscopy has had a developed spectacularly. Video-endoscopes, magnification, confocal and narrow-band imaging endoscopes, endoscopic ultrasounds and enteroscopes emerged. Moreover, endoscopy has surpassed its function as an examination tool and it became a rapid and efficient therapeutic tool of low invasiveness. InTech Open Access Publisher selected several known names from all continents and countries with different levels of development. Multiple specific points of view, with respect to different origins of the authors were presented together with various topics regarding diagnostic or therapeutic endoscopy. This book represents a valuable tool for formation and continuous medical education in endoscopy considering the performances or technical possibilities in different parts of the world.

How to reference

In order to correctly reference this scholarly work, feel free to copy and paste the following:

Javier Molina-Infante, Gema Vinagre-Rodriguez and Miguel Fernandez-Bermejo (2011). Pharmacological Therapy for Recurrent Obscure Gastrointestinal Bleeding, *Gastrointestinal Endoscopy*, Prof. Oliviu Pascu (Ed.), ISBN: 978-953-307-385-9, InTech, Available from: <http://www.intechopen.com/books/gastrointestinal-endoscopy/pharmacological-therapy-for-recurrent-obscure-gastrointestinal-bleeding>

INTech
open science | open minds

InTech Europe

University Campus STeP Ri
Slavka Krautzeka 83/A
51000 Rijeka, Croatia
Phone: +385 (51) 770 447
Fax: +385 (51) 686 166
www.intechopen.com

InTech China

Unit 405, Office Block, Hotel Equatorial Shanghai
No.65, Yan An Road (West), Shanghai, 200040, China
中国上海市延安西路65号上海国际贵都大饭店办公楼405单元
Phone: +86-21-62489820
Fax: +86-21-62489821

© 2011 The Author(s). Licensee IntechOpen. This is an open access article distributed under the terms of the [Creative Commons Attribution 3.0 License](https://creativecommons.org/licenses/by/3.0/), which permits unrestricted use, distribution, and reproduction in any medium, provided the original work is properly cited.

IntechOpen

IntechOpen