

We are IntechOpen, the world's leading publisher of Open Access books Built by scientists, for scientists

6,900

Open access books available

185,000

International authors and editors

200M

Downloads

Our authors are among the

154

Countries delivered to

TOP 1%

most cited scientists

12.2%

Contributors from top 500 universities



WEB OF SCIENCE™

Selection of our books indexed in the Book Citation Index
in Web of Science™ Core Collection (BKCI)

Interested in publishing with us?
Contact book.department@intechopen.com

Numbers displayed above are based on latest data collected.
For more information visit www.intechopen.com



Rare and Emergency Gastric Bleeding Cause – Dieulafoy's Lesion

Baki Ekçi¹, Can Aktas², Sezgin Sarikaya², Asli Cetin Celik² and Didem Ay²

¹*Yeditepe University Hospital, Department of General Surgery, Istanbul,*

²*Yeditepe University Hospital, Department of Emergency Medicine, Istanbul
Turkey*

1. Introduction

Gastrointestinal bleeding is among the most common causes of emergency admissions. Having high mortality rates, high diagnosis and treatment costs, this condition constitutes a clinical problem that requires a multidisciplinary approach. Extra-varicose bleeding of the upper gastrointestinal system has still been frequent and it usually stops spontaneously. However, recurrent bleeding is the most important cause of mortality and morbidity. (Erickson & Glick, 1986; Rivkin & Lyakhovetskiy, 2005; Pfau et al., 2004)

Any remarkable cause could not be demonstrated in approximately 4-9% of massive upper gastrointestinal hemorrhage. (Cotton et al., 1973; Palmer, 1969). Bleeding and anemia might be associated with gastrointestinal vascular malformations. Some epidemiological studies suggest that symptomatic vascular anomalies may be present in approximately 1/10000 individuals (Hodgson et al., 2001). Dieulafoy's lesion is a rarely found vascular malformation in symptomatic vascular anomalies group of disease. It is commonly located in the proximal aspect of the stomach. Dieulafoy's lesion constitutes 1% to 5.8% of nonvariceal bleeds and is more common in men than in women (2:1) (Garg, 2007). Pathogenesis is still unknown, but it is assumed that it might be a congenital lesion (Regula et al., 2008). The typical lesion is generally located in the submucosa and described as a large tortuous vessel and a small defect in the overlying mucosal surface (Ekci et al., 2010; Vats et al., 2006). (Fig 1 & 2 & 3).

In 1884, Gallard first described this lesion, but it was attributed to a French surgeon Dieulafoy in literature (Alva et al., 2006). This medical condition usually presents with a large tortuous arteriole in the stomach wall that erodes and bleeds. In addition, this lesion is generally located at the lesser curvature of the stomach within 6 to 10 cm of the esophagogastric junction (Stojakov et al., 2007). It consists of a single large tortuous arteriole that does not exert normal branching or has a branch 1-5 mm in diameter (Fig 2 & 3). This size is more than the normal diameter of mucosal capillaries. The most common location of the lesion is the body of stomach, followed by the cardia and the esophagus, but they have also been reported in the esophagus, small and large bowel (Ekci et al., 2010; Turan et al., 2008).

This condition is commonly seen in elder males (Schmulewitz & Baillie, 2001; Stark et al., 1992). Large majority of patients having Dieulafoy's lesion might present with comorbidity

including cardiovascular diseases, diabetes, chronic renal failure and hypertension (Norton et al., 1999). However, in a study no association with concomitant disease was found (Veldhuyzen van Zanten et al, 1986)

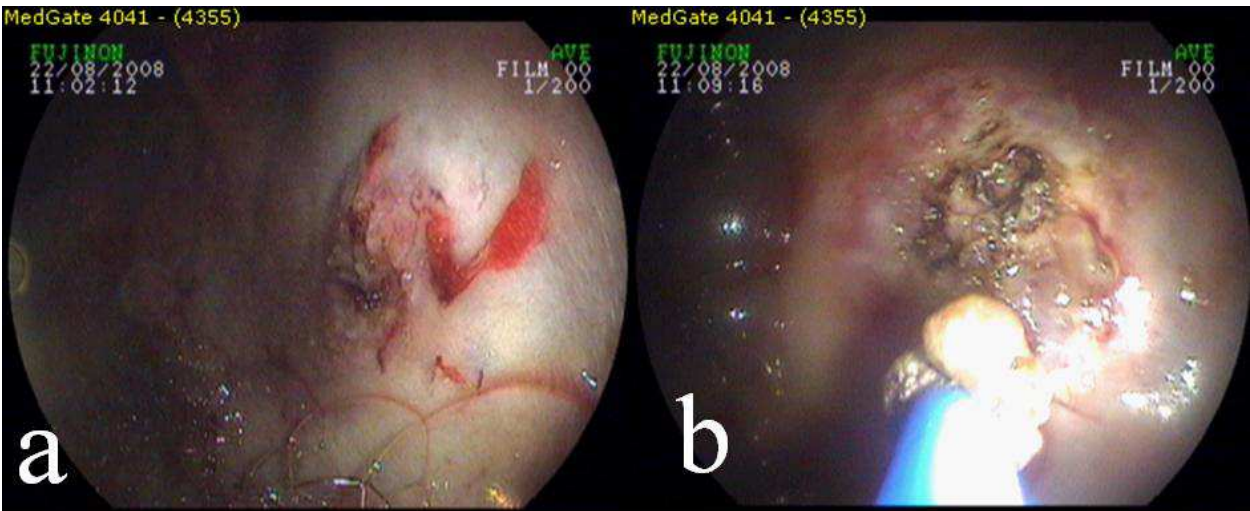


Fig. 1. **a**- Dieulafoy's lesion **b**: After heater probe application (Ekci et al., 2010)

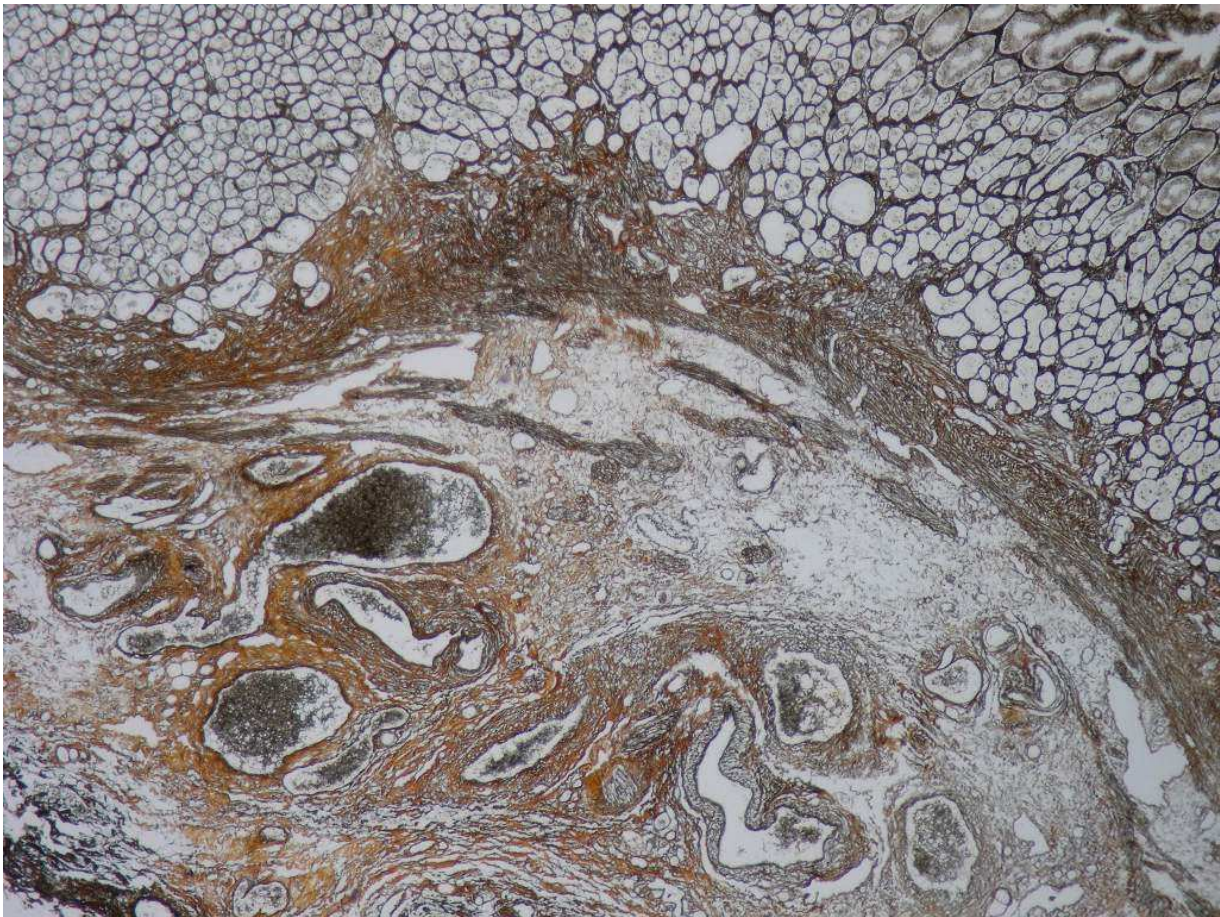


Fig. 2. Large tortuous malformed vessels in the gastric submucosa (Reticulin stain; x100) (Ekci et al., 2010)

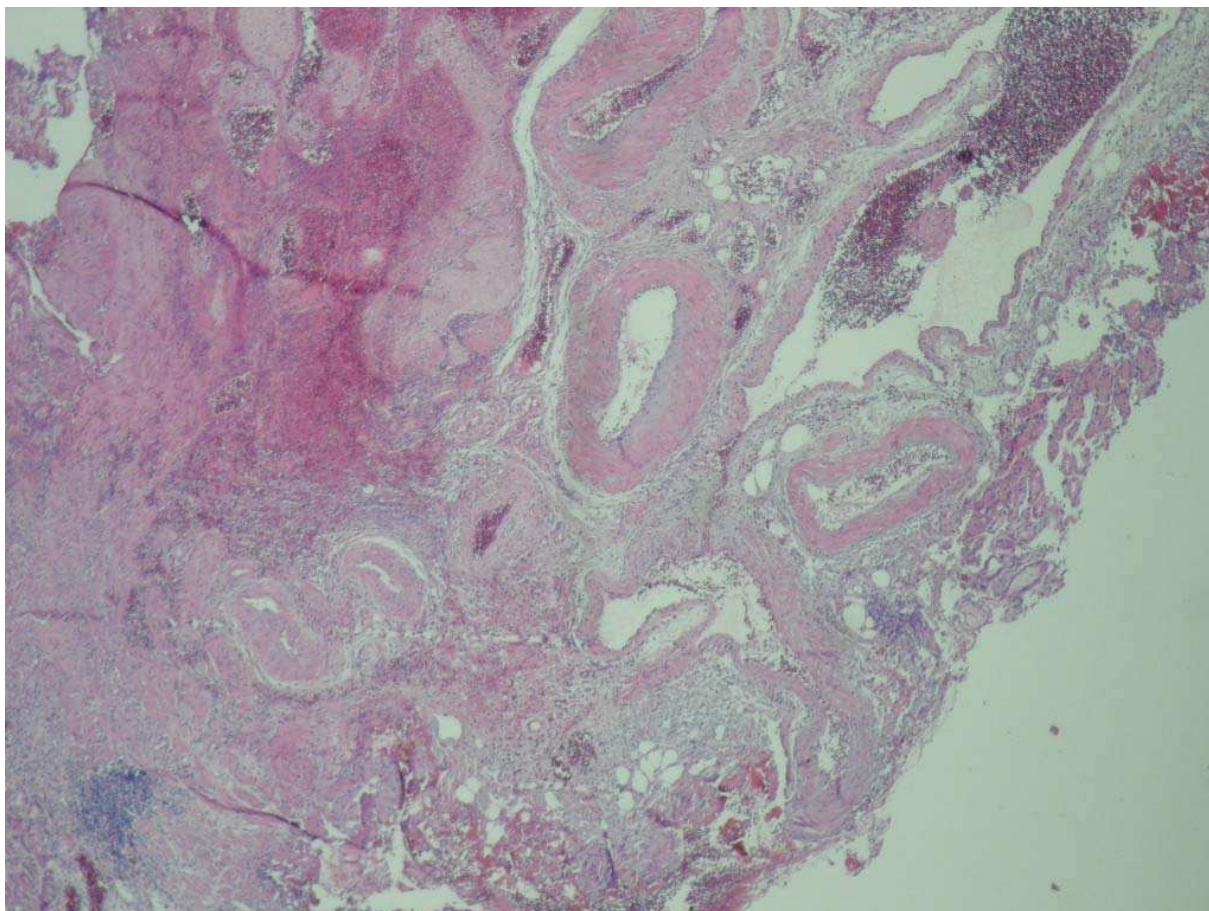


Fig. 3. Large tortuous vessels in the gastric submucosa and overlying eroded, necrotic mucosal surface could be seen (Hematoxylen and Eosin; x100) (Ekci et al., 2010)

The location of the Dieulafoy's lesion usually influences the variety of symptoms. It may rupture spontaneously and lead to massive bleeding. Therefore, the most common clinical symptom is recurrent, often massive, haematemesis associated with melaena (Ekci et al., 2010). However, lesion may present with haematemesis alone, or melaena alone. When this lesion occurs in the duodenum and proximal jejunum, patients often present with symptoms similar with gastric lesions. However, lesions in middle or distal jejunum as well as right colon and rectum are associated with massive rectal bleeding (Boix et al 1988 ; McClave et al 1988). Nearly all patients with this lesion may have hemodynamic instability. (Stark et al., 1992). In physical examination, hemodynamic instability and postural hypotension can be found. When gastrointestinal bleeding increases, hypotension and tachycardia become prominent. In such cases, transfusion for the initial resuscitation is usually necessary (Baettig et al., 1993; Reilly & Al-Kawas, 1991).

Occasionally, amyloid deposition may be found on the vessel wall (Rosai, 2004). In contrast, the histopathologic examination of large tortuous malformed vessels revealed no amyloid deposition in vessel walls (fig 2). The pathology in extragastric locations is essentially the same as that of the more common gastric lesion (Fig 3).

The standard treatment of Dieulafoy's lesion was surgical wedge resection in the past, but today the diagnosis of this lesion is made by endoscopy. Endoscopic methods should be the first choice of treatment in bleeding Dieulafoy's lesions (Yanar et al., 2007). In times when surgical resection was the choice of treatment, mortality and morbidity rates were high

(Goodman 1964). For the lesions located at colon, colonoscopy may be helpful in defining the source of bleeding (Barbier et al., 1985). Sometimes, multiple endoscopies may be necessary. Endoscopic evaluation reveals tiny ulcer, the protruding vessels, surrounding inflammatory reaction and occasionally a clot on this lesion. Since this lesion is small and the bleeding in stomach might interfere with the endoscopic visualization, the aspiration of intragastric blood and good air insufflation is necessary. If the visualization can not be enhanced with these interventions, endoscopy should be ended and restarted after the hemodynamic stabilization is achieved. Endoscopy is used for both diagnosis and treatment (Fig 1) Successful hemostasis has been reported with many different endoscopic techniques. Endoscopic hemoclip application, endoscopic band ligation, heater probe application, Nd:YAG, with or without epinephrine injection therapy have all been shown to be effective in various studies (Al-mushlab et al., 1999; Ekci et al., 2010). An experienced endoscopist and appropriate therapeutic instruments are essential to achieve a high success rate. Reilly et al. (Reilly & Al-Kawas, 1991) achieved permanent haemostasis in 85% of cases with endoscopic therapy. The authors concluded that of the remaining 15% in whom re-bleeding occurs, 10% can successfully be treated by repeat endoscopic therapy and 5% may ultimately require surgical intervention.

If endoscopic therapy fails, angiography with embolization or surgery is indicated (Alva et al., 2006; Garg, 2007; Reilly & Al-Kawas, 1991; Regula et al., 2008). While the bleeding is active, angiography might be helpful with cases in which initial endoscopy failed to show the bleeding source (Katz & Salas., 1993). It should be kept in mind that angiography can not make a diagnose unless there is active bleeding, and therefore, it is of little value. Angiography may also be used therapeutically by gelfoam embolisation (Helliwell & Irving, 1981).

In cases where endoscopic therapy is not effective, surgical therapy is necessary. After a gastrotomy and identification of the lesion, the bleeding vessel can be ligated. Furthermore, proximal gastric resection, or a large wedge resection might be performed. Limited wedge resection is most commonly employed surgical procedure (Turan et al., 2008; Ekci et al., 2010 ; Yanar et al., 2007). During surgery, intra-operative endoscopy might be helpful with the identification of the lesion, thereby unnecessary bowel resection is avoided.

In conclusion, for patients with Dieulafoy's disease, early diagnosis through emergency endoscopy and endoscopic therapy might be very effective and life saving. But if these techniques are not successful, surgical management should be the treatment choice.

2. References

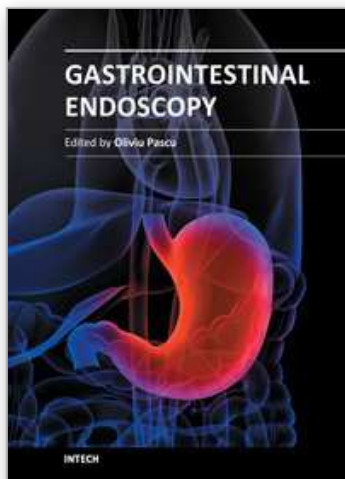
- Al-mushlab T, Amin AM, Ellul JPM. (1999) Dieulafoy's lesion: an obscure cause of GI bleeding. *J. R. Coll. Surg. Edinb.* 44, 222-5
- Alva. S, Abir F, Tran DD. (2006) Laparoscopic Gastric Wedge Resection for Dieulafoy's Disease Following Preoperative Endoscopic Localization With India Ink and Endoscopic Clips. *JSLs* 10: 244-246
- Baettig B, Haecki W, Lammer F, Jost R. (1993) Dieulafoy's disease: endoscopic treatment and follow up. *Gut* 34: 1418-21
- Barbier P, Luder P, Triller J, Ruchti CH, Hassler H, Stafford A. (1985) Colonic haemorrhage from a solitary minute ulcer. Report of three cases. *Gastroenterology* 88: 1065-8
- Boix J, Humbert P, Fernandez-Llamazares J, Planas R, Ojanguren I, Salva JA. (1988) Dieulafoy malformation. *Dig Dis Sci* 33: 1496-7

- Cotton, PB. Rosenberg MT, Waldram RPL, Axon ATR. (1973) Early endoscopy of oesophagus, stomach, and duodenal bulb in patients with haematemesis and melaena. *Br Med J* 2: 505-9
- Ekci B, Gokce O, Ekici I, Akyuz U. (2010). A dangerous gastric bleeding cause: Dieulafoy's lesion. *Hong Kong J Emerg Med* 17:177-79
- Erickson RA, Glick ME. (1986) Why have controlled trials failed to demonstrate a benefit of esophagogastroduodenoscopy in acute upper gastrointestinal bleeding? A probability model analysis. *Dig Dis Sci* 31: 760-8.
- Garg, R. (2007) Bleeding from a gastric Dieulafoy lesion. *Emerg.Med.J.* 24: 520
- Goodman RL. (1964) Mucosal arterial malformation ("aneurysm") of the stomach with fatal hemorrhage. *Gastroenterology* 46: 589-94.
- Helliwell M, Irving JD. (1981) Haemorrhage from gastric artery aneurysms. *Br Med J* 282: 460-1
- Hodgson, H. Watkinson A, Gordon FH. (2001) Vascular malformations of the gastrointestinal tract. *Best Practice & Research Clinical Gastroenterology*. 15: 41-58.
- Katz, PO. (1993) Salas L. Less frequent causes of upper gastrointestinal bleeding. *Gastroenterol Clin Nor Amer* 22: 875-89
- McClave SA, Goldschmid S, Cunningham JT, Boyd W Jr. (1988) Dieulafoy cirroid aneurysm of the duodenum. *Dig Dis Sci* 33: 801-5
- Norton ID, Petersen BT, Sorbi D, Balm RK, Alexander GL, Gostout CJ. (1999) Management and long-term prognosis of Dieulafoy lesion. *Gastrointest Endosc* 50: 762-767
- Palmer, ED. (1969) The vigorous diagnostic approach to upper gastrointestinal tract haemorrhage. *JAMA* 207: 1477-80
- Pfau PR, Cooper GS, Carlson MD, Chak A, Sivak MV Jr, Gonet JA, Boyd KK, Wong RC. (2004) Success and shortcomings of a clinical care pathway in the management of acute nonvariceal upper gastrointestinal bleeding. *Am J Gastroenterol* 99: 425-31.
- Regula, J. Wronska E, Pachlewski J. (2008) Vascular lesions of the gastrointestinal tract . *Best Practice & Research Clinical Gastroenterology* 22: 313-28
- Reilly HF, Al-Kawas FH.(1991) Dieulafoy lesion: Diagnosis and management. *Dig Dis Sci* 36:1702-7
- Rivkin K, Lyakhovetskiy A. (2005) Treatment of nonvariceal upper gastrointestinal bleeding. *Am J Health Syst Pharm* 62: 1159-70.
- Rosai, J. (2004) in Rosai and Ackerman's Surgical Pathology. Mosby press, New York, Volume 1, Chapter 11 (Stomach); p:656
- Schmulewitz N, Baillie J. (2001) Dieulafoy lesion: A review of 6 years of experience at a tertiary referral center. *Am J Gastroenterol* 96: 1688-1694
- Stark ME, Gostout CJ, Balm RK. (1992) Clinical features and endoscopic management of Dieulafoy's disease. *Gastrointest Endosc* 38: 545-50.
- Stojakov, D. Velicković D, Sabljak P, Bjelović M, Ebrahimi K, Spica B, Sljukić V, Pesko P. (2007) Dieulafoy's lesion: rare cause of massive upper gastrointestinal bleeding. *Acta Chir Iugosl.* 54:125-9
- Turan, I. (2008) Ozturk A, Akarca U, Ozutemiz O. An unusual cause of massive upper gastrointestinal bleeding: Dieulafoy's lesion within a giant midesophageal diverticulum. *Endoscopy* 40: 177
- Vats, HS. Wengert TJ, Torbey CF. (2006) Gastrointestinal Stromal Tumor with Dieulafoy Lesion:A Novel Association. *Clinical Medicine & Research* 4: 228-9

- Veldhuyzen van Zanten SJ, Bartelsman JF, Schipper ME, Tytgat GN. (1986) Recurrent massive hematemesis from Dieulafoy vascular malformations- a review of 101 cases. *Gut* 27: 213-222
- Yanar, H. (2007) Dolay K, Ertekin C, Taviloglu K, Ozcinar B, Guloglu R, Barbaros U. An infrequent cause of upper gastrointestinal tract bleeding: "Dieulafoy's lesion". *Hepatogastroenterology*. 54: 1013-7

IntechOpen

IntechOpen



Gastrointestinal Endoscopy

Edited by Prof. Oliviu Pascu

ISBN 978-953-307-385-9

Hard cover, 272 pages

Publisher InTech

Published online 19, July, 2011

Published in print edition July, 2011

Endoscopy has had a major impact in the development of modern gastroenterology. By using different data it provided a better understanding of pathogenic mechanisms, described new entities and changed diagnostic and therapeutic strategies. Meanwhile, taking advantage of many technical advances, endoscopy has had a developed spectacularly. Video-endoscopes, magnification, confocal and narrow-band imaging endoscopes, endoscopic ultrasounds and enteroscopes emerged. Moreover, endoscopy has surpassed its function as an examination tool and it became a rapid and efficient therapeutic tool of low invasiveness. InTech Open Access Publisher selected several known names from all continents and countries with different levels of development. Multiple specific points of view, with respect to different origins of the authors were presented together with various topics regarding diagnostic or therapeutic endoscopy. This book represents a valuable tool for formation and continuous medical education in endoscopy considering the performances or technical possibilities in different parts of the world.

How to reference

In order to correctly reference this scholarly work, feel free to copy and paste the following:

Baki Ekçi, Can Aktas, Sezgin Sarikaya, Asli Cetin Celik and Didem Ay (2011). Rare and Emergency Gastric Bleeding Cause – Dieulafoy's Lesion, *Gastrointestinal Endoscopy*, Prof. Oliviu Pascu (Ed.), ISBN: 978-953-307-385-9, InTech, Available from: <http://www.intechopen.com/books/gastrointestinal-endoscopy/rare-and-emergency-gastric-bleeding-cause-dieulafoy-s-lesion>

INTECH
open science | open minds

InTech Europe

University Campus STeP Ri
Slavka Krautzeka 83/A
51000 Rijeka, Croatia
Phone: +385 (51) 770 447
Fax: +385 (51) 686 166
www.intechopen.com

InTech China

Unit 405, Office Block, Hotel Equatorial Shanghai
No.65, Yan An Road (West), Shanghai, 200040, China
中国上海市延安西路65号上海国际贵都大饭店办公楼405单元
Phone: +86-21-62489820
Fax: +86-21-62489821

© 2011 The Author(s). Licensee IntechOpen. This is an open access article distributed under the terms of the [Creative Commons Attribution 3.0 License](https://creativecommons.org/licenses/by/3.0/), which permits unrestricted use, distribution, and reproduction in any medium, provided the original work is properly cited.

IntechOpen

IntechOpen