

We are IntechOpen, the world's leading publisher of Open Access books Built by scientists, for scientists

6,900

Open access books available

185,000

International authors and editors

200M

Downloads

Our authors are among the

154

Countries delivered to

TOP 1%

most cited scientists

12.2%

Contributors from top 500 universities



WEB OF SCIENCE™

Selection of our books indexed in the Book Citation Index
in Web of Science™ Core Collection (BKCI)

Interested in publishing with us?
Contact book.department@intechopen.com

Numbers displayed above are based on latest data collected.
For more information visit www.intechopen.com



Histopathology and Other Methods for Detection of Viral Hemorrhagic Septicemia (VHS) in Some Iranian Rainbow Trout Farms

Adel Haghighi Khiabani Asl

*Department of Pathology, Veterinary Sciences School,
Science and Research Branch, Islamic Azad University,
Tehran,
Iran*

1. Introduction

Viral haemorrhagic septicaemia (VHS) is one of the most economically important viral disease problems in European salmonid aquaculture (Jorgensen, 1974). It has been widely reported that VHS disease can cause mass mortality in farmed rainbow trout (*Oncorhynchus mykiss*) of all ages. Recently, this disease was found in rainbow trout cultured in the Pacific Ocean and also in farms rearing marine species. Several cases of VHS disease have been reported in rainbow trout breeding farms in Iran. Water temperature also plays an important role in the course of a VHS outbreak (Ahne & Thomsen, 1985), with the disease a more serious problem at water temperatures below 15-16°C (McAllister, 1979). Disease outbreaks usually occur between water temperatures of 4-14°C. The first VHS disease outbreaks occurred in Iranian aquaculture in November 2005 at Rodsar of Gilan province in the north of Iran with water temperatures measured at 10°C.

Viral haemorrhagic septicaemia (VHS) is considered the most serious disease of rainbow trout in aquaculture. It can cause up to 80% mortality in affected stocks. Iran was historically free from this disease. However, in November 2005, a VHS outbreak caused high levels of mortality in Rodsar of Gilan province trout farm. This outbreak resulted in serious economic losses for many farms. Viral haemorrhagic septicaemia virus (VHSV) of the family Rhabdoviridae. VHS was first reported from a rainbow trout farm in Denmark and has since caused significant losses in rainbow trout farms in many countries in continental Europe. It has also been reported in Japan and Russia. A highly virulent new strain of VHS has been reported in a range of freshwater fish species in the USA. Viral hemorrhagic septicemia (VHS) is an acute to chronic viral disease of salmonids that causes serious economic problems in rainbow trout cultured in several European countries. Although this disease has not been detected in North America, it is included here as a disease of significant concern. The disease was first recognized by Schaeperclaus in Germany in 1938. In 1949, the disease was named Egtved disease after an outbreak in Denmark near a village of that name. In 1966, the Office Internationale d'Epizooties recommended that the name be changed to viral hemorrhagic septicemia to reduce confusion due to the names used in the various European countries where it occurs (Roberts 1978).

Viral hemorrhagic septicemia is caused by a bullet-shaped virus similar in size and shape to the virus that causes infectious hematopoietic necrosis (IHN) in North American salmonids. The VHS virus can be distinguished from IHN by specific serum neutralization tests (McAllister et al. 1974). The VHS rhabdovirion, genus *Novirhabdovirus*, is an enveloped, bullet-shaped particle about 180 nm long and 60 nm in diameter (Haghighi et al., 2008c).

The intact virion is composed of five structural proteins and contains one segment of single stranded RNA (de Kinkelin & Scherrer, 1970); (McAllister, 1974; de Kinkelin, 1983). Losses to VHS among infected rainbow trout fingerlings often exceed 90%. If fish are exposed for the first time at older ages, the resultant disease is more chronic and has a more prolonged course. Losses can be severe in cold water under crowded, stressful situations, even among older fish. The disease is transmitted by contact and from fish to fish through the water (Rasmussen 1965). If parent to progeny transmission occurs, it is suspected that the virus is spread as a contaminant during spawning operations rather than by the virus being carried within the egg (Roberts 1978). Outbreaks of VHS are most common and most severe during the winter. Losses taper off in the spring as water temperatures rise, cease during the summer, then recur sporadically in the fall. As for other viral diseases, there is no therapy for VHS. Avoidance is the only successful control technique (Ghittino 1965).

2. Etiology

A variety of clinical signs and histopathological changes may be apparent in fish infected with VHS virus. Some fish show frank clinical manifestations of disease, whereas others appear healthy. Historically, clinical and pathologic signs of VHS have been catalogued into acute, chronic, and latent forms. Acute signs are typically accompanied by a rapid onset of heavy mortality, whereas the later or chronic stage is associated with lower mortalities, which occur over a protracted time period. It has also been reported that apparent virus carriers can demonstrate no clinical signs of VHS (Roberts, 2001). Disease signs of VHS include; fish that appear lethargic, dark in colour, exophthalmic, and anaemic. Haemorrhages are often evident in the eyes, skin, gills and at the bases of the fins. Internally, profuse haemorrhaging can be found in periocular tissues, skeletal muscle, and viscera, while congestion of the liver tissue and necrosis of the haematopoietic tissues can also be found (Bruno & Poppe, 1996).

Horizontal transmission of VHSV through contact with infected stocks or VHSV contaminated water supplies has been associated with several VHS outbreaks in European salmonid aquaculture. Other potential transmission routes include; viruscontaminated nets, boots, egg crates or other equipment. Feeding cultured fish with wet fish food prepared from contaminated fish stocks can also transmit the virus. Such practices are considered high risk and should not be encouraged (Roberts & Shepherd, 1974). At present there is no evidence to suggest that VHSV can be vertically transmitted from parent to progeny.

There is no cure for VHS. Therefore, the best methods for the prevention of disease are based on prohibiting the use of the wet fish foods, minimising fish farm escapes, and ensuring that appropriate biosecurity practices are applied on all aquaculture facilities (Haghighi et al., 2007). In the case of a VHS outbreak on a farm, the site should be fallowed immediately and all holding ponds/tanks should be dried and disinfected.

Disinfection should be performed at least three months before restocking of the aquaculture facility (Ahne & Thomsen, 1985).

3. The species affected from VHS

VHS is principally a disease of farmed rainbow trout, but most salmonid fish are considered susceptible, as are whitefish (*Coregonus* spp), grayling and pike. The disease has also been reported in farmed turbot, wild Pacific herring and numerous other marine fish species (Jensen, M.H. 1965).

4. Geographic distribution

Research samples were collected from farmed rainbow trout populations that had symptoms of VHS disease. Fish were sampled between October 2004 and October 2006, from 100 rainbow trout sites in 10 provinces in Iran. Samples for diagnostic screening were aseptically collected from liver, kidney, spleen, bronchia, heart, intestine, and pancreas of rainbow trout with symptoms of VHS disease and all were screened by pathological Technique. The first confirmed VHS disease outbreaks occurred in Iranian aquaculture in November 2005 at Rodsar of Gilan province in the north of the country. In this study of 100 rainbow trout fish farms, 15 positive sites were identified by Histopathology. The results of this study reveal a potential high frequency of VHS virus in some centers of rainbow trout aquaculture in Iran and therefore the control and diagnosis of VHS disease is vitally important to the development of the Iranian rainbow trout aquaculture industry. This is the Important study of VHS infection in rainbow trout aquaculture sites in Iran and highlights the need for routine diagnostic screening of aquaculture facilities to control the spread of VHS disease.

5. Transmission

The disease is transmitted horizontally through contact with infected fish or water. Large numbers of virus are shed in the faeces, urine and sexual fluids. There is no vertical transmission of the virus (Amend, D.E 1975).

There is no treatment for VHS. As a notifiable disease there is a legal obligation to report any suspected outbreaks of VHS to the Fish Health Inspectorate.

If the disease were found on a farm, movement restrictions would be applied to all farms on the same river catchment and all contact sites. Attempts would be made to eradicate the disease and all contact sites would be investigated to look for evidence of the source and spread of the virus (Bellet, R. 1965).

The approved status of any infected area would be lost until a testing programme had been undertaken to confirm the eradication of the disease.

6. Clinical signs

The Office International des Epizooties (OIE), Manual of Diagnostic Tests for Aquatic Animals recommend that the following methods are used for VHS diagnosis:

1. Clinical signs of VHS disease.

2. Clinical methods (gross pathology - microscopic pathology - electron microscopy /cytopathology).
3. Agent detection and identification methods include; microscopic examination of histological sections, isolation of VHSV in cell culture then identification by one of the following confirmatory tests:- neutralisation assay, indirect fluorescent antibody test (IFAT), enzyme-linked antibody test (ELISA) and reverse-transcription polymerase chain reaction (OIE 2006).

Disease signs of VHS include; fish that appear lethargic, dark in colour, exophthalmic, and anaemic. Haemorrhages are often evident in the eyes, skin, gills and at the bases of the fins. Internally, profuse haemorrhaging can be found in periocular tissues, skeletal muscle, and viscera, while congestion of the liver tissue and necrosis of the haematopoietic tissues can also be found (Bruno & Poppe, 1996). Horizontal transmission of VHSV through contact with infected stocks or VHSV contaminated water supplies has been associated with several VHS outbreaks in European salmonid aquaculture. Other potential transmission routes include; virus contaminated nets, boots, egg crates or other equipment. Feeding cultured fish with wet fish food prepared from contaminated fish stocks can also transmit the virus. Such practices are considered high risk and should not be encouraged. At present there is no evidence to suggest that VHSV can be vertically transmitted from parent to progeny. There is no cure for VHS. Therefore, the best methods for the prevention of disease are based on prohibiting the use of the wet fish foods, minimising fish farm escapes, and ensuring that appropriate biosecurity practices are applied on all aquaculture facilities (Haghighi et al., 2007). In the case of a VHS outbreak on a farm, the site should be fallowed immediately and all holding ponds/tanks should be dried and disinfected. Disinfection should be performed at least three months before restocking of the aquaculture facility (Ahne & Thomsen, 1985).

The Office International des Epizooties (OIE), Manual of Diagnostic Tests for Aquatic Animals recommend that the following methods are used for VHS diagnosis: 1. Clinical signs of VHS disease. 2. Clinical methods gross pathology -microscopic pathology - electron microscopy/cytopathology). 3. Agent detection and identification methods include; microscopic examination of histological sections, isolation of VHSV in cell culture then identification by one of the following confirmatory tests:- neutralisation assay, indirect fluorescent antibody test (IFAT), enzyme-linked antibody test (ELISA) and reverse-transcription polymerase chain reaction (OIE 2006). This manuscript describes the one of the detection of VHSV from farmed rainbow trout in Iran by Histopathological identification method.

The VHS virus has also been isolated from the marine environment in the Baltic and North seas, the Atlantic Ocean and off the Pacific coast of North America.

Outbreaks of VHS in rainbow trout typically occur between temperatures of 7°C and 14°C. The disease progresses in three stages. The acute stage sees a rapid onset of high mortalities often with severe clinical signs such as darkening of body colour, exophthalmia (popeye), bleeding around eyes and fin bases, pale gills and petechial (pin point) haemorrhaging on the surfaces of the gills, viscera and in the muscle. During the second sub acute, or chronic stage, the body continues to darken, exophthalmia may become more pronounced but haemorrhaging around the eyes and fin bases is often reduced. Fish are severely anaemic and paleness is particularly evident in the abdomen. Fish may develop a spiralling swimming motion, corkscrewing around the body axis.



Fig. 1. An acute anemia in the gills with pale in color.

The final, nervous stage sees reduced mortality and clinical signs are usually absent. The corkscrew swimming motion becomes more pronounced.

External Signs:

1. Rainbow trout involved in acute outbreaks of VHS are dark in color, lethargic, and exhibit hemorrhages in the fin sockets. Exophthalmia (popeye) is common and persists throughout the course of the disease.
2. As the disease progresses, affected fish become nearly black. An acute anemia develops, and the gills are pale in color.
3. After several months, the mortality finally may cease and some of the remaining fish often display whirling behavior, erratic swimming and nervousness.

Internal Signs:

1. During acute outbreaks, small hemorrhages are common in the musculature, gills, and visceral organs. Massive hemorrhages can often be found in the abdominal cavity of freshly dead fish (Roberts 1978).
2. During mid-stages of a disease outbreak, internal organs become very pale. Visceral, intramuscular, and gill hemorrhages develop as distinctive signs of the disease.
3. In late stages of the disease, kidneys become swollen and discolored.



Fig. 2. Exophthalmia (popeye) with bleeding around eyes and dark in color are common signs of the disease.

Results

Province (state) Mazandaran Sample size Fish farms 25/Positive cases
2/Percent positive cases 8%
Province (state) Ardebil Sample size Fish farms 6/Positive cases
3/Percent positive cases 50%
Province (state) Lorestan Sample size Fish farms 8/Positive cases
(-)/Percent positive cases 0%
Province (state) Markazi Sample size Fish farms 4/Positive cases
2/Percent positive cases 50%
Province (state) North Khorasan Sample size Fish farms 6/Positive cases
2/Percent positive cases 33.3%
Province (state) Kordestan Sample size Fish farms 10/Positive cases
3/Percent positive cases 30%
Province (state) Kohkiloeh Sample size Fish farms 12/Positive cases
1/Percent positive cases 8.3%
Province (state) West Azarbayjan Sample size Fish farms 8/Positive cases
(-)/Percent positive cases 0%
Province (state) Esfahan Sample size Fish farms 12/Positive cases
(-)/Percent positive cases 0%
Total Sample size Fish farms 100/Positive cases 15/Percent positive cases 15%

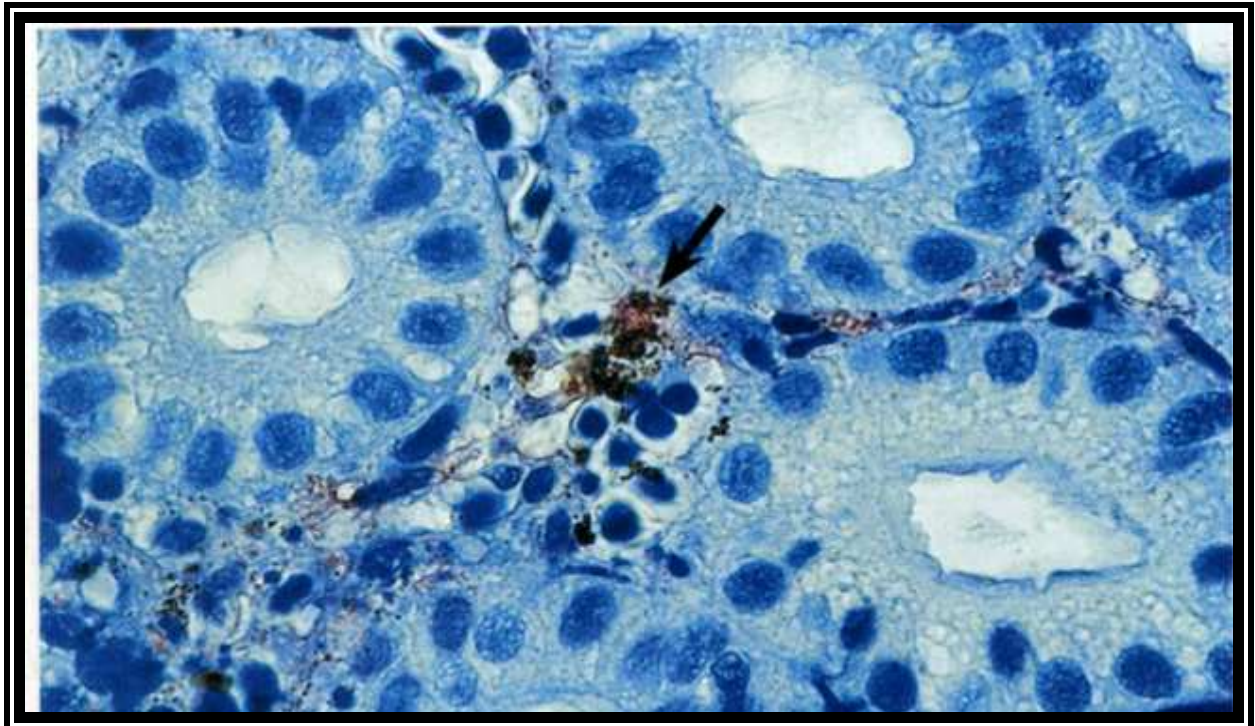


Fig. 3. The histopathological section of kidney, staining with immunoperoxidase assay technique indicates the localized virus in kidney haematopoietic tissue (arrow).

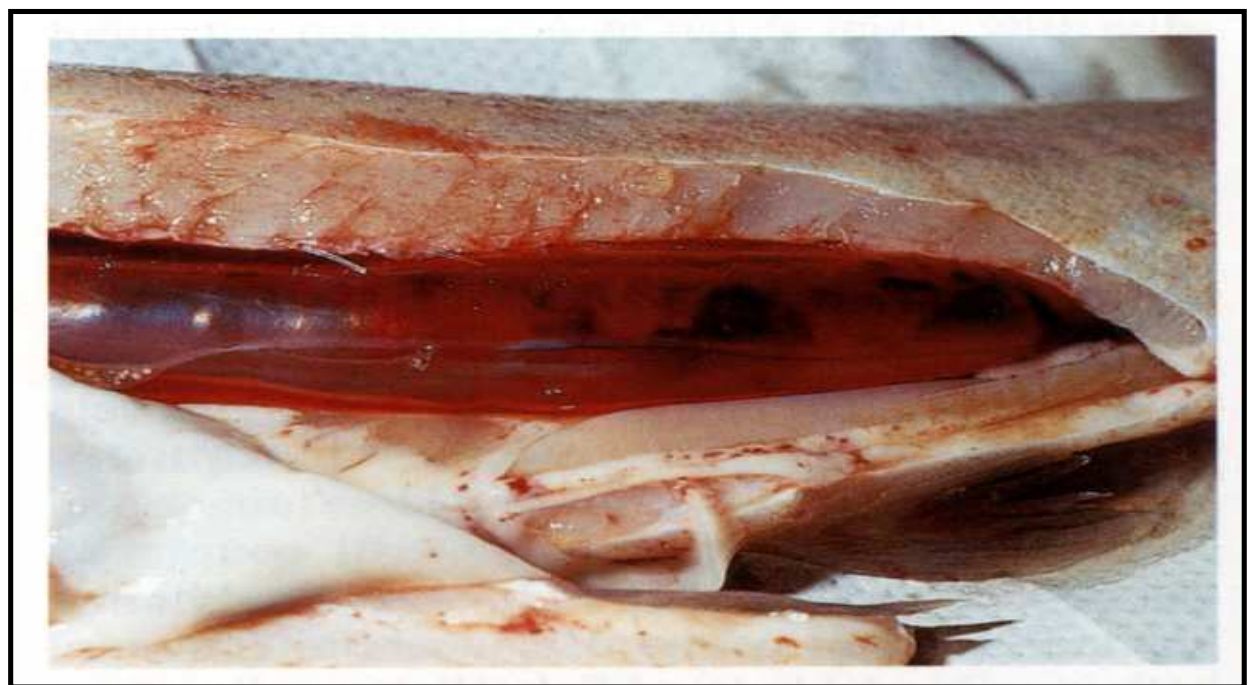

Fig. 4. Dissection of infected tissue with the typical signs as haemorrhage in swim bladder and visceral adipose caused by VHS.

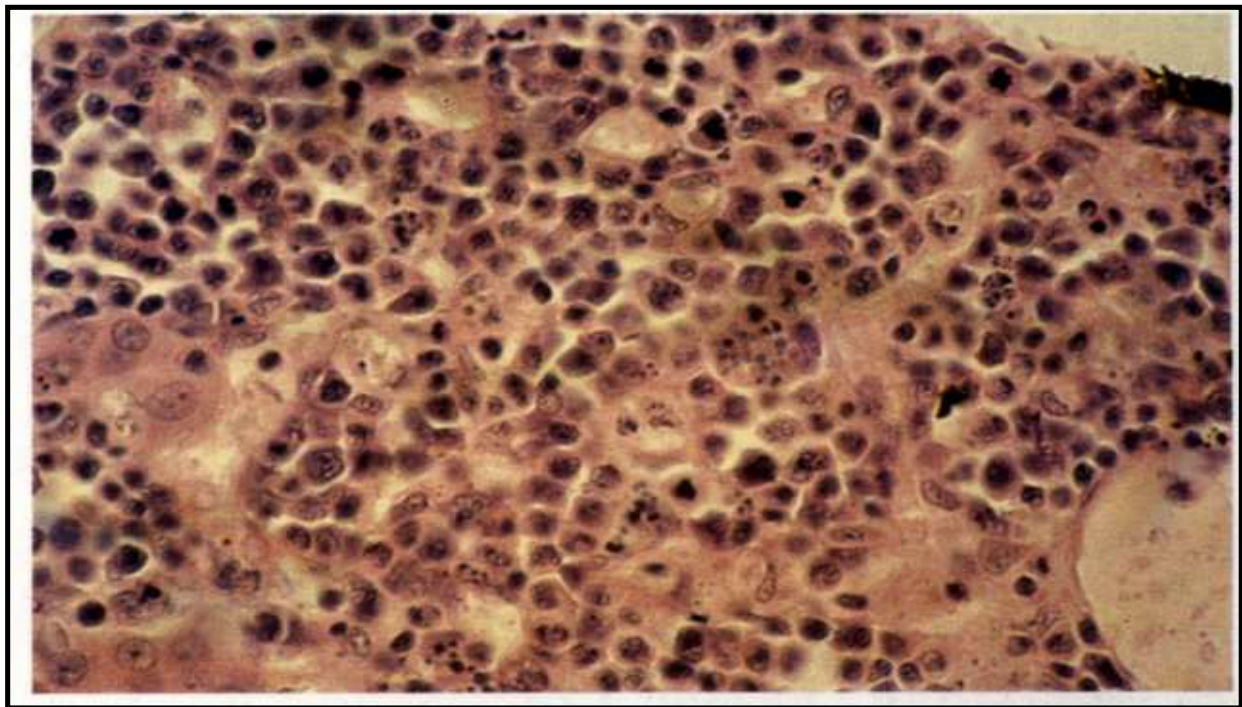


Fig. 5. The histopathological section of kidney, severe cellular necrosis with disintegrated nuclei (H&E staining).

7. Laboratory tests

7.1 Sample collection

All research samples were collected from farmed rainbow trout populations that had symptoms of VHS disease. Sixty fish were sampled from each farm, producing a 95% confidence that the disease would be detected at a 5% prevalence level, between October 2004 and October 2006. In total 100 rainbow trout farms in 10 provinces in Iran were sampled. Most of the fish sampled were rainbow trout fry, weighting between 3-5 grams, however from some sites in the Gilan, Mazandaran and Markazi (Arak) provinces rainbow trout broodfish were tested for VHSV. Disease outbreaks usually occurred between the months of November and March, at lower water temperatures between 4-14°C. Tissue samples for the Pathological method was aseptically dissected from anterior kidney, liver, spleen, heart, bronchi, intestine, pancreas, and muscle. Samples for Histopathological examination were stored in saline formalin 10% (Merck, Iran). All tissues were processed within 24h of sampling.

Results	Positive Cases	Negative Cases	Percent positive cases
Histopathology	15	85	15
Clinical Signs	18	82	18

Table 1. Sampling of Iranian rainbow trout fish farms for VHS virus by Histopathological method.

7.2 Serology

One of the important Serological techniques such as the ELISA method (Haghighi et al., 2007) is also useful diagnostic tools for screening.

Serological techniques use to confirmatory tests for identification such, neutralisation assay (SNT), enzyme-linked antibody test (ELISA).

7.3 Virus isolation in cell culture

One of the important and careful methods for detection and isolation of the virus pathogen agent is the cell culture. To study the pathogenicity and to obtain isolates of VHS virus the establishment of a laboratory with virus culture equipment is necessary (de Kinkelin, 1983).

7.4 Immunohistochemistry

This method was done as standard method, for eliminating cellular peroxide, slides were kept in a room temperature in 10% H₂O₂ for 10 min, were washed three times with TBS (0.05 M Tris base, 0.15 M NaCl, pH 7.6). In order to block unspecific sites, incubation done with normal serum for 10 min (Diluted in 1:10 TBS). About 50 µL of VHS monoclonal antibody (diluted by TBS 1:800) was added to slides and was kept at 37 °C for one hour. Slides were washed by TBS for 3 other times and then the conjugate (F(ab) 2 Rabbit Anti Mouse IgG-HRP) was added and kept for 30 min in 37°C. Slides were washed again for 3 times by TBS buffer and the substrate containing chromosole (DAB) Diaminobenzidine tetra hydro chloride 3) was added after 10 min slides were put in water in order to stop the reaction. About 3 to 5 min they were stained by hematoxiline (0.4 g sodium iodate, 100 g potassium alum, 100 g chloral hydrate, 2 g citric acid, 2000 ml ddH₂O) and were washed for 10 min by the water. To dehydration of tissue, slides were put in 70 % ethanol for 3 min, in 95% ethanol for 5 min, and again twice for 5 min in 100% ethanol. In order to make a transparent tissue it was put in xylol for 5 min. For microscopic study, slides were mounted and brown and golden structures in infected tissues were studied by magnifying lenses of 20, 40 and 100 (Haghighi et al., 2007).

7.5 Immunofluorescence

Indirect fluorescence Antibody test (IFAT) and Immunoperoxidase assay techniques (OIE, 2006) are important methods for screening test. In this methods by preparing of histopathological section from kidney or other tissues (spleen, liver), and staining with specialized Immunofluorescence and immunoperoxidase assay techniques indicates the localized virus in kidney haematopoietic tissue (arrow in figure 3).

7.6 Histopathology

Histopathology signs for diagnostic studies of the disease is one of the golden test. A standard tissue preparation method was applied, whereby all tissues from live or moribund fish were fixed in 10 % formalin for 24 hours. Samples were then embedded in a paraffin block and sectioned with digital microtome at 5-7 micrometer thickness. Slides were stained by haematoxin and eosin, then treated with mounting media (Roberts, 2001). A small number of samples were confirmed VHSV positive by immunoperoxidase assay as previously described (Haghighi et al., 2007). Samples were screened by pathological technique. The results of this study are summarized in table 1. Out of 100 fish farms, 15 sites tested VHSV positive by pathology method and 18 positive cases with clinical signs that, referred to VHS for further research electron microscopy and cytopathology tests (TEM & SEM) are proposed.

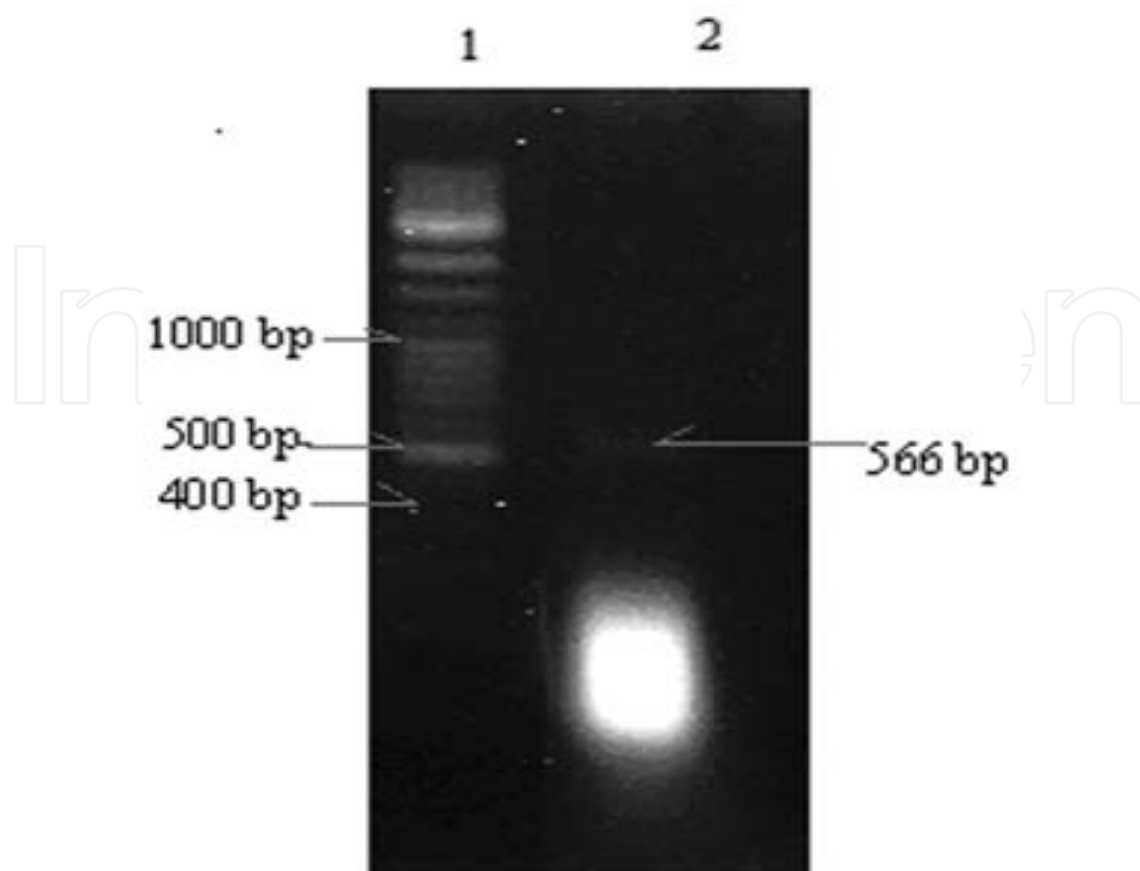


Fig. 6. Agarose gel electrophoresis. Lane 1: 100 bp ladder DNA marker. Lane 2: 566 bp PCR product related to VHS virusglycoprotein gene (agarose gel prepared on 2 %).

7.7 PCR method

The other way for diagnosis of VHS in Iran is PCR method. For this technique need **RNA extraction**, that Viral RNA extraction was done by RNXplus buffer following the manufacturers protocol (CinnaGen, Iran).

Briefly, about 1 cubic mm of fish tissue was transferred to 1.5 ml micro tube, then 200 μ l RNX plus buffer was added. The mixture was incubated for 5 min at room temperature, and then 50 μ l of chloroform was added and centrifuged at 12000 rpm for 15 min at 4°C.

Total tissue RNA (including viral RNA) was precipitated by ethanol, and then dissolved in 10 ml of diethyl pyrocarbonate treated water (Kazemi et al., 2004).

7.7.1 Reverse transcription reaction

Reverse transcription (RT) was performed as previously described (Pfeffer, 1988). Briefly, template RNA (1 ml) was incubated in a 20 ml reaction mixture containing: 40 pico mol of specific antisense external primer (VHS R 5'- TTT TGG AGT CAG TTT CCT CGC G - 3'), 100 unit of reverse transcriptase enzyme (RT) (Fermentas, Lithuania), 20 unit RNAsine (Fermentas, Lithuania), 1x RT buffer, 0.2 mM dNTP, for 1 h at 42°C.

A nested-PCR was used to amplify a fragment of the viral glycoprotein gene. The first PCR reaction mixture contained 10 μ l of synthesized cDNA, 1.5 mM MgCl₂, 0.1 mM dNTP, 1X PCR buffer, 40 pico mol each forward and reverse primers and 1.25 unit of Taq DNA polymerase (CinnaGen, Iran). Primers for nested PCR were designed based on virus

glycoprotein gene, Accession number Z93412 (Nest I primers: VHS F 5'- GTC CCA ACT CAG ATC ATC CAT C - 3' and VHS R 5'- TTT TGG AGT CAG TTT CCT CGC G - 3', amplified 617 bp of viral glycoprotein gene). The PCR was performed by 30 cycles of: denaturation at 94°C for 30 seconds, annealing at 58°C for 30 seconds and extension at 72°C for 40 seconds. 1 micro liter of PCR product was used as template DNA for the second PCR. The second PCR reaction was also performed within 30 cycles (Nest II primers: VHS2 F 5' - GCT ATC AGT CAC CAG CGT CTC - 3' and VHS2 R 5' - GGT CCT GTA ACC TGG ATC AGG - 3', amplified 566 bp of viral glycoprotein gene). Neither of the primer sets have been referenced previously (Haghighi et al., 2008b).

7.7.2 Detection of PCR product

Electrophoresis of the PCR product was performed on a 2% agarose gel, stained by ethidium bromide and DNA banding was observed by UV light under UV Transilluminator.

8. Conclusion

The results of this study indicate that VHS infection can be found in rainbow trout hatcheries and broodstock sites in Iran. The severity of VHS disease is dependant on the virulence of the virus strain, the immunological resistance of individual fish, stress factors and environmental conditions related to season, temperature, and PH changes (Ahne & Thomsen, 1985). An increased awareness of on-site hygiene and biosecurity rules, screening of broodstock populations for specific pathogens and isolation and quarantining of infected fish or fish with abnormal behaviour has played a major role in limiting the spread of VHS in Iran. Often, it is difficult to detect asymptomatic carriers of VHSV and this potentially could lead to a spread of infection. Therefore the innovation of sensitive and specific techniques for the detection of VHSV, such as PCR is necessary (Haghighi et al., 2008a).


Fish populations for VHSV. Disease is found in the some farms of rainbow trout breeding and propagation in Iran and Histopathological technique is useful for the diagnosis of disease.

For prevention must to be have, avoidance of VHS is by far the best approach to control (Jorgensen, P.E.V. 1977). No fish or eggs should be introduced from areas where VHS has been detected. There is no cue for VHS. Before discovery of the viral etiology of VHS, several European veterinarians believed the disease was the result of nutritional deficiencies. The finding of a viral agent explained why nutritional supplements and antibacterial treatments failed to control losses. Eradication plan is need for every country in outbreak of VHS.

9. References

- Amend, D.E 1975. Detection and transmission of infectious hematopoietic necrosis virus in rainbow trout. J. Wildl. Dis. 11: 471-478.
- Ahne W & Thomsen I (1985). Occurrence of viral hemorrhagic septicemia virus in wild whitefish *Coregonus* sp. Zentralbl. Veterinaermed. Reihe B 32, 7375.
- Bruno DW & Poppe TT (1996). A colour atlas of salmonid diseases. Academic Press, London. ISBN 0-12-137810-1.
- de Kinkelin P & Scherrer R (1970). Le Virus d'Egtved I. Stabilite, developpement et structure du virus de la souche danoise F1. *Annales de Recherches Veterinaires (Paris)* 1, 1730 (in French).

- de Kinkelin P (1983). Viral haemorrhagic septicaemia. In "Antigens of fish pathogens" (D.P. Anderson, M. Dorson and Ph. Dubourget, Eds.), pp. 5162. Fondation Marcel Merieux, Lyon, France.
- Bellet, R. 1965. Viral hemorrhagic septicemia (VHS) of rainbow trout in France. Am. N.Y. Acad. Sci. 126(1): 461-467.
- Ghittino, P 1965. Viral hemorrhagic septicemia (VHS) of rainbow trout in Italy. Ann. N.Y. Acad. Sci. 126(1): 468-478.
- Jensen, M.H. 1965. Research on the virus of Egtved disease. Ann. N.Y. Acad.Sci. 126(1): 422-426.
- Jorgensen, P.E.V. 1977. Surveillance and eradication of diseases from hatcheries, p. 72-73. In Proc. Int. Symp. Dis. Cult. Salm., Tavolek, Inc., Seattle. WA.
- Jorgensen, P.E.V. 1974. A study of viral diseases in Danish rainbow trout, their diagnosis and control. Ph.D. thesis. Danish Royal Vet. and Agri. Univ.Copenhagen. 101 p.
- McAllister, F.E., J.L. Fryer, and K.S. Pilcher. 1974. An antigenic comparison between infectious hematopoietic necrosis virus (OSV strain) and the virus of hemorrhagic septicemia of rainbow trout, *Salmo gairdneri* (Denmark strain) by cross neutralization. J. Wild. Dis. 10: 101-103.
- Rasmussen, C.J. 1965. A biological study of the Egtved disease (INUL). Ann. N.Y. Acad. Sci. 126(1): 427-460.
- Roberts, R.J. 1978. The virology of teleosts, p. 128-130. In R.J. Roberts (ed.) Fish pathology, R.J. Roberts (Ed.), Balliere Tindall, London.179
- Haghighi A, Soltani M, Kazemi B, Sohrabi I & Sharifpour I (2007). Use of Immunohistochemical and PCR Methods in Diagnosis of Infection Haematopoietic Necrosis Disease in some Rainbow Trout Hatcheries in Iran. *Pakistan Journal of Biological Sciences* 10(2), 230- 234.
- Haghighi, A., Z. Sharifnia, M. Bandehpour and B. Kazemi, (2008a). The first report of spring viraemia of carp in some rainbow trout propagation and breeding by pathology and molecular techniques in Iran. *AJAVA.*, 3: 263-268.
- Haghighi, A., M. Bandehpour, Z. Sharifnia and B. Kazemi, (2008b). Diagnosis of viral haemorrhagic septicaemia (VHS) in Iranian rainbow trout aquaculture by pathology and molecular techniques. *Bull. Eur. Assoc. Fish Pathol.*, 28: 171-175.
- A. Haghighi - Khiabani Asl, M. Azizzadeh, M. Bandehpour, Z. Sharinia and B. Kazemi (2008c). The First Report of SVC from Indian Carp Species by PCR and Histopathologic Methods in Iran, *Pakistan Journal of Biological (PJBS)* 2008 | Volume: 11 | Issue: 24 | Page No.: 2675-2678 DOI: 10.3923/pjbs.2008.2675.2678
- Kazemi B, Bandehpour M, Yahyazadeh H, Roozbehi M, Seyed N, Ghotasloo A & Taherpour A (2004). Comparative study on HCV detection in Iranian patients by RT- PCR and ELISA techniques during 2001-2003. *Journal of Medical Science* 4(2), 132- 135.
- The Office International des Epizooties (OIE) (2006). Manual of Diagnostic Tests for Aquatic Animals. Fifth edition, Notifiable disease chapter 2.1.5. pp. 141-158.
- Pfeffer U (1988). One Tube RT PCR with sequence Specific Primers. In "RNA isolation and characterization protocols", (R. Rapley and D.L. Manning, Eds.), pp. 143-151. Humana Press.
- Roberts RJ (2001). Fish pathology. Bailliere Tindall, London. Virology pp. 238-243 and pp. 386-387.



Recent Advances in Fish Farms

Edited by Dr. Faruk Aral

ISBN 978-953-307-759-8

Hard cover, 250 pages

Publisher InTech

Published online 21, November, 2011

Published in print edition November, 2011

The world keeps changing. There are always risks associated with change. To make careful risk assessment it is always needed to re-evaluate the information according to new findings in research. Scientific knowledge is essential in determining the strategy for fish farming. This information should be updated and brought into line with the required conditions of the farm. Therefore, books are one of the indispensable tools for following the results in research and sources to draw information from. The chapters in this book include photos and figures based on scientific literature. Each section is labeled with references for readers to understand, figures, tables and text. Another advantage of the book is the "systematic writing" style of each chapter. There are several existing scientific volumes that focus specially on fish farms. The book consists of twelve distinct chapters. A wide variety of scientists, researchers and other will benefit from this book.

How to reference

In order to correctly reference this scholarly work, feel free to copy and paste the following:

Adel Haghighi Khiabani Asl (2011). Histopathology and Other Methods for Detection of Viral Hemorrhagic Septicemia (VHS) in Some Iranian Rainbow Trout Farms, Recent Advances in Fish Farms, Dr. Faruk Aral (Ed.), ISBN: 978-953-307-759-8, InTech, Available from: <http://www.intechopen.com/books/recent-advances-in-fish-farms/histopathology-and-other-methods-for-detection-of-viral-hemorrhagic-septicemia-vhs-in-some-iranian-r>

INTECH
open science | open minds

InTech Europe

University Campus STeP Ri
Slavka Krautzeka 83/A
51000 Rijeka, Croatia
Phone: +385 (51) 770 447
Fax: +385 (51) 686 166
www.intechopen.com

InTech China

Unit 405, Office Block, Hotel Equatorial Shanghai
No.65, Yan An Road (West), Shanghai, 200040, China
中国上海市延安西路65号上海国际贵都大饭店办公楼405单元
Phone: +86-21-62489820
Fax: +86-21-62489821

© 2011 The Author(s). Licensee IntechOpen. This is an open access article distributed under the terms of the [Creative Commons Attribution 3.0 License](https://creativecommons.org/licenses/by/3.0/), which permits unrestricted use, distribution, and reproduction in any medium, provided the original work is properly cited.

IntechOpen

IntechOpen