

We are IntechOpen, the world's leading publisher of Open Access books Built by scientists, for scientists

6,900

Open access books available

186,000

International authors and editors

200M

Downloads

Our authors are among the

154

Countries delivered to

TOP 1%

most cited scientists

12.2%

Contributors from top 500 universities



WEB OF SCIENCE™

Selection of our books indexed in the Book Citation Index
in Web of Science™ Core Collection (BKCI)

Interested in publishing with us?
Contact book.department@intechopen.com

Numbers displayed above are based on latest data collected.
For more information visit www.intechopen.com



Genital Skin Flap Urethroplasty

Abimbola O. Olajide
Ladoke Akintola University of Technology
Nigeria

1. Introduction

Urethral stricture disease is one of the commonest diseases treated by Urologists. No two forms of the disease can be assumed to be the same because of the varied aetiologies and modalities of management. Choice of treatment modality depends on location of the stricture, available facilities and the experience of the managing surgeon.

Urethral dilatation and internal urethrotomy as modalities of treatment have limited usage in current day practice because when there is associated spongiofibrosis, they are not curative. Urethral reconstruction has therefore become the mainstay treatment of urethral stricture disease when the aim is to cure the patient of such a crippling ailment. (Rosen et al., 1994) Anastomotic urethroplasty is considered the best form of reconstruction when possible because no tissue can replace the urethra better than the urethra itself. (Santucci et al., 2002) However, anastomotic urethroplasty has limited application in urethral reconstruction because it can cause abnormal penile curvature (chordee) due to shortening of the urethra relative to the spongy tissues during penile erection. This may result in painful erection and disturbance of sexual function with resultant psychological disturbances. Anastomotic urethroplasty is therefore better avoided in reconstruction of some urethral stricture like those located in the penile urethra or long segment stricture (>2cm) located in the bulbar urethra. In such cases, substitution urethroplasty is considered most appropriate. (Kellner et al., 2004) Since its introduction, substitution urethroplasty has remained one of the standard methods for urethral reconstruction especially in difficult urethral stricture or where other modalities of treatment have failed. (Olajide et al., 2010)

Several tissues have been used to replace diseased urethra and the best tissue to use is an area of controversy. Buccal mucosa, bladder mucosa, intestinal mucosa, scrotal skin, perineal skin and penile skin are some of the tissues that have been used. Some are used as graft while others are used as flaps. However, one incontrovertible finding is the fact that flaps have an obvious advantage over grafts because it does not depend on the blood supply of the recipient tissue which may be non dependable in some situation because of associated severe spongiofibrosis and precarious blood supply. (MacDonald & Santucci, 2005)

2. Classification of genital skin

Although there is no conventional classification of the genital skin in the literature, with regards to urethral reconstruction, genital skin can be classified into the hirsute (hair bearing) and the non-hirsute (non-hair bearing). This is necessary because the presence or absence

of hair is taken into consideration in the choice of genital skin to use as the consequences of hair within the urethra could be crippling. All the skin around the external genitalia have been tried in urethral reconstruction at different stages in the evolution of substitution urethroplasty, these include the perineal, scrotal, penile and preputial skin.

2.1 Hirsute skin

Scrotal and perineal skin were used for urethral reconstruction in the past but the outcome was not favourable. (Mundy, 1993, 1995) Despite the close proximity to the urethra, the pedicle is often short and the flap doesn't go farther than the bulbar urethra. The greatest problem with such flaps is the presence of hair with complications such as obstruction to flow of urine, recurrent urinary tract infection and urethral calculi formation. (Crew et al., 1996) This equally applies to the proximal penile skin which is hair bearing and therefore avoided when constructing penile skin flap. This explains the limitation of flap length with longitudinal distal penile skin flap: the longer the flap length, the more the risk of harvesting hair bearing proximal penile skin. Attempt was made at pre-operative depilation using laser or electrocautery but the outcome remains disappointing (Finkelstein & Blatstein, 1991). Since understanding the fact that urethral hair growth is inevitable sequelae of using hair bearing skin for urethral reconstruction, use of scrotal and perineal skin has been abandoned.

2.2 Non-hirsute skin

Non-hirsute genital skin includes the preputial and distal penile skin. These have been used with remarkable successes recorded by all. Currently, non-hirsute genital skin has become a 'formidable weapon' in the hand of seasoned urologists to cure the menace of urethral stricture worldwide. The skin is hairless, adapted to wetness and enough to be closed back without tension after removal of part of it.

3. Advantages of genital skin flap

Advantages of genital skin flap for urethral reconstruction are numerous and it has been found very versatile in all forms of anterior urethral reconstruction. The skin and its superficial fascia have generous blood supply from the external pudendal artery which is a branch of the femoral artery. Therefore, when raised as a flap, the penile skin is able to support itself without dependence on the blood supply of the corpus spongiosum which is the recipient tissue. This explains why this tissue survives when the prevailing conditions in the recipient site is unfavourable, e.g. in the presence of fibrosis and/or wound infection, or when grafts have failed. Furthermore, the underlying superficial fascia containing the blood vessels can be easily raised from the underlying deep fascia as the pedicle of the flap. When properly done, this pedicle can be long enough to reach any part of the urethra, from the prostatic portion to the meatus. Proximity of the genital skin to the urethra makes it possible to carry out the reconstruction as a single procedure by flipping it over to the adjacent urethra to replace the strictured segment. (Elliot & McAninch, 2008)

The preputial / penile skin is relatively thin, pliable and able to withstand prolonged contact with urine than most other tissues. Enough skin can also be raised as flap from this source to substitute the whole anterior urethra. More so, being hairless, the fear of hair ball formation, recurrent infection or urethral calculi from hair growth within the lumen is

excluded (Hinman Jr., 1991). Genital skin flap can be used as an onlay or tubularised to substitute the entire circumference of a urethral segment and the donor site heals perfectly with barely noticeable scar. This is because the incisions are made along pre-existing or natural skin lines like the circumcision line or the median raphe on the ventral surface of the penis. There is therefore neither cosmetic nor psychological problem arising from the post operative scar. (Elliot & McAninch, 2008)

Lastly, the procedure can be done under regional techniques of anaesthesia like spinal or epidural block. This is possible because both the donor and the recipient sites are in the same region of the body and supplied by similar nerve roots. Thus, general anaesthesia and its attendant complications can be avoided.

4. Limitations of genital skin flap

Lichen Sclerosis of the penile skin (Balanitis Xerotica Obliterans) is a chronic progressive disease of the genital skin which may be responsible for urethral stricture disease itself. The aetiology is unknown and there is no satisfactory treatment till date. It causes white patches on the skin which later becomes atrophic and hardened. When this affects the genital skin or if it is the cause of the urethral stricture, it makes the skin unusable for urethral reconstruction. (Barbagli et al., 2004) Where a patient has had previous hypospadias repair complicated by urethral stricture, the penile skin is of poor quality because of the cicatrization from previous surgery. (Imamoglu et al., 2003) Such a skin is not ideal for substitution of the urethra. Rarely, recurrent balanitis/balanoposthitis with scarring or perforation of the preputial skin may make the skin unusable for reconstruction. Preputial skin may be unavailable if the patient has had circumcision prior to presentation. In such situation, distal penile skin can still be used if it is adjudged normal and unlikely to be involved in the primary pathology. (Quartey, 1987)

5. Applied anatomy of penis

Good understanding of the anatomy of penis and its covering is an important prerequisite to successful construction of preputial or distal penile island skin flap for urethral substitution. This is because construction of these flaps is based on the natural relatively bloodless planes of the superficial fascia of the penis. Furthermore, penile skin flaps used in urethral reconstruction are 'axial' (based on definite vessel) and 'island' (completely detached from the skin from which it is raised); they are only attached by the pedicle which contains the vascular supply to the island of skin. (Tung & Nichols, 2008) Thus, understanding of the distribution and location of the vessels are important for successful creation of such flap for reconstruction of the urethra.

5.1 Structure of penis

The penis is composed of three cylindrical erectile tissues: 2 paired corpora carvernosa dorsally and a corpus spongiosum located ventrally in the groove between the corpora carvernosa. These erectile tissues are made up of blood spaces lined by endothelium and each is enclosed by a tough, fibrous-elastic capsule called tunica albuginea. (Figure 1) Corpora carvernosa bodies are fused together in the midline, separated only by an incomplete septum, while corpus spongiosum contains the urethra within it. At the distal end of the penis, corpus spongiosum expands to form the glans which is folded proximally

to cover the distal ends of the corpora cavernosa. Proximally, the corpora cavernosa bodies separate as they approach the perineum to become the crura which are covered by the ischiocavernosus muscles and attached to the medial margins of the ischio-pubic bone. The corpus spongiosum at this region becomes expanded to form the bulb which is surrounded by the bulbospongiosus muscle and together are attached to the inferior surface of the urogenital diaphragm. The urethra within the bulb makes an upward bend through the urogenital diaphragm to become the membranous urethra. Superficial to the tunica albuginea of the erectile bodies is the deep fascia of the penis called “Buck’s Fascia”. It forms a common covering for the corpus spongiosum and the two corpora cavernosa. It is closely adherent to the tunica albuginea which makes it difficult to separate. Beneath this fascia, in the groove between the two corpora cavernosa lie deep dorsal vein, dorsal arteries and the dorsal nerve which supplies the deep structures of the penis. Outside this fascia lie the loose areolar subcutaneous tissue (dartos) and the skin.

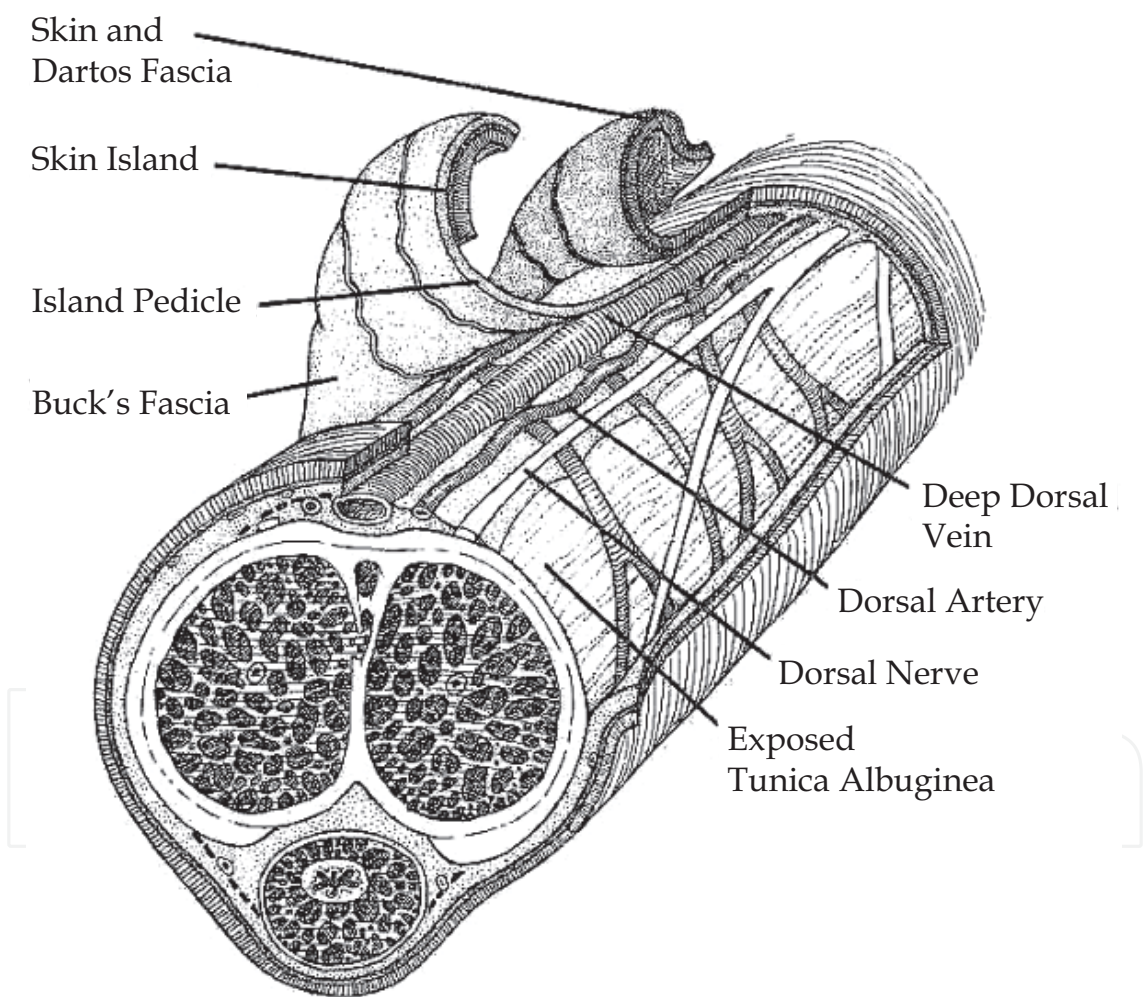


Fig. 1. Structure of penis and its coverings. (From Buckley & Mc Aninch, 2007)

5.2 Coverings of penis (skin and subcutaneous tissue)

The dartos fascia is devoid of fat, slides freely over the underlying Buck’s fascia and continuous with membranous layer of the superficial fascia (Scarpa’s fascia) of the anterior abdominal wall. It can be separated into two layers with the superficial layer closely

apposed to the skin of the penis while the deeper layer contains the superficial vessels, nerves and lymphatics of the penis. (Figure 1) They are termed dartos fascia and tunica dartos respectively. (Buckley & MacAninch 2007) The skin is the outermost covering of penis. It is thin, devoid of fat and loose with non prominent smooth muscle fibre (dartos muscle) in the dermis which allows the skin to accommodate changes in the size of the penis when flaccid or turgid. Below the dermis is a subdermal vascular plexus which is supplied by the superficial branches of external pudendal vessels given off at the root of the penis. During dissection to create the flap, care must be taken to preserve the subdermal plexus so that necrosis of penile skin does not occur. The skin and dartos fascia of the penis are prolonged as a double layer from the coronal sulcus, covering the glans to a variable extent. This is the prepuce of the penis. It is essentially a folding of the penile skin on itself, which is stretched to a single layer during penile erection and by retraction over the penile shaft. The outer surface of the prepuce is normal skin but the inner surface is mucosal membrane; although it resembles skin in appearance, there is a muco-cutaneous boundary just inside the tip of the prepuce. The entire skin system moves freely due a low friction gliding plane immediately beneath the surface of the skin, thus the skin of the penis does not adhere to the underlying tissue the way skin adheres in other parts of the body. This skin can move as a unit back and forth longitudinally or around the shaft circumferentially making it the most mobile skin in male. These qualities make the penile skin redundant and afford easy closure after a portion of it is removed as flap.

5.3 Vascular supply

The deep structures are supplied by internal pudendal artery which runs beneath the buck's fascia while the skin and superficial fascia are supplied by the superficial and deep external pudendal arteries which are branches of the femoral arteries. After branching from femoral artery, these vessels run medially towards the penis in the membranous layer of the superficial fascia. (Figure 2)

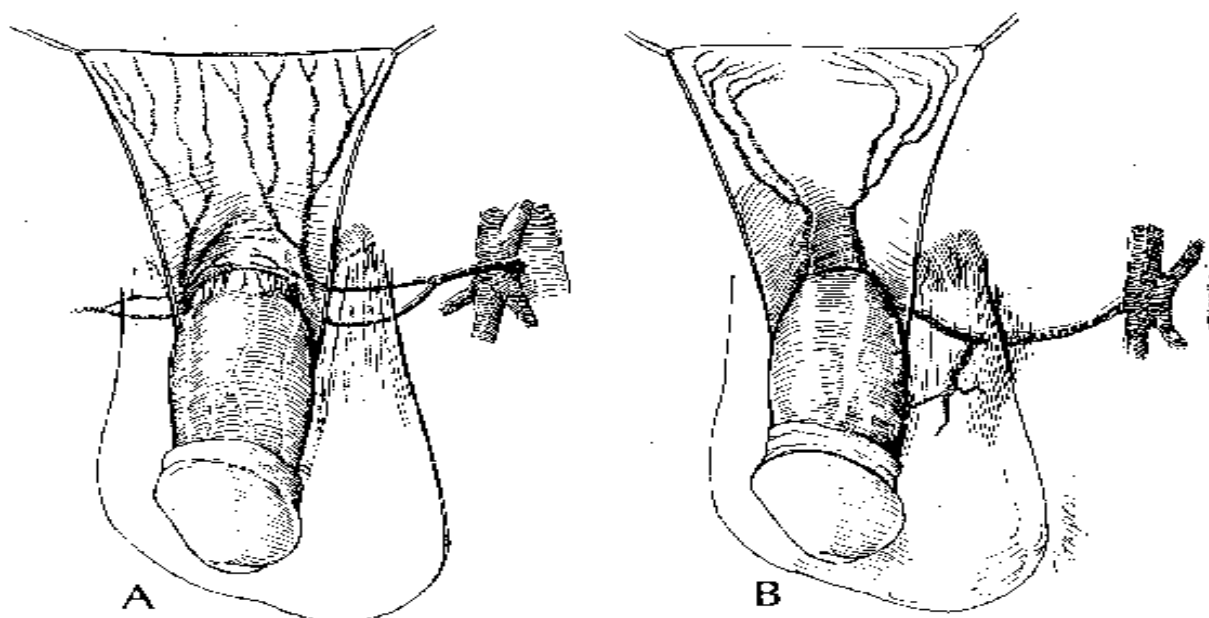


Fig. 2. Arterial supply and venous drainage of penile coverings (From Hinman Jr, 1991)

At the base of the penis, they divide into dorsolateral and ventrolateral axial penile branches which run distally in the tunica dartos of the subcutaneous tissue, dividing into smaller branches which ramify to cover the entire skin and the superficial fascia of the penis. At the base of the penis, they give superficial branches which supply the subdermal plexus of vessels. The prepuce being a double layer of skin has a single terminal arterial system, axially oriented in the subcutaneous tissue such that after retraction, the vessels are seen to end at the coronal sulcus and not at the preputial ring. The venous drainage follows the arterial pattern with venae comitantes accompanying the arteries. At the root of the penis, a small venous trunk emerges from the subdermal plexus to join the venae comitantes which ultimately drains into the femoral vein.

Principle of developing preputial/distal penile skin flap requires two planes of dissection: superficially between the dartos fascia and tunica dartos (sub-epithelial plane) and deeper between the tunica dartos and buck's fascia (sub-dartos plane). These are relatively avascular planes which make it easy to separate the skin with the adherent dartos fascia from the tunica dartos and also to separate the tunica dartos from the underlying buck's fascia. The tunica dartos with its rich vascular supply forms the pedicle which carries the blood supply to the island of penile or preputial skin to be used for reconstruction. (Brandes, 2008)

6. Applications of penile/preputial skin flap in urethroplasty

Penile skin island flaps are versatile, and applicable in all forms of anterior urethral reconstruction irrespective of the location, length and number of stricture. In the hand of an experienced urologist, the long term success rate is encouraging. Though it is technically challenging, knowledge of the anatomy of penis and adherence to basic principles of tissue transfer are fundamental to the successes recorded with these methods. (Brandes, 2008) Penile skin flaps are used in congenital conditions like hypospadias and congenital strictures. They are also used in acquired conditions like urethral stricture diseases especially when options are limited due to the complex nature of the diseases or unfavourable conditions of the recipient site like infection or precarious blood supply due to extensive fibrosis.

The goal of urethral reconstruction for stricture can be summarise by the following three points:

- Removal of obstruction i.e. resolution of the pre-operative symptoms and prevention of possible sequelae.
- Cosmetically acceptable appearance of the penis after the procedure.
- Normal sexual intercourse i.e. absence of chordee and no pain on erection or sexual intercourse.

These are all taken care of by the use of the genital skin flaps because adequate skin can be harvested as flap to maintain adequate urethral length and prevent chordee while skin incisions are created along pre-existing skin lines (median raphe and/or circumcision line) to give cosmetically acceptable scar.

Various techniques abound in the literature but all the techniques using penile skin flaps are based on same principle with differences being only in the orientation of the flap (transversely or longitudinally), or whether raised ventrally or dorsally. (Jordan & Rourke, 2006) These basic principles will be described using 3 techniques: Transverse preputial island flap, transverse distal penile island flap, and longitudinal distal penile island flap.

6.1 Transverse distal penile island flap

6.1.1 Indication

More suitable for long segment stricture (>2cm) of the bulbar urethra, when the prepuce is unavailable or not usable. Although more technically difficult than the longitudinal distal penile island flap, it can also be used for penile urethral stricture. It has also been applied in the repair of posterior urethral stricture. (Quartey, 1987)

6.1.2 Recommended instruments

Ring retractor or Turner-Warwick perineal retractor, van Burren (antegrade) sound, fine serrated scissors, bipolar electrocautery, non crushing forceps.

6.1.3 Pre-operative preparation

Retrograde urethrogram with or without micturating urethrogram is done to know the site and length of the stricture and to guide the surgeon intra-operatively. Urethral ultrasonography may be done to know the extent and depth of involvement of the spongy tissue. A fleet enema can be given on the evening before surgery to avoid bowel motion in the immediate post operative period which could lead to wound infection. The skin of the perineum is shaved preferably on the morning of surgery and the genitalia and perineum washed with soap and copious amount of water to reduce bacterial load. Prophylactic intravenous quinolone and metronidazole is given just before anaesthesia is administered.

6.1.4 Anaesthesia and position

Spinal or epidural block can be used when not contraindicated. This is one of the advantages of using the genital flap over extra-genital graft since the spinal block also anaesthetizes the donor area. In few selected patients, we have done this procedure under saddle block with good intra and post operative outcome.

Where spinal or epidural block is contraindicated or when patient refuses them, a general anaesthesia can also be used. However, in the paediatric age group, general anaesthesia is always used.

6.1.5 Position

Lithotomy position is used in distal bulbar stricture. When the lesion is in the proximal bulbar region, an exaggerated lithotomy is preferred to aid exposure.

6.1.6 Procedure

Following anaesthesia and positioning, the skin is prepped and draped to expose the perineum, external genitalia and suprapubic region (Figure 3). If the patient does not have suprapubic cystostomy prior surgery, one is created before perineal incision. This allows for passage of antegrade sound to delineate the proximal end of the stricture. A size 18FG Foley's catheter is also passed retrogradely through the urethra to delineate the distal end of the stricture. An inverted 'Y' incision is made on the perineum with the vertical part on the median raphe extending from the perineo-scrotal junction to about 2.5cm from the anus. The wings of the 'Y' are carried on either sides of the anus to a point medial to the ischial tuberosity. The incision is deepened in the midline through the colle's fascia to expose bulbospongiosus muscle (Figure 4), which is then incised in the midline to expose the bulbar urethra and the bulb. The bulb is mobilised by separating the muscles laterally and the

corpora cavernosa dorsally. Care should be taken at the proximal end of the bulb where the arteries to the bulb enter laterally. Inadvertent division of these vessels at this stage could result in severe haemorrhage due to the limited operating space, the shortness of the vessels and retraction when divided. Mobilization of the urethra at the region of the stricture may be very difficult because of the surrounding spongiofibrosis, it is thus easier and better to start mobilization from the normal urethral (distally) where the dissection planes are preserved. Care should be taken not to take the distal dissection beyond the suspensory ligament to prevent chordee post operatively. The dissection is continued proximally, mobilising the strictured segment of the urethra completely until normal urethral proximally. Urethrotomy incision is then made through the dorsal or ventral surface into the lumen of the urethra (Figure 5), extending 0.5-1cm into the normal urethra proximally and distally to prevent stricture recurrence. The length and width of the flap to be constructed is then measure before proceeding to its construction. The perineal wound is packed with gauze to reduce haemorrhage from the corpus spongiosum while constructing the skin flap.

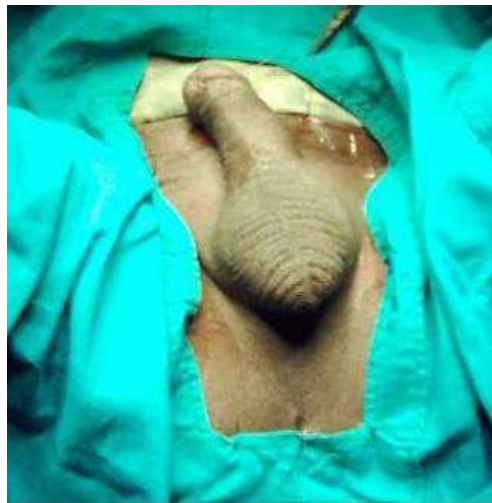


Fig. 3. Skin draped to expose the operation site

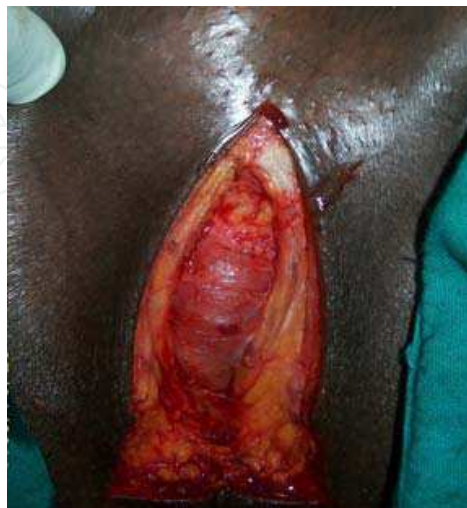

Fig. 4. Inverted “Y” perineal incision deepened through subcutaneous layer to expose the bulbospongiosus muscle

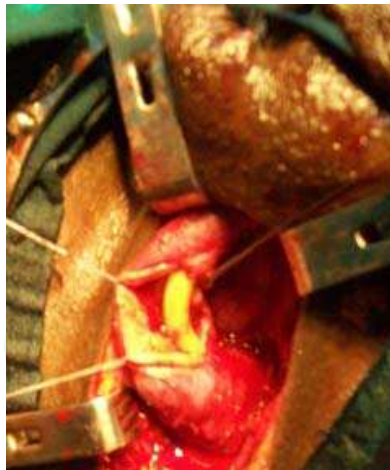

Fig. 5. Incision of the dorsal aspect of the urethra (urethrotomy) exposing the strictured region of the urethra

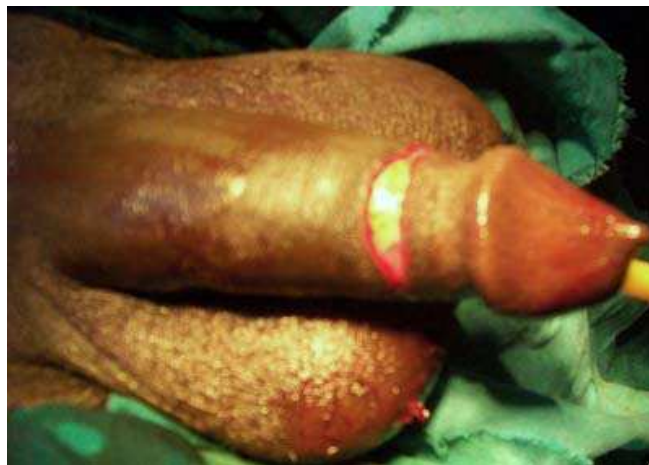

Fig. 6. Circumferential skin incision along the circumcision line, deepened to the avascular plane between the tunica dartos and Buck's fascia

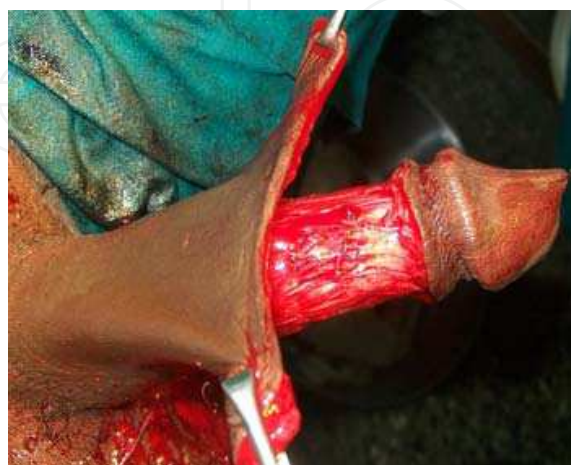

Fig. 7. De-gloved penis with its covering opened like a sheet by longitudinal extension of incision along median raphe

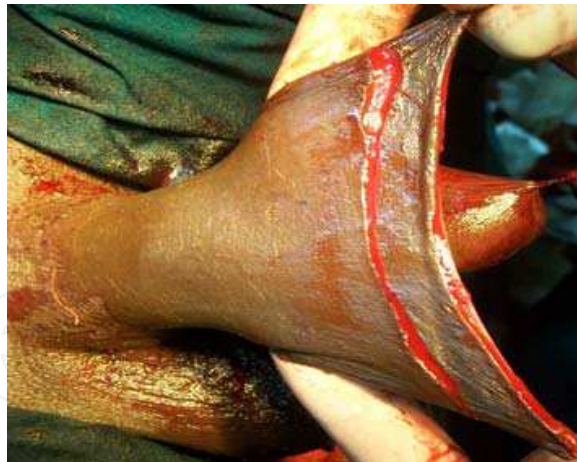

Fig. 8. Second skin incision deepened to the avascular plane between the dartos fascia and the tunica dartos, mapping the island of skin for reconstruction

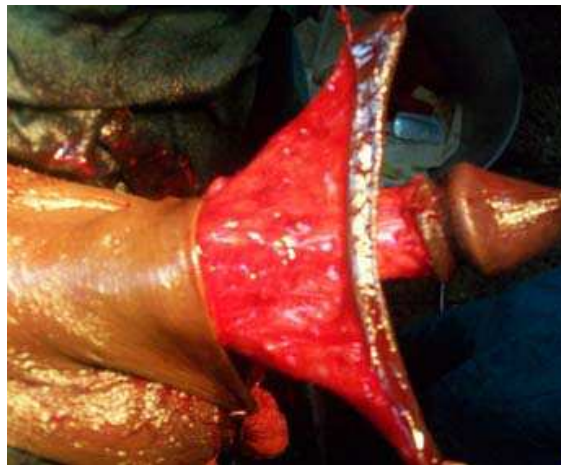


Fig. 9. Island of skin to be used for reconstruction with its pedicle

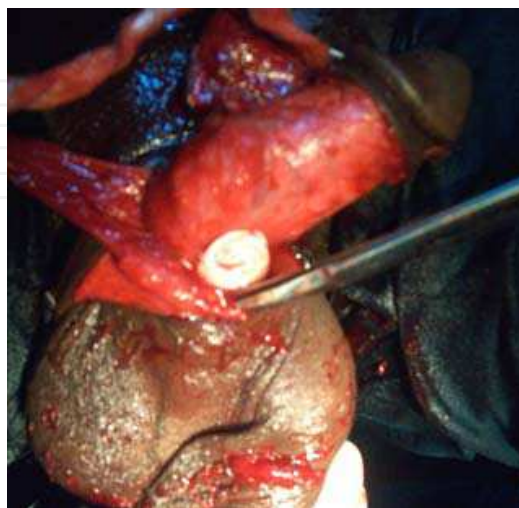


Fig. 10. Creation of retro-scrotal tunnel through which the island and its pedicle is delivered into the perineum

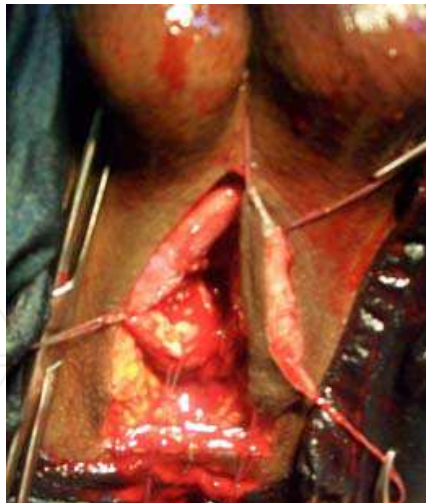

Fig. 11. Skin Island already delivered into the perineum

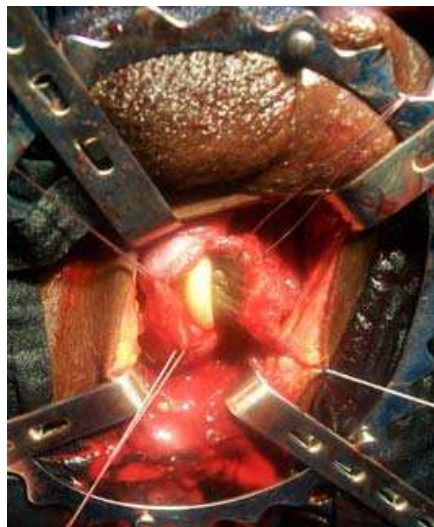


Fig. 12. Anastomosis of the skin island to the urethra with Foley's catheter in the lumen

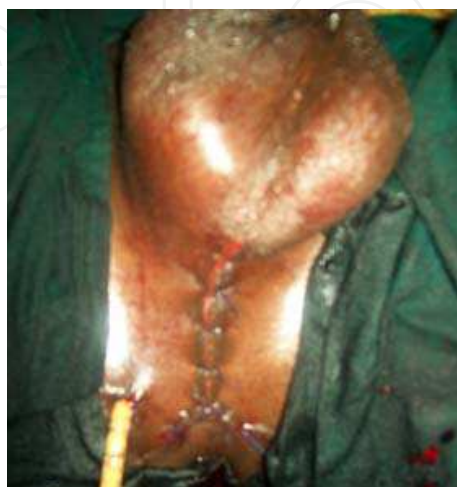

Fig. 13. Perineum on completion of closure with drain in place

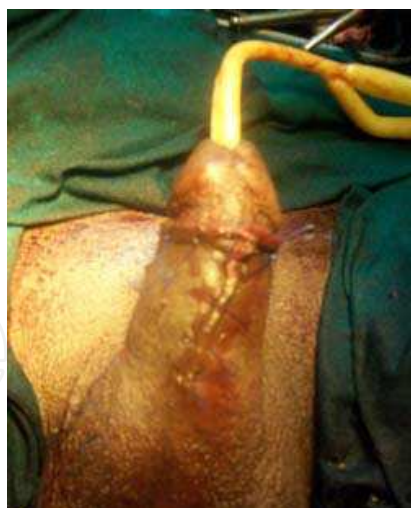

Fig. 14. Penis after closure of the skin

A 2/0 silk suture is used as stay on the glans penis to keep the penis extended while dissection is going on. A circumferential incision is made just proximal to the coronal sulcus on the penile skin and deepened to the buck's fascia (Figure 6). On the midline ventrally (on median raphe), the incision is extended proximally to the penoscrotal junction. A plane is created between the tunica dartos and the buck's fascia through which the penis is degloved by combination of both blunt and sharp dissection to the root of the penis (Figure 7). Starting from the frenular end, another incision that is skin-deep is made proximal to the initial incision to map out the island of skin to be used for the reconstruction. The distance between the two incisions should equal the width of the urethral gap to be bridged (Figure 8). The second incision is deepened just to the plane between the dartos fascia and the tunica dartos, where the penile skin and the firmly adherent dartos fascia is carefully dissected off the tunica dartos which contains the vascular supply to the island skin flap. Care must be taken to preserve the subdermal plexus and avoid necrosis of the penile skin (Figure 9). A tunnel is created deep to the scrotum by insinuating the index finger from the perineal wound below, towards the penile wound while dissecting with scissors from above to meet the insinuating finger (Figure 10). Through this retroscrotal tunnel, the island flap is delivered into the perineum (Figure 11). Care is taken to avoid twisting of the pedicle at this stage so that the vascular supply of the flap is not compromised. Excess skin can be trimmed off to prevent redundant skin which could lead to diverticulum as the flap is sutured as onlay to the native urethra to bridge the gap using a 5-0 polyglycolic or polyglactin interrupted suture (Figure 12). Care should also be taken to ensure that the knots of the suture are outside the lumen. After completion of one side of the anastomosis, a size 16FG or 18FG Foley's catheter is passed through the urethra into the bladder to serve as stent for the repair. A wound drain is sometimes placed underneath the bulbospongiosus muscle if there is extensive dissection around the scrotum or if there is significant oozing of blood from the dissected spongiofibrosis. The drain is brought out through a stab wound on the skin of the perineum, aimed at preventing hematoma collection when this is anticipated (Figure 13). The incision is closed in layers and firm sterile pressure dressing is applied sparing the anus. Suprapubic catheter is placed in the cystostomy site for diversion of urine and penile skin closure is done with interrupted 3-0 nylon suture (Figure 14). An occlusive dressing is also applied to the penis.

Where there is a long segment stricture with completely occluded lumen precluding onlay repair, the urethral segment can be excised and the flap tubularised around a catheter which is then sutured to the proximal and distal urethral to bridge the gap. However, the success rate for tubularisation of the flap is lower when compared with onlay repair. (Carney & McAninch, 2002) Thus, onlay repair is favoured by most urologists when intraoperative findings allow it.

6.1.7 Post operative management

Intravenous antibiotics and analgesics are continued for 24-48 hours and changed to oral thereafter. Perineal wound drain, if placed, is removed on the second or third post operative day and the penile occlusive dressing is changed on the fourth or fifth day after inspection of both wounds.

Perineal and penile stitches are removed between the eighth and tenth day. Pericatheter urethrogram is done 14-21 days after surgery, following which the catheter is removed if there is no extravasation of contrast. Uroflowmetry is done at varied interval to assess the urine flow rate.

6.1.8 Complications

Common early post operative complications are wound infection, urosepsis, urethrocuteaneous fistula, scrotal haematoma, penile skin necrosis, epididymo-orchitis and flap necrosis. Late complications include urethral diverticulum and restenosis of the urethra.

6.2 Transverse preputial island flap

The inner surface (mucosa) of the preputial skin is preferred for reasons explained earlier. Where the prepuce is intact, this technique should be chosen, but where the patient is circumcised, distal penile skin is considered.

6.2.1 Indication

Use of preputial island flap was initially described and has been widely used in the repair of all forms of hypospadias with or without chordee. Its use is however not limited to hypospadias as it has been applied to reconstruction of the urethra for various forms of stricture disease. In uncircumcised adult, it has been widely used in reconstruction of urethra stricture located any part of the urethra, even membranous urethra. Application of this method for hypospadias is not described in this chapter.

6.2.2 Recommended instruments

Ring retractor or Turner-Warwick perineal retractor, van-Burren (antegrade) sound, fine serrated scissors, bipolar electrocautery, non crushing forceps.

6.2.3 Pre-operative preparation

Delineation of stricture length and location by retrograde urethrogram with or without micturating urethrogram is essential. Urethral ultrasound may also be used to characterise the strictured segment and the surrounding tissue. On the morning of surgery, perineum and external genitalia is shaved and washed thoroughly with soap and copious amount of water, prepuce is retracted and the inner skin is similarly washed to reduce bacterial load. A

fleet enema is given on the evening before surgery to avoid bowel motion in the immediate post operative period. Prophylactic intravenous quinolone and metronidazole is given just before anaesthesia.

6.2.4 Anaesthesia

Just like for transverse distal penile island flap, spinal or epidural block can be used. Where these regional block methods cannot be used because it is contraindicated or because the patient prefers not to be conscious during the surgery, general anaesthesia can also be used. In contrary, when this procedure is done in paediatric age group for hypospadias or any other urethral pathology, general anaesthesia is always used.

6.2.5 Position

Lithotomy or exaggerated lithotomy as explained under the transverse distal penile island flap repair.

6.2.6 Proceedure

The steps in exposure of the diseased bulbar urethra are as described for transverse distal penile island flap urethroplasty. The main technical difference in the two procedure is the need to retract the prepuce over the penile shaft before raising the flap from the inner preputial skin.

A 2/0 silk penile suture is placed at the dorsum of the glans to allow for traction on the penis while dissection is ongoing. The prepuce is retracted back and pulled on the penile shaft so that the two layers of skin becomes single and continuous around the penile shaft. A circumferential incision is made 0.5-1.0 cm proximal to the corona, this is deepened to subdartos plane just as explained for the distal penile island flap. The penis is degloved at this avascular plane up to the root of the penis; the incision is then extended down vertically on the midline (median raphe) on the ventral surface of the penis such that the penile/preputial skin can be opened out as a flat sheet of skin rather than a circumferential one. A transverse island flap from the inner layer of the prepuce is outlined with another proximal skin incision, deepened to the plane between the fascia dartos and tunica dartos. The dimensions of this island of skin is also measured based on the size needed to cover the defect in the urethral without redundancy. The skin and the fascia Dartos are carefully dissected off the underlying tunica dartos which is the pedicle containing the vascular supply to the flap. The flap with its axial vascular pedicle is dissected proximally up to the root of penis to allow ventral transposition of the island flap with no tension. A retroscrotal tunnel is created and the island flap is delivered into the perineal wound for anastomosis to bridge the urethral gap.

6.2.7 Post operative management

This is essentially as described for the transverse distal penile island flap method.

6.2.8 Complications

Complications of this technique are similar to those described for transverse distal penile island flap. However; flap necrosis is theoretically more likely than distal penile island flap because of longer length of pedicle and smaller size of vessels supplying the preputial skin.

6.3 Longitudinal distal penile island flap

6.3.1 Indications

Whenever stricture involves the penile urethra, anastomotic urethroplasty is not favoured because it can cause unacceptable penile deformity on erection, thereby putting sexual function at risk. Substitution urethroplasty is therefore the mainstay of reconstruction in penile urethral stricture. Longitudinal distal penile island flap is technically easier and faster than the transverse distal penile island flap in the repair of penile urethral stricture.

6.3.2 Recommended instruments

Fine serrated scissors, non-crushing forceps, bipolar electrocautery.

6.3.3 Pre-operative preparation

The strictured segment is characterised using ultrasonography and urethrography. The non hirsute region of the penile skin can be marked before shaving or else the penile skin is not shaved to allow the surgeon to mark a flap without incorporating hair. Penile skin can be washed with soap on the morning of surgery to reduce the load of microorganism. Peri-operative quinolone and metronidazole are given just before anaesthesia.

6.3.4 Anaesthesia

Spinal or epidural block is preferred though general anaesthesia can also be used.

6.3.5 Position

Supine position is preferred for penile urethral reconstruction.

6.3.6 Procedure

Following spinal or epidural block and positioning, the skin is prepped and draped to expose the penis and suprapubic region. A 2-0 silk suture is applied to the glans for traction and a size 18 FG Foley's catheter passed through the meatus to mark the distal end of the stricture. A curvilinear skin incision is made on one side of the midline on the ventral surface of the penis, deepened through the dartos layer and buck's fascia onto the tunica albuginea of the corpus cavernosum. The edge of the skin is elevated and dissected across the midline to the other corpus cavernosum to expose the strictured segment of the urethra. Longitudinal urethrotomy incision is then made on the urethra to expose the lumen of the strictured segment. This is done on the lateral surface of the urethra opposite to side of the skin incision and extending about 1 cm into the normal urethra proximally and distally. The size 18 FG Foley's catheter is advanced proximally in the urethra to assess the remaining part of the urethra for stricture (Figure 15). The length and width of the flap needed to complete the circumference of the urethra is measured once the diseased segment is laid open. The partially raised flap is marked based on the dimension of the strictured segment and another incision made through the skin, deepened to the plane between the Darto's fascia and tunica Dartos, outlining the island flap to be constructed for the repair. Blunt and sharp dissections are carried out on this plane to isolate the marked skin on the vascular pedicle made of tunica Dartos (Figure 16). Care must be taken at this level to ensure dissection is done at the proper plane to preserve the subdermal plexus and prevent necrosis of the penile skin being raised form the tunica dartos. The skin flap is rotated into the urethral defect and a watertight anastomosis is done with interrupted 5-0 polyglycolic or polyglactin suture, ensuring that

knots are extra-luminal. Size i6 or 18 FG Foley's catheter is left in place to serve as a stent (Figure 17). This small size catheter is actually preferred to allow drainage of secretions or blood around the catheter and to prevent pressure necrosis of urethral mucosa due to large catheter which could result in another stricture at a later date.

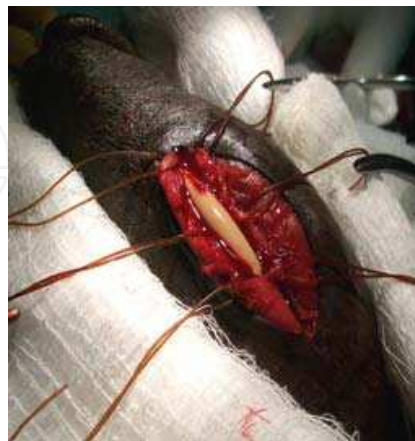

Fig. 15. Urethrotomy incision into the strictured segment of the urethra

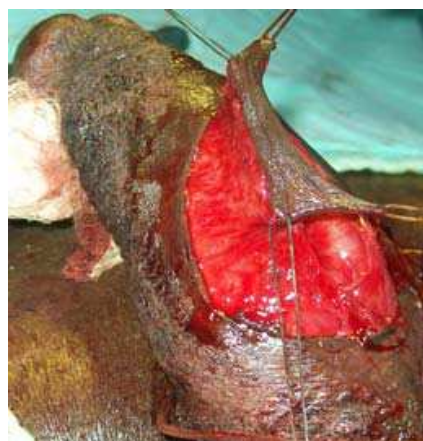

Fig. 16. Longitudinal island flap constructed on its pedicle

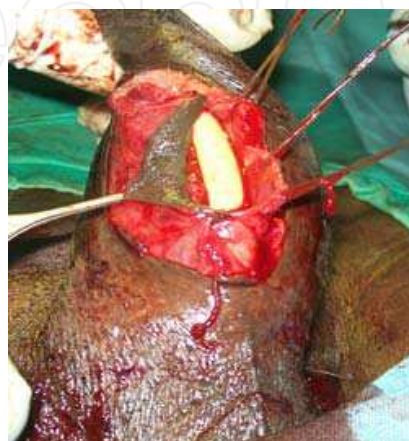


Fig. 17. Anastomosis of the island flap to the native urethra

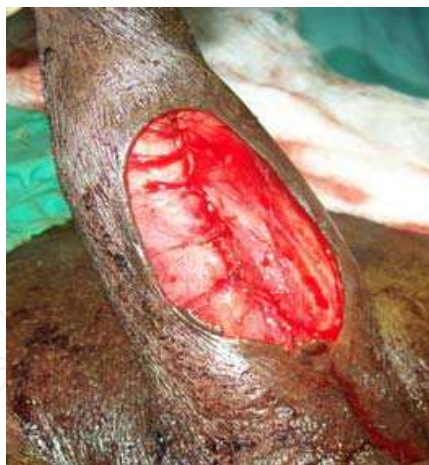

Fig. 18. Completed of anastomosis

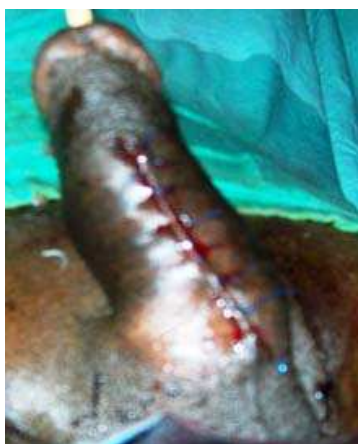

Fig. 19. Final appearance of penis on completion of repair

A layer of subcutaneous (dartos) fascia can be closed over the anastomosis before penile skin closure with interrupted 3-0 nylon suture. Patients with pre-operative suprapubic cystostomy are maintained on diversion by inserting Foley's catheter into the suprapubic opening while those without suprapubic cystostomy are left un-diverted. An occlusive dressing is applied with the penis retracted dorsally and anchored to the anterior abdominal wall to reduce oedema.

6.3.7 Post operative management

Intravenous antibiotics and analgesics are continued for 24-48 hours and changed to oral drugs thereafter. Wound is inspected on the third or fourth post operative day and dressing is changed. Stitches are removed after 7-10 days and peri-catheter urethrogram is done 14-21 days after surgery, following which the catheter is removed if there is no extravasation. Uroflowmetry can be after 3 months to evaluate the urine flow.

6.3.8 Complications

Urethrocutaneous fistula can result but usually resolves within few days. Wound infection and penile skin necrosis are not common if the surgeon adheres to basic rules of raising flaps. Recurrence is rarely seen if the strictured segment was properly laid open during

surgery. Hair in the urethra could occur if a long flap extending to the hirsute proximal penile skin is used to construct the flap for a long segment stricture.

7. Experience with genital skin flap

We have used genital skin flap for urethral reconstruction in our unit and have found it very useful in complex cases of urethral stricture. Between 2002 and 2008, we treated about 55 cases with success rate of 81.2% (Olajide et al, 2010). Commonest early post operative complication was wound infection which was not surprising because a large proportion of the patient had significant bacteriuria pre-operatively. Commonest delayed complication was urethral diverticulum which made us to trim our flap more thereafter and to use dorsal urethrotomy and dorsal onlay anastomosis which is associated with lesser occurrence of diverticulum. Recurrence was found in only one patient (1.8%) 2 years post operation.

Preputial island flap in our unit is practiced mainly for hypospadias because circumcision is practiced routinely in Nigeria for religious and cultural reasons. Virtually all our patients are circumcised; this fact negates the use of prepuce for urethral reconstruction in adult in our unit. We reported use of this flap for hypospadias 2009, (Sowande et al, 2009) but this experience cannot be extrapolated to the adult because they are treating different clinical conditions.

Longitudinal penile island flap is routinely used in our unit to treat all strictures located in the penile urethra. Though yet unpublished, we treated 23 cases over a 4 year period and found penile skin necrosis in 2 patients which healed on wound dressing. All the patients had satisfactory outcome.

8. Future trend

Introduction of vascularised flap techniques and use of grafts has broadened the field of urethral reconstruction. Several modifications of the original techniques have evolved and more are still on the way. With improvement in immune modulation and techniques of tissue transfer, substitution with both allogeneic, xenogeneic and synthetic tissues may add more to the array of option available for the reconstructive surgeons. Urethral tissue has been harvested from human cadaveric donor, converted to matrix graft enzymatically and use as graft for urethral reconstruction with no immunosuppression, no complication and satisfactory outcome. (Ribero-Filho et al, 2006) However, bioengineering and tissue culture are marking the future of urethral reconstruction because optimal tissues for urethral replacement will be produced by this technology. (Carson, 2006; MacAninch, 2005). Introduction of these tissues into clinical practice may actually be the beginning of a new era in urethral reconstruction.


9. Conclusion

Given the wide arrays of procedures available to urologist to reconstruct a strictured urethra, urologists should try to acquaint themselves with all the methods as a single technique cannot suffice for all stricture cases. More so, there are reasons why one technique can be chosen over another in each particular case. Where there are multiple options, I feel the experience of attending urologists should guide them in the choice of technique to treat each case.

10. References

- Barbagli G, Palminteri E, Balo S, Vallasciani S, Mearini E, Constantini E, Mearini L, Zucchi A, Vivacqua C, & Porena M. (2004). Lichen sclerosis of the male genitalia and urethral stricture disease. *Urol Int*, 73, 1-5.
- Brandes SB. (2008). Vascular anatomy of the genital skin and the urethra: Implications for urethral reconstruction. In: *Current Clinical Urology: Urethral Reconstructive Surgery*, SB Brandes, (Ed.) 153-164, Humana Press, ISBN-978-1-588-29826-3, Totowa, NJ.
- Buckley J & MacAninch J. (2007). Distal penile circular fascio-cutaneous flap for complex anterior urethral strictures. *BJU*, 100, 221-231.
- Carney KJ & McAninch JW (2002) Penile circular fasciocutaneous flaps to reconstruct complex anterior urethral strictures. *Urol Clin N Am* 29:97-409.
- Carson CC. (2006). Urethroplasty: a model for international progress in urology. *Contemp Urol.*, 18, 11.
- Crew JP, Nargund V & Fellows GJ. (1996). Symptomatic urethral ball and Diverticulum complicating island flap urethroplasty. *Scand J Urol Nephro*, 30, 231-233.
- Elliot SP & McAninch JW. (2008). Penile skin flap for urethral reconstruction, In: *Current Clinical Urology: Urethral Reconstructive Surgery*, SB Brandes, (Ed.) 153-164, Humana Press, ISBN-978-1-588-29826-3, Totowa, NJ.
- Finkelstein LH & Blatstein LM. (1991). Epilation of hair bearing urethral grafts using the neodymium:YAG surgical laser. *J Urol*, 146, 840-842.
- Hinman Jr. F. The blood supply to preputial island flaps. (1991). *J Urol*, 145, 1232-1235.
- Imamoglu MA, Kiper A, Tuygun C & Gucuk A. (2003). Results of TIPU on patients with primary and recurrent hypospadias. *J.Ankara Med.Sch.*, 25(4), 179-84.
- Jordan GH & Rourke KF. (2005) The use of flaps in urethral reconstructive surgery. In: *Reconstructive Urethral Surgery*. Schreiter F & Jordan GH, (Eds.) 130-136, Springer, ISBN- 978-3-540-41226-7,
- Kellner DS, Fracchia JA & Armenakas NA. (2004). Ventral onlay buccal mucosal grafts for anterior urethral strictures: long-term followup. *J Urol* 171: 726-729, 2004.
- MacDonald MF & Santucci RA. (2005). Review and treatment algorithm of open surgical techniques for management of urethral strictures. *Urology*, 65, 9-15.
- McAninch JW: (2005). Urethral reconstruction: a continuing challenge. *J Urol.*, 73, 7.
- Mundy AR. Results and complications of urethroplasty and its future. (1993). *BJU*, 71, 322-325.
- Mundy AR. (1995). The long term results of skin inlay urethroplasty. *BJU*, 75, 59-61.
- Olajide AO, Salako AA, Aremu AA, Amogu KE, Olajide FO & Banjo OO. (2010). Complications of transverse distal penile island flap urethroplasty of complex anterior urethral stricture. *Urology Journal*, 7, 78-182.
- Quartey JKM. (1987) One stage penile/preputial island flap urethroplasty for difficult posterior urethral stricture. *World J Urol*, 5, 37-40.
- Ribeiro-Filho LA, Mitre AI, Sarkis AS, Guimaraes PE, Arap MA, Silva IA, et al. (2006). Human organ-specific acellular matrix grafting for severe urethral stenosis. *J Urol.*, 175: 161.
- Rosen MA, Nash PA, Bruce J E, & McAninch J W. (1994). The actuarial success rate of surgical treatment of urethral strictures. *J Urol.*, 151, 360A, 529.

- Sowande OA, Olajide AO, Salako AA, Olajide FO, Adejuyigbe O. Talabi AO. (2009). Experience with transverse preputial island flap for repair of hypospadias in Ile-Ife, Nigeria. *African Journal of Paediatric Surgery*, 6 (1), 40-43.
- Santucci RA, Mario LA & McAninch JW. (2002). Anastomotic urethroplasty for bulbar urethral stricture: analysis of 168 patients. *J Urol* 167, 1715-1719.
- Tung TA & Christopher MN. (2008). Techniques in tissue transfer: plastic surgery for the Urologist. In: *Current Clinical Urology: Urethral Reconstructive Surgery*, SB Brandes, (Ed.) 153-164, Humana Press, ISBN-978-1-588-29826-3, Totowa, NJ.



Current Concepts of Urethroplasty

Edited by Dr Ivo Donkov

ISBN 978-953-307-392-7

Hard cover, 152 pages

Publisher InTech

Published online 19, July, 2011

Published in print edition July, 2011

Urethral reconstructive surgery has always been a challenging part for urologist since the dawn of our specialty. In this book leading experts in lower urinary reconstructions from all over the world present their views and experience in that field, together with practical tips and tricks. The book is an excellent source of information for those who are already dealing with urethral surgery, and also an invaluable companion for urologists in training or those who want to dedicate themselves to this great sub-specialty. This book is an excellent reference guide and companion on the way to operating and consulting room, or when writing an article and reviewing the current practices. The abundance of methods and continuing development of new approaches to the problem prove the complexity of it.

How to reference

In order to correctly reference this scholarly work, feel free to copy and paste the following:

Abimbola O. Olajide (2011). Genital Skin Flap Urethroplasty, Current Concepts of Urethroplasty, Dr Ivo Donkov (Ed.), ISBN: 978-953-307-392-7, InTech, Available from: <http://www.intechopen.com/books/current-concepts-of-urethroplasty/genital-skin-flap-urethroplasty>

INTECH
open science | open minds

InTech Europe

University Campus STeP Ri
Slavka Krautzeka 83/A
51000 Rijeka, Croatia
Phone: +385 (51) 770 447
Fax: +385 (51) 686 166
www.intechopen.com

InTech China

Unit 405, Office Block, Hotel Equatorial Shanghai
No.65, Yan An Road (West), Shanghai, 200040, China
中国上海市延安西路65号上海国际贵都大饭店办公楼405单元
Phone: +86-21-62489820
Fax: +86-21-62489821

© 2011 The Author(s). Licensee IntechOpen. This is an open access article distributed under the terms of the [Creative Commons Attribution 3.0 License](https://creativecommons.org/licenses/by/3.0/), which permits unrestricted use, distribution, and reproduction in any medium, provided the original work is properly cited.

IntechOpen

IntechOpen