

We are IntechOpen, the world's leading publisher of Open Access books Built by scientists, for scientists

6,900

Open access books available

185,000

International authors and editors

200M

Downloads

Our authors are among the

154

Countries delivered to

TOP 1%

most cited scientists

12.2%

Contributors from top 500 universities



WEB OF SCIENCE™

Selection of our books indexed in the Book Citation Index
in Web of Science™ Core Collection (BKCI)

Interested in publishing with us?
Contact book.department@intechopen.com

Numbers displayed above are based on latest data collected.
For more information visit www.intechopen.com



The Treatment of Panurethral Strictures

Yue-Min Xu and Chao Feng

*Department of Urology, Sixth People's Hospital, Urethral Reconstruction Center,
Jiaotong University of Shanghai, Shanghai 200233,
China*

1. Introduction

Extensive or panurethral strictures that involve both the pendulous and bulbar urethra were difficult to treat surgically. Successful repair of panurethral strictures was challenging, particularly in patients with recurrent panurethral strictures after previous surgical attempts. Such therapeutic efforts were well-known risk factors for the failure of urethroplasty, because of spongiofibrosis and poor vascular supply. Such strictures were traditionally managed with 2-stage repairs using scrotal skin (1, 2). However, as the field of urethral reconstruction developed, there was a move towards 1-stage repair using free grafts made of skin, pedicle-based flaps or combined approaches (3-9). Numerous substitution urethroplasty techniques have been described and there were, however, no universally accepted graft material for either primary urethral substitution or technique of reconstruction after multiple failed attempts. (3-9).

The penile skin flap provided a versatile mechanism for achieving excellent results in the single-stage repair of complex anterior urethral strictures. The distal penile circular fasciocutaneous flap (FCF) technique of urethroplasty was first reported in 1993 by McAninch (10). The flap meets all criteria for tissue transfer and urethral reconstruction. It reliably provides ample hairless tissue, usually 13 to 15 cm long (depending on penile size), flexibility, versatility, and without compromising cosmesis or function (11). In addition, the circular fasciocutaneous penile flap is easily combined with other tissue-transfer techniques when necessary, enabling one-stage reconstruction in the majority of cases.

For those patients in whom genital skin was insufficient or panurethral strictures involving more than the distal bulbar urethra, alternative tissue or combined grafts urethroplasty was needed for urethral reconstruction. Wessells et al (3) reported a series of seven patients with pan-urethral strictures (mean length, 19 cm.) treated using a fasciocutaneous flap combined with buccal mucosa, bladder epithelium or skin grafts. Elliott et al (4) described nine patients who underwent distal penile fasciocutaneous flap repair of a concomitant penile urethral stricture and buccal graft reconstruction for a bulbar stricture; the repair was successful in eight of the nine patients. Berglund et al (5) reported a series of 18 patients with a mean stricture length of 15.1 cm using combined buccal mucosal graft and genital skin flap for reconstruction of extensive anterior urethral strictures.

For those patients in whom no adequate donor skin was available for grafting because of multiple penile surgeries or diseased skin existing, mucosal grafts urethroplasty may be appropriate (7,8). Several experimental studies and clinical experiences have contributed to

the development and evolution of substitute urethroplasty in surgical treatment of penile and bulbar urethral strictures. In 2002 and 2003, we described the results of a pilot study on the use of the colonic mucosa as a novel substitute for urethral reconstruction in 10 dogs before performing the operation in 16 patients with severe lengthy urethral stricture (7,12,13). In 2009, we reported a series of 35 patients with a mean stricture length of 15.1 cm and mean followup 53.6 months (range 26 to 94) using colonic mucosal graft for reconstruction of extensive urethral strictures (14).

This chapter will focus on combined the penile skin flap and mucosal graft urethroplasty, combined two oral mucosal grafts urethroplasty, or colonic mucosa graft urethroplasty for urethral reconstruction. We will also review the technical aspects of staged urethroplasty.

2. Preoperative evaluation

The patient's clinical history, as well as the stricture etiology, location, and length must be carefully examined to better define the characteristics needed in substitution urethroplasty. Preoperative retrograde urethrography was mandatory to evaluate the site, number, length of stricture and the urethral plate, and voiding cystourethrography was useful in evaluating continence of the bladder neck and urethral dilation proximally to the stenosis (Fig. 1a-d). Sonourethrography and urethroscopy were suggested to collect more detailed information on stricture characteristics, especial for posterior urethra (Fig. 2a,b).

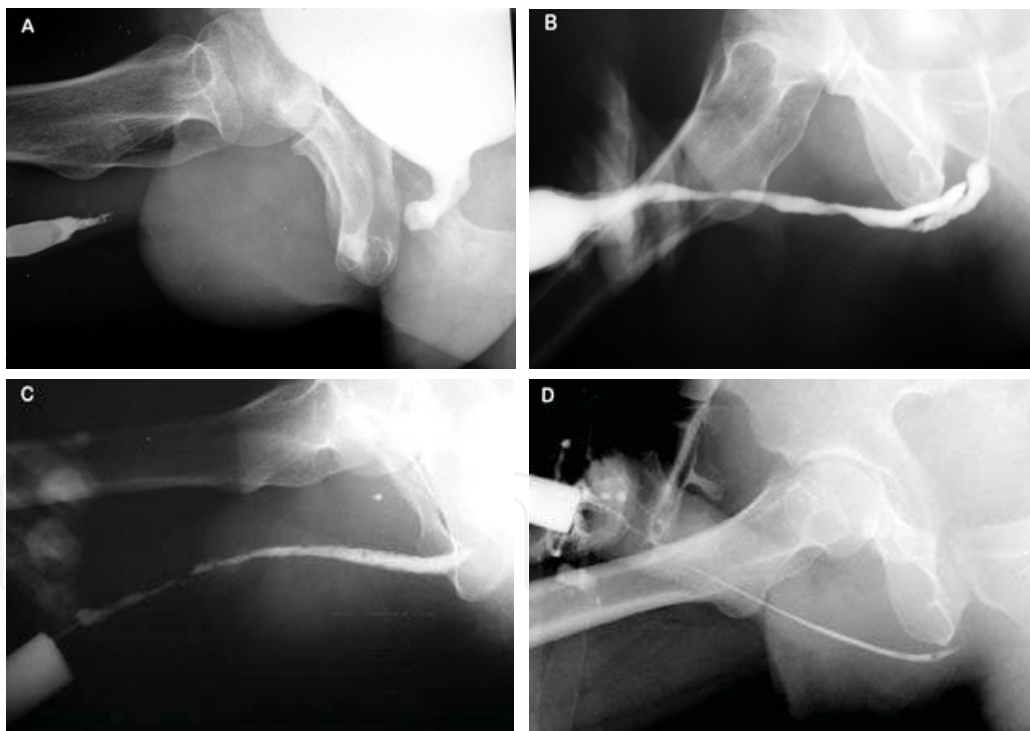

Fig. 1. Retrograde urethrography demonstrated a long segment urethral occlusion (A), multiple strictures and pseudopath (B) or long, severe stricture (C,D) in anterior urethra

Patients selected for one-stage procedure should be informed that early or later complications, such as hematoma, infection, meatal stenosis or fistula may occur with any surgical technique. The patient requiring a penile flap one-stage urethroplasty must be carefully reviewed and the genitalia meticulously inspected taking into consideration glan's shape,

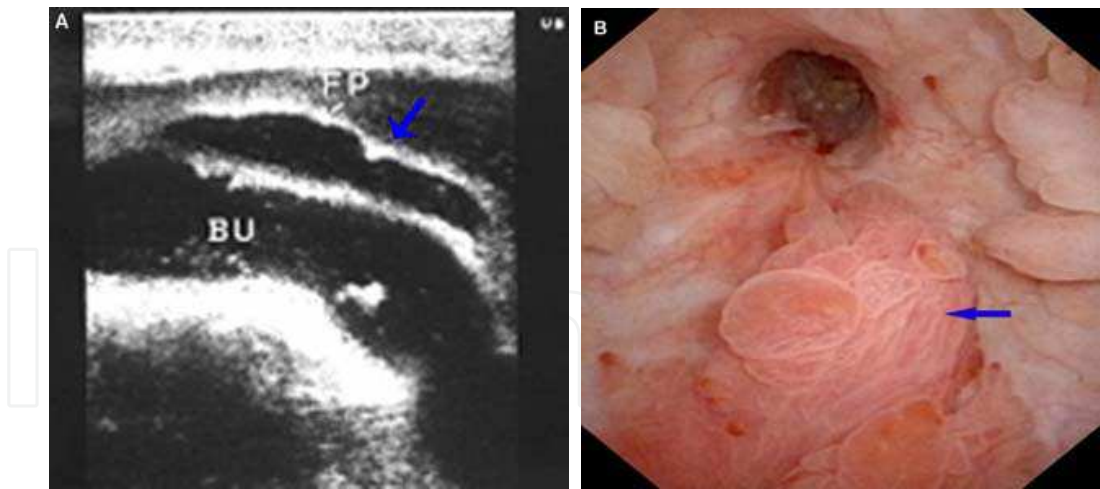


Fig. 2. (A) sonourethrogram demonstrated a pseudopath in bulbar urethra; (B) urethroscopy suggested a rigid bladder neck and neoplasm

scars in the penile and scrotal skin, the presence of residual foreskin, hair in the meatus or stones in the urethra. In addition, the presence of Lichen Sclerosus disease must be excluded (Fig. 3a-c).

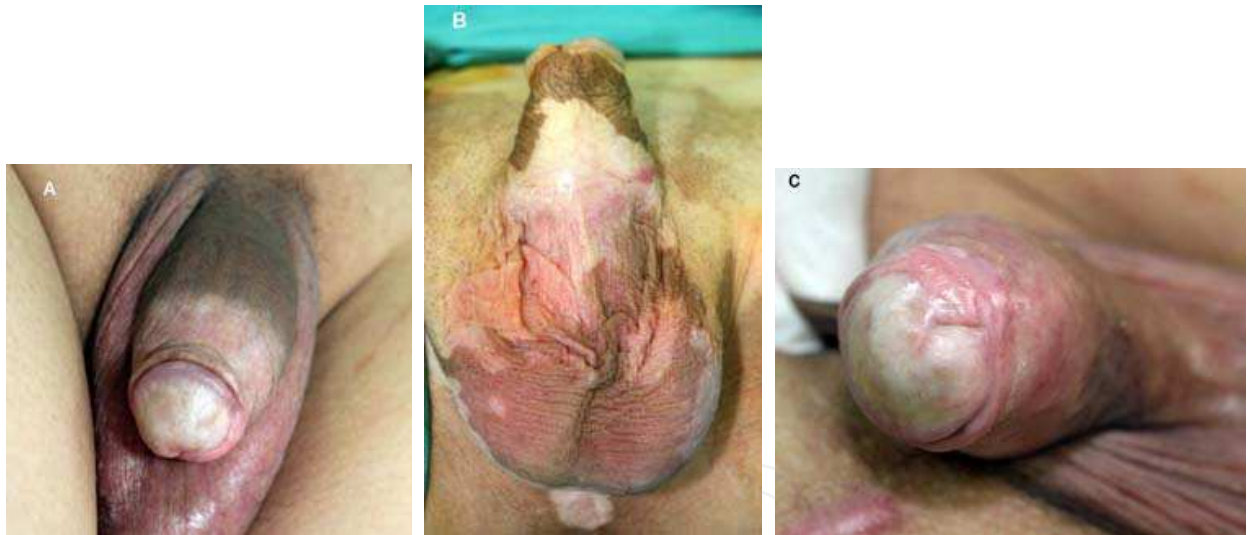


Fig. 3. LS affecting the entire glans (A), penile and scrotum skin (B), severe meatal stenosis (C)

The patient requiring an oral mucosa graft one-stage urethroplasty should be informed that oral cleansing. Two days before surgery, the patient should begin using 0.5% metronidazole mouthwash and continue three days following surgery. A broad-spectrum antibiotic is administered intravenously during the procedure and for three days afterward.

Patients who currently had an infectious disease of the mouth (such as Candida, Varicellavirus, or Herpes virus) or who have had previous surgery in the mandibular arch that prevented the mouth from being opened wide, colonic mucosa would be used for the urethroplasty.

The patient requiring a colonic mucosa graft one-stage urethroplasty should be informed that intestinal antisepsis. Three days before surgery, the patient should begin the intestinal preparation for operation, using orally nonabsorbable antibiotics administered.

3. Surgical techniques

The patient was placed in a normal lithotomy position and all surgeries were performed under general anesthesia.

3.1 Managing stenotic or obliterated urethra

A midline perineal incision and a circumcoronal foreskin or longitudinal penile incisions were required. The penile urethra and bulbar urethra were dissected from the corpora cavernosa only along the left. On the right side, the urethra remains attached to the corpora cavernosa for its full length, thus preserving its lateral vascular blood supply (Fig. 4a). The distal extent of the urethral stenosis was identified by gently inserting a 16-Fr catheter with a soft round tip until it meets resistance. The dorsal urethral surface was incised in the midline until the catheter tip and urethral lumen were exposed. The stricture tract was then incised along its entire length by a dorsal midline incision and for about 1 cm both proximally and distally into the healthy urethra (Fig. 4b). Once the entire stricture had been incised, the length and width of the remaining urethral plate was measured. Proximal and distal calibration of the urethra with a specially modified nasal speculum was critical for identifying any residual narrowing.

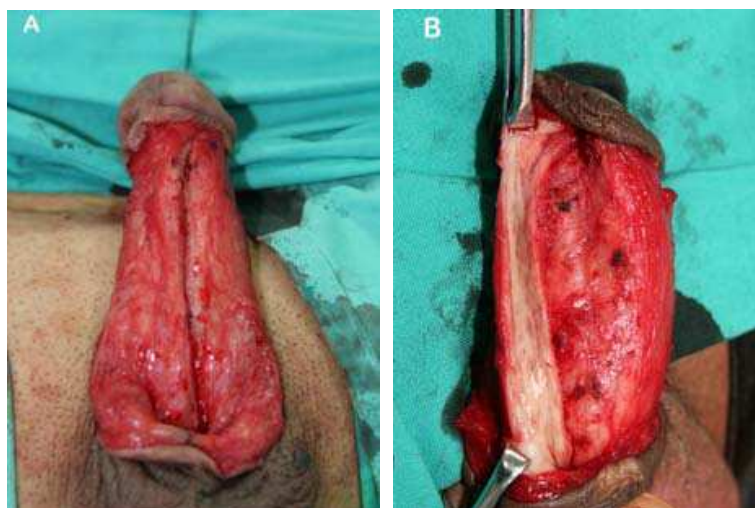


Fig. 4. (A) the penile urethra and bulbar urethra were dissected from the conpora cavernosa only along the left and remains attached to the corpora cavernosa on the right side. (B) the stricture tract was then incised along its entire length by a dorsal midline incision

For a stricture in which the lumen was more or less completely obliterated and one in which the lumen was significantly narrowed but not actually lost. For this diseased segment, we usually prefer to excise it and to replace it with mucosal grafts (Fig. 5a,b).

3.2 Oral grafts urethroplasty

Oral mucosal graft included two mucosal grafts (buccal and lingual mucosa). Since 1993 El-Kasaby et al reported the first experience with buccal mucosa urethroplasty for treatment of penile and bulbar urethral strictures (15), buccal mucosa has become an increasingly popular graft tissue for penile or bulbar urethral reconstruction performed in single or multiple stages because it was readily available in all patients and was easily harvested from the cheek or lip with a concealed donor site scar (16-20).

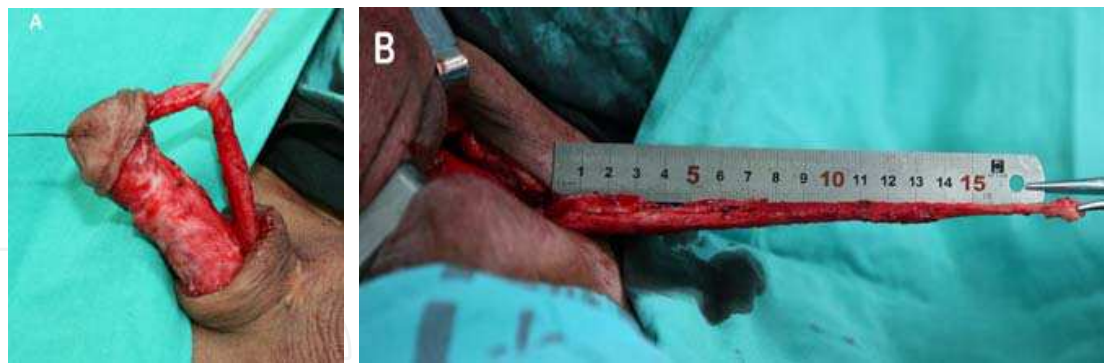

Fig. 5. (A) and (B) excising the stricture tract in which the lumen is significantly narrowed or completely obliterated

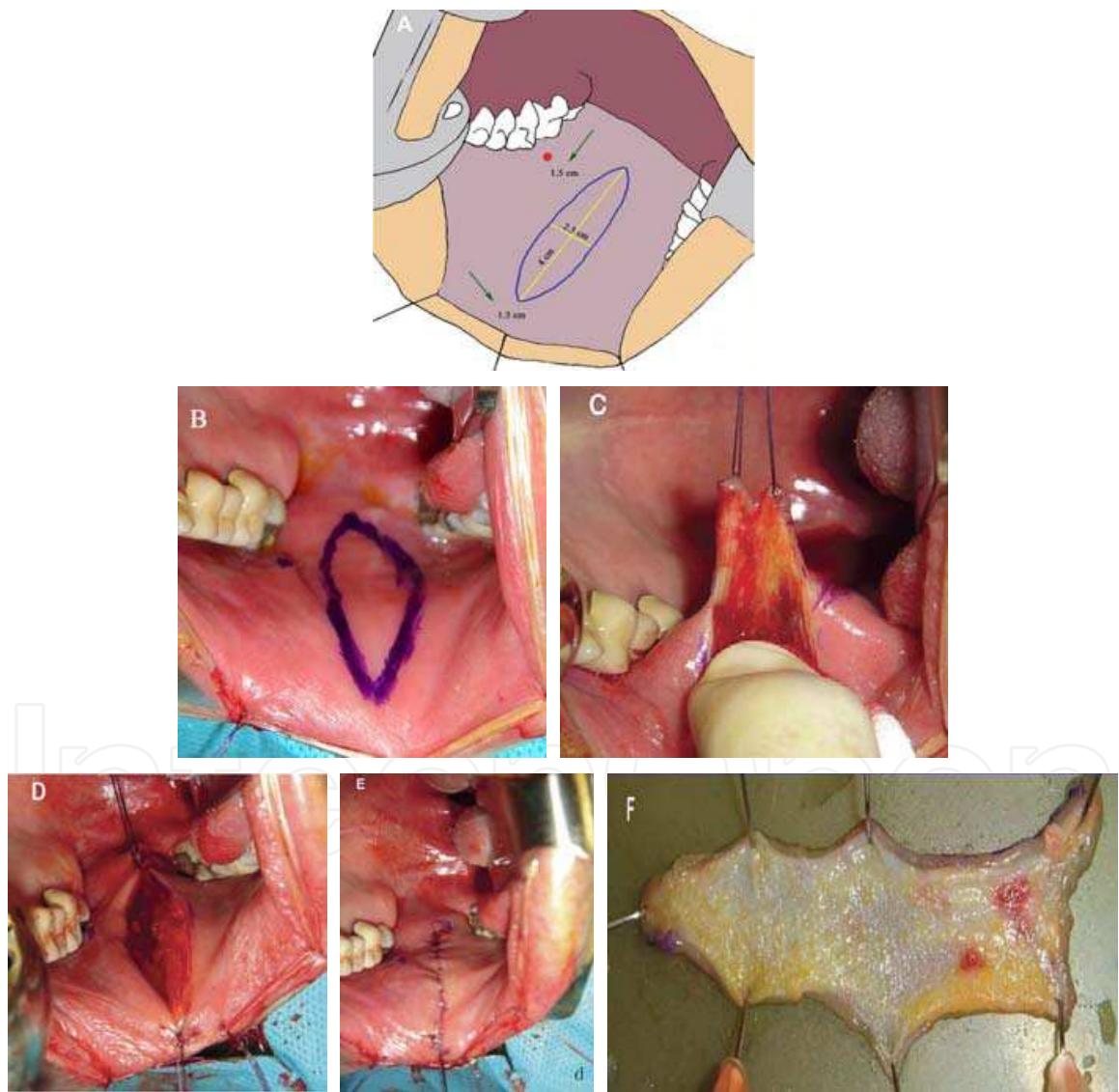


Fig. 6. The required graft marked with a surgical pen (A, B), BMG harvesting from one cheek (C), The donor site bed was carefully examined for bleeding (D) and closed using 4-0 polyglactin running sutures (E), and any excess submucosal tissue of the graft was carefully dissected away (F)

In 2006, Simonato et al first described the use of tongue tissue as an alternative donor site for graft urethroplasty and achieved good functional and aesthetic results (21,22). To further explore the use of lingual mucosa for urethral reconstruction, we investigated the use of lingual mucosa as a novel substitute for urethral reconstruction in 10 dogs before performing this operation in patients with urethral strictures (8,23,24).

3.2.1 Harvesting buccal graft

A standard mouth opener was put into place. The area to harvest was outlined and in case of buccal mucosa harvesting the Stensen's duct was identified. The required graft was measured and marked with a surgical pen (Fig. 6a,b). The area was then infiltrated with a mixed solution of 0.01% epinephrine plus bupivacaine to make subsequent dissection easier, minimize the amount of fat left on the undersurface of the graft and avoid dissection into the muscles (Fig. 6c). Buccal mucosal graft harvest from one cheek typically will give graft of 5cm to 6cm (depending on oral anatomy) and thus can be used to repair strictures of up to 9cm to 11cm. However, the buccal mucosa may not be useful independently for the treatment of the panurethral stricture because of limited material.

The donor site bed was carefully examined for bleeding (Fig. 6d) and the donor site was closed using 4-0 polyglactin running sutures (Fig. 6e). Any excess submucosal tissue, fat or muscle of the graft was carefully dissected away to optimize subsequent vascularization (Fig. 6f).

An ice pack was left for 6 hours postoperatively. Fluid and food intake was left up to the patient.

3.2.2 Harvesting lingual mucosal graft

A standard mouth opener was put into place. The apex of the tongue was passed through via a stitch for traction outside of the mouth to expose the ventrolateral surface of the tongue. Graft was harvested from the ventral to lateral mucosal lining of the tongue. The required graft was measured and marked with a surgical pen (Fig. 7a,b). The harvest graft site was infiltrated with a mixed solution of 0.01% epinephrine plus bupivacaine. The graft edges were incised and a full-thickness mucosal graft was harvested using a sharp knife beginning at the anterior landmark of the graft (Fig. 7c,d). Any excess submucosal tissue, fat or muscle of the graft was carefully dissected away to optimize subsequent vascularization. The donor site bed was carefully examined for bleeding and the donor site was closed using 4-0 polyglactin running sutures (Fig. 7e).

Bilateral lingual mucosal grafts harvested from the tongue typically will give grafts of 10 cm to 14 cm (Fig. 7f,g) (depending on tongue size), and thus can be used to repair strictures of up to 9 to 13cm.

3.2.3 Combined two oral grafts (buccal or lingual) urethroplasty

Most singleness oral mucosa graft may not be insufficient in length for the treatment of the panurethral stricture and combined two oral mucosa grafts (buccal mucosa or lingual mucosa) were always required.

One or two oral mucosa grafts (buccal or lingual grafts) were trimmed to an appropriate size according to the length and width of the urethrotomy. Combined buccal mucosa graft (Fig. 8a) or longer lingual mucosal graft (9 to 14 cm, Fig. 8b) (depending on the length of urethra

stricture or defection) were positioned into the urethrotomy defect. Spread-fixed to the underlying corpora cavernosa and two apices of the graft were sutured to the proximal and distal apices of the urethrotomy with interrupted stitches of 5-0 polyglactin. (Fig. 8a-c). Continuous upward traction was applied to the inverted penis while applying the penile portion of the graft to prevent chordee. A Foley 16 Fr to 18 Fr soft grooved silicone catheter was inserted. The full length of the urethra was rotated to its original position over the graft on the left side (Fig. 8d,e). At the end of the procedure, the graft was completely covered by the urethra, then by the muscles. Colles' fascia, the skin were closed with interrupted absorbable sutures (Fig. 8f). The bladder was drained through a suprapubic catheter; the urethral silicone stent was left indwelling for 14-21 days.

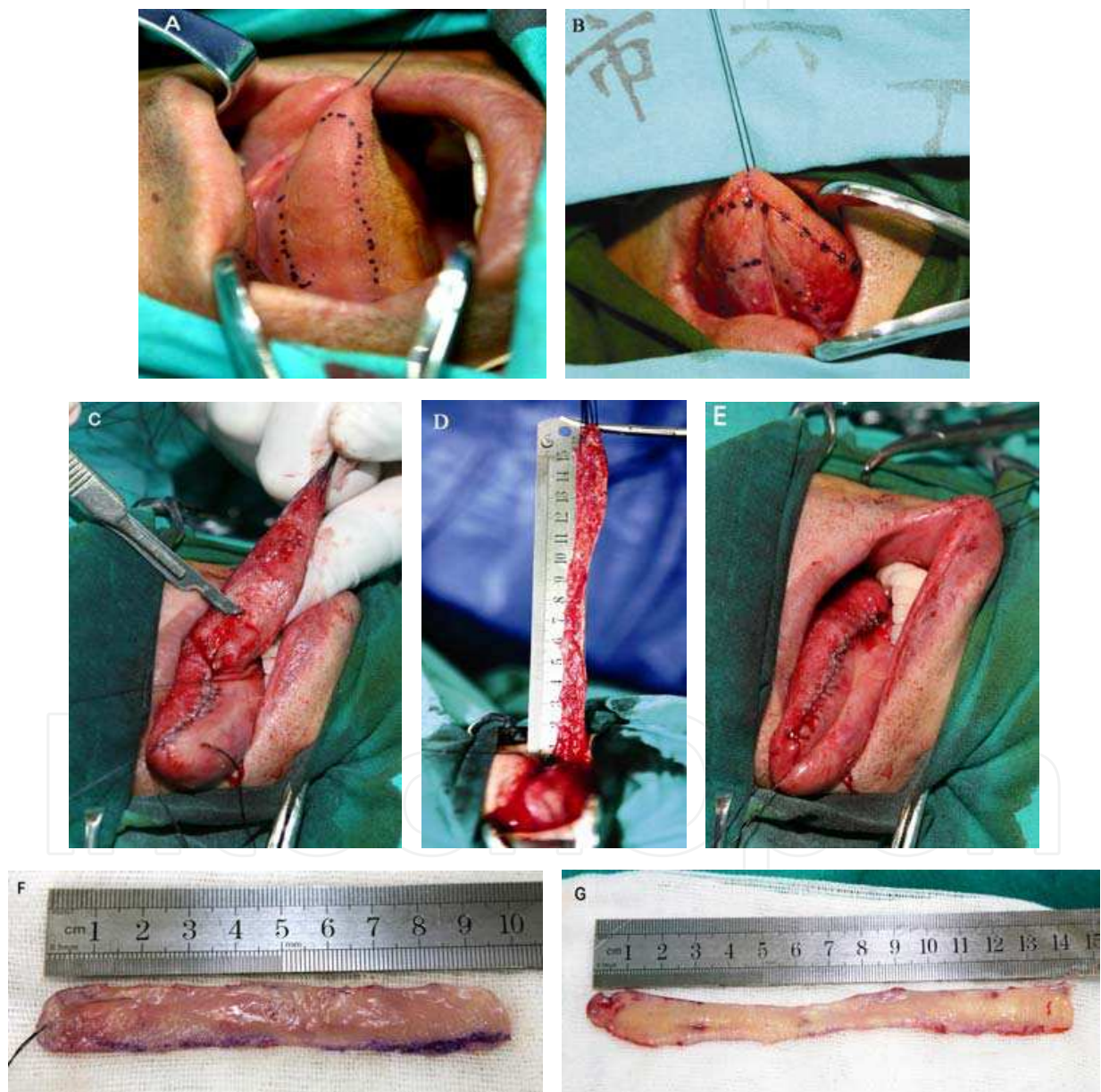


Fig. 7. The required graft marked with a surgical pen (A, B), LMG harvesting from the tongue (C) and (D), The donor site bed was closed using 4-0 polyglactin running sutures (E). Bilateral lingual mucosal grafts harvest from the tongue (F,G)

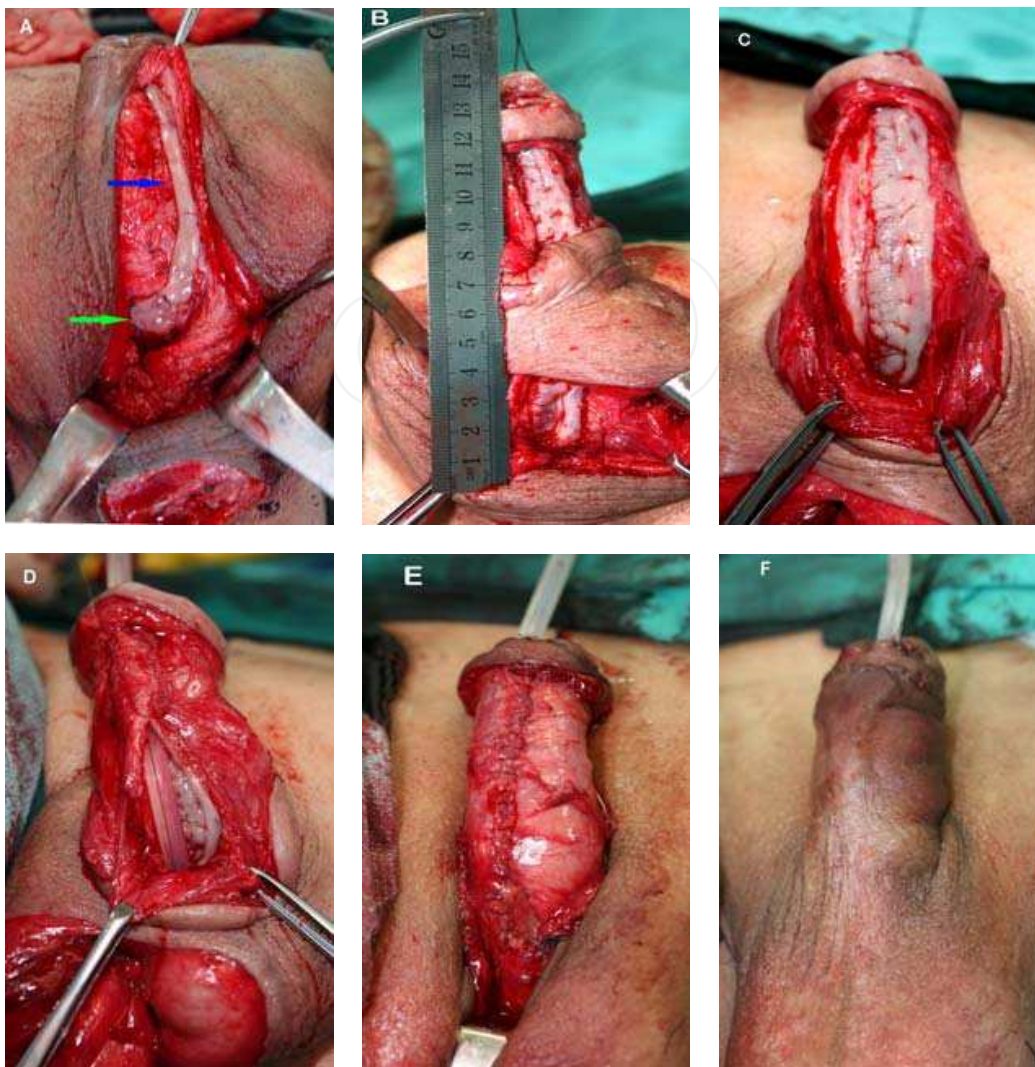


Fig. 8. Oral mucosal grafts urethroplasty. Augmentation of the urethral plate using the LMG and BMG (A), green arrow indicates LMG; blue arrow indicates BMG; LMG was positioned into the urethrotomy defect, spread-fixed to the underlying corpora cavernosa. (B), The LMG was sutured laterally to the mucosal margin of the urethral plate, augmentation of the urethral plate (C), the urethral plate sutured to mucosal margins over an 18 F soft grooved silicone catheter and the urethra was retubularized (D,E), closing the penile skin (F)

In our center, 92 consecutive patients, average age 33.8 yr (range 13 to 71 yr), underwent anterior urethra reconstruction with LMG between August 2006 and April 2009 for urethral strictures (24). Of the 92 patients, 38 patients with long-segment urethral strictures (9–18 cm) underwent dual LMG or LMG combined with foreskin flap or buccal mucosal graft urethroplasty. 34 of 38 patients were successful (89.47%) and 4 (10.53%) were failures, including urinary fistulas in one patient, recurrent stricture developed in 3 patients. We harvested grafts from both the ventral to lateral mucosa of the tongue in order to obtain a wider graft and create stable neourethras, thereby reducing the risk of recurrence at the distal or proximal graft anastomotic sites. The surgical techniques for harvesting single and double mucosal grafts from the tongue are simple and safe; and complications are rare. The tongue is an excellent source of graft material for anterior mucosal strictures. Dual LMG or

combined lingual mucosa/buccal mucosa grafts and/or foreskin flap substitution urethroplasty can successfully treat longer, more complex urethral strictures.

3.3 Colonic mucosa urethroplasty

Another graft material for reconstructing the panurethral stricture was the colonic mucosa. Under general anesthesia, stricture or atretic urethra and scar tissue were excised and the penis was straightened. The length of urethra defect was measured.

3.3.1 Harvesting colonic graft

Sigmoid colon resections may be performed using laparoscopic techniques or by lower abdomen paramedian incisions, 12 to 15 cm long sigmoid colon with its blood pedicle was isolated from the intestinal tract; the digestive connection was immediately restored by an end-to-end anastomosis. Full-thickness colonic mucosal graft (15 to 22 cm in length) was harvested from the isolated colon and the isolated colon was resected afterward. After tailoring the mucosa graft, any excess submucosal tissue, fat or muscle was carefully dissected away to optimize subsequent vascularization.

3.3.2 Urethral reconstruction

An unstretched colonic mucosa was trimmed to an appropriate size according to the length (15 to 22 cm in length and 3.0 cm in width), and was tubularized over an 16 to 18 Fr fenestrated or fluted silicone tube with interrupted 5-zero polyglactin sutures to create the neourethra (Fig. 9a). End-to-end anastomosis was performed between the native urethra and the neourethra with interrupted 5-zero polyglactin sutures or one end of neourethra was anastomosed to the proximal native urethra and the other end was pulled through the glanular tunnel to form the new meatus (Fig. 9b,c). The penile skin was closed and penis was wrapped with soft, elastic, and roller bandage incorporating the traction suture into the dressing. Strips of elastic adhesive were placed over this to keep the penis in the erect position. The dressing and bolster were taken down after 3 to 5 d. The bladder was drained through a suprapubic catheter; the urethral silicone stent was left indwelling for 14-21 days. In our center, 35 patients, average age 39.8yr (range 17 to 70yr), underwent colonic mucosal graft urethroplasty between 2000 and 2006 for complex, long-segment urethral strictures. Urethral reconstruction was performed using 11 to 21 cm (mean, 15.1) colonic mucosa grafts (14). The study demonstrates that, at a mean follow-up interval of 53.6 months, five of the 35 patients had developed recurrent strictures. However, an anastomotic site stricture developed in only one patient, and recurrent strictures in two additional patients were unrelated to the urethroplasty. Therefore, tubularized urethroplasty using colonic mucosa was associated with a lower recurrence rate than patch urethroplasty.

Colonic mucosa graft urethroplasty should be considered in patients with complex, long-segment urethral strictures. This approach may be particularly useful in patients for whom prior anterior urethroplasty was unsuccessful or in cases for where penile skin or other types of mucosal grafts are not available.

Most urethroplasty using mucosa grafts was a one-stage method for the treatment of complex urethral lengthy stricture. The key to a successful transplantation of mucosa grafts depended on whether the neovascularization was established. The following conditions were necessary for the success: 1) scar tissue should be excised as long as possible and the urethral bed for receiving the graft must be well vascularized; 2) an ischemia time of the

mucosal grafts should be as short as possible; 3) to avoid wound infection and sterile urine should be ensured.

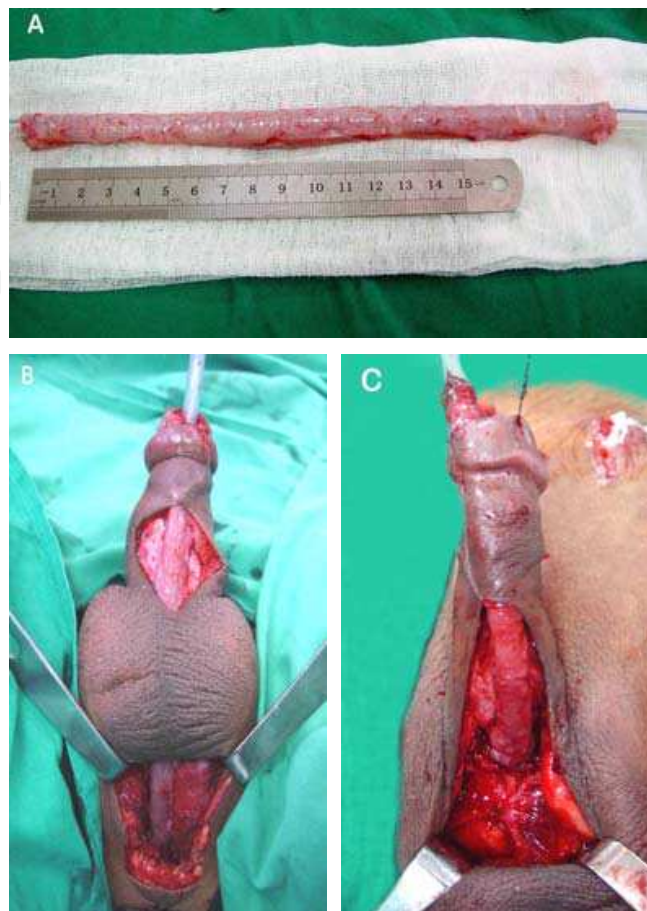


Fig. 9. A free colonic mucosa tubularized over 18 Fr silicone tube (A); colonic mucosa was anastomosed to native urethral ends (B), end of mucosa was pulled through the glanular tunnel to form the new meatus (C)

3.4 Flap combined with graft urethroplasty

For patient had a prepuce and no lichen sclerosus (LS), single-stage urethral reconstruction with a distal circumferential penile skin flap was often used to repair urethra. If the flap was insufficient or panurethral strictures involving more than the distal bulbar urethra, alternative tissue or combined grafts urethroplasty was needed for urethral reconstruction.

3.4.1 Taking penile flap

The circular pedicle island skin flap (McAninch) will typically be roughly 10~13 cm in length (depending on penile size) and 2cm in width (Fig. 10a,b). Others have used an Orandi flap in combination with a proximal graft; however, the Orandi flap was typically limited by shaft hair, and thus typically only 8-9cm in length (depending on penile size) (25).

For the distal margin of the circular skin flap, the incision was deep to the dartos of the penis and includes the anterior lamella of Buck's fascia. Such a depth was free of vascular. For the proximal margin of the skin flap, the skin was incised sharply with a scalpel, until the skin easily separates from its underlying dartos tissue. The skin can then be mobilized

away from the dartos vascular pedicle in an avascular, areolar like layer. If the pedicle of dartos and anterior lamella of Buck's fascia was adequately mobilized, the flap can be transposed even to the distal bulbar urethra, through a window underneath the scrotum.

3.4.2 Urethral reconstruction

The circular fasciocutaneous onlay flap was positioned into the urethrotomy defect and spread-fixed to the underlying corpora cavernosa. The edges of the flap were sutured to the native urethra with interrupted stitches of 5-0 polyglactin.

If the flap was insufficient in length to repair panurethral strictures, the penile urethral stricture was to repair with the flap and the bulbar stricture was to repair using an oral graft (buccal or lingual mucosa graft). The oral graft (buccal or lingual mucosa graft) was spread-fixed to the proximal bulbar urethra and the distal end of the graft was sutured to the proximal end of the flap with interrupted sutures (Fig. 10c). At the end of the procedure, the graft was completely covered by the urethra, then by the muscles. Colles' fascia, the skin were closed with interrupted absorbable sutures. The bladder was drained through a suprapubic catheter; the urethral silicone stent was left indwelling for 14-21 days.

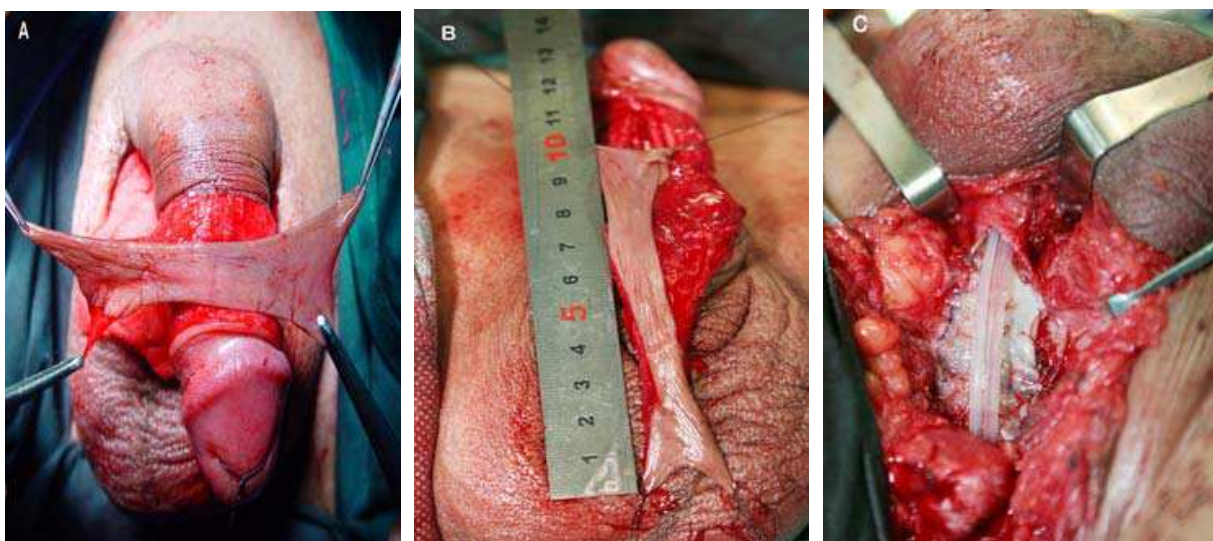


Fig. 10. A circular fasciocutaneous flap (A), fully mobilized and rotated vertically for use as an onlay flap (B). obliterated bulbar stricture was to repair using lingual mucosa graft (C)

3.5 Staged urethroplasty

For the patient with multiple surgeries and urethral infection resulting in the patient had only a 5 to 6 cm normal pendulous urethra and 2 to 3 cm prostatic urethra (Fig. 11a), the residual urethra was occlusive, and there was not enough healthy skin graft and the bed to receive the graft was not well vascularized, and where the tissues were often very scarred that had failed multiple prior urethroplasty (Fig. 11b), so substitution urethroplasty was not feasible. A staged urethroplasty may be preferable or essential (26).

3.5.1 Surgical procedures

The patient was placed in a normal lithotomy position and all surgeries were performed under general anesthesia. An inverted Y-shaped perineal incision was made, extending anteriorly to the scrotum and penis. After the scrotum was split open, the anterior urethra

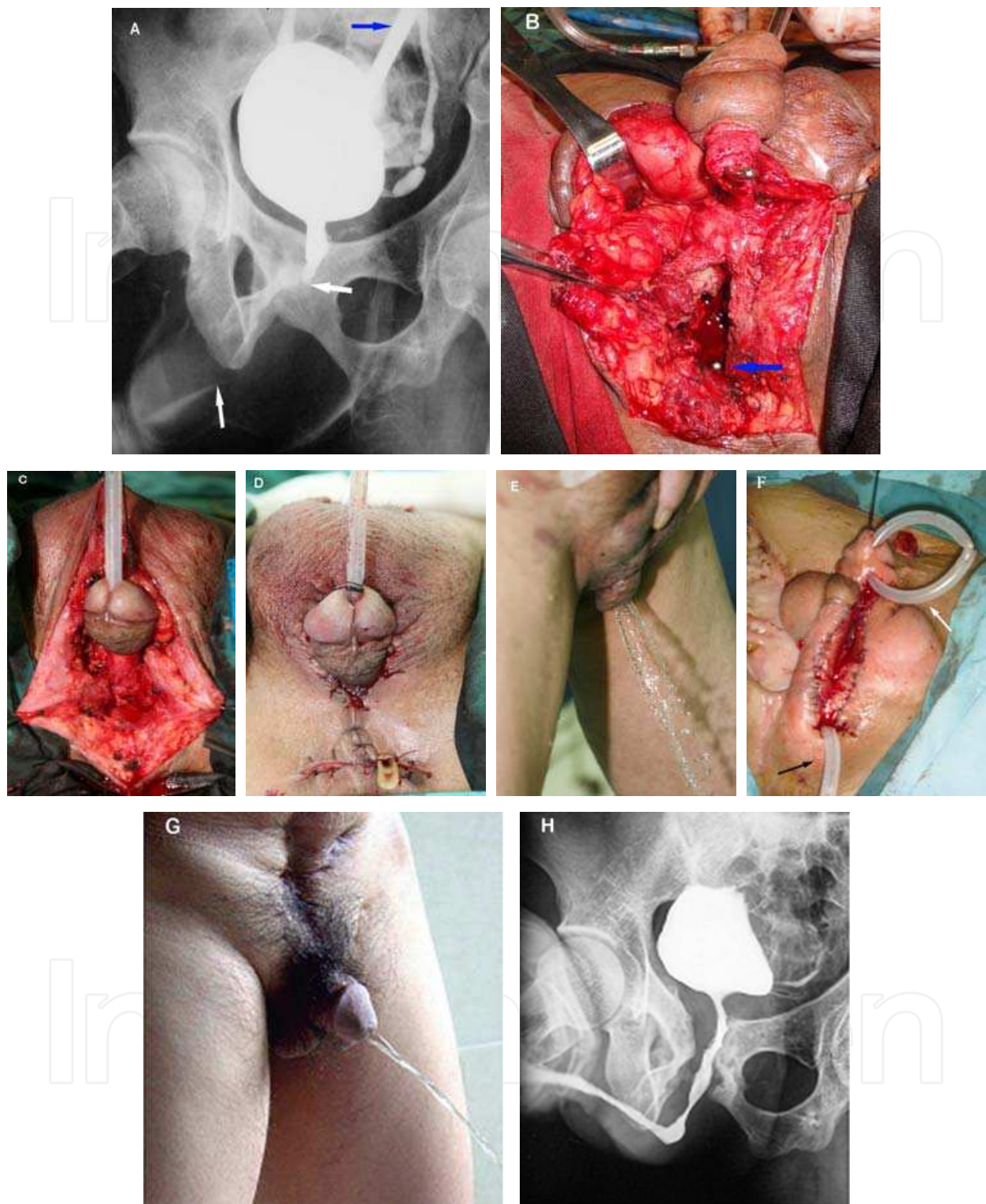


Fig. 11. (A), RUG and VUG show a shorter anterior urethra and posterior urethra, (B), transposition of penis to perineum, blue arrow indicates the distal end of posterior urethra. Pendulous-prostatic anastomotic urethroplasty (C). At the end of the procedure (D), voiding well after the first-stage op (E), straightened penis and urethroperineostomy and urethral ditch after the second-stage op (F). (G), urination after the third stage op; (H), RUG and VUG show patent urethra

was mobilized circumferentially down to the coronary sulcus (Fig. 11c). The obliterated urethra and periurethral fibrotic tissues were completely excised until a healthy prostatic urethra was mobilized about 0.5 cm for the suture. At the same time, a crural bifurcation of the corporal body separation was made. The penis and external urethral meatus were transposed to the perineum through the scrotal septum incision. The pendulous urethra was rerouted to the prostatic urethra. Tension-free pendulous-prostatic anastomotic urethroplasty was performed with the use of 4-0 polyglycolic acid sutures (Fig. 11d).

If a tension-free anastomosis could not be achieved through the perineal route; therefore, a transpubic incision and pubectomy or transperineal incision and partial inferior pubectomy should be considered. A 16 to 18 Fr fenestrated or fluted silicone tube was used as a urethral stent, a suprapubic cystostomy tube was inserted, and perineal wound was closed with a drain.

The urethral catheter was removed 21 days postoperatively. Uroflowmetry and VUG were done. If voiding was satisfactory (Fig. 11e), the suprapubic cystostomy tube was removed one day later.

The curved spongy body of the penis was separated at least 6 months later when the anterior urethra was revascularized from periurethral tissue. After the urethra was transected at the site of the coronary sulcus, the spongy body was straightened. Urethroperineostomy was performed with the proximal urethral meatus being fractionated into three valves and sutured with perineal skin. The fibrotic tissue of the albuginea penis was excised. The distal urethral stump was sutured with the skin of the penis. Skin edges of the penis and the scrotum between the urethral defects were sutured to two sides of the penile albuginea. This ventral part of the penile albuginea from the urethroperineostomy to the coronary sulcus formed an open urethral ditch that would later become epithelized. After the second-staged operation, the urethra was something like an artificial hypospadias with a normal urethral meatus (Fig. 11f).

After the urethra was transected at the site of the coronary sulcus, the spongy body was straightened, if there had a well vascularized bed to receive the graft between the proximal and distal urethral meatus, following substitution urethroplasty with oral mucosa graft between the proximal and distal urethral meatus may be preferable.

The following surgery was reconstruction of a new anterior urethra using second-stage Johanson urethroplasty. It was performed 6 months after the second surgery. A longitudinal incision of two sides of the ventral epithelized skin was made, which circled the proximal and distal meatus of the urethra, and external epithelized deep to the albuginea penis. A 1.5cm wide strip of ventral epithelized skin at the urethral ditch was used to form the dorsal wall of the new urethra. The lateral skin was undermined and closed over the buried strip to form a tube for the new urethra. In the meantime, a release incision on the dorsum of penis was made to ease the tension of the ventral wound. The ventral side of the new urethra was left to become epithelized. A suprapubic cystostomy tube was placed.

The urethral stent was removed 14 to 21 days postoperatively. If voiding was satisfactory (Fig. 11g, h), the suprapubic catheter was then removed 1 day later.

4. Selection of the urethral surgical procedures

Revisional surgery of a full-length stricture involving both the bulbar and the penile urethra was very difficult and the recurrence rate was therefore higher. Indeed the more extensive the disease, the more complicated its surgical treatment. What is the best technique to repair

panurethral stricture? How to choose? There was no gold standard and was a matter of individual judgment based on experience and the circumstances. The surgical procedures for repairing a panurethral stricture in our experiences were selected according to following principle:

1. For patient had a prepuce and no lichen sclerosus (LS), single-stage urethral reconstruction with a distal circumferential skin flap has become our first choice to repair anterior urethra. If the flap was insufficient in length or panurethral strictures involving more than the proximal bulbar urethra, alternative tissue or combined oral grafts urethroplasty was needed to augment the entire bulbar urethra from the sphincter to the peno-scrotal junction (Fig. 10b,c). Most of the complications with skin flap urethroplasty were recurrent stricture, troublesome postvoid dribbling, and diverticulum formation (6).
2. Panurethral strictures were induced by lichen sclerosus (LS) and that was the complex and difficult to repair, surgery often needs to be individualized. In severe lichen sclerosus, the meatus and fossa navicularis were almost completely obliterated (Fig. 3c), wood-hard fibrosis extended into the pendulous urethra. The stenotic bands that develop were typically multiple and throughout the bulbar and pendulous urethra.

In these severe cases the penile shaft skin was often affected by LS as well (Fig. 3b) and, thus, the nonvisible, subclinical disease will often just manifest later. Therefore, the presence of lichen sclerosus has to be considered a contraindication for any type of urethroplasty involving skin. The general principle here was to excise the diseased segment and to replace it with colonic mucosal graft, because colonic mucosal graft was the material least likely to be affected by recurrent LS.

Colonic mucosa was elastic with a slight tendency to retract. Its harvesting was less difficult with good dissecting technique and the graft provided abundant material for urethroplasty. Colonic mucosal graft urethroplasty was an effective technique for the management of extensive or pan-urethral strictures. The result was good, sustained and associated with a low complication rate so that it should be performed in preference to a substitution repair when possible. Meatal or anastomosed site stenosis was seemed to have a higher risk of failure (14).

3. For patient with multiple surgeries resulting in a shortage of local skin or in medium lichen sclerosus, therefore, the urethral lumen was not significantly narrowed and the urethral plate was remaining, we usually prefer a longer lingual mucosal graft (9 to 14 cm) or combined buccal mucosa graft (depending on the length of urethra stricture or defect) to augment strictures urethra.

For meatal stricture was induced by lichen sclerosus (Fig. 12a), where the tissues were often very scarred, we favor excision of the glandular urethral plate and enlarge meatus and followed by complete replaced by mucosal grafts and a neomeatus was then made (Fig. 12b-d).

Combined dual lingual/buccal graft urethroplasty can successfully treat long urethral strictures. The surgical technique for harvesting single and double mucosal grafts from the tongue is simple, safe, and complications were rare (8).

4. If patient had only a 5 to 6 cm normal pendulous urethra and 2 to 3 cm prostatic urethra, the residual urethra was occlusive, and there was not enough healthy skin graft and the bed for receiving the graft was not well vascularized, we usually prefer a staged urethroplasty (26).

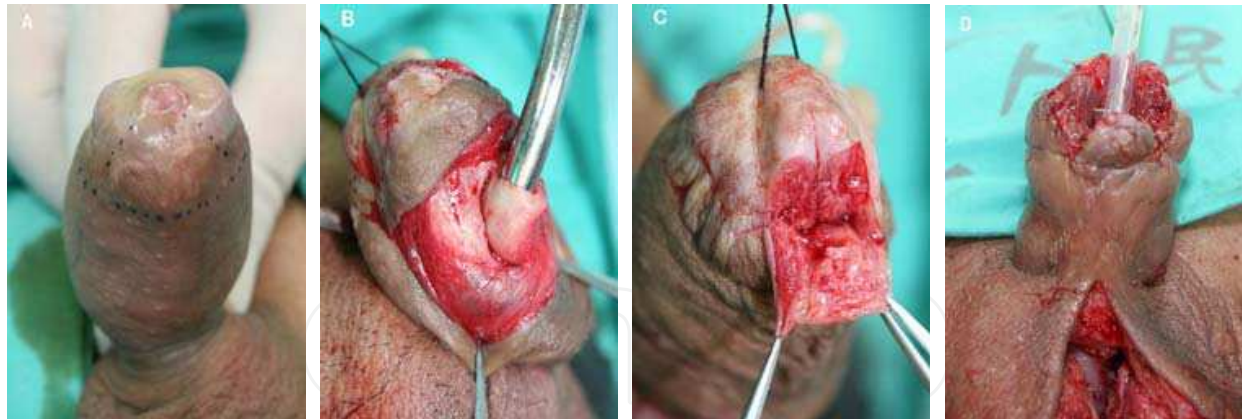



Fig. 12. Glandular reconstruction. Meatus and subcoronal incision (A), urethral plate was dissected from the glans-wings (B), excised urethral plate (C) and replaced by colonic mucosal graft (D)

5. References

- [1] Johansen B. Reconstruction of the male urethra in strictures. *Acta Chir Scand* 1953; 176 (Suppl):1-103.
- [2] Al-Ali M, Al-Hajaj R. Johanson's staged urethroplasty revisited in the salvage treatment of 68 complex urethral stricture patients: presentation of total urethroplasty. *Eur Urol*, 2001;39:268-71.
- [3] Wessells H, Morey AF, McAninch JW. Single stage reconstruction of complex anterior urethral strictures: combined tissue transfer techniques. *J Urol*, 1997;157: 1271-1274.
- [4] Elliott SP, Metro MJ, McAninch JW. Long-term followup of the ventrally placed buccal mucosa onlay graft in bulbar urethral reconstruction. *J Urol*, 2003;169:1754-1757.
- [5] Berglund RK, Angermeier KW. Combined buccal mucosa graft and genital skin flap for reconstruction of extensive anterior urethral strictures. *Urology*, 2006; 68:707-710.
- [6] Xu Y-M, Qiao Y, Sa Y-L, Wu DL, Zhang XR, Zhang J, et al. Substitution urethroplasty of complex and long-segment urethral strictures: a rationale for procedure selection. *Eur Urol*, 2007; 51:1093-1099,
- [7] Xu Y-M, Qiao Y, Sa YL, Wu DL, Zhang J, Zhang XR, et al. 1-stage urethral reconstruction using colonic mucosa graft for the treatment of a long complex urethral stricture. *J Urol*, 2004; 171:220-223,
- [8] Xu YM, Sa YL, Qiang Fu, Zhang J, Si JM, Liu ZS. Oral mucosal grafts urethroplasty for the treatment of long segmented anterior urethral strictures. *World J Urol*, 2009; 27:565-571.
- [9] Barbagli G, Palminteri E, Lazzeri M, Guazzoni G. Anterior urethral strictures. *BJU Int*, 2003; 92:497-505
- [10] McAninch JW. Reconstruction of extensive urethral strictures circular fasciocutaneous flap. *J Urol*, 1993; 149:488-491.
- [11] Carney KJ, McAninch JW. Penile circular fasciocutaneous flaps to reconstruct complex anterior urethral strictures. *Urol Clin N Am*, 2002; 29:397-409
- [12] Xu YM, Qiao Y, Sa YL, Zhang, HZ, Zhang, XR, Zhang J, et al.: An experimental study of colonic mucosa graft for urethral reconstruction. *Chin Med J*, 2002; 115:1163-1165.

- [13] Xu YM, Sa YL, Qiao Y, Zhang HZ, Zhang XR, Zhang J, et al. Histopathological changes of tree buccal mucosa and colonic mucosa grafts after translation to dog bladder. *Chin Med J*, 2005; 118:337-339.
- [14] Xu YM, Qiao Y, Sa YL, Zhang J, Jin CR, Fu Q, et al. Urethral reconstruction using colonic mucosa graft for complex strictures. *J Urol*, 2009; 182:1040-1043.
- [15] El-kasaby AW, Fath-Alla M, Noweir AM, El-Halaby MR, Zakaria W, El-Beialy MH. The use of buccal mucosa patch graft in the management of anterior urethral strictures. *J Urol*, 1993; 149:276-278.
- [16] Kane CJ, Tarman GJ, Summerton DJ, Buchmann CE, Ward JF, O'Reilly KJ, et al. Multi-institutional experience with buccal mucosa onlay urethroplasty for bulbar urethral reconstruction. *J Urol*, 2002; 167:1314-1317.
- [17] Andrich DE, Mundy AR. Substitution urethroplasty with buccal mucosal free grafts. *J Urol*, 2001; 165:1131-1133.
- [18] Patterson JM, Chapple CR. Surgical techniques in substitution urethroplasty using buccal mucosa for the treatment of anterior urethral strictures. *Eur Urol*, 2008; 53:1162-1171.
- [19] Markiewicz MR, Lukose MA, Margarone 3rd JE, Barbagli G, Miller KS, Chuang SK. The oral mucosa graft: a systematic review. *J Urol*, 2007; 178:387-394.
- [20] Barbagli G, Guazzoni G, Lazzeri M. One-stage bulbar urethroplasty: retrospective analysis of the results in 375 patients. *Eur Urol*, 2008; 53:828-833.
- [21] Simonato A, Gregori A, Lissiani A, Galli S, Ottaviani F, Rossi R, et al. The tongue as an alternative donor site for graft urethroplasty: a pilot study. *J Urol*, 2006; 175:589-592.
- [22] Simonato A, Gregori A, Ambruosi C, Venzano F, Varca V, Romagnoli A, et al. Lingual mucosa graft urethroplasty for anterior urethral reconstruction. *Eur Urol*, 2008; 54:79-87.
- [23] Song LJ, Xu YM, Hu XY, Zhang HZ. Urethral substitution using autologous lingual mucosal grafts: an experimental study. *BJU Int*, 2008; 101:739-743.
- [24] Xu YM, Fu Q, Sa YL, Zhang J, Jin CR, Si JM, et al. Treatment of urethral strictures using lingual mucosas urethroplasty: experience of 92 cases. *Chin Med J*, 2010; 123:458-462.
- [25] Quartey JK. One-stage penile/preputial cutaneous island flap urethroplasty for urethral stricture: a preliminary report. *J Urol*, 1983; 129:284-287.
- [26] Wu DL, Jin SB, Zhang J, Chen Y, Jin CR, Xu YM. Staged pendulous-prostatic anastomotic urethroplasty followed by reconstruction of the anterior urethra: An effective treatment for long-segment bulbar and membranous urethral stricture. *European Urology*, 2007; 51:504-511.



Current Concepts of Urethroplasty

Edited by Dr Ivo Donkov

ISBN 978-953-307-392-7

Hard cover, 152 pages

Publisher InTech

Published online 19, July, 2011

Published in print edition July, 2011

Urethral reconstructive surgery has always been a challenging part for urologist since the dawn of our specialty. In this book leading experts in lower urinary reconstructions from all over the world present their views and experience in that field, together with practical tips and tricks. The book is an excellent source of information for those who are already dealing with urethral surgery, and also an invaluable companion for urologists in training or those who want to dedicate themselves to this great sub-specialty. This book is an excellent reference guide and companion on the way to operating and consulting room, or when writing an article and reviewing the current practices. The abundance of methods and continuing development of new approaches to the problem prove the complexity of it.

How to reference

In order to correctly reference this scholarly work, feel free to copy and paste the following:

Yue-Min Xu and Chao Feng (2011). The Treatment of Panurethral Strictures, Current Concepts of Urethroplasty, Dr Ivo Donkov (Ed.), ISBN: 978-953-307-392-7, InTech, Available from:
<http://www.intechopen.com/books/current-concepts-of-urethroplasty/the-treatment-of-panurethral-strictures>

INTECH
open science | open minds

InTech Europe

University Campus STeP Ri
Slavka Krautzeka 83/A
51000 Rijeka, Croatia
Phone: +385 (51) 770 447
Fax: +385 (51) 686 166
www.intechopen.com

InTech China

Unit 405, Office Block, Hotel Equatorial Shanghai
No.65, Yan An Road (West), Shanghai, 200040, China
中国上海市延安西路65号上海国际贵都大饭店办公楼405单元
Phone: +86-21-62489820
Fax: +86-21-62489821

© 2011 The Author(s). Licensee IntechOpen. This is an open access article distributed under the terms of the [Creative Commons Attribution 3.0 License](https://creativecommons.org/licenses/by/3.0/), which permits unrestricted use, distribution, and reproduction in any medium, provided the original work is properly cited.

IntechOpen

IntechOpen