

We are IntechOpen, the world's leading publisher of Open Access books Built by scientists, for scientists

6,900

Open access books available

185,000

International authors and editors

200M

Downloads

Our authors are among the

154

Countries delivered to

TOP 1%

most cited scientists

12.2%

Contributors from top 500 universities



WEB OF SCIENCE™

Selection of our books indexed in the Book Citation Index
in Web of Science™ Core Collection (BKCI)

Interested in publishing with us?
Contact book.department@intechopen.com

Numbers displayed above are based on latest data collected.
For more information visit www.intechopen.com



Cardiac and Multi-Organ Transplantation in Patients with Amyloidosis

Eugenia Raichlin¹ and Sudhir S. Kushwaha²

¹University of Nebraska Medical Center, Division of Cardiology, Omaha, NE,

²Mayo Clinic, Rochester, MN, USA

1. Introduction

1.1 AL amyloidosis

Background

Amyloidosis is a group of diseases characterized by the extracellular deposition of a proteinaceous material in various organs and tissues, leading to progressive multiple organ failure and death. The presence of cardiac involvement and its relative predominance varies with the type of amyloidosis, tends to progress rapidly and has a very poor prognosis.

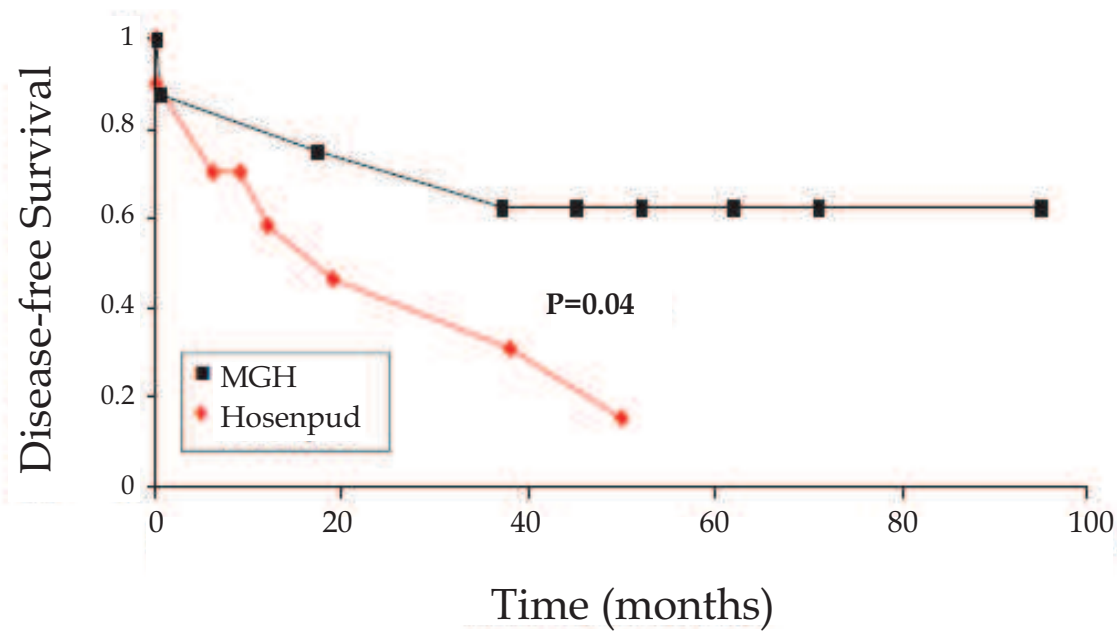
AL amyloidosis is the most common form of the disease. The heart in AL amyloidosis is affected in close to 50% of cases and amyloid deposition can be very rapidly progressive with increased untreated myocardial wall thickening at rates of up to 1.45–2.16 mm/month (Kristen *et al.*, 2007). Heart failure (HF) is the presenting clinical manifestation in about half of these patients (Dubrey *et al.*, 1998). Even among patients in whom another organ system dysfunction predominates, the presence of cardiac amyloidosis is frequently the worst prognostic factor (Kyle *et al.*, 1995). Once HF occurs, the median survival is less than six months in untreated patients (Dubrey *et al.*, 1998; Kyle *et al.*, 1995). Although the overall survival of AL amyloidosis patients can be improved by the use of high dose chemotherapy and autologous stem-cell transplantation (ASCT) (Dey *et al.*, 2010), the advanced cardiac disease at the time of diagnosis place these patients at a risk of 30% peri-treatment mortality (Falk *et al.*, 1998). Marked wall thickening, elevated brain natriuretic peptide or elevated troponin predict poor outcomes and an ejection fraction < 40% is considered an absolute contraindication to high-dose chemotherapy and ASCT (Dispenzieri *et al.*, 2003; Dispenzieri *et al.*, 2004; Falk *et al.*, 2005). However, it has been suggested that cardiac transplantation can restore health and permit subsequent administration of intensive chemotherapy.

1.2 Cardiac transplantation for AL amyloidosis

Cardiac transplantation for AL amyloidosis was first described in 1994 (Hall *et al.*, 1994). Early experience came from individual case reports and small series, which demonstrated that short and medium term mortality, did not differ from that in other disorders (Dubrey *et al.*, 2001; Hosenpud *et al.*, 1991). However reports generated from a survey of heart transplantation (HTx) centers in the USA, Canada and Europe showed outcomes significantly inferior to those seen in cardiac transplantation for primary cardiomyopathy

(Hosenpud *et al.*, 1990; Hosenpud *et al.*, 1991). Survival at four years was 39% and systemic progression was seen in the majority of patients. The Heart Transplant Centers in the European consortium reported a five-year survival of 38% in recipients with AL amyloidosis compared with 67% in recipients with HF due to non-amyloid cases (Dubrey *et al.*, 2004). Amyloid deposition occurred in the graft in every case in which it was sought histologically, and progressive systemic amyloidosis contributed to mortality in 70% of patients (Dubrey *et al.*, 2001). United Network for Organ Sharing data (Kpodonu *et al.*, 2005) are the largest published series of patients undergoing cardiac transplantation for AL amyloidosis which included 69 cardiac transplantations performed at 24 different centers in the USA, found a five-year survival of 54%. However, survival was not analyzed according to amyloid type in this study. Based on these discouraging outcomes amyloid heart disease has been considered a contraindication for HTx. Moreover, the need for adjunctive chemotherapy to suppress production of monoclonal light chains became obvious from the findings of several series that confirmed that relatively rapid development of cardiac allograft amyloid (Dubrey *et al.*, 1995; Valantine *et al.*, 1989;).

In 2004, Skinner *et al.* reported a complete hematologic response, defined as no evidence of an underlying plasma cell dyscrasia one year after treatment, in 40% of patients with primary AL amyloidosis who received high-dose melphalan followed by autologous stem cell transplantation (Dey *et al.*, 2010; Skinner *et al.*, 2004). Recently cardiac transplantation followed by high-dose chemotherapy and ASCT has been shown to be feasible in carefully selected patients with AL amyloidosis and severe HF (Dey *et al.*, 2010; Gillmore *et al.*, 2006; Kristen *et al.*, 2009; Lacy *et al.*, 2008; Maurer *et al.*, 2007; Mignot *et al.*, 2008; Sattianayagam *et*

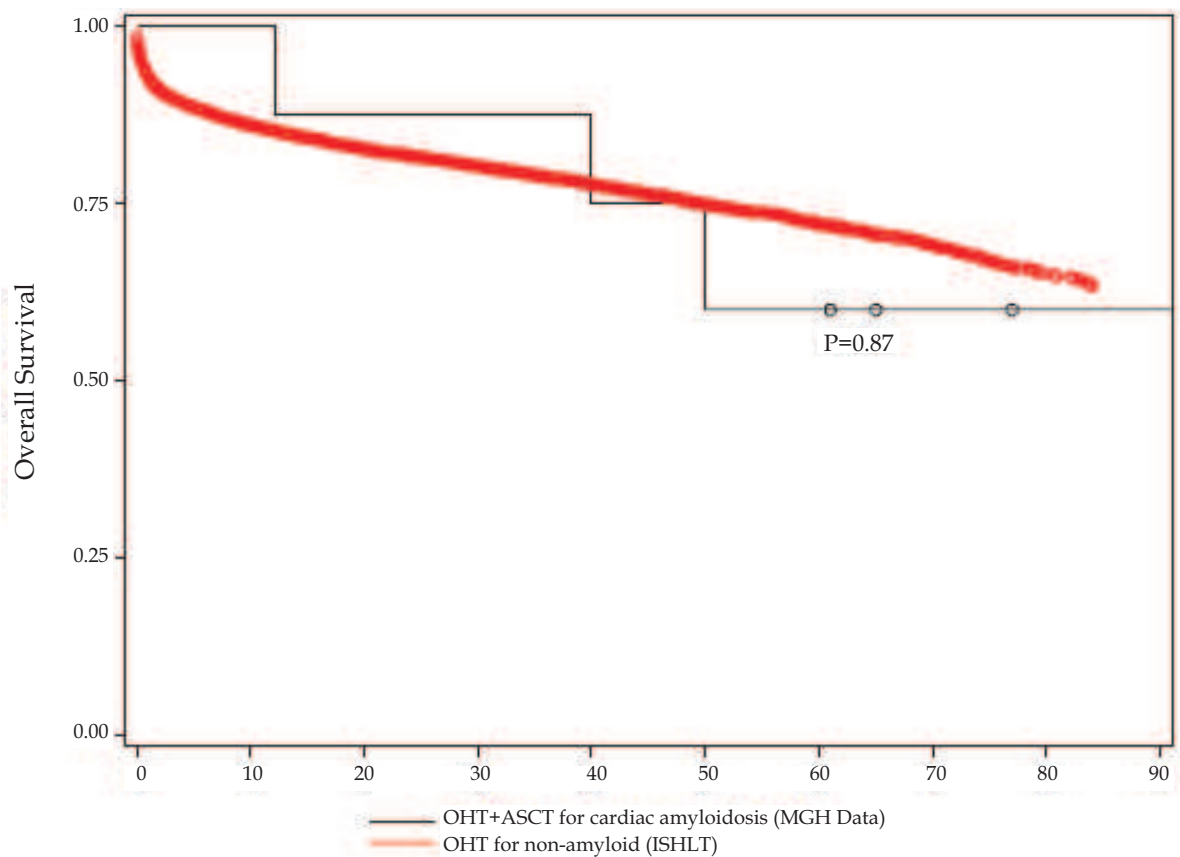


Reproduced from Dey *et al.*, 2010

Fig. 1. Kaplan-Meier disease free survival estimates, according to treatment MGH, orthotopic heart transplant followed by hematopoietic stem-cell transplant for cardiac amyloidosis; Hosenpud, orthotopic heart transplant alone for cardiac amyloidosis. Comparisons of survival between two groups of patients were made using the log-rank and Wilcoxon tests

al., 2010). This treatment is aimed at preventing recurrence of amyloid in the cardiac allograft or progression of extra cardiac amyloidosis, thus long-term remission and apparent improvement in long term survival in carefully selected patients can be achieved. (Fig. 1) Gillmore *et al.*, reported five patients with AL amyloidosis and predominant cardiomyopathy undergoing sequential HTx followed by ASCT: three patients survived for more than nine years without evidence of recurrence and two patients died of progressive amyloidosis at 33 and 90 months after HTx (Gillmore *et al.*, 2006). This study also showed that relapse of the plasma cell dyscrasia after ASCT was associated with characteristic echocardiographic evidence of cardiac amyloidosis and rise in serum NT-pro-BNP. Maurer *et al.*, reported on 10 patients who underwent HTx for AL amyloidosis (Maurer *et al.*, 2007). In this study among eight patients who received subsequent ASCT, two died from sepsis and lymphoma. The median survival from cardiac transplantation of 9.7 years in this series is comparable to US all-cause cardiac transplant survival (Sattianayagam *et al.*, 2010).

The largest case scenarios came from Mayo Clinic and Massachusetts General Hospital (Dey *et al.*, 2010; Lacy *et al.*, 2008). In report of Dey *et al.*, five of eight patients who underwent sequential HTx /ASCT were alive with a good functional status at a median follow-up of 56 months (range, 7–101 months). None have evidence of recurrent amyloidosis, with four



OHT, orthotopic heart transplant; ASCT, autologous hematopoietic stem-cell transplant; MGH - Massachusetts General Hospital; ISHLT, International Society for Heart and Lung Transplantation. Reproduced from Dey *et al.*, 2010

Fig. 2. Kaplan-Meier overall survival estimates, according to treatment. Comparisons of survival between OHT and OHT+ASCT groups of patients (p=0.87, log-rank and Wilcoxon tests)

remaining in complete hematologic remission. The survival of these patients (Figure 2) was 60% at seven years, which is not significantly different from the outcomes of 17,389 patients collected in the database of the International Society for Heart and Lung Transplantation who underwent HTx for non-amyloid heart disease during the same time. Lacy *et al.*, from the Mayo Clinic have published a series of 11 carefully selected patients undergoing sequential HTx /ASCT. They reported a one and five-year survival of 82% and 65%, respectively (Lacy *et al.*, 2008). Although two patients died from transplant-related toxicity and three patients died from progressive amyloidosis, the survival was comparable to patients undergoing HTx for non-amyloid disease.

Thus, the data indicates that reasonable outcomes are achievable in patients with severe cardiac AL amyloidosis after HTx if underlying dyscrasia plasma cell is successfully treated afterward.

1.3 Selection criteria

In the early experience of cardiac transplantation for AL amyloidosis, patients were not screened to exclude extensive systemic involvement and a significant degree of systemic involvement may have accounted for the particularly poor prognosis. Careful patient selection may have contributed at least partially to improved outcomes in more recent studies.

The baseline evaluation of all patients being considered for transplantation includes bone marrow aspirate and biopsy, echocardiogram, serum and 24-hour urine monoclonal protein studies, immunoglobulin-free light-chain assay, a chemistry panel including creatinine, liver function tests and renal clearance estimates (Gertz *et al.*, 2005).

In the Mayo Clinic series, selection criteria for cardiac transplantation included advanced cardiomyopathy, age under 60 years, and absence of myeloma or extensive extra-cardiac amyloidosis (Lacy *et al.*, 2008). (Table 1)

In the MGH data, however, in addition to advanced cardiac disease extra cardiac solid organ involvement by amyloidosis was present in all patients at the time of evaluation: all but one of the patients had evidence of amyloid deposition in the gastrointestinal tract, significant proteinuria was present in two and peripheral neuropathy in three HTx patients. Monoclonal plasma cells comprised 5% to 10% of marrow cellularity (Dey *et al.*, 2010).

1.4 Waiting period

Unfortunately, patients with AL amyloidosis and severe HF have an extraordinarily poor prognosis on completing their cardiac transplant evaluation. Of 26 patients evaluated in the MGH series, 18 patients were selected and listed for HTx/ASCT, but only half survived to HTx (Dey *et al.*, 2010). In the Mayo Clinic experience, of 54 patients evaluated, 27 patients were selected and listed for HTx but nine died while on the waiting list and six were removed from the list due to progressive disease. Only 11 patients (20%) underwent cardiac transplantation. In the study of Sattianayagam *et al.*, less than 2% of all patients with systemic AL amyloidosis assessed at the United Kingdom National Amyloidosis Center underwent cardiac transplantation (Sattianayagam *et al.*, 2010).

Despite the significant risk of death associated with the use of vigorous chemotherapy in patients with AL cardiac amyloidosis, it should be considered in selected patients: a clinical improvement in HF despite an unchanged echocardiographic appearance has been reported (Dubrey *et al.*, 1996). This improvement may result from the abolition of the production of freshly produced light chains, which have been shown to be toxic to myocardial cells,

Routine cardiac transplantation evaluation with the following additional studies:	<ul style="list-style-type: none">● Serum protein electrophoresis● Urine protein electrophoresis (24-hour urine)● Factor X and thrombin time (special coagulation studies)● Bone marrow biopsy with aspirate, labeling index and smear● Labeling index in peripheral blood with number of circulating plasma cells● Serum carotene● β_2-microglobulin● C-reactive protein● 24-hour urine creatinine clearance● 48-hour stool collection for fat● Subcutaneous fat aspirate● Metastatic bone survey with single views of humeri and femurs
Pulmonary assessment will proceed as follows:	Recurrent pleural effusions, refractory to treatment will necessitate: <ul style="list-style-type: none">● Chest CT● Possible lung biopsy dependent on CT findings
Liver assessment will proceed as follows:	<ul style="list-style-type: none">● If alkaline phosphatase <1.5-fold upper limit of normal (350), then proceed with transplant evaluation● If alkaline phosphatase 1.5- to 3-fold upper limit of normal, then proceed to liver biopsy:<ol style="list-style-type: none">1. If there is portal tract amyloid deposition, then there is an absolute contraindication2. If vascular amyloid only, then proceed with transplant evaluation● If alkaline phosphatase is \geq3.0-fold upper limit of normal (750), absolute then there is an contraindication to HT
Renal assessment will proceed as follows:	Lothalamate clearance should exceed 50 ml/min/1.73 m ² <ul style="list-style-type: none">● If urinary albumin is <250 mg/24 hours, then proceed with transplant evaluation● If urinary albumin is 250 to 1,000 mg/24 hours, then proceed to renal biopsy<ol style="list-style-type: none">1. If vascular amyloid only, is present then proceed with transplant evaluation2. If interstitial or glomerular amyloid is present, then there is an absolute contraindication to cardiac transplant
Blood/marrow plasma cell labeling index assessment will proceed as follows:	Plasma cell labeling index <ul style="list-style-type: none">● If plasma cell labeling index is \geq2%, then exclude from consideration for transplant evaluation● If plasma cell labeling index is \geq1%, then proceed to metastatic bone survey to exclude myeloma-associated bony lesions● If plasma cell labeling index is <1%, then proceed with transplant evaluation Peripheral blood labeling index <ul style="list-style-type: none">● If peripheral blood plasma cell labeling index is >1%, then absolute contraindication to cardiac transplant Plasmacytosis <ul style="list-style-type: none">● If plasma cell differential on marrow aspirate is <10%, then proceed with transplant evaluation● If plasma cell differential on marrow aspirate is 10% to 20%, then do metastatic bone survey to exclude myeloma-associated bony lesions● If plasma cell differential on marrow aspirate, marrow biopsy or cytoplasmic immunoglobulin–positive plasma cells are \geq20%, then contraindication to there is an absolute cardiac transplant
Intestinal assessment will proceed as follows:	<ul style="list-style-type: none">● 48-hour stool collection for fecal fat to rule out malabsorption● Serum carotene if low level could indicate malabsorption● Endoscopic and flexible sigmoidoscopic evaluation with biopsy<ol style="list-style-type: none">1. If vascular amyloid deposition only, then proceed with transplant evaluation2. If mucosal amyloid deposition, then there is an absolute contraindication to cardiac transplantation

Adapted from Lacy *et al.*, 2008

Table 1. Cardiac Transplantation: pre-transplant evaluation of AL amyloid patients

suggesting that AL amyloidosis is not simply an infiltrative cardiomyopathy but rather a toxic infiltrative disorder (Brenner *et al.*, 2004; Falk *et al.*, 2005; Liao *et al.*, 2001; Nakamura *et al.*, 2002). Despite the risk and delayed clinical benefits (Skinner *et al.*, 1996), successful outcomes have been reported in small numbers of patients treated with chemotherapy followed by cardiac transplantation (Mignot *et al.*, 2008). At the United Kingdom National Amyloidosis Center five patients were fit enough to receive chemotherapy and achieved a partial hematologic response before cardiac transplantation. Similarly, one patient at Mayo Clinic and two patients at MGH received systemic therapy consisting of melphalan and prednisone before cardiac transplantation. In cases when a substantial delay before the cardiac transplant is likely, the earlier application of plasma-cell-targeted therapeutic approaches with newer agents, such as bortezomib and lenalidomide (Kastritis *et al.*, 2007; Santhorawala *et al.*, 2007) which are effective and better tolerated than conventional chemotherapeutic agents, beginning at the time of the evaluation process may be beneficial, and improve patients' chances for receiving an HTx. A similar approach may also be considered for patients who are not ready for ASCT after cardiac transplantation since a prolonged time without treatment may allow progression of the amyloidosis and therefore both impair the candidacy of these patients for ASCT and increase their transplant related mortality (Dey *et al.*, 2010; Lacy *et al.*, 2008).

1.5 Timing of ASCT after the HTx

During the last several years, ASCT has undergone further refinement, including changes in supportive care and a better understanding of the complications of ASCT that are unique to amyloid patients. The optimal timing of ASCT after the HTx is debatable. Pursuing ASCT too soon may be problematic if the patient continues to require intensive immunosuppression to prevent organ rejection. Waiting too long may result in the amyloidosis progressing in other organs. Therefore, at the present time, it is recommended that ASCT be pursued approximately six to seven months after HTx (Dey *et al.*, 2010; Lacy *et al.*, 2008).

1.6 Recurrence of cardiac amyloidosis

Although in the United Kingdom study the patients were followed for two to six years with serial endomyocardial biopsies with no evidence of recurrent amyloid deposition during this time (Dubrey *et al.*, 2004), five of the 11 patients reported by Lacy *et al.*, demonstrated biopsy-proven recurrence in the cardiac allograft. Interestingly, none of these patients had symptoms, echocardiographic evidence, or biochemical evidence of cardiac amyloidosis. A similar observation was reported by Dey *et al.*, demonstrating that amyloid deposition in their heart transplant patients has had little clinical consequence, with no echocardiographic evidence of amyloid cardiomyopathy. By contrast, Gilmore showed that relapse of the plasma cell dyscrasia after ASCT was associated with characteristic echocardiographic evidence of cardiac amyloidosis and rise in serum NT-pro-BNP. The varying results may be secondary to multiple factors, including the type of chemotherapy used, the timing of ASCT following heart transplant, the type of underlying plasma cell dyscrasia as well as individual patient factors (Luk *et al.*, 2009). Nevertheless, the recurrent disease despite aggressive multimodality therapy is a reminder that it may be difficult to prevent recurrent protein deposition in patients with AL amyloidosis. Although conclusions are limited by the small sample size, it is likely that ASCT following cardiac transplantation results in a lack of clinically significant recurrent amyloidosis despite the presence of recurrent amyloid deposition and prolongs the interval of disease recurrence in the cardiac allograft. However,

it is possible that future survival of patients with disease recurrence in the cardiac allograft beyond the time described may be limited (Dey *et al.*, 2010).

1.7 Conclusions

Although a multidisciplinary approach dedicated to early diagnosis, appropriate and timely screening for HTx and a multimodality plasma cell dyscrasia specific strategy may offer long-term remission for carefully selected patients with cardiac amyloidosis, HTx for amyloid cardiomyopathy continues to generate controversy because of the donor shortage and concerns about recurrence either in the transplanted heart or other vital organs. Clinical trials are still required to clarify which patients are most likely to achieve durable remissions after HTx and which chemotherapy strategy is most effective to eradicate the plasma cell clone.

1.8 Combined heart and kidney transplantation in patients with AL amyloidosis

AL amyloidosis is a multi-organ disease and the proportion of patients with cardiac AL amyloidosis and minimal systemic disease at the time of diagnosis is less than 5% (Dubrey *et al.*, 1998). Cardiac amyloidosis frequently coexists with renal involvement which is characterized by nephrotic proteinuria and progressive worsening of renal function. However there are only two published cases of combined organ transplantation in patients with AL amyloidosis. Because of significant renal impairment, one patient received a combined heart and kidney transplantation (CHKTx) followed by ASCT at MGH and is reported to be alive up to 65 months with no evidence of recurrence. In case of partial hematologic remission induced by two courses of oral melphalan plus prednisone, followed by CHKTx, without ASCT, resulting in excellent renal and cardiac allograft function at three years has been reported (Audard *et al.*, 2009).

2. Familial amyloidosis (ATTR)

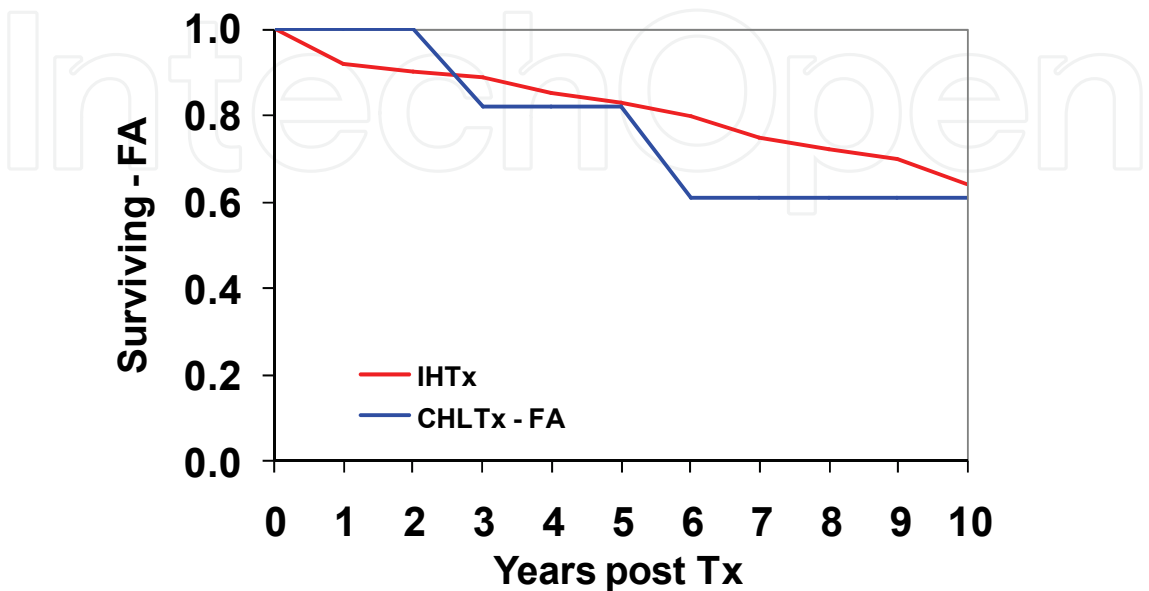
2.1 Introduction

Familial amyloidosis (ATTR) is a fatal autosomal-dominant multisystem disorder induced by deposition in several organs of abnormal serum ATTR (prealbumin) protein which is mainly produced in the liver. Amongst the over 40 mutations described, the Portuguese variant (ATTR Met30) is the most frequent and not associated with cardiomyopathy. Orthotopic liver transplantation is established as the treatment of choice for ATTR Met30 with stabilization or remission of symptoms. In patients with a non-ATTR Met30 mutation and cardiomyopathy, after isolated liver transplantation (ILTx), the amyloid fibril deposition in the heart is increased suggesting that wild-type ATTR probably constitutes amyloid in the heart similar to the phenomenon observed in senile systemic amyloidosis (Stangou *et al.*, 1998; Westermarck *et al.*, 1990; Yazaki *et al.*, 2000). This leads to progression of cardiomyopathy following ILTx in patients carrying a non-ATTR Met30 mutation and suggests that CHLTx is the procedure of choice (Pomfret *et al.*, 1998). The first case of CHLTx in familial amyloidosis patients was reported by (Rela *et al.*, 1995), however, the world-wide experience of this is small, and less than 25 cases of CHLTx have been reported in the medical literature.

2.2 Survival after CHLTx in ATTR amyloidosis

CHLTx experience has been analyzed for ATTR disease in the United Kingdom and the five-year survival has been shown to be comparable with survival after transplantation for other diseases suggesting that this procedure should be indicated for several non-ATTR Met30

variants with recognized risk for progressive amyloid cardiomyopathy (Dubrey *et al.*, 2004). A relatively large series from Mayo Clinic demonstrates the feasibility and excellent short and long term success that can be achieved with CHLTx for selected high-risk patients with familial amyloidosis. Indeed, patient survival after CHLTx was shown to be equivalent to those with IHTx. (Figure 3)



IHTx – isolated heart transplantation. CHLTx – combined heart and liver transplantation.
Reproduced from Raichlin *et al.*, 2009

Fig. 3. Survival rates for FA patients at 1 month, 1 year, 5 and 10 years were 100%, 100%, 75%, and 60% and did not differ from IHTx (97%, 93%, 83% and 65%, $p=0.39$, Log-Rank test)

In the Mayo Clinic study, among 11 patients with ATTR the most frequent mutations were ALA 60 (4), and TYR 77 (3), followed by PRO 24 (1), SER (1) and ASP 18 GLU (1). One patient had an undefined mutation. This study showed that specific ATTR mutations do not affect the therapeutic success of CHLTx. Indeed, ALA 60 ATTR has been reported as a mutation of particularly poor prognosis and five of eight patients with ALA60 mutation described in the literature have died after ILTx (Kotani *et al.*, 2002; Sharma *et al.*, 2003). Moreover, the Tyr 77 ATTR (German variant) mutation is also typically associated with prominent and progressive cardiac involvement after ILTx (Garcia-Herola, 1999). In the Mayo Clinic report three of the four patients with ALA 60 ATTR mutation remain alive and one died of progressive renal failure; three patients with the TYR 77 ATTR variant remain alive and had no amyloid deposition on the last endomyocardial biopsy.

Autonomic disturbances, modified body mass index, duration of symptoms, polyneuropathy, disability score, orthostatic hypotension, gastrointestinal and urinary tract dysfunction are important factors in the preoperative evaluation (Grazi *et al.*, 2003; Sharma *et al.*, 2003; Pilato *et al.*, 2007) and optimizing the timing for CHLTx appears to be crucial.

2.3 Surgical approaches for CHLTx

Several different surgical approaches have been described for CHLTx:

1. Transplantation of the heart but maintaining the patient on cardio-pulmonary bypass during the liver transplant was described. Subsequent concerns about substantial

- coagulopathy and increased bleeding changed the strategy to performing liver implantation following separation from cardiopulmonary bypass (Befeler *et al.*, 1999; Grazi *et al.*, 2003; Shaw *et al.*, 1985; Detry *et al.*, 1997; Nardo *et al.*, 2004). Improved surgical and anesthetic techniques during liver transplant, and the potential benefits to the transplanted heart to remain on cardio-pulmonary bypass during liver implantation led to revising this strategy for CHLTx. In the case study by Hennessey and colleagues, this technique was suggested to provide a considerably shortened liver ischemia time and decreased blood transfusion compared to the sequential approach (Hennessey *et al.*, 2010).
2. Transplantation of the heart with discontinuation of cardio-pulmonary bypass, leaving the chest opened. The liver transplantation was performed as a second step through a bilateral sub-costal incision with extension in the midline to the sternotomy (Couetil *et al.*, 1995) and was accomplished by a caval sparing hepatectomy with an anastomosis between the donor supra-hepatic cava and the recipient left/middle hepatic vein trunk. Biliary tubes were inserted through the donor cystic duct stumps whenever possible, and the abdomen was closed over drains after achieving hemostasis. (Raichlin *et al.*, 2009) One of the major advantages of this procedure is that CHLTx can be performed with minimal deviation from the standard procedures of IHTx and ILTx.
 3. Staged heart and liver transplantation was first reported by Figuera (Figuera *et al.*, 1986) for patients who underwent HTx and were hemodynamically unstable after cardiac reperfusion. Subsequent liver transplantation was deferred, and the patients underwent deceased donor liver transplantation from a second donor. (Barreiros *et al.*, 2010; Pilato *et al.*, 2007)

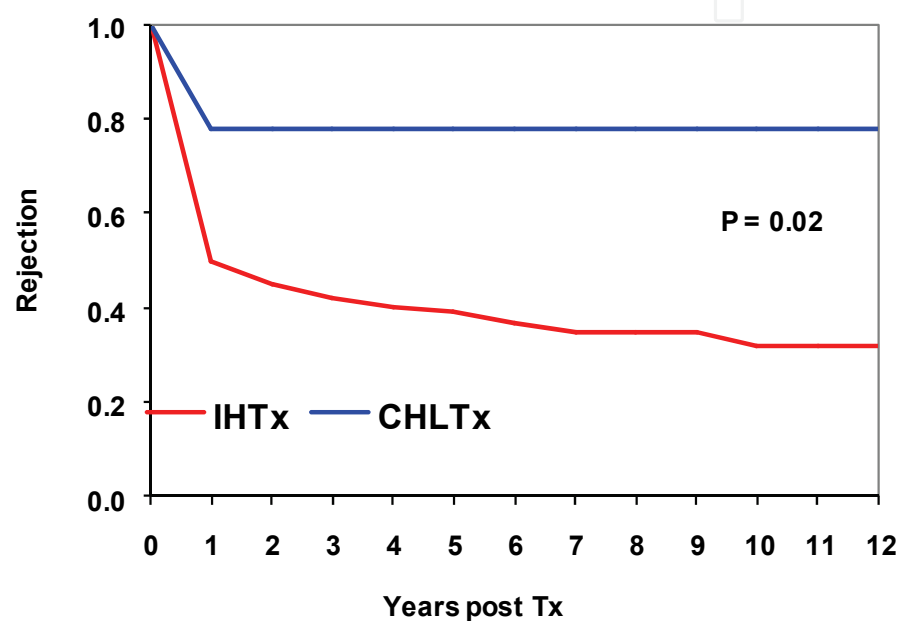
In the Mayo Clinic study simultaneous CHLTx was feasible in 87% (13 of 15) of patients and appears favorable if cardiac function and hemodynamics are satisfactory (Raichlin *et al.*, 2009).

Based on the experience of several centers (Befeler *et al.*, 1999; Raichlin *et al.*, 2007a) it seems that renal failure secondary to hypo-perfusion from cardiopulmonary and veno-venous bypass, blood loss and the nephrotoxic effects of peri-operative medications (including inotropic agents and immunosuppressive drugs) complicate the early post-operative course of many patients following CHLTx. As demonstrated in the study from Mayo Clinic, none of the preoperative evaluations were able to predict such postoperative complications. Within one month following transplantation renal function improved in the CHLTx patients and was comparable with the isolated heart transplantation (IHTx) group. However, three patients (30%) developed late end-stage renal failure presumably as a result of calcineurin inhibitor toxicity (clinical picture was not consistent with amyloid glomerulopathy) and required hemodialysis. Therefore, renal function was significantly worse in the CHLTx patients at the late follow-up. It was previously demonstrated that the risk of chronic renal failure after transplantation of a non-renal organ depends on the type of organ transplanted and at five years the cumulative incidence of chronic renal failure was lower after IHTx (10.9 ± 0.2) compared to ILTx (18.1 ± 0.20) (Gonwa *et al.*, 2001; Ojo *et al.*, 2003). Calcineurin inhibitor sparing (Sirolimus based) immunosuppression probably should be considered in CHLTx patients to prevent progressive calcineurin inhibitor - induced renal damage (Raichlin *et al.*, 2007a; Raichlin *et al.*, 2007b).

2.4 Acute cellular rejection

Acute cellular rejection of the liver is infrequent in CHLTx (Raichlin *et al.*, 2009). The more aggressive immunosuppression regimen employed for CHLTx compared with that used for

ILTx may make rejection of liver allografts a relatively infrequent event. Interestingly, heart rejection was less frequent in CHLTx than in those receiving IHTx. (Figure 4) To explain the favorable low rejection rate an induction of partial tolerance has been proposed as a mechanism. The liver has been demonstrated to permit acceptance of other simultaneously transplanted organs operating via shedding soluble HLA antigens (Davies *et al.*, 1989; McMillan *et al.*, 1997). It has been hypothesized that maintaining a concentration of soluble HLA in the circulation would lead to tolerance to the allotype of the soluble HLA. This concept may help explain the protection of a simultaneous heart transplant by a successful human liver transplant (Vogel *et al.*, 1988). Therefore, less intensive immunosuppression therapy for these patients after CHLTx than for IHTx may be justified.



IHTx – isolated heart transplantation. CHLTx – combined heart and liver transplantation.
Reproduced from Raichlin *et al.*, 2009

Fig. 4. Freedom from cardiac allograft rejection (International Society for Heart and Lung Transplantation \geq Grade 2) for at 1 month was 83% and did not change further. For IHTx freedom from rejection at 1 month, 1 year, 3 years and 10 years was 80%, 48%, 42% and 32% respectively ($p=0.02$, Log-Rank test)

2.5 Postoperative course and complications

In the Mayo Clinic report for recipients of CHLTx the mean intensive care unit stay did not differ ($p=0.23$) and the mean hospital stay was not significantly longer than for IHTx ($p=0.09$).

2.6 Pulmonary embolism

Pulmonary embolism is a rare complication in early period post IHTx (Berroeta *et al.*, 2006). In Mayo Clinic study two patients developed pulmonary embolism and were treated with anticoagulation. This high incidence of pulmonary embolism in recipients of CHLTx probably reflects the prolonged immobilization period and delayed recovery of anticoagulant proteins in this group of patients (Stahl *et al.*, 1990).

2.7 Cardiac allograft function

In the Mayo Clinic study, during a mean 65 month follow up, all heart allografts displayed normal systolic function on echocardiography with mean left ventricular ejection fraction $65\% \pm 7\%$ and no signs of left ventricular heart. Congo red stain and/or sulfated alcian blue stain was negative for amyloid in all patients. There has been no significant cardiac allograft vasculopathy in any of these.

2.8 Use of amyloidotic livers for domino liver transplantation

Since livers explanted from patients with FA contain only microscopic amyloid deposits and are otherwise essentially normal, and it typically takes approximately 50 years for TTR deposition to progress to clinically apparent disease, the FA liver can be used as a domino donor liver for selected older patients awaiting liver transplantation. CHLTx does not preclude domino donation of FA recipients' liver. In contrast to caval sparing hepatectomy with an anastomosis between the donor supra-hepatic cava and the recipient left/middle hepatic vein trunk caval excision with veno-venous and portal-venous bypass was employed for FA patients serving as domino liver donors. None of the domino donors experienced any technical problems related to donation or veno-venous and porto-venous bypass. (Azoulay *et al.*, 1999; Raichlin *et al.*, 2009)

3. Conclusion

CHLTx for ATTR is a successful therapy for this disease and can be performed safely, with a acceptable level of morbidity. Given the 10-year survival of 60% with an associated freedom of rejection of 83%, the procedure is consistently curative in patients with ATTR and cardiac involvement. Specific ATTR mutations do not affect outcome. Cardiac allograft rejection after CHLTx is significantly less frequent than with IHTx and may justify less intensive immunosuppression therapy for these patients. In addition calcineurin sparing (sirolimus based) immunosuppression to prevent progressive calcineurin-induced renal damage should be considered in CHLTx recipients.


4. References

- Audard V, Matignon M, Weiss L, *et al.* Successful long-term outcome of the first combined heart and kidney transplant in a patient with systemic AL amyloidosis. *Am J Transplant.* 2009;9:236-40
- Azoulay D, Samuel D, Castaing D, *et al.* Domino liver transplants for metabolic disorders: experience with familial amyloidotic polyneuropathy. *J Am Coll Surg.* 1999;189:584-93
- Barreiros AP, Post F, Hoppe-Lotichius M, *et al.* Liver transplantation and combined liver-heart transplantation in patients with familial amyloid polyneuropathy: a single-center experience. *Liver Transpl.* 2010; 16:314-23
- Befeler AS, Schiano TD, Lissos TW, *et al.* Successful combined liver-heart transplantation in adults: report of three patients and review of the literature. *Transplantation.* 1999;68:1423-7
- Berroeta C, Flament F, Lathyris D, *et al.* Pulmonary embolism: an uncommon cause of dyspnea after heart transplantation. *J Cardiothorac Vasc Anesth.* 2006;20:236-8. Epub 2005 Dec 1

- Brenner DA, Jain M, Pimentel DR, *et al.* Human amyloidogenic light chains directly impair cardiomyocyte function through an increase in cellular oxidant stress. *Circ Res.* 2004;94:1008-10. Epub 2004 Mar 25
- Couetil JP, Houssin DP, Soubrane O, *et al.* Combined lung and liver transplantation in patients with cystic fibrosis. A 4 1/2-year experience. *J Thorac Cardiovasc Surg.* 1995;110:1415-22; discussion 1422-3
- Davies HS, Pollard SG, Calne RY. Soluble HLA antigens in the circulation of liver graft recipients. *Transplantation* 1989;47:524-7
- Detry O, Honore P, Meurisse M, *et al.* Advantages of inferior vena caval flow preservation in combined transplantation of the liver and heart. *Transpl Int.* 1997;10:150-1
- Dey BR, Chung SS, Spitzer TR, *et al.* Cardiac transplantation followed by dose-intensive melphalan and autologous stem-cell transplantation for light chain amyloidosis and heart failure. *Transplantation* 2010 Oct 27;90(8):905-11
- Dispenzieri A, Kyle RA, Gertz MA, *et al.* Survival in patients with primary systemic amyloidosis and raised serum cardiac troponins. *Lancet* 2003;361:1787-9
- Dispenzieri A, Gertz MA, Kyle RA, *et al.* Serum cardiac troponins and N-terminal pro-brain natriuretic peptide: a staging system for primary systemic amyloidosis. *J Clin Oncol.* 2004;22:3751-7
- Dubrey S, Simms RW, Skinner M, Falk RH. Recurrence of primary (AL) amyloidosis in a transplanted heart with four-year survival. *Am J Cardiol.* 1995;76:739-41
- Dubrey S, Mendes L, Skinner M, Falk RH. Resolution of heart failure in patients with AL amyloidosis. *Ann Intern Med.* 1996;125:481-4
- Dubrey SW, Cha K, Anderson J, *et al.* The clinical features of immunoglobulin light-chain (AL) amyloidosis with heart involvement. *Qjm.* 1998;91:141-57
- Dubrey SW, Burke MM, Khaghani A, Hawkins PN, Yacoub MH, Banner NR. Long term results of heart transplantation in patients with amyloid heart disease. *Heart.* 2001;85:202-7
- Dubrey SW, Burke MM, Hawkins PN, Banner NR. Cardiac transplantation for amyloid heart disease: the United Kingdom experience. *J Heart Lung Transplant.* 2004;23:1142-53
- Falk RH, Dubrey SW, Mendes LA, Sancherawala V, Ekery, D CR, Vosburgh E, Skinner M. . The effect of cardiac involvement on the outcome of intravenous melphalan therapy and autologous stem cell rescue for AL amyloidosis. In: Kyle RA GM, eds., ed. *Amyloid and the Amyloidoses: VIIIth International Symposium on Amyloidosis.* Rochester, MN: Parthenon 1998:181-183
- Falk RH. Diagnosis and management of the cardiac amyloidoses. *Circulation.* 2005;112:2047-60.
- Figuera D, Ardaiz J, Martin-Judez V, *et al.* Combined transplantation of heart and liver from two different donors in a patient with familial type IIa hypercholesterolemia. *J Heart Transplant.* 1986;5:327-9
- Garcia-Herola A, Prieto M, Pascual S, *et al.* Progression of cardiomyopathy and neuropathy after liver transplantation in a patient with familial amyloidotic polyneuropathy caused by tyrosine-77 transthyretin variant. *Liver Transpl Surg* 1999;5:246-8
- Gertz MA, Comenzo R, Falk RH, *et al.* Definition of organ involvement and treatment response in immunoglobulin light chain amyloidosis (AL): a consensus opinion from the 10th International Symposium on Amyloid and Amyloidosis, Tours, France, 18-22 April 2004. *Am J Hematol.* 2005;79:319-28

- Gillmore JD, Goodman HJ, Lachmann HJ, *et al.* Sequential heart and autologous stem cell transplantation for systemic AL amyloidosis. *Blood*. 2006;107:1227-9. Epub 2005 Oct 6
- Gonwa TA, Mai ML, Melton LB, *et al.* End-stage renal disease (ESRD) after orthotopic liver transplantation (OLT) using calcineurin-based immunotherapy: risk of development and treatment. *Transplantation* 2001;72:1934-9
- Grazi GL, Cescon M, Salvi F, *et al.* Combined heart and liver transplantation for familial amyloidotic neuropathy: considerations from the hepatic point of view. *Liver Transpl.* 2003;9:986-92
- Hall R, Hawkins PN. Cardiac transplantation for AL amyloidosis. *Bmj*. 1994;309:1135-7
- Hennessey T, Backman SB, Cecere R, *et al.* Combined heart and liver transplantation on cardiopulmonary bypass: report of four cases. 2010; *Can*;57:355-60
- Hosenpud JD, Uretsky BF, Griffith BP, O'Connell JB, Olivari MT, Valantine HA. Successful intermediate-term outcome for patients with cardiac amyloidosis undergoing heart transplantation: results of a multicenter survey. *J Heart Transplant.* 1990;9:346-50
- Hosenpud JD, DeMarco T, Frazier OH, *et al.* Progression of systemic disease and reduced long-term survival in patients with cardiac amyloidosis undergoing heart transplantation. Follow-up results of a multicenter survey. *Circulation*. 1991;84:III338-43
- Kotani N, Hattori T, Yamagata S, *et al.* Transthyretin Thr60Ala Appalachian-type mutation in a Japanese family with familial amyloidotic polyneuropathy. *Amyloid* 2002;9:31-4
- Kpodonu J, Massad MG, Caines A, Geha AS. Outcome of heart transplantation in patients with amyloid cardiomyopathy. *J Heart Lung Transplant.* 2005;24:1763-5
- Kristen AV, Sack FU, Schonland SO, *et al.* Staged heart transplantation and chemotherapy as a treatment option in patients with severe cardiac light-chain amyloidosis. *Eur J Heart Fail.* 2009;11:1014-20
- Kyle RA, Gertz MA. Primary systemic amyloidosis: clinical and laboratory features in 474 cases. *Semin Hematol.* 1995;32:45-59
- Kristen AV, Perz JB, Schonland SO, *et al.* Non-invasive predictors of survival in cardiac amyloidosis. *Eur J Heart Fail.* 2007;9:617-24
- Lacy MQ, Dispenzieri A, Hayman SR, *et al.* Autologous stem cell transplant after heart transplant for light chain (AL) amyloid cardiomyopathy. *J Heart Lung Transplant.* 2008;27:823-9
- Liao R, Jain M, Teller P, *et al.* Infusion of light chains from patients with cardiac amyloidosis causes diastolic dysfunction in isolated mouse hearts. *Circulation*. 2001;104:1594-7
- Luk A, Ahn E, Lee A, Ross HJ, Butany J. Recurrent cardiac amyloidosis following previous heart transplantation. *Cardiovasc Pathol* 2009;19:9
- Maurer MS, Raina A, Hesdorffer C, *et al.* Cardiac transplantation using extended-donor criteria organs for systemic amyloidosis complicated by heart failure. *Transplantation*. 2007;83:539-45
- McMillan RW, Gelder FB, Zibari GB, Aultman DF, Adamashvili I, McDonald JC. Soluble fraction of class I human histocompatibility leukocyte antigens in the serum of liver transplant recipients. *Clin Transplant* 1997;11:98-103
- Mignot A, Bridoux F, Thierry A, *et al.* Successful heart transplantation following melphalan plus dexamethasone therapy in systemic AL amyloidosis. *Haematologica*. 2008;93:e32-5
- Nakamura M, Satoh M, Kowada S, *et al.* Reversible restrictive cardiomyopathy due to light-chain deposition disease. *Mayo Clin Proc.* 2002;77:193-6

- Nardo B, Beltempo P, Bertelli R, *et al.* Combined heart and liver transplantation in four adults with familial amyloidosis: experience of a single center. *Transplant Proc* 2004;36:645-7
- Ojo AO, Held PJ, Port FK, *et al.* Chronic renal failure after transplantation of a nonrenal organ. *N Engl J Med* 2003;349:931-40
- Pilato E, Dell'Amore A, Botta L, Arpesella G. Combined heart and liver transplantation for familial amyloidotic neuropathy. *Eur J Cardiothorac Surg.* 2007;32:180-2
- Raichlin E, Khalpey Z, Kremers W, *et al.* Replacement of calcineurin-inhibitors with sirolimus as primary immunosuppression in stable cardiac transplant recipients. *Transplantation.* 2007;84:467-74
- Raichlin E, Bae JH, Khalpey Z, *et al.* Conversion to sirolimus as primary immunosuppression attenuates the progression of allograft vasculopathy after cardiac transplantation. *Circulation.* 2007;116:2726-33
- Raichlin E, Daly RC, Rosen CB, *et al.* Combined heart and liver transplantation: a single-center experience. *Transplantation* 2009;88:219-25
- Sanchorawala V, Skinner M, Quillen K, Finn KT, Doros G, Seldin DC. Long-term outcome of patients with AL amyloidosis treated with high-dose melphalan and stem-cell transplantation. *Blood* 2007;110:3561-3
- Sattianayagam PT, Gibbs SD, Pinney JH, *et al.* Solid organ transplantation in AL amyloidosis Outcomes of heart transplantation for cardiac amyloidosis: subanalysis of the Spanish registry for heart transplantation. *Am J Transplant.* 2010;10(9):2124-31
- Sharma P, Perri RE, Sirven JE, *et al.* Outcome of liver transplantation for familial amyloidotic polyneuropathy. *Liver Transpl* 2003;9:1273-80
- Shaw BW, Jr., Bahnson HT, Hardesty RL, Griffith BP, Starzl TE. Combined transplantation of the heart and liver. *Ann Surg* 1985;202:667-72
- Skinner M, Anderson J, Simms R, *et al.* Treatment of 100 patients with primary amyloidosis: a randomized trial of melphalan, prednisone, and colchicine versus colchicine only. *Am J Med.* 1996;100:290-8
- Skinner M, Sanchorawala V, Seldin DC, *et al.* High-dose melphalan and autologous stem-cell transplantation in patients with AL amyloidosis: an 8-year study. *Ann Intern Med.* 2004;140:85-93
- Stahl RL, Duncan A, Hooks MA, Henderson JM, Millikan WJ, Warren WD. A hypercoagulable state follows orthotopic liver transplantation. *Hepatology* 1990;12:553-8
- Stangou AJ, Hawkins PN, Heaton ND, *et al.* Progressive cardiac amyloidosis following liver transplantation for familial amyloid polyneuropathy: implications for amyloid fibrillogenesis. *Transplantation* 1998;66:229-33
- Valantine HA, Billingham ME. Recurrence of amyloid in a cardiac allograft four months after transplantation. *J Heart Transplant.* 1989;8:337-41
- Vogel W, Steiner E, Kornberger R, *et al.* Preliminary results with combined hepatorenal allografting. *Transplantation* 1988;45:491-3
- Westermarck P, Sletten K, Johansson B, Cornwell GG, 3rd. Fibril in senile systemic amyloidosis is derived from normal transthyretin. *Proc Natl Acad Sci U S A* 1990;87:2843-5
- Yazaki M, Tokuda T, Nakamura A, *et al.* Cardiac amyloid in patients with familial amyloid polyneuropathy consists of abundant wild-type transthyretin. *Biochem Biophys Res Commun* 2000;274:702-6



Amyloidosis - An Insight to Disease of Systems and Novel Therapies

Edited by Dr. Işıl Adadan Güvenç

ISBN 978-953-307-795-6

Hard cover, 194 pages

Publisher InTech

Published online 16, November, 2011

Published in print edition November, 2011

Amyloidosis is a benign, slowly progressive condition characterized by the presence of extracellular fibrillar proteins in various organs and tissues. It has systemic or localized forms. Both systemic and localized amyloidosis have been a point of interest for many researchers and there have been a growing number of case reports in the literature for the last decade. The aim of this book is to help the reader become familiar with the presentation, diagnosis and treatment modalities of systemic and localized amyloidosis of specific organs or systems and also cover the latest advancements in therapy.

How to reference

In order to correctly reference this scholarly work, feel free to copy and paste the following:

Eugenia Raichlin and Sudhir S. Kushwaha (2011). Cardiac and Multi-Organ Transplantation in Patients with Amyloidosis, *Amyloidosis - An Insight to Disease of Systems and Novel Therapies*, Dr. Işıl Adadan Güvenç (Ed.), ISBN: 978-953-307-795-6, InTech, Available from: <http://www.intechopen.com/books/amyloidosis-an-insight-to-disease-of-systems-and-novel-therapies/cardiac-and-multi-organ-transplantation-in-patients-with-amyloidosis>

INTECH
open science | open minds

InTech Europe

University Campus STeP Ri
Slavka Krautzeka 83/A
51000 Rijeka, Croatia
Phone: +385 (51) 770 447
Fax: +385 (51) 686 166
www.intechopen.com

InTech China

Unit 405, Office Block, Hotel Equatorial Shanghai
No.65, Yan An Road (West), Shanghai, 200040, China
中国上海市延安西路65号上海国际贵都大饭店办公楼405单元
Phone: +86-21-62489820
Fax: +86-21-62489821

© 2011 The Author(s). Licensee IntechOpen. This is an open access article distributed under the terms of the [Creative Commons Attribution 3.0 License](https://creativecommons.org/licenses/by/3.0/), which permits unrestricted use, distribution, and reproduction in any medium, provided the original work is properly cited.

IntechOpen

IntechOpen