

We are IntechOpen, the world's leading publisher of Open Access books Built by scientists, for scientists

6,900

Open access books available

186,000

International authors and editors

200M

Downloads

Our authors are among the

154

Countries delivered to

TOP 1%

most cited scientists

12.2%

Contributors from top 500 universities



WEB OF SCIENCE™

Selection of our books indexed in the Book Citation Index
in Web of Science™ Core Collection (BKCI)

Interested in publishing with us?
Contact book.department@intechopen.com

Numbers displayed above are based on latest data collected.
For more information visit www.intechopen.com



Pulmonary Manifestations of Amyloidosis

Mark E. Lund^{1,2}, Priya Bakaya² and Jeffrey B. Hoag^{1,2}

¹*Cancer Treatment Centers of America, Eastern Regional Medical Center,*

²*Drexel University College of Medicine,
Philadelphia, PA,
USA*

1. Introduction

Amyloidosis is a disease characterized by the deposition of abnormal proteins in extracellular tissue. The deposits originate from serum derived or locally produced proteins. (Sipe et al., 2010) The term “amyloid” was first used by Rudolph Virchow in 1854. (Saleiro et al., 2008) According to the Nomenclature Committee of the International Society of Amyloidosis 2010 recommendations, an amyloid fibril protein must occur in tissue deposits and exhibit affinity for Congo red and green birefringence when viewed by polarization microscopy. Furthermore, the protein must have been unambiguously characterized by protein sequence analysis (DNA sequencing in the case of familial diseases). In this chapter, we will focus on the pulmonary manifestations of amyloid. We will discuss the classification, presentation, symptoms, diagnostic testing and therapeutic options with regards to amyloid in the respiratory tract.

Amyloidosis had been classified over the years based on the site of deposition and presence or absence of other diseases. (Thompson & Citron, 1983) The term “Generalized” or “Systemic” had been used to describe deposition in multiple anatomic sites and “localized” used to describe deposition in one anatomic site. The term “secondary” used to describe patients with coexistent disease like multiple myeloma and “primary” for patients with no such coexistent disease. (Utz et al., 1996)

2. Classification of pulmonary amyloidosis

Amyloid in the respiratory tract has been classified by authors at The Mayo Clinic as associated with systemic amyloidosis and localized pulmonary disease. (Utz et al., 1996) The most common cause of the respiratory amyloid disease is secondary to systemic AL Amyloidosis which accounts for up to 80% of pulmonary amyloid. (Pitz et al., 2006) Moreover, it has been reported that 88% of patients with systemic amyloid have pulmonary disease. (Smith et al., 1979)

Amyloidosis localized to the respiratory tract was first recognized by Lesser in 1877. (Lesser, 1877) Amyloidosis at present is best classified by the protein fibrils and then by the location of sites involved clinically. To date, there are 27 known extracellular fibril proteins identified in humans. Table 1 lists some of the common protein subunits. Clinically there are three broad classifications of pulmonary involvement. The amyloid deposition may predominantly

involve the tracheobronchial tree with nodules or submucosal infiltration. There can also be predominant interstitial localization. A third presentation is with single or multiple pulmonary parenchymal nodular deposits. A combination of radiographic and bronchoscopic studies provides this classification of pulmonary amyloidosis. Interestingly, it is uncommon for interstitial and tracheobronchial involvement to develop in the same patient.

Classification	Amyloid Protein Fibril Type	Symptoms	Imaging	Treatment
Nodular	AL	Incidental Finding Cough Dyspnea	Round nodules with sharp margins, subpleural and peripheral, may be cavitary, can be PET avid	Observation Local treatment Bronchoscopic (if in larynx) Lobectomy (very rarely)
Tracheo-bronchial	AL, Rare AA	Cough Dyspnea Hemoptysis	Tracheal and bronchial wall thickening, post-obstructive pneumonia, atelectasis	Observation Local treatment with laser therapy External Beam Radiation Surgery (rarely)
Diffuse Alveolar-Septal	AL, AA, ATTR	Cough Dyspnea Lethargy	Interlobular septal thickening, traction bronchiectasis	Usually requires systemic treatment with chemotherapy and/or stem cell transplant
Adenopathy	AL	Incidental Finding Compression of the airway Wheezing Cough Dyspnea	Extrathoracic nodes more common, often calcify with an eggshell or popcorn pattern	Observation Bronchoscopic (Stenting) Surgical (rarely)
Pleural Effusion	AL	Dyspnea, cough, lethargy	Opacity on CXR Pleural studing on CT	Thoracentesis Chest tube PleurX catheter Chemical or Mechanical pleurodesis

Table 1. Classification of Pulmonary Amyloidosis with Commonly Encountered Symptoms, Radiographic Findings, and Treatment Modalities

2.1 Tracheobronchial amyloidosis

Pulmonary nodules of amyloid deposits can be found in the larynx, tracheobronchial tree and lung parenchyma. Discrete nodular deposits in the larynx were described in 1919 (New, 1919). Tracheobronchial amyloidosis is characterized by deposits in the trachea and large bronchi. This is the most common form of primary pulmonary amyloidosis. (Sugihara et al., 2006) Isolated tracheal disease is very rare with less than 20 cases reported in the literature as of 2006. (Sharma & Katlic, 2006) It typically presents in the fifth and sixth decade of life and is slightly more common in females than males. (Berk et al., 2002) As previously mentioned, tracheobronchial amyloid deposition can occur in two forms: nodular or unifocal disease and diffuse submucosal disease. Tracheobronchial amyloidosis has been associated with tracheobronchopathia osteochondroplastica (TBO) by some authors. (Jones & Chatterji, 1977) Tracheobronchopathia osteochondroplastica is a disorder characterized by the deposition of calcified or cartilaginous submucosal nodules in the airways. (Capizzi et al., 2000) The uncertainty is related to the fact that most patients with TBO do not show evidence of amyloid deposition. (Mimori et al., 1998)

In a retrospective review of a series at The Mayo Clinic of 17 patients with biopsy proven tracheobronchial amyloidosis concluded that this form of pulmonary amyloid appeared to be a type of localized amyloid, with protein fibril deposition only present in the tracheobronchial tree. (Utz et al., 1996) This form is quite rare with less than 150 cases published in the medical literature. Although tracheobronchial amyloidosis often follows a relatively stable course, it can present with significant morbidity in patients with extensive airway involvement. It may require repeated therapeutic bronchoscopies in an attempt to prevent progression of airway involvement. Three patterns of airway involvement have been described by Berk et al: (1) proximal, (2) mid or main bronchial, and (3) distal disease. (Berk et al., 2002) Although tracheobronchial amyloidosis is most commonly caused by the AL form of amyloid fibril deposition, AA amyloidosis has also been reported in a case of tracheobronchial amyloidosis complicating mediastinal fibrosis. (Hoag & Yung, 2008)

2.2 Diffuse interstitial amyloid

Diffuse amyloid deposition in the lung parenchyma is usually associated with systemic AL amyloidosis. It is characterized by widespread amyloid deposition involving small vessels and the interstitium. There is little association between the extent of amyloid deposition in the lung and level of functional compromise. A Mayo clinic series included 35 patients who had pulmonary involvement with primary systemic amyloidosis. Celli and coauthors reported case series of 12 patients with AL lung disease, of which only 1 patient his clinical outcome dictated by his pulmonary involvement. (Celli, 1978) Cordier and colleagues reported that only 10% of patient deaths were due to AL lung disease in their series. (Cordier, 1986) Pathologists at John Hopkins have examined the association between cardiac and pulmonary amyloid. (Smith et al., 1979) They found that all patients with pulmonary amyloid deposition had cardiac amyloid disease. They concluded that histologic and clinical pulmonary disease in AL patients was principally a marker of severe cardiac infiltration.

2.3 Nodular amyloidosis

Amyloid nodules in the lung parenchyma are usually incidental findings on chest radiographs and usually need to be differentiated from neoplastic lesions. These nodules are typically located peripherally or subpleurally, and they can also be bilateral in some cases. If

these lesions are located more centrally, airflow limitation may occur leading to symptomatic presentations. Moreover, these amyloid lesions may cavitate. (Cordier et al., 1986) AL amyloidosis is a well recognized complication of Sjogren's syndrome and is most often associated with localized nodular pulmonary amyloidosis. An association with benign hypergammaglobulinemic purpura has been reported in one patient. (Bignold et al., 1980)

3. Other manifestations of thoracic amyloidosis

3.1 Adenopathy

Hilar and mediastinal adenopathy are commonly associated with the AL form of systemic amyloidosis, and rarely adenopathy is present in localized pulmonary disease. (Lachmann & Hawkins, 2006) The majority of patients with amyloid-associated lymphadenopathy have detectable circulating monoclonal immunoglobulin which are typically associated with very low grade lymphoplasmacytic lymphoma or Waldenstrom's macroglobulinemia. (Plockinger et al., 1993) Plockinger et al. reported a case of nodular amyloidosis of hilar lymph nodes with no evidence of a paraprotein immunoglobulins or light chains present on immunoelectrophoretic analyses of the plasma and urine. Amyloid infiltrated nodes frequently calcify in a "popcorn" pattern or an "eggshell" conformation. (Gross, 1981)

3.2 Pleural effusions

Pleural effusions have also been reported in patients with systemic amyloid disease. The incidence of pleural effusion in amyloidosis is not known. Effusions can be unilateral or bilateral, and they can present with either exudative or transudative chemistries. (Berk et al., 2003) One of the first reports of amyloid-associated pleural effusion included five patients by Kavuru and colleagues. (Kavuru et al., 1990) These authors found that pleural effusions in the majority of their patients (60% in their series) were believed related to either congestive heart disease or nephrotic syndrome, and only 40% of pleural effusions were "idiopathic". Despite this they found that even those patients with transudative effusions had pleural infiltration with amyloid on biopsy. The Amyloid Program at Boston University reported their 7 year experience with 636 patients. (Berk et al., 2003) Thirty five patients in this series (6%) had large recurrent pleural effusions along with another 10-15% with less significant effusions. They compared patients with primary systemic amyloidosis and coincident cardiomyopathy without pleural effusions and patients with recurrent large pleural effusions. They noted exudative chemistries in pleural fluid of 37% of their patients along with chylothorax in another two patients. In contrast to the conclusions drawn by Kavuru et al., their hypothesis was that direct amyloid infiltration of the parietal pleural was responsible for large recurrent pleural effusions. Their claim was supported by thoracoscopic descriptions of pleural studding and histologic evidence of amyloid infiltrating pleural surfaces on biopsy. (Kavuru et al., 1990) After extensive comparisons between the two groups using echocardiography, they concluded that cardiac dysfunction alone was not sufficient to produce the pleural effusions in their cohort. The paucity of chylous effusions in patients with AL amyloid despite the propensity of mediastinal lymphadenopathy points towards direct amyloid infiltration of lymph nodes by amyloid as the cause of chylothorax as opposed to a compression of lymph nodes. Although uncommon, pleural effusions in patients with primary pulmonary amyloidosis can be hemorrhagic. (BoydKing et al., 2009)

4. The clinical presentation of pulmonary amyloidosis

Pulmonary amyloid may present with symptoms or may be found as an incidental finding on thoracic imaging. Patients present to pulmonologists in a number of ways: patients with systemic amyloidosis may present with respiratory symptoms; localized forms of amyloid may be detected incidentally on imaging or biopsy; and patients may present with respiratory symptoms that warrant pulmonary workup leading to the diagnosis of amyloidosis. (Lachmann & Hawkins, 2006; Sipe et al., 2010; Thompson & Citron, 1983) Tracheobronchial amyloidosis usually presents in fifth decade of life with symptoms of cough, dyspnea, wheezing, and hemoptysis. (Berk et al., 2002) In addition, hoarseness is frequently reported.

The most common symptoms of amyloid involvement with the respiratory system are cough, wheezing, dyspnea on exertion, and hemoptysis; none of which are uniquely specific to the diagnosis of pulmonary amyloidosis. One elderly male presented with diffuse alveolar hemorrhage. (Shenin et al., 2010) Amyloid nodules in the lung parenchyma are most often asymptomatic and are usually incidental findings on imaging studies; however, they sometimes can produce space occupying effects, most often if they limit either air or blood flow in the lungs. These nodules tend to calcify, and sometimes they may cavitate. They can cause luminal narrowing of the airways and thus may lead to post obstructive atelectasis and/or pneumonia. Diffuse alveolar-septal amyloidosis related to systemic AL disease may present with symptoms of dyspnea or even more frightening symptoms of hemoptysis due to dissection of pulmonary arteries infiltrated by amyloid protein deposits (Cools et al., 1996; Road et al., 1985) or massive pulmonary embolism related to thrombosis of inferior vena cava. Mediastinal or hilar adenopathy is less common than extrathoracic adenopathy in patients with systemic AL disease. However, these patients may sometimes present with cervical nodes that may enlarge, become tender or recede in periods mimicking sarcoidosis. Pleural effusions in patients with amyloidosis will cause dyspnea and may at times require repeated thoracenteses to relieve symptoms.

5. Diagnosis of pulmonary amyloid

5.1 General considerations for diagnosis

When systemic amyloid disease is present, consideration for pulmonary evaluation for amyloid involvement should be based upon symptoms and clinical suspicion. The delay from time of presentation to the diagnosis of pulmonary involvement has been up to 17 months in some series. (O'Regan et al., 2000) In a patient with systemic amyloidosis, exercise limitation or cough should prompt an evaluation for lung involvement. In the setting of isolated pulmonary disease, amyloid is often low on the differential diagnosis. Pulmonary amyloidosis can be evaluated with plain films, computed tomography, bronchoscopy and pulmonary function testing. Figure 1 depicts an algorithm of a diagnostic approach for patients with systemic amyloidosis.

5.2 Radiographic evaluation

As previously described, the nodular form amyloidosis is most often an incidental finding on thoracic imaging. The plain chest radiograph can be normal in as many as half of patients with pulmonary nodular amyloidosis. (O'Regan et al., 2000) Amyloid nodules are generally described as rounded with sharp, discreet margins, and they are occasionally cavitory

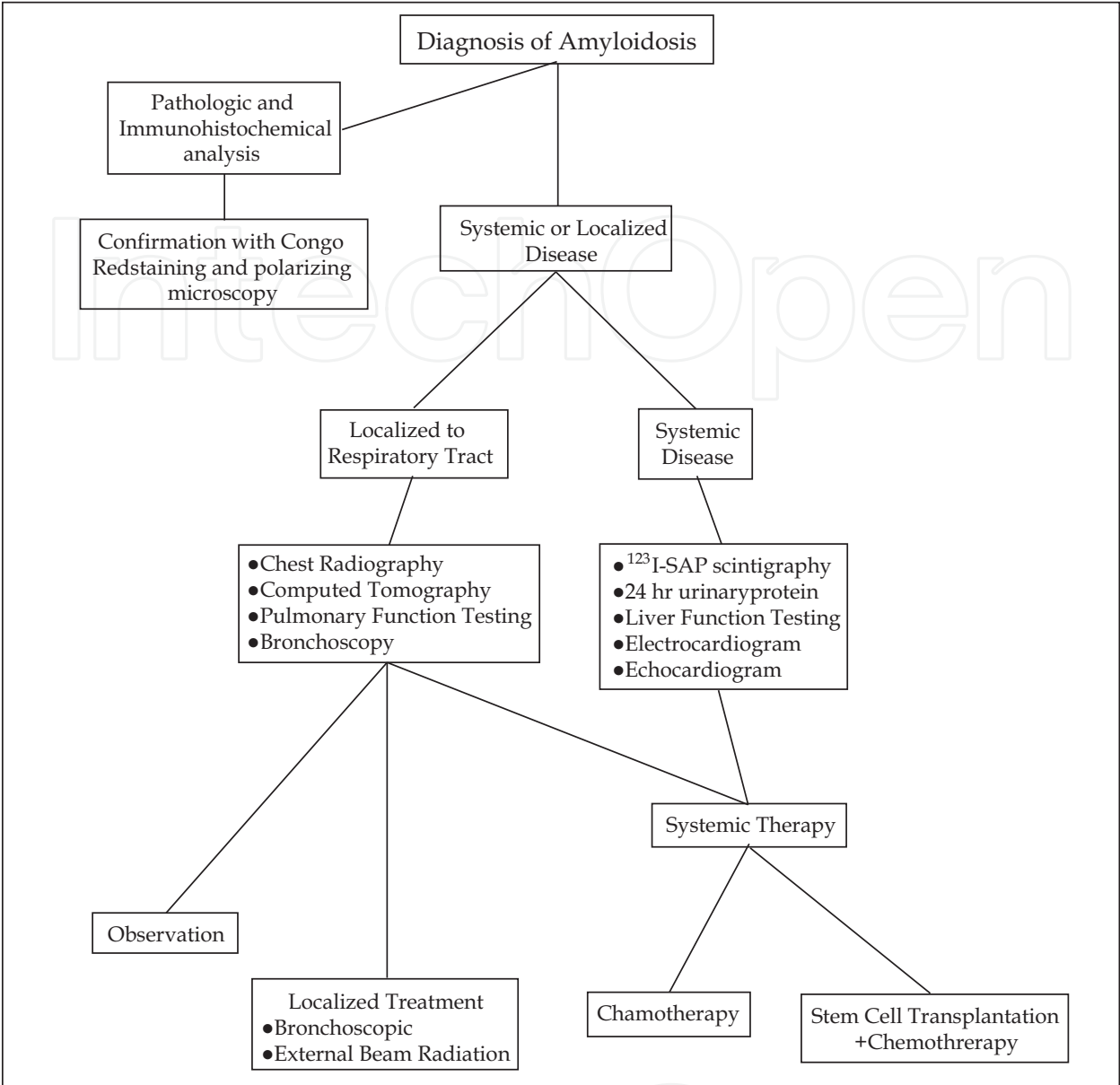


Fig. 1. Flow diagram of a decision pathway for the evaluation and treatment of respiratory amyloidosis

in appearance. One case report found that a lesion of amyloid measured 282 Hounsfield units, which is significantly less dense than blood. (M’Rad et al., 1988) Pulmonary nodular amyloidosis are predominantly subpleural and peripheral with a random distribution. Imaging of patients with diffuse alveolar-septal disease may show infiltrative opacities on chest plain radiographs. In systemic amyloidosis, diffuse interstitial disease is most common. This may be reticular nodular on computed tomography imaging. Interlobular septal thickening and diffuse irregular lines with some honeycombing can be seen at the lung bases peripherally, and traction bronchiectasis can also be seen. Some report that diffuse cystic changes may predominate. (Wink, 2003)

Tracheal and bronchial wall thickening or discrete tumor masses may be a CT finding of tracheobronchial amyloid. The presence of multifocal masses with calcification should prompt a differential diagnosis of carcinoma, Wegener’s Granulomatosis, relapsing

polychondritis, tracheobronchial tuberculosis, pulmonary hyalinizing granuloma, tracheobronchopathia osteochondroplastica along with tracheobronchial amyloidosis. (Bhadra et al., 2010; Carter & Patchefsky, 1998; Gibbaoui et al., 2004) Circumferential calcification involving the membranous airway should suggest amyloidosis as other forms of airway thickening do not involve this portion.

Positron emission tomography (PET) may demonstrate increased uptake of ^{18}F -fluorodeoxyglucose (FDG) in patients with nodular amyloidosis. (Currie et al., 2005; Kung et al., 2003; Seo et al., 2010) From the studies of PET with pathology confirming amyloidosis, the standardized uptake value (SUV) ranged from 1.8 to 6.81, suggesting the need for biopsy to exclude malignancy. Coincident pulmonary nodular amyloid and adenocarcinoma has been reported in a patient with systemic AL amyloidosis. (Miyazaki et al., 2011) An uncharacteristic speculated appearance of the nodule in question in this case highlights the need for careful review of thoracic imaging in conjunction with a high index of suspicion. Coincident carcinoma and amyloid deposits have been described in thyroid medullary carcinoma. (Westermarck et al., 2007)

5.3 Pulmonary function testing

Pulmonary function testing (PFT) in patients with pulmonary involvement of amyloidosis is similarly variable due to the variety of presentations. Overall, pulmonary functions can be normal or exhibit obstructive or restrictive disease. When tracheobronchial amyloidosis is present, the most common finding is airflow limitation as demonstrated by a reduced ratio of forced expiratory volume in the 1st second (FEV_1) to forced vital capacity (FVC) of less than 70%. The severity is dependent on the degree and location of amyloid deposition. In a series of patients with tracheobronchial amyloidosis from Boston, those with proximal disease tended to have more severe airflow limitation than those with more distal disease, although both groups had significant air trapping present with elevated residual volumes. (O'Regan et al., 2000) With the nodular form of pulmonary amyloidosis, direct compression of central airways may lead to obstructive patterns on PFTs. Evidence of a fixed upper airway obstruction not only suggests central airway disease but also portends a higher probability of progressive central obstructive disease. (Bhadra et al., 2010)

Restriction may be present as would be expected in patients with significant pleural effusion, or in very severe cases of diffuse alveolar-septal disease. Diffusing capacity for carbon monoxide is most often preserved.

5.4 Diagnostic bronchoscopic findings

The bronchoscopic findings of pulmonary amyloidosis vary with the classification of disease. In patients with interstitial or pulmonary nodular disease the endobronchial appearance on bronchoscopy may be entirely normal. In contradistinction to the interstitial variety, those with tracheobronchial amyloidosis commonly have significant visible pathology. The lesions of tracheobronchial amyloid can be nodular, sessile, or polypoid. The sessile lesions have been described as hard yellow plaques that may be expansive or thinner longitudinal irregularities. Cobblestoning of the mucosa may be present. The sessile lesions may cause significant airway stenosis, and these regions of stenosis can be diffuse.

The nodules or polypoid lesions may suggest endoluminal carcinoma to both the experienced and inexperienced bronchoscopist. These nodules are usually firm, non mobile, and covered with hypervascular mucosa. Because of the hypervascularity in conjunction with the infiltrated submucosa, the endobronchial lesions in tracheobronchial amyloidosis

are quite friable, and bleed easily with minimal bronchoscopic contact. (Hoag & Yung, 2008) In contradistinction to tracheobronchopathia osteochondroplastica (TBO), the membranous trachea and mainstem airways are not spared. Tracheobronchial amyloidosis was associated with TBO in 22% in one series. (Piazza et al., 2003)

Ultimately, the diagnosis of pulmonary amyloidosis requires histologic confirmation. An excellent overview of the pathologic features of pulmonary amyloidosis has been published. (Katzenstein, 1997) Congo red staining that produces green birefringence under polarized light remains the gold standard for diagnosis. Classic teaching is that these lesions have a tendency to bleed. An increased risk of hemorrhage during biopsies of amyloidotic tissues may result from increased fragility of involved blood vessels, reduced elasticity of tissues and rarely to an acquired deficiency of clotting factors 9 or 10. So while endolumenal forceps biopsy is required, preparation for potential airway bleeding is advisable. Strange et al. reported on the fatal hemorrhage and air embolism complicating a routine transbronchial biopsy of a patient with pulmonary amyloidosis. (Strange et al., 1987) Treatment with low level Neodymium: Yttrium Aluminum Garnet (Nd:YAG) laser or argon plasma coagulation (APC) can be effective in controlling bleeding from the central airway amyloid lesion. Both approaches offer non contact therapy. Application of electrocautery can create rebleeding by disruption of the coagulum. The non-contact therapies (APC and Nd:YAG Laser) does not disrupt the bleeding site and remove the coagulum created by its application. Pretreatment with endobronchial epinephrine injections into the lesions may decrease the bleeding risk.

Effective biopsy may be obtained by the use of Wang needle or endobronchial forceps. Biopsy of the lesions may be difficult due to calcifications, and small biopsy specimens are open to sampling errors. False positive results also do occur in routine practice, usually as a result of poor Congo red staining. A confirmatory stain with Thioflavine T, which fluoresces yellow-green, may be helpful. (Saleiro et al., 2008) Any bronchoscopic finding suggesting tracheobronchopathia osteochondroplastica should be stained with Congo red due to the similarity of endobronchial appearance. (Bhadra et al., 2010) When the tissue is too calcified or when the operator feels uncomfortable with handling larger volume bleeding open surgical biopsy may be warranted.

Like any tumor mass, malignant or non-malignant, post obstructive pneumonia can develop in pulmonary amyloidosis. Protected brush samples or clean bronchoalveolar lavage for culture should be obtained when there is a high grade stenosis or evidence of mucopurulent drainage.

Once histologic evaluation with Congo red staining has been performed, immunochemistry to determine protein fibril type should be performed. Anatomical and functional evaluation of the various organs involved in systemic amyloidosis should also be performed. (Hawkins et al., 1990) Radiolabeled Serum Amyloid P (SAP) component localizes specifically to amyloid deposits *in vivo* in proportion to the amount of amyloid present and enables diagnosis, quantification and monitoring of amyloid to be performed scintigraphically. (Hazenberget al., 2007)

6. Follow up of the patient with pulmonary amyloid

Several non-invasive methods of surveilling the progress of disease include computed tomography imaging and pulmonary function testing, especially serial spirometry. Proximal disease can present as pattern of fixed airway obstruction on flow volume loops, (Lachmann et al., 2006) or progression of disease may be apparent with progression flow limitation as

demonstrated by decreasing FEV₁. Radiographic imaging may show areas of atelectasis or hyperinflation due to progression of obstructing endobronchial disease. Due to the relative rarity of this condition the most appropriate method of surveillance is not known.

7. Management of pulmonary amyloidosis

The outcome of patients with pulmonary amyloidosis reported in the literature is variable. From a series of 21 patients with primary pulmonary amyloidosis, the median survival was 16 months and no patients were alive at five years. (Utz et al., 1996) The survival of this cohort was much shorter than would be expected in comparison to patients with systemic amyloidosis without pulmonary involvement. As some have suggested that respiratory failure is rarely the direct cause of death in patients with amyloidosis, it seems that its presence is a marker of more severe disease. In contrast, in another series over 15 years with 10 patients reported survival averaged 8 years. (O'Regan et al., 2000) In this series death was predominantly caused by respiratory complications.

Due to the variability of amyloid involvement in the pulmonary system, the treatment for respiratory amyloidosis ranges from observation to bronchoscopic or surgical resection based on severity and symptomatology. Management decisions are mostly based on an individual basis. Systemic amyloidosis can be treated with chemotherapy while localized forms are typically treated with local interventions.

7.1 Chemotherapy

Infiltrative and systemic disease has been amenable to chemotherapy with oral melphalan and prednisone. (Kyle et al., 1997) A prospective study done at The Mayo Clinic in patients with systemic amyloidosis showed that combination therapy with melphalan, prednisone and colchicine or melphalan and prednisone resulted in prolonged survival compared to colchicine alone. The median duration of survival after randomization was 8.5 months in the colchicine group, 18 months in the group assigned to melphalan and prednisone, and 17 months in the group assigned to melphalan, prednisone, and colchicine ($p < 0.001$). (Wechalekar et al., 2008) The National Amyloidosis Center in The United Kingdom has divided its treatment strategies for systemic AL disease into low dose, intermediate and high dose regimens. They recommend one of the intermediate dose regimens involving risk-adapted CTD (cyclophosphamide, thalidomide and dexamethasone) or oral mel-dex (melphalan, dexamethasone) as first line therapy, and autologous stem cell transplantation as an alternative treatment. (Cohen et al., 2007) Stem cell transplantation has been attempted with variable success in more severe disease. Recent phase 2 trials in systemic amyloidosis showed that risk-adapted Stem Cell Transplant with adjuvant thalidomide and dexamethasone is feasible and results in low treatment related mortality and high hematological and organ response rates in patients. (Cohen et al., 2007) There are several ongoing trials at amyloid centers in the United States and internationally, and physicians are encouraged to refer their patients to be enrolled in these studies in order to determine best practices.

7.2 Therapeutic bronchoscopy

In light of poor responses of tracheobronchial amyloid to systemic therapy, the majority of these patients will require endobronchial therapy. Bronchoscopic therapies remain the key to airway management in these patients.

Ablative therapy with Neodymium: Yttrium Aluminum Garnet (Nd:YAG) or Carbon Dioxide (CO₂) laser has been fairly successful. It appears that amyloid is very sensitive to photoablation. (Saleiro et al., 2008) Nd:YAG laser therapy is the most commonly utilized and is not only ablative but has significant hemostatic effects which is of particular benefit in these friable lesions. Laser ablation is the standard of care for endobronchial amyloidosis. In a retrospective series of 32 patients over 19 years, sixteen had persistent asymptomatic endolumenal disease. (Piazza et al., 2003) Two patients had endolumenal procedures with subsequent requirement of surgical resection. Each patient had no evidence of recurrent endolumenal amyloid after 5 to 8 years. Herman et al. reported on 13 cases of tracheobronchial amyloid successfully treated with Nd:YAG laser. (Herman et al., 1985) Follow up of another patient with CT imaging showed stabilization of the lesions after laser resection. (M'Rad et al., 1988) In a series by Diaz-Jimenez three of 11 laser ablations required termination because of significant hemorrhage. (Diaz-Jimenez et al., 1999)

In addition to photoablative strategies, cryotherapy has also been utilized to treat tracheobronchial amyloidosis. (Maiwand et al., 2001) Like other endolumenal therapies, multiple treatments (21 procedures over an 11 year follow up) over the patient's disease course are often required.

Rigid bronchoscopy has been utilized to mechanically debulk the amyloid lesions and for serial dilation of stenotic airways. In addition, the rigid bronchoscope has been used to help with potential bleeding when undergoing biopsy or laser photoablation. Placement of silicone stents has been utilized in conjunction with the ablative therapies to help prolong the airway stability. (Yang et al., 2003)

The use of airway stents after dilation may also be considered in select patients. Serial therapeutic bronchoscopies are not uncommon. (Gibbaoui et al., 2004) If large mediastinal amyloid masses or lymphadenopathy cause central airway obstruction airway stenting is an option. As in all benign airways disease it is always preferential to implant a silicone stent. If a self expanding metallic stent is the only option, the authors recommend a fully covered stent. Operator experience should not be the determinant of the type of stent placed. Because of the complex nature of these patients, the high risk of significant bleeding, and the potential for repeated procedural requirements, it is recommended that these patients be referred to a formally trained interventional pulmonologist or thoracic surgeon with significant experience in managing high grade central airway obstruction.

Localized tracheobronchial amyloidosis can cause post obstructive pneumonia. (Daniels et al., 2007) When evidence suggests a post obstructive state, appropriate empiric antibiotics should be started. Once bronchoscopic cultures are obtained, a strategy of proper de-escalation of therapy should be employed based upon the culture results.

7.3 Radiation therapy

External beam radiotherapy has been successfully utilized in tracheobronchial amyloidosis in a patient believed not to be a candidate for endolumenal therapy due to the diffuse nature of the airways disease. (Monroe et al., 2004) A total of 24 Gy was delivered in 12 fractions, and colchicine was given as an adjunctive therapy. Improvements were measured by sequential pulmonary function testing, radiographic imaging, bronchoscopic evaluation, and performance status.

Kurrus et al. published a case report demonstrating a benefit of external beam radiation (20 Gy in 10 fractions) in causing local response in a patient with localized tracheobronchial disease. (Kurrus et al., 1998) The authors noted decreased thickness of the airway wall and

less friable and erythematous airway post radiation on a subsequent bronchoscopy. They treated the patient based on the hypothesis that plasma cells that secrete amyloidogenic protein are radiosensitive. Other hypotheses proffered include radiation injures cells other than plasma cells that may secrete amyloidogenic proteins, and free radicals generated by radiation may modify and enhance the degradation of amyloid protein deposits. Combined endobronchial and radiation therapy have demonstrated a similar beneficial effect. (Kalra et al., 2001). The authors know of no reports utilizing high dose rate brachytherapy for endobronchial disease. It stands to reason that this too would be a potentially viable option.

7.4 Pleural drainage

Large recurrent pleural effusions in patients with amyloidosis will often require repeated thoracenteses followed by pleurodesis. (Berk et al., 2003; Berk et al., 2005) In a case series reporting on 35 patients with recurrent amyloid pleural effusions at Boston University, chest tubes were placed in 18 patients after a failure of diuresis and intermittent thoracenteses. Seven patients had the chest tube removed without chemical pleurodesis because of unremitting large volume drainage. Eight patients underwent talc slurry pleurodesis via chest tube with symphysis achieved in those with output less than 100 ml/day while in those patients with more than 200 ml/day, the pleurodesis failed uniformly. Video-assisted thoracoscopic surgery with talc insufflation achieved success in 2 patients, and another 2 patients had PleurX™ catheters placed for continued intermittent drainage.

8. Conclusions

In conclusion, although amyloid in the respiratory tract is not a common occurrence, physicians should be aware of the various manifestations. Symptoms of pulmonary amyloidosis are very non specific and hence require a high degree of clinical suspicion. The workup should include a complete physical examination, pulmonary function testing, appropriate clinical imaging followed by biopsies and pathology confirmation of amyloid. The treatment strategy needs to be individualized to the particular patient's clinical status and symptomatology, and may range from close observation to locally directed and systemic therapeutic options. Airway interventions, including debulking of amyloidomas with rigid bronchoscopy, laser photoablation, or airway stents should be performed by an experienced interventional pulmonologist or thoracic surgeon. This will help reduce the risks of these therapies and allow the most expansive treatment options in a rare condition with un-defined best practices.

Future therapies will focus on strategies that involve preventing formation or propagation of insoluble beta-pleated sheets and/or enhance their degradation. Two ubiquitous molecules, serum amyloid P (SAP) and heparin sulfate proteoglycan (HSP), promote beta pleated sheet formation and inhibition of proteolytic degradation. (Gillmore et al., 2010) Drugs that target these molecules may be of interest in the future.


9. References

- Berk JL, O'Regan A, Skinner M. (2002). Pulmonary and tracheobronchial amyloidosis. *Semin Respir Crit Care Med.* Vol 23, No. 2, (Apr 2002), pp. 155-65
- Berk JL, Keane J, Seldin DC, Sancherawala V, Koyama J, Dember LM, Falk RH. (2003). Persistent pleural effusions in primary systemic amyloidosis: etiology and prognosis. *Chest.* Vol. 124, No. 3, (Sep 2003), pp. 969-977

- Berk JL. (2005). Pleural effusions in systemic amyloidosis. *Curr Opin Pulm Med*. Vol. 11, No. 4, (Jul 2005), pp. 324-8
- Bhadra K, Butnor KJ, Davis GS. (2010). A Bronchoscopic Oddity Nodular Tracheobronchial Amyloid. *J Bronhcol Interv Pulmonol*. Vol. 17, No. 3, (Jul 2010), pp. 248-52
- Bignold LP, Martyn M, Basten A. (1980). Nodular pulmonary amyloidosis associated with benign hypergammaglobulinemic purpura. *Chest*. Vol. 78, No. 2, (Aug 1980), pp. 334-6
- BoydKing A, Sharma O, Stevenson K. (2009). Localized interstitial pulmonary amyloid: a case report and review of the literature. *Curr Opin Pulmon Med*. Vol. 15, No. 5, (Sep 2009), pp. 517-20
- Capizzi SA, Betancourt E, Prakash UB. (2000). Tracheobronchial amyloidosis. *Mayo Clin Proc*. Vol. 75, No. 11, (Nov 2000), pp. 1148-52
- Carter, D., Patchefsky, AS. (1998) Chapter 9 Spindle Cell Tumors of the Lung, In: Tumors and Tumor-like Lesions of the Lung, pp.(286-365) W.B. Saunders, 0-7216-3312-9, Philadelphia
- Celli BR, Rubinow A, Cohen AS, Brody JS. (1978). Patterns of pulmonary involvement in systemic amyloidosis. *Chest*. Vol. 74, No. 5, (Nov 1978), pp. 543-547
- Cohen AD, Zhou P, Chou J, Tenuya-Feldstein J, Reich L, Hassoun H, Levine B, Filippa DA, Riedel E, Kewalrammani T, Stubblefield MD, Fleisher M, Nimer S, Comenzo RL. (2007). Risk-adapted autologous stem cell transplantation with adjuvant dexamethasone + thalidomide for systemic light-chain amyloidosis: results of phase II trial. *Br J Haematol*. Vol. 139, No. 2, (Oct 2007), pp. 224-33
- Cools FJ, Kockx MM, Borchxstaens GE, Heuvel PV, Cuykens JJ. (1996). Primary systemic amyloidosis complicated by massive thrombosis. *Chest*. Vol. 110, No. 1, (Jul 1996), pp. 282-4
- Cordier JF, Loire R, Brune J. (1986). Amyloidosis of the lower respiratory tract. Clinical and pathologic features in a series of 21 patients. *Chest*. Vol. 90, No. 6, (Dec 1986), pp. 827-831
- Currie GP, Rossiter C, Dempsey OJ, Legge JS. (2005). Pulmonary amyloid and PET scanning. *Respir Med*. Vol. 99, No. 11, (Nov 2005), pp. 1463-4
- Daniels JT, Cury JD, Diaz J. (2007). An unusual cause of postobstructive Pneumonia. *Chest*. Vol. 131, No. 3, (Mar 2007), pp. 930-933
- Diaz-Jimenez JP, Rodriguez A, Ballarin JIM, Castro MJ, Argemi TM, Manresa F. (1999). Diffuse tracheobronchial amyloidosis. *J Bronchol*. Vol. 6, No. 1, (Jan 1999), pp. 13-7
- Gibbaoui H, Abouchacra S, Yaman M. (2004). A case of primary diffuse tracheobronchial amyloidosis. *Ann Thorac Surg*. Vol. 77, No. 5, (May 2004), pp. 1832-4
- Gillmore JD, Tennent GA, Hutchinson WL, Gallimore JR, Lachmann HL, Goodman HJB, Offer M, Millar DJ, Petrie A, Hawkins PN, Pepys MB. (2010). Sustained pharmacological depletion of serum amyloid P component in patients with systemic amyloidosis. *Br J Haematol*. Vol. 148, No. 5, (Mar 2010), pp. 760-7
- Gross BH. (1981). Radiographic manifestations of lymph node involvement in amyloidosis. *Radiology*. Vol. 138, No. 1, (Jan 1981), pp. 11-14
- Hawkins PN, Lavender JP, Pepys MB. (1990). Evaluation of systemic amyloidosis by scintigraphy with ¹²³I -labelled serum amyloid P component. *N Engl J Med*. Vol. 323, No. 8, (Aug 23, 1990), pp. 508-513
- Hazenber BP, van Rijswijk MH, Lub-de Hooge MN, Vellenga E, Haagsma EB, Posthumus MD, Jager PL. (2007). Diagnostic performance and prognostic value of extravascular retention of ¹²³I-labeled serum amyloid P component in systemic amyloidosis. *J Nucl Med*. Vol. 48, No. 6, (Jun 2007), pp. 865-72

- Herman DP, Colchen A, Milleron B, Bentata-Pessayre M, Personne C, Akoun G. (1985). The treatment of tracheobronchial amyloidosis using a bronchial laser. Apropos of a series of 13 cases. *Rev Mal Respir.* Vol. 2, No. 1, pp. 19-23
- Hoag JB, Yung RC. (2008). An unexpected finding of endobronchial amyloidosis in a patient with mediastinal fibrosis. *J Bronchol.* Vol. 15, No. 1, pp. 61-3
- Jones AW, Chatterji AN. (1977). Primary tracheobronchial Amyloidosis with tracheobronchopathia osteoplastica. *Br J Dis Chest.* Vol. 71, No. 4, (Oct 1977), pp. 268-72
- Kalra S, Utz JP, Edell ES, Foote RL. (2001). External-beam radiation therapy in the treatment of diffuse tracheobronchial amyloidosis. *Mayo Clin Proc.* Vol. 76, No. 8, (Aug 2001), pp. 853-6
- Katzenstein, A. (1997) Chapter 7 Systemic Diseases involving the Lung, In: Katzenstein and Askins Surgical Pathology of Non-neoplastic Lung Disease , pp.(168-192) W.B. Saunders, 0-7216-5575-9, Philadelphia
- Kavuru MS, Adamo JP, Ahmad M, Mehta AC, Gephardt GN. (1990). Amyloidosis and Pleural Disease. *Chest.* Vol. 98, No. 1, (Jul 1990), pp. 20-3
- Kung J, Zhuang H, Yu JQ, Duarte PS, Alavi A. (2003). Intense flourodeoxyglucose activity in pulmonary amyloid lesions on positron emission tomography. *Clin Nucl Med.* Vol. 28, No. 12, (Dec 2003), pp. 975-6
- Kurrrus JA, Hayes JK, Hoidal JR, Menendez MM, Elstad MR. (1998). Radiation therapy for tracheobronchial amyloidosis. *Chest.* Vol. 114, No. 5, (Nov 1998), pp. 1489-92
- Kyle RA, Gertz MA, Greipp PR, Witzig TE, Lust JA, Lacy MQ, Therneau TM. (1997). A trial of three regimens for primary amyloidosis: colchicine alone, melphalan and prednisone, and melphalan, prednisone and colchicine. *N Engl J Med.* Vol. 336, No. 17, (Apr 24, 1997), pp. 1202-7
- Lachmann HJ, Hawkins PN. (2006). Amyloidosis and lung. *Chron Respir Dis.* Vol. 3, No. 4, pp. 203-214
- Lesser A. (1877). Ein Fall von Enchondroma osteiodes mixtum der lunge mit partieller amyloid Entortung. *Virchows Arch (Path Anat)* Vol. 69, pp 404-408
- M'Rad S, Le Thi Huong D, Wechsler B, Monsigny M, Buthiau D, Colchen A, Godeau P. (1988). Localized tracheobronchial amyloidosis. A new case studies with x-ray computed tomographic and nuclear magnetic resonance. Review of the literature. *Rev Pneumol Clin.* Vol. 44, No. 6, pp. 260-5
- Maiwand MO, Nath AR, Kamath BSK. (2001). Cryosurgery in the treatment of tracheobronchial amyloidosis. *J Bronchol.* Vol. 8, No. 2, (Apr 2001), pp. 95-7
- Mimori Y, Rikimaru T, Mitsui T, Shiraishi T, Kinoshita M, Oizumi K. (1998). Localized amyloidosis of the lower respiratory tract. *J Bronchol.* Vol 5, No. 4, (Oct 1998), pp. 316-8
- Miyazaki D, Yazaki M, Ishii W, Matsuda M, Hoshii Y, Nara K, Nakayama J, Ikeda SI. (2011). A rare lung nodule consisting of adenocarcinoma and amyloid deposition in a patient with primary systemic AL amyloidosis. *Intern Med.* Vol. 50, No. 3, (Feb 2011), pp. 243-6
- Monroe AT, Walia R, Zlotecki RA, Jantz MA. (2004). Tracheobronchial Amyloidosis: A case report of successful treatment with external bean radiation therapy. *Chest.* Vol. 125, No. 2, (Feb 2004), pp. 784-789
- New GB. (1919). Amyloid Tumors of the upper air passages. *Laryngoscope.* Vol. 29, No. 6, pp. 327-41
- O'Regan A, Fenlon HM, Beamis JF Jr., Steele MP, Skinner M, Berk JL. (2000). Tracheobronchial amyloidosis: The Boston University experience from 1984 to 1999. *Medicine.* Vol. 79, No. 2, (Mar 2000), pp 69-79

- Piazza C, Cavaliere S, Foccoli P, Toninelli C, Bolzoni A, Peretti G. (2003). Endoscopic management of laryngo-tracheobronchial amyloidosis: as seroes of 32 patients. *Eur Arch Otorhinolaryngol*. Vol. 260, No. 7, (Aug 2003), pp. 349-54
- Pitz MW, Gibson IW, Johnston JB. (2006). Isolated Pulmonary Amyloidosis: Case report and review of the Literature. *Am J Hematol*. Vol. 81, No. 3, (Mar 2006), pp. 212-3
- Plockinger B, Muller MR, Eskersberger F. (1993). Isolated amyloidosis of hilar lymph node. *Langenbecks Arch Chir*. Vol. 378, No. 3, pp. 167-70
- Road JD, Jacques J, Sparling JR. (1985). Diffuse alveolar septal amyloidosis presenting with recurrent hemoptysis and medial dissection of pulmonary arteries. *Am Rev Respir Dis*. Vol. 132, No. 6, (Dec 1985), pp. 1368-70
- Saleiro S, Hespanhol V, Magalhaes A. (2008). Endobronchial amyloidosis. *J Bronchol*. Vol. 15, No. 2, (Apr 2008), pp. 95-99
- Seo JH, Lee SW, Ahn BC, Lee J. (2010). Pulmonary amyloidosis mimicking multiple metastatic lesions on F-18 FDG PET/CT. *Lung Cancer*. Vol. 67, No. 3, (Mar 2010), pp. 376-9
- Sharma D, Katlic MR. (2006). Localized Tracheal Amyloidosis. *J Bronchol*. Vol. 13, No. 1, (Jan 2006), pp. 19-20
- Shenin M, Xiong W, Naik M, Sandorfi N. (2010). Primary amyloidosis causing diffuse alveolar hemorrhage. *J Clin Rheumatol*. Vol. 16, No. 4, (Jun 2010), pp. 175-7
- Sipe JD, Benson MD, Buxbaum JN, Ikeda S, Merlini G, Saraiva MJ, Westmark P. (2010). Amyloid fibril protein nomenclature: 2010 recommendations from the nomenclature committee of the International Society of Amyloidosis. *Amyloid*. Vol. 17, No. 3-4, (September-December 2010) pp. 101-104
- Smith RR, Hutchins GM, Moore GW, Humphrey RL. (1979). Type and distribution of pulmonary parenchymal and vascular amyloid: Correlation with cardiac amyloid. *Am J Med*. Vol. 66, No. 1, (Jan 1979), pp. 96-104
- Strange C, Heffner JE, Collins BS, Brown FM, Sahn SA. (1987). Pulmonary hemorrhage and air embolism complicating transbronchial biopsy in pulmonary amyloidosis. *Chest*. Vol. 92, No. 2, (Aug 1987), pp. 367-9
- Sugihara E, Dambara T, Okamoto M, Sonobe S, Koga H, Inui A, Aiba M, Isonuma H, Hayashida Y. (2006). Clinical features of 10 patients with pulmonary amyloidosis. *J Bronchol*. Vol. 13, No. 4, (Oct 2006), pp. 191-3
- Thompson PJ, Citron KM. (1983). Amyloid and the lower respiratory tract. *Thorax*. Vol. 38, No. 2, (Feb 1983), pp. 84-87
- Utz JP, Swensen SJ, Gertz MA. (1996). Pulmonary Amyloidosis. The Mayo Clinic Experience from 1980 to 1993. *Annals of Internal Medicine*. Vol. 124, No. 4, (Feb 15, 1996), pp. 407-413
- Wechalekar AD, Hawkins PN, Gillmore JD. (2008). Perspectives in treatment of AL amyloidosis. *Br J Haematol*. Vol. 140, No. 4, (Feb 2008), pp. 365-77
- Westmark P, Benson MD, Buxbaum JN. (2007). A primer of amyloid nomenclature. *Amyloid*. Vol. 14, No. 3, (Sep 2007), pp. 179-83
- Wink JS. (2003). An unusual presentation of an uncommon disease: A diffuse cystic radiologic pattern in a patient with localized pulmonary amyloidosis. *Chest*. Vol. 124, No. 4 suppl, (Oct 2003), pp. 280S
- Yang S, Chia SY, Chuah KL, Eng P. (2003). Tracheobronchial amyloidosis treated with rigid bronchoscopy and stenting. *Surg Endosc*. Vol. 17, No. 4, (Apr 2003), pp. 658-9



Amyloidosis - An Insight to Disease of Systems and Novel Therapies

Edited by Dr. Işıl Adadan Güvenç

ISBN 978-953-307-795-6

Hard cover, 194 pages

Publisher InTech

Published online 16, November, 2011

Published in print edition November, 2011

Amyloidosis is a benign, slowly progressive condition characterized by the presence of extracellular fibrillar proteins in various organs and tissues. It has systemic or localized forms. Both systemic and localized amyloidosis have been a point of interest for many researchers and there have been a growing number of case reports in the literature for the last decade. The aim of this book is to help the reader become familiar with the presentation, diagnosis and treatment modalities of systemic and localized amyloidosis of specific organs or systems and also cover the latest advancements in therapy.

How to reference

In order to correctly reference this scholarly work, feel free to copy and paste the following:

Mark E. Lund, Priya Bakaya and Jeffrey B. Hoag (2011). Pulmonary Manifestations of Amyloidosis, Amyloidosis - An Insight to Disease of Systems and Novel Therapies, Dr. Işıl Adadan Güvenç (Ed.), ISBN: 978-953-307-795-6, InTech, Available from: <http://www.intechopen.com/books/amyloidosis-an-insight-to-disease-of-systems-and-novel-therapies/pulmonary-manifestations-of-amyloidosis>

INTECH
open science | open minds

InTech Europe

University Campus STeP Ri
Slavka Krautzeka 83/A
51000 Rijeka, Croatia
Phone: +385 (51) 770 447
Fax: +385 (51) 686 166
www.intechopen.com

InTech China

Unit 405, Office Block, Hotel Equatorial Shanghai
No.65, Yan An Road (West), Shanghai, 200040, China
中国上海市延安西路65号上海国际贵都大饭店办公楼405单元
Phone: +86-21-62489820
Fax: +86-21-62489821

© 2011 The Author(s). Licensee IntechOpen. This is an open access article distributed under the terms of the [Creative Commons Attribution 3.0 License](https://creativecommons.org/licenses/by/3.0/), which permits unrestricted use, distribution, and reproduction in any medium, provided the original work is properly cited.

IntechOpen

IntechOpen