

We are IntechOpen, the world's leading publisher of Open Access books Built by scientists, for scientists

6,900

Open access books available

186,000

International authors and editors

200M

Downloads

Our authors are among the

154

Countries delivered to

TOP 1%

most cited scientists

12.2%

Contributors from top 500 universities



WEB OF SCIENCE™

Selection of our books indexed in the Book Citation Index
in Web of Science™ Core Collection (BKCI)

Interested in publishing with us?
Contact book.department@intechopen.com

Numbers displayed above are based on latest data collected.
For more information visit www.intechopen.com



Update on Modulating Wound Healing in Trabeculectomy

Hosam Sheha

*Ocular Surface Center & Tissue Tech Inc., Miami, Florida
United States*

1. Introduction

Trabeculectomy is the most commonly used surgical procedure for managing medically uncontrolled glaucoma. It reduces intraocular pressure (IOP) by creating an artificial drainage pathway of the aqueous humor from the anterior chamber to the subconjunctival space, forming a filtering bleb. Aqueous humor in the subconjunctival space may then exit by multiple pathways including transconjunctival filtration and absorption through the episcleral veins (Fig. 1).

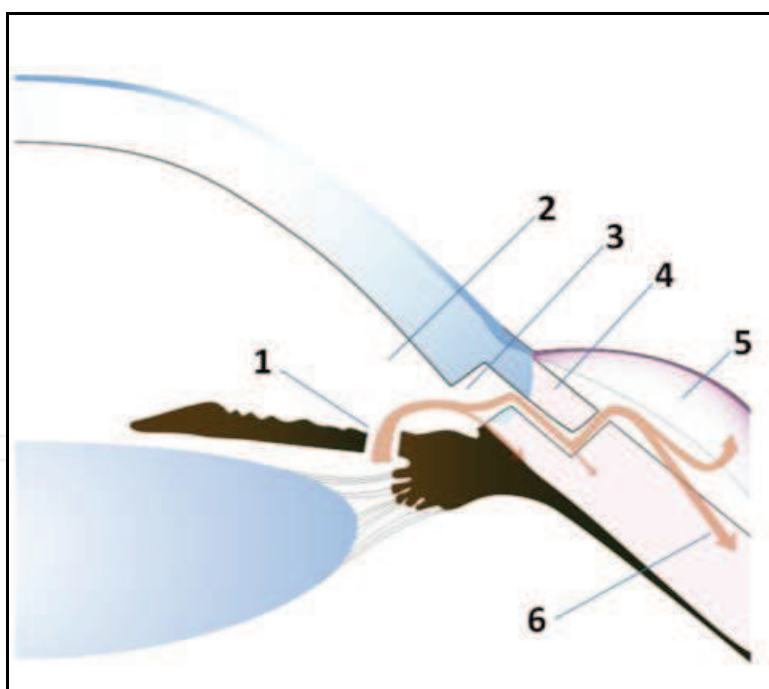


Fig. 1. Aqueous pathway after trabeculectomy through peripheral iridectomy (1) to the anterior chamber (2), the internal ostium (3), the route under the scleral flap (4), and the edge of the scleral flap to be absorbed via the bleb wall (5), and the episcleral venous plexus (6)

The success of trabeculectomy has been limited by postoperative fibrosis at the surgery site, leading to bleb failure months or years after surgery. High risk factors that lead to the failure in trabeculectomy include previous ocular surgery, specific types of glaucoma e.g. secondary

glaucoma such as neovascular, uveitic, post-traumatic, and lens-induced glaucoma, and to a lesser extent, young age and black race (Sturmer et al, 1993; Broadway and Chang, 2001).

Several surgical and pharmacologic techniques have been introduced to enhance the success in eyes with poor surgical prognoses. Until now, no effective and safe agent has been identified that can inhibit fibrosis, without complications, in the glaucoma filtering wound created by trabeculectomy. Although antimetabolites have revolutionized glaucoma surgery, the use of these agents is still associated with substantial risk (Chen, 1983). The common clinical practice of using mitomycin C (MMC) in trabeculectomy as an anti-fibrotic and anti-metabolic agent has achieved only limited success in cases with high-risk glaucoma while raising notable sight-threatening complications such as hypotony, bleb leaks, and infection (Lama and Fechtner, 2003).

To circumvent complications caused by MMC, there is a great need to improve the outcome of trabeculectomy by identifying a physiological modulator that may suppress pathological fibrosis without compromising the normal reparative wound healing process.

Our recent clinical research suggests that amniotic membrane (AM) could be a physiological modulator of wound healing that prevents scar formation in the subconjunctival space. We have demonstrated that AM not only prevents scar formation via its anti-inflammatory and anti-scarring actions but also serves as a spacer integrated into the intra-bleb structure to avert early over-filtration complications associated with trabeculectomy, and to stabilize the patency of the filtering fistula for prolonged maintenance of the bleb function (Sheha et al, 2008). This chapter reviews recent advances in the use of amniotic membrane as a biological modulator of wound healing that suppresses pathological fibrosis in trabeculectomy.

2. Wound healing process following trabeculectomy

Wound healing is triggered by activating the body's innate immunity and is characterized by inflammation in the acute phase, granulation tissue formation in the intermediate phase, and scarring in the chronic phase. This wound healing process is mediated by a number of cell types and is orchestrated by complex arrays of growth factors, cytokines, chemokines, and non-protein mediators. Trabeculectomy differs from most surgical procedures in that inhibition of wound healing is desirable to achieve surgical success (Dvorak, 1986).

Experimental and human studies have outlined a sequence of events that occurs in early bleb failure (Summarized in Fig. 2) (Skuta and Parrish, 1987). After surgical trauma, plasma proteins, including fibrinogen, fibronectin, and plasminogen, form a gel-like fibrin-fibronectin matrix, into which inflammatory cells (including monocytes and macrophages), new capillaries, and fibroblasts migrate. Macrophages from monocytes appear in about 12 hours, reaching peak numbers around day 3. These macrophages activate an inflammatory response, including the activation of lymphocytes and fibroblasts. T-cells appear on day 5, and after reaching a peak in numbers by the end of two weeks, they are activated into specific T-cells, which release various cytokines to control the activity and proliferation of fibroblasts. The fibrin-fibronectin matrix is eventually degraded by inflammatory cells, and fibroblasts subsequently synthesize fibronectin, interstitial collagens, and glycosaminoglycans to form fibrovascular granulation tissue (Desjardins et al, 1986; Grierson et al, 1988; Reichel et al, 1998; Miller et al, 1989; Chang et al, 2000).

The proliferated fibroblasts gradually begin to differentiate; this process is suspected to be mediated by various factors: transforming growth factor (TGF)-beta (Wipff et al, 2007), connective-tissue growth factor (CTGF) (Sherwood, 2006), Rho-associated serine-threonine

kinase (ROCK1) (Meyer-ter-Vehn et al, 2006), and the matrix-metalloproteinases (MMPs) (Chintala et al, 2005). Unlike undifferentiated fibroblasts, the newly-differentiated myofibroblasts transform the secreted extracellular matrix into an actin-based component which creates stronger scar tissue (Desmouliere et al, 1993). Blood vessels retract over time and fibroblasts largely disappear as the tissue is remodeled to form a dense collagenous subconjunctival scar.

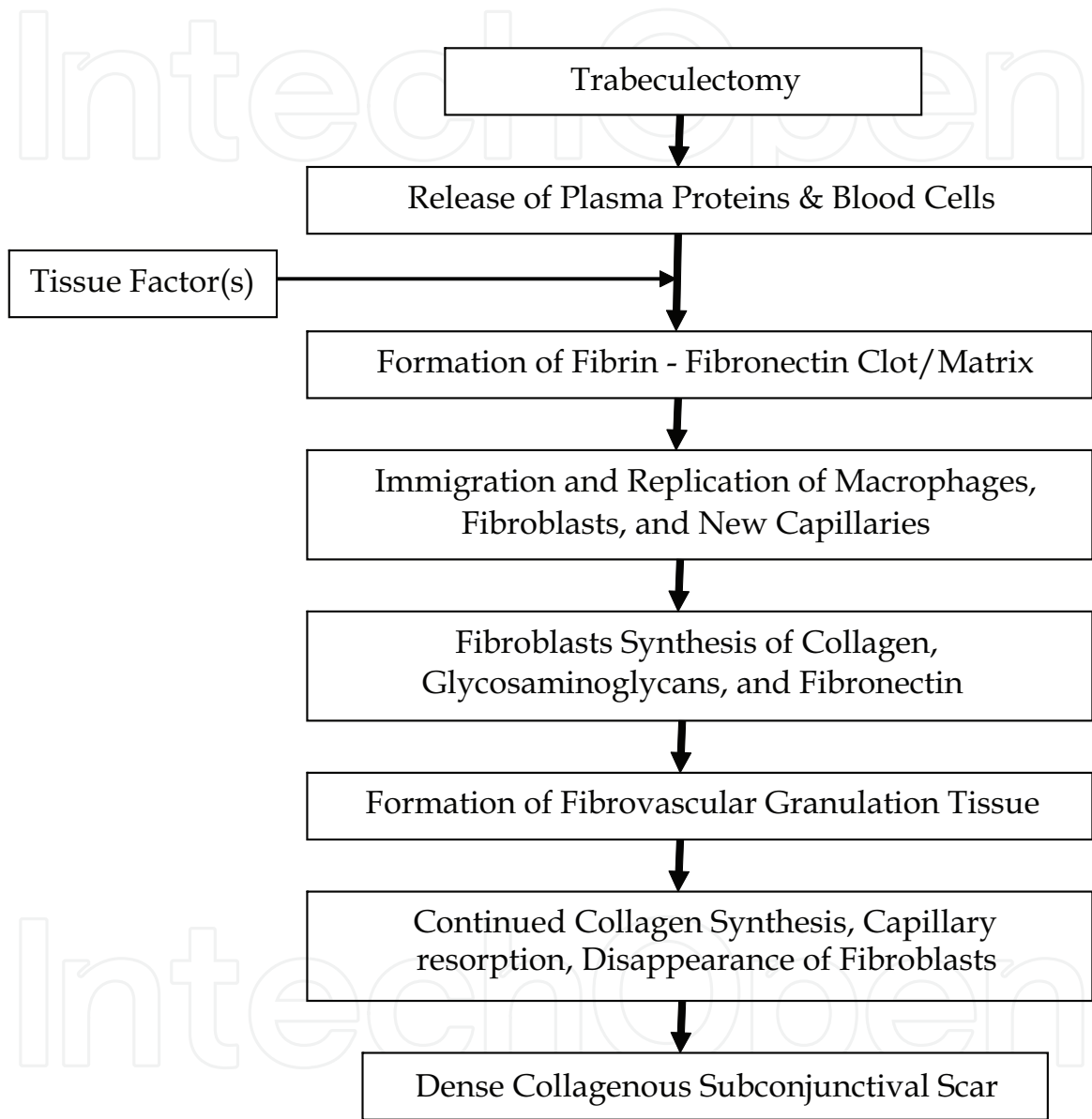


Fig. 2. Events of wound healing in trabeculectomy failure

3. Risk factors and potential causes of trabeculectomy failure

3.1 External factors

External factors at the episcleral-conjunctival interface are responsible for most cases of trabeculectomy failure. Fibroblast proliferation, synthesis of the extracellular matrix, and subsequent development of subconjunctival fibrosis play prominent roles in external failure. Chemotactic factors for fibroblasts include lymphokines, complement, native collagens of

types I to V, fibronectin, some proteolytic digestion fragments of collagen and fibronectin, and platelet-derived growth factor (Ross et al, 1986).

Intense preoperative and postoperative inflammation induces a cellular response that accelerates wound healing. The presence of blood beneath the conjunctiva may also increase the probability of bleb failure. As noted above, serum derivatives including fibronectin and platelet-derived growth factor may stimulate fibroblast migration and proliferation. In addition, macrophages, which may be activated by blood, appear to play a key role in inducing the fibroproliferative response in wound repair (Leibovich and Ross, 1975). Extrapolation of these observations to trabeculectomy wound healing is consistent with the clinical impression that the presence of blood increases the likelihood of postoperative fibrosis.

3.2 Intraocular factors

In the absence of scar formation, an inadequate opening into the anterior chamber due to scleral remnants or Descemet's membrane in the fistula may lead to primary failure. Blockage of the filtration site by prolapsed iris, vitreous, or ciliary body may also lead to early postoperative failure (Maumenee, 1960). Many of these potential causes of bleb failure can be avoided by careful surgical technique. A spacer during surgery can enhance the likelihood of a patent fistula.

4. Measures to improve the trabeculectomy outcome

Trabeculectomy success relies on the continued patency of the fistula and the continued ability of the filtering bleb created out of the conjunctiva to absorb aqueous humor. Thus, the success of the procedure lies not only on the surgical technique but also the intraoperative and postoperative measures to minimize scar formation.

Preoperative inflammation should be treated with anti-inflammatory agents, usually corticosteroids. Miotics, which break down the blood-aqueous barrier, should be discontinued at least two weeks before trabeculectomy. Treatment of postoperative inflammation is also important. Cycloplegic agents help restore the blood-aqueous barrier and may reduce the release of plasma proteins, which may contribute to the postoperative healing response.

With respect to surgical technique, tissue trauma should be minimized by avoiding unnecessary manipulation of the conjunctiva, Tenon and iris. Hemostasis should be performed to decrease bleeding. Removal of the inner sclerectomy block should establish a patent channel without remnants of Descemet's membrane. A basal iridectomy prevents postoperative iris incarceration at the filtering site.

Although a fornix-based conjunctival flap might prevent scarring of the posterior conjunctiva and Tenon's capsule, randomized studies of limbus versus fornix-based conjunctival flaps in primary trabeculectomies failed to document significant differences in surgical success between the two techniques (Shuster et al, 1984; Traverso et al, 1987). The effect of the excision of Tenon's capsule on trabeculectomy success is also controversial.

5. Pharmacologic modulation of wound healing

Unlike most surgical procedures, success of glaucoma filtering surgery is achieved through the inhibition of wound healing. The use of pharmacologic agents is based on suppression

of proliferation of cells, mainly fibroblasts, which would limit the healing at the site of the fistulizing surgery and consequently limit postoperative scarring.

5.1 Corticosteroids

As stated above, the initial steps in wound healing are inflammation and coagulation, leading to a cascade of biological events including cellular, hormonal, and growth factor release. These events finally lead to scar tissue formation (Skuta and Parrish, 1987). Corticosteroids regulate wound healing through the inhibition of macrophage functions, such as phagocytosis and the release of enzymes like collagenase, plasminogen activator, and growth factors, and thus suppress inflammation. Specific anti-inflammatory effects include suppression of fibrin deposition, capillary permeability, migration of leukocytes and macrophages, and phagocytic activity (Starita et al, 1985). Corticosteroids also inhibit vascular permeability and fibroblast proliferation (Lama and Fechtner, 2003). Tissue culture studies of human Tenon capsule fibroblasts have shown that corticosteroids inhibit cell attachment and proliferation (Nguyen and Lee, 1992).

Postoperative topical corticosteroids have been reported to significantly increase the success of trabeculectomy (Araujo 1995). Sub-Tenon injection of triamcinolone acetonide (TA) appears to be a more effective mean of high-dose corticosteroid delivery and may increase the success rate of trabeculectomy (Hosseini 2007). Tham and associates reported that the use of TA (1.2 mg) injection into filtration blebs at the conclusion of trabeculectomy was associated with good intraocular pressure (IOP) control for 3 months (Tham 2006). However, Yuki et al reported no significant differences between the success rates of trabeculectomy with or without intraoperative sub-Tenon injection of 20 mg TA within the 12-month follow-up period (Yuki, 2009).

Besides intra- and post-operative administration, some studies have highlighted the beneficial effect of preoperative use of corticosteroids and non steroidal anti-inflammatory agents in improving the success rate of filtration surgery. Baudouin demonstrated that fluorometholone drops one month before filtering surgery has effectively reduced inflammation, as indicated by the expression of human leukocyte antigen (HLA)-DR after impression cytological analysis (Baudouin 2002). Breusegem compared preoperative topical anti-inflammatory medications to placebo before trabeculectomy. Significantly fewer postoperative needling procedures were needed in the steroid-treated group (5%) than in the placebo group (41%). Furthermore, none of the patients in the steroid group required topical IOP-lowering medication to maintain a subtarget IOP, compared with 24% of patients in the placebo group. However, there was no significant overall difference in absolute IOP values or in relative IOP reduction between two groups at any point (Breusegem 2010). Despite the aforementioned advantages, topical steroids pose a risk for steroid-induced IOP elevation and cataract.

5.2 Antimetabolites

Anti-mitotic agents such as MMC and 5-fluorouracil (5-FU) help suppress post-surgical scarring by causing widespread non-selective cell death and apoptosis. The intraoperative application of MMC in trabeculectomy was introduced by Chen (Chen, 1983), while Heuer was the first to report the use 5-FU postoperatively as subconjunctival injections (Heuer et al, 1984).

While 5-FU can be used both for intraoperative application and postoperative injection (Parrish et al, 2001), the use of MMC as a postoperative injection is not as widely accepted as

5-FU (Apostolov and Siarov, 1996). The concentration of 5-FU used intraoperatively is 50 mg/mL applied for up to 5 minutes. The concentration of MMC used intraoperatively ranges from 0.1-0.5 mg/mL applied for 2-5 minutes, depending on the risk of failure. The antifibrotic agent can be applied to the scleral bed before or after the scleral flap is made, using cellulose sponges. The antifibrotic-soaked sponges should be applied to the area where aqueous flow is desired and should not be placed too close to the limbus or in contact with the wound edges. After all the sponges have been removed, the site is irrigated with copious amounts of saline solution to remove residual antifibrotic agents.

Although anti-mitotic agents improved the success rate of trabeculectomy (Chen et al, 1990; Kitazawa et al, 1991), there is an increased risk of early postoperative complications such as hypotony, bleb rupture, and infectious endophthalmitis (Shields et al, 1993; Greenfield and Parrish, 1996; Singh et al, 2000; WuDunn et al, 2002; Palanca-Capistrano et al, 2009). Another common late complication is bleb leakage, which may cause other serious complications such as infection, hypotony related maculopathy, and corneal endothelial decompensation (Greenfield et al, 1996; Nuyts et al, 1994). Thus, understanding mechanisms of wound healing following MMC treatment is important to reduce bleb-related complications of leakage.

As a mechanism of MMC action, it is commonly accepted that inhibiting fibroblast proliferation leads to decreased conjunctival adhesion and maintaining the bleb (Lama and Fechtner, 2003). In terms of the pharmacokinetics of MMC, the $t_{1/2}$ in blood doses of 30, 20, and 10 (mg/body) is 50, 43, and 10 minutes, respectively (Fujita, 1982). This suggests that the half-life of MMC is very short. Because we use MMC at a dosage of less than 1% on the sclera for several minutes in trabeculectomy, its effective lifespan seems to be less than several hours. As stated above, fibroblasts appear and are activated at 12 hours after surgery by macrophages and various cytokines that are released from T-cells. Therefore, it seems unreasonable that MMC directly suppresses fibroblasts' proliferation.

It is more likely that MMC initially suppresses the proliferation of mast cells, including chymase-positive cells which may promote inflammatory response. As a result of this, fibroblast proliferation is then restrained (Okada et al, 2009). In fact, topical instillation of an anti-mast-cell agent, tranilast, was useful for filtering bleb formation and IOP

reduction (Chihara et al, 2002). Therefore, suppression of mast cells might be related to formation of the filtering bleb. In addition, chymase inhibition might play a role in maintaining filtering blebs for an extended period of time. It has been reported that a chymase inhibitor prevents adhesion for up to three months in an abdomen adhesion model (Okamoto et al, 2004), so bleb formation may be maintained for a long period if MMC inhibits chymase function after tissue injury. Further investigation is needed to verify that chymase inhibitors are appropriate for glaucoma surgeries.

5.3 Anti-vascular endothelial growth factor (VEGF) antibodies

Pathologic angiogenesis is frequently associated with massive inflammation and migration of fibroblasts. It was shown that cultured conjunctival fibroblasts could be stimulated to produce VEGF by pro inflammatory cytokines (Sano-Kato et al, 2005), and Tenon's capsule fibroblasts were inhibited by angiogenesis inhibitors (Wong et al, 1994). Based on these findings, it is imaginable that a selective inhibition of growth factors such as VEGF could be an approach to prevent or treat extensive wound healing. To further elucidate the direct effect of anti-VEGF agents on fibroblasts, Guerriero et al. illustrated in vitro effects of bevacizumab on human corneal and conjunctival fibroblast cell lines. Their research

concluded that when corneal stromal fibroblasts are exposed to bevacizumab, loss of cell-to-cell adhesions and morphological changes are seen. They further stated that these changes are dose-dependent (Guerriero et al. 2006).

Currently, two therapeutic anti-VEGF antibodies exist; bevacizumab and ranibizumab. The use of subconjunctival bevacizumab 1mg in 0.04ml to treat a failing filtering bleb in addition to a needling procedure has been described in one patient (Kahook et al, 2006b). This patient showed an immediate decrease in IOP and was symptomatically improved as well. Bevacizumab has also been used in neovascular glaucoma (Kahook et al, 2006a; Michels et al, 2005). Kapetansky et al. studied the utility of subconjunctival bevacizumab injections administered proximal to blebs after trabeculectomy at the earliest sign of vascularization (Kapetansky et al, 2007). They noted that nearly two thirds of the blebs had an observable reduction in vascularity while decreasing IOP from a mean of 17.8 to 14mmHg 1 month after injection. Improved results were noted when the injections were given earlier in the postoperative phase. Coote et al presented a case of subconjunctival injection of bevacizumab that resulted in a dramatic reduction of bleb vascularity for 6 weeks. In their case, even 6 months after injection, a healthy bleb with minimal scar tissue was seen (Coote et al., 2008).

Ranibizumab is a fully humanized monoclonal antibody-fragment and therefore has a low molecular weight, which results in good tissue penetration. The antibody deactivates all isoforms of VEGF-A. Although intraocular injection of the drug showed no toxic side effects in an animal model (Manzano et al, 2006), the disadvantage of this form of application in trabeculectomy is the short half life of the drug. Although ranibizumab has a longer intravitreal half-life (6 days), this form of application does not cover the main peak of scarring reaction that is occurring around 2-3 weeks after surgery (Choi et al, 2010). For example, Purcell et al. noted decreased IOP and bleb vascularization after bleb needle revision using ranibizumab. But, this effect was short-lived, as increased vascularization was noted after 1 month of follow-up (Purcell, et al. 2008).

Further studies are needed to better understand how anti-VEGF agents might benefit patients undergoing glaucoma filtration surgery. There are ongoing safety studies to better analyze the importance of route of administration – intracameral, sub-Tenon and intravitreal – and to determine whether unknown side effects co-exist. It is important to delineate duration of action when anti-VEGF agents are injected in the intra or sub-Tenon's space and how this might influence efficacy.

6. Amniotic membrane as a modulator of trabeculectomy wound healing

6.1 Fetal strategy of wound healing

The amniotic membrane shares the same cell origin as the fetus. The majority of the studies testify the clinical efficacy of amniotic membrane transplantation (AMT) in gearing adult wound healing toward regeneration with minimal inflammation and scarring, suggesting that amniotic membrane (AM), like the fetal tissue, carries similar features that may not only facilitate regeneration but also inhibit scar formation (Mast et al, 1992; Adzick and Lorenz, 1994)

A number of mechanisms have been put forth to explain the AM's biological actions in modulating adult wound healing toward the fetal direction with anti-inflammation, anti-scarring and anti-angiogenesis. (Tseng et al, 2004).

It remains unclear whether such therapeutic actions are directly or indirectly linked to modulate healing and differentiation. AM has been shown to down-regulate transforming

growth factor- β signaling in cultured normal conjunctival fibroblasts (Tseng et al., 1999; Lee et al., 2000) and to inhibit the cellular migration triggered by vascular endothelial growth factor (VEGF) (Shey et al., 2011). Furthermore, AM can exert potent anti-inflammatory effects by facilitating macrophage apoptosis (Li et al, 2006).

6.2 Preliminary studies

Several investigators have explored the clinical efficacy of deploying AM as an adjunctive therapy to improve the surgical outcome of various glaucoma procedures, including trabeculectomy (Sheha et al, 2010). They have shown that transplantation of a single (Fujishima et al, 1998; Lu and Mai, 2003; Yue et al, 2003; Drolsum et al, 2006) or folded (Bruno et al, 2006; Eliezer et al, 2006) sheet of AM under the scleral flap (Fujishima et al, 1998; Yue et al, 2003; Drolsum et al, 2006; Bruno et al, 2006), and/or under the conjunctiva (Yue et al, 2003; Drolsum et al, 2006; Bruno et al, 2006; Eliezer et al, 2006), with additional MMC (Fujishima et al, 1998; Drolsum et al, 2006; Bruno et al, 2006), reduces IOP in eyes with refractory glaucoma. Experimental rabbit studies demonstrated that the AM, inserted under the scleral flap, achieves the same reduction of subconjunctival fibroblasts and macrophages around the trabeculectomy sites as that achieved by MMC (Demir et al, 2002; Wang et al, 2005), as well as reduces the number of fibroblasts at trabeculectomy sites when inserted under the scleral flap even without MMC (Zhong et al, 2000; Barton et al, 2001).

6.3 Potential advantages of AM

We have conducted the first prospective randomized trial to demonstrate the clinical efficacy of transplanting a single layer of cryopreserved AM under and around the scleral flap (Fig. 3), in conjunction with application of MMC in refractory glaucoma. In this study of 37 eyes, 18 received 0.2 mg/ml MMC under the flap for 2 min while 19 received additional implantation of cryopreserved AM under and around the scleral flap (Sheha et al, 2008).

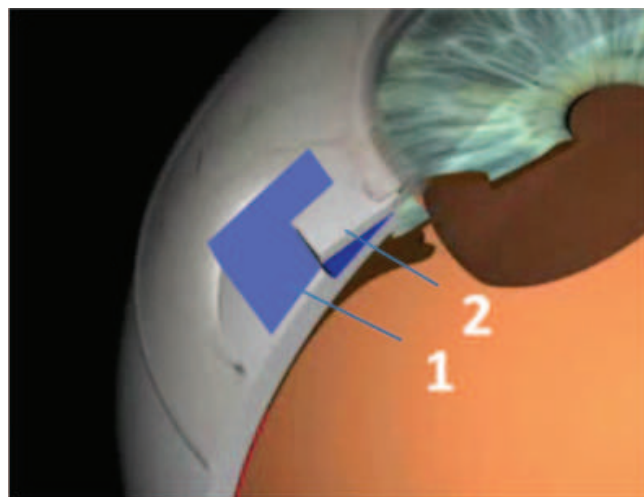


Fig. 3. AMT in trabeculectomy. AM (1) inserted under and around the scleral flap (2)

In the control MMC only group, IOP continuously rose between 3 and 12 months postoperatively. The incidence of encapsulated blebs, which are caused by collagen-producing fibroblasts (Ophir, 1992), was greater in the control group (38.9% vs. 5.3%) at 12 months postoperatively. This indicates that the effect of MMC was not sufficient to suppress scar formation, potentially due to its short half-life.

At 12 months postoperatively, the group with AM transplantation achieved significantly higher rates of complete (IOP \leq 21 mmHg without medications) and qualified success (IOP \leq 21 mmHg with or without additional medications). Furthermore, the resultant blebs were diffuse and translucent, but still retained normal vascularity (Fig. 4A). This bleb morphology was notably different from a MMC-induced ischemic bleb, which is prone to develop late complications such as bleb leak and infection (Fig. 4B). There were significantly fewer early postoperative complications such as shallow anterior chamber and choroidal effusion. These beneficial effects may be attributed to the fact that AM inserted under the scleral flap effectively halts rapid drainage of aqueous humor from the trabeculectomy site to reduce immediate hypotony from overfiltration and reduces scarring in the filtration site in the long run.

Hence, it is plausible that AM implanted in subconjunctival and subscleral spaces might reduce the adverse side effects intrinsically associated with MMC and with over-filtration, making AM a unique natural biological modulator that may exert a similar anti-scarring action to MMC while eliminating the potential sight-threatening complications known to MMC.

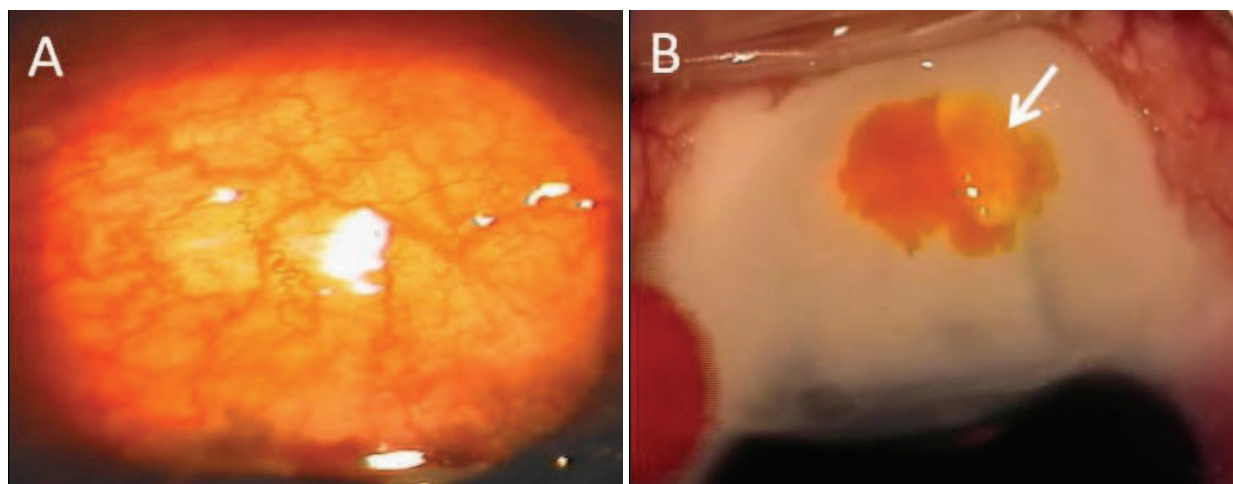


Fig. 4. Comparison between functioning bleb with normal vascularity after AMT (A) and ischemic leaking bleb after MMC (B); arrow indicates the bleb leak revealed by fluorescein staining (B)

The aforementioned favorable results could be attributed to a synergistic beneficial effect of MMC and AM on controlling fibrosis at the trabeculectomy site. It remains unclear whether the AM can substitute MMC completely in trabeculectomy. Furthermore, the mechanism through which the AM exerts its effects as well as its fate in the subscleral space over time remains largely unknown. The AM may not only prevent scar formation via its known anti-inflammatory and anti-scarring actions but may also serve as a spacer integrated into the internal bleb structure to stabilize the patency of the filtering fistula and maintain a functioning bleb.

Currently we are studying the fate of AM and internal bleb morphology. Although histological studies showed that human AM dissolves at 1 month postoperatively in rabbits (Wang et al, 2005), we do not know whether similar AM dissolution also occurred in human patients. We have gathered preliminary data supporting the feasibility of using anterior segment optic coherence tomography (OCT) to detect the presence of AM and the evidence of host cell integration into the AM after being transplanted in the subconjunctival space to

cover the glaucoma shunt tube. Our results showed that implanted AM maintained its thickness over a period of 12 months (Anand et al, 2011).

6.4 Evidence of AM anti-angiogenic action

Pathologic angiogenesis that is frequently associated with uncontrolled inflammation may lead to fibrosis. While reducing fibrosis in subconjunctival and subscleral spaces as shown above, AM was found to deliver anti-angiogenic actions to resolve rubeosis iridis that is known to occur in neovascular glaucoma. In our study, there were 7 eyes with neovascular glaucoma in each group, which was accompanied by circumcorneal congestion, neovascularization at the angle and the iris in the form of rubeosis iridis (Fig. 5A), and hyphema (Fig. 6A). Interestingly, 2 weeks following implantation of AM, we observed rapid resolution of the circumcorneal congestion and dramatic regression of the anterior chamber neovascularization (Fig. 5B) and hyphema (Fig. 6B). The effect was persistent through 12 months of follow-up.

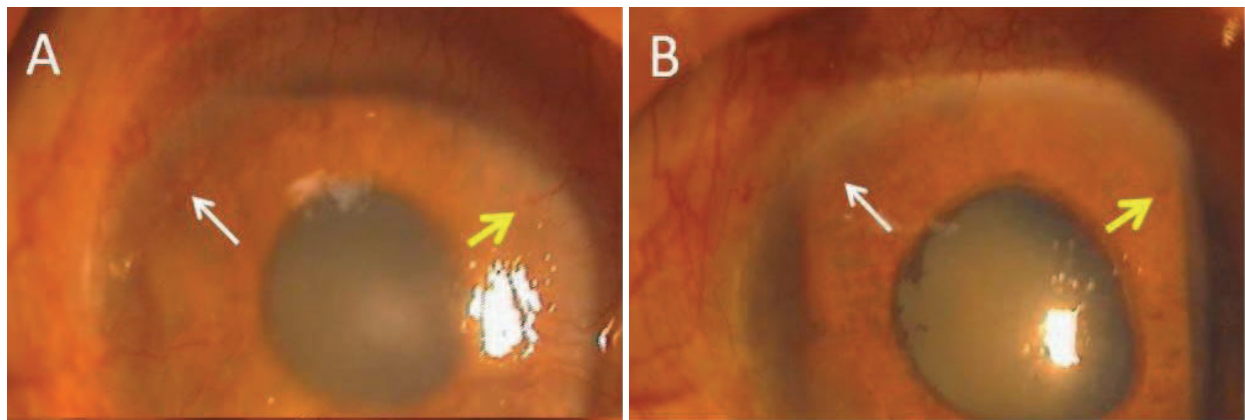


Fig. 5. Resolution of rubeosis iridis (arrows) in neovascular glaucoma

Hence, our study was the first showing AM’s anti-angiogenic clinical efficacy. Because such an action was not associated with reduction of the normal vascularity of the bleb (Fig.4A), we speculate that AM’s anti-angiogenic action is preferentially directed toward abnormal neovascularization. This novel therapeutic action against neovascularization may add an extra benefit in the management of high-risk neovascular glaucoma.

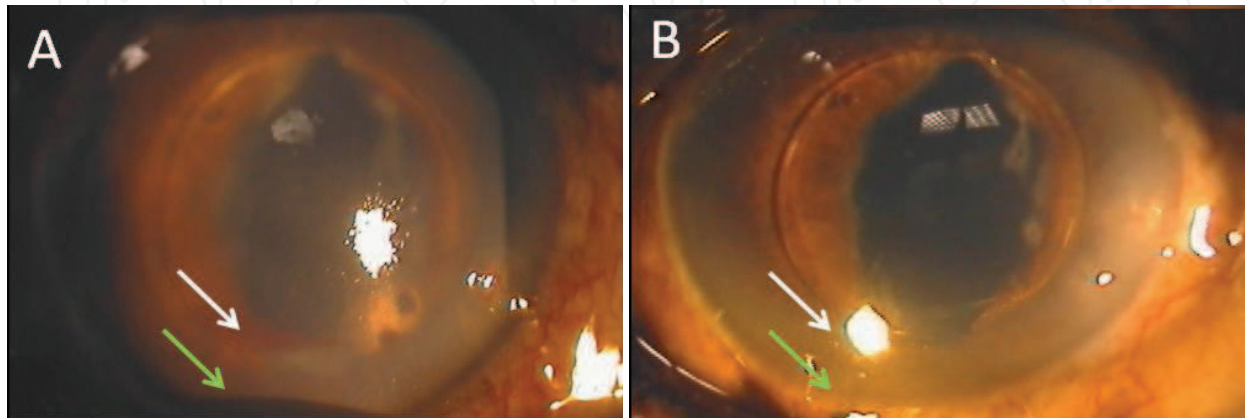


Fig. 6. Rapid resolution of rubeosis iridis (white arrow) and hyphema (green arrow) in neovascular glaucoma

7. Future research

Our preliminary studies designate that the implantation of AM to lower IOP in trabeculectomy represents a significant advance in treating glaucoma by eliminating complications associated with MMC and over-filtration. Further understanding of the fate of AM via imaging studies will not only confirm its anti-inflammatory and anti-scarring effects but will also teach us how intrableb wound healing can be modulated by the AM regarding integration into the surrounding operated tissue. Such knowledge will further strengthen our belief that AM can be a natural biological matrix derived from the fetus that may modulate adult wound healing toward regeneration through the reduction of inflammation, scarring, and unwanted new blood vessel formation. Further proof of the anti-angiogenic action of AM in reverting neovascularization in cases of neovascular glaucoma will generate a direct impact on using AM to treat ocular diseases where angiogenesis threatens vision. We expect that such a treatment will be more effective than the conventional approach based on an antibody blockade against VEGF, because AM not only suppresses angiogenesis mediated by VEGF and other growth factors, but also curtails inflammation and scarring. This innovative concept can then be applied to other parts of the body where pathological fibrosis or angiogenesis is considered detrimental and undesirable.

8. Financial disclosure and acknowledgement

The clinical research mentioned in this article was supported in part by grant #EY019785 from the National Eye Institute via TissueTech, Inc., which owns US patents on the method of preparation and clinical uses of human amniotic membrane. The content is solely the responsibility of the author and does not necessarily represent the official views of the National Eye Institute or the National Institutes of Health. The author thanks Lingyi Liang, MD, PhD and Shunsuke R. Sakurai for assistance in editing the text.

9. References

- Adzick NS, Lorenz HP. (1994). Cells, matrix, growth factors, and the surgeon. The biology of scarless fetal wound repair. *Ann Surg*, Vol.220, pp.10-18.
- Anand A, Sheha H, Teng C, Liebmann JM, Ritch R, Tello C. (2011). Use of Amniotic Membrane Graft in Glaucoma Shunt Surgery. *Ophthalmic Surg Lasers Imaging*.
- Apostolov VI, Siarov NP. (1996). Subconjunctival injection of low-dose Mitomycin-C for treatment of failing human trabeculectomies. *Int Ophthalmol*, Vol.20, No.1-3, pp.101-105.
- Araujo SV, Spaeth GL, Roth SM, Starita RJ. A ten-year follow-up on a prospective, randomized trial of postoperative corticosteroids after trabeculectomy. *Ophthalmology* 1995; 102:1753-1759.
- Barton K, Budenz D, Khaw PT, Tseng SCG. (2001). Glaucoma filtration surgery using amniotic membrane transplantation. *Invest Ophthalmol Vis Sci*, Vol.42, pp.1762-1768.
- Baudouin C, Nordmann JP, Denis P, et al. Efficacy of indomethacin 0.1% and fluorometholone 0.1% on conjunctival inflammation following chronic application of antiglaucomatous drugs. *Graefes Arch Clin Exp Ophthalmol* 2002;240:929-35.

- Breusegem C, Spielberg L, Van Ginderdeuren R, Vandewalle E, Renier C, Van de Veire S, Fieuws S, Zeyen T, Stalmans I. Preoperative Nonsteroidal Anti-inflammatory Drug or Steroid and Outcomes after Trabeculectomy. *Ophthalmology* 2010;117:1324-1330
- Broadway DC, Chang LP. (2001). Trabeculectomy, risk factors for failure and the preoperative state of the conjunctiva. *J Glaucoma*, Vol.10, No.3, pp.237-249.
- Bruno CA, Eisengart JA, Radenbaugh PA, Moroi SE. (2006). Subconjunctival placement of human amniotic membrane during high risk glaucoma filtration surgery. *Ophthalmic Surg Lasers Imaging*, Vol.37, No.3, pp.190-197.
- Chang L, Crowston JG, Cordeiro MF, Akbar AN, Khaw PT. (2000). The role of the immune system in conjunctival wound healing after glaucoma surgery. *Surv Ophthalmol*, Vol.45, No.1, pp.49-68.
- Chen CW, Huang HT, Bair JS, Lee CC. (1990). Trabeculectomy with simultaneous topical application of mitomycin-C in refractory glaucoma. *J Ocul Pharmacol*, Vol.6, No.3, pp.175-182.
- Chen C. (1983). Enhanced intraocular pressure controlling effectiveness of trabeculectomy by local application of mitomycin C. *Trans Asia Pac Acad Ophthalmol*, Vol.9, pp.172-177.
- Chihara E, Dong J, Ochiai H, Hamada S. (2002). Effects of tranilast on filtering blebs: a pilot study. *J Glaucoma*, Vol.11, No.2, pp.127-133.
- Chintala SK, Wang N, Diskin S, Mattox C, Kagemann L, Fini ME, Schuman JS. (2005). Matrix metalloproteinase gelatinase B (MMP-9) is associated with leaking glaucoma filtering blebs. *Exp Eye Res*, Vol.81, No.4, pp.429-436.
- Choi JY, Choi J, Kim YD. (2010). Subconjunctival bevacizumab as an adjunct to trabeculectomy in eyes with refractory glaucoma: a case series. *Korean J Ophthalmol*, Vol.24, No.1, pp.47-52.
- Coote MA, Ruddle JB, Qin Q, Crowston JG (2008). Vascular changes after intra-bleb injection of bevacizumab. *J Glaucoma* Vol.17, No., pp.517-518.
- Demir T, Turgut B, Akyol N, Ozercan I, Ulas F, Celiker U. (2002). Effects of amniotic membrane transplantation and mitomycin C on wound healing in experimental glaucoma surgery. *Ophthalmologica*, Vol.216, No.6, pp.438-442.
- Desjardins DC, Parrish RK, Folberg R, Nevarez J, Heuer DK, Gressel MG. (1986). Wound healing after filtering surgery in owl monkeys. *Arch Ophthalmol*, Vol.104, No.12, pp.1835-1839.
- Desmouliere A, Geinoz A, Gabbiani F, Gabbiani G. (1993). Transforming growth factor-beta 1 induces alpha-smooth muscle actin expression in granulation tissue myofibroblasts and in quiescent and growing cultured fibroblasts. *J Cell Biol*, Vol.122, No.1, pp.103-111.
- Drolsum L, Willoch C, Nicolaissen B. (2006). Use of amniotic membrane as an adjuvant in refractory glaucoma. *Acta Ophthalmol Scand*, Vol.84, No.6, pp.786-789.
- Dvorak HF. (1986). Tumors: wounds that do not heal. Similarities between tumor stroma generation and wound healing. *N Engl J Med*, Vol.315, No.26, pp.1650-1659.
- Eliezer RN, Kasahara N, Caixeta-Umbelino C, Pinheiro RK, Mandia C, Jr., Malta RF. (2006). Use of amniotic membrane in trabeculectomy for the treatment of glaucoma: a pilot study. *Arq Bras Oftalmol*, Vol.69, No.3, pp.309-312.


- Fujishima H, Shimazaki J, Shinozaki N, Tsubota K. (1998). Trabeculectomy with the use of amniotic membrane for uncontrolled glaucoma. *Ophthalmic Surg Lasers*, Vol.29, pp.428-431.
- Fujita H. (1982). [Pharmacokinetics of mitomycin C and its derivative (KW-2083)]. *Gan To Kagaku Ryoho*, Vol.9, No.8, pp.1362-1373.
- Greenfield DS, Parrish RK. (1996). Bleb rupture following filtering surgery with mitomycin-C: clinicopathologic correlations. *Ophthalmic Surg Lasers*, Vol.27, No.10, pp.876-877.
- Greenfield DS, Suner IJ, Miller MP, Kangas TA, Palmberg PF, Flynn HW, Jr. (1996). Endophthalmitis after filtering surgery with mitomycin. *Arch Ophthalmol*, Vol.114, No.8, pp.943-949.
- Guerriero E, Yu JU, Kahook MY. (2006) Morphologic evaluation of bevacizumab (Avastin) treated corneal stromal fibroblasts. *Invest Ophthalmol Vis Sci*, Vol.47, E-Abstract 1642.
- Grierson I, Joseph J, Miller M, Day JE. (1988). Wound repair: the fibroblast and the inhibition of scar formation. *Eye (Lond)*, Vol.2 (Pt 2), pp.135-148.
- Heuer DK, Parrish RK, Gressel MG, Hodapp E, Palmberg PF, Anderson DR. (1984). 5-fluorouracil and glaucoma filtering surgery. II. A pilot study. *Ophthalmology*, Vol.91, No.4, pp.384-394.
- Hosseini H, Mehryar M, Farvardin M. Focus on triamcinolone acetate as an adjunct to glaucoma filtration surgery. *Med Hypotheses* 2007;68:401– 403
- Kahook MY, Schuman JS, Noecker RJ. (2006a). Intravitreal bevacizumab in a patient with neovascular glaucoma. *Ophthalmic Surg Lasers Imaging*, Vol.37, No.2, pp.144-146.
- Kahook MY, Schuman JS, Noecker RJ. (2006b). Needle bleb revision of encapsulated filtering bleb with bevacizumab. *Ophthalmic Surg Lasers Imaging*, Vol.37, No.2, pp.148-150.
- Kapetansky FM, Pappa KS, Krasnow MA, et al (2007). Subconjunctival injection(s) of bevacizumab for failing filtering blebs. *Invest Ophthalmol Vis Sci* 2007 [E-Abstract 837
- Kitazawa Y, Kawase K, Matsushita H, Minobe M. (1991). Trabeculectomy with mitomycin. A comparative study with fluorouracil. *Arch Ophthalmol*, Vol.109, No.12, pp.1693-1698.
- Lama PJ, Fechtner RD. (2003). Antifibrotics and wound healing in glaucoma surgery. *Surv Ophthalmol*, Vol.48, No.3, pp.314-346.
- Lee S-B, Li D-Q, Tan DTH, Meller D, Tseng SCG. (2000). Suppression of TGF- β signaling in both normal conjunctival fibroblasts and pterygial body fibroblasts by amniotic membrane. *Curr Eye Res*, Vol.20, pp.325-334.
- Leibovich SJ, Ross R. (1975). The role of the macrophage in wound repair. A study with hydrocortisone and antimacrophage serum. *Am J Pathol*, Vol.78, No.1, pp.71-100.
- Li W, He H, Kawakita T, Espana EM, Tseng SCG. (2006). Amniotic membrane induces apoptosis of interferon-gamma activated macrophages in vitro. *Exp Eye Res*, Vol.82, No.2, pp.282-292.
- Lu H, Mai D. (2003). [Trabeculectomy combined amniotic membrane transplantation for refractory glaucoma]. *Yan Ke Xue Bao*, Vol.19, No.2, pp.89-91.
- Manzano RP, Peyman GA, Khan P, Kivilcim M. (2006). Testing intravitreal toxicity of bevacizumab (Avastin). *Retina*, Vol.26, No.3, pp.257-261.
- Mast BA, Diegelmann RF, Krummel TM, Cohen IK. (1992). Scarless wound healing in mammalian fetus. *Surgery*, Vol.174, pp.441-451.

- Maumenee AE. (1960). External filtering operations for glaucoma: the mechanism of function and failure. *Trans Am Ophthalmol Soc*, Vol.58, pp.319-328.
- Meyer-ter-Vehn T, Sieprath S, Katzenberger B, Gebhardt S, Grehn F, Schlunck G. (2006). Contractility as a prerequisite for TGF-beta-induced myofibroblast transdifferentiation in human tenon fibroblasts. *Invest Ophthalmol Vis Sci*, Vol.47, No.11, pp.4895-4904.
- Michels S, Rosenfeld PJ, Puliafito CA, Marcus EN, Venkatraman AS. (2005). Systemic bevacizumab (Avastin) therapy for neovascular age-related macular degeneration twelve-week results of an uncontrolled open-label clinical study. *Ophthalmology*, Vol.112, No.6, pp.1035-1047.
- Miller MH, Grierson I, Unger WI, Hitchings RA. (1989). Wound healing in an animal model of glaucoma fistulizing surgery in the rabbit. *Ophthalmic Surg*, Vol.20, No.5, pp.350-357.
- Nguyen KD, Lee DA. Effect of steroids and nonsteroidal anti-inflammatory agents on human ocular fibroblast. *Invest Ophthalmol Vis Sci* 1992;33:2693-2701
- Nuyts RM, Felten PC, Pels E, Langerhorst CT, Geijssen HC, Grossniklaus HE, Greve EL. (1994). Histopathologic effects of mitomycin C after trabeculectomy in human glaucomatous eyes with persistent hypotony. *Am J Ophthalmol*, Vol.118, No.2, pp.225-237.
- Okada K, Sugiyama T, Takai S, Jin D, Ishida O, Fukmoto M, Oku H, Miyazaki M, Ikeda T. (2009). Effects of mitomycin C on the expression of chymase and mast cells in the conjunctival scar of a monkey trabeculectomy model. *Mol Vis*, Vol.15, pp.2029-2036.
- Okamoto Y, Takai S, Miyazaki M. (2004). Significance of chymase inhibition for prevention of adhesion formation. *Eur J Pharmacol*, Vol.484, No.2-3, pp.357-359.
- Ophir A. (1992). Encapsulated filtering bleb. A selective review--new deductions. *Eye*, Vol.6 (Pt 4), pp.348-352.
- Palanca-Capistrano AM, Hall J, Cantor LB, Morgan L, Hoop J, WuDunn D. (2009). Long-term outcomes of intraoperative 5-fluorouracil versus intraoperative mitomycin C in primary trabeculectomy surgery. *Ophthalmology*, Vol.116, No.2, pp.185-190.
- Parrish RK, Schiffman JC, Feuer WJ, Heuer DK. (2001). Prognosis and risk factors for early postoperative wound leaks after trabeculectomy with and without 5-fluorouracil. *Am J Ophthalmol*, Vol.132, No.5, pp.633-640.
- Purcell JM, Teng CC, Tello C, et al (2008). Effect of needle bleb revision with ranibizumab as a primary intervention in a failing bleb following trabeculectomy. *Invest Ophthalmol Vis Sci* 2008. [E-Abstract 4165]
- Reichel MB, Cordeiro MF, Alexander RA, Cree IA, Bhattacharya SS, Khaw PT. (1998). New model of conjunctival scarring in the mouse eye. *Br J Ophthalmol*, Vol.82, No.9, pp.1072-1077.
- Ross R, Rainee EW, Bowen-Pope DF. (1986). The biology of platelet-derived growth factor. *Cell*, Vol.46, pp.155-169.
- Sano-Kato N, Fukagawa K, Okada N, Kawakita T, Takano Y, Dogru M, Tsubota K, Fujishima H. (2005). TGF-beta1, IL-1beta, and Th2 cytokines stimulate vascular endothelial growth factor production from conjunctival fibroblasts. *Exp Eye Res*, Vol.80, No.4, pp.555-560.

- Sheha H, Liang L, Tseng SCG (2010). Amniotic Membrane Grafts for Glaucoma Surgery. In: Paul N.Schacknow, John R.Samples, editors. *The Glaucoma Book; A Practical, Evidence-Based Approach to Patient Care*. New York:Springer. p. 861-869.
- Sheha H, Kheirkhah A, Taha H. (2008). Amniotic membrane transplantation in trabeculectomy with mitomycin C for refractory glaucoma. *J Glaucoma*, Vol.17, No.4, pp.303-307.
- Sherwood MB. (2006). A sequential, multiple-treatment, targeted approach to reduce wound healing and failure of glaucoma filtration surgery in a rabbit model (an American Ophthalmological Society thesis). *Trans Am Ophthalmol Soc*, Vol.104, pp.478-492.
- Shey E, He H, Sakurai S, Tseng SC. (2011) Inhibition of Angiogenesis by HC{middle dot}HA, a Complex of Hyaluronan and the Heavy Chain of Inter-{alpha}-Inhibitor, Purified from Human Amniotic Membrane. *Invest Ophthalmol Vis Sci*. [Epub ahead of print]
- Shields MB, Scroggs MW, Sloop CM, Simmons RB. (1993). Clinical and histopathologic observations concerning hypotony after trabeculectomy *with* adjunctive mitomycin C. *Am J Ophthalmol*, Vol.116, pp.673-683.
- Shuster JN, Krupin T, Kolker AE, Becker B. (1984). Limbus- v fornix-based conjunctival flap in trabeculectomy. A long-term randomized study. *Arch Ophthalmol*, Vol.102, No.3, pp.361-362.
- Singh K, Mehta K, Shaikh NM, Tsai JC, Moster MR, Budenz DL, Greenfield DS, Chen PP, Cohen JS, Baerveldt GS, Shaikh S. (2000). Trabeculectomy with intraoperative mitomycin C versus 5-fluorouracil. Prospective randomized clinical trial. *Ophthalmology*, Vol.107, No.12, pp.2305-2309.
- Skuta GL, Parrish RK. (1987). Wound healing in glaucoma filtering surgery. *Surv Ophthalmol*, Vol.32, No.3, pp.149-170.
- Starita RJ, Fellman RL, Spaeth GL, Poryzees EM, Greenidge KC, Traverso CE. (1985). Short- and long-term effects of postoperative corticosteroids on trabeculectomy. *Ophthalmology*, Vol.92, No.7, pp.938-946.
- Sturmer J, Broadway DC, Hitchings RA. (1993). Young patient trabeculectomy. Assessment of risk factors for failure. *Ophthalmology*, Vol.100, No.6, pp.928-939.
- Tham CC, Li FC, Leung DY. Intra-bleb triamcinolone acetate injection after bleb-forming filtration surgery (trabeculectomy, phacotrabeculectomy, and trabeculectomy revision by needling): a pilot study. *Eye* 2006;20:1484 -1486.
- Traverso CE, Tomey KF, Antonios S. (1987). Limbal- vs fornix-based conjunctival trabeculectomy flaps. *Am J Ophthalmol*, Vol.104, No.1, pp.28-32.
- Tseng SCG, Espana EM, Kawakita T, Di Pascuale MA, Wei Z-G, He H, Liu TS, Cho TH, Gao YY, Yeh LK, Liu C-Y. (2004). How does amniotic membrane work? *The Ocular Surface*, Vol.2, No.3, pp.177-187.
- Tseng SCG, Li D-Q, Ma X. (1999). Suppression of Transforming Growth Factor isoforms, TGF- β receptor II, and myofibroblast differentiation in cultured human corneal and limbal fibroblasts by amniotic membrane matrix. *J Cell Physiol*, Vol.179, pp.325-335.
- Wang L, Liu X, Zhang P, Lin J. (2005). [An experimental trial of glaucoma filtering surgery with amniotic membrane]. *Yan Ke Xue Bao*, Vol.21, No.2, pp.126-131.
- Wipff PJ, Rifkin DB, Meister JJ, Hinz B. (2007). Myofibroblast contraction activates latent TGF- β 1 from the extracellular matrix. *J Cell Biol*, Vol.179, No.6, pp.1311-1323.

- Wong J, Wang N, Miller JW, Schuman JS. (1994). Modulation of human fibroblast activity by selected angiogenesis inhibitors. *Exp Eye Res*, Vol.58, No.4, pp.439-451.
- WuDunn D, Cantor LB, Palanca-Capistrano AM, Hoop J, Alvi NP, Finley C, Lakhani V, Burnstein A, Knotts SL. (2002). A prospective randomized trial comparing intraoperative 5-fluorouracil vs mitomycin C in primary trabeculectomy. *Am J Ophthalmol*, Vol.134, No.4, pp.521-528.
- Yue J, Hu CQ, Lei XM, Qin GH, Zhang Y. (2003). Trabeculectomy with amniotic membrane transplantation and combining suture lysis of scleral flap in complicated glaucoma. *Zhonghua Yan Ke Za Zhi*, Vol.39, No.8, pp.476-480.
- Yuki K, Shiba D, Kimura I, Ohtakey Y, Tsubota K. Trabeculectomy With or Without Intraoperative Sub-Tenon Injection of Triamcinolone Acetonide in Treating Secondary Glaucoma *Am J Ophthalmol* 2009;147:1055-1060
- Zhong Y, Zhou Y, Wang K. (2000). Effect of amniotic membrane on filtering bleb after trabeculectomy in rabbit eyes. *Yan Ke Xue Bao*, Vol.16, No.2, pp.73-6, 83.

IntechOpen



Glaucoma - Basic and Clinical Concepts

Edited by Dr Shimon Rumelt

ISBN 978-953-307-591-4

Hard cover, 590 pages

Publisher InTech

Published online 11, November, 2011

Published in print edition November, 2011

This book addresses the basic and clinical science of glaucomas, a group of diseases that affect the optic nerve and visual fields and is usually accompanied by increased intraocular pressure. The book incorporates the latest development as well as future perspectives in glaucoma, since it has expedited publication. It is aimed for specialists in glaucoma, researchers, general ophthalmologists and trainees to increase knowledge and encourage further progress in understanding and managing these complicated diseases.

How to reference

In order to correctly reference this scholarly work, feel free to copy and paste the following:

Hosam Sheha (2011). Update on Modulating Wound Healing in Trabeculectomy, Glaucoma - Basic and Clinical Concepts, Dr Shimon Rumelt (Ed.), ISBN: 978-953-307-591-4, InTech, Available from: <http://www.intechopen.com/books/glaucoma-basic-and-clinical-concepts/update-on-modulating-wound-healing-in-trabeculectomy>

INTECH
open science | open minds

InTech Europe

University Campus STeP Ri
Slavka Krautzeka 83/A
51000 Rijeka, Croatia
Phone: +385 (51) 770 447
Fax: +385 (51) 686 166
www.intechopen.com

InTech China

Unit 405, Office Block, Hotel Equatorial Shanghai
No.65, Yan An Road (West), Shanghai, 200040, China
中国上海市延安西路65号上海国际贵都大饭店办公楼405单元
Phone: +86-21-62489820
Fax: +86-21-62489821

© 2011 The Author(s). Licensee IntechOpen. This is an open access article distributed under the terms of the [Creative Commons Attribution 3.0 License](https://creativecommons.org/licenses/by/3.0/), which permits unrestricted use, distribution, and reproduction in any medium, provided the original work is properly cited.

IntechOpen

IntechOpen