

We are IntechOpen, the world's leading publisher of Open Access books Built by scientists, for scientists

6,900

Open access books available

185,000

International authors and editors

200M

Downloads

Our authors are among the

154

Countries delivered to

TOP 1%

most cited scientists

12.2%

Contributors from top 500 universities



WEB OF SCIENCE™

Selection of our books indexed in the Book Citation Index
in Web of Science™ Core Collection (BKCI)

Interested in publishing with us?
Contact book.department@intechopen.com

Numbers displayed above are based on latest data collected.
For more information visit www.intechopen.com



A Vascular Approach to Glaucoma

Luís Abegão Pinto¹ and Ingeborg Stalmans²

¹*Department Ophthalmology, CHLC Lisbon,*

²*Department Ophthalmology, UZ Leuven,*

¹*Portugal*

²*Belgium*

1. Introduction

Despite the tremendous impact of glaucoma on the vision of our elderly population, the mechanisms of glaucomatous neuropathy have not been fully elucidated. Intra-ocular pressure (IOP) has been convincingly identified as the main risk factor for glaucoma development and progression, and IOP lowering, therefore, is the hallmark of glaucoma therapy. However, a certain proportion of glaucoma patients continue to show disease progression despite “optimal” IOP control. This observation has been a great motivation for the quest for discovering pathogenic mechanisms beyond IOP.

Besides IOP, glaucomatous optic neuropathy has also been associated with various causes of impaired blood flow, such as hypotension, migraine or peripheral vasospasm, and laboratory evidence of ocular and systemic vasodysregulation. These observations support the idea that the eye being treated for glaucoma is likely part of a wider systemic dysfunction, particularly blood flow dysregulation. The ophthalmologist with interest in glaucoma is thus confronted with the need to know what to recognise as a vascular risk factor, how to diagnose vascular dysfunction, which tools are available to study it and what the possibilities for improving such blood flow impairment are. To better understand the complexity and systemic nature of this multifactorial neuropathy, ophthalmologists must look beyond the eye.

2. Anatomic considerations and clinical relevance

The need for extensive knowledge about the vascular anatomy of the eye and especially the optic nerve is universal to all ophthalmologists. The complexities of the arterial branching and supply network for each anatomical compartment in the eye have a number of clinical implications that result from the eye’s unique vascularisation tree.

All blood to the optic nerve comes from the carotid artery through its ophthalmic artery branch. This ophthalmic artery follows a tortuous path inside the orbit towards the anterior nasal orbital wall, crossing the optic nerve as the short posterior ciliary arteries, the long posterior ciliary arteries and the central retinal artery branch off. The anatomical proximity between the optic nerve and major pulsating arteries, such as the carotid artery, has been proposed as a risk factor for optic nerve damage in some normotensional glaucoma patients due to optic nerve compression (Ogata N., 2005).

Glaucomatous neuropathy is characterised by structural damage to the optic nerve head (ONH) and a decrease in the thickness of the retinal nerve fiber layer. While the retinal nerve fiber layer blood supply derives exclusively from the central retinal artery, the ONH blood supply is divided into four anatomic compartments (see table 1). The most anterior, named surface nerve fiber layer, is also supplied by the retinal arteries. The prelaminar and laminar compartments are supplied by branches of the short posterior ciliary artery, which sometimes encircle the ONH, creating the Zinn-Haller ring. A functional anastomosis could theoretically protect the optic nerve from occlusion or hypoperfusion of a single short posterior ciliary artery. The most posterior compartment, the retrolaminar region, is mostly supplied by pial vessels that give off centripetal branches into the septa of the optic nerve.

Arterial vascularisation of the different compartments of the optic nerve head	
Retinal nerve fiber layer	Central retinal artery
Prelaminar	Short posterior ciliary artery
Laminar	Short posterior ciliary artery
Retrolaminar	Pial arteries

Table 1. Overview of main arterial branches supplying the optic nerve head

Regulation of blood flow is also different in the various ocular compartments. As elsewhere in the body, blood flow in the eye should be under the control of the autonomic nervous system. However, as this innervation stops at the level of the lamina cribosa, the retinal circulation is not regulated by sympathetic output. Instead, retinal arteries have the ability through autoregulation to constrict or dilate in response to changes in oxygen or pH and thus maintain a constant metabolic environment despite exposure to conditions that might upset this equilibrium. The choroidal circulation, on the contrary, is under the control of the autonomic nervous system and has no intrinsic ability to adapt to these stimuli. It is able to decrease or increase blood flow in response to cervical sympathetic stimulation, but it cannot adapt to sudden changes in IOP, for example. A clinical consequence of this inability to self-regulate its flow is the uveal effusion that can be seen when opening the eye during surgery. As a consequence of these differences in vasoreactive mechanisms, the response to medical therapy also differs between these vascular beds. Phosphodiesterase inhibitors, for example, clearly enhance choroidal flow by increasing nitric oxide concentration, whereas the retinal circulation does not significantly change in response to this drug (Harris A., 2008).

ONH circulation has particularities that make its study particularly challenging. Like its retinal counterparts, the ONH capillaries lack pre-capillary sphincters; they have pericytes instead. As in the retinal circulation, these pericytes respond to metabolic and neuro-endocrine factors that regulate their contractility. However, while there is no consistent evidence of autonomic nervous system directly regulating ONH blood flow, the lack of a cellular barrier separating the ONH from the choroid tissues could make the ONH susceptible to autonomic stimulations. As both are supplied by the same vessels, imbalances in the choroidal blood flow could redirect blood flow away from the ONH.

The venous drainage of the entire retina and ONH takes place through the central retina vein. Although not directly involved in aqueous humour drainage, the central vein has been

studied for glaucoma progression purposes. Indeed, there seems to be a relationship between spontaneous venous pulsations and glaucoma progression, suggesting the lack of spontaneous pulsations as a risk factor for progression visual field damage (Balaratnasingam C., 2007) (Nicollela, 2007).

The aqueous humour, however, is drained from Schlemm’s canal through the episcleral veins. Therefore, an increase in venous pressure leads to a decrease in drainage due to passive diffusion. Altered vein reactivity or systemically increased vein pressure can lead to an increase in IOP. Increased episcleral venous pressure in glaucoma patients may be one mechanism behind the nocturnal rise in IOP many of these patients present (Liu JH., 1999).

3. Tools to study ocular blood flow

There are an increasing number of tools that can provide insight into different aspects of ocular blood flow (OBF) in various vascular beds in and around the eye. A full description of all the techniques is beyond the scope of this book, and thus, we will focus on succinctly describing the most commonly used methods.

Colour Doppler imaging (CDI) is a non-invasive ultrasound-based technology that uses the Doppler effect to measure blood velocities. This technique can provide information on the ophthalmic artery, short posterior ciliary arteries (divided into temporal and nasal groups) and the central retinal artery (figure 1). It describes peak systolic velocities (PSV), end-diastolic velocities (EDV), resistance index (RI) (Pourcelot, 1975) and, in some devices, the mean flow velocities (MFV) and the pulsatility index (PI) (Gosling, 1971). These two indices can be calculated using the following formulas: $RI = (PSV-EDV)/PSV$ and $PI = (PSV-EDV)/MFV$. CDI is not dependent on optical transparency or pupil size. The downside of this technology, however, is that it provides only blood velocities. To calculate blood flow from these velocities, the vessel diameter would have to be known. However, the diameter of the retrobulbar vessels cannot be measured with high precision with this technique, making blood flow calculations uncertain (Zeitz, 2006). As with any ultrasound-based technique, it is highly observer-dependent, and good reproducibility requires an experienced technician. A consensus is needed to define standard operating procedures, thus reducing such bias, so that valid comparisons can be made between the results from different centers.

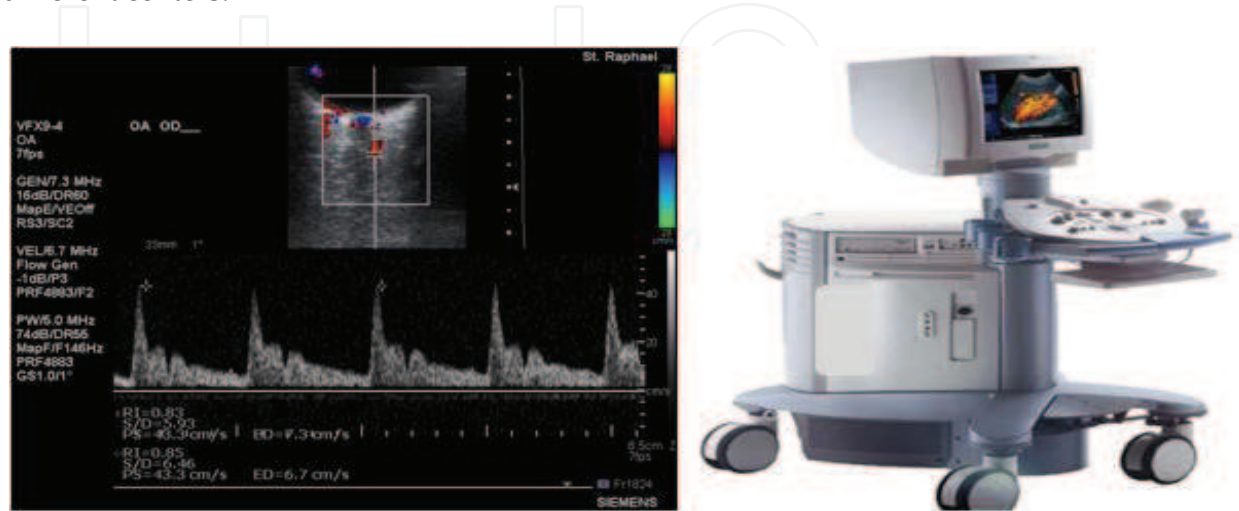


Fig. 1. CDI data printout (left); CDI device (right)

Laser Doppler flowmetry (LDF) utilises a fundus camera and non-invasive confocal laser flowmetry using the Doppler effect to measure retinal capillary blood flow. This confocal system provides individual data points from each analysed vessel, allowing the information to be interpreted on a pixel-to-pixel level by several different types of automated software, all of which have a very good coefficient of reproducibility (figure 2). Although this technique provides volumetric measurements, it does so in arbitrary units, which is the major drawback of this technology. As with any fundoscopic-based evaluation, it is dependent on clear optical media, pupil size and the fixation capability of the patient.

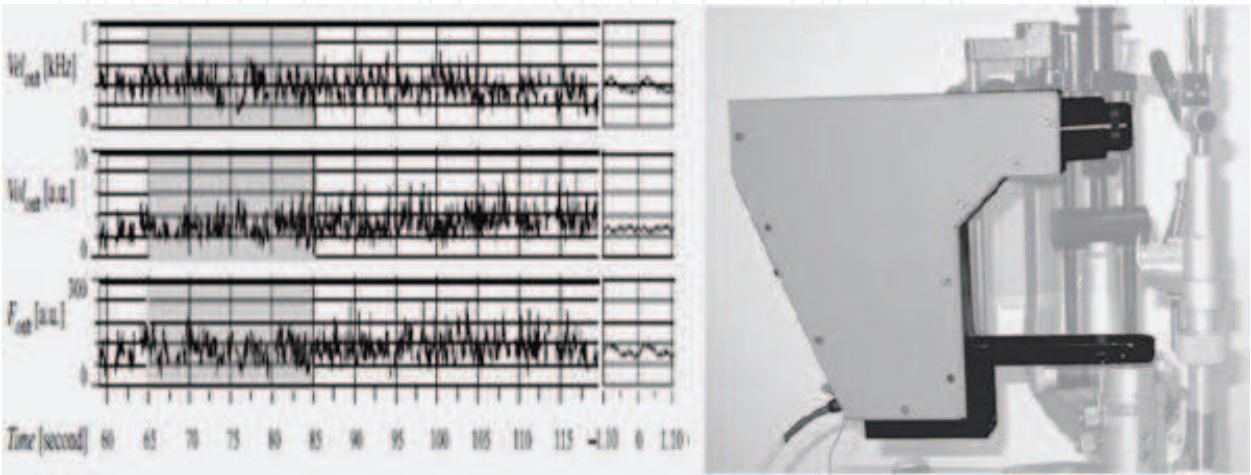


Fig. 2. LDF printout data (left); LDF device (right) (courtesy of Charles Riva; reproduced with permission from Acta Ophthalmologica)

Doppler optical coherence tomography (OCT) is another device that uses the Doppler frequency shift. Recent technological advances have allowed this technology to be added to Fourier-domain OCT, making it possible to determine the velocity of the blood inside the major retinal vessels and the cross-sectional diameter of these vessels throughout the cardiac cycle. This allows for a volumetric assessment of the flow rate while taking into account background motion, beam incidence angle and pulsation (figure 3). However, this device is still under further development and has currently a limited clinical application.

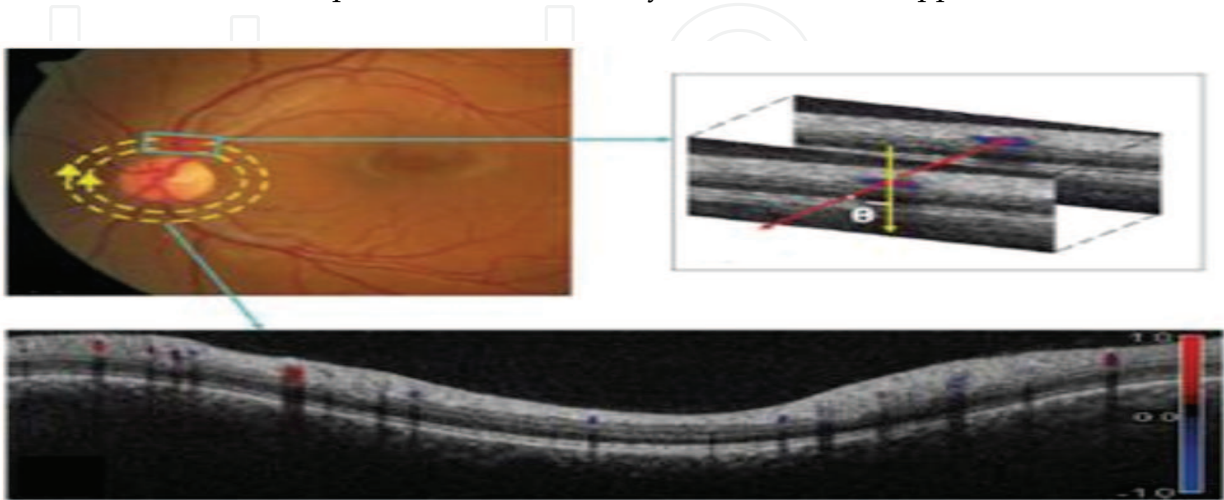


Fig. 3. Doppler OCT image printout (courtesy of David Huang)

The *retinal vessel analyser* (RVA) also relies on a fundus camera and uses vessel diameter analysis software. It allows for real-time retinal vessel diameter measurements with a maximum frequency of 50 Hz (figure 4). Although it provides measurements in arbitrary units, an approximation can be made to microns. The main advantage of this technique is the real-time acquisition, which allows for the simultaneous investigation of different vessels and vascular segments. In contrast to CDI, this technology can measure vessel diameter but not the velocity of the blood within the vessel. It is again influenced by optical media transparency and requires pupil dilation, which may affect blood flow itself.




Fig. 4. RVA data printout (left); RVA device (right) (courtesy of Gerhard Garhofer; reproduced with permission from Acta Ophthalmologica)

Retinal oximetry is a non-invasive method for assessing the haemoglobin oxygen saturation in the retinal vessels. It relies on digital fundus photography coupled with a beam splitter and a filter that discriminates different bandwidths. Using both an oxygen-sensitive and an oxygen-insensitive bandwidth, it can determine the oxygen saturation of the retinal vessels in comparison to the retinal background (figure 5). It is used to study *in vivo* the metabolic needs of the retina and its ability to react to stimuli, either pharmacological or physiological. Its drawbacks are related to the lack of information about the oxygenation of the optic nerve itself, as only retinal vessels are analysed, and the need for pupil dilation and clear optic media.

Dynamic contour tonometry (DCT) represents a device for non-invasive continuous measurement of IOP. Contrary to applanation tonometers, its concave contact surface allows for the equal distribution of forces between the device and the cornea as the pressure applied by the observer equals the pressure inside the eye. Because it allows for a continuous reading, a sinusoidal variation can be registered (figure 6). The difference between the highest and the lowest IOP is called the ocular pulse amplitude (OPA) (figure 3). This parameter probably relates to the blood volume that is pumped into the eye during each cardiac cycle, and it may represent choroidal blood flow or the pulsatile component itself. It has an acceptable intra- and inter-observer variability. Factors modulating this amplitude are not fully understood. It is not dependent on corneal thickness, but it positively correlates with IOP and negatively with axial length. An algorithm that transforms this pressure amplitude into blood flow is not yet available.

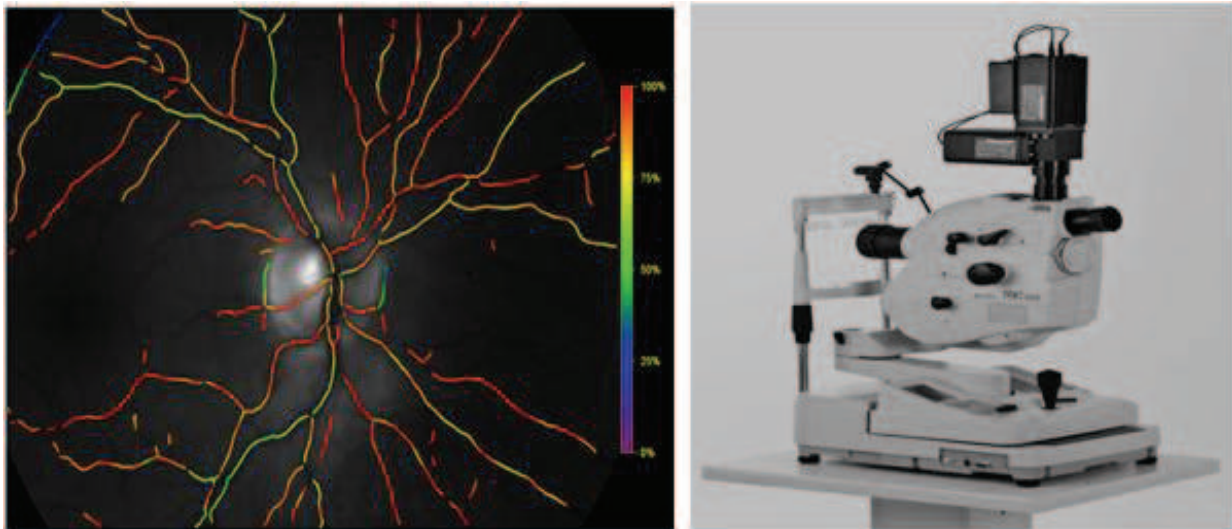


Fig. 5. Retinal oximetry data printout (left); retinal oximetry device (right) (reproduced with permission from Oxymap ©)

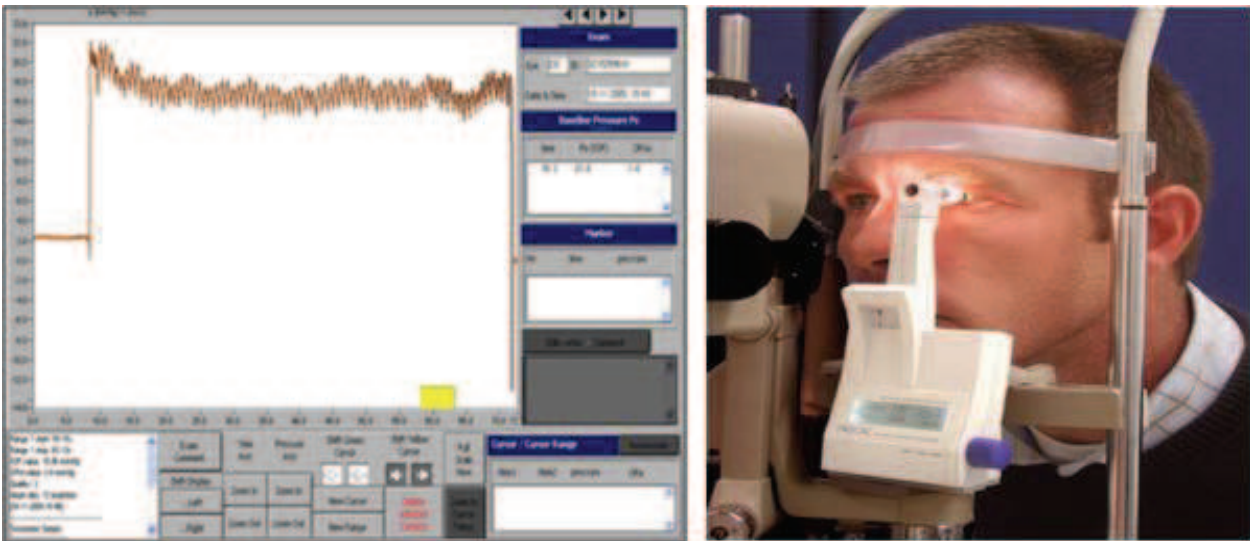


Fig. 6. DCT data printout (left) (courtesy of C. Marques-Neves); DCT device (right) (reproduced with permission from Ziemer Ophthalmic ©)

The *pulsatile ocular blood flow (POBF)* analyser is a modified pneumotonometer that also measures ocular pulse. As with DCT, this device also allows for digital recording of the sinusoidal intra-ocular pressure curve throughout the cardiac cycle (figure 7). However, this device actually indents the cornea instead of adapting to its surface. Its similarities to DCT are reflected in its limitations. While changes in POBF measures are assumed to be related to choroidal blood flow, due to its greater significance to the overall OBF, this cannot be directly tested. Structurally, POBF also negatively correlates with axial length while still being more sensitive to changes in cornea thickness than DCT. It is nevertheless an inexpensive and simple to operate device that can produce data related to blood flow, such as changes in ocular pulse volume, duration of systole and diastole and the maximum speed of blood flowing into the eye (in $\mu\text{l/s}$).




Fig. 7. POBF analyser data printout (left); POBF analyser device (right) (reproduced with permission from Paradigm Medical Industries Inc)

	Anatomic region of blood flow studied	Contact	Arbitrary units	Clear media	Pupil dilation
CDI	Retrobulbar	Yes	No	No	No
Laser Doppler Flowmetry	Retinal	No	Yes	Yes	Yes
Doppler OCT	Retinal	No	No	Yes	Yes
Retinal vessel Analyser	Retinal	No	Yes	Yes	Yes
Retinal oximetry	Retinal	No	No	Yes	Yes
DCT	Choroid?	Yes	No	No	No
POBF analyser	Choroid?	Yes	No	No	No

Table 2. Overall description of OBF measuring tools

4. Altered blood flow as a risk factor for glaucoma (progression)

There are a growing number of publications showing blood flow disturbances in glaucoma patients that emphasise the role for a vascular component in glaucoma pathogenesis. However, the nature of these disturbances in OBF is still under discussion, including whether such changes are part of the pathogenic mechanism or secondary to the underlying disease. When considering ocular diseases in which vascular mechanisms are involved, such as diabetic retinopathy or occlusion of the central retinal artery or vein, none of these diseases produce a characteristic glaucomatous cupping of the disc (Jonas, 1993) (Jonas, 1999). Therefore, hypoperfusion, as seen in those diseases, does not provide a full explanation for glaucomatous neuropathy. Should hypoperfusion alone represent the vascular risk factor for glaucoma (progression), one would expect a stronger relationship between glaucoma and known risk factors for atherosclerosis, such as C-reactive protein or dyslipidaemias. However, data on these variables is far from consistently pointing them out as risk factors for glaucoma (de Voogd, 2006). Alternatively, or in addition to hypoperfusion, there may be a vascular dysfunction that compromises the normal self-regulating mechanisms of the vessels supplying ONH in response to hypoperfusion (Sossi, 1983). Interestingly, the ONH, due to its unique anatomical condition, is exposed to circulating hormones in a way that the rest of the central nervous system is not. Not only is

the barrier function decreased in the capillaries in this region (Grieshaber, 2007), but there is also diffusion from the choroid, where these mechanisms do not exist (Flage, 1977). Vasoconstrictive agents, such as angiotensin II and endothelin, could therefore have a greater impact in this region than elsewhere in the nervous system. Available data suggest that glaucoma patients may have an endothelial dysfunction with increased levels of endothelin and vasodilation impairment, thus increasing the risk for ONH injury.

Such dysfunction, as suggested by Flammer, would not lead to a stable reduction in OBF but rather to an instability of ocular perfusion, leading to a repeated mild reperfusion injury (Flammer, 2006) (Flammer J., 1999). This mechanism of ischaemia-reperfusion injury is associated with the generation of reactive oxygen species and cellular apoptosis. These reactive oxygen species induce changes in the trabecular meshwork, possibly resulting in decreased aqueous humour drainage and increased IOP (Saccà, 2007). Additionally, they alter nitric oxide metabolism. Indeed, mitochondrial malfunction due to hypoxia can lead to increased superoxide formation, a metabolite with high affinity for nitric oxide, in a reaction that creates peroxynitrite (Beckman, 1990). This process not only reduces nitric oxide availability but also the ability of this molecule to induce endothelial-dependent dilation (Aslan, 2007). The resulting increase in vasoconstriction and oxidative stress can lead to an activation of several apoptotic pathways through cellular dysfunction (Kim, 1999). It has been suggested that this oxidative stress could also occur as a result of elevated intra-ocular pressure in what seems to be an IOP-related mechanical stress event (Sacca, 2005). In humans, the role of this cellular hypoxia in glaucoma is further supported by increased staining of hypoxia-induced factor (HIF-1 α) in the retina and optic nerve of patients with glaucoma compared with non-glaucomatous individuals (Tezel, 2004).

This endothelial dysfunction believed to exist in glaucoma can also have an impact on rheological factors. In addition to perfusion pressure and local vascular resistance, blood viscosity can also reduce OBF (Flammer, 2002). Glaucoma patients have been described as having decreased erythrocyte deformability (Ates, 1998), hyperaggregability of the erythrocytes (Hamard, 1994) and altered red blood cell membrane integrity (Carter, 1990). In addition, the presence of an activated coagulation cascade (O'Brien, 1997) and an increase in platelet aggregability (Hoyng, 1992) (Bojic, 1998) have been reported in glaucoma patients. It is also possible, however, that these rheological abnormalities are a consequence of the vascular changes. The endothelial cells not only release vasoactive factors abluminally, which influence vascular smooth muscle cells and pericytes, but they also release factors intraluminally that influence blood cells. For instance, nitric oxide, whose impairment in glaucoma patients has been widely described (see above), is a powerful inhibitor of platelet aggregation (Hampton, 1967) (Zhou, 2010).

This impaired self-regulation capacity of the vessels supplying the ONH may be clinically relevant. Recent studies have shown that fluctuations in perfusion pressure are particularly important in glaucoma progression, especially in patients with normotensional glaucoma (Sung, 2009). Glaucoma patients not only have a higher IOP, but they also show circadian vascular rhythms that can tip the balance of perfusion pressure to pathogenic levels. These abnormal circadian cardiovascular responses may be due to an underlying dysautonomic disturbance, as it is the autonomic nervous system's responsibility to regulate these daily rhythms (Appenzeller, 1997). Glaucoma patients seem to have a number of signs of autonomic dysfunction, from dysregulation of aqueous humour production and drainage (Curtis, 2002) to abnormal heart rate and blood pressure variability, both of which are associated with increased cardiovascular risk. This blood pressure variability is particularly

prominent in patients with normotensional glaucoma, and a correlation between the extent of autonomic nervous system dysfunction and the severity of the disease has been suggested (Gherghel, 2004).

Blood pressure itself has been positively correlated with IOP, with a calculated average increase of 0.21 mmHg in IOP for every 10 mmHg increase in blood pressure (Klein, 2005). However, the literature is not conclusive on the impact that arterial hypertension may have on glaucoma. While there are studies showing a correlation between higher blood pressure and a higher prevalence of glaucoma (Tielsch, 1995) (Mitchell, 2004), this has not been the case in the Barbados Study, in which baseline hypertension actually decreased the risk for primary open-angle glaucoma (Leske, 2002). More consistently, a lower ocular perfusion pressure (perfusion pressure = blood pressure-IOP), in particular a lower diastolic OPP, has been associated with a significant increase in the risk for glaucoma (Leske, 2002) (Hulsman CA., 2007). Because measuring the local arterial pressure in the eye is not currently feasible, epidemiologic and other studies calculate ocular perfusion pressure from the brachial artery blood pressure and IOP. In the Baltimore Eye Survey (Tielsch, 1995), a perfusion pressure above 50 mmHg was a predictor for a low risk of optic nerve atrophy. This risk roughly doubled if the perfusion pressure was between 30 and 49 mmHg, and it increased more than 6-fold if the perfusion pressure fell below 30 mmHg. As both IOP and blood pressure show circadian variations, this ocular perfusion pressure can fluctuate during a 24-hour period (Bagga, 2009) (Millar-Craig, 1978). The night-time period, when there is an increase in IOP perfusion of the optic nerve head, may be a particularly vulnerable time for decreases in blood pressure. While the vast majority of the overall population shows a physiological decrease in blood pressure of less than 10%, there are a number of patients who have a decrease of over 20%. These patients are known as big dippers and are considered to be at a higher risk of developing cardiac ischaemia and silent brain damage (Pierdomenico, 1998). These patients may also have an increased risk for glaucoma due to ocular hypoperfusion and ischaemia-reperfusion damage.

Interestingly, deeper glaucomatous visual field defects are associated with a decreased arteriovenous difference in retinal oxygen saturation, possibly indicating decreased oxygen delivery to the retina. These data suggest a change in oxygen metabolism in the glaucomatous retina, possibly related to tissue atrophy (Olafsdottir, 2010). Whether these changes are causes or effects of damage to the retinal ganglion cells is still under debate. IOP is not likely a clinically relevant factor in oxygen saturation, as large decreases in IOP, such as after trabeculectomy, have almost no effect on retinal vessel oxygen saturation (Hardarson, 2009).

A number of studies have shown that this vascular dysfunction and impairment in normal blood flow associated with glaucoma is not restricted to the eye. Indeed, there are also indications of slower flow in peripheral capillary beds (Gasser, 1991) and signs of microvascular encephalopathy, such as white matter lesions (Stroman, 1995). This association between ocular circulation and systemic cardiovascular disease has been extensively studied, with changes in retinal vessel diameters having been shown to predict risk for coronary heart disease, stroke and stroke mortality (Wong, 2001) (Wong, 2002). Pooled data from the Beaver Dam Eye Study and the Blue Mountains Eye Study also show that smaller arterial diameters and larger retinal venous diameters are associated with increased risk for stroke mortality (Wang, 2007). As glaucoma patients also have similar disturbances in retinal arterial diameter (Jonas, 1989), there is clear reasoning for associating glaucoma with cardiovascular dysfunction.

One of the most striking disturbances of clinical importance happening in the ocular vessels is the splinter optic disk haemorrhage, a clinical feature that has been associated with glaucoma progression. These haemorrhages more frequently occur in patients with normotensional glaucoma and are strongly associated with altered circulation within the optic disc (Drance, 1977) (Bengtsson, 1990). Some authors have suggested that these splinter haemorrhages represent distressed small venules (Soares, 2004), as these thinner veins may reflect earlier lamina cribosa changes than their thicker arterial counterparts (Jonas, 2003). Data have indicated that an increased central vein pressure is associated with progressing glaucomatous damage (Balaratnasingam C., 2007), predicts optic disc excavation (Morgan, 2009) and is correlated with visual field defects (Morgan, 2005). This association between glaucoma and increased venous pressure and decreased pulse can help explain why glaucoma is a risk factor for central vein occlusion.

The changes in OBF are not restricted to the retinal vessels, as changes of clinical significance have also been found in the retrobulbar circulation. A number of CDI studies have found reduced peak systolic and diastolic velocities and increased resistivity indices in the retrobulbar vessels of glaucoma patients compared with healthy normal controls (Galassi, 1992), (Trible, 1994) (Harris A, 1994) (Michelson, 1995) (Kaiser, 1997). Interestingly, patients that progress seem to have a more important alteration in blood flow, namely, reduced PSV and EDV in short posterior ciliary arteries (Zeitz O, 2006). Moreover, a prospective study showed that within individuals, the eye with the more pronounced blood flow impairment also showed a faster progression (Drance, 1995). By helping determine patterns associated with a worst disease prognosis, CDI studies may be important in identifying glaucoma patients that are at greater risk for progression.

Other fundoscopic imaging techniques, such as fluorescein angiography, also provide data that are consistent with the CDI data. In normotensional glaucoma patients, for example, filling defects were correlated with lower EDV and increased RI of the short posterior ciliary arteries and with lower blood flow velocities of the central retinal arteries (Plange, 2003). Other imaging techniques have also been consistent in documenting these OBF disturbances in normotensional glaucoma patients. Laser Doppler flowmetry showed a decrease in retinal and optic nerve flow in glaucoma patients (Kerr, 1997) (Grunwald, 1998). Furthermore, measurements of pulsatile OBF showed it to be significantly lower in normotensional glaucoma eyes with or without field-loss than in normal subjects (Fontana, 1998). OPA, the alternative to study the pulsatile component of OBF, is reduced in both primary open angle and normotensional glaucoma patients (Schwenn O., 2002) (Stalmans I., 2008). Moreover, lower OPA values are associated with more advanced visual fields defects (Vulsteke C., 2008). OPA is positively correlated with IOP and negatively correlated with axial length. Its relationship with other blood flow-related parameters is still under discussion. In an initial study, blood pressure was found to be correlated with OPA (Pourjavan, 2007). Subsequent studies could not confirm an impact of blood pressure on OPA (Grieshaber MC., 2009) and found no correlation with the blood pressure amplitude itself (Choi J., 2010). However, there have been case reports of OPA being increased in patients with aortic insufficiency (McKee HD., 2004) and decreased in patients with carotid stenosis (Perkins, 1985). Further reports about increases in OPA after correcting upstream arterial stenosis (Kaufmann C., 2002) give support to the intuitive notion that blood pressure might yet be important. Of note, the studies that have ruled out a relationship between blood pressure and OPA were either performed in young healthy volunteers (Grieshaber MC., 2009) or in glaucoma patients with normal arterial blood pressure (Choi J., 2010).

Recently, it has been proposed that OPA can be related to blood pressure amplitude, specifically in glaucoma patients with arterial hypertension (Pinto, 2010). As mentioned above, choroidal blood flow may be capable of autoregulation (Schmidt KG., 1998). However, such mechanisms may be insufficient to maintain normal blood flow at both high and low extremes. This may result in the transmission of an abnormally high arterial pulse pressure to the choroidal vascular bed, leading to an increased OPA. Furthermore, as the choroid is supplied by the short posterior ciliary arteries, one could expect OPA to reflect changes in those arteries. A CDI study has shown a positive correlation between OPA and the RI in the short posterior ciliary arteries (and ophthalmic and central retinal arteries) in non-glaucomatous subjects. However, no correlation could be found in patients with primary open-angle or normotensional glaucoma, again suggesting a vascular dysregulation in glaucoma patients (Stalmans I., 2009). However, the mechanisms involved in such dysregulation in glaucoma are not yet completely understood.

Although the totality of these observations provides a strong indication for blood flow disturbances to be related to glaucoma, many uncertainties remain. One of the questions that remain to be answered is whether the decreased blood flow is actually involved in the aetiology of glaucoma or whether it is secondary to a loss of retinal ganglion cells and a decrease in the corresponding metabolic demand for oxygen and nutrients. There are indications that the reduction in OBF precedes the glaucomatous damage (Costa, 1994) (Kaiser, 1997), which contradicts the objection that the observed OBF impairment might be solely secondary to tissue atrophy.

The extent of the damage induced by OBF alone is difficult to determine. OBF changes *per se* might lead to glaucoma damage, but they could also synergistically act with other risk factors. For example, OBF disturbances might act as a sensitiser to IOP, making it possible for normal-range values of IOP to produce damage. Finally, while these vascular disturbances exist and are associated with (particularly progressive) glaucoma, there is still very little evidence that improving blood flow in glaucoma patients might change the course of their disease.

5. Clinical approach

When assessing possible vascular issues in glaucoma patients, it may be useful to consider the following two aspects: 1. systemic conditions that are associated with an overall vascular dysfunction and 2. external influences from lifestyle, diet or current medication that may negatively affect the patient's OBF.

5.1 A sick eye in a sick body

As referred to by Flammer, glaucoma may well be an ocular disease that is part of a wider systemic condition (Pache, 2006). As such, the ophthalmologist may inquire for signs of vascular dysfunction that have been associated with glaucoma, namely, peripheral vasospasm, Raynaud phenomenon and migraine. Other cardiovascular conditions, like blood pressure fluctuations, irregular heart rate and vascular resistance or obstruction, might influence OBF and are thus worth attention.

Blood pressure, for instance, has been extensively studied with regard to its impact on glaucoma. Changes in ocular perfusion pressure are well established as a risk factor for glaucoma progression (see above). On the one hand, high values of blood pressure can be deleterious to the retina and optic nerve (Caprioli, 2010). As it can be associated with an

increase in overall mortality, blood pressure should remain below the 140/90 threshold or below 125/75 in a diabetic patient with microproteinuria (Chobanian, 2003). On the other hand, blood pressure values are subject to change during the 24-hour period. The combination of the otherwise physiological decrease in blood pressure during the night and the otherwise normal nocturnal increase in IOP can lead to a severe decrease in ocular perfusion pressure (Leske, 2002). The magnitude of this blood pressure nocturnal dip in glaucoma patients correlates with visual field progression, as greater nocturnal dips were associated with progressive visual field defects (Graham, 1999). Idiopathic blood pressure dippers exist, especially in patients with signs of autonomic dysfunction. Importantly, iatrogenic-induced blood pressure dipping due to over-medication for arterial hypertension should also be kept in mind as a possible cause of unexplained visual field progression despite good IOP control. Additionally, the quality of sleep can alter an individual's blood pressure dip status (Sei, 1999). Obstructive sleep apnoea syndrome, characterised by snoring, excessive daytime sleepiness, and insomnia, has been proposed as a glaucoma risk factor (Walsh, 1982). The incidence of glaucoma in patients with sleep apnoea syndrome has been described to range from 7.2 to up to 50% (Mojon, 1999) (Onen SH, 2000), with the latter figure likely corresponding to normotensional glaucoma patients (Mojon, 2002). Obstructive sleep apnea syndrome, which is due to intermittent collapse of the upper airway, leads to insufficient tissue oxygenation. Concomitantly, the produced negative intra-thoracic pressure leads to reflex activation of the adrenergic system with increased peripheral resistance (Gherghel, 2004). These combined actions may aggravate an underlying endothelial dysfunction and impair autoregulation by the vessels supplying blood to the eye (Dean, 1993). Data connecting sleep apnoea with glaucoma, especially normotensional glaucoma, is mounting, with authors claiming a correlation between sleep apnoea and a decrease in the retinal nerve fibre layer (Kargi, 2005) and with an increase in both perimetric mean defect and resistance index of the central retinal artery (Karakucuk, 2008).

Blood pressure dipping has been addressed in some patients by prescribing fludrocortisone (Gugleta, 1999) or salt tablets (Pechère-Betschi, 1998) as intra-vascular volume expanders. Fludrocortisone treatment in glaucoma patients may not only slightly increase blood pressure and reduce nocturnal dips but also improve the regulation of blood flow indirectly (Gugleta, 1999). Patients with sleep apnoea should be counselled towards weight loss and avoidance of alcohol and sedatives. Mechanical measures, including continuous or bilevel positive airway pressure devices, may also be used.

One of the clinical signs for the vascular impact of glaucoma is the presence of vasospasm. Not to be mistaken for Raynaud syndrome, patients with symptoms of cold hands, sometimes cold feet and a tendency towards low blood pressure should be investigated as whether they have primary vasodysregulation syndrome (Flammer, 2001). The vasospastic prototype patient has a low body mass index, is frequently intellectual and is a (pre-menopausal) female (Prunte-Glowazki, 1991) (Harada, 1991) (Flammer, 2006). They have different sensitivities to medications, such as beta blockers or calcium channel blockers. In such patients, the desired pharmacological effect may be achieved by a lower dosage of such drugs (Flammer, 2001). Patients presenting with this inborn dysfunction of vascular endothelium have inappropriate constriction or insufficient dilatation in the microcirculation (Flammer, 1996). This leads to ischaemia-reperfusion damage (see above) in what seems to be an endothelin-related phenomenon (Flammer J., 1999). Being a systemic condition, these patients are prone to ischaemia in other organs, not just the eye. The heart or the inner ear, for example, are likely to show signs of vascular dysfunction-related events, such as silent

cardiac ischaemia (Waldmann, 1996) and benign positional vertigo (Ishiyama, 2000), respectively. Diagnostic procedures have been developed, including nailfold capillaromicroscopy combined with a cold provocation test (Gasser, 1990) or measuring serum endothelin-1 (Miyauchi, 1999). The syndrome is mostly harmless. However, if the patient has symptoms or if the optic nerve head turns pale or even starts to excavate, a clinical evaluation is warranted (Flammer, 2001).

Treatment for vasospasticity in glaucoma patients has tried to establish a safe way to prevent or reverse endothelin-induced vasoconstriction. Antivasospastic treatment with calcium channel blockers in glaucoma patients seems to be helpful, although its usefulness has not yet been firmly established (Yamamoto, 1998) (Tomita, 1999). Short-term studies indicate that calcium channel blockers diminish the effect of increased levels of endothelin-1 on ocular perfusion (Strenn, 1998) and improve visual field defects (Gasser, 1990) (Gaspar, 1994). The same effect can be achieved by CO₂ inhalation, suggesting that the visual function improvements are in fact due to vasodilation (Niwa, 2000).

The blood-brain barrier prevents exposure of the brain to endothelin. Accordingly, brain-located vascular spasms are only slightly correlated with primary vasodysregulation. Nevertheless, migraine is also associated with vascular reactivity. This disease has been consistently pointed out as a risk factor for glaucoma. This evidence is mostly confined to normotensional glaucoma patients because cross-sectional population-based prevalence studies have generally found no significant association between migraine and glaucoma. Nevertheless, migraine was identified as an independent risk factor for progression in the Collaborative Normal-Tension Glaucoma Study (Drance, 2001). Migraine treatment is not only related to pain control but also to the use of vasoactive substances. Prophylaxis of migraine attacks can be achieved by the administration of beta-blockers, which act via a mechanism thought to down regulate the serotonergic and beta-receptor activity involved in initiating the attacks (Evers, 2006). Acute migraine treatment, however, involves drugs with powerful vasoconstrictive activity, such as ergot derivatives and triptans (Silberstein, 2000). Although they produce preferential vasoconstriction of intracranial extracerebral blood vessels due to serotonin receptor binding activity, some have important peripheral activity and are formally contraindicated in patients with Raynaud phenomenon, for instance (Tfelt-Hansen P, 2000). Although there is not enough evidence to draw conclusions on its impact on ONH blood flow, the fact that serotonergic activity may play a significant role in modulating OBF should raise awareness of a possible hypoperfusion of the ONH.

Age is a known risk factor for developing glaucoma. As such, it has also been studied whether age has an impact on OBF. In healthy individuals, CDI showed a decrease in blood flow parameters in both the ophthalmic and central retinal arteries correlating with increasing age (Williamson, 1995) (Lam, 2003). The resistance index of the vessels seems to increase with age, as a possible sign of increased arterial stiffness (Groh, 1996). Different devices have also identified choroidal and optic nerve head blood flow decreases (Ravalico, 1996) (Boehm, 2005). These changes do not seem to stem from a decreased metabolic demand by retina neural cells, as there seems to be no significant correlation between perfusion parameters as measured by scanning laser Doppler flowmetry and retinal nerve fibre layer thickness (Kuba, 2001). However, gender may play a role in age-related changes in OBF, as short posterior ciliary arteries in males is less affected than that in females, with significant differences at EDV and RI levels (Harris, 2000). The Collaborative Normal-Tension Glaucoma trial showed that women were at risk of increased progression (odds ratio: 1.85) after correction for age and IOP (Drance, 2001). Age-related changes are of

particular importance in women, where menopause-induced changes in oestrogen levels induce a number of changes at the cardiovascular level, such as increasing blood pressure and heart rate. At the ocular level, there seems to be an increase in IOP in post-menopausal women but no significant changes in OBF (Siesky, 2000).

Finally, concerns over the optic nerve's OBF must also take into account what can happen upstream of the ophthalmic artery, namely, in the blood flow passing through the carotid artery. Even in unilateral carotid stenosis, there have been reports of bilateral decrease in OBF. Such changes would rely on a patent circle of Willis that would balance blood flow between the two carotid arteries, resulting in a reduced OBF in both eyes (Quaranta, 1997). In patients presenting with unilateral stenosis above 70%, endarterectomy improved PSV in all retrobulbar vessels of the operated side and the PSV in ophthalmic artery and short posterior ciliary arteries of the fellow eye. The perimetric median defect also bilaterally improved, thus supporting the above hypothesis of OBF in one eye influencing the fellow eye (Kozobolis, 2007).

5.2 Systemic medications and other measures

The ophthalmologist should be aware of the complete medical history and treatment of his glaucoma patients, as many systemic medications may have an impact on OBF. Systemic modulators of the cardiovascular responses, such as patient lifestyle or dietary habits, should also be considered.

Anti-hypertensive medications are particularly important because they can change perfusion pressure directly. Calcium channel blockers are one of the most well-studied groups of anti-hypertensive medications. Because they prevent smooth muscle contraction, they are vasodilators that reduce peripheral resistance (Braunwald, 1982). They have been used in glaucoma patients with primary vasodysregulation, where they have shown improvement not only in OBF (Schmidt, 1996) but also in visual field indices (Flammer, 1987). The widespread use of calcium channel blockers has been controversial because of the severe nocturnal hypotension they can induce. Such a hypotensive profile can have severe implications on ocular perfusion pressure. However, the impact on OBF does not seem to be a class effect. Generally speaking, centrally acting calcium channel blockers, such as nimodipine, appear to increase OBF, whereas peripheral agents, such as nifedipine, do not (Lesk, 2008). Magnesium, known as "nature's physiological calcium blocker" (Iseri, 1984), has also been studied regarding its impact on OBF. A small, non-randomised study has shown a statistically significant improvement in peripheral blood flow and a tendency to improve visual field scores in glaucoma patients (Gaspar, 1995). Other hypotensive medications, such as angiotensin-converting enzyme inhibitors or angiotensin receptor antagonists, have also been studied. Both trandolapril, (an angiotensin-converting enzyme inhibitor) (Steigerwalt, 1998), and losartan, (an angiotensin receptor antagonist) (Matulla, 1997), slightly improved OBF in healthy individuals.

Anti-platelet medications and statins are among the most widely prescribed cardiovascular drugs. As both of them have positive impacts on ischaemia-reperfusion damage and oxidative stress, researchers have tried to determine their impact, if any, on OBF and glaucoma. Dipyridamole, a known anti-platelet drug, acts by increasing the levels of adenosine and cyclic adenosine monophosphate. Both metabolites have vasoactive properties that increase coronary vasodilation (Alonso, 1967). In glaucoma patients and anterior ischemic optic neuropathy patients, dipyridamole induced increases in PSV and

EDV in the retrobulbar vessels (Kaiser, 1996). Other more common anti-platelet drugs, such as aspirin, may also have a role in glaucoma. Aspirin may stabilise OBF by decreasing platelet aggregation (Bell, 2004). It may have a neuroprotective role in glutamate-related apoptosis (Ritch, 2000) and may improve the efficiency of prostaglandin analogues in IOP lowering by up-regulating prostaglandin F receptors (Hardy, 1998). No studies, however, have proven these hypothesis. Statins, in contrast, have been the focus of many researchers in OBF. They are the mainstay treatment for hypercholesterolaemia, but thanks to their pleiotropic properties, their vasoactive effects extend beyond their cholesterol-lowering ability. They reduce the incidence of cerebrovascular and cardiovascular events, independently of a patient's blood cholesterol level at baseline (Everett, 2010) (Stroke Prevention by Aggressive Reduction in Cholesterol Levels (SPARCL), 2006). Statins upregulate endothelial nitric oxide synthase and possess antioxidant properties that may ameliorate ischemic oxidative stresses in the brain (Vaughan, 1999) (Cimino, 2007). This vascular endothelial protective effect may have an effect in OBF because statins have been shown to increase the retinal vasculature calibre (Nagaoka, 2006). One may postulate that this dilatation may affect the ONH vasculature as well. Although no study has yet tested for ONH blood flow improvements, a prospective study showed that simvastatin use may be associated with visual field defect stabilisation in patients with normotensional glaucoma (Leung, 2010).

While much controversy exists over the cardiovascular benefits for hormone-replacement therapy, it does not seem to significantly change ONH blood flow. While apparently reducing vascular resistance distal to the ophthalmic artery to levels matching those of younger women, oestrogen replacement has little impact on flow velocities in the short posterior ciliary arteries (Harris-Yitzhak, 2000). While oestrogen alone may not significantly change the risk of developing glaucoma, oestrogen-progestin hormone replacement therapy may be associated with a reduced risk of primary open-angle glaucoma (Pasquale, 2007).

Everyday life activities, food habits and other systemic medications may also affect OBF. Coffee, for example, has been studied regarding its impact on glaucoma and ocular circulation. Caffeine is a xanthine with known cardiovascular effects, such as increasing heart rate and increasing peripheral resistance by vasoconstriction (Bunker, 1979). A placebo-controlled trial in healthy individuals showed that the resistance index of ophthalmic; short posterior ciliary arteries and central retinal arteries were significantly increased after coffee ingestion (Ozkan, 2008). Despite its concomitant ability to mildly increasing IOP, a prospective study did not find an increased risk for primary open-angle glaucoma in average coffee drinkers (people consuming more than 5 cups a day had a small risk increase) (Kang, 2008). Alcohol, however, is associated with a mild IOP-lowering property while having known neurotoxicity. Its impact on glaucoma is not completely understood, but a link between alcohol consumption and glaucoma has not been found (Kang, 2007). Other dietary habits have also been studied in glaucoma. Diets favouring omega-3 fatty acids, such as soy oils, instead of omega-6 fatty acids, such as corn or sunflower oils, have been associated with an increased risk for glaucoma (Kang, 2004). Considering its OBF-related effects, fish oil (rich in omega-6) improves circulation in patients with Raynaud's phenomenon (DiGiacomo, 1989) by inhibiting the endothelin-1 effect (Nitta, 1998). A number of dietary anti-oxidative agents, such as ginkgo biloba (Ritch, 2000), might also improve OBF. A single, small study in normotensional glaucoma patients has suggested an improvement in visual field damage while on ginkgo (Quaranta, 2003). Vitamin E

supplements, despite improving vasospastic angina by decreasing oxidative stress, have a still unknown impact on glaucoma (Motoyama, 1998). Nevertheless, the enthusiasm over such therapies must be balanced with the risks of overconsumption because high dosages are known to increase all-cause mortality (Miller, 2005). Another lifestyle activity is cigarette smoking. A meta-analysis has shown a significant increase in the risk of developing glaucoma in smokers (Bonovas, 2004). Smokers show a markedly reduced ability of retinal vessels and the choroid to adapt to stimuli, such as light exposure or a carbogen breathing environment, when compared with a non-smoker population (Havelius, 2005) (Wimpissinger, 2004). Physical fitness and cardiovascular health status probably also impact glaucoma. People who do regular exercise have lower baseline IOPs. However, upon the cessation of exercise, values return to pretraining levels within 1 month. In healthy subjects, moderate exercise has been known to increase endothelial shear stress, which improves nitric oxide release and therefore has a positive impact on blood flow, for instance, in the coronary arteries (Niebauer, 1996). OBF seems to be unchanged during exercise due to vascular autoregulation. This autoregulation fails at ocular perfusion pressures greater than 70% above baseline. Summarising, at this time, the consensus recommendations are that regular exercise is most likely beneficial in glaucoma patients and should be encouraged (Risner, 2009).

6. Ophthalmological therapies

Ophthalmologists today have a greater arsenal of drugs with IOP-lowering effects than ever before. The IOP-lowering effect of each medication is beyond the scope of this vascular approach to glaucoma and can be found elsewhere, particularly in the European Glaucoma Society guidelines (European Glaucoma Society, 2008). We shall therefore focus instead on what is currently known about their non-IOP-related vascular impact on OBF.

Carbonic anhydrase inhibitors act by specifically inhibiting the carbonic anhydrase-II isoform, which is concentrated in the ciliary body. This enzyme is responsible for producing bicarbonate, an important part of the aqueous humour, from the hydration of CO_2 . This carbonic anhydrase blockade thus leads not only to a decrease of aqueous humour production but also to an increase in CO_2 and a lower tissue pH. In vessels with autoregulatory mechanisms, these last two changes can lead to vasodilation. Carbonic anhydrase inhibitors have been found to increase OBF when compared with other treatments with similar IOP reduction. A recent meta-analysis concluded that patients receiving topical carbonic anhydrase inhibitor treatment had a higher PSV and EDV in the central retinal and short posterior ciliary arteries, while their calculated vascular RI was reduced (Siesky, 2009). Increased blood flow velocities in both nasal and temporal short posterior ciliary arteries may improve blood flow in the ONH and possibly even the high-flow, low-resistance choroidal circulation. No statistically significant effects were seen in the ophthalmic artery. This improvement in blood flow has also been reported in retinal arteries, with dorzolamide accelerating the arteriovenous passage of fluorescein dye when compared with a beta-blocker (Harris, 2000). Topical carbonic anhydrase inhibitors may also play a role in retinal oxygenation because withdrawal of the drug leads to a decrease in arterial and venous saturation (Traustason, 2009). However, this class of drug is mostly used in association with other drugs, namely, beta-blockers. Studies comparing therapies combining beta-blockers with either carbonic anhydrase inhibitors or prostaglandins have shown that despite a similar lowering in IOP, patients taking carbonic anhydrase inhibitors/beta-blockers had a smaller RI in the retrobulbar vasculature (Siesky, 2006) (Januleviciene, 2009).

Systemic carbonic anhydrase inhibitors, such as acetazolamide, are not carbonic anhydrase-II specific and block both isoforms II and IV. Their ability to change vascular parameters is not only widely known but is clinically used in provocative tests to study cerebrovascular vasomotor reactivity. The cerebral vasodilatory effects of systemic carbonic anhydrase inhibitors are therefore well established and often utilised to test for vasodilative reserve potential. Unlike its topical counterparts, acetazolamide has also been reported to affect ophthalmic artery, decreasing RI (Dallinger, 1998). No additional effect seems to exist by combining both topical and systemic carbonic anhydrase inhibitors. Interestingly, a recent basic research study has offered a new perspective on the use of carbonic anhydrase inhibitors in glaucoma. As previously stated, the mechanisms behind glaucoma may be related to vascular endothelial dysfunction and impairment of nitric oxide activity (see above). Carbonic anhydrase inhibition by dorzolamide and acetazolamide may increase the affinity of the carbonic anhydrase for another substrate besides bicarbonate, namely, nitrite, in a reaction that produces nitric oxide. This IOP-independent activity would not only decrease reactive oxygen species activity by consuming nitrite but probably replenish nitric oxide, allowing for better endothelial function (Aamand, 2009). No multicentre, randomised study has reached a conclusion about the impact of these changes on glaucoma progression. Beta-blockers are among the most prescribed IOP-lowering therapies. They reduce IOP by decreasing aqueous humour production by approximately 30–50%. The exact mechanism involved in this inhibition is unknown, although the β_2 receptors in the non-pigmented ciliary body epithelium are the most likely target. However, the beta-blockers clinically in use are not a uniform group, ranging from non-selective beta-blockers (timolol) to β_1 -selective blockers (betaxolol) to non-selective beta-blockers with intrinsic sympathetic activity (carteolol). Because the non-selective beta-blockers could be associated with a vasoconstrictive effect, this impact on OBF has been extensively studied. A review on this potential effect concluded that neither primary open-angle nor normotensional glaucoma patients had a deleterious response to beta-blockers therapy in retinal, choroidal or retrobulbar vascular beds (Costa, 2003). Few reports have focused on the impact of carteolol on blood flow. Its intrinsic sympathetic activity would theoretically prevent the negative impact of blocking vasodilation-related β_2 receptors. A small study comparing timolol with carteolol, in which the IOP lowering was not significantly different, showed that the RI of the short posterior ciliary arteries was significantly lower in the carteolol group (Montanari, 2001). Interestingly, a recent review has shown that the β_1 -selective blocker betaxolol has been associated with greater preservation of visual field defects when compared with other beta-blockers despite a smaller IOP reduction (Grieshaber, 2010). It also seems to have a different effect on OBF. When compared with other non-selective beta-blockers, it has been shown to reduce the RI of the ophthalmic artery while increasing both central retinal artery RI and diameter (Evans, 1999) (Collignon, 1997). One hypothesis about this probable non-IOP-related impact on visual field preservation is a positive impact on OBF because betaxolol has been demonstrated to have a calcium channel blocking activity (Grieshaber, 2010).

Prostaglandin analogues are a powerful tool in IOP-lowering therapy. Their activity on prostaglandin F receptors leads to an overall increase in the uveoscleral outflow of aqueous humour. As one of the most effective IOP-lowering agents, these drugs can improve ocular perfusion pressure by significantly decreasing IOP. Their direct impact on OBF in an IOP-independent manner is still controversial. As such, the majority of available data has shown a neutral effect on OBF by prostaglandin analogues therapy administration (Nicolela, 1996)

(Liu, 2002). However, there are some reports claiming that patients under prostaglandin analogues have an improvement in OBF, specifically at the level of the ONH (Ishii, 2001). Endothelin-1-induced vasoconstriction was successfully prevented *in vivo* by PA, most likely by blocking ET-1-induced capacitative calcium entry (Kurashima, 2010).

Of the alpha-2 agonists used in clinical practice, the only one with relevance for chronic IOP-lowering treatment in glaucoma is brimonidine. This drug is a potent alpha-adrenoceptor agonist that is 1000-fold more selective for the alpha-2 *versus* the alpha-1 adrenoceptor. Other than the IOP-lowering effect, this drug has been touted as having a potential in neuroprotection (Krupin, 2011). This first prospective clinical trial demonstrated that normotensional glaucoma patients showed a slower progression rate when treated with brimonidine when compared with their beta-blocker-treated, IOP-adjusted counterparts. This neuroprotective effect is, however, not likely related to changes in OBF. Despite its theoretic vasoconstrictive properties, there seems to be no strong evidence on modulation, positive or negative, of OBF in either the retinal, or ONH vascular territories (Costa, 2003). It may, however, lead to decreased flow and increased resistance in the choroidal compartment, but further studies are warranted (Weigert, 2007).

Pilocarpine is a parasympathomimetic drug that stimulates the ciliary muscle contraction, which results in traction of the scleral spur, altering the configuration of the trabecular meshwork and leading to enhanced outflow and therefore reduced IOP. Its limited use in the clinical management of open angle glaucoma has also limited its study on the impact of OBF. The only study in glaucoma patients revealed no IOP-independent impact on blood flow (Claridge, 1993).

Glaucoma surgery has also been studied for OBF changes. Existing data on the subject is not only scarce but also conflicting. While some authors have described a neutral effect in retrobulbar and retinal artery flow velocities by trabeculectomy (Breusegem, 2010) (Cantor, 2001), others have found increases in OBF (Berisha, 2005) (Tribble, 1994). Different measuring techniques and different experimental designs have precluded definitive conclusions as to whether surgery can significantly improve OBF. To the best of our knowledge, no study so far has focused on OBF and glaucoma laser therapy.

7. Future research

Glaucoma specialists still debate the mechanisms that initiate and perpetuate optic neuropathy. The growing evidence for a background vascular dysfunction in primary open angle glaucoma is transforming the clinical approach to these patients. However, and despite the recognition of disturbances in OBF, little is known about the impact of correcting such imbalances. A question still remains as to whether these OBF changes represent the cause or rather the end result of impaired neuron metabolism. Studies so far have not been able to answer these complex issues. There are still no available population-based studies on OBF and no randomised, multi-centre studies on long-term follow-up. Current data is nevertheless encouraging, with reports claiming that improving OBF might slow disease progression. Advances in the tools to study OBF, such as magnetic resonance imaging, or a more widespread clinical use of already existing devices, such as Doppler OCT, will most likely allow for a more thorough analysis of the ocular vascular system. Importantly, efforts to increase the standardisation of procedures and methodology in OBF research centres worldwide might lead to a more effective and rational use of currently available data. The Association for Ocular Circulation (<http://www.obfra.org>) is currently addressing this problem by outlining consensus reports on the subject.

8. References

- Aamand, R., Dalsgaard, T., Jensen, FB., Simonsen, U., Roepstorff, A. & Fago, A. 2009. Generation of nitric oxide from nitrite by carbonic anhydrase: a possible link between metabolic activity and vasodilation. *Am J Physiol Heart Circ Physiol*. 2009, Vol. 297, pp. 2068-74.
- Alonso, S. & O'Brian, GS. 1967. Enhancement of the coronary vasodilator action of adenosine tri-phosphate by dipyridamole. *Circ Res*. 1967, Vol. 20, pp. 403-408.
- Appenzeller, O. & Orbie, E. 1997. *The Autonomic Nervous System: An introduction to basic and clinical concepts*. Amsterdam, The Netherlands: Elsevier Science, 1997. ISBN 0444825460.
- Aslan, M., Freeman, BA. 2007. Redox-dependent impairment of vascular function in sickle cell disease. *Free Radic. Biol. Med*. 2007, Vol. 43, pp. 1469-1483.
- Ates, H., Uretmen, O., Temiz, A. & Andac, K. 1998. Erythrocyte deformability in high-tension and normal tension glaucoma. *Int Ophthalmol*. 1998, Vol. 22, pp. 7-12.
- Bagga H., Liu JH. & Weinreb RN. 2009. Intraocular pressure measurements throughout the 24 h. *Curr Opin Ophthalmol*. 2009, Vol. 20(2), pp. 79-83.
- Balaratnasingam C., Morgan WH., Hazelton ML., House PH., Barry CJ., Chan H., Cringle SJ. & Yu DY. 2007. Value of retinal vein pulsation characteristics in predicting increased optic disc excavation. *Br J Ophthalmol*. 2007, Vol. 91, pp. 441-4.
- Beckman, JS., Beckman, TW., Chen, J., Marshall, PA. & Freeman, BA. 1990. Apparent hydroxyl radical production by peroxynitrite: implications for endothelial injury from nitric oxide and superoxide. *Proc. Natl. Acad. Sci*. 1990, Vol. 87, pp. 1620-1624.
- Bell, NP., Orengo-Nania, S., Pietz, K. & Gross, RL. 2004. Aspirin use in advanced uncontrolled glaucoma. *J Glaucoma*. 2004, Vol. 13, pp. 365-70.
- Bengtsson, B. 1990. Optic disc haemorrhages preceding manifest glaucoma. *Acta Ophthalmol*. 1990, Vol. 68, pp. 450-454.
- Berisha, F., Schmetterer, K., Vass, C., Dallinger, S., Rainer, G., Findl, O., Kiss, B. & Schmetterer, L. 2005. Effect of trabeculectomy on ocular blood flow. *Br J Ophthalmol*. 2005, Vol. 89, pp. 185-8.
- Boehm, AG., Koeller, AU. & Pillunat, LE. 2005. The Effect of Age on Optic Nerve Head Blood Flow. *Invest Ophthalmol Vis Sci*. 2005, Vol. 46, pp. 1291-1295.
- Bojic, L. & Skare-Librenjak, L. 1998. Circulating platelet aggregates in glaucoma. *Int. Ophthalmol*. 1998, Vol. 22, pp. 151-154.
- Bonovas, S., Filioussi, K., Tsantes, A. & Peponis, V. 2004. Epidemiological association between cigarette smoking and primary open-angle glaucoma: a meta-analysis. *Public Health*. 2004, Vol. 118, pp. 256-61.
- Braunwald, E. 1982. Mechanisms of action of calcium channel blocking agents. *N. Engl. J. Med*. 1982, Vol. 307, pp. 1618-1627.
- Breusegem, C., Fieuws, S., Zeyen, T. & Stalmans, I. 2010. The effect of trabeculectomy on ocular pulse amplitude. *Invest Ophthalmol Vis Sci*. 2010, Vol. 51, pp. 231-5.
- Bunker, ML. & McWilliams, M. 1979. Caffeine content of common beverages. *J Am Diet Assoc*. 1979, Vol. 74, pp. 28-32.
- Cantor, LB. 2001. The effect of trabeculectomy on ocular hemodynamics. *Trans Am Ophthalmol Soc*. 2001, Vol. 99, pp. 241-52.
- Caprioli, J., Coleman, AL., Blood Flow in Glaucoma Discussion Group. 2010. Blood Pressure, Perfusion Pressure, and Glaucoma. *Am J Ophthalmol*. 2010, Vol. 149, pp. 704-712.

- Carter, CJ., Brooks, DE., Doyle, DL. & Drance, SM. 1990. Investigations into a vascular etiology for low-tension glaucoma. *Ophthalmology*. 1990, Vol. 97, pp. 49-55.
- Chobanian, AV., Bakris, GL., Black, HR., Cushman, WC., Green, LA., Izzo, JL., Jones, DW., Materson, BJ., Oparil, S., Wright, JT., Rocella, EJ., JNC. 2003. The Seventh Report of the Joint National Committee on Prevention, Detection, Evaluation and Treatment of High Blood Pressure: the JNC7 report. *JAMA*. 2003, Vol. 289, pp. 2560-72.
- Choi J., Lee J., Park SB., Lee KS., Sung KR. & Kook MS. 2010. Factors affecting ocular pulse amplitude in eyes with open angle glaucoma and glaucoma suspect eyes. *Acta Ophthalmol*. 2010, Vols. doi: 10.1111/j.1755-3768.2010.01954.x.
- Cholesterol Treatment Trialists' (CTT), Collaborators. 2005. Efficacy and safety of cholesterol-lowering treatment: prospective metaanalysis of data from 90,056 participants in 14 randomized trials of statins. *Lancet*. 2005, Vol. 366, pp. 1267-78.
- Cimino, M., Gelosa, P., Gianella, A., Nobili, E., Tremoli, E. & Sironi, L. 2007. Statins: multiple mechanisms of action in the ischemic brain. *Neuroscientist*. 2007, Vol. 13, pp. 208-13.
- Claridge, KG. 1993. The effect of topical pilocarpine on pulsatile ocular blood flow. *Eye*. 1993, Vol. 7, pp. 507-510.
- Collignon, NJ. & Collignon-Brach, JD. 1997. Effect of topical betablockers on human retinal vessels diameters. *Int Ophthalmol*. 1997, Vol. 21, pp. 199-203.
- Costa, VP., Sergott, RC., Spaeth, GL., Moster, MR., Katz, LJ., Schmidt, CM., Wilson, RP. & Smith, M. 1994. Color Doppler imaging in glaucoma patients with asymmetric cups. *J Glaucoma*. 1994, Vol. 3, pp. S91-97.
- Costa, VP., Harris, A., Stefánsson, E., Flammer, J., Krieglstein, GK., Orzalesi, N., Heijl, A., Renard, JP. & Serra, LM. 2003. The effects of antiglaucoma and systemic medications on ocular blood flow. *Prog Retin Eye Res*. 2003, Vol. 22, pp. 769-805.
- Curtis, BM. & O'Keefe, JH. 2002. Autonomic tone as a cardiovascular risk factor: the dangers of chronic fight or flight. *Mayo Clin Proc*. 2002, Vol. 77, pp. :45-54.
- Dallinger, S., Bobr, B., Findl, O., Eichler, HG. & Schmetterer, L. 1998. Effects of acetazolamide on choroidal blood flow. *Stroke*. 1998, Vols. 997-1001, p. 29.
- de Voogd, S., Wolfs, RC., Jansonius, NM., Witteman, JC., Hofman, A. & de Jong PT. 2006. Atherosclerosis, C-reactive protein, and risk for open-angle glaucoma: the Rotterdam study. *Invest Ophthalmol Vis Sci*. 2006, Vol. 47, pp. 3772-6.
- Dean, RT. & Wilcox, I. 1993. Possible atherogenic effects of hypoxia during obstructive sleep apnea. *Sleep*. 1993, Vol. 16, pp. S15-21.
- DiGiacomo, RA., Kremer, JM. & Shah, DM. 1989. Fishoil dietary supplementation in patients with Raynaud's phenomenon: a double-blind, controlled, prospective study. *Am J Medicine*. 1989, Vol. 86, pp. 158-164.
- Drance, SM., Fairclough, M., Butler, DM. & Kottler, MS. 1977. The importance of disc hemorrhage in the prognosis of chronic open angle glaucoma. *Arch Ophthalmol*. 1977, Vol. 95, pp. 226-228.
- Drance, SM. & Rojanapongpun, P. 1995. The ophthalmic artery velocity in open-angle glaucoma. [book auth.] Drance SM. *Update to Glaucoma, Ocular Blood Flow, and Drug Treatment*. New York, NY : Kugler Publications, 1995.
- Drance, S., Anderson, DR., Schulzer, M., Collaborative Normal-Tension Glaucoma Study Group. 2001. Risk factors for progression of visual field abnormalities in normal-tension glaucoma. *Am J Ophthalmol*. 2001, Vol. 131, pp. 699-708.
- European Glaucoma Society. 2008. *Terminology and guidelines for glaucoma, 3rd Edition*. Savona, Italy : Dogma, 2008. ISBN - 978-88-87434-28-6.

- Evans, DW., Harris, A. & Cantor, LB. 1999. Primary open-angle glaucoma patients characterized by ocular vasospasm demonstrate a different ocular vascular response to timolol versus betaxolol. *J Ocul Pharmacol Ther.* 1999, Vol. 15, pp. 479-87.
- Everett, BM., Glynn, RJ., MacFadyen, JG. & Ridker, PM. 2010. Rosuvastatin in the prevention of stroke among men and women with elevated levels of C-reactive protein: justification for the Use of Statins in Prevention: an Intervention Trial Evaluating Rosuvastatin (JUPITER). *Circulation.* 2010, Vol. 121, pp. 143-150.
- Evers, S., Afra, J., Frese, A., Goadsby, PJ., Linde, M., May, A. & Sándor, PS. 2006. EFNS guideline on the drug treatment of migraine - report of an EFNS task force. *Eur J Neurol.* 2006, Vol. 13, pp. 560-72.
- Flage, T. 1977. Permeability properties of the tissues in the optic nerve head region in the rabbit and the monkey. An ultrastructural study. *Acta Ophthalmol (Copenh).* 1977, Vol. 55, pp. 652-64.
- Flammer, J. & Guthauser, U. 1987. Behandlung chorioidaler vasospasmen mit kalziumantagonisten. *Klin. Mbl. Augenheilk.* 1987, Vol. 190, pp. 299-300.
- Flammer, J. 1996. *To what extent are vascular factors involved in the pathogenesis of glaucoma?* Basel : Karger, 1996.
- Flammer J., Haefliger IO., Orgül S. & Resink T. 1999. Vascular dysregulation: a principal risk factor for glaucomatous damage? *J Glaucoma.* 1999, Vol. 8(3), pp. 212-9.
- Flammer, J., Pache, M. & Resink, T. 2001. Vasospasm, its role in the pathogenesis of diseases with particular reference to the eye. *Prog Retin Eye Res.* 2001, Vol. 20, pp. 319-49.
- Flammer, J., Orgul. S, Costa, VP., Orzalesic, N. & Krieglsteind, GK. 2002. The impact of ocular blood flow in glaucoma. *Progress in Retinal and Eye Research.* 2002, Vol. 21, pp. 359-393.
- Flammer, J. 2006. *Glaucoma; A Guide for the Patient; An Introduction for Care-Providers; A Quick Reference.* 3. Gottingen, Germany, Bern : Hogrefe and Huber Publishers, 2006.
- Fontana, L., Poinoosawmy, D., Bunce, CV., O'Brien, C. & Hitchings, R.A. 1998. Pulsatile ocular blood flow investigation in asymmetric normal tension glaucoma and normal subjects. *Br. J. Ophthalmol.* 1998, Vol. 82, pp. 731-736.
- Galassi, F., Nuzzaci, G., Sodi, A., Casi, P. & Vielmo, A. 1992. Color Doppler imaging in evaluation of optic nerve blood supply in normal and glaucomatous subjects. *Int. Ophthalmol.* 1992, Vol. 16, pp. 273-276.
- Gaspar, AZ., Flammer, J. & Hendrickson, P. 1994. Influence of nifedipine on the visual fields of patients with optic nerve head diseases. *Eur. J. Ophthalmol.* 1994, Vol. 1, pp. 24-8.
- Gaspar, AZ., Gasser, P. & Flammer, J. 1995. The influence of magnesium on visual field and peripheral vasospasm in glaucoma. *Ophthalmologica.* 1995, Vol. 209, pp. 11-13.
- Gasser, P. & Flammer, J. 1990. Short- and long-term effect of nifedipine on the visual field in patients with presumed vasospasm. *J. Int. Med. Res.* 1990, Vol. 18, pp. 334-339.
- Gasser, P. & Flammer, J. 1991. Blood-cell velocity in the nailfold capillaries of patients with normal-tension and hightension glaucoma. *Am J Ophthalmol.* 1991, Vol. 111, pp. 585-8.
- Gherghel, D., Hosking, LS. & Orgul, S. 2004. Autonomic Nervous System, Circadian Rhythms, and Primary Open-Angle Glaucoma. *Surv Ophthalmol.* 2004, Vol. 49, pp. 491-508.

- Gosling, Rg., Dunbar, G., King, DH., Newman, DL., Side, CD., Woodcock, JP., Fitzgerald, DE., Keates JS. & Macmillan, D. 1971. The Quantitative Analysis of Occlusive Peripheral Arterial Disease By a Non-Intrusive Ultrasonic Technique. *Angiology*. 1971, Vol. 22, pp. 52-55.
- Graham, SL. & Drance, SM. 1999. Nocturnal hypotension: role in glaucoma progression. *Surv Ophthalmol*. 1999, Vol. 43, pp. S10-16.
- Grieshaber, MC. & Flammer, J. 2007. Does the blood--brain barrier play a role in glaucoma? *Surv Ophthalmol*. 2007, Vol. 52, pp. S115-21.
- Grieshaber MC., Katamay R., Gugleta K., Kochkorov A., Flammer J. & Orgul S. 2009. Relationship between ocular pulse amplitude and systemic blood pressure measurements. *Acta Ophthalmol*. 2009, Vol. 87, pp. 329-334.
- Grieshaber, MC. & Flammer, J. 2010. Is the medication used to achieve the target intraocular pressure in glaucoma therapy of relevance? – An exemplary analysis on the basis of two beta-blockers. *Prog Retin Eye Res*. 2010, Vol. 29, pp. 79-93.
- Groh, MJ., Michelson, G., Langhans, MJ. & Harazny, J. 1996. Influence of age on retinal and optic nerve head blood circulation. *Ophthalmology*. 1996, Vols. 529-34, pp. 529-34.
- Grunwald, JE., Piltz, J., Hriprasad, SM. & DuPont, J. 1998. Optic nerve and choroidal circulation in glaucoma. *Investig. Ophthalmol. Vis. Sci*. 1998, Vol. 39, pp. 2329-2336.
- Gugleta, K., Orgul, S., Stumpfig, D., Dubler, B. & Flammer, J. 1999. Fludrocortisone in the treatment of systemic hypotension in primary open-angle glaucoma patients. *Int Ophthalmol*. 1999, Vol. 23, pp. 25-30.
- Hamard, P., Hamard, H., Dufaux, J. & Quesnot, S. 1994. Optic nerve head blood flow using a laser Doppler velocimeter and haemorheology in primary open angle glaucoma and normal pressure. *Br. J. Ophthalmol*. 1994, Vol. 78, pp. 449-453.
- Hampton, JR., Harrison, AJ., Honour, AJ. & Mitchell, JR. 1967. Platelet behaviour and drugs used in cardiovascular disease. *Cardiovasc Res*. 1967, Vol. 1, pp. 1-6.
- Harada, N., Ueda, A. & Takegata, S. 1991. Prevalence of Raynaud's phenomenon in Japanese males and females. *J Clin Epidemiol*. 1991, Vol. 44, pp. 649-55.
- Hardarson, SH., Gottfredsdottir, MS., Halldorsson, GH., Karlsson, RA., Benediktsson, JA., Eysteinnsson, T., Beach, JM., Harris, A. & Stefansson E. 2009. Glaucoma filtration surgery and retinal oxygen saturation. *Invest Ophthalmol Vis Sci*. 2009, Vol. 50, pp. 5247-50.
- Hardy, P., Bhattacharya, M., Abran, D., Peri, KG., Asselin, P. & Varma, DR. 1998. Increases in retinovascular prostaglandin receptor functions by cyclooxygenase-1 and -2 inhibition. *Invest Ophthalmol Vis Sci*. 1998, Vol. 39, pp. 1888-98.
- Harris A, Sergott RC, Spaeth GL, Katz JL, Shoemaker JA, Martin BJ. 1994. Color Doppler analysis of ocular vessel blood velocity in normal-tension glaucoma. *Am J Ophthalmol*. 1994, Vol. 118, pp. 642-9.
- Harris, A., Arend, O., Chung, HS., Kagemann, L., Cantor, L. & Martin, B. 2000. A comparative study of betaxolol and dorzolamide effect on ocular circulation in normal-tension glaucoma patients. *Ophthalmology*. 2000, Vol. 107, pp. 430-4.
- Harris, A., Harris, M., Biller, J., Garzozzi, H., Zarfty, D., Ciulla, TA. & Martin, B. 2000. Aging affects the retrobulbar circulation differently in women and men. *Arch Ophthalmol*. 2000, Vol. 118, pp. 1076-80.

- Harris-Yitzhak, M., Harris, A., Ben-Refael, Z., Zarfati, D., Garzosi, HJ. & Martin, BJ. 2000. Estrogen-replacement therapy: effects on retrobulbar hemodynamics. *Am J Ophthalmol.* 2000, Vol. 129, pp. 623-628.
- Harris A., Kagemann L., Ehrlich R., Ehrlich Y., Lopez CR. & Purvin VA. 2008. The effect of sildenafil on ocular blood flow. *Br J Ophthalmol.* 2008, Vol. 92, pp. 469-473.
- Havelius, U. & Hansen, F. 2005. Ocular vasodynamic changes in light and darkness in smokers. *Invest Ophthalmol Vis Sci.* 2005, Vol. 46, pp. 1698-705.
- Hoyng, P.F., de Jong, N., Oosting, H. & Stilma, J. 1992. Platelet aggregation, disc haemorrhage and progressive loss of visual fields in glaucoma. A seven year follow-up study on glaucoma. *Int. Ophthalmol.* 1992, Vol. 16, pp. 65-73.
- Hulsman CA., Vingerling JR., Hofman A., Witteman JC. & de Jong Pt. 2007. Blood pressure, arterial stiffness, and open-angle glaucoma: the Rotterdam Study. *Arch Ophthalmol.* 2007, Vol. 125, pp. 805-812.
- Iseri, LLT. & French, JH. 1984. Magnesium: nature's physiologic calcium blocker. *Am. Heart J.* 1984, Vol. 108, pp. 188-193.
- Ishii, K., Tomidokoro, A., Nagahara, M., Tamaki, Y., Kanno, M., Fukaya, Y. & Araie, M. 2001. Effects of topical latanoprost on optic nerve head circulation in rabbits, monkeys, and humans. *Invest Ophthalmol Vis Sci.* 2001, Vol. 42, pp. 2957-2963.
- Ishiyama, A., Jacobson, KM. & Baloh, RW. 2000. Migraine and benign positional vertigo. *Ann. Otol. Rhinol. Laryngol.* 2000, Vol. 109, pp. 377-380.
- Januleviciene, I., Ehrlich, R., Siesky, B., Nedzelskienė, I. & Harris, A. 2009. Visual function, optic nerve structure, and ocular blood flow parameters after 1 year of glaucoma treatment with fixed combinations. *Eur J Ophthalmol.* 2009, Vol. 19, pp. 790-7.
- Jonas, JB., Nguyen, XN. & Naumann, GO. 1989. Parapapillary retinal vessel diameter in normal and glaucoma eyes. I. Morphometric data. *Invest Ophthalmol Vis Sci.* 1989, Vol. 30, pp. 1599-603.
- Jonas, JB. & Xu, L. 1993. Optic disc morphology in eyes after nonarteritic anterior ischemic optic neuropathy. *Invest Ophthalmol Vis Sci.* 1993, Vol. 34, pp. 2260-5.
- Jonas, JB. & Hayreh SS. 1999. Optic disk morphology in experimental central retinal artery occlusion in rhesus monkeys. *Am J Ophthalmol.* 1999, Vol. 127, pp. 523-30.
- Jonas, JB. 2003. Central retinal artery and vein collapse pressure in eyes with chronic open angle glaucoma. *Br J Ophthalmol.* 2003, Vol. 87, pp. 949-51.
- Kaiser, HJ., Stumpfig, D. & Flammer, J. 1996. Short-term effect of dipyridamole on blood flow velocities in the extraocular vessels. *Int. Ophthalmol.* 1996, Vol. 19, pp. 355-358.
- Kaiser, HJ., Schoetzau, A., Stumpfig, D. & Flammer, J. 1997. Bloodflow velocities of the extraocular vessels in patients with high-tension and normal-tension primary open-angle glaucoma. *Am J Ophthalmol.* 1997, Vol. 123, pp. 320-327.
- Kang, JH., Pasquale, LR., Willett, WC., Rosner, BA., Egan, KM., Faberowski, N. & Hankinson, SE. 2004. Dietary fat consumption and primary open-angle glaucoma. *Am J Clin Nutr.* 2004, Vol. 79, pp. 755-64.
- Kang, JH., Willett, WC., Rosner, BA., Hankinson, SE. & Pasquale, LR. 2007. Prospective study of alcohol consumption and the risk of primary open-angle glaucoma. *Ophthalmic Epidemiol.* 2007, Vol. 14, pp. 141-7.
- Kang, JH., Willett, WC., Rosner, BA., Hankinson, SE. & Pasquale, LR. 2008. Caffeine consumption and the risk of primary open-angle glaucoma: a prospective cohort study. *Invest Ophthalmol Vis Sci.* 2008, Vol. 49, pp. 1924-31.

- Karakucuk, S., Goktas, S., Aksu, M., Erdogan, N., Demirci, S., Oner, A., Arda, H. & Gumus, K. 2008. Ocular blood flow in patients with obstructive sleep apnea syndrome (OSAS). *Graefes Arch Clin Exp Ophthalmol.* 2008, Vol. 246, pp. 129-34.
- Kargi, SH., Altin, R., Koksall, M., Kart, L., Cinar, F., Ugurbas, SH. & Ayoglu, F. 2005. Retinal nerve fibre layer measurements are reduced in patients with obstructive sleep apnea syndrome. *Eye.* 2005, Vol. 19, pp. 575-579.
- Kaufmann C., Fierz A., Kollias SS. & Robert YC. 2002. Ocular pulse amplitude in a case of innominate steal syndrome. *Am J Ophthalmol.* 2002, Vol. 133(1), pp. 155-6.
- Kerr, J., Nelson, P. & O'Brien, C. 1997. A comparison of ocular blood flow in untreated primary open-angle glaucoma and ocular hypertension. *Am. J. Ophthalmol.* 1997, Vol. 126, pp. 42-51.
- Kim, Y M., Bombeck, CA. & Billiar, TR. 1999. Nitric oxide as a bifunctional regulator of apoptosis. *Circ. Res.* 1999, Vol. 84, pp. 253-256.
- Klein BE., Klein R. & Knudtson MD. 2005. Intraocular pressure an systemic blood pressure: longitudinal perspective: the Beaver Dam Eye Study. *Br J Ophthalmol.* 2005, Vol. 89, pp. 284-287.
- Kozobolis, PV., Detorakis, ET., Georgiadis, GS., Achtaropoulos, AA., Papas, TT. & Lazarides, MK. 2007. Perimetric and retrobulbar blood flow changes following carotid endarterectomy. *Graefe's Arch Clin Exp Ophthalmol.* 2007, Vol. 245, pp. 1639-1645.
- Krupin, T., Liebmann, JM., Greenfield, DS., Ritch, R., Gardiner, S., Low-Pressure Glaucoma Study Group. 2011. A Randomized Trial of Brimonidine Versus Timolol in Preserving Visual Function: Results From the Low-pressure Glaucoma Treatment Study. *Am J Ophthalmol.* 2011, Vol. 151, pp. 671-81.
- Kuba, GB., Pillunat, LE., Bohm, AG. & Klemm, M. 2001. Retinal nerve fiber layer thickness and peripapillary blood flow in glaucoma patients and healthy probands. *Ophthalmologe.* 2001, Vol. 98, pp. 41-46.
- Kurashima, H., Watabe, H., Sato, N., Abe, S., Ishida, N. & Yoshitomi, T. 2010. Effects of prostaglandin F(2 α) analogues on endothelin-1-induced impairment of rabbit ocular blood flow: comparison among tafluprost, travoprost, and latanoprost. *Exp Eye Res.* 2010, Vol. 91, pp. 853-9.
- Lam, AK., Chan, ST., Chan, H. & Chan B. 2003. The effect of age on ocular blood supply determined by pulsatile ocular blood flow and color Doppler ultrasonography. *Optom Vis Sci.* 2003, Vol. 80, pp. 305-311.
- Lesk, MR., Wajszilber, M. & Deschenes, MC. 2008. The effects of systemic medications on ocular blood flow. *Can J Ophthalmol.* 2008, Vol. 43, pp. 351-5.
- Leske Mc., Wu SY., Nemesure B. & Hennis A. 2002. incident open-angle glaucoma and blood pressure. *Arch Ophthalmol.* 2002, Vol. 120, pp. 954-959.
- Leung, DY., Li, FC., Kwong, YY., Tham, CC., Chi, SC. & Lam, DS. 2010. Simvastatin and disease stabilization in normal tension glaucoma: a cohort study. *Ophthalmology.* 2010, Vol. 117, pp. 471-6.
- Liu JH., Kripke DF., Twa MD., Hoffman RE., Mansberger SL., Rex KM., Girkin CA. & Weinreb RN. 1999. Twenty-four-hour pattern of intraocular pressure in the aging population. *Invest Ophthalmol Vis Sci.* 1999, Vol. 40, pp. 2912-7.
- Liu, CJ., Ko, YC., Cheng, CY., Chou, JC., Hsu, WM. & Liu, JH. 2002. Effect of latanoprost 0.005% and brimonidine tartrate 0.2% on pulsatile ocular blood flow in normal tension glaucoma. *Br J Ophthalmol.* 2002, Vol. 86, pp. 1236-1239.

- Matulla, B., Streit, G., Pieh, S., Findl, O., Entlicher, J., Graselli, U., Eichler, HG., Wolzt, M. & Schmetterer, L. 1997. Effects of losartan on cerebral and ocular circulation in healthy subjects. *Br J Clin Pharmacol.* 1997, Vol. 44, pp. 369-75.
- McKee HD., Saldaña M. & Ahad MA. 2004. Increased ocular pulse amplitude revealing aortic regurgitation. *Am J Ophthalmol.* 2004, Vol. 138(3), p. 503.
- Michelson, G., Groh, MJ., Groh, ME. & Grundler, A. 1995. Advanced primary open-angle glaucoma is associated with decreased ophthalmic artery blood-flow velocity. *Ger. J. Ophthalmol.* 1995, Vol. 4, pp. 21-24.
- Millar-Craig MW., Bishop CN. & Raftery EB. 1978. Circadian variation of blood-pressure. *Lancet.* 1978, Vol. i., pp. 795-7.
- Miller, ER., Pastor-Barriuso, R., Dalal, D., Riemersma, RA., Appel, LJ. & Guallar, E. 2005. Meta-analysis: high-dosage vitamin E supplementation may increase all-cause mortality. *Ann Intern Med.* 2005, Vol. 142, pp. 37-46.
- Mitchell P., Lee AJ., Rochtchina E. & Wang JJ. 2004. Open-angle glaucoma and systemic hypertension: the Blue Mountains Eye Study. *J Glaucoma.* 2004, Vol. 13, pp. 319-326.
- Miyauchi, T. & Masaki, T. 1999. Pathophysiology of endothelin in the cardiovascular system. *Annu. Rev Physiol.* 1999, Vol. 61, pp. 391-415.
- Mojon, DS., Hess, CW., Goldblum, D., Fleischhauer, J., Koerner, F., Bassetti, C. & Mathis, J. 1999. High prevalence of glaucoma in patients with sleep apnea syndrome. *Ophthalmology.* 1999, Vol. 106, pp. 1009-1012.
- Mojon, DS., Hess, CW., Goldblum, D., Boehnke, M., Koerner, F., Gugger, M., Bassetti, C. & Mathis, J. 2002. Normal-tension glaucoma is associated with sleep apnea syndrome. *Ophthalmologica.* 2002, Vol. 216, pp. 180-184.
- Montanari, P., Marangoni, P., Oldani, A., Ratiglia, R., Raiteri, M. & Berardinelli, L. 2001. Color Doppler imaging study in patients with primary open-angle glaucoma treated with timolol 0.5% and carteolol 2%. *Eur. J. Ophthalmol.* 2001, Vol. 11, pp. 240-244.
- Morgan, WH., Balaratnasingam, C., Hazelton, ML., House, PH., Cringle, SJ. & Yu, DY. 2005. The force required to induce hemivascular pulsation is associated with the site of maximum field loss in glaucoma. *Invest Ophthalmol Vis Sci.* 2005, Vol. 46, pp. 1307-12.
- Morgan, WH., Hazelton, ML., Balaratnasingam, C., Chan, H., House, PH., Barry, CJ., Cringle, SJ. & Yu DY. 2009. The association between retinal vein ophthalmodynamometric force change and optic disc excavation. *Br J Ophthalmol.* 2009, Vol. 93, pp. 594-6.
- Motoyama, T., Kawano, H., Kugiyama, K., Hirashima, O., Ohgushi, M., Tsunoda, R., Moriyama, Y., Miyao, Y., Yoshimura, M., Ogawa, H. and Yasue, H. 1998. Vitamin E administration improves impairment of endothelium-dependent vasodilation in patients with coronary spastic angina. *J. Am. Coll. Cardiol.* 1998, Vol. 2, pp. 1672-1679.
- Nagaoka, T., Takahashi, A., Sato, E., Izumi, N., Hein, TW., Kuo, L. & Yoshida, A. 2006. Effect of systemic administration of simvastatin on retinal circulation. *Arch Ophthalmol.* 2006, Vol. 124, pp. 665-70.
- Nicolela, MT., Buckley, AR., Walman, BE. & Drance, SM. 1996. A comparative study of the effects of timolol and latanoprost on blood flow velocity of the retrobulbar vessels. *Am J Ophthalmol.* 1996, Vol. 122, pp. 784-789.


- Nicolela, MT. 2007. Retinal vein pulsation predicts increasing optic disc excavation. *Br J Ophthalmol.* 2007, Vol. 91, pp. 405-6.
- Niebauer, J. & Cooke, JP. 1996. Cardiovascular effects of exercise: role of endothelial shear stress. *J Am Coll Cardiol.* 1996, Vol. 28, pp. 1652-60.
- Nitta, K., Uchida, K., Tsutsui, T., Honda, K., Kawashima, A., Yumura, W. & Nihei, H. 1998. Eicosapentaenoic acid inhibits mitogen-induced endothelin-1 production and DNA synthesis in cultured bovine mesangial cells. *Am. J. Nephrol.* 1998, Vol. 18, pp. 164-170.
- Niwa, Y., Yamamoto, T., Harris, A., Kagemann, L., Kawakami H. & Kitazawa, Y. 2000. Relationship between the effect of carbon dioxide inhalation or nilvadipine on orbital blood flow in normal-tension glaucoma. *J Glaucoma.* 2000, Vol. 9, pp. 262-267.
- O'Brien, C., Butt, Z., Ludlam, C. & Detkova, P. 1997. Activation of the coagulation cascade in untreated primary open-angle glaucoma. *Ophthalmology.* 1997, Vol. 104, pp. 725-729.
- Ogata N., Imaizumi M., Kurokawa H., Arichi M. & Matsumura M. 2005. Optic nerve compression by normal carotid artery in patients with normal tension glaucoma. *Br J Ophthalmol.* 2005, Vol. 89, 174-179.
- Olafsdottir, OB., Hardarson SH., Gottfredsdottir, MS., Harris, A. & Stefánsson, E. 2010. Retinal Oximetry in Open-Angle Glaucoma. *ARVO.* [Online] 2010.
- Onen SH, Mouriaux F, Berramdane L, Dascotte JC, Kulik JF Rouland JF. 2000. High prevalence of sleep-disordered breathing in patients with primary open-angle glaucoma. *Acta Ophthalmol Scand.* 2000, Vol. 78, pp. 638-641.
- Ozkan, B., Yüksel, N., Anik, Y., Altintas, O., Demirci, A. & Çağlar Y. 2008. The effect of caffeine on retrobulbar hemodynamics. *Curr Eye Res.* 2008, Vol. 33, pp. 804-9.
- Pache, M. & Flammer, J. 2006. A sick eye in a sick body? Systemic findings in patients with primary open-angle glaucoma. *Surv Ophthalmol.* 2006, Vol. 51, pp. 179-212.
- Pasquale, LR., Rosner, BA., Hankinson, SE., & Kang, JH. 2007. Attributes of Female Reproductive Aging and Their Relation to Primary Open-angle Glaucoma: A Prospective Study. *J Glaucoma.* 2007, Vol. 16, pp. 598-605.
- Pechère-Betschi, A., Nussberger, J., Biollaz, J., Fahti, M., Grouzmann, E., Morgan, T., Brunner, HR & Burnier, M. 1998. Circadian variations of renal sodium handling in patients with orthostatic hypotension. 1998, Vol. 54, pp. 1276-82.
- Perkins, E.S. 1985. The ocular pulse and intraocular pressure as a screening test for carotid artery stenosis. *Br J Ophthalmol.* 1985, Vol. 69, pp. 676-680.
- Pierdomenico SD., Bucci A., Costantini F., Lapenna D., Cuccurullo F. & Mezzetti A. 1998. Circadian blood pressure changes and myocardial ischemia in hypertensive patients with coronary artery disease. *J Am Coll Cardiol.* 1998, Vol. 31(7), pp. 1627-34.
- Pinto, L., Leitão, P., Ferreira, J., Domingues, I., Vandewalle, E. & Fernandes, F. 2010. Diurnal variation of ocular pulse amplitude in primary open angle glaucoma patients. *Ophthalmologica.* 2010, pp. doi: 10.1111/j.1755-3768.2010.2356.x.
- Plange, N., Remky, A. & Arend, O. 2003. Colour Doppler imaging and fluorescein filling defects of the optic disc in normal tension glaucoma. *Br J Ophthalmol.* 2003, Vol. 87, pp. 731-736.
- Pourcelot, L. 1975. Indications de l'ultrasonographie Doppler dans l'étude des vaisseaux peripheriques. *Rev Prat.* 1975, Vol. 25, pp. 4671-4680.

- Pourjavan, S., Boëlle, PY., Detry-Morel, M. & De Potter, P. 2007. Physiological diurnal variability and characteristics of the ocular pulse amplitude (OPA) with the dynamic contour tonometer (DCT-Pascal). *Int Ophthalmol.* 2007, Vol. 27, pp. 357-60.
- Prunte-Glowazki, A. & Flammer, J. 1991. Ocular vasospasm. 4: Clinical examples. *Klin Monatsbl Augenheilkd.* 1991, Vol. 198, pp. 415-8.
- Quaranta, L., Harris, A., Donato, F., Cassamali, M., Semeraro, F., Nascimbeni, G., Gandolfo, E. & Quaranta, CA. 1997. Color Doppler imaging of ophthalmic artery blood flow velocity: a study of repeatability and agreement. *Ophthalmology.* 1997, Vol. 104, pp. 653-658.
- Quaranta, L., Bettelli, S., Uva, MG., Semeraro, F., Turano, R. & Gandolfo, E. 2003. Effect of Ginkgo biloba extract on preexisting visual field damage in normal tension glaucoma. *Ophthalmology.* 2003, Vol. 110, pp. 359-62.
- Ravalico, G., Toffoli, G., Pastori, G., Croce, M. & Calderini, S. 1996. Age-related ocular blood flow changes. *Invest Ophthalmol Vis Sci.* 1996, Vol. 37, pp. 2645-2650.
- Risner, D., Ehrlich, R., Kheradiya, NS., Siesky, B., McCranor, L. & Harris, A. 2009. Effects of exercise on intraocular pressure and ocular blood flow: a review. *J Glaucoma.* 2009, Vol. 18, pp. 429-36.
- Ritch, R. 2000. Neuroprotection: is it already applicable to glaucoma therapy? *Curr Opin Ophthalmol.* 2000, Vol. 11, pp. 78-84.
- Sacca, SC., Pascotto, A., Camicione, P., Capris, P. & Izzotti, A. 2005. Oxidative DNA damage in the human trabecular meshwork: clinical correlation in patients with primary open-angle glaucoma. *Arch. Ophthalmol.* 2005, Vol. 123, pp. 458-463
- Saccà, SC., Izzotti, A., Rossi, P. & Traverso, C. 2007. Glaucomatous outflow pathway and oxidative stress. *Exp. Eye Res.* 2007, Vol. 84, pp. 389-399.
- Schmidt, KG., Mittag, TW., Pavlovic, S. & Hessemer, V. 1996. Influence of physical exercise and nifedipine on ocular pulse amplitude. *Graefes Arch Clin Exp Ophthalmol.* 1996, Vol. 234, pp. 527-32.
- Schmidt, KG., Mittag, TW., Pavlovic, S. & Hessemer, V.. 1996. Influence of physical exercise and nifedipine on ocular pulse amplitude. *Graefes Arch. Clin. Exp. Ophthalmol.* 1996, Vol. 234, pp. 527-532.
- Schmidt KG., Ruckmann A., Klingmuller V., Becker R., Pillunat LE. & Mittag TW. 1998. Ocular pulse amplitude during manipulation of systemic perfusion parameters. *Klin Monatsbl Augenheilkd.* 1998, Vol. 213, pp. 241-244.
- Schwenn O., Troost R., Vogel A., Grus F., Beck S. & Pfeiffer N. 2002. Ocular pulse amplitude in patients with open angle glaucoma, normal tension glaucoma, and ocular hypertension. *Br J Ophthalmol.* 2002, Vol. 86, pp. 981-984.
- Sei, H. & Morita, Y. 1999. Why does arterial blood pressure rise actively during REM sleep? *J Med Invest.* 1999, Vol. 46, pp. 11-7.
- Shah, P., Whittaker, KW., Wells, AP. & Khaw, PT. 2001. Exercise-induced visual loss associated with advanced glaucoma in young adults. *Eye (Lond).* 2001, Vol. 15, pp. 616-20.
- Siesky, BA., Harris, A., Patel, C., Klaas, CL., Harris, M., McCranor, LJ., Lauer, J. & Kaplan, B. 2000. Comparison of visual function and ocular hemodynamics between pre- and post-menopausal women. *Eur J Ophthalmol.* 2000, Vol. 18, pp. 320-3.
- Siesky, B., Harris, A., Sines, D., Rechtman, E., Malinovsky, VE., McCranor, L., Yung, CW. & Zalish, M. 2006. A comparative analysis of the effects of the fixed combination of

- timolol and dorzolamide versus latanoprost plus timolol on ocular hemodynamics and visual function in patients with primary open-angle glaucoma. *J Ocul Pharmacol Ther.* 2006, Vol. 22, pp. 353-61.
- Siesky, B., Harris, A., Brizendine, E., Marques, C., Loh, J., Mackey, J., Overton, J. & Netland, P. 2009. Literature review and meta-analysis of topical carbonic anhydrase inhibitors and ocular blood flow. *Surv Ophthalmol.* 2009, Vol. 54, pp. 33-46.
- Silberstein, SD., Goadsby, PJ. & Lipton, RB. 2000. Management of migraine: an algorithmic approach. *Neurology.* 2000, Vol. 55, pp. 46-52.
- Soares, AS., Artes, PH., Andreou, P., Leblanc, RP., Chauhan, BC. & Nicolela, MT. 2004. Factors associated with optic disc hemorrhages in glaucoma. *Ophthalmology.* 2004, Vol. 111, pp. 1653-7.
- Sossi, N. & Anderson, DR. 1983. Blockage of axonal transport in optic nerve induced by elevation of intraocular pressure. Effect of arterial hypertension induced by angiotensin I. *Arch Ophthalmol.* 1983, Vol. 101, pp. 94--7,.
- Stalmans I., Harris A., Vanbellinghen V., Zeyen T. & Siesky B. 2008. Ocular Pulse Amplitude in Normal Tension and Primary Open Angle Glaucoma. *J Glaucoma.* 2008, Vol. 17, pp. 403-407.
- Stalmans I., Harris A., Fieuws S., Zeyen T., Vanbellinghen V., McCranor L. & Siesky B. 2009. Color Doppler imaging and ocular pulse amplitude in glaucomatous and healthy eyes. *European Journal of Ophthalmology.* 2009, Vol. 19, pp. 580-587.
- Steigerwalt, RD., Belcaro, GV., Laurora, G., Cesarone, MR., De Sanctis, MT. & Incandela, L. 1998. Ocular and orbital blood flow in patients with essential hypertension treated with trandolapril. *Retina.* 1998, Vol. 18, pp. 539-45.
- Strenn, K., Matulla, B., Wolzt, M., Findl, O., Bekes, MC., Lamsfuss, U., Graselli, U., Rainer, G., Menapace, R., Eichler, HG. & Schmetterer, L. 1998. Reversal of endothelin-1-induced ocular hemodynamic effects by low-dose nifedipine in humans. *Clin. Pharmacol. Ther.* 1998, Vol. 63, pp. 54-63.
- Stroke Prevention by Aggressive Reduction in Cholesterol Levels (SPARCL), Investigators. 2006. High-dose atorvastatin after stroke or transient ischemic attack. *N Engl J Med.* 2006, Vol. 355, pp. 549 -59.
- Stroman, GA., Stewart, WC., Golnik, KC., Curé, JK. & Olinger, RE. 1995. Magnetic resonance imaging in patients with low-tension glaucoma. *Arch Ophthalmol.* 1995, Vol. 113, pp. 168-72.
- Sung, KR., Lee, S., Park, SB., Choi, J., Kim, ST., Yun, SC., Kang, SY., Cho, JW. & Kook, MS. 2009. Twenty-four hour ocular perfusion pressure fluctuation and risk of normal-tension glaucoma progression. *Invest Ophthalmol Vis Sci.* 2009, Vol. 50, pp. 5266-74.
- Tezel, G. & Wax M. 2004. Hypoxia-inducible factor 1alpha in the glaucomatous retina and optic nerve head. *Arch Ophthalmol.* 2004, Vols. Tezel, G. and M. Wax, Hypoxia-inducible factor 1alpha in the glaucomatous retina and optic nerve head. *Arch Ophthalmol*, 2004. 122(9): p. 1348-56., pp. 1348-56.
- Tfelt-Hansen P, Saxena PR, Dahlöf, C., Pascual, J., Láinez, M., Henry, P., Diener, H., Schoenen, J., Ferrari, MD. & Goadsby, PJ. 2000. Ergotamine in the acute treatment of migraine: a review and European consensus. *Brain.* 2000, Vol. 123, pp. 9-18.
- Tielsch JM., Katz J., Sommer A., Quigley HA. & Javitt JC. 1995. Hypertension, perfusion pressure, and primary open angle glaucoma. A population-based assessment. *Arch Ophthalmol.* 1995, Vol. 113, pp. 216-221.

- Tomita, K., Araie, M., Tamaki, Y., Nagahara, M., & Sugiyama, T. 1999. Effects of nilvadipine, a calcium antagonist, on rabbit ocular circulation and optic nerve head circulation in NTG subjects. *Invest. Ophthalmol. Vision Sci.* 1999, Vol. 40, pp. 1144–1151.
- Traustason, S., Hardarson, SH., Gottfredsdottir, MS., Eysteinnsson, T., Karlsson, RA., Stefánsson, E. & Harris, A. 2009. Dorzolamide-timolol combination and retinal vessel oxygen saturation in patients with glaucoma or ocular hypertension. *Br J Ophthalmol.* 2009, Vol. 93, pp. 1064–7.
- Tribble, JR., Costa, VP., Sergott, RC., Spaeth, GL., Smith, M., Wilson, RP., Katz, LJ., Moster, MR. & Schmidt, CM. 1994. The influence of primary open-angle glaucoma upon the retrobulbar circulation: baseline, postoperative and reproducibility analysis. *Trans. Am. Ophthalmol.* 1994, pp. 245–265.
- Tribble, JR., Sergott, RC., Spaeth, GL., Wilson, RP., Katz, LJ., Moster, MR. & Schmidt, CM. 1994. Trabeculectomy is associated with retrobulbar hemodynamic changes. A color Doppler analysis. *Ophthalmology.* 1994, Vol. 101, pp. 340–51.
- Vaughan, CJ. & Delanty, N. 1999. Neuroprotective properties of statins in cerebral ischemia and stroke. *Stroke.* 1999, Vol. 30, pp. 1969–73.
- Vulsteke C., Stalmans I., Fieuws S. & Zeyen T. 2008. Correlation between ocular pulse amplitude measured by dynamic contour tonometer and visual field defects. *Graefes Arch Clin Exp Ophthalmol.* 2008, Vol. 246, pp. 559–565.
- Waldmann, E., Gasser, P., Dubler, B., Huber, C. & Flammer, J. 1996. Silent myocardial ischemia in glaucoma and cataract patients. *Graefe's Arch. Clin. Exp. Ophthalmol.* 1996, Vol. 234, pp. 595–598.
- Walsh, JT. & Montplaisir, J. 1982. Familial glaucoma with sleep apnoea: a new syndrome? *Thorax.* 1982, Vol. 37, pp. 845–9.
- Wang, JJ., Liew, G., Klein, R., Rochtchina, E., Knudtson, MD., Klein, BE., Wong, TY., Burlutsky, G. & Mitchell, P. 2007. Retinal vessel diameter and cardiovascular mortality: pooled data analysis from two older populations. *Eur Heart J.* 2007, Vol. 28, pp. 1984–92.
- Weigert, G., Resch, H., Garhofer, G., Fuchsjäger-Mayrl, G. & Schmetterer, L. 2007. Effects of topical clonidine versus brimonidine on choroidal blood flow and intraocular pressure during squatting. *Invest Ophthalmol Vis Sci.* 2007, Vol. 48, pp. 4220–5.
- Williamson, TH., Lowe, GD. & Baxter, GM. 1995. Influence of age, systemic blood pressure, smoking and blood viscosity on orbital blood velocities. *Br J Ophthalmol.* 1995, Vol. 79, pp. 17–22.
- Wimpissinger, B., Resch, H., Berisha, F., Weigert, G., Schmetterer, L. & Polak, K. 2004. Response of choroidal blood flow to carbogen breathing in smokers and non-smokers. *Br J Ophthalmol.* 2004, Vol. 88, pp. 776–81.
- Wong, TY., Klein, R., Couper, DJ., Cooper, LS., Shahar, E., Hubbard, LD., Wofford, MR. & Sharrett, AR. 2001. Retinal microvascular abnormalities and incident stroke: the Atherosclerosis Risk in Communities Study. *Lancet.* 2001, Vol. 358, pp. 1134–40.
- Wong, TY., Klein, R., Sharrett, AR., Duncan, BB., Couper, DJ., Tielsch, JM., Klein, BE. & Hubbard LD. 2002. Retinal arteriolar narrowing and risk of coronary heart disease in men and women. The Atherosclerosis Risk in Communities Study. *JAMA.* 2002, Vol. 287, pp. 1153–9.
- Yamamoto, T., Niwa, Y., Kawakami, H. & Kitazawa, Y. 1998. The effect of nilvadipine, a calcium-channel blocker, on the hemodynamics of retrobulbar vessels in normal-tension glaucoma. *J. Glaucoma.* 1998, Vol. 7, pp. 301–305.

- Zeitz O, Galambos P, Wagenfeld L, Wiermann A, Wlodarsch P, Praga R, Matthiessen ET, Richard G, Klemm M. 2006. Glaucoma progression is associated with decreased blood flow velocities in the short posterior ciliary artery. *Br J Ophthalmol*. 2006, Vol. 90, pp. 1245-8.
- Zeitz, O., Vilchez, SE., Matthiessen, ET., Richard, G. & Klemm, M. 2006. Volumetric colour Doppler imaging: a useful tool for the determination of ocular blood flow in glaucoma patients? *Eye (Lond)*. 2006, Vol. 20, pp. 668-73.
- Zhou, RH. & Frishman, WH. 2010. The Antiplatelet Effects of Nitrates: Is it of Clinical Significance in Patients With Cardiovascular Disease? *Zhou, Rui-Hai MD**; *Frishman, William H. MD†*. 2010, Vol. 18, pp. 198-203.



Glaucoma - Basic and Clinical Concepts

Edited by Dr Shimon Rumelt

ISBN 978-953-307-591-4

Hard cover, 590 pages

Publisher InTech

Published online 11, November, 2011

Published in print edition November, 2011

This book addresses the basic and clinical science of glaucomas, a group of diseases that affect the optic nerve and visual fields and is usually accompanied by increased intraocular pressure. The book incorporates the latest development as well as future perspectives in glaucoma, since it has expedited publication. It is aimed for specialists in glaucoma, researchers, general ophthalmologists and trainees to increase knowledge and encourage further progress in understanding and managing these complicated diseases.

How to reference

In order to correctly reference this scholarly work, feel free to copy and paste the following:

Luís Abegão Pinto and Ingeborg Stalmans (2011). A Vascular Approach to Glaucoma, Glaucoma - Basic and Clinical Concepts, Dr Shimon Rumelt (Ed.), ISBN: 978-953-307-591-4, InTech, Available from: <http://www.intechopen.com/books/glaucoma-basic-and-clinical-concepts/a-vascular-approach-to-glaucoma>

INTech
open science | open minds

InTech Europe

University Campus STeP Ri
Slavka Krautzeka 83/A
51000 Rijeka, Croatia
Phone: +385 (51) 770 447
Fax: +385 (51) 686 166
www.intechopen.com

InTech China

Unit 405, Office Block, Hotel Equatorial Shanghai
No.65, Yan An Road (West), Shanghai, 200040, China
中国上海市延安西路65号上海国际贵都大饭店办公楼405单元
Phone: +86-21-62489820
Fax: +86-21-62489821

© 2011 The Author(s). Licensee IntechOpen. This is an open access article distributed under the terms of the [Creative Commons Attribution 3.0 License](https://creativecommons.org/licenses/by/3.0/), which permits unrestricted use, distribution, and reproduction in any medium, provided the original work is properly cited.

IntechOpen

IntechOpen