

# We are IntechOpen, the world's leading publisher of Open Access books Built by scientists, for scientists

6,900

Open access books available

185,000

International authors and editors

200M

Downloads

Our authors are among the

154

Countries delivered to

TOP 1%

most cited scientists

12.2%

Contributors from top 500 universities



WEB OF SCIENCE™

Selection of our books indexed in the Book Citation Index  
in Web of Science™ Core Collection (BKCI)

Interested in publishing with us?  
Contact [book.department@intechopen.com](mailto:book.department@intechopen.com)

Numbers displayed above are based on latest data collected.  
For more information visit [www.intechopen.com](http://www.intechopen.com)



# Medical Theory on Orthopedics Combining Molecular Imaging with Clinical Practice

Jing jing Peng

*Dept. Beijing Institute of Traumatology and Orthopaedics*

*Beijing Ji Shui-Tan Hospital*

*The 4<sup>th</sup> Clinical Hospital of Peking University*

*China*

## 1. Introduction

Soft tissue is defined as the supportive tissue of various organs, the term soft tissue tumors defines neoplasms derived from soft tissue. At the clinical level, a mass is the most common sign of a soft tissue tumor. However the clinical manifestations and signs of parathyroid adenoma are not in the neck at first. Some patient who's neck was normal at physical examination. Bone pain or dysfunction fractures are always the main reason for the parathyroid tumor patients to the hospital [1, 2]. Parathyroid tumor Figure 1 is an endocrine tumor, mainly associating with bone metabolism, so the patients go to the orthopedic department first. Although the parathyroid tumor is benign, However if patients do not get timely and accurate diagnosis and effective treatment (surgical removal of parathyroid adenoma), they will not only receive the delayed treatment, the decline of life quality, but also the disability, loss of ability to work, Increasing the burden on families and society. Figure 2 Whole body bone scan: Parathyroid tumor lead to severe metabolic bone disease which causes the patient disabled.

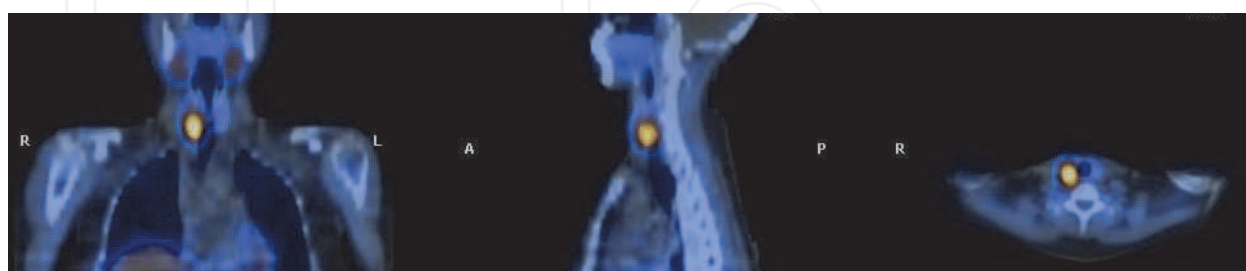


Fig. 1. Parathyroid adenoma

The neck SPECT/CT scan function-anatomy fused Imaging reveals A focus of increased  $^{99m}\text{Tc}$ -MIBI activity at the posterior inferior of the right lobe of the thyroid which consistent with parathyroid adenoma

Figure 2: metabolic bone disease which causes the patient disabled

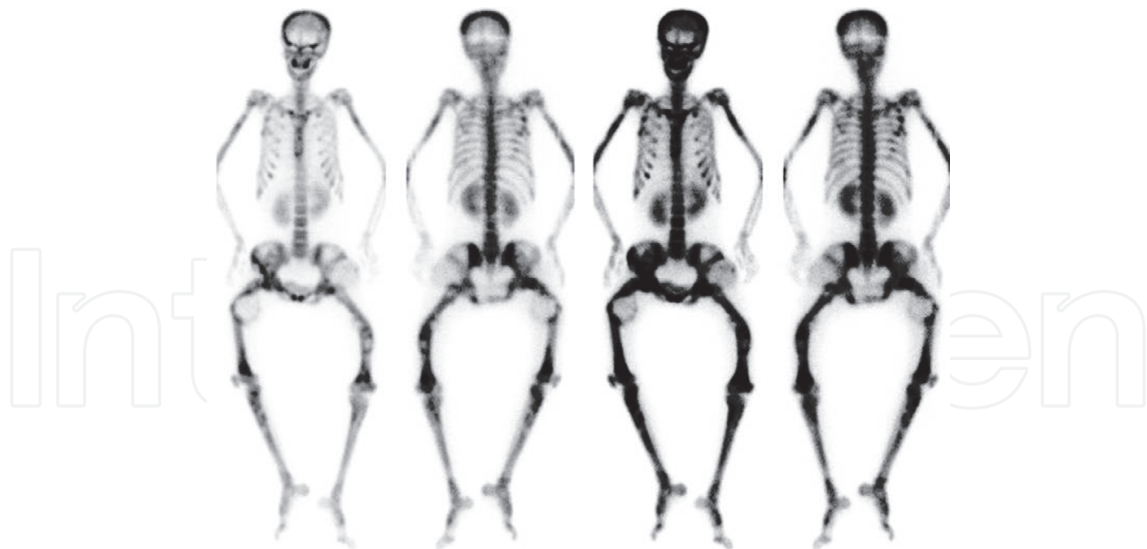



Fig. 2. A 39 years-old woman complained of painful bone and joint for a long time with occurred fracture time and again.  $^{99m}\text{Tc}$ -MDP Bone Scan shows: metabolic bone disease which causes the patient disabled. Her diagnosis is Parathyroid adenoma and she was performed a parathyroid adenoma ectomy in surgical operation.

Effective treatment for parathyroid tumors depends on timely, accurate diagnosis. Beijing Ji Shui Tan Hospital Peking University(JST) doctor Peng Jing Jing Primary academic contributions<Advancement in the Application of Nuclear Medicine> was published in Apr.2001 V7N4:59-61 Journal of "China Contemporary Medicine" reported the use of nuclear medicine that is molecular imaging of early diagnosis successful treatment of patients with parathyroid adenoma. The cases in clinical with SPECT for  $^{99m}\text{Tc}$ -MDP whole body bone scan and  $^{99m}\text{Tc}$ -MIBI parathyroid tumor imaging, in which patients receive timely diagnosis and successful treatment, recover and happy life<sup>[3]</sup>. In recent years, as the clinic study of new technology and equipment in bone-joint disorders, orthopedic clinical applications of molecular imaging and promotion of the Chinese doctors for parathyroid tumor diagnosis and treatment, as medical science has made a positive contribution <sup>[4]</sup>.

The contribution showed typical diagnostic Imaging of hyperparathyroidism resulted in metabolic bone disease characteristic abnormalities Figure.3:

1. The Black skull: increased uptake in calvaria and jawbone.
2. Generalized increased uptake with increased contrast between bone and soft tissue due to bone turnover speed and subtracted kidney image.
3. Tie sternum and Cage beads.
4. Foci of increased uptake due to fracture or brown tumor in rib cage.
5. Decreased uptake brown tumor in the right ilium as doughnut .
6. Whole body Bone scan patterns in advanced metabolic bone disease and insufficiency fracture in right neck of femur.

There are two main features of metabolic bone disease due to hyperparathyroidism in  $^{99m}\text{Tc}$ -MDP bone imaging: (1) Increased uptake in calvaria and jawbone showed "the Black skull". (2) Bone scan is clear showed total body as "Super Scan": Generalized increased uptake with increased contrast between bone and soft tissue: increased uptake in long bones and increased uptake in axial skeleton, increased uptake in periarticular areas, increased uptake in costochondral junctions (beads) and increased uptake in sternum (tie sternum).The patient right leg was shorten with foci of increased uptake due to dysfunction fracture, brown tumor due to fibrocystic changes.



Beijing JST hospital 31<sup>st</sup> Xin Jie-kou East Street, Beijing, P.R. China

Dear Dr. Sun: 1999.01.11

RE: Mis. Liang beauty DOB1958.07.09 Age: 40

ID: 305447 SPECT: 981193 Address: Hebei China

---

I saw this pleasant lady in my inpatients clinic on 1998.12 .09

She was C/O painful hip radiating to her legs.

Mrs. Liang was admitted into hospital on 1998.12.07 her X-Ray showed the Femoral neck pathological fracture of the right femur. ? metastatic bone disease.

On questioning her, I found that Mrs. liang had been C/O leg pain for 3 years, Also she felt severe right hip pain before my seeing her 2 /52.

On examination, I found her right leg was external rotated and shorten, there was tenderness in the hip joint and mildly swollen. Her Vital signs were normal (Temp\ pulse \Resp \B/P).

Tests carried out were:

Hip X-ray BMD (bone mineral density)

ECT: bone scan and parathyroid tumor image

Ultra scan

Blood tests:

Serum Ca (calcium), P (phosphorus), AKP, PTH, ESR

The results showed she had a hypercalcemia and hypophosphatemia:

Serum Ca was high 3.11(2.25-2.75) mmol/L,

Serum P was lower 0.85(0.97-1.6) mmol/L.

AKP was high 502(25-90) IU/L.

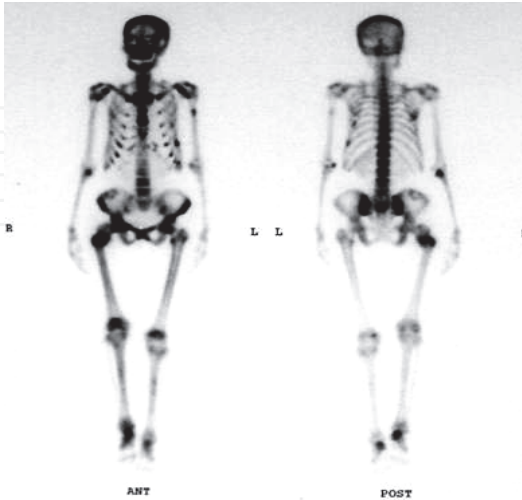
PTH (parathyroid hormone) was high.

Hip X-ray showed: The intertrochanter's fracture of the right femur.

BMD was low: T scores of < 2.5SD

Bone scan(<sup>99m</sup>Tc-MDP)patterns in advanced metabolic bone disease (please see attached picture):

FIGURE 3: Diagnostic Imaging of hyperparathyroidism resulted in metabolic bone disease



99mTc-MDP Bone scan showed metabolic disease

Fig. 3. Diagnostic Imaging of hyperparathyroidism resulted in metabolic bone disease characteristic abnormalities.

The right leg was dysfunction fracture of the right femur. In conclusion, I think that diagnosis hyperparathyroidism.

So, I have had  $^{99m}\text{Tc}$ -MIBI parathyroid tumor double-phase imaging.  $^{99m}\text{Tc}$ -MIBI parathyroid tumor imaging not only can observe the shape and location, but also display functional status for parathyroid tumor.

FIGURE 4:  $^{99m}\text{Tc}$ -MIBI parathyroid tumor (double-phase) imaging

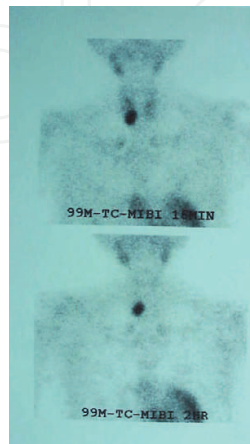


Fig. 4.  $^{99m}\text{Tc}$ -MIBI parathyroid tumor (double-phase) imaging.

Immediate (upper) and Delayed (lower)  $^{99m}\text{Tc}$ -MIBI imaging reveals a focus of increased activity at the inferior tip of the right lobe of the thyroid, Consistent with parathyroid adenoma.

$^{99m}\text{Tc}$ -MIBI scan showed: right lower parathyroid adenoma (Please see attached).

Ultra scan also showed: Parathyroid tumor

Diagnosis: Primary hyperparathyroidism caused by a parathyroid adenoma

Metabolic bone disease Osteoporosis

Dysfunction fracture (the right femur).

Mrs. Liang was given operating treatments on 1998.12.21:

First, was performed parathyroid adenoma' ectomy in surgical operating theatre.

Then, Reduction of fracture and internal fixation was performed by orthopedic doctor.

Finally, the diagnosis in pathology (98-X1095) was:

Parathyroid adenoma

Focus which lead to fracture of the right femur was brown tumor

She was discharged on 1999.01.11.

She was given diet and some medication advice to help her to gain full recovery.

I have suggested to Mrs. liang that she sees you, when she arrives at Hebei for a check up.

Kind regards,

Dr. Jing-jing Peng

Beijing Ji Shui-Tan Hospital

Beijing Institute of

Traumatology and Orthopaedics

The 4<sup>th</sup> Clinical Hospital of Peking University

Email: pjhyx@sina.com

Web: <http://www.jst-hosp.com.cn>

JST' doctor Peng Jing Jing etc. Primary Academic contributions to this project

< Application of Radionuclide Imaging in Diagnosis of hyperfunctioning Parathyroid tumors>journal of Chinese Nuclear Medicine Dec.2003<sup>[2]</sup> .Cited by Zhuhai City, Guangdong Province People's Hospital Chen Jiang lin etc. in Anthology of Medicine Apr.2006<sup>[5]</sup>, the paper reported a case Qualitative and locational diagnosis with nuclear medicine of primary hyperparathyroidism and successful surgery of parathyroid adenoma: Peng Jingjing et al thought, there are two main features of metabolic bone disease due to hyperparathyroidism in <sup>99m</sup>Tc-MDP bone imaging: (1) Bone scan is clear showed total body as "Super Scan"; (2) Increased uptake in calvaria and jawbone for <sup>99m</sup>Tc-MDP showed "the Black skull". <sup>99m</sup>Tc- MIBI parathyroid tumor imaging not only can observe the shape and location, but also display hyper-functional status for parathyroid tumor.

Achiever said: Primary hyperparathyroidism is rare in clinic. Because of occult onset and symptoms varied, misdiagnosis is made sometimes. A clear diagnosis of hyperparathyroidism and parathyroid tumors localization is the key for successful treatment. <sup>99m</sup>Tc-MDP bone scintigraphy and <sup>99m</sup>Tc -MIBI parathyroid tumor imaging has certain advantages. To be used clinically, those principal achieves can reduce misdiagnosis of primary hyperparathyroidism.

## 2. Clinical features of parathyroid adenoma

### 2.1 Definition

Primary hyperparathyroidism incidence rate is about 27/100000 per year, of which 80% is parathyroid tumor, 20% is benign hyperplasia, and parathyroid carcinoma is extremely rare. Because of the parathyroid hormone (PTH) secretes more than the level required to maintain normal serum calcium concentration, bring about laboratory parameters abnormal shows hypercalcemia, hypophosphatemia, elevated alkaline phosphatase and parathyroid hormone increased.

Clinical symptoms mainly in four systems

1. Bones-- musculoskeletal symptoms: bone pain, dysfunction fractures;
2. Stones--symptoms of urinary system: history of kidney stones with pain;
3. Groans--digestive symptoms: abdominal discomfort, nausea, vomiting, dyspepsia and constipation;
4. Moans -- neuropsychiatric symptoms: memory loss, depression, depressed.

Diagnostic whole body bone scan image

"Super scan" of hyperparathyroidism (HPT) metabolic bone disease

Early parathyroid adenoma causing bone metabolism changes in <sup>99m</sup>Tc-MDP whole body bone scan image is generalized increased uptake with characterized by the "black skull" and very clearly as "super scan" which give expression to increased contrast between bone and soft tissue due to bone turnover speed and active bone metabolism.

Metabolic bone disease with HPT different from metastasis imaging

Differential point in whole body bone scan image between "super scan" of HPT metabolic bone disease and wide range of bone metastasis is: HPT metabolic bone disease "super scan" is general uniformity high uptake in the axial skeleton and limb bones (Figure 5); and features of bone metastasis "super scan" are: high uptake of the mainly axial skeleton (Figure 6) and proximal limb bone, with point like lesions of radioactive concentration.

Figure 5: "Super scan" with HPT metabolic bone disease

Figure 6: "Super scan" with extensive bone metastases



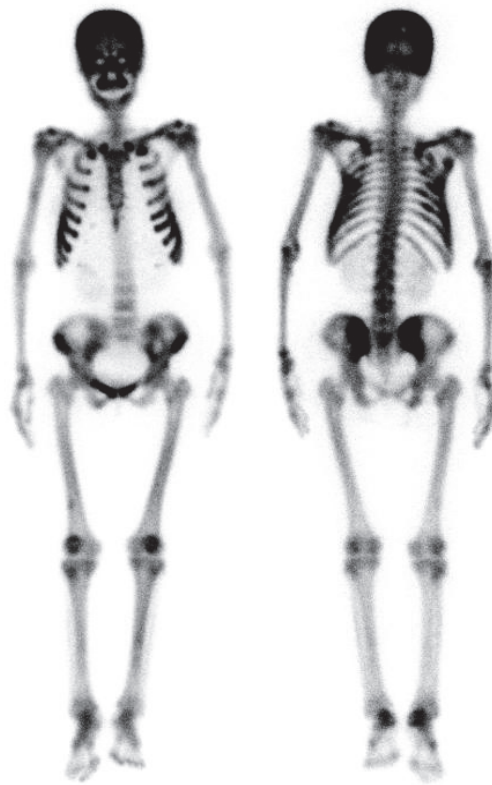

Fig. 5. "Super scan" with HPT metabolic bone disease

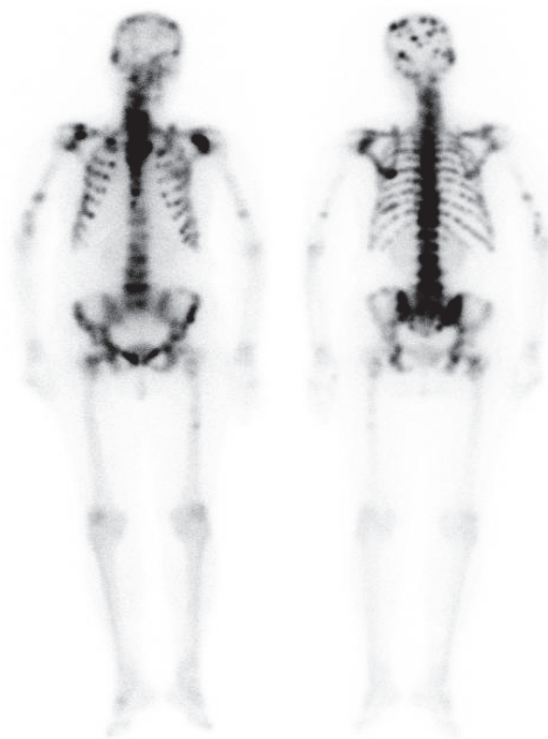


Fig. 6. "Super scan" with extensive bone metastases

## 2.2 Fracture and brown tumor

The Patient with proceeding of parathyroid tumors, X-ray radiograph shows bone resorption caused by osteoclast, and lacy cortical thinning leading to subperiosteal bone resorption, typical in middle phalanx radial side of index finger and middle finger.

Radiology images can also show brown tumor formed by micro-fracture bleeding, local accumulation of macrophages, and replacement of fibrous tissue. Brown tumor and fractures in the whole body bone scan images showed localized uptake. Large fibrocystic changes (brown tumor) can be expressed as a radioactive defect of the "cold zone" (Figure 2, the anteposition imaging shows: brown tumor in right ilium).

## 2.3 Preoperative localization of parathyroid adenoma

B-ultrasonic examination: after the diagnosis of HPT metabolic bone diseases, neck ultrasound is a simple and preferred method to localize the parathyroid tumors.

$^{99m}\text{Tc}$ -MIBI parathyroid tumor imaging: after the diagnosis of HPT metabolic bone diseases, the SPECT  $^{99m}\text{Tc}$ -MIBI double-phase parathyroid tumor imaging is helpful to the localization diagnosis of parathyroid adenoma (especially ectopic parathyroid adenoma) which is prepared for surgical removal.

## 3. Diagnosis and differential diagnosis of parathyroid tumor

### 3.1 Clinical diagnosis of parathyroid adenoma

1. Clinical manifestations of parathyroid adenoma have diversity. There are four mainly symptoms: skeletal system, urinary tract stones, neuropsychiatric system and digestive symptoms. Bone pain and fracture is the most common complained of. Therefore, physicians and surgeons should have a basic consciousness with the diagnosis of parathyroid tumors, such as patients with long kidney stones history, have symptoms of bone pain or fractures.
2. Laboratory test is helpful to the diagnosis of hyperparathyroidism: calcium, phosphorus, alkaline phosphatase (AKP) and parathyroid hormone (PTH) was abnormal.
3. The recognition characteristic image of the "super scan " of hyperparathyroidism in  $^{99m}\text{Tc}$ -MDP whole body bone scan is very important.
4. Neck ultrasonography and  $^{99m}\text{Tc}$ -MIBI double-phase parathyroid imaging can diagnose and localize parathyroid tumor clearly, which contribute to parathyroid tumor surgery.

### 3.2 Differential diagnosis of parathyroid adenoma in clinical orthopedics

Abnormal secretion of parathyroid hormone PTH leads to changes in bone metabolism in parathyroid tumor patients .Bone pain or dysfunction fracture are always the reason for patients to the hospital. There were many patients initially diagnosed with unilateral bone cyst (Brown tumor of fibrocystic changes in local radiology images), or misdiagnosed as bone metastases (bone scan imaging features were not yet understand). In order to accurate diagnosis and effective treatment for parathyroid tumor, it is very important to familiar with the differential diagnosis of bone scan, advances of orthopedic medical imaging basic research in molecular imaging and clinical application in bone tumors and disease as a starting point, the next section focus on the bone scan imaging features and differential diagnosis between parathyroid tumor metabolic bone disease and multiple myeloma,



rickets etc. eight diseases, with the aim of doctor comprehend typical characteristic distinction.

#### 4. Advancement in fundamental researches

New concept of orthopedic molecular imaging

International medical imaging community reached a consensus on the "molecular imaging" definition In June 2007:

1. "Molecular imaging" is the imaging embodiment for the molecular level;
2. "molecular imaging" observed living body (human or animal) in vivo, which can provided dynamic observation time-varying continuously.
3. "molecular imaging" can be detected by means of instruments (such as PCT/CT and MRI, etc. equipment) and can be quantitative.

The theoretical development of orthopedic molecular imaging was based on the new understanding of bone anatomy and physiology.

Bone structure of normal adult bone can be summarized in four categories [6]:

Gross level

The skeleton consists of two major parts, the axial skeleton includes the skull, spine and rib cage (ribs and sternum), while the appendicular skeleton includes the bones of the extremities, pelvic girdle and pectoral girdle (clavicles and scapulae)

Tissue level

Bone is divided into two types of tissues forming the skeleton: compact or cortical bone and cancellous, trabecular or spongy bone. The compact bone constitutes 80% of the skeletal mass. The appendicular skeleton is composed predominantly of cortical bone. The cortical bone is thicker in the diaphysis. The blood supply to the metaphysis is rich. The spine is composed predominantly of cancellous bone in the body of the vertebra and compact bone in the endplates and posterior elements. The spongy bone has a turnover rate approximately eight times greater than the cortical bones and hosts hematopoietic cells and many blood cells.

**Cellular level**

Three types of cells can be seen in bone: osteoblasts, which produce the organic bone matrix; osteocytes, which produce the inorganic matrix; osteoclasts, which are active in bone resorption. Osteoclasts are derived from the hemopoietic system, in contrast to the mesenchymal origin of osteoblasts. Osteocytes are derived from osteoblasts that have secreted bone matrix around themselves.

Molecular level

At the Molecular level, bone matrix is composed primarily of organic matrix (approximately 35%), including collagen and glycoproteins, and inorganic matrix (approximately 65%), which includes hydroxyapatite, cations (calcium, magnesium, sodium, potassium and strontium) and anions (fluoride, phosphorus and chloride). The calcium in inorganic matrix of bone provide hardness to withstand pressure, and the collagen fibers in organic components provide support and tension.

<sup>99m</sup>Tc-MDP bone scan can embodiment changes in the pathogenesis of the human body on the molecular level, and it is detected by SPECT, three phase imaging for patient examine dynamic change with time varying and may performed semi—quantitative analysis for

lesion,so bone scan is part of within the domain of molecular imaging [7]. Orthopedic Nuclear Medicine constitutes an important component of orthopedic molecular imaging. Recent Advances in Orthopedics Combined Medical Imaging with Clinical Practice are important to the development of molecular imaging and rich of content [8, 9], [7, 10]. For example, using isotopic tracer  $^{99m}\text{Tc}$ -MDP as a molecular probe we can tracer the oncology biological behavior of osteosarcoma<sup>[11]</sup>,Bone scan can detect multiple lesions of osteosarcoma, show the lung,bone and lymph node metastasis FIGURE.7(A), and provide postoperative follow-up for painful body differential diagnosis recurrence from prosthetic loose FIGURE.7 (B) and efficacy evaluation of chemotherapy. Chemotherapy efficacy for osteosarcoma before operation may be evaluted by quantitative study of  $^{18}\text{F}$ -FDG [12], and  $^{18}\text{F}$ -FDG imaging (SPECT/CT) to detect what primary carcinoma lesion is from and location for biopsy pathological confirmed diagnosis metastatic carcinoma<sup>[10]</sup> FIGURE.8, to solve the medical difficult problem.

Primary Academic contributions to this project 《Application of Radionuclide Imaging in Osteosarcoma》<sup>[11]</sup>Cited by Ruijin Hospital, Shanghai Jiao Tong University School of Medicine Feng Guo-wei etc. the paper reported a case bone scan uptake  $^{99m}\text{Tc}$ -MDP increased appearance in aggressive osteosarcoma with pleural,lung metastases demonstrated by operative pathological specimen<sup>[13]</sup>: Using SPECT Imaging and Molecular probe with tracer  $^{99m}\text{Tc}$ -MDP, After following up 133 patients with osteosarcoma,Peng Jingjing et al thought,  $^{99m}\text{Tc}$ -MDP SPECT images for detection of pulmonary and bone metastases and recurrent is useful, the usefulness of bone scintigraphy is overall, much earlier and sensitive than radiograph, X-ray and bone scan may complementary in favor of the patients diagnoses, treatment and follow up.

FIGURE.7  $^{99m}\text{Tc}$ -MDP tracer the oncology biological behavior of osteosarcoma

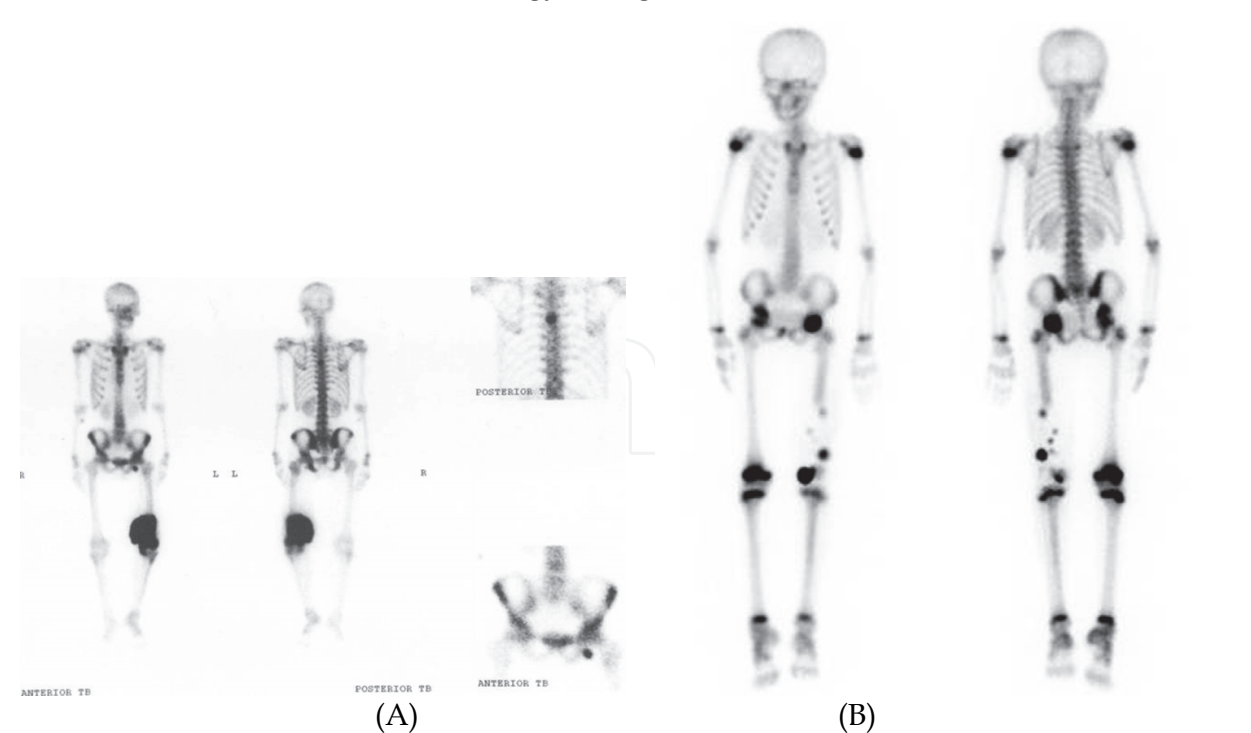


Fig. 7. Bone scan showed Osteosarcoma focus for  $^{99m}\text{Tc}$ -MDP positive imaging tracing metastases in bone and lymph node with surgical pathology confirmed (A) and recurrence indication after operation (B).

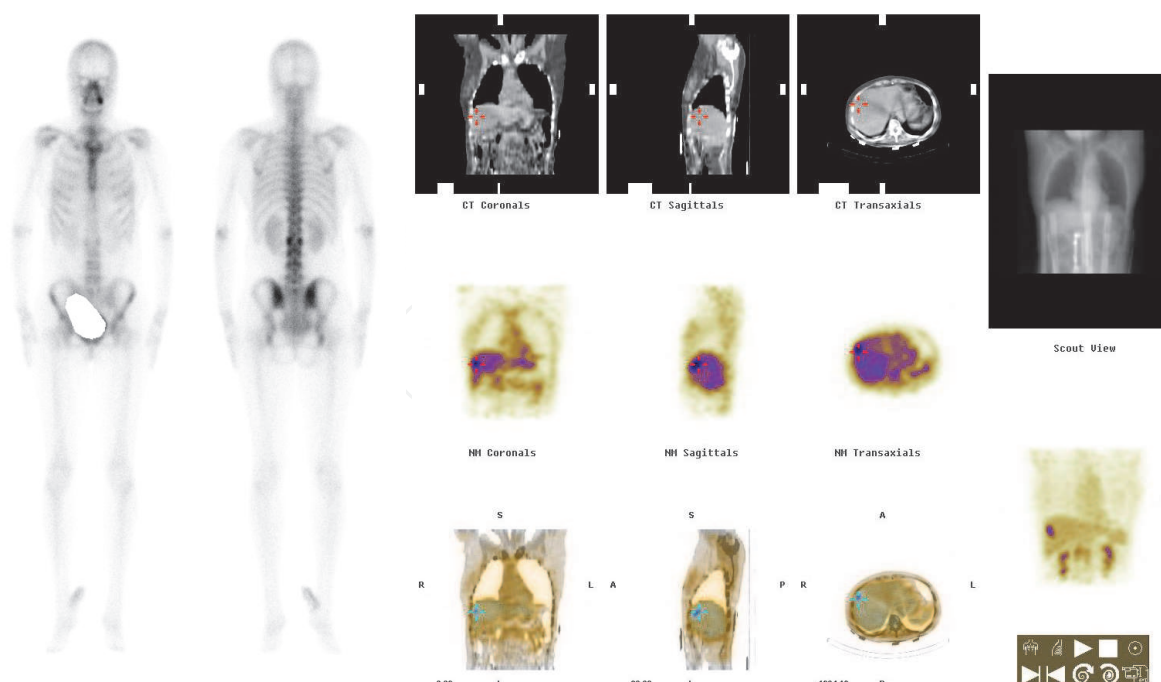


Fig. 8.  $^{18}\text{F}$ -FDG SPECT/CT detecting the primary carcinoma lesion and location for pathological confirmed lumbar spine metastatic carcinoma.

$^{99\text{m}}\text{Tc}$ -MDP bone scan (left) seen in single lumbar spine bone tumor which by hospital after operation surgical pathology confirmed metastatic carcinoma, primary tumor is unknown. By  $^{18}\text{F}$ -FDG SPECT / CT imaging (right) to detect the primary lesion, located in the liver, so the patient performed a specific liver therapy.

Of unknown primary tumor of bone metastases performed PET/CT scan is necessary because a variety of  $^{18}\text{F}$ -FDG is a sensitive tracer of malignant tumor, to identify the primary tumor so that patients can receive timely treatment. Unknown primary metastatic tumors occur in approximately 5% to 6.5%, according to report at least 1 / 3 of patients with PET detected the primary lesion, in which patients receive accurate and timely treatment.

## 5. Application of molecular imaging in diagnosis of orthopedic diseases

In the difficult diagnosis of puzzle patients and treatment, bring forth diagnostic  $^{99\text{m}}\text{Tc}$ -MDP bone scan new ideas were a positive contribution to the patient healthcare. 20 years ago, bone scan application was limited to multiple metastases. However in clinical practice, patients out of admiration for a famous, from all country came to Beijing JST Hospital whose first symptom are always bone pain and pathologic (or insufficiency) fractures. Difficult diagnosed patients were abnormal in bone scan, X-ray film, CT, or magnetic resonance imaging, but failed to identify problems .What is the real illness cause? Doctor must timely and accurate answers to diagnostic questions.

JST' hospital doctors lived through a long period and careful clinical research, the cognitive level of medical images has improved and advancement, bring Molecular Imaging in Diagnosis of Orthopedic Diseases new ideas. We summed up the imaging features diagnosis law of parathyroid tumor, and differentiate diagnosis regular pattern from other some diseases on bone scan, used the scientific theory to guide clinical practice.

The patients complained of bone pain and reasons unknown fracture were diagnosed accurately by the bone scan. Patients diagnosed metabolic bone disease primary hyperparathyroidism were treated with surgically removing of parathyroidoma, metabolic bone diseases by secondary hyperparathyroidism such as renal osteopathy or Rickets went to department of internal medicine treatment. Patients diagnosed with Multiple myeloma were treated in the hematology department. Patients diagnosed with articular disease were treated in the orthopedics [14] or rheumatology department. Patients diagnosed with benign or malignant bone primary tumor or bone disease were treated in bone oncology or pediatrics orthopedic department. Importantly, which eliminate the burden of mind for the patients without serious diseases and let them life tend to happily. Application of the research findings for imaging diagnoses can not only exclude the difficulty and anxiety for patients and get the cure suitable timely, but also provide the effective way for acquire the best economy social performance.

The bone scans imaging differential diagnosis of parathyroid adenoma there are eight of typical image patterns which a doctor should be familiar with in clinical diagnoses. Have you had an knowledge of thereafter imaging diagnoses Trained continued medical education[4]?

5.1 Primary hyperparathyroidism caused by a parathyroid adenoma

Metabolic bone disease

【case report】 Female patient, 29 years old complaining of pain in low back and both knees for 4 years, lower extremity weakness, vomiting and kidney stones 2 years. X-ray film showed severe osteoporosis, and fracture of the right pubic bone.

【The results of tests】 Ca ↑ 3.27 mmol / L (2.25 ~ 2.75), P ↓ 0.78 mmol / L (0.8 ~ 1.6), AKP ↑ 1002 mmol / L (25 ~ 90), parathyroid hormone (PTH) ↑ 70.1 (0.8 ~ 3.9)

【<sup>99m</sup>Tc-MDP Bone scan】

Fig. 9. <sup>99m</sup>Tc-MDP Bone scan showed metabolic disease with HPT



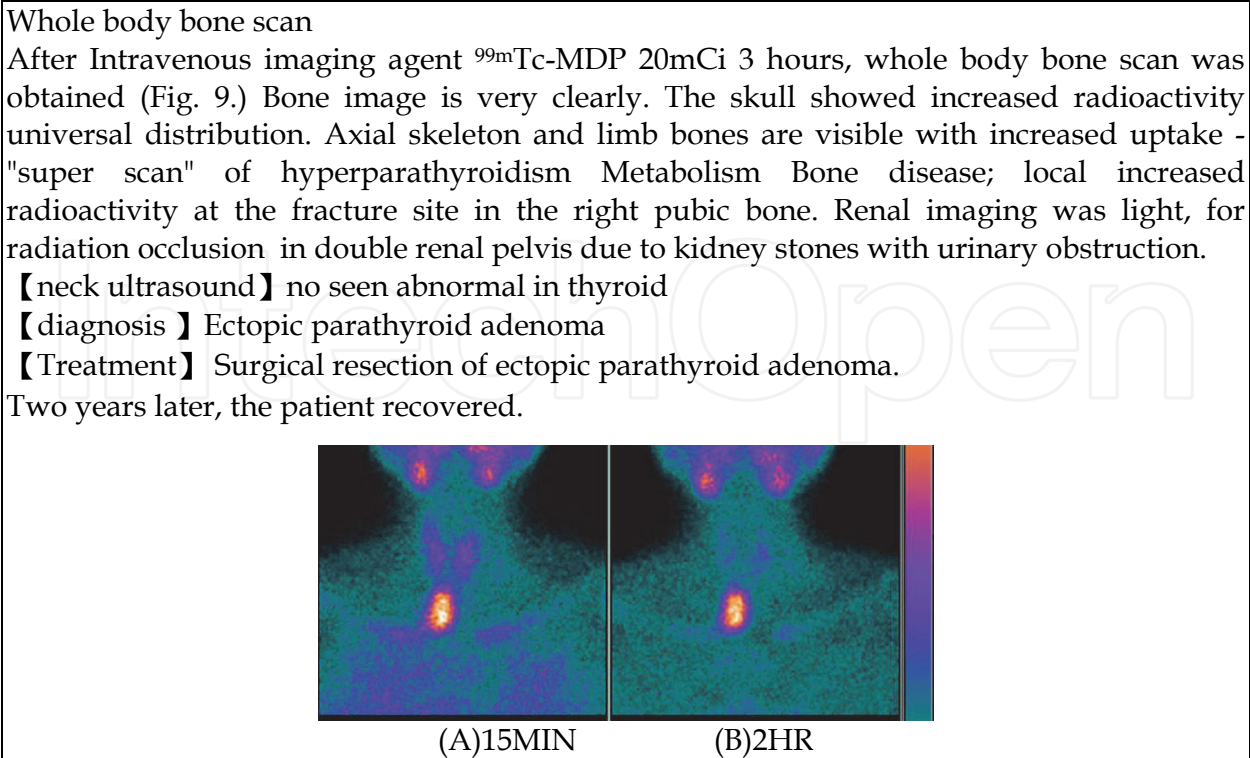


Fig. 10.  $^{99m}\text{Tc}$  -MIBI parathyroid tumor imaging

$^{99m}\text{Tc}$ -MIBI double-phase parathyroid tumor imaging: Early image (A)shows, the position and morphology of double-leaf thyroid were normal. The abnormal radioactive uptake can be seen on the right side below thyroid, the lower edge of which was close to the level of sternum .The size is about 3.8cm × 2.4cm. Delayed image (B) showed the thyroid image faded, and the oval-shaped abnormal lesion is still visible below the right side of thyroid.

5.2 Metastases “Super scan”

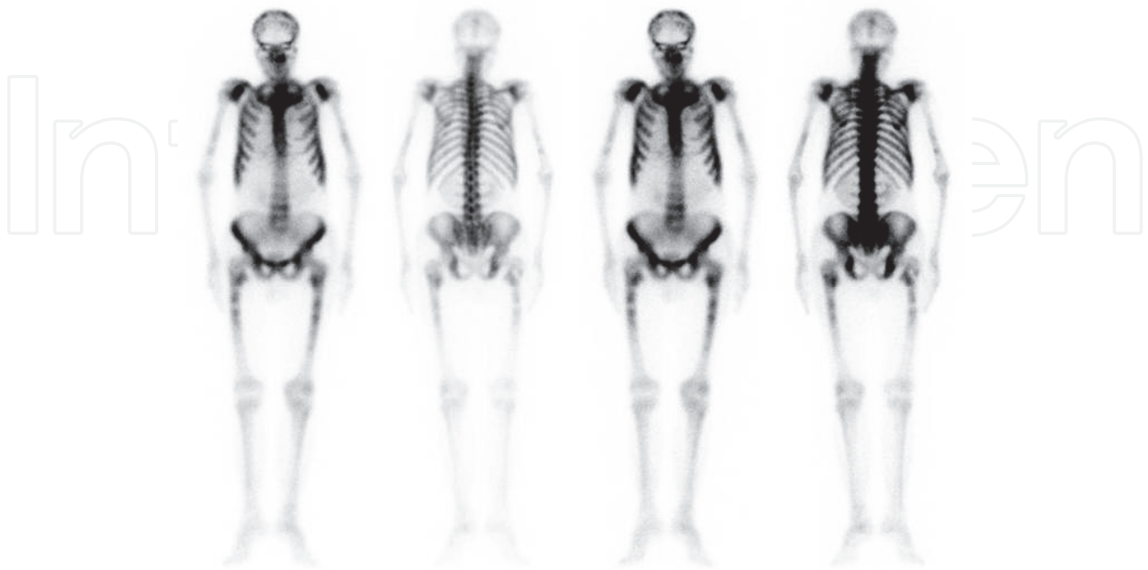

Fig. 11. Bone and bone marrows Metastases from poorly differentiated adenocarcinoma.

“Super scan” caused by extensive bone and marrow metastasis is different from the one caused by metabolic bone disease with hyperparathyroidism. The metastasis’ Super scan is characterized by diffuse uptake of lesions mainly located in the axial skeleton and proximal limbs, which can be spotty radioactivity concentration.

In hyperparathyroidism resulting in metabolic bone disease, “Super scan” is involving the entire bone. “The black skull” is obviously. Radioactivity distributes diffusely and evenly.

### 5.3 Hypertrophic Osteoarthropathy

Hypertrophic Osteoarthropathy caused by Secondary form intrathoracic pathological condition which is a form of periostitis and may be painful. Tubular bones may show periosteal new bone formation. This pathological feature explains the typical bone scan pattern of diffusely increased uptake along the cortical margins of long bones giving the appearance of “parallel tracks”.

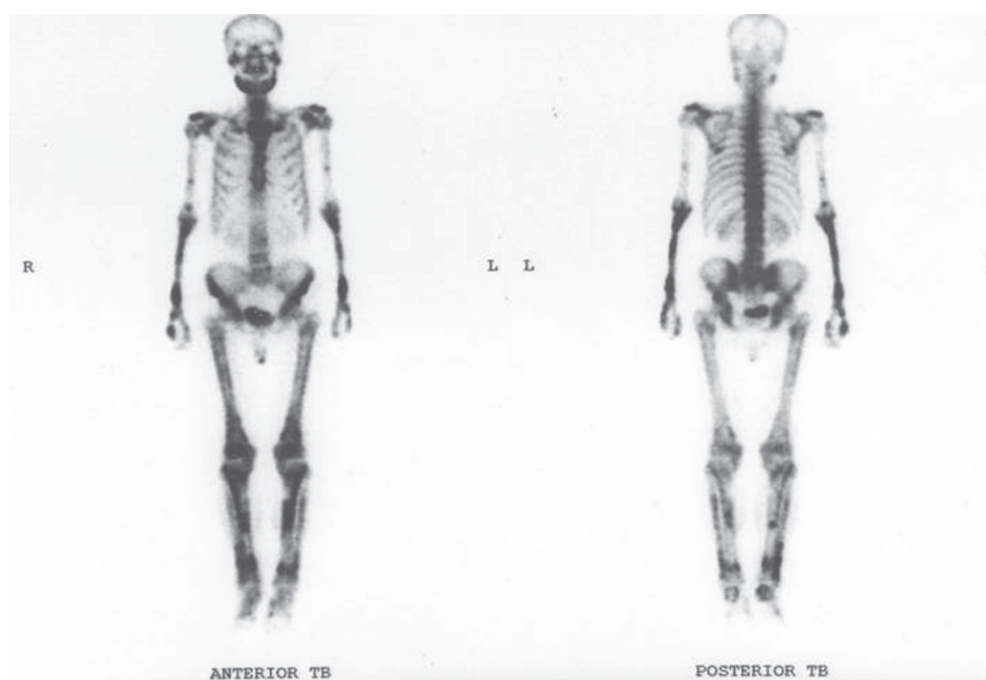


Fig. 12. Hypertrophic Pulmonary Osteoarthropathy: The parallel track pattern

Hypertrophic Pulmonary Osteoarthropathy in a patient with left lung hilum mass.

Note the diffusely increased uptake in all bones of the upper extremity and lower extremity with a parallel track pattern in the ulna-radius and tibiae.

### 5.4 Multiple Myeloma (MM)

Bone scan of MM shows “the same disease with different characteristics images”. The patient's image can have many manifestations: multiple uptake Increase strip or banding, decreased uptake cold spot lesions [15], which mainly distribute in the spine, pelvis, ribs, skull and proximal long bone.

In clinical work, some MM bone scan image does not show the bone destruction, so bone scan revealed no abnormalities. Imaging physicians and orthopedic surgeons should pay attention to the patient's complain for bone pain, considering for multiple myeloma.



Patient's relevant laboratory tests, bone pain, anemia, infection and renal dysfunction and related organ or tissue damage (ROTI) should be recorded.

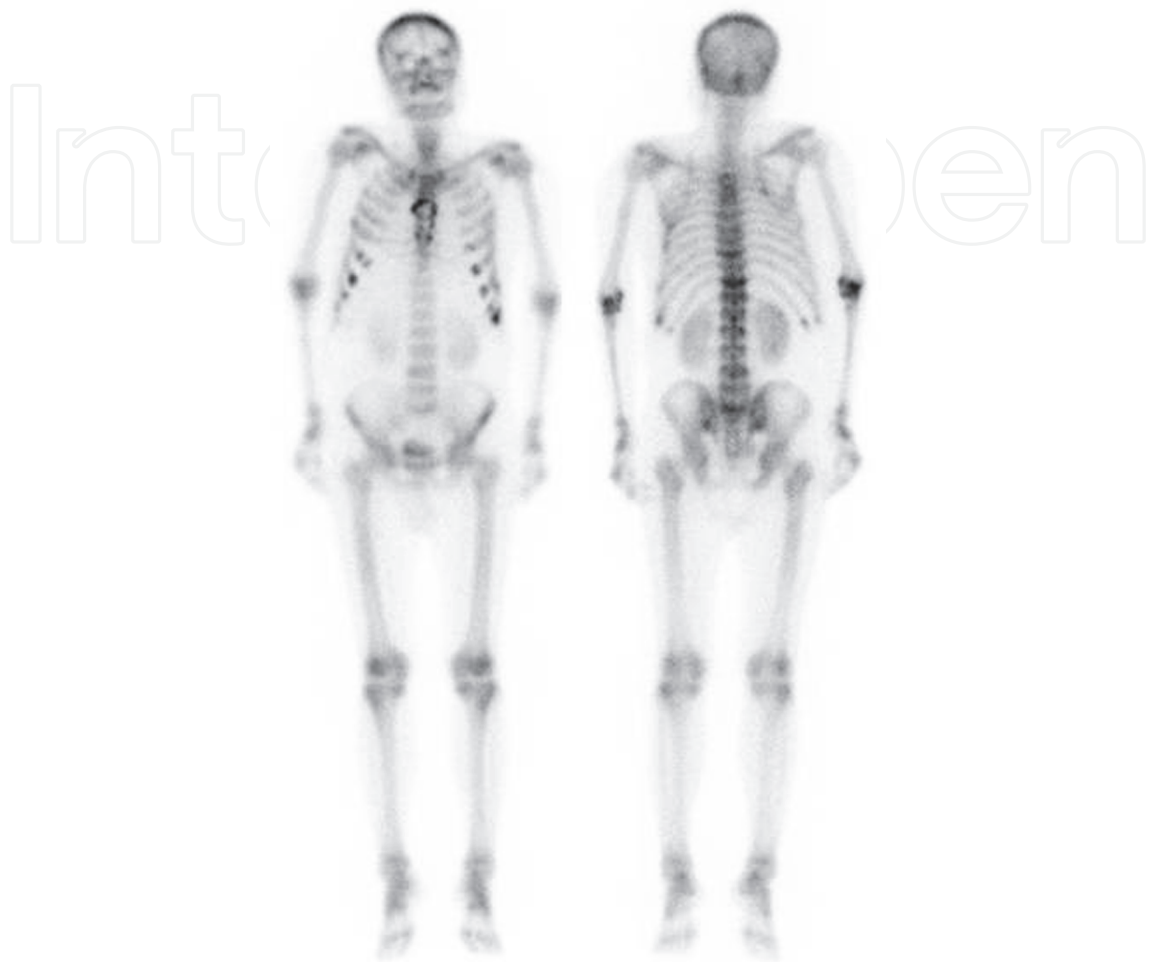


Fig. 13. Multiple Myeloma (MM) multiple striping or banding increased uptake with Spinal is the most common image pattern and the typical image pattern of decreased uptake “Cold spot” lesions on  $^{99m}\text{Tc}$ -MDP Bone scan (Note the “Cold spot” lesions in sternum)

### 5.5 Fibrous dysplasia

Fibrous dysplasia is a benign bone disorder which remains essentially unchanged and can be seen in lesion of long duration. The lesions cause thinning of the bone cortex and replacement marrow.

The condition may present as solitary lesion (monostotic) or with multiple foci (polyostotic). Polyostotic fibrous dysplasia may be associated with café-au-lait pigmentation and multiple endocrine hyperfunction, most commonly seen as precocious puberty in girls, Cushing's syndrome, and is called the McCune-Albright syndrome.

Standard radiographs show lucent areas with various amounts of ossification and cyst formation and may show expansion. Fibrous dysplasia, in general appears as an area of markedly increased uptake on  $^{99m}\text{Tc}$ -MDP bone scan.

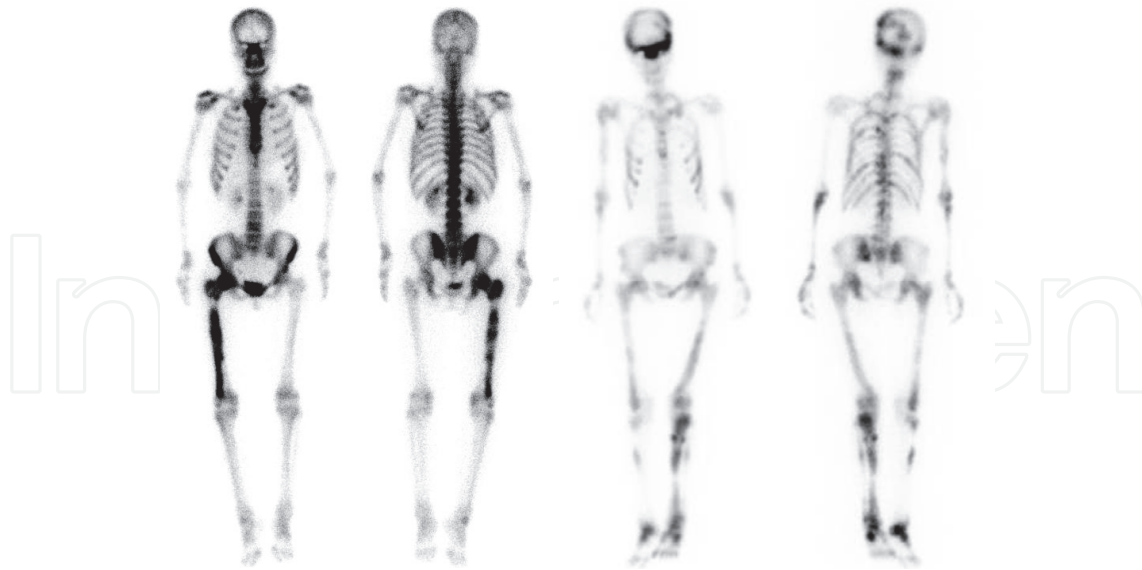


Fig. 14. Fibrous dysplasia (A) monostotic the right femur (B) polyostotic for whole body bone

Bone scan image show intensely increased uptake in lesion bones.

Whole body bone scan used for overlook the Fibrous dysplasia condition present as solitary lesion (monostotic) or with multiple foci (polyostotic).

### 5.6 Rheumatoid Arthritis

Rheumatoid Arthritis is the autoimmune disease causes inflammation of the connective tissue mainly in the joints. Synovitis activity is the dominant clinical variable that determines the therapeutic approach in patients with rheumatoid arthritis.  $^{99m}\text{Tc}$ -MDP bone scan used for overlook the all joint to measure the condition present of synovitis activity and differential diagnosis from other diseases result in bone-joint pain.

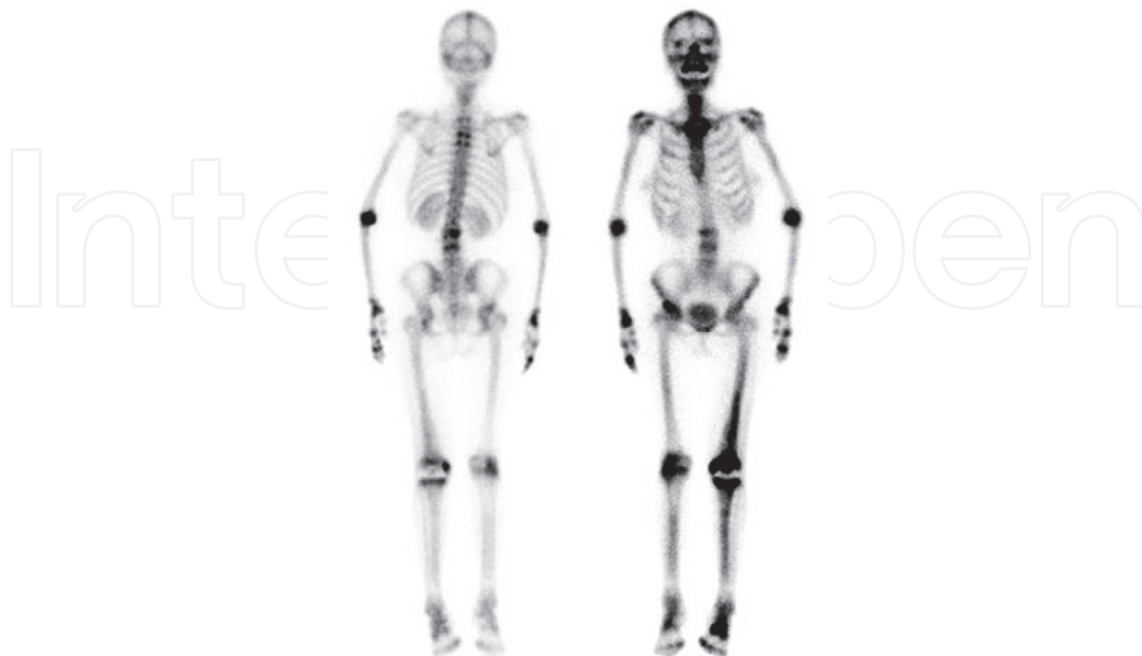


Fig. 15. Rheumatoid Arthritis Synovitis activity

A 52 years old female patient, suffered from rheumatoid arthritis 4 years. The left knee was painful and deformed for six months. TKA was done. Whole body bone scan showed that left knee joint was after treated by replacement surgery, and rheumatoid arthritis (active phase) violated elbows, wrists, hands, hips, knees, feet and thoracic and lumbar spine with Increase uptake in the areas of the joints affected Synovitis activity.

### 5.7 Rickets

A 41-year-old male patient suffered from joint pain and back pain more than 5 years and lower limbs were weakness gradually 1 year. He could not go on the working.

The patient suffered from intermittent back pain with no obvious incentive for 5 years, more severe in morning .It was also accompanied by joint stiffness, which reduced after the event, and did not affect the activities. Initially he was treated at a local hospital as rheumatoid arthritis, the pain releived. But in the past 2 years, the pain gradually got worse, double shoulder, hips, chest, leg were painful and weak. He was bound to bed, get up on stage difficultly. He was 7cm lower than he was young.

Tests carried out and The results showed

Serum calcium (Ca) 2.4mmol / L (2.25-2.75)

Serum phosphorus (P) ↓ 0.53mmol / L (0.8-1.6)

Alkaline phosphatase (AKP) ↑ 480 IU / L (25-90)

Rheumatoid factor (RF)-negative

HLA-B27- negative

A/G were normal, renal function BUN, CRE, UA mused in the normal range.

Spine X-ray showed osteoporosis. MRI reported suspected pelvis bone destruction. Whole body bone scan (Figure16) shows skeletal clearly: Bilateral ribs show multiple hot spots, as "beaded ribs"; the spine shows multiple vertebral collapse as strip change; The agent  $^{99m}\text{Tc}$ -MDP uptake in shoulders is increased, and the left is more; There are ribbon-like zones increased uptake in rib cage, pelvis, femora, tibia and metatarsals. Bone scintigraphy scan shows metabolic bone disease: A specific abnormality of the rickets is the presence of Looser's zones, also called Pseudofractures or Milkman's fractures.

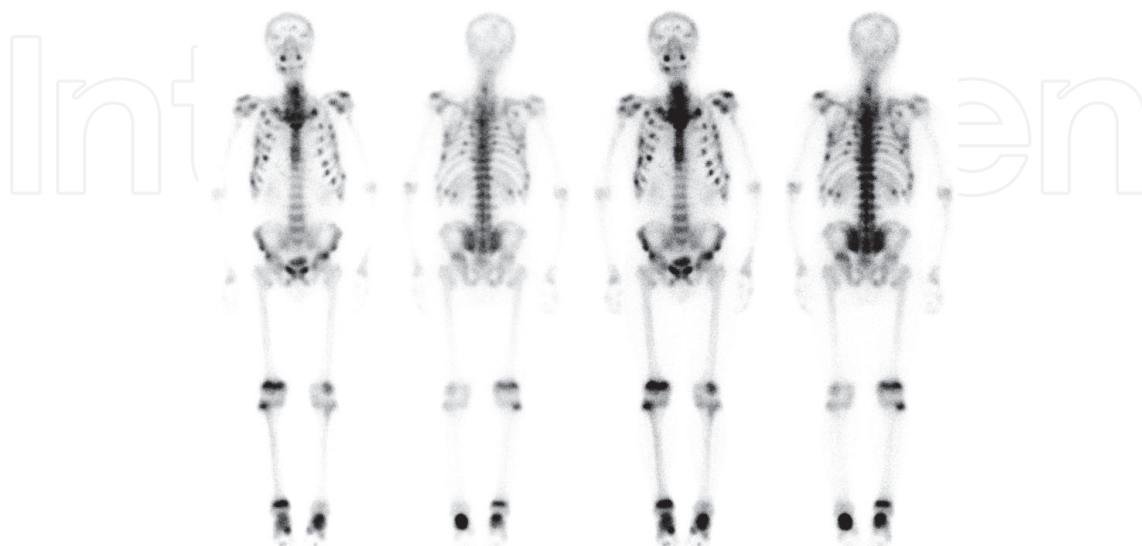


Fig. 16. Diagnostic Imaging feature of Rickets

Bone scintigraphy scan shows metabolic bone disease. Note there are ribbon-like zones multiple foci increased uptake in rib cage caused by pseudofractures on bone scans mimicking metastatic bone disease. This characteristic pseudofractures is one of specific abnormality of Rickets.

The presence of Looser's zones, also called Pseudofractures or Milkman's fractures, there are ribbon-like zones increased uptake in rib cage, pelvis, right distal femora & tibia, Bilateral metatarsals and spinal column, Long-standing Osteomalacia result in characteristic Biconcave collapsed vertebrae.

We recommended further examination: 1.25-dihydroxyvitamin D<sub>3</sub> [1, 25 - (OH)<sub>2</sub>D<sub>3</sub>] 26.75pg/ml (26 -65pg/ml), Parathyroid hormone PTH ↑ 84.6 pg / ml (8.3 -68.0), 24-hour urine calcium 0.36mmol, urinary phosphorus 38.13mmol.

Diagnosis: The patient was diagnosed as hypophosphatemic rickets based on the fact of middle-aged male patients with chronic process. The bone pain and muscle weakness was the main manifestation, which progressively increased and lead to movement disorder. Laboratory tests: normal calcium, hypophosphatemia and elevated ALP. Bone scan with pseudo fractures are the characteristic of bone scan imaging finding prompted rickets. The diagnosis of hypophosphatemic rickets was established. Increased PTH caused by hyperparathyroidism was secondary to rickets.

After three years of out-patient and hospital treatment, this patient has been able to work properly.

The patient's <sup>99m</sup>Tc-MDP bone scan image shows the pseudofeatures of metabolic bone disease: rib pseudofracture site showed local radioactivity uptake; ribbon-like zones increased uptake in spine, pelvis and lower extremities which embodiment Osteomalacia reflect the pathological changes of pseudofracture in rickets.

Rickets refers that bone matrix of adults whose epiphyseal growth plate has been closed mineralized impediently. It is a metabolic bone disease that newly formed bone matrix is not mineralized in the normal manner. There are many causes responsible for decreased extracellular calcium phosphate product, and resulted in bone mineral deposition obstacles. The clinical manifestations of rickets are mainly bone pain and muscle weakness, fractures and deformities. Metabolic bone disease, pseudo fractures are the characteristic of bone scan imaging finding.

Rickets belongs to endocrine and metabolic diseases. Now there are many related diseases, including seven sets of issues: Associated with vitamin D endocrine system diseases, phosphate balance abnormalities, metabolic acidosis, abnormal calcium balance, bone matrix abnormalities, lack of primary mineralization, some factors leading to the inhibition of mineralization. Although the clinical presentation is similar, but the pathogenic mechanisms are different, relating biochemical laboratory examination and treatment are also different. Therefore, in the diagnosis of rickets, we need the systematic, in-depth inspection and analysis to clarify the etiology. Diagnosis and treatment guide of rickets refers to Cecil Medicine.

### 5.8 Paget's disease (Osteitis deformans)

A 54 years old male patient, complained of "left knee pain, glided into varus deformity leg 4 years, left muscle atrophy, walking inconvenience", were diagnosed as Paget's Osteitis by pathology.

Whole body bone scan showed characteristic bone expansion changes: left tibia was bending deformity; T4 vertebral body, left pelvis and tibia in the active stage of osteolysis which osteogenesis showed increased uptake. The radioactivity distribution of the left humerus was mild and uniform in sclerotic phase.

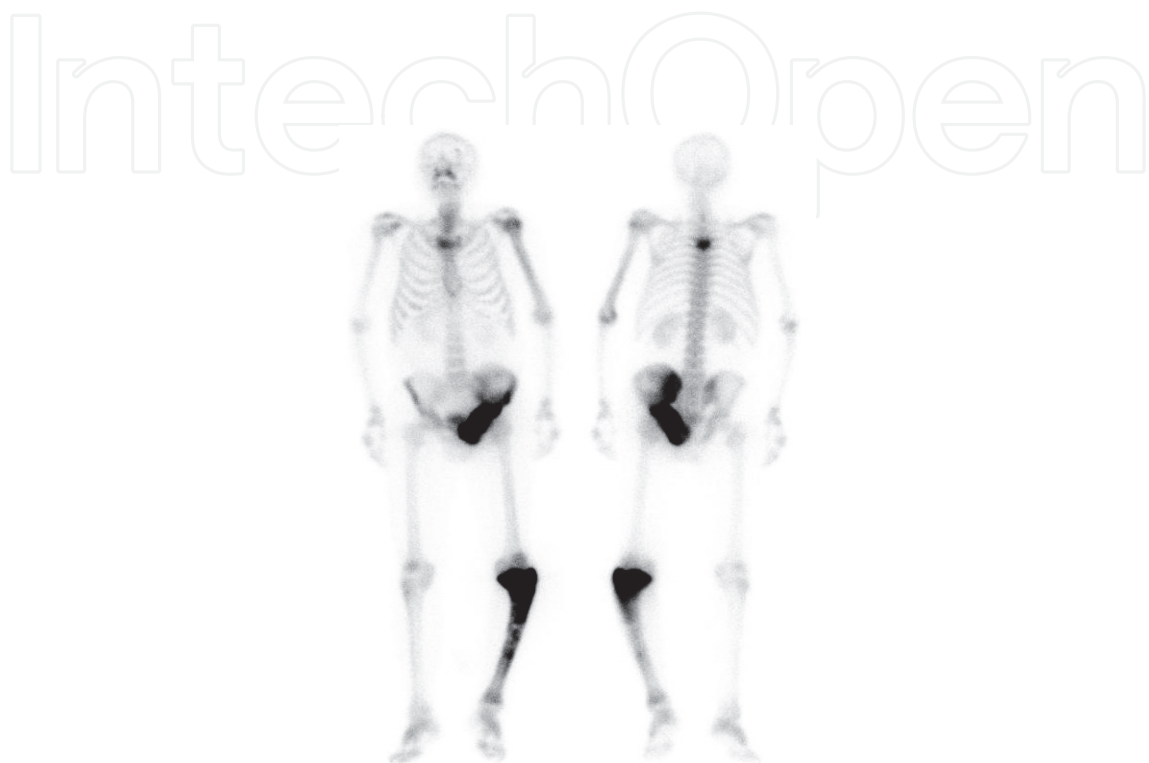


Fig. 17. Diagnostic Imaging of Paget's disease

Bone scintigraphy scan shows increased uptake in the left tibia with bending deformation, T4 and left pelvis with enlargement and bending deformations of the bones affected with lytic the active phase. The Left humerus shows no abnormal uptake of the radiopharmaceuticals with time on the sclerotic phase indicating a relatively inactive lesion.

## **6. Ensure patient safety preventing traumatic complication Acute Pulmonary Embolism (APE)**

Beijing Ji Shui Tan Hospital is a large modern comprehensive hospital which focuses on Orthopedic and traumatology. The surgical volume reached 35000 in 2009. Clinical research in medical imaging make a positive contribution for the protection of medical quality and patient safety, during the process of exploring critical and difficult orthopedic patients and optimize the efficacy of the diagnosis.

The treatment of post-traumatic critically ill patients with acute pulmonary embolism (APE) In Nov. 10, 2000, a 56-year-old man fell from 3 meters high and got multiple traumas (Right hip fracture, fracture of the right pubis ischium branch, open comminuted fracture of the right olecranon). On Nov. 20, when the patient received second operation of open reduction and plate fixation for the right fracture acetabular under general anesthesia, he had chest tightness, shortness of breath,  $\text{PaO}_2$  critical situation of declining. Orthopedic surgery was stopped and the rescue was implement in the ICU ward immediately. ECG shows sinus tachycardia and  $\text{S}_1\text{Q}_3\text{T}_3$  &  $\text{V}_1\text{rsr}$  'wave, which was believed to be acute pulmonary embolism. Lung perfusion ECT was done for the patient immediately in nuclear medicine department.

$^{99\text{m}}\text{Tc}$ -MAA Lung perfusion Imaging showed lung with morphologic abnormalities. Right lung was lobe and segmental perfusion defects, and left lung shows segmental perfusion defects (figure 18). With normal X-ray before surgery (Nov. 18), V / Q diagnosis was done-acute pulmonary embolism. In the ICU ward the patient received anticoagulation and thrombolytic therapy. 2 weeks later (Dec. 4), pulmonary perfusion imaging (Figure 19) was reviewed, the original lobe and segmental perfusion defects had been seen the distribution of perfusion and lung morphology was normal after effectively treatment. X-ray and ECG were normal too. The patient was pulled through by accurate diagnoses and effective treatment.

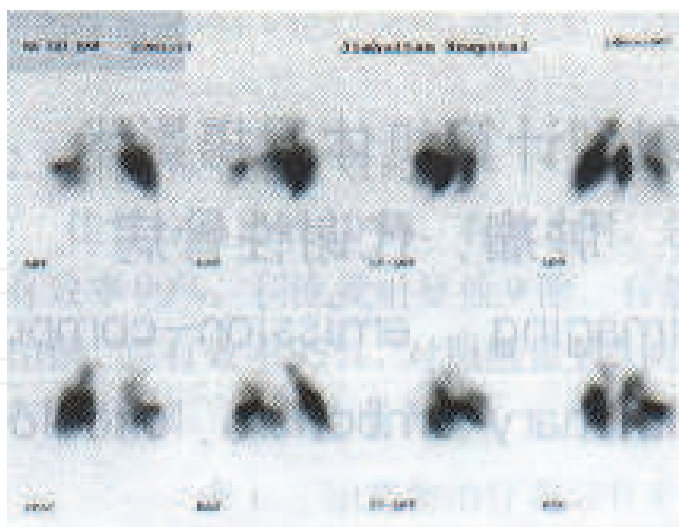

Fig. 18. Lung perfusion imaging of post-traumatic acute pulmonary embolism



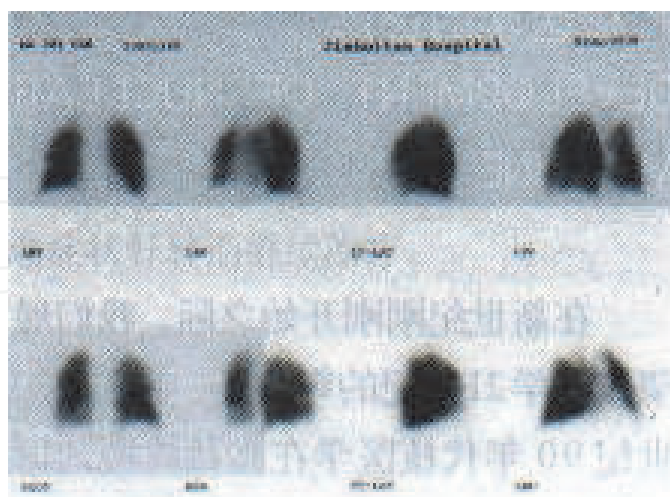


Fig. 19. 2 weeks after treatment, normal lung perfusion imaging

Timely diagnosis and successful treatment of the patient with large area of APE after injury and is described in paper <Advancement in the Application of Nuclear Medicine> was published in Apr.2001 V7N4:59-61 Journal of "China Contemporary Medicine" reported. This paper inspired Beijing Ji Shui Tan Hospital on the understanding and study of acute pulmonary embolism<sup>[16]</sup>. Doctors can see directly from the image: lower limb Thrombosis bring about post-traumatic pulmonary embolism is an important research topic. Early diagnosis and treatment for APE patients can prevent recurrent thromboembolism. It can improve the cure rate, reduce mortality and ensure medical safety of patients before and after surgery.

The development of molecular imaging in China to follow simple, efficient, accurate principles, accuracy is the key <sup>[4]</sup>. The first time in the Hospital for patients with accurate diagnosis and effective treatment, cost savings, improved quality of life, to enjoy the development of medicine and science and technology progress in health benefits for the people.

## 7. Acknowledgements

The author would like thank my Teachers JST Hospital Orthopedic Prof. Shu-huan Wang, Prof. Guo-wei Rong, Beijing Hospital Nuclear Medicine Prof. Wan-ying Qu and Peking Union Medical College Hospital Prof. Qian Zhou for their previous contribution and inspire.

The author would like thank all helped me to make this chapter sincerely a reality: JST Hospital lead orthopedist Wei Tian, oncologist You bo Cai, Qing-zhang, and Pathologist Hong-hong Liu, surgeon Fu rong Xia, for your expertise and work in coordination with.

Thanks all the Technologists of Dept. Nuclear Medicine JST and my Students Dr. Jin Feng, Dr. Lian-na Zhang and Dr. Fang Yang for your time and scrupulous work.

The author would like thank my patients with gratitude a moment of thanks for us.


## 8. References

- [1] Jing-jing Peng, Wei Tian \*(corresponding author) Application of bone scintigraphy in the fracture diagnosis. Guide of China Medicine 2010; 8(5): 115-118.
- [2] Jing-jing Peng, Hong-hong Liu \*(corresponding author), Xia Fu-rong, Cai You-Bo <sup>99m</sup>Tc-MDP Bone Imaging Diagnoses of parathyroid tumors. Chin J Nucl Med, 2003;23(6):263-265
- [3] Jing-jing Peng Advancement in application of *nuclear medicine* .China Contemporary Medicine 2001; 7(4):59-61
- [4] Jing-jing Peng Advancement in clinical application of *orthopedic nuclear medicine* (lectures)Chin J of Bone Tumor and Bone Disease 2009; 8(6): 356-359
- [5] Jiang-lin Chen, Zhao-chang Lin, Shu-ping Tang. Case report: Qualitative and location diagnosis with nuclear medicine of primary hyperparathyroidism. Anthology of Medicine Apr.2006; 25 2:361-362 (PEER REVIEWS AND EVALUATIONS)
- [6] Book Orthopedic Nuclear Medicine, Berlin: springer, 2004 ISBN: 3-540-00614-1 Book Editor: Abdelhamid. H. Elgazzar. (translation <Orthopedic Nuclear Medicine> into Chinese Publication ISBN-978-7-117-12367-9/R·12368 Book Editor: Jing-jing Peng, Wei Tian \*)
- [7] Book *Diagnostic Imaging Orthopedic Nuclear Medicine* ISBN-978-7-117-13047-9/R·13048 Book Editor: Jing-jing Peng Chapter 1 Fundamental Researches: New concept of orthopedic molecular imaging
- [8] Book *Clinical Orthopedics* ISBN-7-5323-7404-1 Book Editor: Shu-huan Wang: Jing-jing Peng Chapter: Radionuclide Imaging
- [9] Book *Chinese Medical Imaging* ISBN-978-7-117-12740-0/R·12741 Book Editor: Qian Zhou, Wanying Qu Jing-jing Peng Chapter Bone Scintigraphy: Primary bone tumors section 4217-4221
- [10] Book *Practical Orthopedics of Jishuitan* ISBN-978-7-117-09461-0 Book Editor: Wei Tian Jing-jing Peng Chapter :PET Imaging 69-76
- [11] Jing-jing Peng, Guo-wei Rong \* (corresponding author), Qing Zhang, You-bo Cai et al Application of Radionuclide Imaging in Osteosarcoma. Chin J Nucl Med, 2000;20(2):65-67
- [12] Jin Feng, Jing-jing Peng \* (corresponding author), Hong-hong Liu Yang Fang, Xiao-hui Niu Response of osteosarcoma to chemotherapy evaluated by <sup>18</sup>F-FDG Imaging Chin J of Clinic med imaging 2010,21(9):638-640
- [13] Guo-wei Feng, Zhong-yi Yang, Liang Guan, Cheng-mo Zhu Case report: Lung Metastases Diagnosis with <sup>99m</sup>Tc-MDP Bone Scan Tracing of Osteosarcoma. (PEER REVIEWS AND EVALUATIONS) Chinese Journal of Nuclear Medicine 2007;(27)6:372
- [14] Jing-jing Peng, Xu Fu. Radionuclide Image manifestation characteristics in osteoarthritis of knee Chin J Nucl Med, 1988;8(3):142-144 Chin J of Med Imaging Technology 2008,24(1):127-130
- [15] Yan-xia Bai, Jing-jing Peng \*(corresponding author), Fang Yang, Min-qiu Lu. Detecting bone lesions of patient multiple myeloma on scintigraphy. Chin J Med Imaging Technol. 2008;24 (7):1106-1109

- [16] Zhang Yun-jian , Zhao Ning , Xia Guo-guang, Li Tian-shui, Wang Yan-xia. Prognostic factors for patients with pulmonary thromboembolism after orthopedic surgery  
Journal of Peking University (Health Sciences) 2010,42(6):798-710

IntechOpen

IntechOpen



### **Soft Tissue Tumors**

Edited by Prof. Fethi Derbel

ISBN 978-953-307-862-5

Hard cover, 270 pages

**Publisher** InTech

**Published online** 16, November, 2011

**Published in print edition** November, 2011

Soft tissue tumors include a heterogeneous group of diagnostic entities, most of them benign in nature and behavior. Malignant entities, soft tissue sarcomas, are rare tumors that account for 1% of all malignancies. These are predominantly tumors of adults, but 15% arise in children and adolescents. The wide biological diversity of soft tissue tumors, combined with their high incidence and potential morbidity and mortality represent challenges to contemporary researches, both at the level of basic and clinical science. Determining whether a soft tissue mass is benign or malignant is vital for appropriate management. This book is the result of collaboration between several authors, experts in their fields; they succeeded in translating the complexity of soft tissue tumors and the diversity in the diagnosis and management of these tumors.

### **How to reference**

In order to correctly reference this scholarly work, feel free to copy and paste the following:

Jing jing Peng (2011). Medical Theory on Orthopedics Combining Molecular Imaging with Clinical Practice, Soft Tissue Tumors, Prof. Fethi Derbel (Ed.), ISBN: 978-953-307-862-5, InTech, Available from: <http://www.intechopen.com/books/soft-tissue-tumors/medical-theory-on-orthopedics-combining-molecular-imaging-with-clinical-practice>

**INTECH**  
open science | open minds

### **InTech Europe**

University Campus STeP Ri  
Slavka Krautzeka 83/A  
51000 Rijeka, Croatia  
Phone: +385 (51) 770 447  
Fax: +385 (51) 686 166  
[www.intechopen.com](http://www.intechopen.com)

### **InTech China**

Unit 405, Office Block, Hotel Equatorial Shanghai  
No.65, Yan An Road (West), Shanghai, 200040, China  
中国上海市延安西路65号上海国际贵都大饭店办公楼405单元  
Phone: +86-21-62489820  
Fax: +86-21-62489821

© 2011 The Author(s). Licensee IntechOpen. This is an open access article distributed under the terms of the [Creative Commons Attribution 3.0 License](https://creativecommons.org/licenses/by/3.0/), which permits unrestricted use, distribution, and reproduction in any medium, provided the original work is properly cited.

IntechOpen

IntechOpen