

# We are IntechOpen, the world's leading publisher of Open Access books Built by scientists, for scientists

6,900

Open access books available

186,000

International authors and editors

200M

Downloads

Our authors are among the

154

Countries delivered to

TOP 1%

most cited scientists

12.2%

Contributors from top 500 universities



WEB OF SCIENCE™

Selection of our books indexed in the Book Citation Index  
in Web of Science™ Core Collection (BKCI)

Interested in publishing with us?  
Contact [book.department@intechopen.com](mailto:book.department@intechopen.com)

Numbers displayed above are based on latest data collected.  
For more information visit [www.intechopen.com](http://www.intechopen.com)



# Laparoscopic Appendectomy

Konstantinos M. Konstantinidis and Kornilia A. Anastasakou  
*Department of Surgery, Athens Medical Center  
 Greece*

## 1. Introduction

Suspected acute appendicitis is the most frequent cause of emergency operations in visceral surgery worldwide. Acute appendicitis is the reason for most urgent admissions and unscheduled operations in general surgery. In the western world approximately 8% of the population are appendectomised (Addis et al., 1990). The treatment for acute appendicitis has been conventional appendectomy for more than a century. This procedure proved to be safe and effective. However, a problem that remained is the high percentage -up to 47% in women of child-bearing age- of negative appendectomies (Borgstein et. al, 1997). Laparoscopic appendectomy counts almost 30 years of presence, and its introduction has met with more hurdles than that of laparoscopic cholecystectomy. Especially during the last two decades numerous studies tried to define the role of laparoscopic appendectomy in the treatment of suspected acute appendicitis. In this chapter we aim to present our experience with the laparoscopic approach for suspected appendicitis during the last almost twenty years and discuss the diagnostic and therapeutic effects of laparoscopy in suspected appendicitis. We will present our diagnostic approach, our surgical technique, and our results, and will discuss the literature. The role of laparoscopy in fertile females will be analysed. Also the place of laparoscopy in special groups such as the elderly, the employed patients, the obese patients, the pregnant women, and the children will be discussed. Finally we will refer briefly to newer techniques including the single port laparoscopic appendectomy, the needlescopic procedure, and the incidental robotic appendectomy.

## 1.1 Background

### 1.1.1 Literature

Since the introduction of endoscopic appendectomy by Kurt Semm in 1983 (Semm, 1983) the surgical community tried to determine its advantages and disadvantages compared to the open procedure. Especially during the last twenty years there have been over 60 randomized controlled trials comparing laparoscopic and open appendectomy in adults (Vettoretto et al., 2010) as well as many meta-analyses of randomized controlled trials (Bennett et al., 2007; Chung et al, 1999; Fingerhut et al., 1999; Garbutt et al., 1999; Golub et al., 1998; Liu et al., 2010; Sauerland et al., 1998, 2002, 2004, 2010). The number of publications on laparoscopic appendectomy is still increasing, while publications on laparoscopic cholecystectomy decline. The latter shows that the laparoscopic approach in suspected acute appendicitis has not yet been fully accepted as the gold standard. There are still open issues regarding the laparoscopic approach. These have to do with the indications, the results, the

costs, the standardisation of the surgical technique, the severity of leaving back a macroscopically 'innocent' appendix and the learning curve. Last but not least the debate about the place of laparoscopy in complicated appendicitis, the incidence of intraabdominal abscesses after laparoscopic appendectomy and its relationship to the severity of the disease, the surgical technique, and the surgical expertise is still vivid.

In the last years it has become apparent that the laparoscopic approach does not have the same value for all subpopulations. The investigators tried to determine the importance of the laparoscopic method in several patient groups. So, one can maintain that recent studies tend to clarify the issues regarding the worth of laparoscopy in the fertile female group, the elderly, the obese and the employed patients. The debate is still ongoing about laparoscopy in men, in complicated appendicitis, laparoscopy in pregnancy and in the paediatric population.

### **1.1.2 Own experience**

The first laparoscopic appendectomy in our department (surgical department specialized in laparoscopy in a big private hospital in Athens) was performed in 1992. Since then we have performed over 1800 laparoscopic appendectomies. We did not analyse all these cases, but we performed a retrospective analysis in more than a thousand patients. Patients with suspected appendicitis, who were treated in the Department of General, Laparoscopic, and Robotic Surgery at the Athens Medical Center between April 1993 and March 2003 were considered for our retrospective study on laparoscopic appendectomy published in 2008 (Konstantinidis et al, 2008). The study presented the results in 1026 patients and was not comparative. Only laparoscopic patients were included as laparoscopy has been the treatment of choice since the department was founded. Patients operated on during the learning curve (100 pts.) and the few patients approached from the start by open technique (15 pts.) were not included in the study. The inclusion criteria for our study on laparoscopic appendectomy were suspected acute appendicitis (after clinical examination, laboratory tests, and imaging tests) or chronic recurrent symptoms that could be attributed to appendicitis, age 15 years or more and laparoscopy as first approach. All patients in whom we performed a laparoscopic appendectomy or an appendectomy after conversion to an open procedure were included in our analysis (908 pts). Also, diagnostic accuracy of laparoscopy was analysed separately in the subgroup of fertile women (558 pts), and was compared to diagnostic accuracy in the rest of the patients (468 pts).

After standardisation of our technique the latter did not actually change. New developments were the single incision technique and the introduction of the DaVinci robotic (TM- Intuitive Surgical Inc.) system in 2006. In this chapter we will refer to the results we had between 1993 and 2003, as we measured and published them. With this exception we will comment only on major complications and new developments.

## **2. Diagnostic approach, patient management and surgical technique**

### **2.1 Diagnostic approach**

We perform routine preoperative control in all patients. Women in whom differential diagnosis includes gynaecological disorders are in many cases examined by the gynaecologist and a transabdominal or transvaginal ultrasound or a CT scan is being performed whenever indicated and possible. There are also some male patients, in whom we might perform ultrasound or CT scan.

From the diagnostic point of view it has been suggested that active observation leads to a consistently lower rate of negative laparotomies and laparoscopies (Jones, 2001). Several scoring systems have also been proposed as diagnostic tools, but none of them has achieved general acceptance. In the literature very low statistical association is reported between a temperature  $>37^{\circ}\text{C}$  and the presence of appendicitis (Cardal et al., 2004). An elevated WBC count  $> 10.000$  cells/mm, while statistically associated with the presence of appendicitis, is reported to have very poor sensitivity and specificity and almost no clinical utility (Cardall et al., 2004). On the other hand the combination of either leucocyte count and CRP value (Gronroos JM & Gronroos P, 1999) or leucocyte count, CRP value, and neutrophil percentage (Yang et al., 2005) is considered very important in the exclusion of appendicitis. Finally helical CT and graded compression US are reported to be useful instruments in the diagnosis of acute appendicitis as they may lower the false negative rate (Balthazar et al, 1991, 1998; Birnbaum et al., 2000; Jones et al., 2001, Pacharn et al., 2010). CT is in most studies found to be superior to US as it misses fewer cases; nonetheless, they are both reliable in suspected acute appendicitis (van Randen et al., 2011). A diagnostic pathway using routine US, limited CT, and clinical re-evaluation is proposed by Toorenvliet et al. (Toorenvliet et al., 2010). US should be the first choice especially for pregnant patients (Butala et al, 2010). Finally a multicenter study is ongoing to define the role of MRI instead of CT in the diagnostic approach of acute appendicitis (Leeuwenburgh et al., 2010).

## 2.2 Patient management

Our patients are being given prophylactic antibiotics (1g cefotaxime and 500mg metronidazole intravenously) and in complicated cases antibiotics are continued. Our policy is to leave back a normal looking appendix, if another pathology is found at surgery, but to remove a normal looking appendix, if there are no other findings. We normally release patients in the first postoperative day. In complicated cases the hospital stay is prolonged. Patients are examined on the tenth postoperative day as well as one month postoperatively.

## 2.3 Surgical team and surgical technique

The surgical team involved in diagnosis and treatment consisted of specialized surgeons trained in laparoscopy and working together over several years. The team grew with time. The operating surgeon in most cases was the director of the department (K.M.K), performing about several hundred laparoscopic procedures every year, many of them being advanced procedures. The policy of the department is to approach patients laparoscopically whenever possible. This is facilitated by the fact that almost all of the abdominal operations in this department are performed by laparoscopy, over 50% of them being advanced procedures. There are also scrub nurses and technicians with experience in laparoscopy during the day as well as after hours.

Surgical technique evolved with time, experience and appearance of new technical devices. Our technique went through several stages and has been described before (Konstantinidis et al., 2008). The technique, which was performed in the last over 1600 patients will be described here: Surgery is performed under general anesthesia with the patient lying in supine position on a multi-positional operating table. There are two monitors. The surgeon stands on the patient's left side and the assistant on the right. The abdomen is entered at the umbilicus using the open Hasson technique routinely. If there are dense adhesions another approach can be used. A 10mm reusable port is placed at the umbilicus and the 30 degree

laparoscope is inserted. The abdominal cavity can now be visualized. Two further 5mm reusable trocars are inserted in the suprapubic area and the left lower quadrant under visual control. The surgeon operates with two hands and the assistant holds the laparoscope. The small bowel is retracted away from the right lower quadrant with the patient lying in the Trendelenburg position and right side up. Atraumatic forceps are used. The dissection continues, sometimes using the Plasma Kinetics™ (Gyrus Medical, Cardiff, UK) bipolar electrocautery, until the base of the cecum is visualized, and the appendix can be elevated. The mesoappendix is managed in a retrograde fashion by lifting the apex of the appendix and using the cutting bipolar electrocautery until the cecum is reached. Three ligating Endoloops PDS II™ (Ethicon, Sommerville, NJ, USA) are placed, the first one at the appendicular base, the second one next to the first loop, and the third one in about 1cm distance. The appendix is then transected using scissors. Before the transaction is complete the remaining appendicular mucosa is first suctioned and then burned with caution using the bipolar electrocautery. The laparoscope is changed from the 10 to the 5mm laparoscope

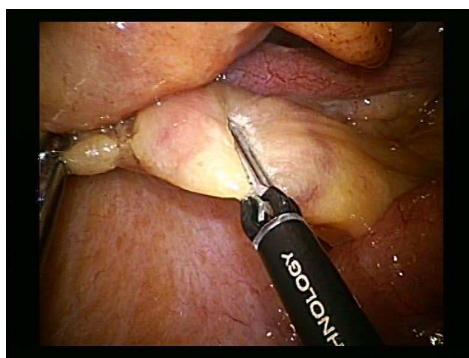


Fig. 1. Cauterisation of the mesoappendix

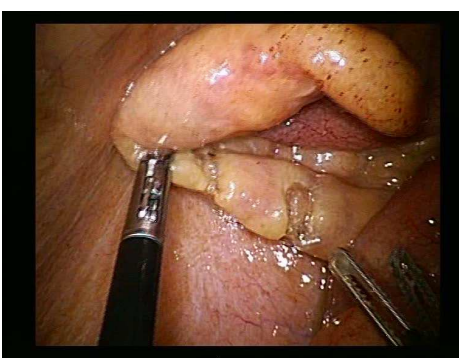

Fig. 2. Cauterisation and cutting of the mesoappendix

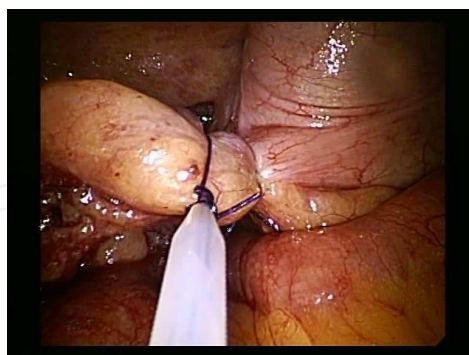

Fig. 3. Placement of the Endoloops PDS II™

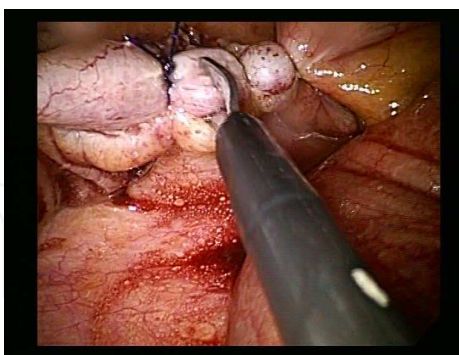


Fig. 4. Cutting of the appendix

and placed through the LLQ port. If uncomplicated, the appendix is grasped and pulled through a reducer at the umbilical port. If ruptured or gangraenous the appendix is put in a retrieval bag and the bag grasped with a traumatic grasper and pulled through the umbilical port. The site of appendectomy, right paracolic gutter, and pelvis are irrigated with about 3 to 5 liters of normal saline irrigation solution with pressure. Fluid from the suprahepatic area and the pouch of Douglas is suctioned. In cases of intraabdominal abscess a drain connected to a closed suction system is placed in the abscess cavity and brought out through the subrapubic



trocar. The fascial incision at the umbilicus is closed with 2.0 Vicryl™ sutures. The skin is closed with 4.0 or 5.0 absorbable subcuticular sutures, unless there is an intraabdominal contamination, in which case the skin is closed with 4.0 interrupted nylon sutures.

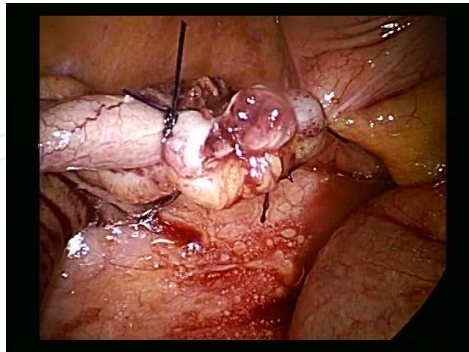


Fig. 5. Not the whole lumen of the appendix is being cut

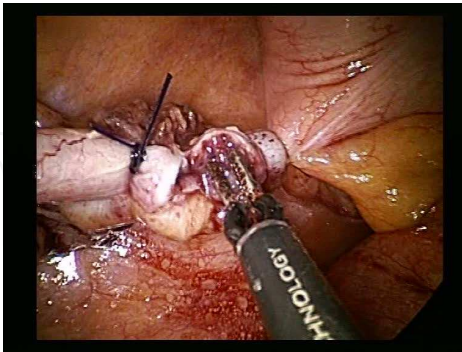


Fig. 6. Cauterisation of the appendiceal mucosa

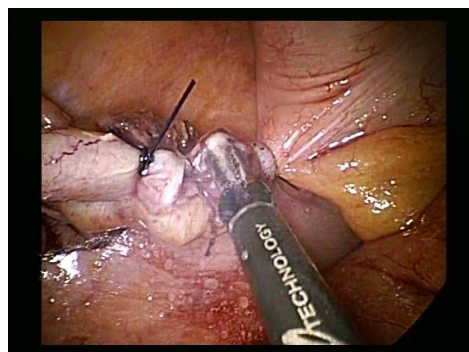


Fig. 7. Cauterisation of the appendiceal mucosa

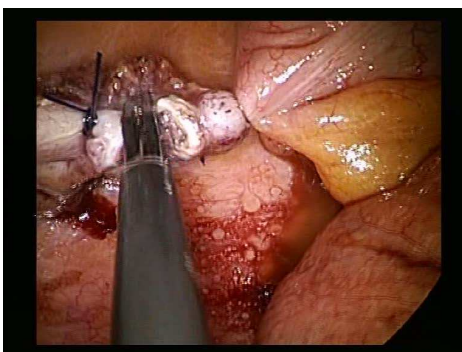


Fig. 8. Cutting of the remaining appendix with the bipolar.

Many surgeons prefer routine stapling of the appendiceal stump. The stapling is reported to be quicker, easier, and lead to less postoperative infections (Kazemier et al., 2006). On the other hand it means greater costs and the obligatory use of a 12- mm trocar. Other investigators do not report a higher complication rate with the use of endoloops as is stated in a recent review. The only difference between the two methods is considered to be operating time (Sajid et al., 2009). A protocol recruitment is now running to investigate, whether routine stapling of the stump can lead to less intraabdominal abscesses (Sauerland & Kazemier, 2007). Peritoneal lavage is contradictory, as it may lead to spillage of infection according to some investigators (Gupta, 2006) but may prevent infection if performed copiously in all quadrants according to others (Hussain, 2008). We believe that a lavage with 3-5 liters of normal saline, as we described it, using a peristaltic pump is effective and saves time. One could argue that it is more expensive, but our experience in over 1.800 patients has been that it is worth the cost. Routine use of drains is not necessary, and may in some patients lead to cecal fistulae (Petrowsky, 2004).

Finally, standardisation of surgical technique leads to reduction of operative time, conversion rate, morbidity, and to a higher surgeon satisfaction in training centers (Ng et al., 2004; Hsieh et al., 2009).

### 3. Results of laparoscopic appendectomy and discussion

#### 3.1 Parameters examined in the literature

To evaluate the benefits of the laparoscopic approach in suspected appendicitis the scientific community examines several parameters. Important issues in the study of laparoscopic appendectomy are: **intraoperative findings, conversion rate to open surgery, histological findings and negative appendectomy rate, duration of operation, intra- and postoperative complications (early and late), postoperative pain, time to bowel mobilization, time until intake of solid food, duration of hospital stay, time until return to normal activities, full activities and sports, reoperations, cosmesis, and costs.** All of these parameters are dealt with in the literature and most of them were measured in our published study (Konstantinidis et al., 2008). In our patients we did not investigate the costs or the cosmetic results.

#### 3.2 Diagnostic and therapeutic outcomes of laparoscopic appendectomy

**Conversion rate** ranges in meta-analyses between 0% and 23% (Lippert et al, 2002; Sauerland et al., 2004) but there are studies which report conversion rates as high as 39% (Moberg et al., 1998). In everyday praxis conversion rate typically seems to range between 10 and 20%, while in centers of excellence it is lower than 2%. It is apparent that these fluctuations are related with differences in laparoscopic experience. In most studies the operator is a surgical trainee for about 80 to 95% of open appendectomies and for about 50 to 75% of laparoscopic procedures. In our study we had a conversion rate of 0,55% in the 908 patients, in whom an appendectomy was performed. The low conversion rate in our study can be explained by the fact that we are not a teaching hospital but a private center. The operating surgeon in most of our patients has been the director of the department (K.M.K). But also the other surgeons belonging to the team are specialised and very experienced with laparoscopy. A learning curve was apparent for the first 100 appendectomies, where we had a conversion rate of 9%, but these patients were not included in the trial. Conversion rate is reported to be increased in complicated appendicitis (Wullstein et al., 2001). The most common reason for conversion is reported to be dense adhesions due to inflammation, followed by localized perforation and diffuse peritonitis (Agresta et al., 2003; Liu et al., 2002). The presence of significant fat stranding associated with fluid accumulation, inflammatory mass or localized abscess in CT scan is also reported to significantly increase the possibility of conversion (Liu et al., 2002). In our patients the reasons for conversion were dense adhesions in two patients and excessive inflammation in 3 patients.

There were also some patients, who had to be converted because of other pathologies. In our experience these were pelvic hemoperitoneum, inflammatory pelvic disease, ovarian cyst torsion, ovarian mass, ruptured diverticulitis (of the sigmoid and of the cecum) and cecal volvulus. Finally, we performed laparoscopic assisted procedures in a number of patients with Meckelitis. **The necessity to convert patients due to another pathology emphasises the role of laparoscopy as a diagnostic tool.**

There is a strong heterogeneity in **operating time** reported in the literature. Mean operating times in meta-analyses of randomised trials range between 23,5 and 102,2 min (Sauerland et al., 2004). Apart from differences in laparoscopic experience, this can be attributed to the different definitions of operating time. Nevertheless, all meta-analyses agree that the duration of surgery is longer in laparoscopic appendectomy (Benett, 2007; Chung et al., 1999; Fingerhut et al, 1999; Garbutt et al., 1999; Golub et al, 1998; Sauerland et al., 2010;

Temple et al, 1999). It is nonetheless remarkable that - as laparoscopy evolves - the results of meta-analyses performed by the same investigators show through the years a decreasing difference in operating time between the two approaches (Sauerland et al., 1998, 2002, 2004, 2010). Sauerland et al. report in their most recent meta-analysis that laparoscopic appendectomy is on the average 10 minutes longer than the open one (Sauerland et al., 2010). The median operating time in our study was 26 minutes, which compares favourably with most other studies (The time from cutting the skin at the umbilicus until putting the last skin suture was defined as operating time). We believe that the short operating time is due to the surgeon's expertise, and the training of the surgical team. We also believe that it has to do with the standardisation of the surgical technique.

It has been suggested, and seems logical, that surgical expertise has a great impact in conversion rate and operating time. The latter one as well as the lack of precision in manoeuvres by novices could affect complication rate and patients' outcome.

In our study we had an overall **complication rate** of 5,7%, consisting mostly of minor complications. At the beginning of our series we had to reoperate on a 28 year old female patient 3 days after surgery because of persisting abdominal pain. We performed a diagnostic laparoscopy. There were no findings. We attributed the pain to not properly washed instruments, with remainings of Cidex™ (Johnson & Johnson, Cincinnati, Ohio, USA) solution on them. We had no other reoperations or major complications except for one intraabdominal abscess outside our published series.

The average **wound infection rate** for laparoscopic appendectomy is reported to be 2,8% in the meta-analysis by Golub et al. (Golub, 1998) and 2,5% in a big prospective multi-center-study (Lippert et al., 2002). Wound infection rate is reduced by a half after laparoscopic appendectomy in the most recent meta-analysis (Sauerland et al., 2010) based on the study of more than 6000 cases. This is consistent with the findings of a large data base analysis of over 40.000 in the US (Guller, 2004). Wound infection rate in our study was measured separately and was 1,1%.

**Intraabdominal abscesses** are reported in the older meta-analyses to be equally frequent as in the open procedure (Chung et al., 1999; Garbutt et al., 1999; Temple et al.) or even increased, but without reaching statistical significance (Golub, 1998). In the most recent review **intra-abdominal abscesses** are reported to be nearly threefold after laparoscopic appendectomy (Sauerland et al., 2010), and moderate heterogeneity was detectable. There were no notable differences in the results of trials using staplers versus loop. The problem with studies reporting higher incidence of intraabdominal abscesses with laparoscopic appendectomy is that they lack standardization of the surgical technique, and also that they do not uniformly describe the different grades of disease. A recent prospective randomised study on 220 patients reports less intraabdominal abscesses with the laparoscopic approach (Wei et al., 2010). Also, a very recent review on 2.264 patients (Asarias et al., 2011) did not find a significant difference in intraabdominal abscesses between the open and the laparoscopic approach. On the other hand a multivariate analysis from the American College of Surgeons on almost 40.000 appendectomies (77% laparoscopic) found that laparoscopy was associated with an increased risk for intraabdominal abscesses in the high risk patients (12,3% vs. 8,9%) but not for the low risk patients (Fleming et al., 2010). We had no intraabdominal abscesses after laparoscopic appendectomy in our study (Konstantinidis et al., 2008). Our only experience with an intraabdominal abscess after laparoscopic appendectomy was in a 59 year old man, in whom we performed one of the first operations for a ruptured appendix in January 1993, and who was not included in our study, as



mentioned before. This patient was readmitted, and reoperated laparoscopically. A large retrocecal abscess was drained without further problems in his postoperative course. We believe that surgical expertise, precise manoeuvres during the operation, technique standardisation, and irrigation with normal saline solution (5 ltrs., under pressure) are very important in order to avoid intraabdominal abscesses.

Most meta-analyses agree that **postoperative pain** is reduced after laparoscopy compared to the open procedure (Chung, 1999, Chung et al., 1999; Garbutt et al., 1999; Golub et al., 1999, Sauerland et al., 2010). Our patients required a median number of 4 minor drugs and 2 narcotics until their discharge.

There is consistent evidence that laparoscopy leads to a shorter **hospital stay** than the open appendectomy (Garbutt, 1999, Liu et al., 2011, Sauerland et al., 2010), although there are great fluctuations. We assume that this has to do with different discharge policies. Also, return to normal activity, which was 7 days in our trial, seems to fluctuate very much between most investigators, but is reported to be quicker with the laparoscopic approach (Chung et al., 1999; Garbutt et al., 1999; Golub et al., 1998; Liu et al., 2010; Sauerland et al., 2010; Temple et al., 1999) as is return to full activity and sport (Sauerland et al., 2010). In our experience **recovery** as expressed through time until flatus (24 hours) and intake of solid food (48 hours), as well as time until discharge (30 hours) was very satisfactory.

There is no other pathology in surgery where as high percentages for **negative laparotomies** are tolerated as in suspected acute appendicitis. In the literature negative laparotomies in suspected acute appendicitis typically range between 20-30%, while the typical range for negative laparoscopies is 10-15% (Tate, 1996). Especially in the subgroup of fertile females authors report a negative laparotomy rate between 22-40% and a negative laparoscopy rate between 4-17% and (Sauerland et al., 2004). We assume that in experienced hands a negative laparoscopy is truly negative - at least concerning the macroscopic findings- whereas a negative laparotomy with a Mc Burney incision fails to diagnose the pathology in about half of the cases as can be confirmed by the numbers. The long-term clinical course of these patients with the missed pathology cannot always be concluded from the published literature (Vettoretto&Agresta, 2010).

The **superior visualization of the abdominal cavity** is undoubtedly the great advantage of laparoscopy and leads to a much higher diagnostic yield in comparison to the open procedure. In the most recent meta-analysis laparoscopy reduced the rate of negative appendectomies and the rate of un-established diagnoses, especially in fertile women (Sauerland et al., 2010). **Gynecological problems** are found more frequently in laparoscopy for suspected acute appendicitis than in laparotomy (Larsson, 2001). Hence, there is consensus about laparoscopy being an invaluable tool in the management algorithm of women in childbearing age (Agresta, 2003; Borgstein, 1997; Cox, 1995; Larsson, 2001; Sauerland et al., 2010; van Dalen, 2003). A recent Cochrane Review about the role of laparoscopy for the management of lower abdominal pain in women of childbearing age found in the laparoscopic group higher rates of specific diagnoses been made, lower rates of negative appendectomies and shorter hospital stays. Also, there was no evidence of an increase of adverse events with either of the two approaches (Gaitan et al., 2010). In our series laparoscopy alone could establish diagnosis in 89% of all patients, in 85,4% of fertile women and in 93,1% in all other patients except fertile women. We had to face other surgical problems than appendicitis in 11,5% of all patients. In the subgroup of fertile women we were confronted with other diagnoses in 20,4% of all patients. Most of these conditions were gynaecologic problems (19,2%), despite the fact that some of these patients were examined

by the gynaecologist –which is consistent with the literature (Borgstein, 1997)- and/or had imaging studies performed. The laparoscopic approach gave us the opportunity to define these problems, as well as to deal with most of them without having to convert to an open procedure. So, even in therapeutic terms, laparoscopy offers the possibility to manage unexpected problems, while a classical Mc Burney incision has many constraints in this direction.

It has been questioned if one should remove a **normal looking appendix**, if there are no other findings at laparoscopy, especially in fertile women. Investigators who chose not to remove normal looking appendices report good results and almost no or few readmissions both in the fertile women group and in all patients (Borgstein et al., 1997; Moberg et al., 1998; Teh et al, 2000; van Dalen et al., 2003). That is why many investigators suggest not to remove a normal looking appendix (van Brock, 2001; Morino, 2006). Their argument is that removing all appendices diminishes the diagnostic value of laparoscopy, as well as being accompanied by morbidity, mortality, and extra hospital costs (Benjamin et al, 2002; Binjen et al, 2003; Sauerland et al., 2003). However, the assertion that mortality of incidental appendectomy exceeds that of appendectomy for appendicitis (Benjamin, 2002) did not find general acceptance (Howie, 2003). Howie reports that the estimated avoidable mortality from missed appendicitis or negative appendectomy in Scotland was virtually identical at 1,13 and 1,07 patients per 10.000 admissions. Another argument against incidental appendectomy is that it may have several adverse effects on fertility. Concerning this, a large Swedish retrospective study on 10.000 women could not confirm negative effects of appendectomy on fertility (Anderson et al, 1999). On the other hand incidental appendectomy may increase morbidity, and diminishes the diagnostic value of laparoscopy. We chose to remove all appendices if there were no other findings. This has to do with the nature of our hospital. We are a private center, and cannot always afford to reexamine patients, or, even worse, re-operate on them. It also has to do with the facilities, the laparoscopic experience of our team and the absence of major complications or mortality up to this point. In our study eighteen patients (2%) proved to have histological findings of appendicitis without having macroscopic ones. We had a negative appendectomy rate of 11,6% in fertile women and 6,4% in the rest of the patients after histological examination. In 0,8% of all excised appendices the histological examination revealed a carcinoid tumor.

Removing a macroscopically innocent appendix surely diminishes the diagnostic advantages of laparoscopy. On the other hand, the question whether or not to remove a macroscopically normal appendix cannot be easily answered. Published data show a discrepancy between the good clinical course of most patients in these series, where a macroscopically innocent appendix was not removed and the histological findings in the series where a normal appearing appendix was removed. It has been shown that a macroscopically normal appendix is not always normal (Chiarugi et al., 2001), though the literature is quite inhomogenous concerning the histological findings. It also has been shown that a histologically normal appendix is not always normal (Wang et al, 1996) . Some of these appendices in patients with acute pain in the right iliac fossa have an abnormal content of neuropeptides. This could explain the pain relief after removal of a histologically normal appendix (Di Sebastiano, 1999; Wang et al, 1996).

It seems that some patients suffer crises of **endoappendicitis**, that subsides with conservative treatment. Endoappendicitis varies from 11to 26% and the reoperation rate for the patients whose appendix was left in situ is reported to be 6%(Navez and Therasse, 2003). So it might be that the great majority of these patients will not have any problems in the

future but for the individual patient the surgeon's decision to leave the appendix behind could mean a readmission, a peritonitis, a second operation, or the persistence of recurrent symptoms. So we think that the decision to remove the appendix has to be individualized and discussed with the patient prior to the operation. The experience of the laparoscopic team is very important in this context. We generally agree with the algorithm proposed by (Navez & Therasse, 2003) in the treatment of suspected acute appendicitis. The authors propose to remove a macroscopically normal appendix if one suspects an appendicitis clinically and there are no other findings. In cases of acute abdominal pain of uncertain origin and negative laparoscopy the authors propose to perform only a diagnostic laparoscopy and to avoid the terms of appendicitis or appendectomy. We also agree with the investigators that the appendix should be removed if chronic recurrent symptoms exist, and there are no other findings. We think there is enough evidence about this in the literature (Chandler et al., 2002; Mussak et al., 2002), especially in young females (Chiccolm Mefire et al., 2011).

The debate on whether **complicated appendicitis** is a contraindication for the laparoscopic approach is still ongoing. Sauerland et al. reported in an earlier review (Sauerland et al., 2004) that laparoscopic approach for complicated appendicitis can probably lead to increased complications, though there is not yet enough evidence to support this. On the other hand many authors do not regard complicated appendicitis to be a contraindication for laparoscopic appendectomy. On the contrary, laparoscopic appendectomy in complicated appendicitis is reported to be safe (Ball et al., 2004; Kapischke et al., 2005; Pedersen et al., 2001; Stolzing et al., 2000; Wullstein et al., 2001) and reduce complication rate (Kapischke et al., 2005; Wullstein et al., 2001). Septic wound complications are reported to be less (Piskun et al., 2001; Stolzing et al., 2000). Intraabdominal abscesses are reported to be equally frequent (Asarias et al., 2011; Khalili et al., 1999; Wullstein et al., 2001) in the open and the laparoscopic approach. Also laparoscopic appendectomy in complicated appendicitis is supposed to lead to a shorter length of stay (Ball et al., 2004; Johnson et al., 1998; Kapischke et al., 2005; Towfigh et al., 2006) and reduced hospital costs (Johnson et al., 1998). The problem with some comparative studies is the existence of selection bias in patients undergoing laparoscopic or open appendectomy and also the fact that statistical analysis is not always done on an intention-to-treat-basis. Nevertheless Wullstein et al. in their study on 299 patients with complicated appendicitis report that laparoscopic appendectomy when compared with open appendectomy leads to a significant reduction of early postoperative complications by itself and in an intention-to-treat view (Wullstein et al., 2001). A recent systematic review with meta-analysis of 12 retrospective case-control studies found less surgical site infections in laparoscopic appendectomy for complicated appendicitis with no significant additional risk for intraabdominal abscesses (Makrides et al., 2010). More prospective, randomized trials focusing on this question are needed in the future. We did not study patients with complicated appendicitis separately in our series. Nevertheless we had to face a ruptured or gangrenous appendix in 14,1% and, in spite of that, had an overall wound infection rate of 1,1% and no intraabdominal abscesses. In our experience complicated appendicitis is not a contraindication for the laparoscopic approach. There is evidence supporting that **cosmesis** is superior with the laparoscopic approach (Pedersen et al., 2001), and is difficult to improve (Ruiz de Angulo et al., 2011). We think that this must be especially true in obese patients and complicated appendicitis, where normally bigger incisions are needed. Also, in case of other findings that need an extension of a Mc Burney incision or a new incision, laparoscopy is surely the best choice from the cosmetic point of view.

**Quality of life** is also reported to be better with the laparoscopic approach, both in the early and late period (Kaplan et al, 2009).

**Cost- effectiveness** is difficult to measure. From the institutional perspective laparoscopic appendectomy is reported to be less cost- effective than the open procedure, even if in the future the costs of the operation and the equipment (single- use vs. reusable; Endo-GIA vs. Roeder loops) may decrease whereas from the societal perspective the laparoscopic approach seems to be more cost- effective (Heikkinen et al., 1998; Macarulla et al., 1997; Sauerland, 2010) if lost productivity is taken into consideration (Moore et al., 2004). In middle- aged patients overall costs are reported to be lower with the laparoscopic procedure (Lagares- Garcia et al., 2003). In our patients we try to reduce costs by applying reusable instruments. We also prefer to use loops for the appendicular base instead of staplers and can report excellent results and no complications.

It has been suggested that there may be fewer **adhesions** after laparoscopic appendectomy compared to the open procedure (De Wilde, 1991; Gutt, 2004). We had no patients with adhesion-related complications such as intestinal obstruction in our study. The incidence of late readmissions (>30 days) after appendectomy is of particular interest. In the literature there is increasing evidence that open appendectomy is related to late readmissions and, in some cases, reoperations for SBO but there is an inhomogeneity in the results of different studies (Anderson, 2001; Riber, 1997; Zbar, 1993). During a mean follow-up of 10 years the authors of a retrospective study on 3,230 patients report 2,94% late readmissions after open appendectomy. Almost half (45%) of readmissions were caused by nonspecific abdominal pain with no signs of small bowel obstruction. SBO was seen in 1,24% of patients and was surgically treated in 0,68%. Incisional hernias were seen in 0,4% of all appendectomies., as did patients with complicated appendicitis or negative appendectomy (Tingstend et al., 2004).

Our follow-up lasted 4 weeks. From the 63 patients operated on for chronic symptoms 5(8%) continued to have abdominal pain one month after appendectomy. There were no readmissions or reoperations for adhesion related complications or incisional hernias. We can also report that no patient of this series was readmitted in our department with a late complication such as small bowel ileus or an incisional hernia. More prospective, randomized trials comparing the incidence of late complications with the laparoscopic and open approach for suspected appendicitis in an intention-to-treat basis are needed. We also think that late complications should be included in future cost-analyses.

Laparoscopic appendectomy is reported to be a safe and suitable procedure for **surgical training** (Botha et al., 1995; Duff&Dixon, 2000; Scott-Conner et al., 1992). In our opinion it is in many cases an ideal operation for a surgical trainee starting his/her training in laparoscopy.

## 4. Special patient categories

### 4.1 Fertile females

Especially in the subgroup of fertile females authors report a negative laparotomy rate between 22-40% and a negative laparoscopy rate between 4-17% and (Sauerland et al., 2004). Females predominated among those readmitted (76%). Fertile females benefit from the laparoscopic approach at a level Ia evidence and there was no inconsistency between studies (Sauerland, 2010; Vettoretto & Agresta, 2010; Gaitan, 2011).



4.2 Obese patients

In the literature it is suggested that overweight patients seem to profit from laparoscopic appendectomy in terms of postoperative pain, postoperative recovery (Enochson et al., 2001), and septic wound complication rate (Stolzing et al., 2000, Corneille et al., 2007). In a more recent comparative study no significant differences in terms of complications were found between the two groups (Clarke et al., 2011). We did not perform a separate analysis on overweight patients.

4.3 Employed patients

Employed patients profit from laparoscopic appendectomy as it is superior to open appendectomy in terms of return to normal activities and full activity (Sauerland et al, 2010).

4.4 Elderly patients

Elderly patients have more overall complications after conventional appendectomy (especially regarding pulmonary function impairment and return to normal activities), and seem to benefit from laparoscopic appendectomy (Agresta et al., 2011; Guller et al, 2004; Kim et al., 2011; Yeh et al. 2011).

Patient Population	Level of Evidence
Women of childbearing age	LOE Ia
Employed Patients	LOE Ia
Elderly Patients	LOE IIb
Obese Patients	LOE III
Men	LOE III

Table 1. Adult patient subpopulations that profit from laparoscopic appendectomy

4.5 Pregnant patients

Acute appendicitis is the most common cause of nonobstetric acute abdomen during pregnancy. Some investigators report that the incidence is identical to that of the nonpregnant population, while others suggest that it is less, with the third trimester being particularly protective (Anderson & Lambe, 2001). Non the less, a perforation of the appendix is reported to occur twice as often in the third trimester (69%) compared with the first two (Weingold, 1983). The role of laparoscopic appendectomy during pregnancy remains controversial. Laparoscopy for suspected appendicitis is considered to have less complications and a higher diagnostic value compared to the open procedure. The ongoing debate is whether the laparoscopic procedure leads to a higher percentage of fetal loss as is reported in a systematic review from the UK (Walsh et al., 2008) or not, as is stated in a review from the United States (Jackson et al., 2008). More recent studies consider the laparoscopic approach to be safe and effective with a low rate of complications for the mother and the fetus (Corneille et al., 2010; Jeing et al., 2011; Kirshtein et al., 2009; Lemieux et al, 2009; Machado et al., 2009; Moreno-Sanz, 2007; Sadot et al.). It has to be stated that long-term consequences of the pneumoperitoneum for the fetus have not yet been studied. Also, one should stress the importance of a very good diagnostic work-up in order to avoid

unnecessary procedures without missing pathologic conditions. Walsh et al. report that the negative appendectomy rate in their series was 27%, which is higher than in the nonpregnant population. Regarding the diagnostic tools it has been reported that the sensitivity of ultrasound is inversely correlated to the gestational age, while CT scan retains a high sensitivity and specificity throughout pregnancy. It seems reasonable to perform an ultrasound first, in order to exclude an obstetric pathology, and to proceed with a CT if necessary (Butala, 2010).

#### **4.6 Pediatric patients**

Pediatric patients seem to benefit from the laparoscopic approach for suspected appendicitis in the same ways adults do, and intraabdominal abscesses are not more frequent than with the open approach. However, more RCTs are needed in order to come to final conclusions. Especially in extremely obese children laparoscopy is considered to be the procedure of choice both in complicated, and not complicated cases. The operative time is reported to be shorter, there are less overall complications, and reduced analgesia requirements (Kutasy et al., 2011).

### **5. Novel techniques and future research implications**

#### **5.1 Novel techniques**

##### **5.1.1 Single port appendectomy**

Single-port-laparoscopy for acute appendicitis is reported to be safe and effective in children (Tam et al., 2010) and adults, and may have advantages in terms of cosmetic results and patient satisfaction (Barbaros et al.; 2010; Lee YS, 2009; Raakow et al.; Tsai & Selzer, 2010). We tried this approach on two patients but could not really see the benefits. On the contrary, we believe that the single port technique is much more appropriate and ergonomic in robotic surgery. More comparative studies between the conventional technique and the single port approach are needed in order to determine its role in laparoscopic appendectomy, especially regarding long term morbidity (i.e. hernias) at the entrance site.

##### **5.1.2 Needlescopic appendectomy**

Needlescopic appendectomy can be safe and effective according to a recent review and is supposed to reduce pain compared to conventional laparoscopy (Sajid et al., 2009; Sauerland et al., 2010). Nevertheless it is associated with a longer operating time and a higher conversion rate. Multicenter, randomized controlled trials are recommended before it can be used routinely.

##### **5.1.3 Robotic appendectomy**

Incidental appendectomy is considered to eventually be necessary in women with ovarian endometrioma and chronic pelvic pain, as the majority of the appendices are found to have histopathologically confirmed pathology although being macroscopically normal (Wie et al., 2008). Incidental robotic appendectomy is reported to be safe and effective in women undergoing gynaecologic surgery, in women with chronic pelvic pain, and women with ovarian malignancy (Akl et al., 2008). In the latter group three out of seven patients were found to have appendicular metastasis. Our experience with the DaVinci (TM, Intuitive Surgical Inc.) Robotic System started in 2006, and is today the everyday routine of the

department in advanced procedures. We performed incidental robotic appendectomy in three patients who underwent gynecologic surgery for endometriosis for chronic pelvic pain with good results. We believe that the robotic procedure has its place in complicated cases of appendicitis with dense peritoneal adhesions.

## 5.2 Implications for future research

In our opinion future research should first of all determine the role of diagnostic investigations (such as laboratory parameters, US, CT and MRI) which could lower the percentage of negative laparoscopies, especially in pregnant women and high risk patients. Also, a cost-benefit analysis of the routine appliance of US and CT in order to avoid negative laparoscopies would be reasonable. Additionally, the importance of leaving back a macroscopically innocent appendix in several patient categories (women of childbearing age, patients with chronic pain, high-risk- patients, children) if no other pathology is found should be further investigated. Another issue are intraabdominal abscesses. The role of the patients characteristics, the surgeon's expertise, the stump closure, the intraabdominal lavage and the standardization of technique in abscess formation should be further explored. The value of new techniques like the single port, the needlescopic and the robotic procedure in special cases should be investigated, as should the place of laparoscopy in obese patients and pregnant patients. Finally the late results of laparoscopic appendectomy should be explored (adhesions, SBO).

## 6. Conclusion

In conclusion, laparoscopy seems to be as safe as open appendectomy for acute appendicitis. Laparoscopy has many advantages, such as higher diagnostic yield, fewer postoperative wound infections, less postoperative pain, shorter hospital stay, earlier return to normal and full activity, better cosmesis, and probably decreased late complications such as adhesion formation and incisional hernias. Also one cannot overemphasize the superior visualization of the abdominal cavity and the possibility of not only diagnosing other pathologies but also dealing with them without having to use a bigger incision. Fertile women can profit the most from these advantages. But also elderly, overweight and employed patients seem to profit from laparoscopy. If the safety of leaving a macroscopically innocent appendix in situ is clarified by future studies the value of laparoscopy as a diagnostic tool will be enhanced. One expects that the further expansion of laparoscopy will lead to much more experienced surgeons, and that the progress in technology will facilitate this approach even more in the future. The reported higher incidence of intraabdominal abscesses with laparoscopy in some series could be experience- or technique-related and is likely to decrease with the evolution of laparoscopic skills among surgeons that leads to more precise operative maneuvers, and the standardisation of surgical technique. The higher operative costs in most institutions can perhaps be outweighed by a shorter hospital stay, and quicker return to normal activities with the laparoscopic approach, as well as by the possible decrease in late complications. Operative costs themselves can be reduced by the application of reusable instruments, application of loops instead of staplers, and further reduction of operating times. Finally it is important to reduce negative laparoscopies. The exact role of imaging modalities, inflammatory parameters and scoring systems in this purpose has yet to be defined.

## 7. Acknowledgements

The authors thank Mrs. Sofia Monastiriotti for her assistance in editing the text of this chapter. We also thank Dr. Petros Hiridis for his assistance with the illustrations.

## 8. References

- Addis, DG.; Shaffer, N.; Fowler, BS. & Tauxe, RV. (1990). The epidemiology of appendicitis and appendectomy in the United States. *Am J Epidemiol*, Vol. 8, No. 4, pp.910-925, ISSN 0963-7486
- Agresta, F.; De Simone, P.; Michelet, I. & Bedin, N.(2003). Laparoscopic Appendectomy: why it should be done. *JSLS*, Vol. 16, No.1, pp. 347-352, ISSN 1679-1796
- Akl, MN.; Magrina, JF.; Kho, RM.; Magtibay, PM. (2008). Robotic appendectomy in gynaecological surgery: technique and pathological findings. *Int J Med Robot*, Vol. 4, Issue 3, pp.210-213, ISSN 0029-7844
- Andersson, E.; Lambe, M. & Bergstrom, R. (1999). Fertility patterns after appendicectomy: historical cohort study. *BMJ*, Vol. 318, No. 7189 pp. 963-967, ISSN 1464-3685
- Andersson, RE.(2001). Small bowel obstruction after appendicectomy. *Br J Surg*, Vol.26, No. 2, pp.1387-1391, ISSN 0003-4932
- Andersson, RE. & Lambe, M. (2001). Incidence of appendicitis during pregnancy. *Int J Epidemiol*, Vol., No., pp. 1281-1285, ISSN
- Asarias, JR.; Schluskel, AT.; Cafasso, DE.; Carlson, TL.; Kasprenski, MC.; Washington, EN.; Lustik, MB.; Yamamura, MS.; Matayoshi, EZ. & Zagorski, SM.(2011). Incidence of postoperative intraabdominal abscesses in open versus laparoscopic appendectomies. *Surg Endosc*, Vol.136, No.4, ISSN 003-4932
- Ball, CG.; Kortbeek, JB.; Kirckpatrick, AW. & Mitchell, P. (2004). Laparoscopic appendectomy for complicated appendicitis: an evaluation of postoperative factors. *Surg Endosc*, Vol.8, No.1, pp.969-973, ISSN 0003-1348
- Balthazar, EJ.; Megibow, ACCJ.; Sieger, SE.; & Birnbaum, BA. (1991). Appendicitis: prospective evaluation with high resolution CT. *Radiology*, Vol. 28(2), pp.21-24, ISSN 0033-8419
- Balthazar, EJ.; Rofsky, NM. & Zucker, R. (1998). Appendicitis: the impact of computer tomography imaging on negative appendectomy and perforation rates. *Am J Gastroenterol*, Vol.93, No.5, pp. 768-771, ISSN 1528-8404
- Barbaros, U.; Sümer, A.; Tunca, F.; Gözkün, O.; Demirel, T.; Bilge, O.; Randazzo, V.; Dinççağ, A.; Seven, R.; Mercan, S.; Budak, D. (2010). Our early experiences with single-incision laparoscopic surgery: the first 32 patients. *Surg Laparosc Endosc Percutan Tech*, Vol. 20, Issue 5, pp.306-311, ISSN 1072-7517
- Benjamin, IS. & Patel, AG. (2002). Managing acute appendicitis: Laparoscopic surgery is particularly useful for women. *BMJ*, Vol.22, No.2, pp.505-506, ISSN 0749-5161
- Bennett, J; Boddy, A; Rhodes, M. (2007). Choice of approach in appendicectomy: a meta-analysis of open versus laparoscopic appendicectomy. *Surg Laparosc Endosc Percutan Tech*. Vol. 14. No. 4., pp: 245-255, ISSN 1130-0108
- Bijnen, CL.; Van den Broek, WT.; Bijnen, AB.; De Ruiter, P. & Gouma DJ. (2003). Implications of removing a normal appendix. *Dig Surg*, Vol.20, No.2, pp.215-219; discussion pp. 220-221, ISSN 0303-5212



- Birnbaum, BA. & Wilson, SR. (2000). Appendicitis at the Millenium. *Radiology*, Vol.215, No. 2 pp.337-348, ISSN 1528-8315
- Borgstein, PJ.; Gordijn, RV.; Eijsbouts, QAJ. & Cuesta, MA. (1997). Acute appendicitis – a clear-cut case in men, a guessing game in young women. *Surg Endosc*, Vol. 11 No.9, pp. 923-927, ISSN 1130-0108
- Botha, AJ.; Elton, C.; Moore, EE. & Sauven P. (1995). Laparoscopic appendicectomy: a trainees perspective. *Ann R Coll Surg Eng*, Vol.3, No. 2, pp. 259-262, ISSN 1528-8242
- Butala, P; Greenstein, AJ; Sur, MD; Mehta, N; Sadot, E; Divino, CM. (2010). Surgical management of acute right lower-quadrant pain in pregnancy: a prospective cohort study. *Journal of the American College of Surgeons*. Vol. 211, No.4, pp. 490-4, ISSN 1072-7515
- Cardall, T.; Glasser, J. & Guss, DA. (2004). Clinical value of the total white blood cell count and temperature in the evaluation of patients with suspected appendicitis. *Acad Emerg Med*, Vol.14, No.2, pp.1021-7, ISSN 1007-9327
- Chandler, B.; Beegle, M.; Elfrink, RJ. & Smith, WJ. (2002). To leave or not to leave? A retrospective review of appendectomy during diagnostic laparoscopy for chronic pelvic pain. *Mo Med*, Vol.13, No.5, pp.502-504, ISSN 1333-994
- Chiarugi, M.; Buccianti, P.; Decanini, L.; Balestri, R.; Lerenzetti, L.; Franceschi, M. & Cavina, E. (2001). “What you see is not what you get”. A plea to remove a “normal” appendix during diagnostic laparoscopy. *Acta Chir Belg*, Vol.19, No.5, pp.243-245, ISSN
- Chichom Mefire, A; Tchounzou, R; Kuwong, PM; Atangana, JP; Lysinge, AC. & Malonga, EE. (2011). Clinical, Ultrasonographic and Pathologic Characteristics of Patients with Chronic Right-lower-quadrant Abdominal Pain that May Benefit from Appendectomy. *World Journal of Surgery*. Vol.35, No.4, pp.723-30, ISSN 1069-6563
- Chung, R.; Rowland, D.; Li, P. & Diaz, J A. (1999). Meta-analysis of Randomized Controlled Trials of *Laparoscopic Versus Conventional Appendectomy*. *Am J Surg*, Vol.177, No.3, pp. 250-256, ISSN 1007-9327
- Clarke, T.; Katkhouda, N.; Mason, RJ.; Cheng, BC.; Olasky, J.; Sohn, HJ.; Moazzez, A.; Algra, J.; Chaghouri, E. & Berne, TV. (2011). Laparoscopic versus open appendectomy for the obese patient: a subset analysis from a prospective, randomized, double-blind study. *Surg Endosc*, Vol.25, No.4, pp.1276-1280, ISSN 1432-2218
- Corneille, MG.; Steigelman, MB.; Myers, JG.; Jundt, J.; Dent, DL.; Lopez, PP.; Cohn, SM. & Stewart, RM. (2007). Laparoscopic appendectomy is superior to open appendectomy in obese patients. *Am J Surg*, Vol.194, Issue 6, pp.877-880, ISSN 0803-5253
- Corneille, MG.; Gallup, TM.; Bening, T.; Wolf, SE.; Brougher, C.; Myers, JG.; Dent, DL.; Medrano, G.; Xenakis, E & Stewart, RM. (2010). The use of laparoscopic surgery in pregnancy: evaluation of safety and efficacy. *Am J Surg*, Vol.20, Issue 6, pp.363-367, ISSN 1879-1883
- Cox, MR.; Mc Call, JR.; Padbury, RT.; Wilson, TG. & Wattchow, DA. (1995). Tooul. Laparoscopic surgery in women with a clinical diagnosis of an appendicitis. *Med J Aust*, Vol.8, No.3, pp. 130-2, ISSN 1007-9327
- De Wilde RL. (1991). Goodbye to late bowel obstruction after appendicectomy. *The Lancet*, Vol.73, No.11, ISSN 1421-9983

- Di Sebastiano, P.; Fink, T. & Buchler MW. (1999). Neuroimmune appendicitis. *The Lancet*, Vol. 354, No.9172, pp. 461-66, ISSN 1021-7401
- Duff, SE. & Dixon, AR. (2000). Laparoscopic appendectomy: safe and useful in training. *Ann R Coll Surg Engl*, Vol.172, No.1, pp. 388-391, ISSN 1469-0756
- Enochson, L.; Hellberg, A.; Rudberg, C.; Fenyö; Gudbjartson, T.; Kullman, E.; Ringquist, I.; Sörensen, S. & Wenner, J. (2001). Laparoscopic vs open appendectomy in overweight patients. *Surg Endoscopy*, Vol.3, No.7, pp. 387-392, ISSN 0930-2794
- Fingerhut, A.; Millat, B. & Borrie, F. (1999). Laparoscopic versus Open Appendectomy: Time to Decide. *World J. Surg*, Vol.23, No.8, pp. 835-845, ISSN 0003-4932
- Fleming, FJ.; Kim, MJ.; Messing, S.; Gunzler, D.; Salloum, R. & Monson, JR. (2010). Balancing the risk of postoperative surgical infections: a multivariate analysis of factors associated with laparoscopic appendectomy from the NSQIP database. *Ann Surg*, Vol.252, Issue 6, pp. 895-900, ISSN 0003-4932
- Flum, DR.; McClure, TD.; Morris, A. & Koepsell, T. (2005). Misdiagnosis of appendicitis and the use of diagnostic imaging. *J Am Coll Surg*, Vol.201, No.6, pp. 933-9, ISSN 1468-3288
- Gaitan, HG.; Ludovic Reveiz, & Cindy Farquhar (2010). Laparoscopy for the management of acute lower abdominal pain in women of childbearing age. *Cochrane Database of systematic Reviews*, Vol.1, Issue 1, ISSN 1464-780x
- Gaitán HG, Reveiz L, Farquhar C.(2011). Laparoscopy for the management of acute lower abdominal pain in women of childbearing age. *Cochrane Database Syst Rev*, Vol.22, No.2, ISSN 1464-780X
- Garbutt, JM.; Soper, NJ.; Shannon, WD.; Botero, A. & Littenberg, B. (1999). Meta-analysis of randomized controlled trials comparing laparoscopic and open appendectomy. *Surg Laparosc Endosc*, Vol.5, No.2, pp. 17-26, ISSN 1007-9327
- Golub, R.; Siddiqui, F. & Pohl D. (1998). Laparoscopic versus open appendectomy: a metaanalysis. *J Am Coll Surg* Vol.42, No.1, pp. 545-53, ISSN 1007-9327
- Gronroos, JM. & Gronroos, P. (1999). Leucocyte count and C-reactive protein in the diagnosis of acute appendicitis. *Br J Surg* Vol.16, No.2, pp. 501-4, ISSN 0803-5253
- Gupta, R.; Sample, C.; Bamehriz, F. & Birch, DW. (2006). Infectious complications following laparoscopic appendectomy. *Can J Surg*, Vol.49, No.6, pp. 397-400, ISSN 1435-2451
- Gutt, CN.; Oniu, T.; Schemer, P.; Mehrabi, A. & Buechler, MW. (2004). Fewer adhesions induced by laparoscopic surgery? *Surg Endosc.*, Vol18., No.6, pp. 898-906, ISSN 0930-2794
- Heikkinen TJ, Haukipuro H, Hulkko A. (1998). Cost-effective appendectomy. Open or laparoscopic? A prospective randomized study. *Surg Endosc*, Vol.14, No.31, pp.1204-1208
- Howie J BMJ (2003). 326,p49, ISSN 0253-4886
- Hsieh, CS.; Chen, YL.; Lee, MH.; Chang, HC.; Chen, ST. & Kuo, SJ.(2009). A lower costly laparoscopic appendectomy: our experience of more than 2000 cases. *Int J Surg*, Vol.8, Issue 2, pp. 140-3, ISSN 1007-9327
- Hussain, A.; Mahmood, H.; Nicholls, J. & El-Hasani, S. (2008). Prevention of intra-abdominal abscess following laparoscopic appendectomy for perforated appendicitis: a prospective study. *Int J Surg*, Vol. 180, Issue 6, pp. 374-7, ISSN 1743-9159

- Jackson, H.; Granger, S.; Price, R.; Rollins, M.; Earle, D.; Richardson, W. & Fanelli, R. (2008). Diagnosis and laparoscopic treatment of surgical diseases during pregnancy: an evidence-based review. *Surg Endosc*, Vol.22, No.9, pp. 1917-1927, ISSN 1432-2218
- Jacob, DA.; Raakow, R. (2010). [Single-port transumbilical endoscopic cholecystectomy: a new standard?]. *Dtsch Med Wochenschr*, Vol.22, No 1, pp1363-1367, ISSN 1528-8242
- Jeong, JS.; Ryu, DH.; Yun, HY.; Jeong, EH.; Choi, JW. & Jang LC. (2011). Laparoscopic appendectomy is a safe and beneficial procedure in pregnant women. *Surg Laparosc Endosc Percutan Tech*, Vol.22, Issue 1, pp. 24-27, ISSN 1534-4908
- Johnson AB, Peetz ME. (1998). Laparoscopic appendectomy is an acceptable alternative for the treatment of perforated appendicitis. *Surg Endosc*, Vol.8, No.1, pp. 940-943, ISSN 0253-4886
- Jones PF. (2001). Suspected acute appendicitis: trends in management over 30 years. *Br J Surg*, Vol.88, Issue 1, pp.1570-1577, ISSN 1528-8242
- Kapischke M, Bley K, Tempel J, Schulz T. (2005). Open versus laparoscopic appendectomy for perforated appendicitis- a comparative study. *Zentralbl Chir*, Vol.10, No. 6, pp.137-41, ISSN 1364-5706
- Kaplan, M.; Salman, B.; Yilmaz, TU. & Oguz, M. (2009). A quality of life comparison of laparoscopic and open approaches in acute appendicitis: a randomised prospective study. *Acta Chirurgica Belgica*, Vol. 106, No. 3, pp. 356-63, ISSN 0001-5458
- Kazemier, G.; Hof, KH.; Saad, S.; Bonjer, HJ. & Sauerland, S.; (2006). Securing the appendiceal stump in laparoscopic appendectomy: evidence for routine stapling? *Surg Endosc*, Vol.20, No.9, pp. 1473-6, ISSN 030
- Khalili, TM.; Hiatt, JR.; Savar, A.; Lau, C. & Margulies DR. (1999). Perforeted appendicitis is not a contraindication to laparoscopy. *Am Surg*, Vol.27, No.6, pp. 965- 967, ISSN 0253-4886
- Kim, MJ.; Kim, MJ.; Fleming, FJ.; Gunzler, DD.; Messing, S.; Salloum, RM. & Monson, JR. (2011). Laparoscopic appendectomy is safe and efficacious for the elderly: an analysis using the National Surgical Quality Improvement Project database. *Surgical Endoscopy*, Vol.1, No. 3, (Feb 7). [Epub ahead of print], ISSN 1432-2323
- Kirshtein B, Perry ZH, Avinoach E, Mizrahi S, Lantsberg L. (2009). Safety of laparoscopic appendectomy during pregnancy. *World J Surg*, Vol.21, Issue 1, pp.475-480, ISSN 0364
- Kraemer, M.; Ohmann, C.; Leppert, R. & Yang, Q. (2000). Macroscopic assessment of the appendix at diagnostic laparoscopy is reliable. *Surg Endosc*, Vol.19, Issue 5, pp. 625-33, ISSN 0930-2794
- Larsson, P-G.; Henriksson, G.; Olsson, M.; Boris, J.; Ströberg, P.; Tronstad, S-E. & Skullman, S. (2001). Laparoscopy reduces unnecessary appendicectomies and improves diagnosis in fertile women. *Surg Endosc*, Vol.15, No.2, pp. 200- 202, ISSN 1469-0756
- Konstantinidis, KM.; Anastasakou, KA.; Vorias, KM.; Sambalis, GH.; Georgiou, MK.; Xiarchos, AG. (2008). *Journal of Laparoendoscopic and Advanced Surgical Techniques*, Vol. 18, No.2, pp. 248-258, ISSN 1492-6429
- Kutasy, B.; Hunziker, M.; Laxamanadass, G.; Puri, P. (2011). Laparoscopic appendectomy is associated with lower morbidity in extremely obese children. *Pediatr Surg Int*, Vol. 196, Issue 2, pp.533-536, ISSN 0179-0358
- Lagares-Garcia, JA.; Bandsidhar, B. & Moore, RA. (2003). Benefits of laparoscopy in middle-aged patients. *Surg Endosc*, Vol.7, No.2, pp. 68-72, ISSN 0798-0469

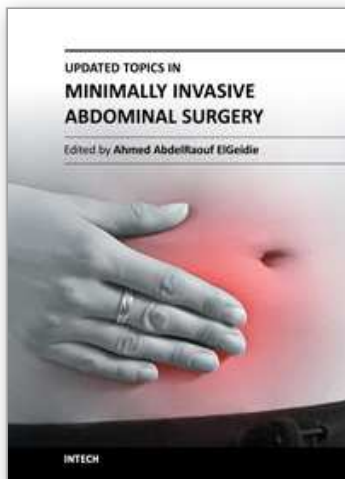
- Lee, YS.; Kim, JH.; Moon, EJ.; Kim, JJ.; Lee, KH.; Oh, SJ.; Park, SM.; Hong, TH. (2009). Comparative study on surgical outcomes and operative costs of transumbilical single-port laparoscopic appendectomy versus conventional laparoscopic appendectomy in adult patients. *Surg Laparosc Endosc Percutan Tech*, Vol. 19, Issue 6, pp.493-496, PMID 2002-7094
- Lee, SL.; Walsh, AJ. & Ho, HS. (2001). Computed tomography and ultrasonography do not improve and may delay the diagnosis and treatment of acute appendicitis. *Arch Surg*, Vol.136, No. 5, pp. 556- 562, ISSN 0014-312
- Leeuwenburgh, MM.; Lameris, W.; Van Randen, A.; Bossyt, PM.; Boermeester, MA. & Stoker, J. OPTIMAP study group. (2010). Optimizing imaging in suspected appendicitis (OPTIMAP-study): a multicenter diagnostic accuracy study of MRI in patients with suspected acute appendicitis. Study Protocol. *BMC Emerg Med*. Vol.7, Issue 11, (Oct 20; 10:19), ISSN 1527-1323
- Lemieux, P.; Rheume, P.; Levesque, I.; Bujold, E. & Brochu, G.(2009). Laparoscopic appendectomy in pregnant patients: a review of 45 cases. *Surg Endosc*, Vol. 23, Issue 8, pp. 1701-1705, ISSN 1432-2218
- Lippert, H.; Koch, A.; Marutsch, F.; Wolff, S. & Gastinger, I. (2002). Offene versus laparoskopische Appendektomie. *Chirurg*, Vol.101, Issue 8, pp.791-98, ISSN 723-7065
- Liu, SL.; Siewert, B.; Raptopoulos, V. & Hodin, RA. (2002). Factors associated with conversion to laparotomy in patients undergoing laparoscopic appendectomy. *J Am Coll Surg*, Vol.194, Issue 3, pp. 298-305, ISSN 1527-1315
- Liu, Z.; Zhang, P.; Ma, Y.; Chen, H.; Zhou, Y.; Zhang, M.; Chu, Z. & Qin, H. (2010). Laparoscopy or not: a meta- analysis of the surgical effects of laparoscopic versus open appendectomy. *Surg Laparosc Endosc Percutan Tech*, Vol.20, No.6, pp.362-70, ISSN 1471-230X
- Macarulla, E.; Vallet, J.; Abad, JM.; Hussein, H.; Fernandez, E. & Nieto, B. (1997). Laparoscopic versus open appendectomy: a prospective randomized trial. *Surg Laparosc Endosc*, Vol.22, No.1, pp.335- 339, ISSN 1025 - 5583
- Machado, NO.; Machado, LS. (2007). Laparoscopic cholecystectomy in the third trimester of pregnancy: report of 3 cases. *Surg Laparosc Endosc Percutan Tech*, Vol. 19, No 6, pp.439-441, ISSN 0972-2068
- Markides, G.; Subar, D. & Riyad K.(2010). Laparoscopic versus open appendectomy in adults with complicated appendicitis: systematic review and meta-analysis. *World J Surg*, Vol.77, Issue 3, pp. 2026-40, ISSN 0003-1348
- Moberg, AC.; Ahlberg, G.; Leijonmarck, CE.; Montgomery, A.; Reiertsen, Rosseland, AR. & Stoerksson, R. (1998). Diagnostic laparoscopy in 1043 patients with suspected acute appendicitis. *Eur J. Surg*, Vol.28, No.5, pp. 833- 840, ISSN 1102-4151
- Moore, D.; Grogan, E.; Sperroff, T. & Holzman, M. (2004). Cost perspectives of laparoscopic and open appendectomy. *SAGES; Poster of distinction*, Vol.18, No.2, ISSN 1366-5278
- Moore, CB.; Smith, RS.; Herbertson, R. & Toevs, C. (2011). Does Use of Intraoperative Irrigation with Open or Laparoscopic Appendectomy Reduce Post-Operative Intra-abdominal Abscess? *Am. Surg*, Vol.136, No.4, pp. 78-80, ISSN 1007-9327



- Moreno-Sanz, C.; Pascual-Pedreño, A.; Picazo-Yeste, JS.; Seoane-Gonzalez, JB. (2009). Laparoscopic appendectomy during pregnancy: between personal experiences and scientific evidence. *J Am Coll Surg*, Vol. 205, Issue 1, pp.37-42, ISSN 1072-7515
- Morino, M.; Pellegrino, L.; Castagna, E.; Farinella, E. & Mao, P.(2006). Acute nonspecific abdominal pain: A randomized, controlled trial comparing early laparoscopy versus clinical observation. *Ann Surg*, Vol.13, No.2, pp.886-888, ISSN 1528-8242
- Mussack, T.; Schmidbauer, S.; Nerlich, A.; Schmidt, W. & Hallfeldt, KK. (2002). Chronic appendicitis as an independent clinical entity. *Chirurg*, Vol.33, No.3, pp.710-715, ISSN 0009-4722
- Navez, B.; Therasse, A. (2003). Should every patient undergoing laparoscopy for clinical diagnosis of appendicitis have an appendectomy? *Acta Chir Belg*, Vol.91, Issue 4, pp.87-89 ISSN 1007-9327
- Neumeyer, L.; Kennedy, A. (2003). Imaging in appendicitis: a review with special emphasis on the treatment of women. *Obstet Gynecol*, Vol.102, Issue 6, pp. 1404- 1409, ISSN 0001-6002
- Ng, WT.; Lee, YK.; Hui, SK.; Sze, YS.; Chan, J.; Zeng, AG.; Wong, CH. & Wong, WH. (2004). An optimal, cost-effective laparoscopic appendectomy technique for our surgical residents. *Surg Laparosc Endosc Percutan Tech*, Vol. 14, No.3, pp. 125-9, ISSN 1681-715X
- Pedersen, AG.; Petersen, OB.; Wara, P.; Ronning, H.; Qvist, N. & Laurberg, S. (2001). Randomized clinical trial of laparoscopic vs open appendectomy. *Br J Surg*, Vol.23, No. 3, pp. 200-205, ISSN 0007-1323
- Piskun, G.; Kozik, D.; Rajpal, S.; Shaftan, G. & Fogler, R. (2001). Comparison of laparoscopic, open, and converted appendectomy for perforated appendicitis. *Surg Endosc*, Vol.10, No. 6, pp. 660- 662, ISSN 0972-2068
- Pokala, N.; Sadhasivam, S.; Kiran, RP. & Parithivel, V.(2007). Complicated appendicitis--is the laparoscopic approach appropriate? A comparative study with the open approach: outcome in a community hospital setting. *Am Surg*, Vol.73, No.8, pp.741-2, ISSN 0303-5212
- Riber, C.; Soe, K.; Jorgensen, T. & Tonnesen, H. (1997). Intestinal obstruction after appendectomy. *Scand J Gastroenterol*, Vol.26, No.3, pp.1125- 1128, ISSN 0253-4886
- Ruiz de Angulo, D.; Martínez de Haro, LF.; Ortiz, MA.; Munitiz, V.; Navas, D.; Abrisqueta, J. & Parrilla, P.(2011). Evaluation of the aesthetic results perceived by patients after 3-port laparoscopic appendectomy. *Cir Esp*, Vol.9, No.1, ISSN 1437-981
- Sadot, E.; Telem, DA.; Arora, M.; Butala, P.; Nguyen, SQ. (2010). Divino CM Laparoscopy: a safe approach to appendicitis during pregnancy. *Surg Endosc*, Vol.24, No 2, pp 383-389, ISSN 0930-27
- Sajid, MS.; Rimple, J.; Cheek, E. & Baig, MK. (2009). Use of endo-GIA versus endo-loop for securing the appendicular stump in laparoscopic appendectomy: a systematic review. *Sug Laparosc Endosc Perculan Tech*, Vol.9, No.4, pp. 5-11, ISSN 1778-3852
- Sauerland, S.; Lefering, R.; Holthausen, U. & Neugebauer EAM. (1998). Laparoscopic vs conventional appendectomy - a meta-analysis of randomised controlled trials. *Langenbeck's Arch Surg*, Vol.127, Issue 3, pp. 289-295, ISSN 0253-4886
- Sauerland, S.; Lefering, R. & Neugebauer EAM. (2002). Laparoscopic versus open surgery for suspected appendicitis. Cochrane Review, The Cochrane Library, Vol.68, Issue 1 Cochrane Database Syst Rev. 2002;(1):CD001546, ISSN 1464-780

- Sauerland, S.; Lefering, R. & Neugebauer EAM. (2004). Laparoscopic versus open appendectomy for suspected appendicitis. The Cochrane Database of Systematic Reviews, Vol.333, Issue 4. Art No.: CD001546. DOI:10.1002/14651858.CD001546.pub2, ISSN 1538-3598
- Sauerland, S. et al. EAM. (2010). Laparoscopic versus open appendectomy for suspected appendicitis. *The Cochrane Database of Systematic Reviews*, Vol.19, No.6, CD001546, ISSN 1538-3598
- Sauerland S, Kazemier G. Appendix stump closure during laparoscopic appendectomy (Protocol). *Cochrane Database of Systematic Reviews* 2007, Issue 2. Art. No.: CD006437. DOI: 10.1002/14651858.CD006437, ISSN 1469-493
- Semm K (1983). Endoscopic appendectomy. *Endoscopy*, Vol.21, Issue 1, pp.59-64, ISSN 1528-8242
- Scott-Conner, CE.; Hall, TJ.; Anglin, BL. & Muakassa FF. (1992). Laparoscopic appendectomy. Initial experience in a teaching program. *Ann Surg*, Vol.20, No.1, pp.660- 667, ISSN 1681-715
- Stoltzing, H. & Thon, K. (2000). Perforated appendicitis: is laparoscopic operation advisable? *Dig Surg*, Vol.17, No.6, pp.610-616, ISSN 1364-5706
- Tate, J. J. T. (1996). Laparoscopic appendicectomy. Leading articles. *Br J Surg*, Vol.83, Issue 9, pp. 1169-70 ISSN 2036-3605
- Teh, SH.; O’Ceallaigh, Mckeon, JG.; O’Ceallaigh, S.; Mckeon, JG.; O’Donohoe, MK.; Tanner, WA. & Keane, FB. (2000). Should an appendix that looks “normal” be removed at diagnostic laparoscopy for acute right iliac fossa pain? *Eur J Surg*, Vol.166, Issue 5 pp.388- 389, ISSN 1102-4151
- Temple, LK.; Litwin, DE. & McLeod, RS. (1999). A meta-analysis of laparoscopic versus open appendectomy in patients suspected of having acute appendicitis. *Can J Surg*, Vol.22, No.2, pp.377- 383, ISSN 1528-8242
- Terasawa, T.; Blackmore, C.; Bent, S. & Kohlwes, J. (2004). Systematic Review: Computed Tomography and Ultrasonography To Detect Acute Appendicitis in Adults and Adolescents. *Ann Intern Med*, Vol.141, No.7, pp.537-546, ISSN 1748-880
- Tingstedt, B.; Johansson, J.; Nehez, L. & Andersson, R. (2004). Late abdominal complaints after appendectomy-readmissions during long-term follow-up. *Dig Surg*, Vol.21, No.1, pp. 23-27, ISSN 1007-9327
- Toorenvliet, BR.; Wiersma, F.; Bakker, RF.; Merkus, JW.; Breslau, PJ. & Hamming, JF. (2010). Routine ultrasound and limited computed tomography for the diagnosis of acute appendicitis. *World Journal of Surgery*. Vol.34, No. 10, pp: 2278-85, ISSN 1432-2323
- Towfiigh, S.; Chen, F.; Mason, R.; Kathkouda, N.; Chan, L. & Berne, T. (2006). Laparoscopic appendectomy significantly reduces length of stay for perforated appendicitis. *Surg Endosc*, Vol. 18, No. 2, pp. 495-499, ISSN 1007-9327
- Tsai, AY.; Selzer, DJ. (2010). Single-port laparoscopic surgery. *Adv Surg*, Vol.23, Issue 1, pp.1-27, ISSN 1528-8242
- Van Randen, A.; Lameris, W.; Van Es, HW.; Van Heesewijk, HP.; Van Ramhorst, B.; Ten Hove, W.; Bouma, WH.; Van Leeuwen, MS.; Van Keulen, EM.; Bossyt, PM.; Stoker, J. & Boeremeester, MA; on behalf of the OPTIMA study group. (2011). *Eur Radiol*. Vol.8, No.25, Mar 2 [Epub ahead of print]. ISSN 0033-8419

- Van Dalen, R.; Bagshaw, PF.; Dobbs, BR.; Robertson, GM.; Lynch, AC. & Frizelle, FA. (2003). The utility of laparoscopy in the diagnosis of acute appendicitis in women of reproductive age. *Surg Endosc*, Vol.2, No.2, pp. 1311- 1313, ISSN 0930-2794
- Van den Broeck, WT.; Bijnen, AB.; Van Eerten, PV.; De Ruiter P. & Gouma DJ. (2000). Selective use of diagnostic laparoscopy in patients with suspected appendicitis. *Surg Endosc*, Vol.14, No.10, pp. 938- 941, ISSN 0930-2794
- Vetturetto, N. & Agresta F. (2011). A brief review of laparoscopic appendectomy: the issues and the evidence. *Tech Coloproctol*, Vol.15, No.1, pp.1-6, ISSN 1428-045X
- Walsh, CA.; Tang, T. & Walsh SR. (2008). Laparoscopic versus open appendectomy in pregnancy: a systematic review. *Int J Surg*, Vol., No., pp. 339-344, ISSN
- Wang, Y.; Reen, DJ. & Puri P. (1996). Is a histologically normal appendix following emergency appendectomy always normal? *The Lancet*, Vol.347, Issue 9008, pp. 1076-79, ISSN 1543-2165
- Weston, AR.; Jackson, TJ. & Blamey, S.(2005). Diagnosis of appendicitis in adults by ultrasonography or computed tomography: Asystemic review and meta-analysis. *International Journal of Technology Assessment in Health Care*, Vol.21, No.3, pp. 368-379, ISSN: 1948-5204
- Wei, HB.; Huang, JL.; Zheng, ZH.; Wei, B.; Zheng, F.; Qiu, WS.; Guo, WP.; Chen, TF. & Wang, TB.(2010). Laparoscopic versus open appendectomy: a prospective randomized comparison. *Surg Endosc*, Vol.59, No.1, pp. 266-9, ISSN 0930-2794
- Wie, HJ.; Lee, JH.; Kyung, MS.; Jung, US.; Choi, JS. (2008). Is incidental appendectomy necessary in women with ovarian endometrioma? *Aust N Z J Obstet Gynaecol*, Vol.48, No 1, pp.107-111, ISSN 0004-8666
- Wullstein, C. Barkhausen, S. & Gross, E. (2001). Results of laparoscopic vs. conventional appendectomy in complicated appendicitis. *Dis Col Rectum*, Vol.44, No.11, pp. 1700-1705, ISSN 0100-6991
- Yang, HR.; Wang, YC.; Chung, PK.; Chan, WK.; Jeng, LB. & Chen, RJ. (2005). Role of leucocyte count, neutrophil percentage, and C-reactive protein in the diagnosis of acute appendicitis in the elderly. *Am Surg*, Vol.2, No.1, pp. 344-7, ISSN 1681-715
- Yeh, CC.; Wu, SC.; Liao, CC.; Su, LT.; Hsieh, CH. & Li, TC. (2011). *Surgical Endoscopy*, Mar 18, [epub ahead of print], Vol.17, No. 13, ISSN 1007-9327
- Zbar, RI.; Crede, WB.; McKhann, CF. & Jekel, JF. (1993). The postoperative incidence of small bowel obstruction following standard, open appendectomy and cholecystectomy: a six year retrospective cohort study at Yale- New Haven Hospital. *Conn Med*, 57, Vol.9, No.12, pp. 123- 127, ISSN 1715-5258



## **Updated Topics in Minimally Invasive Abdominal Surgery**

Edited by Prof. Ahmed Elgeidie

ISBN 978-953-307-773-4

Hard cover, 246 pages

**Publisher** InTech

**Published online** 14, November, 2011

**Published in print edition** November, 2011

Updated topics in minimally invasive abdominal surgery provides surgeons interested in minimally invasive abdominal surgery with the most recent techniques and discussions in laparoscopic surgery. This book includes different topics covering a big variety of medical conditions with up-to-date information. It discusses many controversies in a clear and user-friendly manner. This book is made for young junior surgeons in training and also senior surgeons who need to know the most recent work in the field of laparoscopy. To make the material easily digestible, we provided the book with many figures and illustrations for different procedures and technical pearls.

### **How to reference**

In order to correctly reference this scholarly work, feel free to copy and paste the following:

Konstantinos M. Konstantinidis and Kornilia A. Anastasakou (2011). Laparoscopic Appendectomy, Updated Topics in Minimally Invasive Abdominal Surgery, Prof. Ahmed Elgeidie (Ed.), ISBN: 978-953-307-773-4, InTech, Available from: <http://www.intechopen.com/books/updated-topics-in-minimally-invasive-abdominal-surgery/laparoscopic-appendectomy>

**INTech**  
open science | open minds

### **InTech Europe**

University Campus STeP Ri  
Slavka Krautzeka 83/A  
51000 Rijeka, Croatia  
Phone: +385 (51) 770 447  
Fax: +385 (51) 686 166  
[www.intechopen.com](http://www.intechopen.com)

### **InTech China**

Unit 405, Office Block, Hotel Equatorial Shanghai  
No.65, Yan An Road (West), Shanghai, 200040, China  
中国上海市延安西路65号上海国际贵都大饭店办公楼405单元  
Phone: +86-21-62489820  
Fax: +86-21-62489821



© 2011 The Author(s). Licensee IntechOpen. This is an open access article distributed under the terms of the [Creative Commons Attribution 3.0 License](https://creativecommons.org/licenses/by/3.0/), which permits unrestricted use, distribution, and reproduction in any medium, provided the original work is properly cited.

IntechOpen

IntechOpen