

We are IntechOpen, the world's leading publisher of Open Access books Built by scientists, for scientists

6,900

Open access books available

185,000

International authors and editors

200M

Downloads

Our authors are among the

154

Countries delivered to

TOP 1%

most cited scientists

12.2%

Contributors from top 500 universities



WEB OF SCIENCE™

Selection of our books indexed in the Book Citation Index
in Web of Science™ Core Collection (BKCI)

Interested in publishing with us?
Contact book.department@intechopen.com

Numbers displayed above are based on latest data collected.
For more information visit www.intechopen.com



Quantitative Coronary Angiography in the Interventional Cardiology

Salvatore Davide Tomasello¹, Luca Costanzo²
and Alfredo Ruggero Galassi¹

¹*Department of Internal Medicine and Systemic Disease,
Catheterization Laboratory and Cardiovascular Interventional
Unit, Cannizzaro Hospital, University of Catania*

²*Department of Internal Medicine and Systemic Disease,
Clinical Division of Cardiology, Ferrarotto
Hospital, University of Catania
Italy*

1. Introduction

Coronary angiography through selective injection of radiopaque contrast agent into the coronary arteries is currently the gold standard for evaluating coronary artery disease (CAD). Subjective visual estimation of lesion severity has been shown to be inadequate due to high degrees of intraobserver and interobserver variability (Topol & Nissen, 1995). Since the late 1980s methods and algorithms for quantitative coronary angiography (QCA) have been developed in order to objectively quantify the extent of CAD (Serruys et al., 1984).

Furthermore, validation of specific QCA measurements associated with clinical outcomes has led to their incorporation into various scoring systems and trials endpoint.

2. Two-dimensional QCA

This technique is based on contrast coronary angiograms obtaining parameters that quantify objectively the coronary lumen measuring the significance of a coronary stenosis. Notably, a single coronary angiography image gives only a two-dimensional (2D) radiographic image while coronary arteries can be highly tortuous three-dimensional structures thus at least two projections orthogonal to each other and both perpendicular to the analyzed coronary segment are necessary to obtain the most complete data to avoid foreshortening or underestimation of stenosis severity.

Most of the systems available nowadays are based on vessel edge detection algorithms to designate the arterial lumen on conventional coronary angiograms providing, therefore, the assessment of the lesion in an operator-independent way exploiting specific and dedicated software. The earliest form of quantitative angiography was the application of calipers to visually estimate percent diameter stenosis. In 1971 Gensini and colleagues described an electronic caliper system in which the arterial borders of the lesion and normal segments are manually defined by moving cursors (Gensini et al., 1971). In the years several generations

of QCA systems have been developed based on edge detection algorithms to improve measurement accuracy. First-generation algorithms have been introduced at the beginning of the Eighties (Mancini et al., 1987; Reiber et al., 1985) improving the reliability of coronary measurements (Spears et al., 1983); the main pitfall of these first generation systems was the overestimation of the diameters of small vessels (Herrington et al., 1993a), an issue which was improved in the second generation systems (diameter approximation ~ 1.2 mm) and producing more reliable results at the low end of the spectrum of vessel size (Hausleiter et al., 1997). In more recent years cardiovascular X-ray imaging systems are equipped with flat-panel (FP) detectors (Spahn et al., 2003) replacing the combination of image intensifier and charge-couple device camera providing better image quality and enabling further image enhancement. Novel QCA third-generation system which took advantage of digital flat-panel (FP) detectors instead of the conventional image intensifier systems were better able to determine smaller diameter vessels (Van Herck et al., 2004) and analyze complex lesion morphology with irregular borders (Van der Zwet & Reiber, 1994). However differences in results using FP systems compared with classic image intensifier-based imaging systems were shown to be clinically not significant (Tuinenburg et al., 2006). In the common clinical practice there are different computer systems for QCA that have been validated: among them the most commonly employed are CAAS (PIE Medical, Maastricht, The Netherlands) and QAngio XA (Medis, Leiden, The Netherlands) (Garrone et al., 2009).

3. Three-dimensional QCA

Currently, 2-dimensional (2D) QCA is the most commonly used and validated form of QCA. However, 2D angiography technology has limitations because of vessel overlap and vessel foreshortening during image acquisition. This is especially problematic in more complex lesions such as bifurcations. 3D angiography utilizes standard 2D angiographic images obtained at least 30 degrees apart and with minimal vessel overlap, and reconstructs 3D images. Several 3D QCA programs are now available: among them the most commonly employed are CardiOp-B (Paieon Medical Ltd. Park Afek, Israel) and CAAS 5 (Pie medical Imaging, Maastricht, The Netherlands, and Medis, Leiden, The Netherlands) (Ng & Lansky, 2011). In these systems, the user defines the area of interest by defining the proximal end, distal end and area of stenosis. However, the systems differ in their calibration methods. CardiOp-B requires the operator to input the size of the catheter in the image into the program, whereas the Medis and CAAS 5 systems automatically calibrates the images using DICOM (Digital Imaging and Communications in Medicine) information embedded in the angiographic images (Gradaus et al., 2006; Ramcharitar et al., 2008a). Once the image is created, operators can manipulate the images by zooming in or rotating the image. This allows the operator to have a better understanding of coronary anatomy and could also help the operator find an optimal angle to image of a vessel for an intervention (Dvir et al., 2005; Agostoni et al., 2008). An example of coronary after reconstructed with CardiOp-B system is shown in figure 1.

3D QCA programs have been validated (Schuurbijs et al., 2009; Tsuchida et al., 2007) and are now available to provide information of vessel size, percent diameter stenosis, minimal lumen diameter, bifurcation angle and other QCA values. It was thought that 3D QCA would have improved accuracy by resolving problems with vessel foreshortening and out of plane magnification. However, comparisons of 3D QCA programs to conventional 2D QCA programs have shown mixed results regarding the accuracy of this technology (Ramcharitar

et al., 2008a; Dvir et al., 2005; Tsuchida et al., 2007; Meerkin et al., 2010; Wellnhofer et al., 1999; Tu et al., 2010). One small study has compared the two current 3D QCA programs using phantom models demonstrated that the CAAS 5 system may be more accurate than the CardiOp-B system (Ramcharitar et al., 2008a).

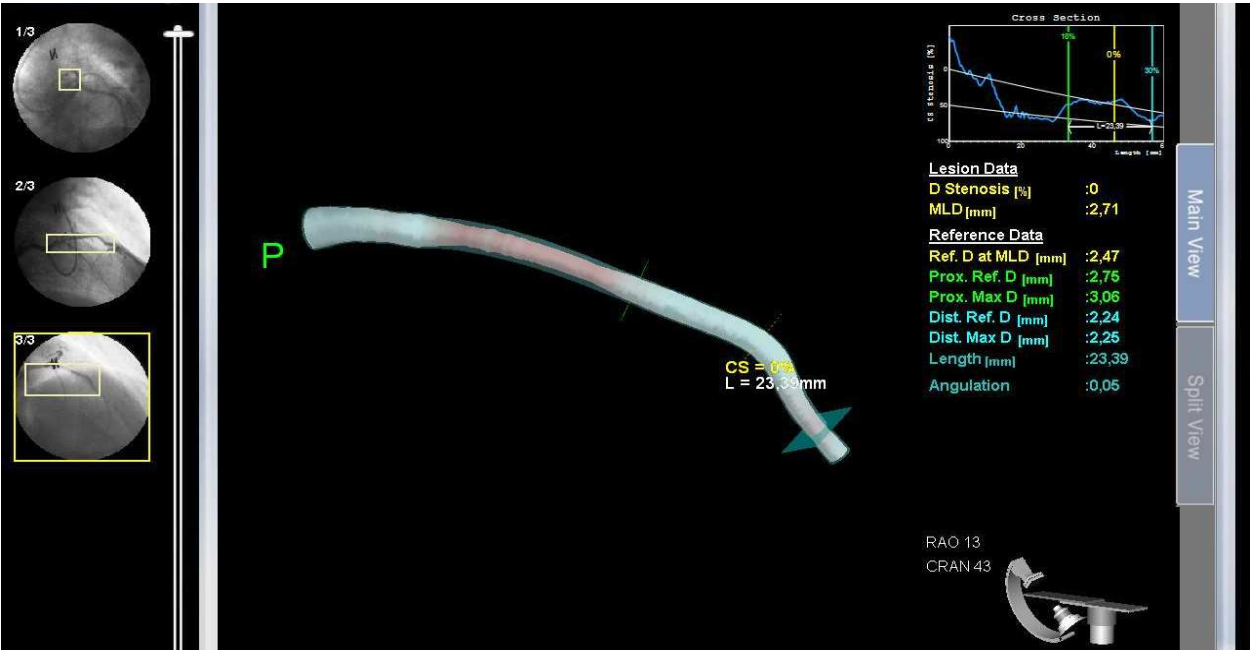


Fig. 1. Reconstruction with 3-D CardiOp-B system of proximal left anterior descending artery.

4. Materials and procedural details

The first step in order to perform a QCA analysis is to acquire high-quality angiographic images of the coronary artery segment of choice using a standard and reliable technique. Coronary angiography actually provides a two-dimensional luminogram of a three-dimensional structure, formed not only of the lumen itself but also of the vessel wall. Therefore, coronary angiography has important limitations that can have a significant impact on the results of QCA (Topol & Nissen, 1995). It is thus clear that coronary angiography cannot analyze coronary remodeling mechanisms, that is, the outward or inward changes in total vessel area that may not correspond to outward or inward changes in lumen area typical of atherosclerosis in an effective way (Glagov et al., 1987). Furthermore, to get coronary angiographic images that profile the exact coronary anatomy with as much details as possible and avoid foreshortening or underestimation of stenosis severity, it is necessary also that the C-arm tube is directly orthogonal to the coronary segment analysed, and it is advisable to get at least two projections orthogonal to each other and both perpendicular to the coronary segment in order to obtain the most complete data. Selection of a coronary image for analysis depends on several factors linked to the limits of radiographic coronary images. The real issue is the choice of the sequence where the stenosis has the minimal foreshortening and the minimal overlap with other structures (e.g., other coronary arteries, bifurcation branches, catheters, or radiopaque surrounding structures such as a calcified mitral valve). The greater is the contrast between the radiopaque contrast-filled coronary artery and the radiotransparent background, the greater

are the accuracy of QCA analysis and reliability of the algorithm for the automated detection and reconstruction of the lumen edges. That is why it is also important that the coronary images are obtained when the patient is in deep inspiration, which increases the radiotransparent lung fields surrounding the heart and thus the possibility that the stenosis is in front of this radiotransparent field. It is also important that the distal tip of the coronary angiography catheter is present in the sequence, at least in the initial frames.

Indeed, the tip of the catheter, whose diameter in French or millimeters is known, is the basic tool for calibration (i.e., to estimate the proportion between pixels in the digitalized images and mm of length). Finally, intracoronary nitroglycerine (e.g., 200 μ g) might be administered to obtain coronary vasodilatation and avoid to mistakenly confounding vasospasm with atherosclerotic processes.

After choosing the appropriate run, a single static image (i.e., frame) is selected which should be chosen in end-diastole, when coronaries tend to “stretch” along their course on the released heart muscle without being subject to contraction or squeezing, even in the case of intra-myocardial course. Regardless of the type of software, the analysis proceeds similarly and the following steps consist in: *digitization*, *image calibration* and *arterial automatic contour detection*. Advances have been made to each of these steps over the last several decades. The process of *digitization* from cine film using cine video converter is obsolete and it has been replaced by digital systems with direct digital input to a video camera. The analogic video output signal is modified electronically and results in a greater contrast difference in the parts with high X-ray absorption and lower contrast differences in areas with low X-ray absorption, significantly improving image quality. *Image calibration* is often done with contrast-filled injection catheters (Figure 2), and can be problematic due to variable image quality and out-of-plane magnification that can be overcome by using biplane calibration.

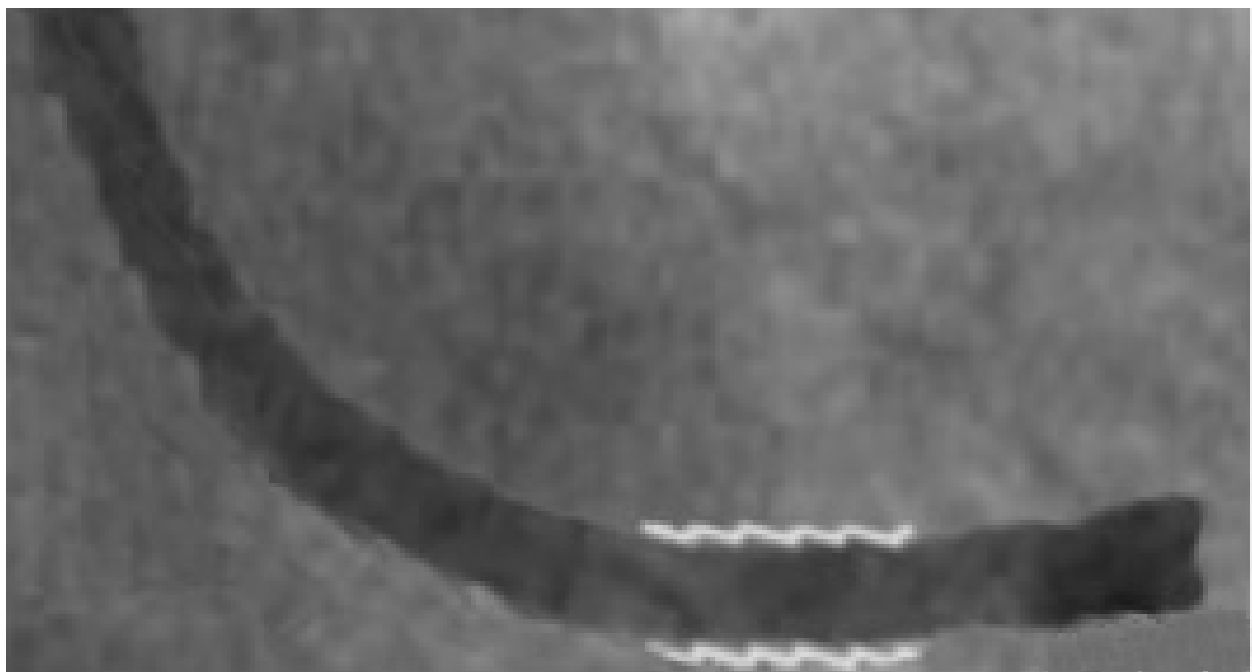


Fig. 2. Image calibration using contrast-filled injection catheter.

A central line is usually then drawn by hand along the stretch of the catheter tip and the software automatically recognizes its margins by using specific algorithms that, by means of digital images, recognize the change from radiopaque pixels (black or dark grey) to radio-transparent pixels (light grey or white) according to a densitometric analysis. The software then transforms every pixel into a square with sides characterized by known dimensions (mm). This parameter is then employed to measure the coronary segment of interest that must be focused on the stenosis or lesion undergoing treatment. The proximal and distal coronary segments should be relatively free of disease and are referred to as reference segments. Afterwards, a central line is traced manually and the software automatically recognizes the margins of the coronary segment under consideration taking advantage of the *automatic contour detection*.

This procedure determines the vessel edge based on the weighted sum of the first and second derivative functions of the brightness values of scanlines perpendicular to the centerline, which in turn undergoes an analysis that determines the optimal contour path along the segment (Figure 3).

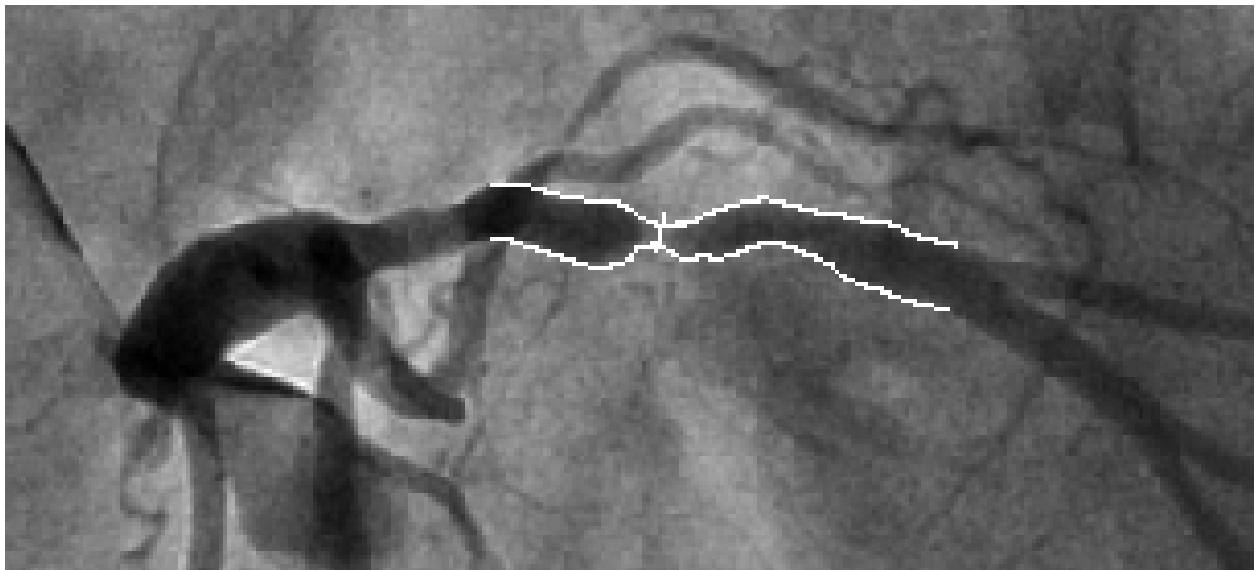


Fig. 3. After having traced a central line the software recognizes the margins elaborating automatically the contours.

A further step allows, always automatically, the reconstruction of the hypothetically normal coronary lumen. An algorithm then creates a line of the coronary margin that interpolates the coronary segment considered free from illness located proximally and distally to the region of interest with the ones of the region of interest. The algorithm then reconstructs the reference coronary segments (i.e., those apparently free from disease) (Figure 4).

This technique is essentially based on the calculation of a mean value of the diameters of the lumen in the segments of reference located upstream and downstream to the lesion. It appears thus clear the importance of including two coronary segments in the QCA analysis, one proximal and one distal to the target segment and both angiographically-free from significant disease. These steps produce different parameters, some measured directly and others derived with interpolation techniques.

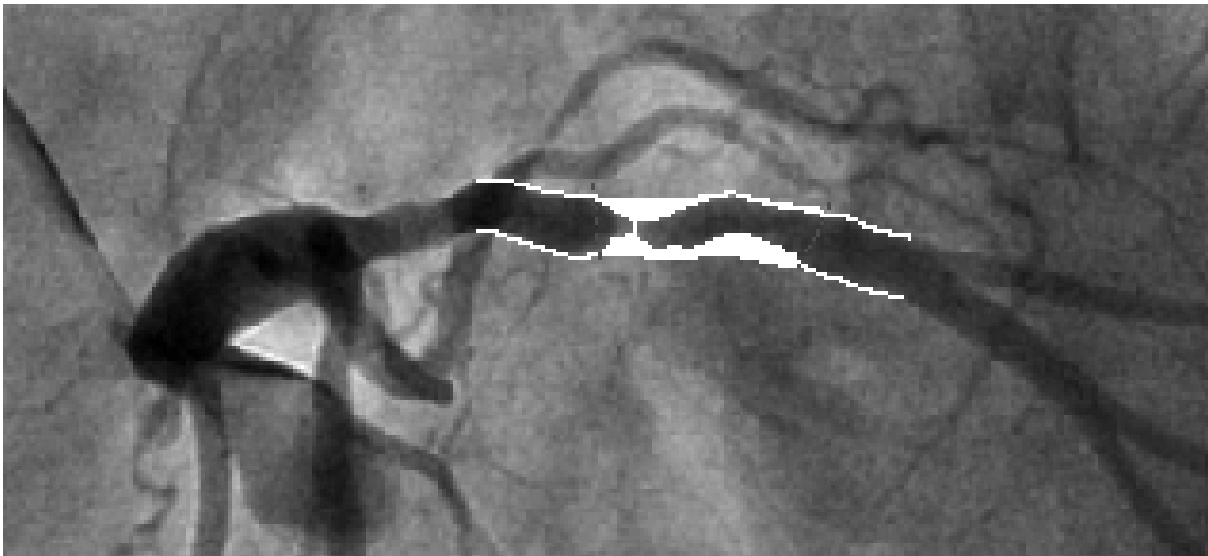


Fig. 4. Software algorithm reconstructs the reference coronary segment.

5. Parameters

Coronary lesions can be assessed qualitatively and quantitatively, in terms of severity of the lesion itself. The qualitative evaluation is based on the visual estimation of the lesion and it depends very much on the operator’s experience. The quantitative evaluation, based on QCA, allows instead to obtain numeric parameters that are much more independent from the operator acquiring the images or the one performing the analyses. The coronary parameters of major interest are summarized in Table 1.

Parameter	Range commonly used	Meaning
Minimal Luminal Diameter (MLD)	0–6.00 mm	The smallest lumen diameter in the segment of interest
Reference Vessel Diameter (RVD)	1.5–6.0 mm	The averaged diameter of the coronary assumed without atherosclerotic disease
Lesion length	0–60.0 mm	Length of the stenosis as measured by 2 points where the coronary margins change direction, creating a shoulder between the angiographically normal subsegment and the diseased subsegment
Acute gain	0–4.0 mm	Post-procedural MLD – pre-procedural MLD
Late loss (LL)	0.10 to 3.00	Post-procedural MLD – MLD at follow-up
Diameter stenosis (DS)	0–100%	(RVD-MLD)/RVD
Binary restenosis (BR)	Yes or no	DS >50% at follow-up coronary angiography in the treated coronary segment

Table 1. Main parameters obtained with QCA (adapted from Garrone et al., 2009)

Additional tool of QCA are also available, indeed it is possible analysis of the stent edges after stent implantation. In fact, the radiopaque stent can generally be visualized during angiographic sequence when the contrast medium has not yet been injected in the coronary vessel. By comparing this image with the frame selected for the QCA analysis, it is possible to determine the two edges, proximal and distal, of the implanted stent. The software then enables to mark the edges with a line transversal to the vessel lumen in order to automatically calculate the segment where the stent has been implanted and to calculate the 5-mm segments that lie proximal and distal to the stent. Therefore, it is possible to determine MLD and DS for each one of the three segments considered.

Several angiographic phenomena can bias QCA and lead to overestimation or underestimation of QCA parameters such as acute or chronic thrombus, extensive calcium deposits, dissections, diffuse disease, and slow flow, therefore it is of paramount importance to add a qualitative analysis for lesion features to any QCA analysis (Garrone et al., 2009).

6. Applications

QCA can be employed in clinical practice during diagnostic coronary angiography (online), to have an objective and independent parameter for the assessment of stenosis severity as the human eye does not have the resolution capability of software. Usually, visual interpretation of the severity of a coronary stenosis is expressed in intervals of percentage of stenosis while QCA produces a single specific measure for DS, improving the accuracy and reproducibility of the severity assessment (Kalbfleisch et al., 1990). It has been shown that the visual assessment tends to underestimate stenoses <50% and to overestimate those >50% (Fleming et al., 1991) therefore the online use of QCA assessing the lesion length and RVD might allow to obtain objective parameters to decide which specific measures (mainly diameter and length) of the device (e.g., balloon or stent) should be chosen.

In the field of clinical research QCA allows serial analysis of the same coronary segment over time in an independent way. In trials on coronary devices typically at least three QCA runs are performed, one before treatment, another immediately after treatment, and a final one at angiographic follow-up, after a respecified time.

In recent years late luminal loss and binary restenosis have taken an important role in several studies aimed at evaluating PCI devices, in particular, stents. These values, more specific and more prevalent of the clinically relevant end-point of target lesion revascularization (TLR), allow researchers to compare different types of devices in clinical trials, with greater statistical power, and thus with fewer patients. In fact, late luminal loss is a continuous parameter and is in itself statistically more powerful and precise, while binary restenosis, despite being a value present or absent as the TLR, occurs with an incidence roughly two times higher than the incidence of TLR. Therefore QCA can reduce the number of patients needed in a clinical trial to obtain significant differences between different devices.

Another interesting application is the study of plaque progression/regression that is based on at least two QCA runs made over a pre-specified interval of time, usually at least 1 year. The change in MLD of the coronary segments of interest is quantified after a given pharmacologic regimen that purports to act on the development or progression of atherosclerotic disease.

7. Prediction of functional significance of a stenosis

2D-QCA systems have substantially improved reproducibility and accuracy of lesion dimension assessment, especially percent diameter stenosis, however its use for the prediction of functional significance of the lesion was shown to have only a modest correlation with the more accurate Flow Fractional Reserve (FFR) (Bartunek et al., 1995; Fischer et al., 2002). Conversely, 3D-QCA has shown reasonable accuracy in predicting FFR < 0.75 in patients with visually determined intermediate stenosis (Saad et al., 2009). Recently, Yong and co-workers investigated the accuracy of 3D- and 2D-QCA measurements in predicting both FFR < 0.75 and ≤ 0.80 , and compared the correlation of FFR with 3D- and 2D-QCA measurements in 63 coronary lesions (Yong et al., 2011). Interesting, the relationship between FFR and apparent stenosis severity was found to be curvilinear. Of all measurements of lesion severity obtained by 3D-QCA, MLA best correlated with FFR ($R = 0.63$, $P < 0.001$), and was the most accurate predictor of FFR < 0.75 (C statistic 0.86, $P = 0.001$). Of 2D-QCA measurements, MLD correlated best with FFR ($R = 0.58$, $P < 0.001$), and best predicted FFR < 0.75 (C statistic 0.80, $P < 0.001$). Overall, 3D-QCA showed a non-significant trend towards more accurate prediction of FFR than 2D-QCA, especially in intermediate lesions. The authors then concluded that both 3D- and 2D-QCA were less accurate in intermediate lesions and in predicting FFR ≤ 0.80 than in predicting FFR < 0.75 (Yong et al., 2011).

8. Special coronary lesion subset: chronic total occlusion and bifurcations

8.1 QCA in chronic total occlusion

Chronic total occlusions (CTOs) of the coronary arteries are one of the most technically challenging lesion subsets for interventional cardiologists due to the most significant difficulty in crossing the lesion with guidewire compared with other lesions subset (Di Mario et al., 2007). This might be considered a failure of conventional 2D-angiography to properly represent stump morphology and true lesion geometry (Safian et al., 1988; Kinoshita et al., 1995). Moreover CTOs are often long lesions length, with severe calcifications and tortuosity (Di Mario et al., 2007), therefore the evaluation of these complex geometric factors is difficult with conventional 2D angiography, often leading to misjudgement of the potential and proper method of treatment (Herrington et al., 1993b).

Recently, Dvir and colleagues evaluated real-time 3D reconstruction of CTOs with CardiOp-B system in a series of 58 patients (61 CTOs) (Dvir et al., 2008). Authors reported a 3D reconstruction success rate of 83% with improved visualization of stump area and/or missing segment. Importantly, in 92% of the successful 3D reconstructions, the artery path in the lesion area could be delineated and in 95% of cases, in which post-stenting 3D reconstruction performed, the vessel path was similar to the lesion path suggested before stenting. Interestingly, the mean stenosis area was significantly smaller in the 3D reconstructions vs. 2D images ($94.6 \pm 5.1\%$ vs. $99.6 \pm 0.3\%$, $P < 0.001$) and the mean lesion length was significantly shorter (15.3 ± 7.4 mm vs. 20.9 ± 8 mm, $P < 0.001$). A possible explanation proposed by the Authors was that in these highly complex lesions, where lesion path was not visible, the 2D measurements were severely inaccurate. Thus 3D reconstructions may be considered as a useful tool in CTO procedures to improve assessment of CTO lesions characteristics (Dvir et al., 2008).

8.2 Bifurcations

With the expanding practice of stenting coronary bifurcation lesions worldwide, the need for reliable, standardized and reproducible quantitative bifurcation analyses became apparent. A fundamental challenge in assessing bifurcations using quantitative methods is in acquiring the entire bifurcation lesion without significant foreshortening or vessel and side branch overlap. While current QCA standards require a minimum of two orthogonal views more than 30° apart, optimal visualization of the bifurcation lesion (parent vessel and side branch) is typically available in one best single view. When QCA is applied using a standard operating procedure, i.e. by including in the analyzed segment the proximal main vessel (PMV) and distal main vessel (DMV), the RVD function takes an average of the “normal” segments of the proximal and distal vessel. Tapering, however, causes the proximal RD and thus the percentage diameter reduction of lesions proximal to the bifurcation to be underestimated, while the distal RD and %DS of lesions distal to the bifurcation will be overestimated. If on-line QCA is used for guidance during a procedure, this can lead to inappropriate balloon selection, with significant under sizing of balloons used for dilatation of the proximal segment and equally, over sizing of balloons used for the distal segment of the main vessel (MV). The operator must manually redraw the proximal segment within the MV and is forced to tediously correct for the contours of the lesion, a possible source of inaccuracy and subjectivity. Even with optimal angiographic views, the main issues of conventional QCA in the analysis of bifurcation lesions are: defining the true reference vessel size of both the parent vessel and its side branch; the assessment of side-branch (SB) stenoses when truly ostial. In the non-diseased state, the RD of the main vessel is reduced from proximal to distal relative to the side branch. It has been shown that the change in RD of the main vessel across the side branch is a function of the size of the PMV, the DMV and that of the SB. Murray was the first to describe the mother/daughter-vessel relations in vascular bifurcations, in terms of a cost function: i.e., the sum of function power loss and metabolic power dissipation proportional to blood flow. Murray described the optimal conditions for vascular bifurcation, known as Murray’s law, which states that the cube of the radius of the mother vessel equals the sum of the cubes of the radii of the daughter vessels: $D_m^3 = D_{d1}^3 + D_{d2}^3$ (Murray, 1926). Afterwards, a simplified equation relating the size of the proximal and distal main vessel and the side branch, in the non-diseased state, has been described by a constant [$D_1 = 0.687 (D_2 + D_3 + \dots)$] (Kassab, 2006; Kamiya & Takahashi, 2007) such that the reference size of any one segment can always be derived if the two other segment sizes are known (Finet et al., 2007). Standard QCA algorithms are designed to detect vessel contours assuming minimal vessel tapering; thus, the reference vessel dimensions are inherently inaccurate when applied to bifurcation lesions. Several techniques have been used to attempt to overcome this limitation but remain problematic (Lansky et al., 2009).

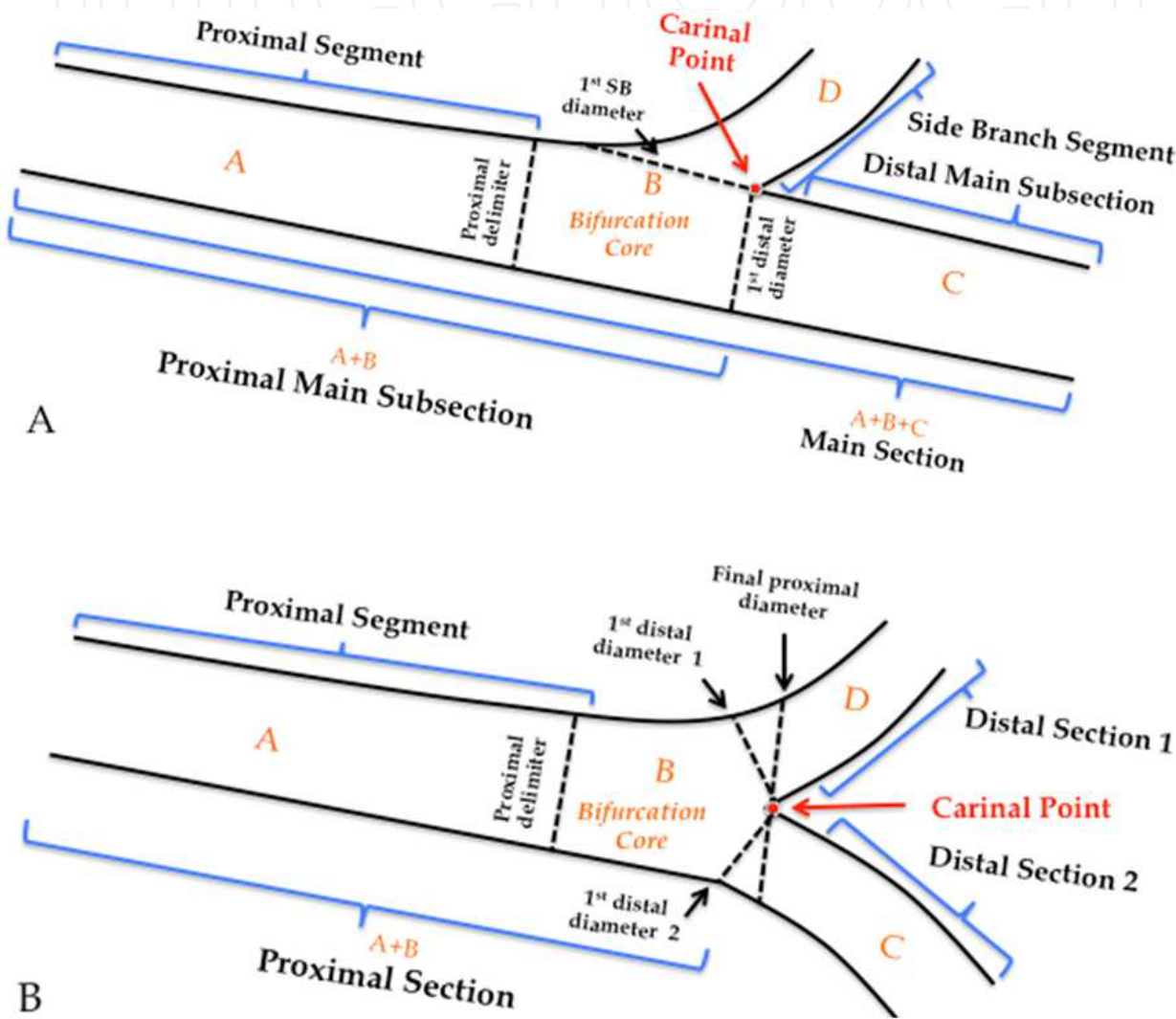
8.2.1 Dedicated bifurcation QCA algorithms

Currently two dedicated bifurcation QCA software packages are commercially available (Medis medical imaging systems, Leiden and The Netherlands and Pie Medical, Maastricht, The Netherlands). The main issue for the application of QCA in bifurcating segments include:

- minimal user interaction in the selection and processing of the coronary segments to be analysed;

- minimal editing of the automatically determined results;
- short analysis time;
- providing highly accurate and precise results, with small systematic and random errors
- providing suitable reporting and data exchange mechanisms.

The Medis medical imaging systems. This system contains two bifurcation models: a T-shape bifurcation model (suitable for bifurcations with a standard side branch structure) (Figure 5 A) and a Y-shape bifurcation model (suitable for bifurcations with distal branches of equal size) (Figure 5 B).



(Adapted from Tuinenburg et al., 2011).

Fig. 5. T-shape model (A) and Y-shape model (B) showing the segments, proximal delimiter, and sections terminology. For each model, the segment generated four segments that represent the building blocks of the models. A) Using the T-shape model, the arterial and reference diameters of the ostium of the side branch and the whole main section (including the transition within the bifurcation core) can be accurately determined. B) Using the Y-shape model, the arterial and reference diameters up to the carinal point and in the distal 1 and 2 sections can be determined accurately.

The particular advantage of these models is that they combine the proximal and two distal vessel segments with the bifurcation core, resulting in a total of two or three sections, all derived from one analysis procedure, such that each of these sections has its own diameter function and associated parameter data.

- Step 1. *Contour detection*. Three path-line points have to be selected to define the arterial bifurcation segment: a start point in the proximal parent vessel (PV), and end points in the distal PV and the SB. From these points, two pathlines are constructed followed by the automated detection of the arterial contours of all three vessel segments using an algorithm.
- Step 2. *Lesions analysis*. The bifurcation core is defined automatically as the area between the first diameter of the distal PV segment, and the interpolated contour between the proximal and distal PV segments.

In the T Bifurcation model, the proximal and distal PV and core segments are combined to define the first section and the SB segment forms the second section. For the entire PV section the arterial diameter function is calculated following the conventional Medis straight analysis approach, while for the SB section the Medis ostial analysis approach is followed.

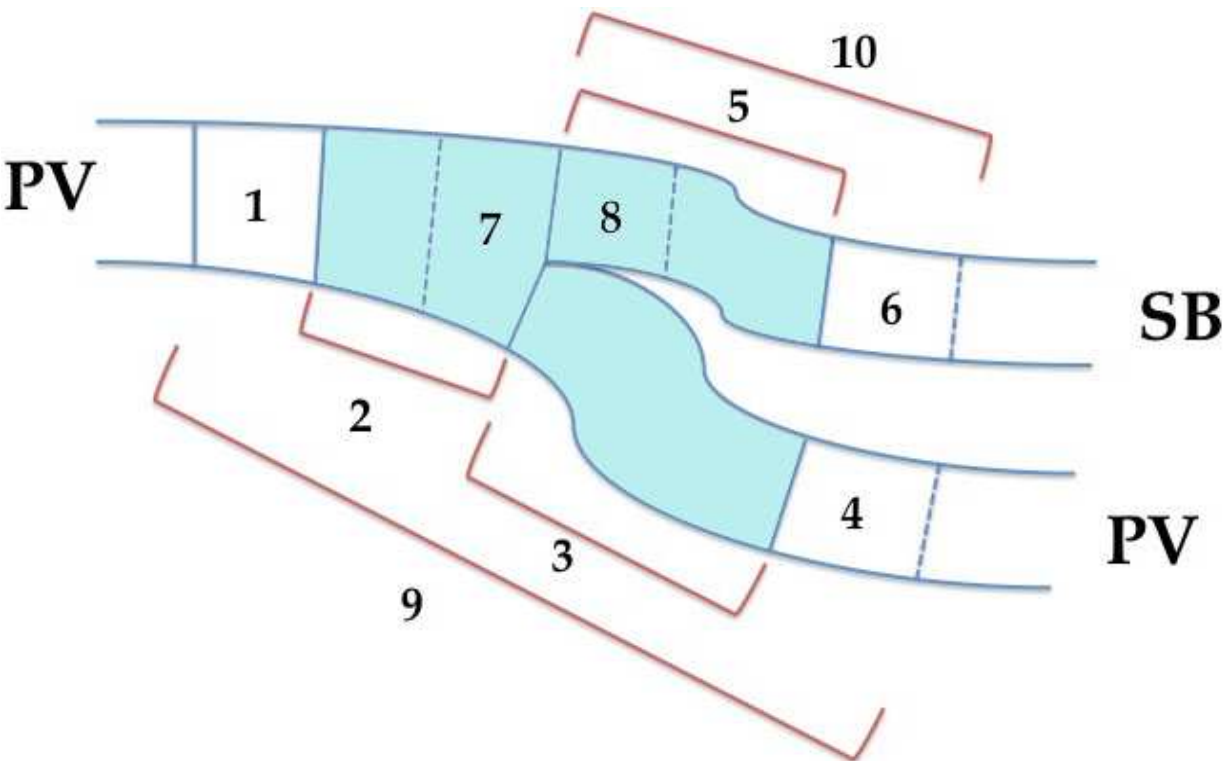
For the Y bifurcation model, the core segment is defined as the area between the automatically determined proximal boundaries of the proximal segment and the carinal point. Excluding the core segment, three sections are defined with each arterial diameter functions calculated using the conventional straight analysis approach.

- Step 3. *Result reporting*. The results of the bifurcation analysis are reported individually for the proximal segment (combining the proximal PV and core segments), the distal PV segment, the SB segment, and the “combined lesion” results (combined proximal, core, and distal PV). Conventional angiographic parameters will be reported including the obstruction, reference, minimum, maximum, and mean diameters and areas, the percent diameter and area stenosis, as well as the vessel and lesion lengths.

The Pie Medical Analysis Principles: CAAS 5 QCA bifurcation methodology. In this system the bifurcated vessel is considered to be a single entity, including the central bifurcation area divided in 10 segments when stented (Ramcharitar S, 2008) (Figure 6).

In this analysis, the segments 1, 4 and 6 are 5 mm beyond the stent edge. The main vessel stent is divided at the carina as that proximal and distal corresponding to segments 2 and 3 respectively, with the side branch stent confined to segment 5. The central portion, segment 7 is an independent region called the Polygon of Confluence (POC) that is unique to the bifurcation and represents a new quantification modality. Segment 8 is an ostial region of side branch including 5 mm distal from the end of bifurcation. The CAAS 5 quantitative analysis of bifurcations can be summarized in six steps:

1. *Contour detection*, that is performed in a semi-automated process employing either manually drawn initial pathline, or three user-defined points (one at the proximal side of the main vessel and two at both distal ends of the bifurcated branches). The algorithm automatically calculates path lines and the contours. The software assumes the bifurcated vessel is a single object delineated by a left, middle and right contour, specifically making no further assumptions.



- | | |
|-----------------------------|--------------------------------------|
| 1 – Proximal Edge (5 mm) | 6 – Distal Edge Side (5 mm) |
| 2 – Proximal Main Stent | 7 – Polygon of Confluence |
| 3 – Distal Main Stent | 8 – Ostium of the Side Branch (5 mm) |
| 4 – Distal Edge Main (5 mm) | 9 – MV Stent + Edges |
| 5 – Side Branch Stent | 10 – SB Stent + Distal Edge |

Fig. 6. The 10 segments used in CAAS (Adapted from Ramcharitar et al., 2008b)

2. *Construction of the centreline and defining the Point of Bifurcation (POB).* The Point of Bifurcation (POB) is defined as the point where all the centrelines meet; the centrelines being the lines through the middle of the vessel. The POB is defined as the midpoint of the largest circle that can be fitted in the bifurcation area, touching all three contours. The intersections between this circle and the centrelines identify the start and end positions of the bifurcation region the boundaries of a new measurement entity the POC (Figure 7).
3. *Defining the POC.* The POC represents the smallest possible independent region that behaves differently from a single vessel segment. It is defined on the 2D radiographic image as the area or region that encompasses the start and the end of the bifurcation region. Regions outside of the POC behave similar to single vessels in classic QCA. The polygon shape is created by connecting begin and end boundaries of the POC by the luminal borders of the vessel. Depending on the type of bifurcation it can have different shapes, such as a pentagon. The plaque area can be evaluated against the actual luminal area or volume to give the percentage area or volume stenosis as a single value for the POC after reconstruction the vessel to its healthy situation. Furthermore the absolute POC area can be compared between pre-, post- and follow-up in clinical studies as a measure for procedural success (Figure 7).

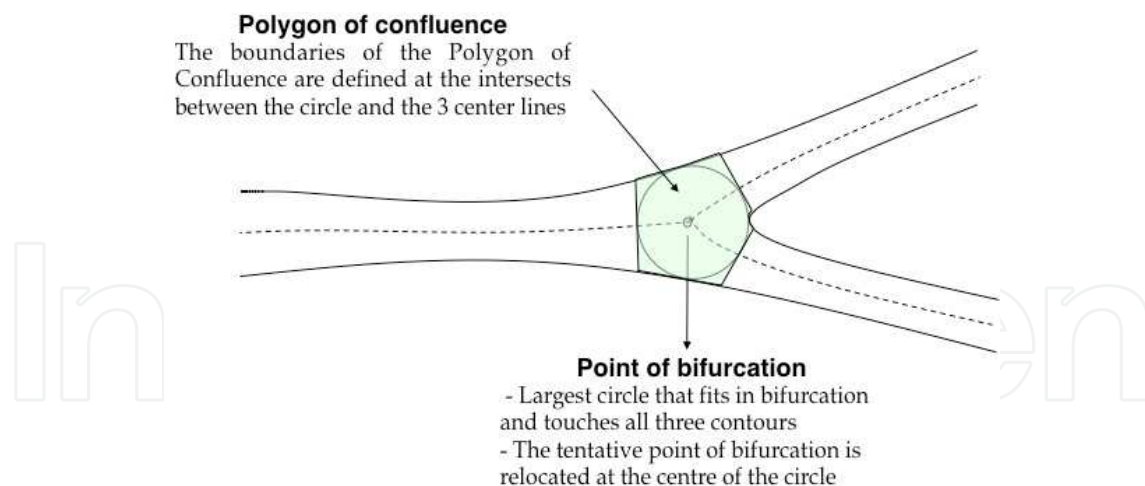


Fig. 7. Polygon of confluence and point of bifurcation in CAAS system (Adapted from Ramcharitar, 2008b)

4. *Determination diameter and reference values within the bifurcation.* Traditional diameter measurements can also be obtained. However, unlike the branches where the diameter measurements are determined by the distance between left and right border, it is not straightforward inside the POC. In order to derive such data within the POC the "Minimum Freedom" approach must be employed. In this approach shortest distances between a centreline point and the boundaries are determined, and the distance between these points used as best estimate for the diameter within the POC for that location along the centreline. The MLD at the bifurcation can be found using this approach by walking through points along the termini of the bifurcation to the centre point within the polygon of confluence. The reference diameter outside the POC is determined from the edges of the 'healthy' part of the vessel. It is based only on the characteristics of the branch itself as in the CAAS single vessel software.
5. *Determining the bifurcation angulation.* For the calculation of the angles between the arterial branches, a method that employs lines derived from the circle used for the definition of the "POC" can be used. The intersection positions of the circle with the centrelines are used as the centres for new circles. These new circles have the same radius as the circle within the "POC" and are not dependent on the mean vessel diameter of the specific branch.
6. *Report.* Different versions of the bifurcation analysis software are available for clinical and core lab use. Available analysis methods include automatic reference obstruction analysis, local reference analysis, user defined subsegments as well as the 10 segmental analysis method to analyse the stented bifurcations, post-procedure and at follow-up.

8.2.2 3D QCA in bifurcation

3D-QCA analysis is able to follow the complex arterial curvilinear structure of the bifurcation and to select the most appropriate view to avoid foreshortening in the region of interest. 3D-QCA, as compared to conventional two-dimensional QCA, allows a more appropriate imaging of bifurcation geometry, with chance of an online assessment of the bifurcation and deviation angle values, which may help the operator to choose the best strategy to approach each lesion (Galassi et al., 2010). Although there are multiple software

programs dedicated for 3-dimensional QCA, only two software packages are dedicated for bifurcation analysis: The CardiOp-B system (Dvir et al., 2007; Galassi et al., 2010) and the recent CAAS 5 QCA 3D bifurcation software (Onuma et al., 2011). CAAS 3-D QCA, while following the already described algorithm based on vessel size adjusted vectors, calculates BA values in 3-D space without overlap, therefore theoretically more precisely than 2-D QCA. On the other hand, in CardiOp-B angle values were computed between the weighted vectors of direction of the respective vessel segments. The weighted vector is calculated as the sum of two vectors, each of them connecting the bifurcation point with distal points along the vessel centre line, distant by 5 mm and 10 mm, respectively. This algorithm was employed in a recent substudy of the SYNTAX trial, the first ever to describe the 3-D angulation of the left main before and after intervention and its impact on 1-year clinical outcome (Girasis et al., 2010a). When it comes to the quantification of stenosis, CardiOp-B provides diameter-derived and cross-sectional (densitometric) data together with the lesion length; lesion markers can be manipulated, in order to relocate the region of interest across the main vessel or from the PMV into the SB. (Figure 8)

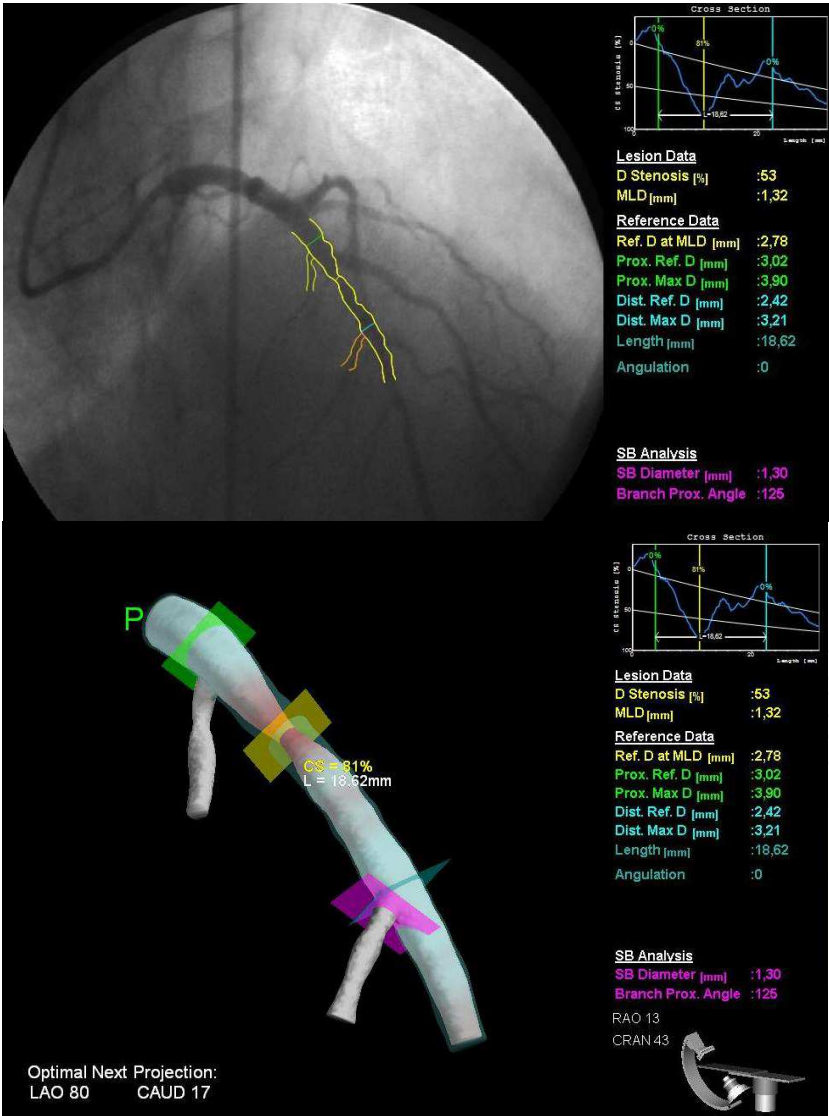


Fig. 8. An example of coronary bifurcation lesion reconstructed with 3D- CardiOp-B software.

In CAAS 5, a 3-D model of the central bifurcation area is constructed taking into account the fact that the contour information obtained from the 2-D projections may contain vessel overlap, since the bifurcated vessel might be partly obscured in at least one of the projections. To overcome this problem the 3-D cross-section shape is created using virtual vessel contours by virtue of information derived outside the bifurcation region (Onuma, 2011).

Cross-sectional area values are calculated on the assumption that the vessel has an elliptical cross section based on the luminal diameters from the two different 2-D projections; this elliptical cross-section is the primary measured parameter. The equivalent luminal diameter, minimum luminal diameter and maximal luminal diameter curves are calculated based on a circularity assumption. Reference vessel lines, up to the entrance of the POC and within the POC, are based on the 2-D approach adapted to 3-D.

So far, there is not direct comparison between these two QCA bifurcation software packages, both of which reconstruct from two projections, thus the issue of overlapping vessels in tortuous bifurcation lesions may still be a problem. Particularly, there are two special challenging situations in QCA analysis: a diffusely diseased bifurcation region with no apparent healthy reference and an ostial stenosis in a short left main trunk (Girasis, 2010 b). Based on the scaling laws of Murray (Murray, 1926) and Finet (Finet, 2007), the size of any bifurcation vessel segment could be determined, if the reference of the other two vessel segments is known. This is not the case in a diffusely diseased bifurcation region; however, extrapolation of the reference of the PMV even on the basis of less accurate RVD values for the DMV and SB could avoid a gross underestimation of the PMV true size (Girasis, 2010 b).

In the case of an ostial stenosis in a short left main stem, both contour detection and sizing could be challenging. Manual contour corrections would not be unreasonable, especially if there is overlap with the angiographic catheter. For the RVD determination, either a user-defined reference outside the obstructions boundaries but within the left main, or a value back-calculated from the distal branches reference values can be chosen (Girasis, 2010 b).

Although 3-D new techniques allow more extensive analyses for coronary bifurcations, there are several limitations such as reproducibility, accuracy and standard reference values for special lesion subsets that need further studies.

9. Conclusion


Although QCA was born more than 20 years ago and still burden well established limitations, it remains a useful tool in clinical research, whereas its role in clinical practice is mainly complementary to standard coronary angiography and other imaging techniques, such as computed tomography (CT), intravascular ultrasound (IVUS), virtual histology and optical coherence tomography. In recent years QCA has advanced to provide more accurate measurements and descriptions of the coronary vascular tree and still continues to evolve as 3D coronary angiographic techniques provide more detailed descriptions of complex lesions such as bifurcations, eccentric lesions and chronic total occlusions. However standard values in these lesions will need to be determined and validated.

10. References

- Agostoni, P.; Biondi-Zoccai, G. & Van Langenhove, G. (2008). Comparison of assessment of native coronary arteries by standard versus three-dimensional coronary angiography. *Am J Cardiol* 102:272-279.
- Bartunek, J.; Sys, S.U. & Heyndrickx, G.R.; (1995). Quantitative coronary angiography in predicting functional significance of stenoses in an unselected patient cohort. *J Am Coll Cardiol* 26:328-334.
- Di Mario, C.; Werner, G.S. & Sianos, G. On behalf of the Euro CTO Club (2007). European perspective in the recanalization of Chronic Total Occlusion (CTO): consensus document from the Euro CTO Club. *Eurointerv* 3:30-43.
- Dvir, D.; Marom, H. & Guetta, V. (2005). Three-dimensional coronary reconstruction from routine single plane coronary angiograms: in vivo quantitative validation. *Int J Cardiovasc Intervent* 7:141-145.
- Dvir, D.; Marom, H. & Assali, A. (2007). Bifurcation lesions in the coronary arteries: early experience with a novel 3-dimensional imaging and quantitative analysis before and after stenting. *EuroIntervention* 3:95-9.
- Dvir, D.; Assali, A. & Kornowski, R. (2008). Percutaneous coronary intervention for chronic total occlusion: novel 3-dimensional imaging and quantitative analysis. *Catheter Cardiovasc Interv* 71:784-789.
- Fleming, R.M.; Kirkeeide, R.L. & Smalling, R.W. (1991). Patterns in visual interpretation of coronary arteriograms as detected by quantitative coronary arteriography. *J Am Coll Cardiol* 18:945-951.
- Finet, G.G.M.; Perrenot, B. & Rioufol, G. (2007). Fractal geometry of arterial coronary bifurcations. A quantitative coronary angiography and intravascular ultrasound analysis. *EuroInterv* 3:490-498.
- Fischer, J.J.; Samady, H. & McPherson, J.A. (2002). Comparison between visual assessment and quantitative angiography versus fractional flow reserve for native coronary narrowings of moderate severity. *Am J Cardiol* 90:210-215.
- Galassi, A.R.; Tomasello, S.D. & Capodanno, D. (2010). A novel 3-d reconstruction system for the assessment of bifurcation lesions treated by the mini-crush technique. *J Interv Cardiol* 23:46-53.
- Garrone, P.; Biondi-Zoccai, G. & Salvetti, I. (2009). Quantitative coronary angiography in the current era: principles and applications. *J Interv Cardiol* 22:527-536.
- Gensini, G.G.; Kelly, A.E. & DaCosta, B.C.B. (1971). Quantitative angiography: The measurement of coronary vasomobility in the intact animal and man. *Chest* 60:522-530.
- Girasis, C.; Serruys, P.W. & Onuma, Y. (2010a). 3-Dimensional Bifurcation Angle Analysis in Patients With Left Main Disease A Substudy of the SYNTAX Trial (SYNergy Between Percutaneous Coronary Intervention With TAXus and Cardiac Surgery). *JACC Cardiovasc Interv* 3:41-48.
- Girasis, C.; van Jeuns, R.J. & Onuma, Y. (2010b). Essentials of quantitative angiography for bifurcation lesions. *Eurointervention Supplement Vol. 6 (Supplement J)* J36-J43.
- Glagov, S.; Weisenberg, E. & Zarins, C.K. (1987). Compensatory enlargement of human atherosclerotic coronary arteries. *N Engl J Med* 316:1371-1375.

- Gradaus, R.; Mathies, K.; Breithardt G, Bocker D (2006). Clinical assessment of a new real time 3D quantitative coronary angiography system: evaluation in stented vessel segments. *Catheter Cardiovasc Interv* 68:44–49.
- Hausleiter, J.; Jost, S. & Nolte, C.W. (1997). Comparative in vitro validation of eight first- and second-generation quantitative coronary angiography systems. *Coron Artery Dis* 8:83–90.
- Herrington, D.M.; Siebes, M. & Walford, G.D. (1993a). Sources of error in quantitative coronary angiography. *Cathet Cardiovasc Diagn* 29:314–321.
- Herrington, D.M.; Siebes, M. & Sokol, D.K. (1993b). Variability in measures of coronary lumen dimensions using quantitative coronary angiography. *J Am Coll Cardiol* 22:1068–1074.
- Kalbfleisch, S.J.; McGillem, M.J. & Pinto, I.M. (1990). Comparison of automated quantitative coronary angiography with caliper measurements of percent diameter stenosis. *Am J Cardiol* 65:1181–1184.
- Kamiya, A. & Takahashi, T. (2007). Quantitative assessments of morphological and functional properties of biological trees based on their fractal nature. *J Appl Physiol* 102:2315–2323.
- Kassab, G.S. (2006). Scaling laws of vascular trees: Of form and function. *Am J Physiol Heart Circ Physiol* 290:894–903.
- Kinoshita, I.; Katoh, O. & Nariyama, J. (1995). Coronary angioplasty of chronic total occlusions with bridging collateral vessels: Immediate and follow-up outcome from a large single center experience. *J Am Coll Cardiol* 26:409–415.
- Lansky, A.; Tuinenburg, J. & Costa, M. (2009). European Bifurcation Angiographic Sub-Committee. Quantitative Angiographic Methods for Bifurcation Lesions: A Consensus Statement from the European Bifurcation Group. *Catheter Cardiovasc Interv* 73:258–266.
- Mancini, G.B.; Simon, S.B.; & McGillem, M.J. (1987). Automated quantitative coronary arteriography: morphologic and physiologic validation in vivo of a rapid digital angiographic method. *Circulation* 75:452–460.
- Meerkin, D.; Marom, H. & Cohen-Biton, O. (2010). Three-dimensional vessel analyses provide more accurate length estimations than the gold standard QCA. *J Interv Cardiol* 23:152–159.
- Murray, C.D. (1926) The physiological principle of minimum work. I. The vascular system and the cost of blood volume. *Proc. Natl Acad. Sci. USA* 12:207–214.
- Ng, V.G. & Lansky, A.J (2011). Novel QCA methodologies and angiographic scores. *Int J Cardiovasc Imaging* 27:157–165.
- Onuma, Y.; Girasis, C. & Aben, J.P. (2011). A novel dedicated 3-dimensional quantitative coronary analysis methodology for bifurcation lesions. *Eurointervention* [Ahead of Print].
- Ramcharitar, S.; Daeman, J. & Patterson, M. (2008a). First direct in vivo comparison of two commercially available three-dimensional quantitative coronary angiography systems. *Catheter Cardiovasc Interv* 71:44–50.
- Ramcharitar, S.; Onuma, Y. & Aben, J.P. (2008b). A novel dedicated qualitative coronary analysis methodology for bifurcation lesions. *Eurointervention* 3:553–557.

- Reiber, J.H.; Serruys, P.W. & Kooijman, C.J. (1985). Assessment of short-, medium-, and long-term variations in arterial dimensions from computer-assisted quantitation of coronary cineangiograms. *Circulation* 71:280–288.
- Saad, M.; Toelg, R. & Khattab, A.A. (2009). Determination of haemodynamic significance of intermediate coronary lesions using three-dimensional coronary reconstruction. *Eurointervention* 5:573–579.
- Safian, R.D.; McCabe C.H. & Sipperly, M.E. (1988). Initial success and long-term follow-up of percutaneous transluminal coronary angioplasty in chronic total occlusions versus conventional stenoses. *Am J Cardiol* 61:23G–28G.
- Schuurbiers, J.C.; Lopez, N.G. & Ligthart, J. (2009). In vivo validation of CAAS QCA-3D coronary reconstruction using fusion of angiography and intravascular ultrasound (ANGUS). *Catheter Cardiovasc Interv* 73:620–626.
- Spahn, M.; Heer, V. & Freytag, R. (2003). Flat-panel detectors in X-ray systems. *Radiologe* 43:340–350.
- Serruys, P.W.; Reiber, J.H.C. & Wijns, W (1984). Assessment of percutaneous transluminal coronary angioplasty by quantitative coronary angiography: Diameter versus densitometric area measurements. *Am J Cardiol* 54:482–488.
- Spears, J.R.; Sandor, T. & Als, A.V. (1983). Computerized image analysis for quantitative measurement of vessel diameter from cineangiograms. *Circulation* 68:453–461.
- Topol, E.J. & Nissen, S.E. (1995). Our preoccupation with coronary luminology. The dissociation between clinical and angiographic findings in ischemic heart disease. *Circulation* 92:2333–2342.
- Tsuchida, K.; van der Giessen, W.J. & Patterson M (2007) In vivo validation of a novel three-dimensional quantitative coronary angiography system (CardiOp-B): comparison with a conventional two-dimensional system (CAAS II) and with special reference to optical coherence tomography. *EuroIntervention* 3:100–108.
- Tu, S.; Koning, G. & Jukema, W. (2010). Assessment of obstruction length and optimal viewing angle from biplane X-ray angiograms. *Int J Cardiovasc Imaging* 26:5–17.
- Tuinenburg, J.C.; Koning, G. & Seppenwoolde, Y. (2006). Is there an effect of flat-panel-based imaging systems on quantitative coronary and vascular angiography? *Catheter Cardiovasc Interv* 68:561–566.
- Tuinenburg, J.C.; Koning, G. & Rares, A. (2011). Dedicated bifurcation analysis: basic principles. *Int J Cardiovasc Imaging* 27:167–74.
- Van der Zwet, P.M. & Reiber, J.H. (1994) A new approach for the quantification of complex lesion morphology: the gradient field transform; basic principles and validation results. *J Am Coll Cardiol* 24:216–224.
- Van Herck, P.L.; Gavit, L. & Gorissen, P. (2004). Quantitative coronary arteriography on digital flat-panel system. *Catheter Cardiovasc Interv* 63:192–200.
- Wellnhofer, E.; Wahle, A. & Mugaragu, I. (1999). Validation of an accurate method for three-dimensional reconstruction and quantitative assessment of volumes, lengths and diameters of coronary vascular branches and segments from biplane angiographic projections. *Int J Card Imaging* 15:339–353 discussion 355–356.
- Yong, A.S.; Ng, A.C. & Brieger, D. (2011). Three-dimensional and two-dimensional quantitative coronary angiography, and their prediction of reduced fractional flow reserve. *Eur Heart J* 32:345–53.



Advances in the Diagnosis of Coronary Atherosclerosis

Edited by Prof. Suna Kirac

ISBN 978-953-307-286-9

Hard cover, 378 pages

Publisher InTech

Published online 09, November, 2011

Published in print edition November, 2011

Coronary artery disease (CAD) and its consequences are most important morbidity and mortality reasons in the developed and developing countries. To prevent hard end-points, early definitive diagnosis and optimum therapy play significant role. Novel advanced diagnostic tests which are biomarkers of inflammation, cell adhesion, cell activation and imaging techniques provide to get the best result in the detection and characterization of calcified or uncalcified atherosclerotic plaques. In spite of last developments in the imaging methods, coronary catheterization is still frequently performed. Following the first cardiac catheterization performed in 1844, date by date historical developments and the mechanics of cardiac catheterization techniques, risks associated with coronary angiography, and also, preventions and treatments of possible complications have been presented in this book. Other important issue is radiation exposure of patients and staff during coronary angiography and scintigraphy. Radiation dose reduction techniques, general radiation protection principles have been discussed in related chapters.

How to reference

In order to correctly reference this scholarly work, feel free to copy and paste the following:

Salvatore Davide Tomasello, Luca Costanzo and Alfredo Ruggero Galassi (2011). Quantitative Coronary Angiography in the Interventional Cardiology, *Advances in the Diagnosis of Coronary Atherosclerosis*, Prof. Suna Kirac (Ed.), ISBN: 978-953-307-286-9, InTech, Available from:
<http://www.intechopen.com/books/advances-in-the-diagnosis-of-coronary-atherosclerosis/quantitative-coronary-angiography-in-the-interventional-cardiology>

INTECH
open science | open minds

InTech Europe

University Campus STeP Ri
Slavka Krautzeka 83/A
51000 Rijeka, Croatia
Phone: +385 (51) 770 447
Fax: +385 (51) 686 166
www.intechopen.com

InTech China

Unit 405, Office Block, Hotel Equatorial Shanghai
No.65, Yan An Road (West), Shanghai, 200040, China
中国上海市延安西路65号上海国际贵都大饭店办公楼405单元
Phone: +86-21-62489820
Fax: +86-21-62489821

© 2011 The Author(s). Licensee IntechOpen. This is an open access article distributed under the terms of the [Creative Commons Attribution 3.0 License](https://creativecommons.org/licenses/by/3.0/), which permits unrestricted use, distribution, and reproduction in any medium, provided the original work is properly cited.

IntechOpen

IntechOpen