

We are IntechOpen, the world's leading publisher of Open Access books Built by scientists, for scientists

6,900

Open access books available

186,000

International authors and editors

200M

Downloads

Our authors are among the

154

Countries delivered to

TOP 1%

most cited scientists

12.2%

Contributors from top 500 universities



WEB OF SCIENCE™

Selection of our books indexed in the Book Citation Index
in Web of Science™ Core Collection (BKCI)

Interested in publishing with us?
Contact book.department@intechopen.com

Numbers displayed above are based on latest data collected.
For more information visit www.intechopen.com



Autoimmunity in the Mediation of Granulomatous Amoebic Encephalitis: Implications for Therapy

Chandirasegaran Massilamany and Jay Reddy
 University of Nebraska-Lincoln
 School of Veterinary Medicine and Biomedical Sciences
 USA

1. Introduction

Acanthamoeba spp. are free-living amoebae that are ubiquitous in the environment. Most healthy individuals carry *Acanthamoeba*-reactive antibodies, suggesting constant exposure to amoebae. In spite of the high prevalence of the amoebae, the incidence of diseases caused by *Acanthamoeba* is very low. Non-opportunisticly, *Acanthamoebae* can induce keratitis in healthy humans, but as an opportunistic pathogen, the amoebae can cause fatal encephalitis especially in immunocompromised individuals and treatments are often ineffective.

Amoebic encephalitis is a life-threatening disease of the central nervous system (CNS) caused by free-living amoebae belonging to the genera *Acanthamoeba*, *Balamuthia* and *Naegleria*. Because they lack host-specificity, the ubiquitous amoebae can infect a wide range of species (Marciano-Cabral & Cabral, 2003, Schuster & Visvesvara, 2004). The diseases caused by *Acanthamoeba* spp. and *Balamuthia* spp. are generally termed "granulomatous amoebic encephalitis" (GAE), whereas those caused by *Naegleria* spp. are called 'primary amoebic meningioencephalitis (PAM)' (Marciano-Cabral & Cabral, 2003, Schuster & Visvesvara, 2004, Khan, 2006, da Rocha-Azevedo, *et al.*, 2009). While *Acanthamoebae* induce illness mostly in immunocompromised individuals, *Balamuthia* spp. and *Naegleria* spp. can cause diseases in both immune-sufficient and immune-deficient individuals (Martinez & Visvesvara, 2001, Marciano-Cabral & Cabral, 2003, Schuster & Visvesvara, 2004, Khan, 2006, da Rocha-Azevedo, *et al.*, 2009). Nevertheless, all of them can induce keratitis in healthy individuals, often in contact lens-wearers (Jones, *et al.*, 1975, Martinez & Visvesvara, 1997, Marciano-Cabral & Cabral, 2003, da Rocha-Azevedo, *et al.*, 2009). We recently discovered that *A. castellanii* contains mimicry sequence for immunodominant epitope of CNS myelin proteolipid protein (PLP), suggesting that exposure to *A. castellanii* can lead to the generation of autoimmune responses by antigenic mimicry. In this review, we discuss our understanding of the pathophysiology of *Acanthamoeba*-induced encephalitis, with a special emphasis on autoimmunity in mediation of the disease, and implications for therapy.

2. Characteristics of *Acanthamoeba* infections

Based on morphological characteristics, such as shape and size of amoebic cysts, and growth conditions, the genus *Acanthamoeba* was initially classified into groups I, II, and III,

containing 4, 11, and 5 species, respectively (De Jonckheere, 1987). Recently, reclassification was made to group various species into 15 genotypes (T1 to T15) based on 18S rRNA gene sequences, which can distinguish different genotypes showing a variation of as low as 5% (Gast, *et al.*, 1996, Schuster & Visvesvara, 2004). The genotypes T1, T4, T10, and T12 generally cause encephalitis, and *A. castellanii* and *A. polyphaga* that belong to T4 genotype are most frequently implicated as causes of GAE (Garate, *et al.*, 2006). The current trend is to classify *Acanthamoebae* based on genotype rather than morphology.

2.1 Geographical distribution

Epidemiologically, no clear disease associations have been found with respect to race, gender, and geographical location, except that the disease has not been reported in Africa, an observation attributed mostly to lack of familiarity and diagnostic tools (Tan, *et al.*, 1993, Barker, *et al.*, 1995, Marciano-Cabral & Cabral, 2003). However, serological evidence suggests that Hispanics are 14.5 times less likely to carry *Acanthamoeba*-reactive antibodies than individuals of other ethnicities (Chappell, *et al.*, 2001, Khan, 2006). A study undertaken to measure the seroprevalence of *Acanthamoeba* in different ethnic groups indicated that up to 90 % of healthy humans can carry *Acanthamoeba* antibodies. Seropositivity occurred in the order of Caucasians, followed by Hispanics and African Americans (Chappell, *et al.*, 2001). But it is unknown whether the occurrence of amoebic encephalitis follows a similar pattern in the general population.

2.2 Host distribution and susceptibility

The amoeba has a two-stage life-cycle: trophozoites (infective and invasive) and cysts (dormant). The life cycle can be completed in either the environment or infected hosts (Chagla & Griffiths, 1974, Marciano-Cabral & Cabral, 2003). Under unfavorable conditions, such as extremes of pH and temperature, trophozoites become cysts that are highly resistant to commonly used disinfectants containing chlorine and the cysts can survive environmental temperatures even upto 80° C (De Jonckheere & van de Voorde, 1976, Khunkitti, *et al.*, 1998, Storey, *et al.*, 2004). *Balamuthia* spp. (e.g., *B. mandrillaris*) can cause GAE in a wide range of species such as horses, baboons, sheeps, dogs, and humans (Martinez & Visvesvara, 2001), but development of clinical disease takes months to years. Likewise, *Acanthamoeba* infections are also reported in humans including domestic and non-domestic species such as dogs, monkeys, kangaroos and buffaloes (Schuster & Visvesvara, 2004). Found ubiquitously, *Acanthamoebae* have been isolated from a variety of sources such as soil; drinking, natural and sea water; hospitals, eye wash stations, and dental irrigation systems; swimming pools; and heating and cooling ducts (Jahnes & Fullmer, 1957, Kingston & Warhurst, 1969, Casemore, 1977, De Jonckheere, 1991, Barbeau & Buhler, 2001, Marciano-Cabral & Cabral, 2003, da Rocha-Azevedo, *et al.*, 2009) and the amoebae generally feed on bacteria, algae, and yeast (Bowers, 1977, Bowers & Olszewski, 1983, Marciano-Cabral & Cabral, 2003, da Rocha-Azevedo, *et al.*, 2009).

Generally, GAE is regarded as a disease of immunocompromised individuals. HIV patients, individuals undergoing immunosuppressive and steroid therapies, and those who have received organ or stem cell transplants are at great risk of developing the disease (Marciano-Cabral, *et al.*, 2000, Seijo Martinez, *et al.*, 2000, Marciano-Cabral & Cabral, 2003, Schuster & Visvesvara, 2004, Khan, 2006, da Rocha-Azevedo, *et al.*, 2009). Other predisposing factors include malignancies and debilitated conditions such as diabetes, chronic alcoholism and

malnutrition (Martinez & Janitschke, 1985, Sell, *et al.*, 1997, Marciano-Cabral & Cabral, 2003, Khan, 2006). Exacerbation of GAE lesions was reported in one patient undergoing treatment for cryoglobulinemia with a monoclonal antibody directed against CD20 which selectively depletes mature B cells (Meersseman, *et al.*, 2007). Likewise, GAE can occur in patients with systemic lupus erythematosus, further emphasizing the importance of a compromised immune system for disease-predisposition (Koide, *et al.*, 1998, Uschuplich, *et al.*, 2004, Cha, *et al.*, 2006). Since amoebic encephalitis is not a reportable disease, and diagnosis is often made postmortem, the number of cases documented in the literature does not reflect actual disease-incidence. One study has reported to have documented upto 500 cases of amoebic encephalitis worldwide (Sarica, *et al.*, 2009). However, the recent availability of PCR-based detection of *Acanthamoeba* is greatly facilitating diagnosis (Schroeder, *et al.*, 2001, Khan, 2006, da Rocha-Azevedo, *et al.*, 2009, Maritschnegg, *et al.*, 2011) and as a result, the number of cases reported in recent years show an increasing trend.

2.3 Importance of *Acanthamoeba* in nosocomial infections

Recently, it is proposed that *Acanthamoebae* might play a role in the increased incidence of nosocomial infections (Michel, *et al.*, 1995, Marciano-Cabral & Cabral, 2003). It is well documented that *Acanthamoebae* act as natural vectors or reservoirs for a variety of microbes, such as *Escherichia coli*, *Klebsiella*, *Bacillus spp.*, *Mycoplasma*, *Legionella pneumophila*, *Mycobacterium avium*, *Mycobacterium leprae*, *Clostridium frigidicarnis*, *Porphyromonas gingivalis*, *Prevotella intermedia*, *Burkholderia pseudomallei*, *Afpia felis*, *Vibrio cholerae*, *Mobiluncus curtissi*, *Campylobacter spp.*, *Helicobacter pylori*, *Cryptococcus neoformans*, *Candida spp.*, *Coxiella burnetti*, *Chlamydia*, *Rickettsia*, and *Coxsackievirus* among others (Marciano-Cabral & Cabral, 2003, Waldner, *et al.*, 2004, Khan, 2006, Mattana, *et al.*, 2006, Thomas, *et al.*, 2009). Bacteria grown in *Acanthamoeba* show resistance to bactericides and biocides; their survival and virulence are enhanced; and they mechanically transport disease-producing agents to various target organs, thus increasing the risk of multiple infections in the affected patients (King, *et al.*, 1988, Barker, *et al.*, 1995, Turner, *et al.*, 2000, Lloyd, *et al.*, 2001, Marciano-Cabral & Cabral, 2003). The amoebae shed waste through vesicles of 2.1 to 6.4 μm diameter, and they can potentially contain pathogenic microbes. For example, *A. polyphaga* can release up to 20 to 200 bacteria per vesicle and the vesicles can become aerosolized leading to their dispersal to wide-range of geographical locations (Rowbotham, 1980, Berk, *et al.*, 1998).

3. Pathogenesis

The amoebae can gain entry into the CNS through two routes: migration via the olfactory neuroepithelium and/or blood (Fig. 1). *Naegleria* spp. tend to follow the former route. After penetrating the nasal mucosa, the amoebae pass through the cribriform plate and travel along the nerve fibers to the olfactory bulb in the cerebrum (Khan, 2007, Elsheikha & Khan). Alternatively, the amoebae that enter through nasal exposure go to the lungs, enter the blood stream, and reach the CNS possibly by disrupting the blood brain barrier (BBB). The hematogenous route also is a choice for amoeba that enter through the skin (Khan, 2007). However, the mechanism by which amoebae actually enter the CNS is not clearly elucidated. Although it is postulated that they enter through the cerebral capillary endothelium or choroid plexus, the former being the more widely accepted mechanism (Khan, 2003, Marciano-Cabral & Cabral, 2003, Khan, 2005b, Khan, 2006, da Rocha-Azevedo,

et al., 2009). These two modes of entry lead to the localization of amoebae in the cerebrum and cerebrospinal fluid (CSF) respectively (Elsheikha & Khan, 2010).

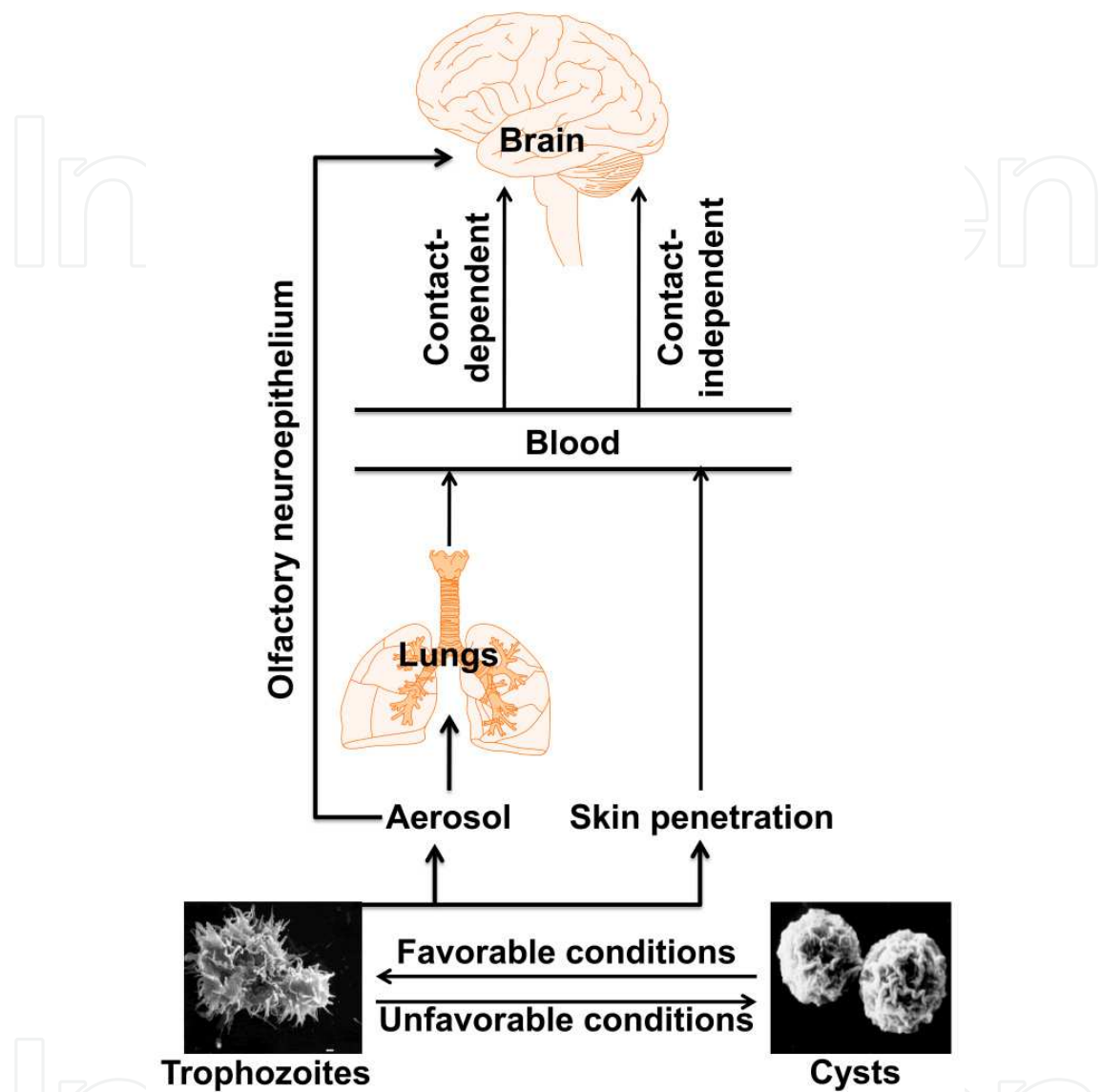


Fig. 1. Proposed routes of entry of *Acanthamoeba* into the CNS. Under favorable conditions, cysts become trophozoites which are the infective stages of *Acanthamoeba*. Upon nasal exposure, trophozoites can reach CNS hematogenously via lungs or through olfactory neuroepithelium. The amoeba that gains entry through the skin can also reach CNS hematogenously. However, actual entry into the brain tissue involves crossing the BBB which appears to be mediated through either contact-dependant mechanisms by inducing apoptosis of the endothelial cells or contact-independent mechanisms via destruction of extracellular matrix by amoebic proteases. The micrographs of *Acanthamoeba* trophozoites and cysts were kindly provided by Dr. Francine Marciano-Cabral, Virginia Commonwealth University, VA, USA

Regardless of route of entry, the amoebae have to cross the BBB, either paracellularly by damaging the tight junctions, or transcellularly, in which the integrity of the BBB is

maintained (Khan, 2003, Khan, 2006, Khan, 2007). Disruption of the BBB is thought to be mediated by contact-dependent or contact-independent mechanisms (Khan, 2003, Khan, 2006, Khan, 2007). Contact-dependent mechanisms require attachment of the amoeba to the brain's microvascular endothelial cells through amoebic mannose-binding protein (mannose-BP) causing apoptosis of the endothelial cells, a phenomenon that depends on the phosphatidylinositol 3-kinase signaling pathway (Sissons, *et al.*, 2005, Khan, 2006, Khan, 2007). In contrast, contact-independent mechanisms involve extracellular proteases secreted by *Acanthamoeba*, particularly serine proteases, and these enzymes destroy extracellular matrix proteins comprised of collagen (type I, III, and IV), elastin, and fibronectin (Khan, *et al.*, 2000, Sissons, *et al.*, 2005, Khan, 2007). Alternatively, infected immune cells, most importantly macrophages, may simply act as Trojan horses to carry the amoebae to the CNS (Khan, 2007).

The pathogenicity of *Acanthamoebae* varies by species, depending on their inherent potential to tolerate temperatures, attachment to cellular surfaces, and induction of cytolysis (Marciano-Cabral & Cabral, 2003, Khan, 2006). The principal virulent factors are mannose-BP, Nicotinamide adenine dinucleotide (NADH)-dehydrogenase, GDP-mannose pyrophosphorylase and proteasomal ATPase (Marciano-Cabral & Cabral, 2003, Han, *et al.*, 2006) and of these, the role of mannose-BP has been well-studied. As noted above, the amoebae use mannose-BP for cellular attachment, and the fact that only the infective stage-trophozoites but not cysts upregulates mannose-BP expression suggests that, this protein is critical for amoebic invasion (Garate, *et al.*, 2006). However, once the infection is established, microglial cells produce inflammatory cytokines, such as tumor necrosis factor (TNF)- α , interleukin (IL)-6, IL-1 β and IL-1 α and they can contribute to tissue damage (Benedetto & Auriault, 2002, Benedetto, *et al.*, 2003, Marciano-Cabral & Cabral, 2003).

4. Immune responses to *Acanthamoeba*

The role of the immune system and immune defense mechanisms in protecting against *Acanthamoeba* has not been well characterized, but protection against amoebae appears to involve both innate and adaptive immune responses. Amoebae are extracellular organisms that lack a sialic acid coat or capsule, making them vulnerable to complement-mediated destruction (Bowers & Korn, 1968, Korn & Olivecrona, 1971, Khan, 2005a). Conversely, amoebae can evade immune mechanisms by binding to a C1q component, as shown in the case of *A. culbertsoni*, and the parasite-derived serine proteases can degrade IgG and IgA (Toney & Marciano-Cabral, 1998, Kong, *et al.*, 2000, Na, *et al.*, 2002, Marciano-Cabral & Cabral, 2003). Neutrophils, macrophages, and microglia can destroy amoebae, and their amoebicidal effects are mediated in part by respiratory burst and nitric oxide under the influence of IL-1 β , IL-1 α , TNF- α and/or IFN- γ (Ferrante, 1991a, Ferrante, 1991b, Marciano-Cabral & Toney, 1998, Marciano-Cabral, *et al.*, 2000, Benedetto & Auriault, 2002a, Benedetto & Auriault, 2002b, Dudley, *et al.*, 2007, Khan, 2008).

Affected patients, including healthy individuals upto 90%, carry the *Acanthamoeba*-reactive antibodies of IgM, IgG, and IgA isotypes with no significant differences between males (86.2%) and females (89.2%), indicating that humans are regularly exposed to *Acanthamoeba* and become sensitized with the amoebic antigens (Chappell, *et al.*, 2001, McClellan, *et al.*, 2002, Schuster, 2002, Khan, 2005a, Brindley, *et al.*, 2009, da Rocha-Azevedo, *et al.*, 2009). It has been reported that T cells from healthy individuals can react to *Acanthamoeba* antigens obtained from CSF and antigen-specific T cell clones capable of producing IFN- γ also have

been derived (Tanaka, *et al.*, 1994). Likewise, peripheral blood mononuclear cells from rheumatoid arthritis patients shows proliferative responses to *A. polyphaga* (Shadidi, *et al.*, 2001). But the significance of these observations is not known. The fact that the individuals exposed to *Acanthamoeba* become seropositive and also carry antigen-specific IFN- γ -secreting cells suggests that the host defenses might involve both antibody- and cell-mediated immune responses but, this aspect requires additional investigations.

4.1 Autoimmunity in the mediation of amoebic encephalitis

In our efforts to identify the disease-inducing microbial mimics for CNS myelin antigens, we recently identified a novel epitope from *A. castellanii* (Fig. 2; Massilamany, *et al.*, 2010, Massilamany, *et al.*, 2011). The epitope termed, ACA 83-95 is derived from rhodanese-related sulfur transferase of *Acanthamoeba*. We tested the disease-inducing ability of ACA 83-95 in the mouse model of experimental autoimmune encephalomyelitis (EAE), which has been traditionally used to study the pathophysiology of multiple sclerosis (MS) in humans (Massilamany, *et al.*, 2010, Massilamany, *et al.*, 2011).

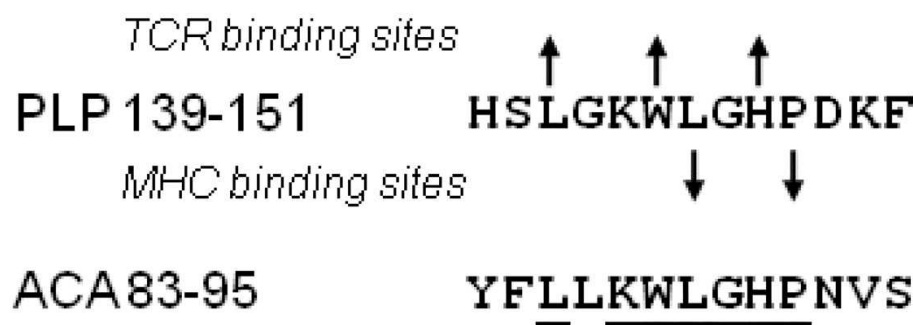


Fig. 2. Comparison of peptide sequences. Peptide sequences of PLP 139-151 and ACA 83-95 are compared. Identical residues are underlined. Top arrows, TCR- contact residues; bottom arrows, MHC-anchor residues (Massilamany, *et al.*, 2010, Massilamany, *et al.*, 2011)

We verified the encephalitogenicity of mimicry epitope in both active immunization and adoptive transfer (AT) EAE protocols in autoimmune-prone SJL mice bearing the H-2^s haplotype. While EAE induction by active immunization requires administration of peptides emulsified in complete Freund’s adjuvant (CFA), AT-EAE involves infusion of antigen-sensitized cells into naïve recipients (Miller & Karpus, 2007). The disease induction by active immunization essentially involves two phases: antigen-sensitization and effector T cell-expansion. On the contrary, the pathogenic potential of effector T cells is directly tested in AT-EAE protocol by transferring antigen-stimulated lymph node or spleen cells generated from previously immunized mice, thus eliminating the need to immunize naive recipients prior to disease induction. Figure 3a shows that SJL mice immunized with ACA 83-95 developed clinical signs of EAE reminiscent of disease induced by the cognate peptide PLP 139-151 (Tuohy, *et al.*, 1989, Massilamany, *et al.*, 2010, Massilamany, *et al.*, 2011). Verification of these results in AT-EAE protocol clearly indicated that the disease-induction by ACA 83-95 requires the mediation of antigen-sensitized T cells (Fig. 3b, Fig. 4; Massilamany, *et al.*, 2010, Massilamany, *et al.*, 2011).

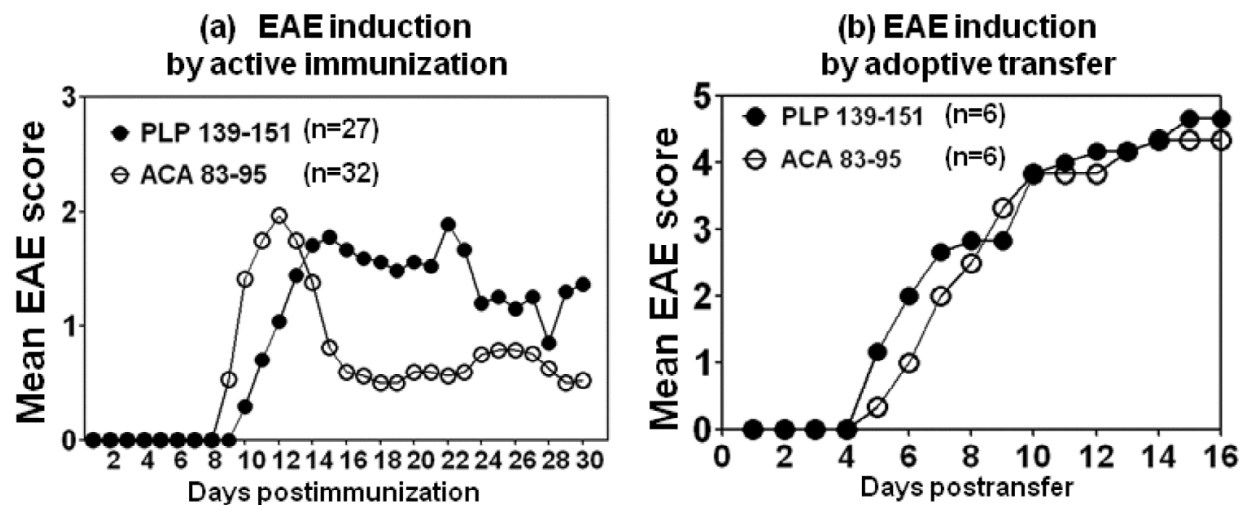


Fig. 3. ACA 83-95 induces autoimmune encephalomyelitis similar to that induced by PLP 139-151. (a) EAE induction by active immunization. SJL mice were immunized with peptides emulsified in CFA, and pertussis toxin was administered on day 0 and 2 postimmunization and the mice were monitored for clinical signs of EAE and scored. (b) EAE induction by adoptive transfer. Short-term T cell lines were derived from mice immunized with the indicated peptides and viable lymphoblasts were injected into naive SJL mice intraperitoneally, and the mice were monitored for signs of EAE and scored (Massilamany, *et al.*, 2010, Massilamany, *et al.*, 2011). Scoring scale: 0, healthy; 1, limp tail or hind limb weakness, but not both; 2, limp tail and hind limb weakness; 3, partial paralysis of hind limbs; 4, complete paralysis of hind limbs; 5, moribund or dead (Tuohy, *et al.*, 1989, Massilamany, *et al.*, 2010, Massilamany, *et al.*, 2011).

4.1.1 ACA 83-95 induces the generation of cross-reactive T cells

We adopted two approaches to prove that EAE induced with ACA 83-95 involves the generation of cross-reactive T cells for PLP 139-151: 1) T cell proliferation assay based on tritiated ³[H] thymidine incorporation and 2) major histocompatibility complex (MHC) class II tetramer staining. The latter assay involves creation of fluorescent dye-labeled MHC class II tetramers for the class II allele of SJL mice, called IAs, into which peptide sequences for ACA 83-95 and PLP 139-151 are covalently tethered. The use of tetramers permitted detection of antigen-specific cells by flow cytometry at a single cell level. As expected, PLP 139-151 induced dose-dependent proliferative T cell response to PLP, but a fraction of these cells also responded to unimmunized mimicry peptide, ACA 83-95 and vice versa (Fig. 5; Massilamany, *et al.*, 2010, Massilamany, *et al.*, 2011). Consistent with the proliferative responses, PLP 139-151 tetramer⁺ CD4⁺ T cells were evident in mice immunized with either PLP 139-151 or ACA 83-95 as predicted (Fig. 6; Massilamany, *et al.*, 2010, Massilamany, *et al.*, 2011). We verified the specificity of tetramer staining using Theiler's murine encephalomyelitis virus (TMEV) 70-86 tetramers, which stained negligibly. Taken together, the data demonstrate that ACA 83-95 induces T cell response that can cross-react with PLP 139-151.

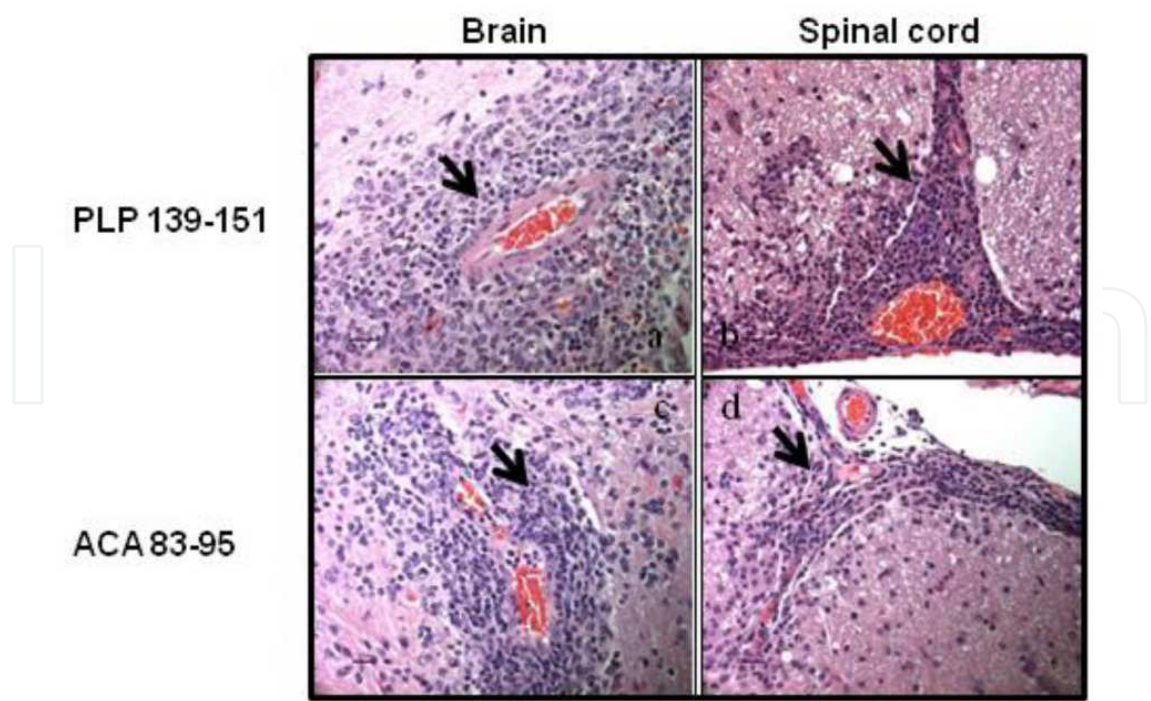


Fig. 4. Histological evaluation of AT-EAE induced by ACA 83-95-sensitized T lymphocytes. Hematoxylin and Eosin-stained sections show perivascular cuffing (arrows) in the brains and spinal cords of mice that received PLP 139-151 (a and b)-, ACA 83-95 (c and d)-sensitized T lymphocytes. Original magnification, x 400 (bar = 20 μm) (Massilamany, *et al.*, 2010, Massilamany, *et al.*, 2011).

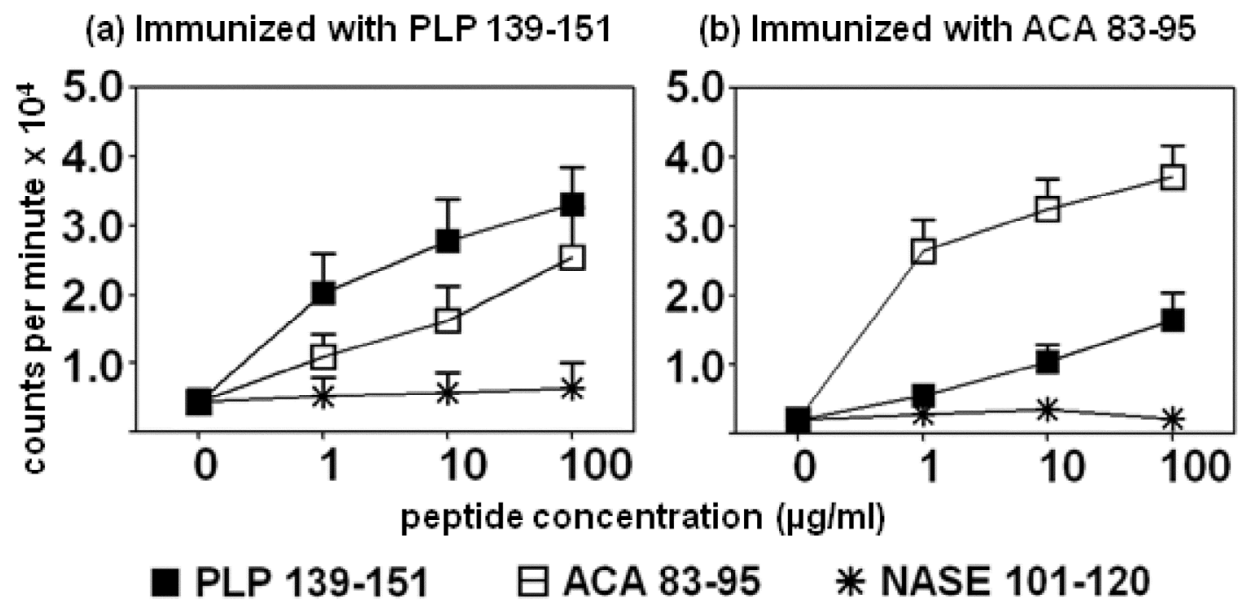


Fig. 5. Cross-reactive T cell responses induced by PLP 139-151 and ACA 83-95. Lymph node cells from PLP 139-151- and ACA 83-95-immunized mice were stimulated with PLP 139-151, ACA 83-95 and NASE 101-120 (control) for two days. After pulsing with tritiated ³[H] thymidine, proliferative responses were measured as counts per minute 16 hours later (Massilamany, *et al.*, 2010, Massilamany, *et al.*, 2011).

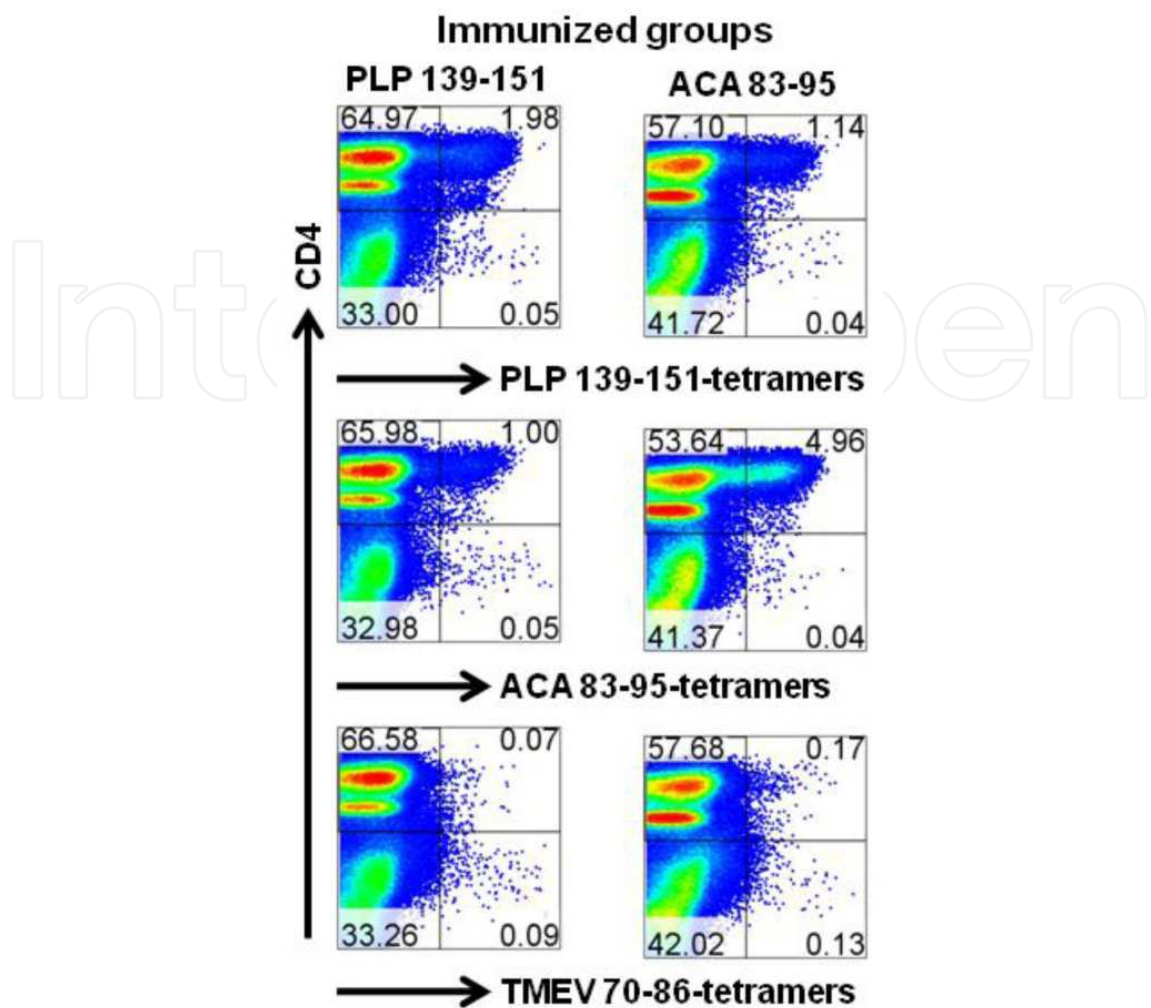


Fig. 6. Cross-reactive T cell responses induced by PLP 139-151 and ACA 83-95 are antigen-specific. Lymph node cells obtained from mice immunized with PLP 139-151 or ACA 83-95 were restimulated with the corresponding peptides, and tetramer staining was performed using PLP 139-151, ACA 83-95 and TMEV 70-86 (control) tetramers, anti-CD4 and 7-amino-actinomycin D (7-AAD). After acquiring the cells by flow cytometry, percentages of tetramer⁺CD4⁺ T cells were enumerated in the live (7-AAD⁻) populations (see upper right quadrant in each plot; (Massilamany, *et al.*, 2010, Massilamany, *et al.*, 2011).

4.1.2 ACA 83-95 induces cytokine responses that favor CNS autoimmunity

One of the hallmarks of CNS autoimmunity is the production of T helper (Th)1 and Th17 cytokines. Although both Th1 and Th17 cells could contribute to EAE pathogenicity, it appears that the ratio between the two subsets of T cells determines the severity of EAE. Predominance of Th17 over Th1 cells exacerbates inflammation and infiltration into the CNS (Bettelli, *et al.*, 2007, Stromnes, *et al.*, 2008). Furthermore, it has been proposed that Th1 cells enter non-inflamed CNS tissues and initiate inflammation, then facilitate the entry of Th17 cells (O'Connor, *et al.*, 2008). Flow cytometrically, we verified Th1 (IL-2, and IFN- γ) and Th17 (IL-17A, IL-17F and IL-22) and Th2 (IL-4 and IL-10) cells, which mediate pro- and anti-inflammatory effects respectively by intracellular staining. As expected, ACA 83-95 induces predominantly Th1 and Th17 cytokines similar to that induced with the cognate peptide,

PLP 139-151 (Fig. 7; Massilamany, *et al.*, 2010, Massilamany, *et al.*, 2011). Based on these data, we expect that animals infected with *A. castellanii* will show the generation of pathogenic PLP-reactive T cells.

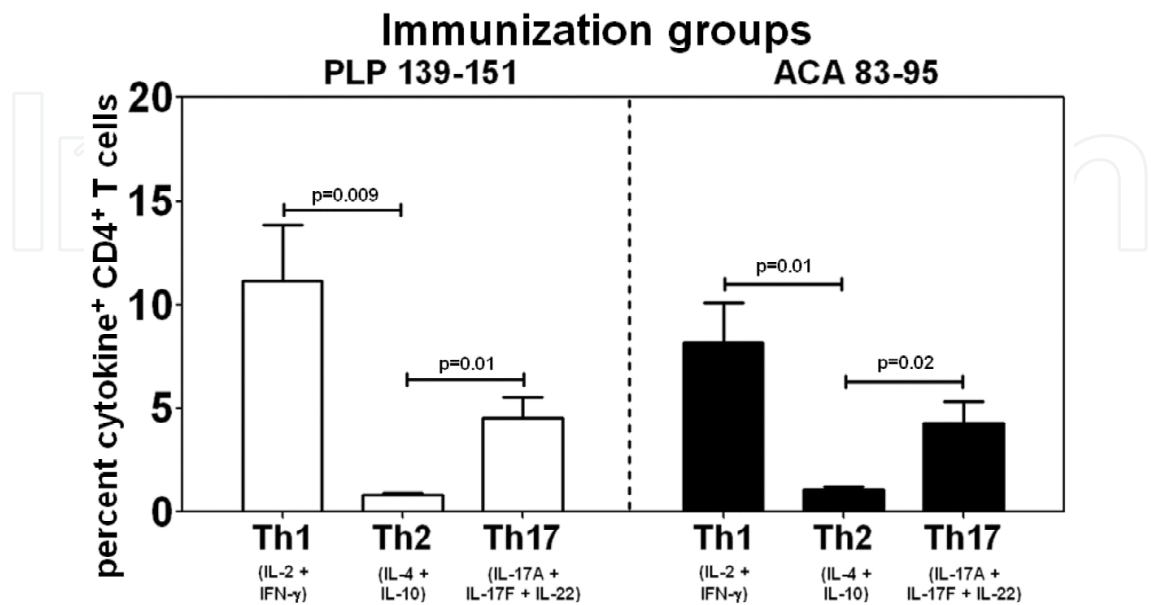


Fig. 7. ACA 83-95 from *A. castellanii* induces cytokines similar to that of PLP 139-151. Lymph node cells obtained from mice immunized with PLP 139-151, or ACA 83-95 were stimulated with the corresponding peptides for two days and then maintained in IL-2 medium. Viable lymphoblasts were harvested on day 4 and stimulated briefly with phorbol 12-myristate 13-acetate and Ionomycin. After staining with anti-CD4 and 7-AAD, intracellular staining was performed using cytokine antibodies and frequencies of cytokine-secreting cells were then determined by flow cytometry in the live (7-AAD-) CD4 subset. Shown are the frequencies of cytokine-secreting cells corresponding to Th1 (IL-2 and IFN-γ), Th2 (IL-4 and IL-10) and Th17 (IL-17A, IL-17F and IL-22) subsets (Massilamany, *et al.*, 2010, Massilamany, *et al.*, 2011).

4.1.3 Murine *Acanthamoeba* granulomatous encephalitis as a disease model of MS

Acanthamoeba spp. can cause choriomeningitis and destructive encephalomyelitis in mice and monkeys (Culbertson, *et al.*, 1958, Culbertson, *et al.*, 1959). The mouse model is widely used to study the pathogenesis of GAE (Kim, *et al.*, 1990, Janitschke, *et al.*, 1996, Marciano-Cabral, *et al.*, 2001, Gornik & Kuzna-Grygiel, 2005, Khan, 2009). Intranasal inoculations of mice with *A. castellanii* produce subacute to chronic granulomatous encephalitis accompanied by rhinitis and pneumonitis (Martinez, *et al.*, 1975, Kim, *et al.*, 1990, Janitschke, *et al.*, 1996, Gornik & Kuzna-Grygiel, 2005). Clinically, GAE in mice is manifested by respiratory distress, pneumonia, head tilt, circling, twirling, seizures, and limb paresis (Culbertson, *et al.*, 1959, Culbertson, 1961, Culbertson, *et al.*, 1966, Martinez, *et al.*, 1975, Kim, *et al.*, 1990, Janitschke, *et al.*, 1996, Gornik & Kuzna-Grygiel, 2005). Histologically, infiltrations consist of microglia, histiocytes and lymphocytes around capillaries, suggestive of formation of foreign body granuloma (Martinez, *et al.*, 1975, Janitschke, *et al.*, 1996, Gornik & Kuzna-Grygiel, 2005). Electron microscopic studies reveal swelling and disintegration of dendrites, astrocytes, oligodendrocyte disruption, and disassociation of the myelin sheath along swollen axon cylinders (Martinez, *et al.*, 1975). In our studies with ACA 83-95-induced

autoimmune encephalomyelitis, in spite of the presence of mononuclear cells (MNC), the dominance of plasma cells and giant cells was absent. Instead, the histologic disease resembled typical PLP 139-151-induced EAE (Sobel, *et al.*, 1990, Massilamany, *et al.*, 2010, Massilamany, *et al.*, 2011), suggesting that naturally occurring GAE may involve the mediation of multiple factors and different cell types, which may reflect the host's response to living organisms *in situ*. To date, there are no reports to indicate that autoimmune response is a component of disease pathogenesis in GAE, and our data with ACA 83-95-induced autoimmune encephalomyelitis provide compelling evidence to test this possibility. This notion is further supported by the fact that humans affected with *A. castellanii* infection can never be treated successfully (Marciano-Cabral & Cabral, 2003). Pathogens that primarily infect the CNS can induce autoimmune responses secondarily. As previously discussed, *A. castellanii* is a pathogen of the CNS that causes granulomatous inflammation of the brain and spinal cord. We propose that *A. castellanii* can induce myelin-reactive T cells by two mechanisms in infected mice (Fig. 8). **(a) Molecular mimicry.** Upon exposure to the parasites, the immune system recognizes parasite-derived mimic of PLP, generating T cells in the periphery, which then migrate into the CNS and cause inflammation. In support of this theory, we have demonstrated that the mimicry epitope from *A. castellanii*,

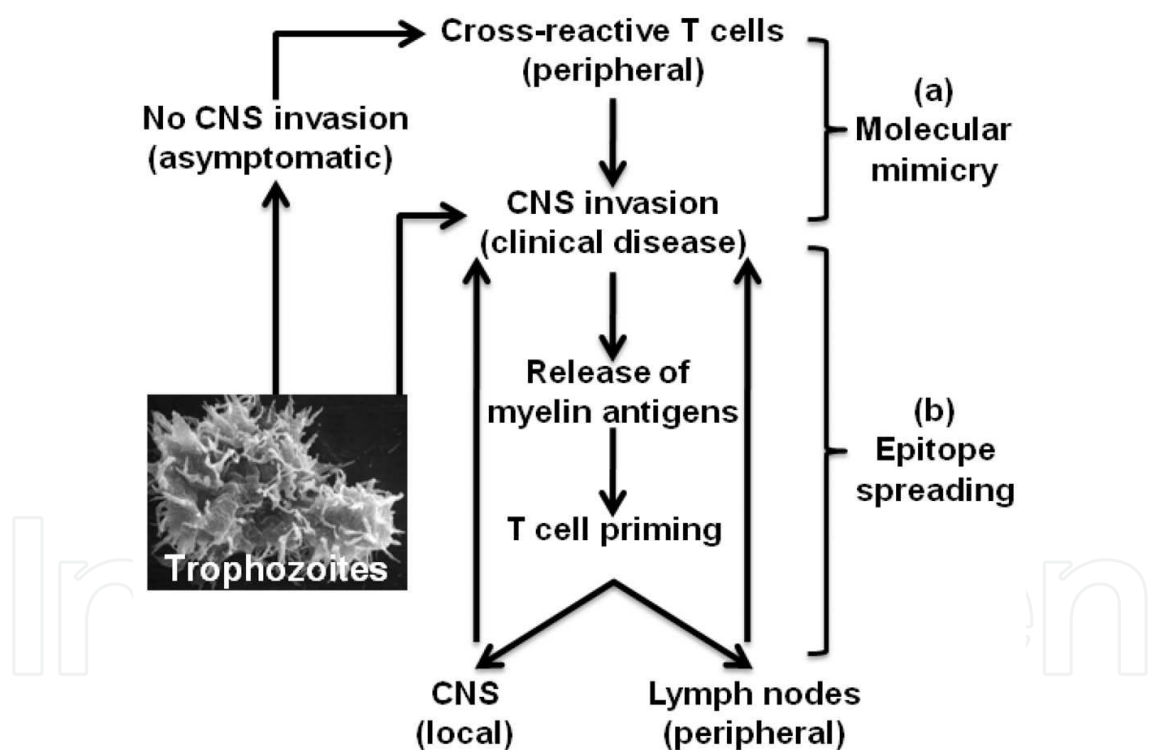


Fig. 8. Proposed mechanisms for the induction of CNS autoimmunity in mice infected with *A. castellanii*. (a) Molecular mimicry. Peripherally, the immune system can recognize mimicry epitope of PLP, and generates cross-reactive T cells, which then migrate into the CNS and cause inflammation. (b) Epitope spreading. Granulomatous CNS inflammation induced by *Acanthamoeba* can lead to the release of myelin antigens and prime T cells locally or peripherally and the *de novo* generated myelin-reactive T cells can further aggravate CNS inflammation. Conversely, mice can remain infected and clinically normal but, cross-reactive cells can still be generated by mimicry.

ACA 83-95, can induce clinical signs of autoimmune encephalomyelitis in the adjuvant protocol of inducing CNS autoimmunity in SJL mice (Massilamany, *et al.*, 2010, Massilamany, *et al.*, 2011). **(b) Epitope spreading.** *A. castellanii* causes granulomatous inflammation in the brain and spinal cord, which can lead to the local release of myelin antigens and prime T cells. Alternatively, the newly released myelin antigens are carried by antigen-presenting cells to the draining lymph nodes and prime T cells, which, in turn, migrate back into the CNS and further aggravate inflammation. Similar events have been earlier demonstrated in the case of murine pathogen, TMEV (Miller, *et al.*, 2001, Olson, *et al.*, 2004, McMahon, *et al.*, 2005).

MS is a disease of the CNS characterized by inflammation and infiltration of MNC and the loss of myelin sheath encapsulating the axons (Noseworthy, *et al.*, 2000, Sospedra & Martin, 2005). Autoimmune responses to myelin antigens have been implicated in MS pathogenesis and this requires the mediation of autoreactive T cells and B cells, but the mechanisms by which the disease is initiated are unknown (Kerlero de Rosbo, *et al.*, 1993, Sospedra & Martin, 2005). Although genetic susceptibility is a major predisposing factor, exposure to environmental microbes such as viruses and bacteria have been suspected in the initiation of autoimmune diseases. In support of the latter, exacerbations of MS attacks or temporal alterations in the disease course have been linked primarily to exposure to virus infections such as Epstein Barr virus and Human Herpes virus-6, but the clinical evidence remains elusive (Cirone, *et al.*, 2002, Pohl, 2009, Salvetti, *et al.*, 2009). The current dogma is that MS does not appear to follow Koch's postulates in that no single organism appears to trigger it; rather, exposure to multiple organisms might be critical for MS predisposition (Sospedra & Martin, 2005). The fact that ACA contains mimicry epitope for PLP, one of the candidate autoantigens implicated in MS pathogenesis, suggests that ACA infection can potentially lead to the generation of PLP reactive T cells and predispose to MS.

5. Clinical signs and histology

Acanthamoeba-induced encephalitis is often overlooked (Schuster & Visvesvara, 2004, da Rocha-Azevedo, *et al.*, 2009), partly due to the rarity of *Acanthamoeba* infections and a lack of familiarity and diagnostic tools. However, when diagnosed, it is difficult to differentiate PAM from GAE because symptoms overlap between each other (da Rocha-Azevedo, *et al.*, 2009). PAM is initially manifested by severe headache, rhinitis, nausea, and fever followed by anosmia, seizures, stiff neck, diplopia, and coma, finally leading to death (Marciano-Cabral & Cabral, 2003, da Rocha-Azevedo, *et al.*, 2009). Histologically, brains contain inflammatory infiltrates comprised of neutrophils, eosinophils, and macrophages (Martinez & Janitschke, 1985, Marciano-Cabral & Cabral, 2003, da Rocha-Azevedo, *et al.*, 2009). In contrast, symptoms of GAE are diverse in that a wide range of clinical manifestations can be expected. These include headache, rise in intracranial pressure, abnormal gait or ataxia, diplopia, stiff neck, confusion, behavioral changes, hemiparesis, cranial nerve palsies, seizures, photophobia, and anorexia; more than 90% of individuals affected with GAE tend to die (Marciano-Cabral & Cabral, 2003, Khan, 2006). The histologic disease is characterized by hemorrhagic or necrotic encephalitis, edema of the brain accompanied by the presence of focal lesions around the cerebrum, cerebellum, and corpus callosum. Cellular infiltrations in histological sections include multinucleated giant cells, plasma cells, polymorphonuclear cells and mononuclear cells (Martinez & Visvesvara, 1997, da Rocha-Azevedo, *et al.*, 2009) and HIV patients can develop granulomas within the CNS possibly due to low CD4 T cell count (Marciano-Cabral & Cabral, 2003, Cha, *et al.*, 2006, Khan, 2006). In some patients,

organs other than brain such as skin, liver, lungs, kidneys, prostate glands, lymph nodes, pancreas, and adrenals can also be affected.

6. Diagnosis

Acanthamoeba-induced encephalitis is not routinely suspected, the disease can be misdiagnosed as neurocysticercosis; viral, rickettsial, fungal, and bacterial meningitis; toxoplasmosis; and brain tumors (Schuster & Visvesvara, 2004, Khan, 2005b). Serologically, detection of *Acanthamoeba*-reactive antibodies gives an indication of amoebic exposure at a population level (Cursons, *et al.*, 1980, Cerva, 1989, Khan, 2006). However, definitive diagnosis requires the demonstration of amoebic trophozoites or cysts in biological samples. Examination of wet-mount smears prepared from CSF or methanol-fixed smears stained with Giemsa-Wright permit identification of amoebic trophozoites. While evaluating wet-mount smears, careful consideration should be given to differentiate trophozoites from macrophages because of their close morphological resemblance to each other (Cleland, *et al.*, 1982, Lalitha, *et al.*, 1985, Singhal, *et al.*, 2001). In addition to CSF, trophozoites can also be detected in bronchoalveolar lavage fluid from patients with respiratory distress (Newsome, *et al.*, 1992). Detection of trophozoites in fixed tissue sections prepared from brains is usually performed using hematoxylin and eosin and trichrome stainings (Newsome, *et al.*, 1992). In contrast, amoebic cysts in brain tissues are detected using calcofluor white staining (Silvany, *et al.*, 1987). Alternatively, periodic acid-Schiff's stain and Gomori-methenamine silver stain can be used to stain tissue sections in which, cysts appear red whereas tissues appear black in color (Marciano-Cabral & Cabral, 2003).

Other specialized techniques employed to demonstrate the presence of amoeba are transmission electron microscopy and immunofluorescent or immunoperoxidase staining (Willaert & Stevens, 1976, Stevens, *et al.*, 1977, McKellar, *et al.*, 2006, Guarner, *et al.*, 2007). However, because most *Acanthamoeba* spp. are antigenically related, the use of immunohistochemical techniques does not permit identification by species. To identify structural brain lesions, computed tomography and magnetic resonance imaging are widely used (Sell, *et al.*, 1997, Kidney & Kim, 1998). These evaluations can reveal changes such as multifocal areas of signal intensities or ring-like lesions or low-density areas indicating occupying mass of tumor or abscess (Martinez, *et al.*, 1977, Martinez, *et al.*, 1980, Ofori-Kwakye, *et al.*, 1986, Matson, *et al.*, 1988, Khan, 2005b, Khan, 2008, da Rocha-Azevedo, *et al.*, 2009). The regions of the brain that are usually affected are midbrain, basal areas of the temporal and occipital lobes, and the posterior fossa (Seijo Martinez, *et al.*, 2000, Marciano-Cabral & Cabral, 2003, Khan, 2006). Molecularly, PCR amplification of the 18S rDNA using sequence-specific primers is currently used as a quick and reliable method of diagnosis (Schroeder, *et al.*, 2001, Khan, 2006, da Rocha-Azevedo, *et al.*, 2009, Maritschnegg, *et al.*, 2011). Hematologically, pleocytosis accompanied by lymphocytosis, neutrophilia, hypoglycemia and hyperproteinemia may be seen in patients with GAE (Marciano-Cabral & Cabral, 2003). In addition, *Acanthamoeba* can be isolated from clinical specimens by plating the samples on non-nutrient agar plates coated with *E. coli* or *Enterobacter aerogenes* (Schuster, 2002, Khan, 2006, da Rocha-Azevedo, *et al.*, 2009).

7. Treatment

The low degree of therapeutic success in treating amoebic encephalitis is due in part to the fact that immunocompromised individuals are most often affected, and the disease outcome

thus depends on successful treatment of underlying causes. Furthermore, *Acanthamoeba* infections tend to escape early diagnosis due to the lack of both awareness and diagnostic tools. Nonetheless, if diagnosed early, the disease can be treated successfully (Marciano-Cabral & Cabral, 2003, Schuster & Visvesvara, 2004, Khan, 2006, Khan, 2008, Matin, *et al.*, 2008, Elsheikha & Khan, 2010, Akpek, *et al.*, 2011). Various treatment regimens have been reported in the literature, but there are no reports to indicate that *Acanthamoeba* infections can be treated with a single drug; rather, a combination of multiple drugs is used (Table 1). These include ketoconazole, fluconazole, flucytosine, sulfa-trimethoprim, amphotericin B, pentamidine isothionate, azithromycin, itraconazole and rifampicin. Currently, to enhance BBB-permeability, soluble analogs of the most effective drugs are being tested (Khan, 2006). Likewise, experimental attempts also are being made to use non-viral plasmid DNAs encoding anti-sense RNA sequences for virulence factors of amoebae which can block their entry into the CNS (Elsheikha & Khan, 2010). Based on our data (Massilamany, *et al.*, 2010, Massilamany, *et al.*, 2011), we propose that amoebic encephalitis might involve mediation of autoimmunity, but this hypothesis needs to be tested experimentally in animal models and clinically in GAE patients. Proving that autoimmunity is a component of GAE provides a basis for exploring treatment modalities directed toward autoimmunity in patient subjects.

Species	Disease	Drugs	Outcome	Reference
<i>Acanthamoeba</i> spp.	GAE	Pyrimethamine and fluconazole	Died	Gardner, <i>et al.</i> , 1991
<i>Acanthamoeba</i> spp.	GAE	Pyrimethamine and sulfadiazine	Died	Gordon, <i>et al.</i> , 1992
<i>Acanthamoeba</i> spp.	Cutaneous amoebiasis and GAE	Fluorocytosine and pentamidine	Died	Murakawa, <i>et al.</i> , 1995
<i>Acanthamoeba</i> spp.	GAE	Sulfadiazine, pyrimethamine, fluconazole and sulfadiazine	Survived	Seijo Martinez, <i>et al.</i> , 2000
<i>Acanthamoeba</i> T4	GAE	Fluconazole, rifampicin, Metronidazole and sulfadiazine	Survived	Petry, <i>et al.</i> , 2006
<i>Acanthamoeba</i> T1	GAE	Fluoxetine, pantoprazole and prednisolone.	Died	Cha, <i>et al.</i> , 2006
<i>Acanthamoeba</i> spp.	GAE	Ketoconazole, trimethoprim, sulfamethoxazole, rifampicin and cotrimoxazole	Survived	Gupta, <i>et al.</i> , 2008
<i>Acanthamoeba</i> T2	GAE	Miltefosine and amikacin.	Survived	Walochnik, <i>et al.</i> , 2008
<i>Acanthamoeba</i> spp.	GAE	Miltefosine and amikacin	Survived	Aichelburg, <i>et al.</i> , 2008
<i>Acanthamoeba</i> spp.	GAE	Rifampicin and co-trimoxazole	Survived	Fung, <i>et al.</i> , 2008
<i>Acanthamoeba lenticulata</i> T3	GAE	Meropenem, linezolid, moxifloxacin and fluconazole	Survived	Lackner, <i>et al.</i> , 2010
<i>Acanthamoeba</i> group II T4	GAE	Trimethoprim-sulfamethoxazole, fluconazole, pentamidine and miltefosine	Survived	Maritschnegg, <i>et al.</i> , 2011

Table 1. Drugs used in the treatment of *Acanthamoeba* infections

8. Conclusion

In spite of high prevalence, the diseases induced by *Acanthamoebae* are extremely low. Although amoebic encephalitis is more commonly seen in immunocompromised individuals, the disease can occur in immunocompetent healthy individuals (Marciano-Cabral & Cabral, 2003, Schuster & Visvesvara, 2004). Our discovery that *A. castellanii* contains mimicry epitope for PLP indicates that exposure to *Acanthamoeba* can accompany autoimmunity through the generation of self-reactive T cells. *Acanthamoebae* are free-living organisms that are ubiquitous in the environment, leading to constant exposure. It is possible that such coexistence can help microbes acquire some of the genetic elements of their hosts as an evasive mechanism for survival. Alternatively, exposure to such organisms could lead to a break in self-tolerance as a result of antigenic mimicry in genetically susceptible individuals who potentially carry pathogenic autoreactive T cell and B cell repertoires. Further research is required to address these hypotheses, proving which creates opportunities to also target therapy toward autoimmunity in patients affected with GAE.

9. References

- Aichelburg AC, Walochnik J, Assadian O, et al. (2008) Successful treatment of disseminated *Acanthamoeba* sp. infection with miltefosine. *Emerg Infect Dis* 14: 1743-1746.
- Akpek G, Uslu A, Huebner T, et al. (2011) Granulomatous amebic encephalitis: an under-recognized cause of infectious mortality after hematopoietic stem cell transplantation. *Transpl Infect Dis*.
- Barbeau J & Buhler T (2001) Biofilms augment the number of free-living amoebae in dental unit waterlines. *Res Microbiol* 152: 753-760.
- Barker J, Scaife H & Brown MR (1995) Intraphagocytic growth induces an antibiotic-resistant phenotype of *Legionella pneumophila*. *Antimicrob Agents Chemother* 39: 2684-2688.
- Benedetto N & Auriault C (2002a) Complex network of cytokines activating murine microglial cell activity against *Acanthamoeba castellanii*. *Eur Cytokine Netw* 13: 351-357.
- Benedetto N & Auriault C (2002b) Prolactin-cytokine network in the defence against *Acanthamoeba castellanii* in murine microglia [corrected]. *Eur Cytokine Netw* 13: 447-455.
- Benedetto N, Rossano F, Gorga F, Folgore A, Rao M & Romano Carratelli C (2003) Defense mechanisms of IFN-gamma and LPS-primed murine microglia against *Acanthamoeba castellanii* infection. *Int Immunopharmacol* 3: 825-834.
- Berk SG, Ting RS, Turner GW & Ashburn RJ (1998) Production of respirable vesicles containing live *Legionella pneumophila* cells by two *Acanthamoeba* spp. *Appl Environ Microbiol* 64: 279-286.
- Bettelli E, Oukka M & Kuchroo VK (2007) T(H)-17 cells in the circle of immunity and autoimmunity. *Nat Immunol* 8: 345-350.
- Bowers B (1977) Comparison of pinocytosis and phagocytosis in *Acanthamoeba castellanii*. *Exp Cell Res* 110: 409-417.
- Bowers B & Korn ED (1968) The fine structure of *Acanthamoeba castellanii*. I. The trophozoite. *J Cell Biol* 39: 95-111.
- Bowers B & Olszewski TE (1983) *Acanthamoeba* discriminates internally between digestible and indigestible particles. *J Cell Biol* 97: 317-322.

- Brindley N, Matin A & Khan NA (2009) *Acanthamoeba castellanii*: high antibody prevalence in racially and ethnically diverse populations. *Exp Parasitol* 121: 254-256.
- Casemore DP (1977) Free-living amoebae in home dialysis unit. *Lancet* 2: 1078.
- Cerva L (1989) *Acanthamoeba culbertsoni* and *Naegleria fowleri*: occurrence of antibodies in man. *J Hyg Epidemiol Microbiol Immunol* 33: 99-103.
- Cha JH, Furie K, Kay J, Walensky RP, Mullins ME & Hedley-Whyte ET (2006) Case records of the Massachusetts General Hospital. Case 39-2006. A 24-year-old woman with systemic lupus erythematosus, seizures, and right arm weakness. *N Engl J Med* 355: 2678-2689.
- Chagla AH & Griffiths AJ (1974) Growth and encystation of *Acanthamoeba castellanii*. *J Gen Microbiol* 85: 139-145.
- Chappell CL, Wright JA, Coletta M & Newsome AL (2001) Standardized method of measuring *acanthamoeba* antibodies in sera from healthy human subjects. *Clin Diagn Lab Immunol* 8: 724-730.
- Cirone M, Cuomo L, Zompetta C, Ruggieri S, Frati L, Faggioni A & Ragona G (2002) Human herpesvirus 6 and multiple sclerosis: a study of T cell cross-reactivity to viral and myelin basic protein antigens. *J Med Virol* 68: 268-272.
- Cleland PG, Lawande RV, Onyemelukwe G & Whittle HC (1982) Chronic amebic meningoencephalitis. *Arch Neurol* 39: 56-57.
- Culbertson CG (1961) Pathogenic *Acanthamoeba* (Hartmannella). *Am J Clin Pathol* 35: 195-202.
- Culbertson CG, Smith JW & Minner JR (1958) *Acanthamoeba*: observations on animal pathogenicity. *Science* 127: 1506.
- Culbertson CG, Ensminger PW & Overton WM (1966) *Hartmannella* (*acanthamoeba*). Experimental chronic, granulomatous brain infections produced by new isolates of low virulence. *Am J Clin Pathol* 46: 305-314.
- Culbertson CG, Smith JW, Cohen HK & Minner JR (1959) Experimental infection of mice and monkeys by *Acanthamoeba*. *Am J Pathol* 35: 185-197.
- Cursons RT, Brown TJ, Keys EA, Moriarty KM & Till D (1980) Immunity to pathogenic free-living amoebae: role of cell-mediated immunity. *Infect Immun* 29: 408-410.
- da Rocha-Azevedo B, Tanowitz HB & Marciano-Cabral F (2009) Diagnosis of infections caused by pathogenic free-living amoebae. *Interdiscip Perspect Infect Dis* 2009: 251406.
- De Jonckheere J & van de Voorde H (1976) Differences in destruction of cysts of pathogenic and nonpathogenic *Naegleria* and *Acanthamoeba* by chlorine. *Appl Environ Microbiol* 31: 294-297.
- De Jonckheere JF (1987) Taxonomy, Amphizoic amoebae human pathology (Rondanelli EG, ed. ^eds.), p. ^pp. pp 25-48. Piccin Nuova Libreria, Padua, Italy, Padua, Italy.
- De Jonckheere JF (1991) Ecology of *Acanthamoeba*. *Rev Infect Dis* 13 Suppl 5: S385-387.
- Dudley R, Alsam S & Khan NA (2007) Cellulose biosynthesis pathway is a potential target in the improved treatment of *Acanthamoeba* keratitis. *Appl Microbiol Biotechnol* 75: 133-140.
- Elsheikha HM & Khan NA (2010) Protozoa traversal of the blood-brain barrier to invade the central nervous system. *FEMS Microbiol Rev* 34: 532-553.
- Ferrante A (1991a) Free-living amoebae: pathogenicity and immunity. *Parasite Immunol* 13: 31-47.
- Ferrante A (1991b) Immunity to *Acanthamoeba*. *Rev Infect Dis* 13 Suppl 5: S403-409.

- Fung KT, Dhillon AP, McLaughlin JE, et al. (2008) Cure of *Acanthamoeba* cerebral abscess in a liver transplant patient. *Liver Transpl* 14: 308-312.
- Gardner HA, Martinez AJ, Visvesvara GS & Sotrel A (1991) Granulomatous amebic encephalitis in an AIDS patient. *Neurology* 41: 1993-1995.
- Garate M, Marchant J, Cubillos I, Cao Z, Khan NA & Panjwani N (2006) In vitro pathogenicity of *Acanthamoeba* is associated with the expression of the mannose-binding protein. *Invest Ophthalmol Vis Sci* 47: 1056-1062.
- Gast RJ, Ledee DR, Fuerst PA & Byers TJ (1996) Subgenus systematics of *Acanthamoeba*: four nuclear 18S rDNA sequence types. *J Eukaryot Microbiol* 43: 498-504.
- Gordon SM, Steinberg JP, DuPuis MH, Kozarsky PE, Nickerson JF & Visvesvara GS (1992) Culture isolation of *Acanthamoeba* species and leptomycid amebas from patients with amebic meningoencephalitis, including two patients with AIDS. *Clin Infect Dis* 15: 1024-1030.
- Gornik K & Kuzna-Grygiel W (2005) Histological studies of selected organs of mice experimentally infected with *Acanthamoeba* spp. *Folia Morphol (Warsz)* 64: 161-167.
- Guarner J, Bartlett J, Shieh WJ, Paddock CD, Visvesvara GS & Zaki SR (2007) Histopathologic spectrum and immunohistochemical diagnosis of amebic meningoencephalitis. *Mod Pathol* 20: 1230-1237.
- Gupta D, Panda GS & Bakhshi S (2008) Successful treatment of *acanthamoeba* meningoencephalitis during induction therapy of childhood acute lymphoblastic leukemia. *Pediatr Blood Cancer* 50: 1292-1293.
- Han KL, Lee J, Kim DS, Park SJ, Im KI & Yong TS (2006) Identification of differentially expressed cDNAs in *Acanthamoeba culbertsoni* after mouse brain passage. *Korean J Parasitol* 44: 15-20.
- Jahnes WG & Fullmer HM (1957) Free living amoebae as contaminants in monkey kidney tissue culture. *Proc Soc Exp Biol Med* 96: 484-488.
- Janitschke K, Martinez AJ, Visvesvara GS & Schuster F (1996) Animal model *Balamuthia mandrillaris* CNS infection: contrast and comparison in immunodeficient and immunocompetent mice: a murine model of "granulomatous" amebic encephalitis. *J Neuropathol Exp Neurol* 55: 815-821.
- Jones DB, Visvesvara GS & Robinson NM (1975) *Acanthamoeba* polyphaga keratitis and *Acanthamoeba* uveitis associated with fatal meningoencephalitis. *Trans Ophthalmol Soc U K* 95: 221-232.
- Kerlero de Rosbo N, Milo R, Lees MB, Burger D, Bernard CC & Ben-Nun A (1993) Reactivity to myelin antigens in multiple sclerosis. Peripheral blood lymphocytes respond predominantly to myelin oligodendrocyte glycoprotein. *J Clin Invest* 92: 2602-2608.
- Khan NA (2003) Pathogenesis of *Acanthamoeba* infections. *Microb Pathog* 34: 277-285.
- Khan NA (2005a) The immunological aspects of *Acanthamoeba* infections. *American journal of immunology* 1: 24-30.
- khan NA (2005b) Granulomatous amoebic encephalitis: Clinical diagnosis and management. *American journal of infectious diseases* 1: 79-83.
- Khan NA (2006) *Acanthamoeba*: biology and increasing importance in human health. *FEMS Microbiol Rev* 30: 564-595.
- Khan NA (2007) *Acanthamoeba* invasion of the central nervous system. *Int J Parasitol* 37: 131-138.

- Khan NA (2008) Acanthamoeba and the blood-brain barrier: the breakthrough. *J Med Microbiol* 57: 1051-1057.
- Khan NA (2009) Novel in vitro and in vivo models to study central nervous system infections due to Acanthamoeba spp. *Exp Parasitol*.
- Khan NA, Jarroll EL, Panjwani N, Cao Z & Paget TA (2000) Proteases as markers for differentiation of pathogenic and nonpathogenic species of Acanthamoeba. *J Clin Microbiol* 38: 2858-2861.
- Khunkitti W, Lloyd D, Furr JR & Russell AD (1998) Acanthamoeba castellanii: growth, encystment, excystment and biocide susceptibility. *J Infect* 36: 43-48.
- Kidney DD & Kim SH (1998) CNS infections with free-living amebas: neuroimaging findings. *AJR Am J Roentgenol* 171: 809-812.
- Kim MJ, Shin CO & Im KI (1990) [Cell-mediated immunity in mice infected with Acanthamoeba culbertsoni]. *Kisaengchunghak Chapchi* 28: 143-154.
- King CH, Shotts EB, Jr., Wooley RE & Porter KG (1988) Survival of coliforms and bacterial pathogens within protozoa during chlorination. *Appl Environ Microbiol* 54: 3023-3033.
- Kingston D & Warhurst DC (1969) Isolation of amoebae from the air. *J Med Microbiol* 2: 27-36.
- Koide J, Okusawa E, Ito T, Mori S, Takeuchi T, Itoyama S & Abe T (1998) Granulomatous amoebic encephalitis caused by Acanthamoeba in a patient with systemic lupus erythematosus. *Clin Rheumatol* 17: 329-332.
- Kong HH, Kim TH & Chung DI (2000) Purification and characterization of a secretory serine proteinase of Acanthamoeba healyi isolated from GAE. *J Parasitol* 86: 12-17.
- Korn ED & Olivecrona T (1971) Composition of an amoeba plasma membrane. *Biochem Biophys Res Commun* 45: 90-97.
- Lackner P, Beer R, Broessner G, et al. (2010) Acute granulomatous acanthamoeba encephalitis in an immunocompetent patient. *Neurocrit Care* 12: 91-94.
- Lalitha MK, Anandi V, Srivastava A, Thomas K, Cherian AM & Chandi SM (1985) Isolation of Acanthamoeba culbertsoni from a patient with meningitis. *J Clin Microbiol* 21: 666-667.
- Lloyd D, Turner NA, Khunkitti W, Hann AC, Furr JR & Russell AD (2001) Encystation in Acanthamoeba castellanii: development of biocide resistance. *J Eukaryot Microbiol* 48: 11-16.
- Marciano-Cabral F & Toney DM (1998) The interaction of Acanthamoeba spp. with activated macrophages and with macrophage cell lines. *J Eukaryot Microbiol* 45: 452-458.
- Marciano-Cabral F & Cabral G (2003) Acanthamoeba spp. as agents of disease in humans. *Clin Microbiol Rev* 16: 273-307.
- Marciano-Cabral F, Puffenbarger R & Cabral GA (2000) The increasing importance of Acanthamoeba infections. *J Eukaryot Microbiol* 47: 29-36.
- Marciano-Cabral F, Ferguson T, Bradley SG & Cabral G (2001) Delta-9-tetrahydrocannabinol (THC), the major psychoactive component of marijuana, exacerbates brain infection by Acanthamoeba. *J Eukaryot Microbiol Suppl*: 4S-5S.
- Maritschnegg P, Sovinz P, Lackner H, et al. (2011) Granulomatous amebic encephalitis in a child with acute lymphoblastic leukemia successfully treated with multimodal antimicrobial therapy and hyperbaric oxygen. *J Clin Microbiol* 49: 446-448.


- Martinez AJ & Janitschke K (1985) *Acanthamoeba*, an opportunistic microorganism: a review. *Infection* 13: 251-256.
- Martinez AJ & Visvesvara GS (1997) Free-living, amphizoic and opportunistic amebas. *Brain Pathol* 7: 583-598.
- Martinez AJ & Visvesvara GS (2001) *Balamuthia mandrillaris* infection. *J Med Microbiol* 50: 205-207.
- Martinez AJ, Markowitz SM & Duma RJ (1975) Experimental pneumonitis and encephalitis caused by *acanthamoeba* in mice: pathogenesis and ultrastructural features. *J Infect Dis* 131: 692-699.
- Martinez AJ, Garcia CA, Halks-Miller M & Arce-Vela R (1980) Granulomatous amoebic encephalitis presenting as a cerebral mass lesion. *Acta Neuropathol* 51: 85-91.
- Martinez AJ, Sotelo-Avila C, Garcia-Tamayo J, Moron JT, Willaert E & Stamm WP (1977) Meningoencephalitis due to *Acanthamoeba* SP. Pathogenesis and clinico-pathological study. *Acta Neuropathol* 37: 183-191.
- Massilamany C, Steffen D & Reddy J (2010) An epitope from *Acanthamoeba castellanii* that cross-react with proteolipid protein 139-151-reactive T cells induces autoimmune encephalomyelitis in SJL mice. *J Neuroimmunol* 219: 17-24.
- Massilamany C, Thulasigam S, Steffen D & Reddy J (2011) Gender differences in CNS autoimmunity induced by mimicry epitope for PLP 139-151 in SJL mice. *J Neuroimmunol* 230: 95-104.
- Matin A, Siddiqui R, Jayasekera S & Khan NA (2008) Increasing importance of *Balamuthia mandrillaris*. *Clin Microbiol Rev* 21: 435-448.
- Matson DO, Rouah E, Lee RT, Armstrong D, Parke JT & Baker CJ (1988) *Acanthamoeba* meningoencephalitis masquerading as neurocysticercosis. *Pediatr Infect Dis J* 7: 121-124.
- Mattana A, Serra C, Mariotti E, Delogu G, Fiori PL & Cappuccinelli P (2006) *Acanthamoeba castellanii* promotion of in vitro survival and transmission of coxsackie b3 viruses. *Eukaryot Cell* 5: 665-671.
- McClellan K, Howard K, Mayhew E, Niederkorn J & Alizadeh H (2002) Adaptive immune responses to *Acanthamoeba* cysts. *Exp Eye Res* 75: 285-293.
- McKellar MS, Mehta LR, Greenlee JE, *et al.* (2006) Fatal granulomatous *Acanthamoeba* encephalitis mimicking a stroke, diagnosed by correlation of results of sequential magnetic resonance imaging, biopsy, in vitro culture, immunofluorescence analysis, and molecular analysis. *J Clin Microbiol* 44: 4265-4269.
- McMahon EJ, Bailey SL, Castenada CV, Waldner H & Miller SD (2005) Epitope spreading initiates in the CNS in two mouse models of multiple sclerosis. *Nat Med* 11: 335-339.
- Meersseman W, Lagrou K, Sciot R, *et al.* (2007) Rapidly fatal *Acanthamoeba* encephalitis and treatment of cryoglobulinemia. *Emerg Infect Dis* 13: 469-471.
- Michel R, Burghardt H & Bergmann H (1995) [*Acanthamoeba*, naturally intracellularly infected with *Pseudomonas aeruginosa*, after their isolation from a microbiologically contaminated drinking water system in a hospital]. *Zentralbl Hyg Umweltmed* 196: 532-544.
- Miller SD & Karpus WJ (2007) Experimental autoimmune encephalomyelitis in the mouse. *Curr Protoc Immunol* Chapter 15: Unit 15 11.

- Miller SD, Katz-Levy Y, Neville KL & Vanderlugt CL (2001) Virus-induced autoimmunity: epitope spreading to myelin autoepitopes in Theiler's virus infection of the central nervous system. *Adv Virus Res* 56: 199-217.
- Murakawa GJ, McCalmont T, Altman J, Telang GH, Hoffman MD, Kantor GR & Berger TG (1995) Disseminated acanthamebiasis in patients with AIDS. A report of five cases and a review of the literature. *Arch Dermatol* 131: 1291-1296.
- Na BK, Cho JH, Song CY & Kim TS (2002) Degradation of immunoglobulins, protease inhibitors and interleukin-1 by a secretory proteinase of *Acanthamoeba castellanii*. *Korean J Parasitol* 40: 93-99.
- Newsome AL, Curtis FT, Culbertson CG & Allen SD (1992) Identification of *Acanthamoeba* in bronchoalveolar lavage specimens. *Diagn Cytopathol* 8: 231-234.
- Noseworthy JH, Lucchinetti C, Rodriguez M & Weinshenker BG (2000) Multiple sclerosis. *N Engl J Med* 343: 938-952.
- O'Connor RA, Prendergast CT, Sabatos CA, Lau CW, Leech MD, Wraith DC & Anderton SM (2008) Cutting edge: Th1 cells facilitate the entry of Th17 cells to the central nervous system during experimental autoimmune encephalomyelitis. *J Immunol* 181: 3750-3754.
- Ofori-Kwakye SK, Sidebottom DG, Herbert J, Fischer EG & Visvesvara GS (1986) Granulomatous brain tumor caused by *Acanthamoeba*. Case report. *J Neurosurg* 64: 505-509.
- Olson JK, Ludovic Croxford J & Miller SD (2004) Innate and adaptive immune requirements for induction of autoimmune demyelinating disease by molecular mimicry. *Mol Immunol* 40: 1103-1108.
- Petry F, Torzewski M, Bohl J, et al. (2006) Early diagnosis of *Acanthamoeba* infection during routine cytological examination of cerebrospinal fluid. *J Clin Microbiol* 44: 1903-1904.
- Pohl D (2009) Epstein-Barr virus and multiple sclerosis. *J Neurol Sci* 286: 62-64.
- Rowbotham TJ (1980) Preliminary report on the pathogenicity of *Legionella pneumophila* for freshwater and soil amoebae. *J Clin Pathol* 33: 1179-1183.
- Sakai K, Zamvil SS, Mitchell DJ, Lim M, Rothbard JB & Steinman L (1988) Characterization of a major encephalitogenic T cell epitope in SJL/J mice with synthetic oligopeptides of myelin basic protein. *J Neuroimmunol* 19: 21-32.
- Salvetti M, Giovannoni G & Aloisi F (2009) Epstein-Barr virus and multiple sclerosis. *Curr Opin Neurol* 22: 201-206.
- Sarica FB, Tufan K, Cekinmez M, Erdogan B & Altinors MN (2009) A Rare But Fatal Case of Granulomatous Amebic Encephalitis with Brain Abscess: The First Case Reported from Turkey. *Turkish Neurosurgery* Vol: 19: 256-259.
- Schroeder JM, Booton GC, Hay J, et al. (2001) Use of subgenic 18S ribosomal DNA PCR and sequencing for genus and genotype identification of acanthamoebae from humans with keratitis and from sewage sludge. *J Clin Microbiol* 39: 1903-1911.
- Schuster FL (2002) Cultivation of pathogenic and opportunistic free-living amebas. *Clin Microbiol Rev* 15: 342-354.
- Schuster FL & Visvesvara GS (2004) Free-living amoebae as opportunistic and non-opportunistic pathogens of humans and animals. *Int J Parasitol* 34: 1001-1027.
- Seijo Martinez M, Gonzalez-Mediero G, Santiago P, Rodriguez De Lope A, Diz J, Conde C & Visvesvara GS (2000) Granulomatous amebic encephalitis in a patient with AIDS:

- isolation of *acanthamoeba* sp. Group II from brain tissue and successful treatment with sulfadiazine and fluconazole. *J Clin Microbiol* 38: 3892-3895.
- Sell JJ, Rupp FW & Orrison WW, Jr. (1997) Granulomatous amebic encephalitis caused by *acanthamoeba*. *Neuroradiology* 39: 434-436.
- Shadidi KR, Aarvak T, Jeansson S, Henriksen JE, Natvig JB & Thompson KM (2001) T-cell responses to viral, bacterial and protozoan antigens in rheumatoid inflammation. Selective migration of T cells to synovial tissue. *Rheumatology (Oxford)* 40: 1120-1125.
- Silvany RE, Luckenbach MW & Moore MB (1987) The rapid detection of *Acanthamoeba* in paraffin-embedded sections of corneal tissue with calcofluor white. *Arch Ophthalmol* 105: 1366-1367.
- Singhal T, Bajpai A, Kalra V, Kabra SK, Samantaray JC, Satpathy G & Gupta AK (2001) Successful treatment of *Acanthamoeba* meningitis with combination oral antimicrobials. *Pediatr Infect Dis J* 20: 623-627.
- Sissons J, Kim KS, Stins M, Jayasekera S, Alsam S & Khan NA (2005) *Acanthamoeba castellanii* induces host cell death via a phosphatidylinositol 3-kinase-dependent mechanism. *Infect Immun* 73: 2704-2708.
- Sobel RA, Tuohy VK, Lu ZJ, Laursen RA & Lees MB (1990) Acute experimental allergic encephalomyelitis in SJL/J mice induced by a synthetic peptide of myelin proteolipid protein. *J Neuropathol Exp Neurol* 49: 468-479.
- Sospedra M & Martin R (2005) Immunology of multiple sclerosis. *Annu Rev Immunol* 23: 683-747.
- Stevens AR, Kilpatrick T, Willaert E & Capron A (1977) Serologic analyses of cell-surface antigens of *Acanthamoeba* spp. with plasma membrane antisera. *J Protozool* 24: 316-324.
- Storey MV, Winiiecka-Krusnell J, Ashbolt NJ & Stenstrom TA (2004) The efficacy of heat and chlorine treatment against thermotolerant *Acanthamoebae* and *Legionellae*. *Scand J Infect Dis* 36: 656-662.
- Stromnes IM, Cerretti LM, Liggitt D, Harris RA & Goverman JM (2008) Differential regulation of central nervous system autoimmunity by T(H)1 and T(H)17 cells. *Nat Med* 14: 337-342.
- Tan B, Weldon-Linne CM, Rhone DP, Penning CL & Visvesvara GS (1993) *Acanthamoeba* infection presenting as skin lesions in patients with the acquired immunodeficiency syndrome. *Arch Pathol Lab Med* 117: 1043-1046.
- Tanaka Y, Suguri S, Harada M, Hayabara T, Suzumori K & Ohta N (1994) *Acanthamoeba*-specific human T-cell clones isolated from healthy individuals. *Parasitol Res* 80: 549-553.
- Thomas V, McDonnell G, Denyer SP & Maillard JY (2009) Free-living amoebae and their intracellular pathogenic microorganisms: risks for water quality. *FEMS Microbiol Rev*.
- Toney DM & Marciano-Cabral F (1998) Resistance of *Acanthamoeba* species to complement lysis. *J Parasitol* 84: 338-344.
- Tuohy VK, Lu Z, Sobel RA, Laursen RA & Lees MB (1989) Identification of an encephalitogenic determinant of myelin proteolipid protein for SJL mice. *J Immunol* 142: 1523-1527.

- Turner NA, Harris J, Russell AD & Lloyd D (2000) Microbial differentiation and changes in susceptibility to antimicrobial agents. *J Appl Microbiol* 89: 751-759.
- Ushuplich V, Mileusnic D & Johnson M (2004) Pathologic quiz case. Progressive fatal encephalopathy in an immunosuppressed patient with a history of discoid lupus erythematosus. Subacute granulomatous meningoencephalitis (*Acanthamoeba culbertsoni*). *Arch Pathol Lab Med* 128: e109-111.
- Waldner H, Collins M & Kuchroo VK (2004) Activation of antigen-presenting cells by microbial products breaks self tolerance and induces autoimmune disease. *J Clin Invest* 113: 990-997.
- Walochnik J, Aichelburg A, Assadian O, Steuer A, Visvesvara G, Vetter N & Aspöck H (2008) Granulomatous amoebic encephalitis caused by *Acanthamoeba amoebae* of genotype T2 in a human immunodeficiency virus-negative patient. *J Clin Microbiol* 46: 338-340.
- Willaert E & Stevens AR (1976) Indirect immunofluorescent identification of *Acanthamoeba* causing meningoencephalitis. *Pathol Biol (Paris)* 24

IntechOpen



Non-Flavivirus Encephalitis

Edited by Dr. Sergey Tkachev

ISBN 978-953-307-720-8

Hard cover, 360 pages

Publisher InTech

Published online 16, November, 2011

Published in print edition November, 2011

This book covers the different aspects of non-flavivirus encephalitis of different etiology. The first section of the book considers general problems of epidemiology such as study of zoonotic and animal vectors of encephalitis causative agents and methods and approaches for encephalitis zoonoses investigations. The members of different virus species are known to be the causative agents of encephalitis, so the second section of the book is devoted to these viral pathogens, their epidemiology, pathology, diagnostics and molecular mechanisms of encephalitis development by such viruses as HIV/SIV, herpes simplex virus type 1 and equine herpesvirus 9, measles virus, coronaviruses, alphaviruses and rabies virus. The next section of the book concerns the study of protozoan pathogens such as toxoplasma and amoebae. The last section of the book is devoted to multicellular pathogen as human *Filaria Loa Loa* - a filarial worm restricted to the West Africa.

How to reference

In order to correctly reference this scholarly work, feel free to copy and paste the following:

Chandirasegaran Massilamany and Jay Reddy (2011). Autoimmunity in the Mediation of Granulomatous Amoebic Encephalitis: Implications for Therapy, *Non-Flavivirus Encephalitis*, Dr. Sergey Tkachev (Ed.), ISBN: 978-953-307-720-8, InTech, Available from: <http://www.intechopen.com/books/non-flavivirus-encephalitis/autoimmunity-in-the-mediation-of-granulomatous-amoebic-encephalitis-implications-for-therapy>

INTech
open science | open minds

InTech Europe

University Campus STeP Ri
Slavka Krautzeka 83/A
51000 Rijeka, Croatia
Phone: +385 (51) 770 447
Fax: +385 (51) 686 166
www.intechopen.com

InTech China

Unit 405, Office Block, Hotel Equatorial Shanghai
No.65, Yan An Road (West), Shanghai, 200040, China
中国上海市延安西路65号上海国际贵都大饭店办公楼405单元
Phone: +86-21-62489820
Fax: +86-21-62489821

© 2011 The Author(s). Licensee IntechOpen. This is an open access article distributed under the terms of the [Creative Commons Attribution 3.0 License](https://creativecommons.org/licenses/by/3.0/), which permits unrestricted use, distribution, and reproduction in any medium, provided the original work is properly cited.

IntechOpen

IntechOpen