

We are IntechOpen, the world's leading publisher of Open Access books Built by scientists, for scientists

6,900

Open access books available

185,000

International authors and editors

200M

Downloads

Our authors are among the

154

Countries delivered to

TOP 1%

most cited scientists

12.2%

Contributors from top 500 universities



WEB OF SCIENCE™

Selection of our books indexed in the Book Citation Index
in Web of Science™ Core Collection (BKCI)

Interested in publishing with us?
Contact book.department@intechopen.com

Numbers displayed above are based on latest data collected.
For more information visit www.intechopen.com



Virology and Pathology of Encephalitis in Alien Hosts by Neurotropic Equine Herpesvirus 9

Hideto Fukushi and Tokuma Yanai
Gifu University
Japan

1. Introduction

Herpesviruses occasionally cause lethal infection in alien hosts by interspecies transmission such as B virus infection in humans from Macaques and pseudorabies virus infection in various animals from pigs. Most of the infection can be characterized as lethal encephalitis. One of typical examples is equine herpesvirus 9 (EHV-9), also called as gazelle herpesvirus 1 (GHV-1), which was isolated from enzootic encephalitis of Thomson’s gazelles (*Gazella thomsoni*) in 1993 (Fukushi et al., 1996, Yanai et al., 1998). EHV-9 infection has been reported in non-equid species such as Thomson’s gazelles, a reticulated giraffe (*Giraffa camelopardalis reticulata*) (Hoenerhoff et al., 2006), and a polar bear (*Ursus maritimus*) (Donovan et al., 2006). Experimental infections have also been investigated including domestic horses, pigs, cattle, and goats, companion animals including cats and dogs and common marmosets (*Callithrix jacchus*) (Section 3). These interspecies or cross-species infections can be characterized as viral lethal and inapparent encephalitis (Table 1).

Animals	Clinical symptoms	Lesions
Thomson’s gazelles, giraffe, Polar bear, goats, cats, dogs, hamsters, mice, rats, marmosets	Lethal Infection with neurological symptoms	meningoencephalitis. Neuronal degeneration and necrosis with intranuclear inclusion bodies, gliosis, cuffing
Horse, cattle, pigs	Fever, light depression	
Onager	Abortion	

Table 1. A list of animals infected with EHV-9

1.1 Epizootiology of encephalitis in a herd of Thomson's gazelles

Epizootic encephalitis occurred in a herd of Thomson's gazelles kept in a zoo in 1993. Twelve Thomson's gazelles were first introduced into the zoo in 1992. Then eight normal newborns and one malformed newborn have been delivered. Ten gazelles died of injury by various causes. The herd consisted of ten Thomson's gazelles at the outbreak. A first

occurrence was sudden death of one gazelle, and then others showed neurological symptoms in turn over 2-week period (Fig. 1). The neurological symptoms in the gazelles were depression, incoordination, nystagmus, and convulsion. Laboratory tests showed occult blood and albumin in the urine samples. Seven out of the nine gazelles died. No evidence of infection was found in this foal. The other two gazelles recovered. The remaining one was a newborn that died of malnutrition, because the sick mother gazelle refused nursing. One of the recovered gazelles delivered a healthy neonate two months later. All dead gazelles did not have apparent changes at necropsy. Microscopically, all dead gazelles except the foal of malnutrition had nonsuppurative encephalitis, which characterized by neuronal degeneration and intracellular inclusion bodies (Fukushi et al., 1996, Yanai et al., 1998).

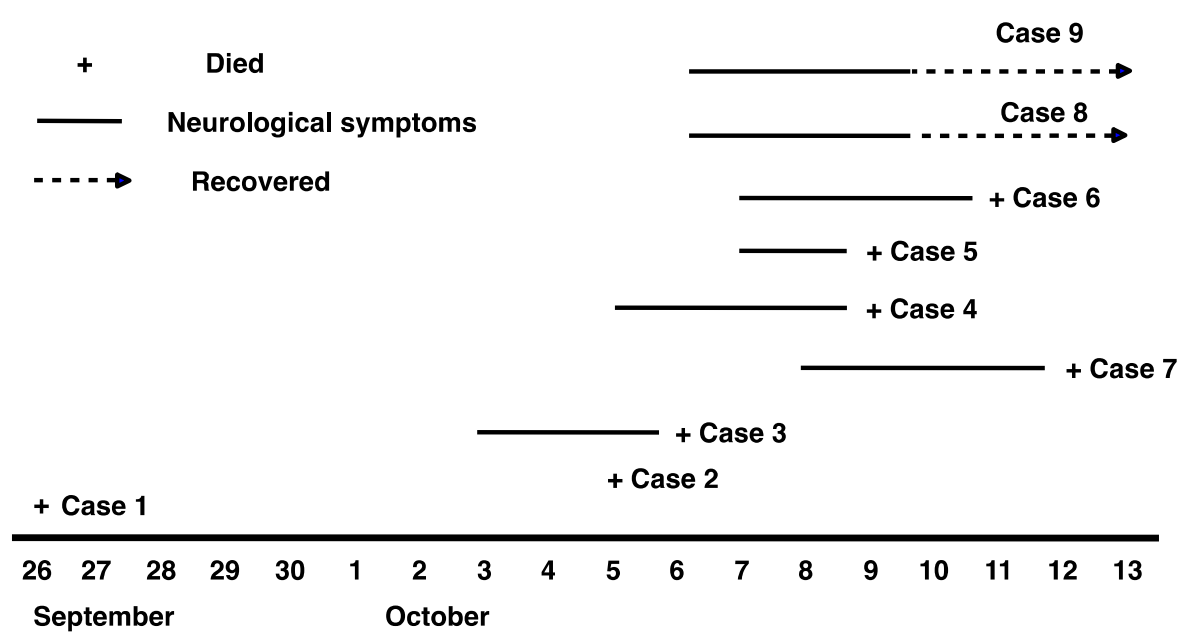


Fig. 1. Outbreak of lethal enzootic encephalitis in Thomson's gazelles

Homogenates of the brain, spinal cord, kidney, liver, lung and spleen were inoculated into Madin-Darby bovine kidney (MDBK) cells. Cells inoculated with the brain homogenate showed cytopathic effect characterized as syncytium formation accompanying nuclear inclusion bodies and detachment (Fig. 2), indicating the isolation of a virus. Physicochemical characterization of the isolate showed that the isolate was chloroform sensitive DNA virus of about 150 to 200 nm diameter. Considering the characteristics, the isolate was identified as a herpesvirus. Serum neutralization tests using antisera against pseudorabies virus, bovine herpesvirus 1, malignant catarrhal fever virus, and equine herpesvirus 1 (EHV-1) indicated that the isolated virus should be EHV-1 or EHV-1 related virus. Comparing DNA fingerprints and nucleotide sequences of a glycoprotein B gene and a glycoprotein G gene, the isolate should be regarded as a new herpesvirus, gazelles herpesvirus 1 (GHV-1) at first (Fukushi et al., 1996). DNA fingerprints of GHV-1 were different from those of EHV- 1, EHV-4, and EHV-8, although GHV-1 cross-reacted with EHV-1 and EHV-4 in neutralization tests. Southern analysis indicated that GHV-1 shared sequence homology with EHV-1.

Sequences of gB and gG homologue genes of GHV-1 are closer to EHV-1 than to other equine herpesviruses including EHV-8. Therefore GHV-1 was recognized as a new member of equine herpesvirus, equine herpesvirus 9 (EHV-9).

It should be noted that a zebra kept in the same field with the gazelles had neutralizing antibody to GHV-1 but not to EHV-1 in neutralization tests examined several months after the episode.

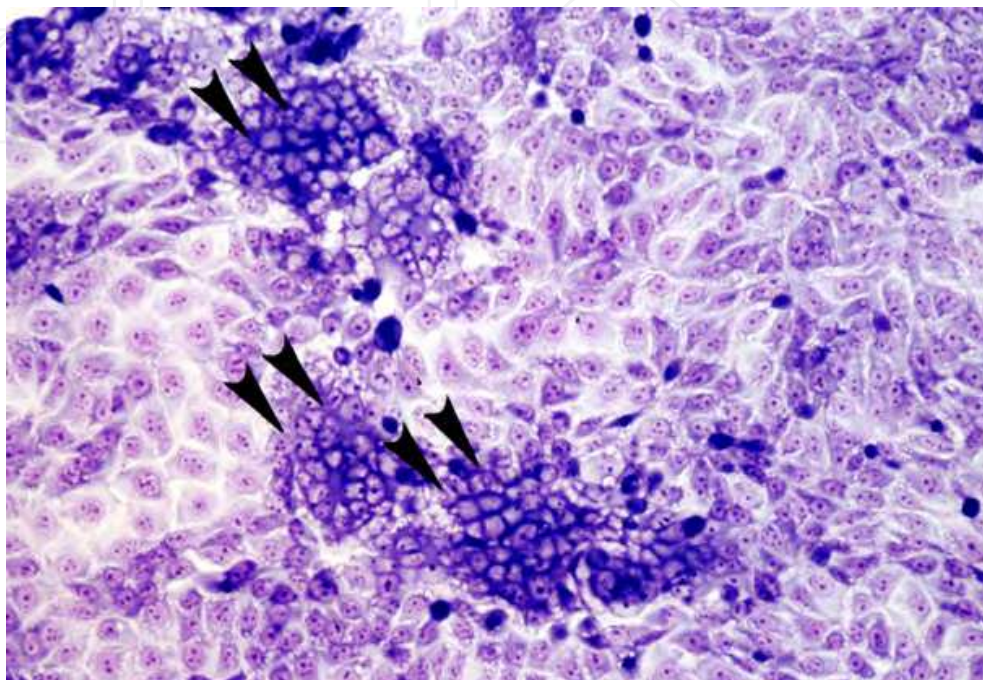


Fig. 2. CPE observed in MDBK cells inoculated with brain homogenate

1.2 A sporadic encephalitis in a giraffe

An 18-month-old male reticulated giraffe (*Giraffa camelopardalis reticulata*) housed in a zoo presented with a one and a half day history of incoordination, stumbling, and abdominal pain and died (Hoenerhoff et al., 2006). Nonsuppurative encephalitis was histopathologically found in the brain of giraffe. Several zebras (*Equus burchelli*), which were apparently healthy, were housed in a pen with the giraffe. Herpesvirus was isolated from the reticulated giraffe. The isolated virus was identified as EHV-1 by PCR and monoclonal antibody assay at first. The giraffe had been housed with a group of zebras that were serologically positive for EHV-1. Considering the situation and histopathological findings, there was a possibility that the isolate could be EHV-9. Several gene sequences of the giraffe virus were almost identical to those of EHV-9 (Samy et al., 2008). Therefore the giraffe virus was EHV-9.

1.3 Meningoencephalitis in a polar bear

A 12-year-old female polar bear (*Ursus maritimus*) developed a sudden onset of neurological symptoms in 2007 (Schrenzel et al., 2008; Donovan et al., 2009). Nonsuppurative pleocytosis of cerebrospinal fluid was observed. The bear was euthanized. Multifocal, random nonsuppurative meningoencephalitis was microscopically found involving most prominently the rostral cerebral cortex, as well as the thalamus, midbrain, and rostral

medulla. Lesions consisted of inflammation, neuronal necrosis, gliosis, and both neuronal and glial basophilic intranuclear inclusion bodies. PCR for the herpesvirus DNA polymerase gene segment was positive on DNA extracted from frozen tissues and from paraffin-embedded fixed brain. The nucleotide sequence of the PCR product indicated the presence of EHV-9, which was further confirmed by following PCR for the EHV-9 gB gene segment. Schrenzel et al. (2008) described that EHV-9 had been detected at the same zoological garden in 2 Grevy's zebras (*Equus grevyi*) from the same herd, which had been relocated near the polar bears before the polar bear case. One of the infected Grevy's zebras was 8 days old and had viral interstitial pneumonia; the other was an adult with rhinitis and intranuclear inclusion bodies. Both zebras were immunocompromised as a result of other concurrent conditions.

1.4 Abortion in an onager

Schrenzel et al. (2008) described that EHV-9 was found by a retrospective analysis of tissues from an aborted Persian onager (*Equus hemionus onager*) fetus from a zoological park in Washington, DC (Montali et al., 1985). The onager fetus was aborted after the dam came in close proximity to a Grevy's zebra. A herpesvirus was isolated from the fetus. The virus was identified as EHV-1 based on DNA fingerprinting and serological analyses (Montali et al., 1985). PCR and DNA sequencing analyses of the DNA polymerase showed that the zebras and the onager had an EHV-9 strain identical to that found in the polar bear (Schrenzel et al., 2008).

1.5 Burchell's zebras from the Serengeti ecosystem

Zebras have been suspected to be the source of EHV-9 infection. To prove the hypothesis, serological analysis was examined by using 43 sera from Burchell's zebras (*Equus burchelli*) and 21 Thomson's gazelles from the Serengeti ecosystem for neutralizing antibodies (Borchers et al., 2008). Seven zebra sera were positive for EHV-1 and EHV-9. The trigeminal ganglia of 17 other Burchell's zebras and one Thomson's gazelles were examined by PCR for EHV-9 gB and EHV-1 ICP0 genes. One zebra ganglion was positive for EHV-9 by PCR and confirmed by sequencing. These results suggest that the Burchell's zebras were latently infected by EHV-9.

2. Virology

2.1 Virus genome

A whole genome sequence of EHV-9 has been determined as 148371 base pairs (bp) (accession number AP010838). The genome encodes at least 80 open reading frames (ORF) (Fig. 3, Table 2). There is no large deletion and insertion comparing with EHV-9 and EHV-1 genomes. All of the ORFs in EHV-1 are conserved in EHV-9 genome. The EHV-9 ORFs have been serially numbered as homologues in EHV-1 genome (Telford et al., 1992). Identities of each ORF to EHV-1 ORFs range from 86% to 99% (Table 2). ORFs showing higher identity (99 %) are glycoprotein K (ORF6), UL37 tegument protein (ORF23), VP26 capsid protein (ORF25), glycoprotein B (ORF33), thymidine kinase (ORF38), a major capsid protein (ORF42), DNA packaging terminase subunit 1 (ORF44_47), a nuclear protein UL3 (ORF60) and glycoprotein E (ORF74). ORFs showing lower identity (86 %) to EHV-1 include UL45 tegument/envelope protein (ORF15) and UL4 nonstructural protein (ORF58).

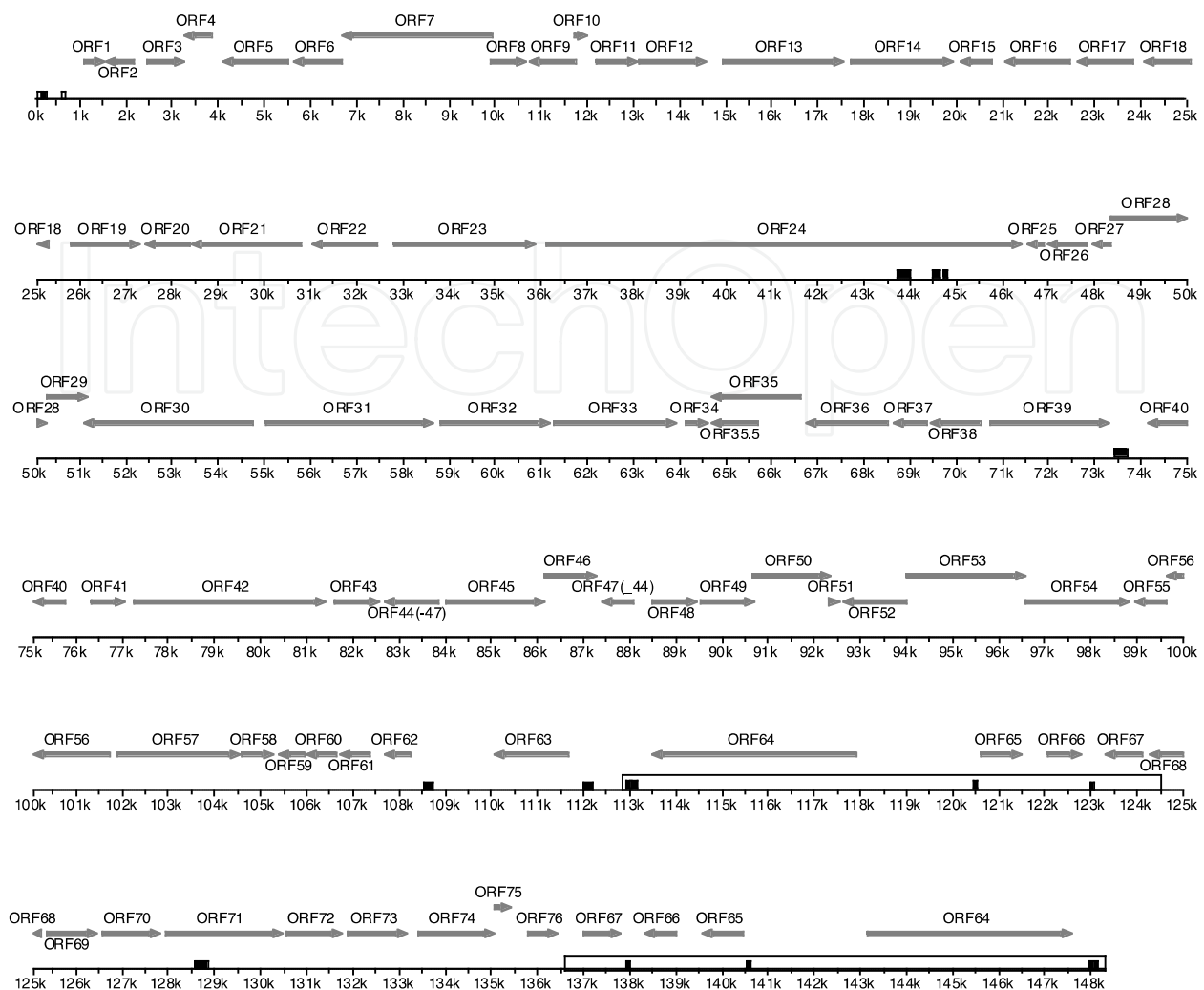


Fig. 3. Scheme of the EHV-9 genome based on the complete nucleotide sequence (AP010838)

ORF	Codons	Identity (%)	HSV-1	Predicted or confirmed functions
1	202	96	-	C-terminal hydrophobic domain
2	204	93	-	C-terminal hydrophobic domain
3	257	93	-	
4	200	93	UL55	
5	470	95	UL54	Post-translational regulator of gene expression
6	343	99	UL53	Glycoprotein (gK)
7	1079	95	UL52	Component of DNA helicase-primase complex; primase
8	245	97	UL51	Tegument protein
9	326	94	UL50	Deoxyuridine triphosphatase
10	100	95	UL49A	Envelope protein

ORF	Codons	Identity (%)	HSV-1	Predicted or confirmed functions
11	305	93	UL49	Tegument protein, VP22
12	449	97	UL48	Tegument protein; transactivator of immediate-early genes
13	868	93	UL47	Tegument protein
14	744	94	UL46	Tegument protein
15	219	86	UL45	Tegument/envelope protein
16	468	96	UL44	Envelope glycoprotein (gC); role in cell entry
17	401	96	UL43	Probable integral membrane protein
18	406	97	UL42	Processivity subunit of replicative DNA polymerase
19	497	96	UL41	Tegument protein; host shut-off factor
20	323	98	UL40	Small subunit of ribonucleotide reductase
21	790	97	UL39	Large subunit of ribonucleotide reductase
22	465	97	UL38	Capsid protein; component of intercapsomeric triplex
23	1021	99	UL37	Tegument protein
24	3439	96	UL36	Very large tegument protein
25	119	99	UL35	Capsid protein; located on tips of hexons, VP26
26	275	95	UL34	Membrane-associated phosphoprotein
27	139	95	UL33	Role in DNA packaging
28	620	93	UL32	Role in DNA packaging
29	326	98	UL31	
30	1220	97	UL30	Catalytic subunit of replicative DNA polymerase
31	1209	98	UL29	Single-stranded DNA-binding protein
32	775	98	UL28	DNA packaging terminase subunit 2
33	980	99	UL27	Envelope glycoprotein (gB); role in cell entry
34	160	93	-	Unknown
35	646	97	UL26	N-terminal protease domain acts in capsid maturation and is a capsid protein; C-terminal domain is the minor capsid scaffold protein
35.5	329	96	UL26.5	Major capsid scaffold protein
36	587	97	UL25	DNA packaging tegument protein

ORF	Codons	Identity (%)	HSV-1	Predicted or confirmed functions
37	272	96	UL24	Nuclear protein, related to neurovirulence
38	352	99	UL23	Thymidine kinase
39	850	96	UL22	Envelope glycoprotein (gH); complexes with gL; role in cell entry
40	530	97	UL21	Tegument protein
41	239	98	UL20	Integral membrane protein; role in virion egress
42	1376	99	UL19	Major capsid protein; component of hexons and pentons
43	314	98	UL18	Capsid protein; component of intercapsomeric triplex
44_47	734	99	UL15	DNA packaging terminase subunit 1
45	706	97	UL17	DNA packaging tegument protein
46	370	97	UL16	Tegument protein
48	318	93	UL14	Tegument protein
49	595	96	UL13	Tegument protein; probable serine-threonine protein kinase
50	565	96	UL12	Deoxyribonuclease; role in maturation/packaging of DNA
51	73	91	UL11	Myristylated tegument protein; role virion envelopment
52	451	98	UL10	Envelope glycoprotein (gM)
53	887	98	UL9	Replication origin-binding helicase
54	751	95	UL8	Component of DNA helicase-primase complex
55	303	96	UL7	Tegument progein
56	753	97	UL6	Minor capsid protein; role in DNA; role in DNA packaging
57	881	97	UL5	Component of DNA helicase-primase complex; helicase
58	224	86	UL4	Nuclear protein
59	182	87	-	Unknown
60	212	99	UL3	Nuclear protein
61	313	97	UL2	Uracil-DNA glycosylase
62	218	97	UL1	Envelope glycoprotein (gL); complexes with gH
63	533	90	RL2	Transcriptional regulator, ICP0

ORF	Codons	Identity (%)	HSV-1	Predicted or confirmed functions
64	1475	92	RS1	Transcriptional regulator, ICP4
65	291	94	US1	Regulatory protein ICP22
66	234	94	US10	Virion protein
67	269	94	-	Virulence determinant virion protein
68	296	93	US2	Virion protein
69	383	95	US3	Serine-threonine protein kinase
70	411	92	US4	Envelope glycoprotein (gG)
71	830	91	US5	Envelope glycoprotein (gp300)
72	402	97	US6	Envelope glycoprotein (gD); role in cell entry
73	425	94	US7	Envelope glycoprotein (gI); complexes with gE in Fc receptor
74	550	99	US8	Envelope glycoprotein (gE); complexes with gI in Fc receptor
75	130	97	US8A	Unknown
76	219	89	US9	Tegument protein

Identity was evaluated by protein-protein BLAST analysis.
-: there is no homologue in herpes simplex virus 1 (HSV-1) genome
Table 2. Characteristics of EHV-9 proteins

2.2 Host range in vitro and in nature

EHV-9 can be propagated by fetal equine kidney cells (FEK), Madine-Darby bovine kidney cells (MDBK), rabbit kidney cells (RK-13), murine fibroblast L929 cells, and human HeLa 229 cells. Cytopathic effects varied in each cell line. Lytic CPE is observed in FEK, RK-13 and HeLa 229, while syncytium formation is observed in MDBK (Fig.). EHV-9 can be also propagated in neural cells derived from a fetal equine brain as well as a fetal murine brain. EHV-9 has been isolated from Thomson's gazelles, zebras (Borchers et al., 2008; Schrenzel et al., 2008), giraffes (Samy et al., 2009), polar bears (Schrenzel et al., 2008; Donovan et al., 2009) and onager (Schrenzel et al., 2008) as described in Section 1. Epizootiologically all of the cases in zoo animals associated with the presence of zebras. These data indicates that Burchell's zebra and other zebras might be a natural host of EHV-9 in nature. EHV-9 can infect several animals experimentally. The experimental hosts include horse, goat, pig, cattle, hamster, mouse, rat, guineapig, dog, cat, and marmosette as described in the section 3.

2.3 Phylogenic relatedness to other related herpesviruses

The phylogenic tree constructed by using a part of glycoprotein B gene sequence indicates three groups of EHV-9, EHV-1 in horses and EHV-1 in zoo animals (Fig. 4). EHV-1 derived from zoo animals might be considered as another type of equid herpesvirus. Unfortunately equine herpesvirus 8 glycoprotein G sequence is not available at present.

Sequences of glycoprotein G in EHV-1 derived from zoo animals would provide a clue to resolve the problem.

EHV-9 strain P19, prototype of EHV-9, is closely related to the strain 1220 which was derived from a Burcell's zebra (Borchers et al., 2008), while the isolate 4 derived from the polar bear associated with Grevy's zebra (Schrenzel et al., 2008) is distantly related to the other EHV-9s. These data suggest the EHV-9 would be strongly related to each species of zebras. Of cause, further research should be examined to prove the hypothesis.

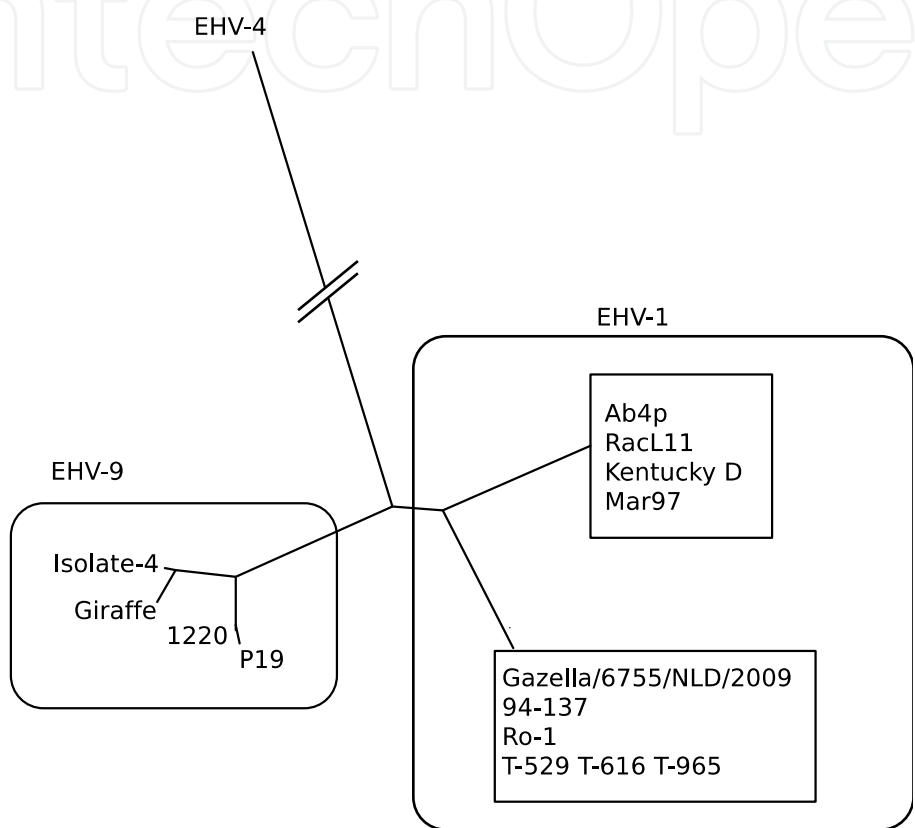


Fig. 4. A phylogenc tree of EHV-9 and other related viruses based on the glycoprotein B gene segment. The phylogenetic tree was constructed by using PHYLIP package (Felsenstein, 2005). Accession numbers are as follows: EHV-9 P19 (D49800), 1220 (EU087294), Giraffe (AB439723), Isolate-4 (EU717150); EHV-1 Ab4p (AY665713), RacL11 (X95374), Kentucky D (AB279609), Mar97 (DQ095871), Gazella/6755/NLD/2009 (HM216495), 94-137 (AB280624), Ro-1 (DQ095872), T-529 (AB280630), T-616 (EU087295), T-965 (DQ095873); EHV-4 (M26171).

3. Pathology

3.1 Lethal Encephalitis in zoo, domestic and companion animals, and experimental small animals

EHV-9 caused lethal encephalitis in several animals such as Thomson’s gazelles, giraffes, and polar bears naturally and goats, cats, dogs, mice, rats, hamster and marmosets experimentally. All of these infections can be regarded as encephalitis with neuronal degeneration, perivascular cuffing and gliosis. Histopathological characteristics will be described.

3.1.1 Thomson's gazelles

An outbreak of acute encephalitis occurred in a herd of Thomson's gazelle in a Japanese zoo. Seven of 9 gazelle died with or without neurological symptoms within a 3-week period as described in the section 1.1 (Fig. 5A). All animals had nonsuppurative encephalitis characterized by necrosis and degeneration of neurons (Fig. 5B), gliosis and perivascular aggregates of lymphocytes (Fig. 5C) in the cerebrum (Yanai et al., 1998). Five cases had intranuclear inclusion bodies in neurons compatible with those of herpesvirus. Immunohistochemically, a positive reaction to EHV-1 antigen was demonstrated in neurons in the necrotic areas of the cortex in all cases. The neuropathology of EHV-9 infection clearly differed from EHV-1-induced encephalitis in the horse, which is characterized by vasculitis, thrombosis, ischemia, and lack of intranuclear inclusion in neurons (Wada et al., 1991).

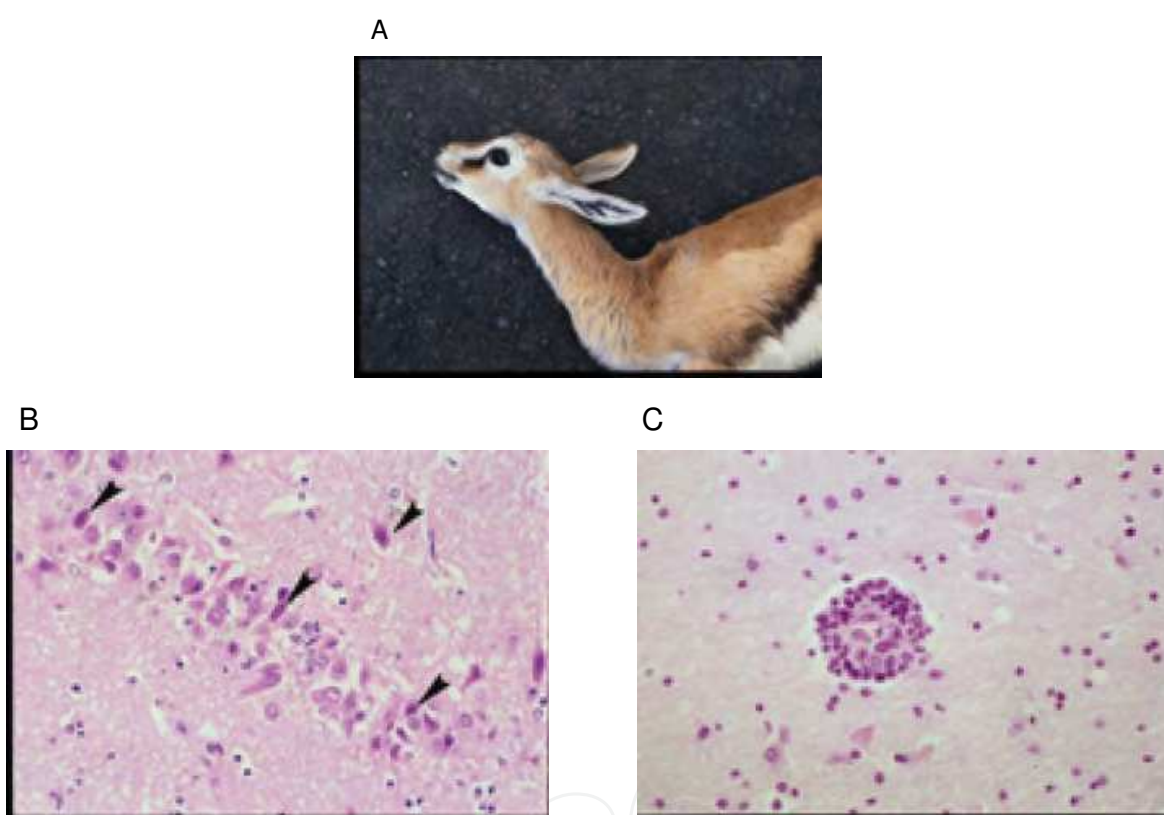


Fig. 5. A: A dead Thomson's gazelle. B: Neuronal necrosis with frequent nuclear inclusion formation. HE. C: Perivascular aggregates of lymphocytes in affected brain. HE.

3.1.2 Giraffe

Hoenerhoff et al. (2006) described as follows. The giraffe was in good body condition. There was a traumatic wound on the dorsal aspect of the tail base. There was a focal area of malacia within the cerebrum on cut section. There were no other lesions noted on gross necropsy examination.

Histopathological examination included sections of brain; cervical, thoracic, and lumbar spinal cord; heart; lungs; liver; spleen; kidneys; adrenal glands; rumen; abomasum; jejunum; ileum; and colon. There was severe multifocal nonsuppurative meningoencephalitis within the white and gray matter of the cerebral cortex, hippocampus, thalamus, midbrain, and medulla

oblongata, and was most severe in the thalamus and ventrolateral portions of the cerebral cortex. Lesions were characterized by multifocal perivascular cuffs composed of moderate numbers of lymphocytes and histiocytes. The endothelium of affected blood vessels was swollen, and there were numerous microglial cell foci distributed diffusely in the gray and white matter. Multifocal neuronal necrosis was most evident in the ventral portion of the cerebral hemispheres, and areas of neuronal necrosis were occasionally associated with characteristic herpetic eosinophilic intranuclear inclusions in neurons and astrocytes.

3.1.3 Polar bear

Donovan et al. (2009) described as follows. The polar bear was in good body condition. The meninges of the brain and spinal cord were diffusely congested. The caudodorsal lung lobes were edematous.

Histopathological findings were severe nonsuppurative meningoencephalitis, predominantly in the grey matter of the cerebrum. The most significantly affected region of the brain was the rostral telencephalon, particularly the rhinencephalon. Scattered regions of inflammation involved the olfactory bulbs, cerebrum, thalamus, midbrain, and rostral medulla. Inflammatory cells consisting of lymphocytes, plasma cells, macrophages, and fewer eosinophils formed perivascular cuffs within the meninges overlying the brain and Virchow-Robin spaces within the parenchyma, as well as more poorly delineated inflammatory cell infiltrates within the subjacent meninges, neuropil, and neuroparenchyma. Neuronal degeneration was characterized by peripheral localization or complete loss of Nissl substance, and neuronal necrosis consisted of cytoplasmic hyperosinophilia, loss of cytoplasmic detail, nuclear pyknosis, karyolysis, and karyorrhexis. Glial proliferation accompanied the inflammation, consisting of microgliosis and astrogliosis.

Within the nuclei of neurons and astrocytes, there were diffuse type and Cowdry type A inclusions. White matter tracts had random areas of vacuolation, axonal degeneration characterized by formation of axonal spheroids, demyelination, edema, and microglial and astrocytic gliosis. Additional histologic findings included mild, multifocal neutrophilic bronchiolitis, mild neutrophilic rhinitis, moderate pulmonary edema, mild lymphocytic myocarditis, and mild membranoproliferative glomerulonephritis.

3.1.4 Goats

Two young goats were inoculated intranasally with 10 ml of virus solution containing 5.25×10^6 PFU (Taniguchi et al., 2000a). These animals showed sudden neurological symptoms consisting of marked salivation, teeth grinding, convulsion, tremor and ataxia 8 days IP. One animal died 30 minutes after the onset of clinical signs and another was sacrificed 3 hours after the onset of teeth grinding and foamy salivation. Both animals had fulminant encephalitis characterized by neuronal degeneration and necrosis with intranuclear inclusion bodies (Fig. 6).

3.1.5 Carnivores

In carnivore cats and dogs got fulminant encephalitis via nasal route of inoculation with EHV-9, which suggested these animals to be fully susceptible to EHV-9 and that EHV-9 could cause fulminant encephalitis with high mortality in dogs and cats, as in gazelles and goats.

An acute lethal infection of EHV-9 was induced in cats by intranasal inoculation of 10^6 pfu (Yanai et al., 2003a). Four cats killed at 4, 5, 6 or 10 days after inoculation showed neurological signs consisting of hyper-excitability and aggressiveness, followed by tremors, occasional

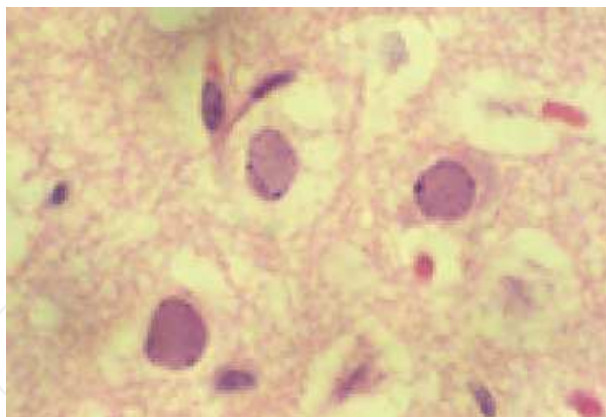


Fig. 6. Frequent intra-nuclear inclusion formation in the neuronal cells. HE stain.

convulsions, and depression. Histologically, the cats affected showed severe encephalitis characterized by neuronal degeneration and loss, intranuclear inclusions, perivascular aggregates of lymphocytes and gliosis in the cerebrum. The olfactory bulb and rhinencephalon were severely affected and collapsed, and eventually softened by complete destruction of both neuronal cells and glial cells. Using Double Label immunohistochemistry all cats showed proliferating astrocytes with double reactivities to both EHV-9 and GFAP, as well as EHV-9 antigen bearing neurons (Fig. 7A and B). These findings were most frequently observed in the intermediate stage of the infection (6th day post-inoculation by intranasal route) while in early stage of the infection (4th day post-inoculation by intranasal route), and 15th day of post-inoculation by intraperitoneal route, only small number of astrocytes showed reactivity to EHV-9. At the later stage (10th day post-ionculation), malacia was observed in the cortex together with marked decrease in the number of astrocytic cells showing GFAP reactivity as well as neuronal number decreased by collapse.

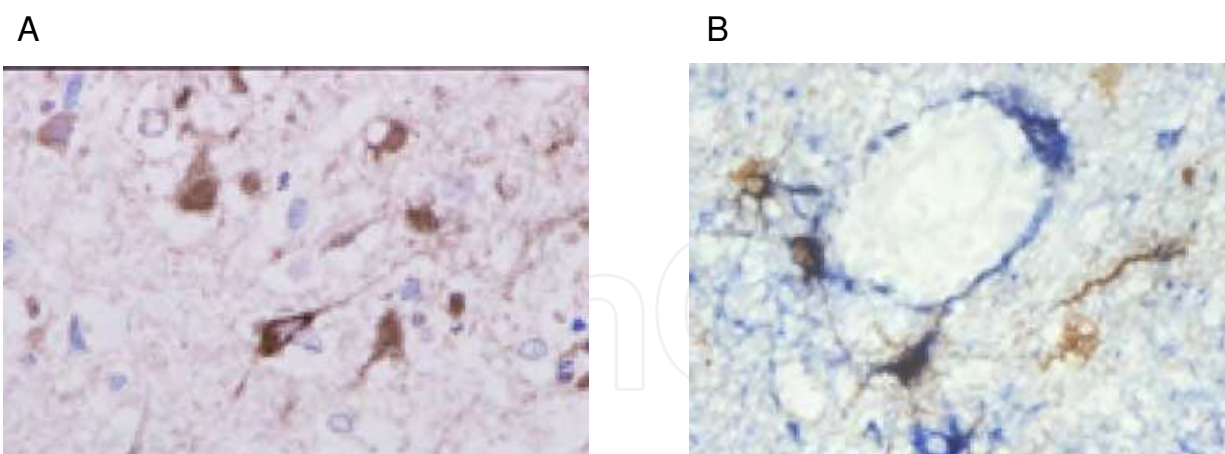


Fig. 7. A: Affected cat had encephalitis with EHV-9 antigen in the brain. IHC. ABC methods. B: Double Label immunohistochemistry showed proliferating astrocytes with double reactivities to both EHV-9 and GFAP, as well as EHV-9 antigen bearing neurons. ABC method.

EHV-9 was inoculated intranasally at 10^7 PFU in five dogs to assess its pathogenicity (Yanai et al., 2003b). Dogs affected showed weight loss, pyrexia, anorexia, and neurologic signs on the fourth day. The EHV-9 virus was recovered from the examined brain. Histologically, dogs had a fulminant encephalitis characterized by severe neuronal degeneration and loss,

with intranuclear inclusions, glial reactions (Fig. 8A), perivascular aggregates of lymphocytes, and multi-focal perivascular hemorrhages (Fig. 8B). The olfactory bulb and the frontal and temporal lobes were predominantly affected. Immunohistochemistry revealed reactivity for EHV-9 antigens in neurons (Fig. 8C).

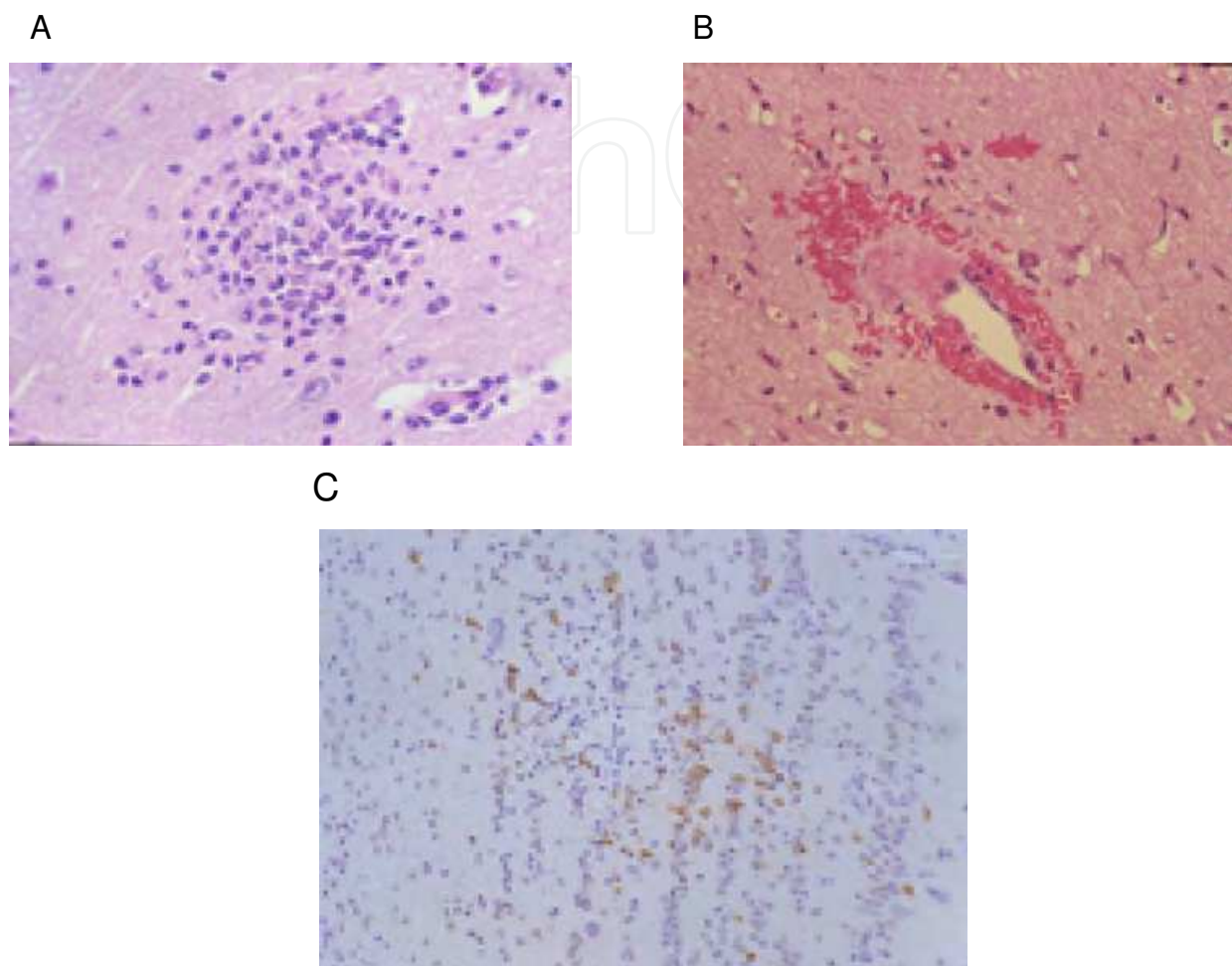


Fig. 8. A: There were frequent positive reaction to EHV-9 antigen in the neuronal cells in the olfactory bulb in a dog inoculated with EHV-9 intra-nasally. IHC. B: There were prominent glial reactions in the brain. HE stain. C: There were occasional perivascular hemorrhages in the affected brain. HE stain.

3.1.6 Rodents

In suckling mice and rats inoculated intra-cerebrally with 10^2 to 10^5 plaque-forming units (PFU) of cell-free viral suspension, growth deterioration (Fig. 9) and neurological symptoms, including depression and seizures were observed, and inoculated animals died within 8 days of inoculation (Fukushi et al., 1997). The brain of dead animal had severe neuronal degeneration and necrosis accompanied by numerous intranuclear inclusion bodies characteristic of herpesviruses.

In mice, rats and hamsters inoculated with 10^2 to 10^6 PFU via intranasal route (Fukushi et al., 1997). The animals had neurological signs, including depression or convulsion, and died of acute encephalitis characterized by neuronal degeneration and necrosis with intranuclear inclusion bodies (Fig. 10A and B). Mortality rates were 100% with 10^4 PFU and 33% with 10^2

PFU in young mice (Fukushi et al., 1997). Although the morphological features of EHV-9-induced encephalitis was common in rodents, the hamsters were thought to be more susceptible to EHV-9 via nasal route (Taniguchi et al., 2000a).

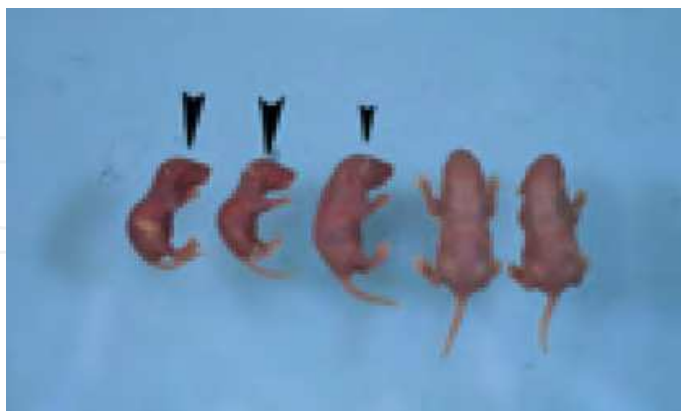

Fig. 9. A: Inoculate suckling rats (arrow heads) showed growth deterioration.

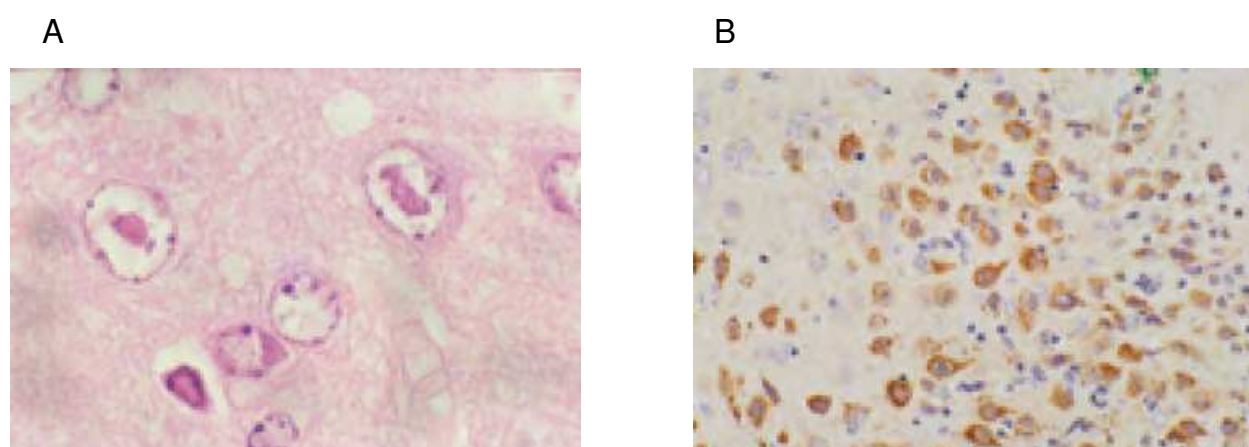


Fig. 10. A: There were frequent intranuclear inclusions in degenerating neuronal cells. A mouse inoculated with EHV-9 intra-nasally. HE stain. B: Most neuronal cells with inclusion body had positive reaction for EHV-9 antigen. A mouse inoculated with EHV-9 intra-nasally. IHC.

3.2 Inapparent encephalitis in several experimental hosts

EHV-9 also cause inapparent encephalitis in horses, cattle and pigs. Although animals inoculated with EHV-9 showed high fever and slight depression, the animals did not show neurological symptoms. These inapparent encephalitis were characterized as meningoencephalitis, gliosis and cuffing with EHV-9 antigen bearing neural cells. Histopathological characteristics will be described and discussed.

3.2.1 Horses

Two young adult horses were inoculated intranasally with 10 ml of virus solution containing 10^7 PFU and euthanized two weeks after inoculation (Taniguchi et al., 2000b). The animals showed no clinical symptom except a moderate fever (higher than 39°C). The brains showed a moderate degree of nonsuppurative encephalitis characterized by

perivascular aggregates of lymphocytes (Fig. 11A) and gliosis (Fig. 11B). Neither neuronal necrosis nor intranuclear inclusions were observed in affected horses.

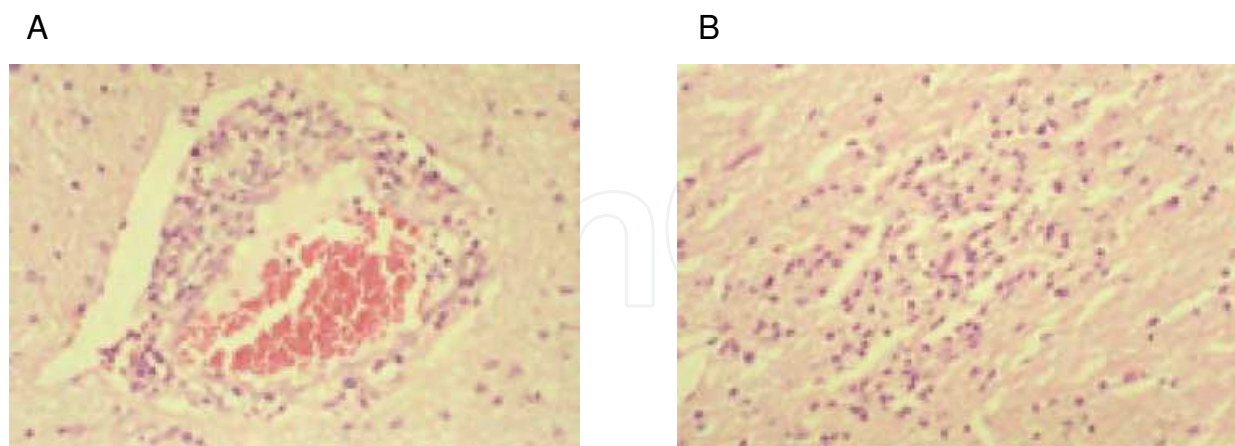


Fig. 11. A: Perivascular aggregates of lymphocytes in the affected brain. HE stain. B: Glial cells reaction was observed. HE stain.

3.2.2 Cattle

In cattle seven calves were inoculated intranasally with 10^5 and 10^7 PFU of the EHV-9 (El-Habashi et al., 2011). Three animals showed brain lesions consisting of glial reactions and perivascular aggregates of lymphocytes in the olfactory bulb and the frontal and temporal lobes. Additionally, the animal inoculated with 10^7 PFU showed neuronal degeneration and loss, as well as nuclear inclusions compatible with herpesvirus. EHV-9 was isolated from the brain of a calf and the lungs of two calves. The results suggested that cattle are susceptible to experimental infection with EHV-9 and at risk from natural infection from reservoir hosts.

3.3 Neuropathogenesis of EHV-9 by experimental infections

The infectivity and pathology of various routes including nasal, ocular, oral, intravenous (IV), or peritoneal routes of experimental infection were studied in hamsters (El-Habashi et al., 2010a). Clinically, all animals inoculated by the nasal route and ~25% inoculated by the oral and peritoneal routes showed neurological signs on days 3, 6 and 9 post-inoculation (PI), respectively. Neurological signs were not observed in animals administered EHV-9 by the IV and ocular routes. With the exception of animals administered EHV-9 by the IV route, all infected animals had lymphocytic meningoencephalitis. Although there were a number of differences in the severity and distribution of the lesions depending on the route of inoculation, the basic features of lymphocytic meningoencephalitis caused by EHV-9 were common. Lesions consisted of neuronal necrosis, perivascular aggregates of lymphocytes, plasma cells, and neutrophils, gliosis, intranuclear inclusion bodies, and diffuse lymphocytic infiltrates in the meninges. Viral antigen was detected in degenerated neurons in infected animals inoculated by the nasal, ocular, oral and peritoneal routes. The distribution of EHV-9 antigen was somewhat dependent upon inoculation route. There were no microscopic abnormalities nor viral antigen in animals treated by the IV route. This study provides new data about experimental EHV-9 infection in hamsters through routes other than the IV route. These results suggest that in the animals infected by the oral, ocular and peritoneal routes, EHV-9 might travel to the brain through nerves, other than by the olfactory route, after initial propagation at the site of viral entry.

To access transmission of EHV-9 in the nasal cavity and brain, a sagittal model using suckling hamsters was developed, and proved useful in detecting viral transmission as well as extension of pathological lesions using the sagittal section of the head (El-Habashi et al., 2010b). Suckling hamsters were inoculated intranasally with EHV-9, and were sacrificed at 6, 12, 18, 24, 36, 48 and 60 h PI. Sagittal sections of the whole heads were made to access viral kinetics and identify the progress of the neuropathological lesions. At 12-24 h PI the virus attached and propagated in the olfactory epithelium and migrated from one cell to another. At 48 h PI, the olfactory epithelium shows irregularity, necrosis, and erosion in the mucosa (Fig. 12 A), and immunohistochemistry showed encephalitis extending into the olfactory bulb, as well as virus antigen in the olfactory nerve. The trigeminal ganglion showed neuronal necrosis and neurophagia of the trigeminal ganglion cells at 48 h PI (Fig. 12B). One of the most striking findings was the presence of the viral antigen in the connection of the trigeminal sensory nerve root to the brain stem, the pons and medulla oblongata, as well as weak positive reactions in the trigeminal nerve at 60 h PI (Fig. 12C). These results suggested that the sagittal model using suckling hamsters might be useful in accessing the kinetics of neuro-virulent viruses, including EHV-9.

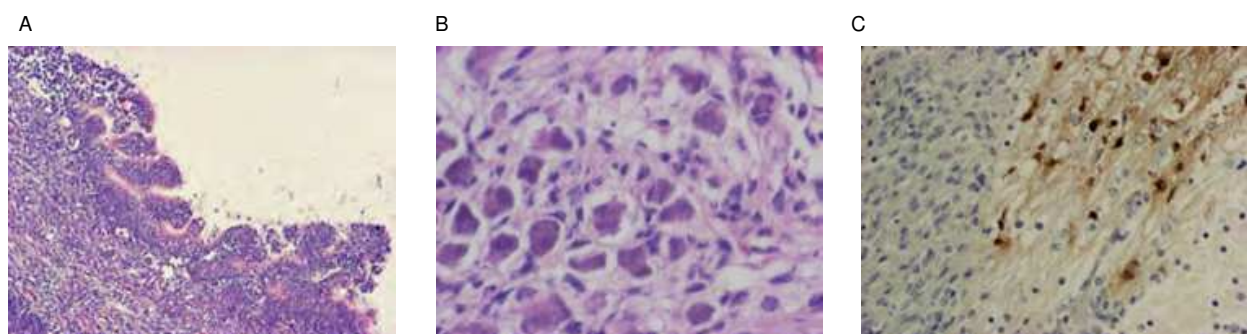


Fig. 12. A: At 48 h PI, the olfactory epithelium shows irregularity, necrosis, and erosion in the mucosa. HE stain. B: At 48 h PI, the trigeminal ganglion shows neuronal necrosis, neurophagia of the trigeminal ganglion cells. HE stain. C: Results of immunolabeling with EHV-9 antibody at 60 h PI. Presence of the viral antigen in the connection of the trigeminal sensory nerve root to the brain stem. IHC.

The kinetics and neuropathogenicity of equine herpesvirus 9 (EHV-9) were studied in hamsters by means of intraperitoneal inoculation (El-Nahass et al., 2011) (Fig. 13). Five-week-old Syrian hamsters and 5-day-old Suckling hamsters were inoculated with 50 and 15 μ l of 2×10^6 pfu/ml of EHV-9 virus solution, respectively. After inoculation, EHV-9 antigens were detected in the peritoneal macrophages, which were possibly the primary site of virus attachment and propagation at 6 h PI (Fig. 13B). At 12 h PI, the viral antigen was observed in both the abdominal ganglions (mainly the celiac ganglions) and the peripheral nerves derived from the spinal cord. The virus antigen was seen in the dorsal root (spinal) ganglions (Fig. 13C) and in different parts of the spinal cord especially the mid-lumbar and cervical spinal cord at 24 and 36 h PI respectively. At 96 h PI, the virus antigen was detected in the most caudal part of the brain as well as the intestinal myenteric plexuses. PCR conducted on the blood, spinal cord and brain samples revealed EHV-9 DNA in both the spinal cord, at 24 h PI, and in blood, at 36 h PI. Based on these results, EHV-9 possibly traveled from the myenteric plexus or abdominal ganglions via the peripheral nerves and spinal cord, and finally reached the brain after initial propagation in the abdominal macrophages.

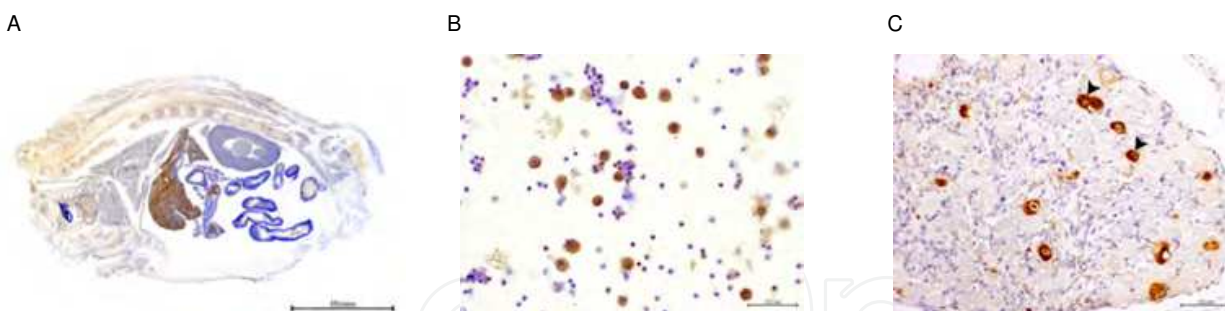


Fig. 13. A: Sagittal section of the entire body of a suckling hamster from the neck to the tail showing all internal organs. IHC. Bar, 10 nm. B: Expression of EHV-9 antigen in peritoneal macrophages at 6 h PI. Bar, 100 micrometer. C: Expression of EHV-9 antigen in the nucleus and cytoplasm of neuron in abdominal ganglion at 24 h PI. IHC. Bar, 100 micrometer.

Several routes of viral entry into the central nervous system (CNS) have been postulated in the neurotropic herpesvirus, which include the neural, olfactory, and hematogenous routes (Johnson, 1998). Other neurotropic herpes viruses, including herpes simplex virus-1 (HSV-1) and porcine herpesvirus-1, may enter the CNS via the intravenous, intramuscular, and intraperitoneal routes (Johnson, 1998). It has been previously hypothesized in hamsters and pigs that a possible route of EHV-9 infection is from the nasal mucosa along the olfactory pathway, vomeronasal organ, and/or trigeminal nerve (Fukushi et al., 2000; Narita et al., 2000) and then trans-synaptically via its connections to the hippocampus, amygdala, and cerebral cortex. Induction of encephalitis by intranasal inoculation in different animals including mice, rats (Fukushi et al., 1997), hamsters (Fukushi et al., 2000), goats (Taniguchi et al., 2000b), pigs (Narita et al., 2000), dogs and cats (Yanai et al., 2003a, b), common marmosets (Kodama et al., 2007) and cattle (El-Habashi et al., 2011) suggests that EHV-9 gains access to the brain via olfactory neurons of the olfactory mucosa specially there was inflammatory reaction in the olfactory mucosa of some of these animals and olfactory bulbs, cerebrum especially the frontal lobe, mid brain and medulla oblongata in most of these animals. Another possible route might be hematogenous dissemination from infected lungs. It is plausible to consider that EHV-9 may have entered the CNS from the nasal mucosa along the olfactory pathway to limbic structures, as was found in other virus, like Bornavirus and rabies virus infection (Gosztonyi et al., 1993).

It was proved that EHV-9 migrates from nasal cavity to the brain through the olfactory nerve after initial propagation in the olfactory receptor neurons in suckling hamster (El-Habashi et al., 2010b). At 48 h PI, EHV-9 antigen was detected in most of the olfactory receptor neurons as well as in the central processes of the olfactory epithelial neurons, olfactory nerve and olfactory bulb. The olfactory epithelium offer direct free surface on the internal lining of the nasal cavity, after propagation in olfactory receptor neurons, the virus could travel directly through olfactory nerve to the brain while the terminal nerve endings of the maxillary branch of the trigeminal nerve lie in the submucosa and could be only infected with the virus if the epithelial surface is damaged and consequently the axons are directly exposed to the virus and this suggested from suckling hamster experiment as well as common marmoset which showed necrotizing rhinitis as well as late access of the virus to the trigeminal nerve, pons and medulla oblongata (El-Habashi et al, 2010b; Kodama et al., 2007). One study compared various routes of experimental EHV-9 inoculation in Syrian hamsters (Fukushi et al., 2000), including intranasal, intravenous, intraperitoneal, intramuscular, intraocular, and subcutaneous routes, but only intranasal inoculation

induced disease. However, in more recent study, possible infection by different routes of inoculation including, nasal, ocular, peritoneal and oral routes were evident. There may be discrepancies in EHV-9 infection of the brain based on the route of inoculation when animals are inoculated with the same quantity of virus (El-Habashi et al, 2010a).

4. Conclusion: EHV-9 infection as a model of cross-species viral transmissions

Based on previous experimental studies in different animals inoculated via the nasal route, the olfactory pathway (i.e. through the olfactory nerves) is the major route of transmission of EHV-9 into the CNS. However, recent study that compared different routes of inoculation clearly indicates that virus can enter the CNS after administration of EHV-9 via the oral, peritoneal, and ocular routes, and that there are differences in the distribution of antigen-positive cells and in the location and severity of the cerebral lesions. Thus, EHV-9 may gain access to the CNS through a non-olfactory route as these animals inoculated via these non-nasal routes did not exhibit EHV-9 induced rhinitis, and the olfactory bulbs showed milder lesions and fewer viral antigen-positive cells than observed in the animals infected via the nasal route.

One of the striking finding was that animals infected via the ocular route had mild and localized lesions in the rhinencephalon, which indicated that the virus had traveled to the CNS through the optic nerve. Similar to what is reported about fatal infections by Cercopithecine herpes virus 1 (B virus) in humans via ocular exposure from biological fluid from macaque monkeys (CDC, 1999).

The differences in the incubation period and paths of travel to the CNS among the various routes in resulting in a variety of clinical signs and histopathological features, suggests a dependency on the replication of the virus at the site of entry and its opportunity to access regional nerves to travel to the brain. A similar hypothesis was proposed in the case of pigs infected orally by EHV-9 (Narita et al., 2000), where the virus was thought to travel centripetally in the nerve fibers from the oral mucosa to the trigeminal ganglion, eventually entering the olfactory lobes (Chowdhury et al., 1997; Kritas, et al., 1994; Narita et al., 1976).


Previously, EHV-9 antigen was found in the neurons and neural fibers but not in the glial cells in the brain, indicating that neurons are the susceptible cells to EHV-9 in the CNS of hamsters (Fukushi et al., 2000). However, other neurotropic herpesviruses such as herpes simplex virus 1 (HSV-1) and pseudorabies virus (PRV) are known to infect glial cells as well as neurons (Johnson, 1998). Astrocytes infection of EHV-9 was described in the cases of a giraffe and a polar bear (Donovan et al., 2009; Hoenerhoff et al., 2006). Immunohistochemistry demonstrated the presence of EHV-9 antigen in the neurons and neuronal fibers including the axons and dendrites in the brain of the goat and the naturally infected bear which indicate a trans-synaptic spread of EHV-9 from neuron to neuron via the neuronal fibers (Taniguchi et al., 2000b; Donovan et al., 2009). Similar transmission has been shown in pseudorabies viral infection (Card et al, 1990). In suckling hamster study, there was necrosis of some of trigeminal ganglion cells as well as detection of the viral antigen in the same ganglion and in the connection between trigeminal sensory nerve root and the brain stem at the level of the pons and medulla oblongata. Based on previous findings, the neurotropism might be the most characteristic property of EHV-9, differentiating it from other neurotropic herpesviruses. Similar transneural passage was suggested after intranasal infection with IBR virus (Narita et al, 1979).

EHV-9 infection can be regarded as one of cross-species viral transmission. In nature, natural barriers exist to prevent the cross-species transmission as well as natural clearance such as predation by carnivores can hide the lethal cross-species transmission. An artificial situation of zoos or farms can cause cross-species transmission among carrier animals and susceptible animals. However, some species do not show clinical symptoms even though they can be infected by viruses. In EHV-9 infection, all of the animals infected by EHV-9 caused various degree of meningo-encephalitis. It is not clear what kind of factors are involved in the clinical course of EHV-9 infection.

5. References

- Borchers K, Lieckfeldt D, Ludwig A, Fukushi H, Allen G, Fyumagwa R, Hoare R: Detection of equid herpesvirus 9 DNA in the trigeminal ganglia of a Burchell's zebra from the Serengeti ecosystem. *J Vet Med Sci* 70: 1377-1381, 2008
- Borchers K, Wiik H, Frolich K, Ludiwig H, East ML: Antibodies against equine herpesviruses and equine arteritis virus in Burchell's zebra (*Equus Burchelli*) from the Serengeti ecosystem. *J Wildl Dis* 41: 80-86, 2005
- CDC: Hazard ID 5- Cercopithecine herpesvirus 1 (B Virus) infection resulting from ocular exposure. National Institute for Occupational Safety and Health (NIOSH). Publication 99-100, 1999
- Chowdhury SI, Lee BJ, Mosier D, Sur JH, Osori FA, Kennedy G, Weiss ML: Neuropathology of bovine herpesvirus type 5 (BHV-5) meningo-encephalitis in a rabbit seizure model. *J Comp Pathol* 117: 295-310, 1997
- Donovan TA, Schrenzel MD, Tucker T, Pessier AP, Bicknese B, Busch MD, Wise AG, Maes R, Kiupel M, McKnight C, Nordhausen RW: Meningoencephalitis in a polar bear caused by equine herpesvirus 9 (EHV-9). *Vet Pathol* 46:1138-43, 2009
- El-Habashi N, Murakami M, EL-Nahass E, Hibi D, Sakai H, Fukushi H, Sasseville V, Yanai T: Study on the infectivity of equine herpesvirus 9 (EHV-9) by different routes of inoculation in hamsters. *Vet Pathol* 47: 1-7, 2010a
- El-Habashi N, EL-Nahass E, Fukushi H, Hibi D, Sakai H, Sasseville V, Yanai T: Experimental intranasal infection of equine herpesvirus 9 (EHV-9) in suckling hamsters: Kinetics of viral transmission and inflammation in the nasal cavity and brain. *J NeuroVirol* 16: 242-248, 2010b
- El-Habashi N, EL-Nahass E, Fukushi H, Namihira Y, Hagiwara H, Fukushi H, Narita M, Hirata A, Sakai H, Yanai T: Neuropathogenicity of equine herpesvirus 9 in cattle. *J Eqine Vet Sci* 31: 72-77, 2011
- El-Nahass E, El-Habashi N, Nayel M, Kasem S, Fukushi H, Suzuki Y, Hirata A, Sakai H, Yanai T: Kinetics and pathogenicity of equine herpesvirus 9 infection following intraperitoneal inoculation in hamsters. *J Comp Pathol* doi:10.1016/j.jcpa.2011.01.009, 2011
- Felsenstein J. PHYLIP (Phylogeny Inference Package) version 3.6. Distributed by the author. Department of Genome Sciences, University of Washington, Seattle, 2005
- Fukushi H, Tomita T, Taniguchi A, Ochiai Y, Kirisawa R, Matsumura T, Yanai T, Masegi T, Yamaguchi T, Hirai K: Gazelle herpesvirus 1: A new neurotropic herpesvirus immunologically related to equine herpesvirus 1. *Virology* 227: 34-44, 1997
- Fukushi H, Taniguchi A, Yasuda K, Yanai T, Masegi T, Yamaguchi T, Hirai K: A hamster model of equine herpesvirus 9 induced encephalitis. *J Neuro Virol* 6: 314-319, 2000

- Gosztonyi G, Dietzschold B, Kao M, Rupprecht CE, Ludwig H and Koprowski H. Rabies and Borna disease: a comparative pathogenetic study of two neurovirulent agents. *Lab Invest* 68: 285-95, 1993
- Johnson RT: Viral infections of the nervous system, 2nd ed. Lippincott-Raven Publishers, Philadelphia. 1998
- Hoenerhoff MJ, Janovitz EB, Richman LK, Murphy DA, Butler TC, Kiupel M. Fatal herpesvirus encephalitis in a reticulated giraffe (*Giraffa camelopardalis reticulata*). *Vet Pathol*. 43:769-772, 2006
- Kodama A, Yanai T, Yomemaru K, Sakai H, Masegi T, Yamada S, Fukushi H, Kuraishi T, Hattori S, Kai C: Acute neuropathogenicity with experimental infection of equine herpesvirus 9 in common marmosets (*Callithrix jacchus*). *J Med Primatol* 36 : 335 – 342, 2007
- Kritas SK, Pensaert MB, Mettenleiter TC: Invasion and spread of single glycoprotein deleted mutants of Aujeszky's disease virus (ADV) in the trigeminal nervous pathway of pigs after intranasal inoculation. *Vet Microbiol* 40: 323-334, 1994
- Montali RJ, Allen GP, Bryans JT, Phillips LG, Bush M. Equine herpesvirus type 1 abortion in an onager and suspected herpesvirus myelitis in a zebra. *J Am Vet Med Assoc*. 187:1248-1249, 1985
- Narita M, Inui S, Namba K, Shimizu Y: Trigeminal ganglionitis and encephalitis in calves intranasally inoculated with infectious bovine rhinotracheitis virus. *J Comp Pathol* 86: 93-100, 1976
- Narita M, Ishikawa Y, Inui S. Neural changes in calves intranasally inoculated with two strains of infectious bovine rhinotracheitis virus. *J Comp Pathol*, 89, 489-494, 1979.
- Narita M, Uchimura A, Kimura K, Tanimura N, Yanai T, Masegi T, Fukushi H, Hirai K: Brain lesions and transmission of experimental equine herpesvirus type 9 in pigs. *Vet Pathol* 37: 476-479, 2000
- Schrenzel MD, Tucker TA, Donovan TA, Martin DM, Busch MDM, Wise AG, Maes RK, Kiupel M: New hosts for equine herpesvirus 9. *Emerging Infectious Diseases* 14: 1616-1619, 2008
- Taniguchi A, Fukushi H, Matsumura T, Yanai T, Masegi T, Hirai K: Pathogenicity of a new neurotropic equine herpesvirus 9 (Gazelle herpesvirus 1) in horses. *J Vet Med Sci* 62: 215-218, 2000a
- Taniguchi A, Fukushi H, Yanai T, Masegi T, Hirai K: Equine herpesvirus 9 induced lethal encephalitis in experimentally infected goats. *Arch Virol* 145: 2619-2627, 2000b
- Telford EA, Watson MS, McBride K, Davison AJ: The DNA sequence of equine herpesvirus-1. *Virology* 189: 304-316, 1992
- Wada R, Kanamaru T, Yokota S, Nanbu M, Matsumura T: Pathological observations on 2 horses of myeloencephalopathy associated with Equine Herpesvirus 1 (EHV-1). *Bull. Equine Res. Inst.* 28, 21-28, 1991
- Yanai T, Sakai T, Fukushi H, Hirai K, Narita M, Sakai H and Masegi T: Neuro-pathological study of Gazelle Herpesvirus 1 (Equine Herpesvirus 9) infection in Thomson's Gazelles (*Gazella thomsoni*). *J Comp Pathol* 119: 158-168, 1998
- Yanai T, Fujishima N, Fukushi H, Hirata A, Sakai H, Masegi T: Experimental infection of equine herpesvirus 9 in dogs. *Vet Pathol* 40: 263-267, 2003a
- Yanai T, Tsujioka S, Sakai H, Fukushi H, Hirai K, Masegi T: Experimental infection with equine herpesvirus 9 (EHV-9) in cats. *J Comp Pathol* 128: 113-118, 2003b



Non-Flavivirus Encephalitis

Edited by Dr. Sergey Tkachev

ISBN 978-953-307-720-8

Hard cover, 360 pages

Publisher InTech

Published online 16, November, 2011

Published in print edition November, 2011

This book covers the different aspects of non-flavivirus encephalitis of different etiology. The first section of the book considers general problems of epidemiology such as study of zoonotic and animal vectors of encephalitis causative agents and methods and approaches for encephalitis zoonoses investigations. The members of different virus species are known to be the causative agents of encephalitis, so the second section of the book is devoted to these viral pathogens, their epidemiology, pathology, diagnostics and molecular mechanisms of encephalitis development by such viruses as HIV/SIV, herpes simplex virus type 1 and equine herpesvirus 9, measles virus, coronaviruses, alphaviruses and rabies virus. The next section of the book concerns the study of protozoan pathogens such as toxoplasma and amoebae. The last section of the book is devoted to multicellular pathogen as human *Filaria Loa Loa* - a filarial worm restricted to the West Africa.

How to reference

In order to correctly reference this scholarly work, feel free to copy and paste the following:

Hideto Fukushi and Tokuma Yanai (2011). Virology and Pathology of Encephalitis in Alien Hosts by Neurotropic Equine Herpesvirus 9, Non-Flavivirus Encephalitis, Dr. Sergey Tkachev (Ed.), ISBN: 978-953-307-720-8, InTech, Available from: <http://www.intechopen.com/books/non-flavivirus-encephalitis/virology-and-pathology-of-encephalitis-in-alien-hosts-by-neurotropic-equine-herpesvirus-9>

INTECH
open science | open minds

InTech Europe

University Campus STeP Ri
Slavka Krautzeka 83/A
51000 Rijeka, Croatia
Phone: +385 (51) 770 447
Fax: +385 (51) 686 166
www.intechopen.com

InTech China

Unit 405, Office Block, Hotel Equatorial Shanghai
No.65, Yan An Road (West), Shanghai, 200040, China
中国上海市延安西路65号上海国际贵都大饭店办公楼405单元
Phone: +86-21-62489820
Fax: +86-21-62489821

© 2011 The Author(s). Licensee IntechOpen. This is an open access article distributed under the terms of the [Creative Commons Attribution 3.0 License](https://creativecommons.org/licenses/by/3.0/), which permits unrestricted use, distribution, and reproduction in any medium, provided the original work is properly cited.

IntechOpen

IntechOpen