

We are IntechOpen, the world's leading publisher of Open Access books Built by scientists, for scientists

6,900

Open access books available

185,000

International authors and editors

200M

Downloads

Our authors are among the

154

Countries delivered to

TOP 1%

most cited scientists

12.2%

Contributors from top 500 universities



WEB OF SCIENCE™

Selection of our books indexed in the Book Citation Index
in Web of Science™ Core Collection (BKCI)

Interested in publishing with us?
Contact book.department@intechopen.com

Numbers displayed above are based on latest data collected.
For more information visit www.intechopen.com



Henoch-Schönlein Purpura Nephritis in Childhood

Marco Zaffanello
University of Verona
Italy

1. Introduction

Henoch-Schönlein purpura is one of the most common causes of systemic vasculitis. Henoch-Schönlein purpura typically affects children between the age of 3 and 10 years. The aetiology is unknown. Diagnosis includes palpable purpura (essential) in the presence of diffuse abdominal pain, acute arthritis/arthralgia, renal involvement characterized by haematuria and/or proteinuria (Ozen et al., 2006) and skin biopsy showing predominant IgA deposition in the walls of cutaneous vessels.

In the majority of cases it is a self-limiting disease. Therefore, up to 40% of children with Henoch-Schönlein purpura require hospitalization for management of acute disease manifestations which may include nephritis, hypertension, severe pain, gastrointestinal bleeding or arthritis. Purpura occurs in all cases, joint pains and arthritis in 80% of cases, and abdominal pain in 62% of cases.

The purpura typically appears on the legs and buttocks (Fig.1), but may also be seen on the arms, face and trunk. The abdominal pain is colicky, and may be accompanied by nausea, vomiting, constipation or diarrhea. There may be blood or mucus in the stools. Sometime finding includes a gastrointestinal haemorrhage, occurring in 33% of cases, due to intussusceptions (Saulsbury, 1999). The joints involved tend to be the ankles, knees, and elbows but arthritis in the hands and feet is possible; the arthritis is non-erosive and hence causes no permanent deformity. Problems in other organs, such as the central nervous system (brain and spinal cord) and lungs may occur, but much less commonly than the skin, bowel and kidneys (Saulsbury, 2001)

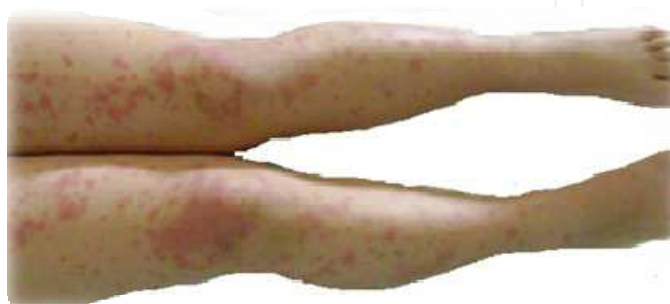


Fig. 1. Henoch-Schönlein purpura in a 8 years old female child

Paediatric patients may develop glomerulonephritis within 4 to 6 weeks of the initial purpura presentation (Saulsbury, 2007). Renal involvement in Henoch-Schönlein purpura is transitory in most cases. Therefore, the long-term prognosis in Henoch-Schönlein purpura depends on the severity of renal involvement and can be poor when complicated by severe nephritis and chronic renal failure.

2. Pathogenesis

Henoch-Schönlein purpura nephritis is a systemic immune-complex mediated disease according to the clinical or histological pattern of recurrences of Henoch-Schönlein purpura nephritis in some patients after transplantation (Soler et al., 2005). The histological hallmark of Henoch-Schönlein purpura is severe inflammation of small vessels, particularly post-capillary venules, with neutrophils, resulting in fibrinoid necrosis of vessel walls and extravasation of erythrocytes (Saulsbury, 1999). The clinical features are a consequence of general vasculitis due to IgA1 deposition in vessels and the renal mesangium (Saulsbury, 1999). Therefore, the pathogenetic mechanisms are still not fully understood.

2.1 IgA immune complexes

Similarly to IgA nephropathy, deposits of IgA-binding M proteins of group A streptococci were found on Henoch-Schönlein purpura kidneys. All Henoch-Schönlein purpura patients have IgA1-circulating immune complexes of small molecular mass. Therefore, only those with nephritis have large-molecular-mass IgA1-IgG-containing circulating immune complexes (Levinsky & Barratt, 1979). Large-molecular mass IgA-IgG complexes in the circulation are the major factor responsible for the formation of the nephritogenic immune complexes in patients with Henoch-Schönlein purpura nephritis.

Some children with Henoch-Schönlein purpura nephritis subsequently have an episode or recurrent episodes of macroscopic hematuria, associated with upper respiratory tract infection without the other clinical features of Henoch-Schönlein purpura nephritis (Waldo, 1988). Thus, these children's clinical phenotype changes to that of IgA nephropathy. As the renal histologic and immunofluorescence microscopy findings in Henoch-Schönlein purpura nephritis are indistinguishable from those seen in patients with IgA nephropathy (Evans et al., 1973), it has long been ever speculated that Henoch-Schönlein purpura nephritis and IgA nephropathy have common pathogenetic mechanisms representing different ends of a continuous spectrum of disease (Waldo, 1988).

Henoch-Schönlein purpura nephritis is similar to IgA nephropathy since IgA1, but not IgA2, is found in the circulating immune complexes and in mesangial immune deposits (Novak et al., 2007). IgA1-containing immune complexes are excreted in elevated amounts in the urine in patients with IgA nephropathy and Henoch-Schönlein purpura nephritis and may provide a specific marker for disease activity and/or severity in these patients (Suzuki et al., 2008). IgA-binding M proteins may encounter circulatory IgA forming a complex with IgA-Fc that could deposit in renal tissues (Schmitt et al., 2010).

Reduced galactosylation of IgA1 O-glycans has been reported in patients with Henoch-Schönlein purpura nephritis (Allen et al., 1998). Glycosylation defects are due to complex changes in expression of specific glycosyltransferases with reduced expression of β 1,3-galactosyltransferase and elevated expression of GalNAc-specific α 2,6-sialyltransferase in patients with both IgA nephropathy and Henoch-Schönlein purpura nephritis, but not in patients with Henoch-Schönlein purpura without nephritis or healthy controls (Suzuki,

Moldoveanu et al., 2008). Due to their size, Galactose-deficient IgA1 containing immune complexes are less efficiently taken up by the asialoglycoprotein receptor in the liver and catabolised and their amounts increase in the circulation (Moura et al., 2004). Galactose-deficient IgA1 leads to the formation of the circulating immune complexes. These complexes may then deposit in the renal mesangium and incite, likely due to the binding to mesangial cells, to cellular activation (Lau et al., 2010). Consequently, mesangial cells start to proliferate and overproduce extracellular matrix components, cytokines and chemokines (Davin & Weening, 2003) leading to glomerular injury contributing to the pathogenesis of Henoch-Schönlein purpura nephritis.

Glomerular depositions of other components, including kappa and lambda light chains, are also variably demonstrated in Henoch-Schönlein purpura nephritis. In patients with IgA nephropathy, lambda light chains were found predominantly over kappa light chains (Lai et al., 1996).

2.2 Complement

Complement activation appears to play an important role in the pathogenesis of IgA nephropathy and Henoch-Schönlein purpura nephritis, as glomerular complement activation may initiate the inflammatory cascade and enhance glomerular injury (Wyatt et al., 1987). Therefore, hypocomplementemia has been reported in some patients with Henoch-Schönlein purpura nephritis, and it is usually transient and not related to the severity of the diseases (Motoyama & Litaka, 2005).

3. Incidence

The estimated annual incidence of Henoch-Schönlein purpura in children is 10–20 per 100,000 children (Rostoker, 2001). The annual incidence of Henoch-Schönlein purpura in Asian children [4.9 per 100,000] and African children [6.2 per 100,000] was significantly lower than Caucasian children [17.8 per 100,000].

In childhood Henoch-Schönlein purpura, the male:female ratio ranges from 1.2–1.6 (Yang et al., 2005).

Renal involvement occurs less frequently in children than adulthood (Yang et al., 2005; Pillebout et al., 2002). The incidence of nephritis in patients with Henoch-Schönlein purpura has been reported to be 15–62% with an estimated annual incidence of 20.4 per 100,000 children (Gardner-Medwin et al., 2002; Shenoy, Bradbury, et al. 2007; Bogdanovic, 2009).

The overall incidence of Henoch-Schönlein purpura nephritis and the severity of Henoch-Schönlein purpura nephritis in patients between 1987 and 1997 were similar to those in children between 1998 and 2008 and the number of patients with severe Henoch-Schönlein purpura nephritis has not decreased (Kawasaki et al., 2010). The overall incidence of Henoch-Schönlein purpura nephritis is rather stable over time.

It could be estimated that 1–2% of all Henoch-Schönlein purpura nephritis patients will ultimately develop chronic kidney disease (Stewart et al., 1988; Narchi, 2005). A variable percentage of children (0–19%) with Henoch-Schönlein purpura nephritis may progress to renal failure or end stage renal disease (Ronkainen et al., 2002; Coppo et al., 1997; Goldstein et al., 1992; Kawasaki et al., 2003; Pillebout et al., 2002). In children with Henoch-Schönlein purpura nephritis followed up at tertiary centres the risk for progression to chronic kidney disease or end-stage renal disease is predicted to be 5–18% at 5 years, 10–20% at 10 years

and 20–32% at 20 years from the diagnosis (Goldstein et al., 1992; Coppo et al., 1997; Kaku et al., 1998; Bogdanovic, 2009).

4. Clinical patterns

The average duration of Henoch-Schönlein purpura symptoms is 4 weeks. The majority of patients experience resolution of symptoms within 2 to 3 months. Approximately 30% of patients have one or more recurrences after the resolution of initial symptoms (Saulsbury, 1999; Trapani et al., 2005). Therefore, purpura lasting longer than 1 month or relapsing disease are associated with the development of nephritis (Rigante et al., 2005; Shin, Park, et al., 2006). Patients showing abdominal pain as the initial symptom had a higher probability of developing nephrotic syndrome. Persistent rash was a poor prognostic factor for Henoch-Schönlein purpura nephritis (Hung et al., 2009).

Renal signs are manifested in the majority of Henoch-Schönlein purpura patients from 3 days to 17 months after onset of the disease (Kaku et al., 1998), occurring more frequently within the first 3 months (Sano et al., 2002). In few cases the renal disease may develop even years after the initial presentation (Mollica et al., 1992). While abnormalities on urinalysis may continue for a long time, only 1% of all Henoch-Schönlein purpura patients develop chronic kidney disease (Saulsbury, 2001).

Nephritis is the one feature of Henoch-Schönlein purpura that may have chronic consequences. The long-term prognosis is largely dependent on the severity of nephritis (Narchi, 2005; Mir et al., 2007). Renal manifestations of the disease ranged from mild, benign involvement, intermittent haematuria and proteinuria, to rapidly progressive or crescentic nephritis. Of the 40% of patients who develop kidney involvement, almost all have evidence (visible or on urinalysis) of blood in the urine. More than half also have proteinuria, which in one eighth is severe enough to cause nephrotic syndrome (Saulsbury, 2001). From a retrospective study, nephritis occurred in 46% of the Henoch-Schönlein purpura patients, consisting of isolated haematuria in 14%, isolated proteinuria in 9%, both haematuria and proteinuria in 56%, nephrotic-range proteinuria in 20% and nephrotic-nephritic syndrome in 1% (Jauhola et al., 2010).

Renal involvement is in most cases mild and self-limited in children. Henoch-Schönlein purpura nephritis in children had a lower risk of progression to renal insufficiency than adults. Gross hematuria and lower extremity edema were less frequent in the children than adults (Hung et al., 2009). Morbidity is low in patients with Henoch-Schönlein purpura who have hematuria and mild proteinuria at onset, while it is higher among those with more severe renal disease, as in a nephritic, nephrotic or a nephritic/nephrotic signs (Coppo et al., 2006; Ronkainen et al., 2002; Narchi, 2005; Goldstein et al., 1992). The main clinical signs of rapidly progressive Henoch-Schönlein purpura nephritis at presentation were edema, hypertension, gross hematuria, and oliguria (Oner, 1995). End-stage renal disease was associated with nephritic and/or nephrotic syndrome at presentation in nearly all children with Henoch-Schönlein purpura nephritis (Soylemezoglu et al., 2009). The highly variable clinical course of Henoch-Schönlein purpura nephritis has been related to the marked variability in histopathologic presentation at renal biopsy, with glomeruli ranging from histologically normal to diffuse proliferative and crescentic lesions (Assadi, 2009).

4.1 Classification

Five categories of Henoch-Schönlein purpura nephritis were identified according to renal manifestations at disease onset (Falkner et al., 2004): (A) micro/macrosopic hematuria or

persistent mild proteinuria (< 1 g/L or urine albumin/creatinine ratio < 200 mg/mmol); (B) persistent mild proteinuria (< 1 g/L or urine albumin/creatinine ratio < 200 mg/mmol) and micro- or macroscopic hematuria; (C) nephritic syndrome (moderate proteinuria and urine albumin/creatinine ratio ≥ 200 – 400 mg/mmol), decreased glomerular filtration rate, hematuria and/or hypertension, or nephrotic syndrome (urinary albumin excretion > 40 mg/hour/m² body surface area or urine albumin/creatinine ratio ≥ 400 mg/mmol, serum albumin < 25 g/L; (D) acute progressive glomerular nephritis; (E) chronic glomerular nephritis. Classes A and B were considered as mild renal disease, and classes C to E as severe disease (Meadow et al., 1972).

Another clinical evaluation categorized the patients according to four stages. Stage (A) is considered normal: the patient was normal on physical examination, with normal urine and renal function; stage (B) had minor urinary abnormalities: the patient was normal on physical examination, with microscopic hematuria or proteinuria of less than 20 mg/m²/h; stage (C) had persistent nephropathy: the patient had proteinuria of 20 mg/m²/h or greater or hypertension and a 24-h creatinine clearance of 60 ml/min/1.73 m² or greater; stage (D) had renal insufficiency: the patient had a 24-h creatinine clearance of less than 60 ml/min/1.73 m², including dialysis/transplant or death (Kawasaki et al., 2010).

4.2 Serum IgA

Although serum IgA levels are higher in children with Henoch-Schönlein purpura / Henoch-Schönlein purpura nephritis than in controls, this serum abnormality does not constitute a sensitive diagnostic marker of Henoch-Schönlein purpura with or without nephritis. In particular, over 40% children with Henoch-Schönlein purpura had elevated serum IgA levels at presentation. Therefore, the difference in serum IgA levels between patients with and without nephritis was not statistically significant.

4.3 Renal biopsy

Renal involvement can be severe but may resolve completely. Therefore, some children will develop long-term sequelae. The renal biopsy is helpful in determining the need for treatment with immunosuppression in the acute phase (McCarthy & Tizard, 2010).

The criteria for renal biopsy were defined as follows: (1) the patients had proteinuria of 20 mg/m²/hour or greater and haematuria or (2) the patients had proteinuria of less than 20 mg/m²/hour and recurrent macrohematuria (Kawasaki et al., 2010). According to another recent review a renal biopsy has been recommended in the following situations: (1) acute renal impairment/nephritic syndrome at presentation; (2) nephrotic syndrome with normal renal function persisting at 4 weeks; (3) nephrotic range proteinuria (urine protein/creatinine ratio, >250 mg/mmol) at 4–6 weeks (if not improving spontaneously); (4) persistent proteinuria-urine protein/creatinine ratio >100 mg/mmol for more than 3 months. Consider biopsy particularly if the diagnosis is not clear (McCarthy & Tizard, 2010).

Renal involvement in Henoch-Schönlein purpura is quantified by means of a kidney biopsy (Fig. 2), which may demonstrate positive mesangial staining and positive anti-IgA antisera on immunofluorescence, with glomerular changes graded chiefly according to the Henoch-Schönlein purpura nephritis classification described in the International Study of Kidney Disease in Children (Rai et al., 1999; Sheno, Bradbury, et al. 2007; Ronkainen et al., 2006). The grading of renal histology has been considered as an important marker of outcome (Farine et al., 1986). The classification provided by the Study of Kidney Disease in Children included grade I: minimal alterations; grade II: mesangial proliferation; grade III: focal or diffuse

proliferation or sclerosis with <50% crescents; grade IV: focal or diffuse mesangial proliferation or sclerosis with 50–75% crescents; grade V: focal or diffuse mesangial proliferation or sclerosis with >75% crescents; grade VI: membranoproliferative-like lesions (Counahan et al., 1977).

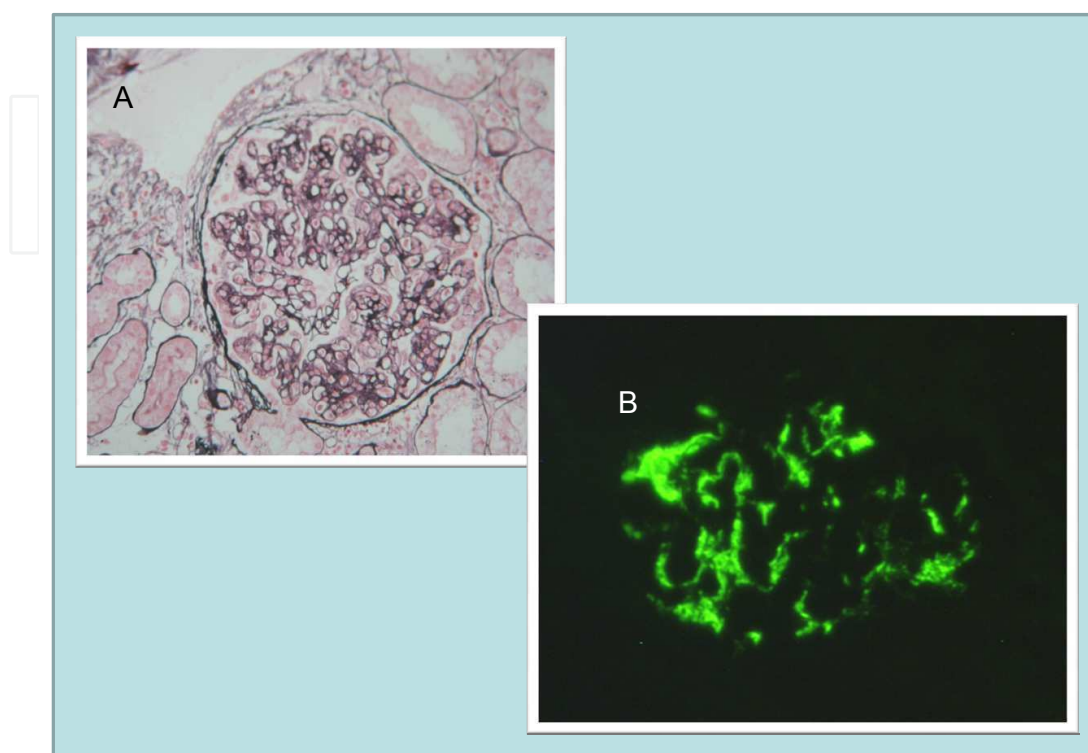


Fig. 2. Methenamine-silver stain of a glomerular of a patient with Henoch-Schönlein purpura nephritis showing diffuse mesangial and focal endocapillary proliferation (panel A). The immunofluorescence studies showed intense IgA positivity (3+) (panel B); complement C3 staining was also mildly positive (1+).

5. Risk factors

5.1 Renal involvement in Henoch-Schönlein purpura

Some authors attempted to identify prognostic factors for a child with Henoch-Schönlein purpura to develop nephritis by using univariate and multivariate analysis models. The independent risk factors for Henoch-Schönlein purpura nephritis were persistent purpura, severe abdominal symptoms and age above 4 or 7 or 10 years. Other independent risk factors were relapse or decreased serum factor XIII activity (Kaku et al., 1998; Sano et al., 2002; Rigante et al., 2005; Shin, Park, et al., 2006; Ronkainen et al., 2006). Persistent purpura, severe abdominal symptoms and an older age were confirmed as the most significant risk factors for later nephropathy (Bogdanovic, 2009). A prospective study showed that age over 8 years at onset (OR 2.7), abdominal pain (OR 2.1) and a recurrence of Henoch-Schönlein purpura disease (OR 3.1) were independent risk factors for developing nephritis (Jauhola et al., 2010).

5.2 Long-term renal impairment

Severe renal involvement at onset of Henoch-Schönlein purpura is in general predictive of a poor renal outcome. The independent predictors of a poor renal outcome were severe initial

presentations with renal failure, nephritic, nephrotic syndrome or mixed syndrome and the percentage of glomeruli with crescents (Mir et al., 2007). Some few children with mild renal symptoms at onset have a poor long-term outcome. Thus, long-term follow-up is mandatory also for these patients (Algoet & Proesmans, 2003; Goldstein et al., 1992).

6. Follow-up

A clinical pathway was recommended if there is evidence of haematuria, proteinuria, renal impairment or hypertension in patients with Henoch-Schönlein purpura (Tizard & Hamilton-Ayres, 2008). Prospectively and systematically collected data suggested that weekly urine dipstick tests should be continued for 2 months from the onset of Henoch-Schönlein purpura. Beyond that point frequent routine follow-up is neither cost-effective nor necessary in patients with no urine abnormalities during follow-up. However, the length of follow-up time should be increased at least up to 6 months individually in the case of Henoch-Schönlein purpura recurrence and in those developing nephritis (Jauhola et al., 2010).

7. Prevention of Henoch-Schönlein purpura nephritis

Intervention to shorten the duration of Henoch-Schönlein purpura and prevent relapses may be helpful in preventing the development of nephritis. However, no therapy has yet been shown to decrease the duration of Henoch-Schönlein purpura, prevent recurrences, or prevent the development of nephritis (Saulsbury, 2009).

Studies reported on patients with Henoch-Schönlein purpura lacking clinical signs of nephropathy at admission were treated with prednisone at doses ranging from 1.0 to 2.5 mg/kg/day over a period of 7–21 days. Early prednisone treatment did not succeed in reducing the risk of further renal complication from Henoch-Schönlein purpura. Although prednisone is effective in alleviating the abdominal pain and joint pain associated with Henoch-Schönlein purpura, it did not short the duration of the disease, prevented the recurrences, or prevented the development of nephritis (Ronkainen et al., 2006). The relatively small subgroup of Henoch-Schönlein purpura patients who may benefit from corticosteroids included those who present with renal involvement and probably those with severe abdominal symptoms requiring medical attention (Mollica et al., 1992; Saulsbury, 1999; Narchi, 2005).

In general, the prophylactic treatment with prednisone at 2 mg/kg/day in Henoch-Schönlein purpura must be considered of value if (1) there is a quicker resolution of abdominal pain, considering the cost and potential damage from prolonged treatment; (2) the treatment performed during the acute phase reduce the rates of abdominal surgery for exploration or actual intestinal injury; (3) the avoidance of several late-onset medical conditions, including hypertension, preeclampsia, and persistent nail-fold capillary changes, suggesting a chronic vasculitis (Gibson et al., 2008). Such measure at this time has not been demonstrated. However, 2–4 weeks of prednisone administration at doses ranging from 1.0 to 2.5 mg/kg per day over a period of 7–21 days or intravenous methylprednisolone prophylaxis (5 mg/kg four to six times per day for 3–5 days) failed to prevent renal involvement in Henoch-Schönlein purpura after 0.5–1 years (Zaffanello et al., 2009).

Dapsone, an antileprotic drug, has been used at 1–2 mg/kg/day daily in a few patients with prolonged in Henoch-Schönlein purpura, improving the time of purpuric rash, but it has not been studied in a rigorous fashion in children with nephritis (Iqbal & Evans, 2005).

The clinical course of patients in a report suggested that colchicines, an ancient anti-inflammatory drug, may be effective treatment at dosages of 1.2 mg/day in children with prolonged Henoch-Schönlein purpura possibly preventing the development of nephritis (Saulsbury, 2009). Therefore, at the current time insufficient data are available to support a recommendation for prophylaxis.

8. Conventional treatment

Conventional therapies were defined as drugs or procedures that act as immune modulators.

8.1 Treatment of mild form of Henoch-Schönlein purpura nephritis

Patients with mild renal symptoms have showed lower proportion of poor outcome than those with severe renal symptoms. In particular, patients with isolated hematuria showed a good prognosis, but 18% of patients with mild proteinuria at onset showed a poor outcome (Edström Halling et al., 2010). For this reason patients would be followed until full clinical resolution of renal symptoms. Since the level of proteinuria at onset does not seem to be a reliable predictor of outcome, the persistence of mild proteinuria in the long-term follow-up (one year) may require renal biopsy. Finally, the treatment of mild clinical form must be weighed according to International Study of Kidney Disease in Children grading score (see 8.2. and 8.3. sections).

8.2 Treatment of moderately severe Henoch-Schönlein purpura nephritis

Patients affected by moderately-severe proteinurias were treated with prednisone, intravenous gamma globulins and tonsillectomy, while pulse methylprednisolon and cyclophosphamide were introduced according to the degree of severity of renal histology.

Three Henoch-Schönlein purpura nephritis patients treated by means of intravenous (2 g/kg/month) and intramuscular gamma globulins (0.35 ml/kg every 15 days) showed improved degrees of proteinuria and acuity index at renal biopsy (Rostoker et al., 1994; Rostoker et al., 1995). The administration of the angiotensin converting enzyme inhibitor (enalapril 10 mg/day) combined with fish oil led to a significant reduction in protein excretion rate after a few weeks of treatment in case series (Dixit et al., 2004). Additionally, tonsillectomy proved to be effective in five patients affected by Henoch-Schönlein purpura nephritis (Sanai & Kudoh, 1996) as well as in 16 children with Henoch-Schönlein purpura nephritis in combination with intravenous pulse methylprednisolon at a dose of 1 gram/1.73 m² of body surface area (three to four cycles), prednisone (2 mg/kg/day) and cyclophosphamide (2 mg/kg/day) (Inoue et al., 2007).

Data obtained from the literature are insufficient to support the use of specific treatments, such as intravenous gamma globulins and angiotensin converting enzyme inhibitors, in moderate-severe Henoch-Schönlein purpura nephritis, based on case series (Zaffanello et al., 2009).

8.3 Treatment of rapidly progressive or crescentic Henoch-Schönlein purpura nephritis

Predictors of treatment with immunosuppression drugs were higher albuminurias and urine immunoglobulin G, and lower glomerular filtration rate at onset and a higher International Study of Kidney Disease in Children grading score in the biopsy. Unfortunately, no significant difference in outcome was found between the treated and

untreated patients with crescents. Neither was there any significant difference in glomerular filtration rate between treated and untreated patients (Edström Halling et al., 2010).

Several studies have reported that patients with severe Henoch-Schönlein purpura nephritis may benefit from an intravenous pulse of methylprednisolone (Kawasaki et al., 2003; Niaudet & Habib, 1998; Edström Halling et al., 2010), cyclosporine A (Ronkainen et al., 2003), cyclophosphamide (Kawasaki et al., 2004; Tarshish et al., 2004; Shenoy et al., 2007; Kawasaki et al., 2004; Edström Halling et al., 2010), urokinase pulse therapy (Kawasaki et al., 2003; Zaffanello et al., 2007), azathioprine (Zaffanello et al., 2007; Foster et al., 2000), and plasma exchange therapy (Scharer et al., 1999). All severe cases almost received angiotensin converting enzyme inhibitors and/or angiotensin II receptor blockers combined with immunosuppressant drugs (Edström Halling et al., 2010).

Some protocols of treatment for Henoch-Schönlein purpura nephritis included the prescription of a single specific immunosuppressive treatment; other included two or multiple immunosuppressive drugs.

8.3.1 Steroids

Steroids included prednisolone or methylprednisolone at 30 mg/kg/day for 3 consecutive days or dexamethasone at 5 mg/kg/day (Kawasaki et al., 2003; Niaudet & Habib, 1998). Fifty-six patients with renal lesions graded as IIIb or higher were treated with intravenous/oral steroids, along with dipyridamole and anticoagulant warfarin. The acuity index decreased at second biopsy, whereas the chronicity index did not differ significantly (Kawasaki et al., 2003).

8.3.2 Cyclosporine A

Single treatment included cyclosporine A performed for 6 months - 2 years (Ronkainen et al., 2003).

Cyclosporine A, at the initial dose of 4–8 mg/kg/day, with blood level kept at 150–200 µg/L, and at the maintenance dose of 1–5 mg/kg/day, with blood level kept at 80–100 µg/L, proved to be effective in some case series with biopsy-proven steroid-resistant Henoch-Schönlein purpura nephritis. In particular, the treatment was effective in reducing the nephrotic proteinuria range after an average of 2 months in seven patients. Stable remission after a mean follow-up of 6 years was achieved in four subjects (Ronkainen et al., 2003). Treatment with cyclosporine A was effective in one patient with renal crescents following the failure of pulse steroid, oral prednisone and an 8 months course of azathioprine at 2 mg/kg/day (Shin et al., 2006). In seven patients, treatment with pulse or oral prednisone and cyclosporine A with or without angiotensin converting enzyme inhibitor cilazapril displayed a marked efficacy in reversing nephrotic-range proteinuria and reducing histological grading post-treatment (Shin et al., 2005). In another study involving a group of 82 children with varying degrees of renal manifestation and histology (Mir et al., 2007), the majority received steroid treatment while only a few were treated with angiotensin converting enzyme inhibitor or cyclophosphamide in combination with steroids. Despite treatment, the long-term prognosis worsened markedly in those children manifesting severe clinical presentation.

8.3.3 Cyclophosphamide

Single treatments included cyclophosphamide performed for 8–12 weeks (Tarshish et al., 2004; Zaffanello et al., 2007).

A case series of patients with biopsy-proven Henoch-Schönlein purpura nephritis displayed varying degrees of response to cyclophosphamide at 2–2.5 mg/kg/day. Several patients in

whom the initial renal biopsy had revealed $\geq 80\%$ crescentic glomeruli received cyclophosphamide in combination with pulse of methylprednisolone and/or long-term oral prednisone. The combined treatment was effective in aiding clinical recovery, maintaining normal renal function and reducing grade histology. Unfortunately, the lack of control patients and the small number of patients treated or short follow-up period hamper the drawing of firm conclusions (Zaffanello et al., 2007; Zaffanello et al., 2009).

Long-term outcome of patients treated with daily cyclophosphamide expressed as end-stage renal disease did not differ with controls (Tarshish et al., 2004), indicating failure at level II of evidence. In a retrospective investigation, 21 children with crescents in 40% of glomeruli who were treated with an association of azathioprine at 1-2 mg/kg/day and steroids displayed an effective clinical outcome. Unfortunately, the considerable variability of the histological patterns complicated any interpretation of the results obtained (Bergstein et al., 1998; Foster et al., 2000). Moreover, nine patients with severe histologically graded lesions were prescribed aggressive therapy with azathioprine and steroids, leading to marked clinical improvement. Regrettably, histological outcome was not reported, thus hindering the drawing of sustainable conclusions (Singh et al., 2002). Lastly, ten children treated with steroids and azathioprine were compared to ten patients receiving steroids alone. The initial biopsy revealed histological lesions comparable to those observed at follow-up, although mesangial IgA depositions were reduced in the majority of patients (Shin et al., 2005). However, the small number of patients studied led to difficulties in interpreting results.

8.3.4 Mycophenolate mofetil

Mycophenolate mofetil at 900-1,200 mg/m²/day was tested in patients with vasculitis and connective tissue disease involving the kidney, one of whom was affected by Henoch-Schönlein purpura nephritis. This drug was administered subsequent to the failure of treatment with steroids and azathioprine (Filler et al., 2003). However, two patients featuring a prolonged course of nephritis were first prescribed steroids and azathioprine with the subsequent addition of mycophenolate mofetil (Algoet & Proesmans, 2003). Once again, due to the exceedingly low number of patients treated, no firm conclusions could be drawn.

8.3.5 Single or combined treatment

Other protocols were performed with double immunosuppressant therapy, including steroid-cyclophosphamide (Oner et al., 1995; Iijima et al., 1998; Flynn et al., 2001; Tanaka et al., 2003; Kawasaki et al., 2004; Mir et al., 2007), steroid combined with azathioprine for 8-15 months (Bergstein et al., 1998; Foster et al., 2000; Singh et al., 2002; Shin et al., 2005; Zaffanello et al., 2007), and steroid- cyclosporine A or steroid - (angiotensin converting enzyme inhibitors) - cyclosporine A (Shin et al., 2005; Shin et al., 2006; Shin et al., 2007).

Triple immunosuppressant therapy was carried out using steroid- cyclophosphamide - azathioprine (Shenoy et al., 2007) and steroid- azathioprine -mycophenolate mofetil (Algoet et al., 2003; Zaffanello et al., 2007).

8.3.6 Evidence based treatment

The majority of reports provide scarce support to the various treatment options identified in cases of severe childhood Henoch-Schönlein purpura nephritis (Zaffanello et al., 2009). As the Henoch-Schönlein purpura nephritis and IgA nephropathy have identical pathogenesis and renal lesions, for which current evidence supports the use of immunosuppressive drugs

in patients with severe disease (Samuels et al., 2003; Cheng et al., 2009), the treatment protocols with proven significant benefit in IgA nephropathy should be used in children having Henoch-Schönlein purpura nephritis of comparable severity (Bogdanovic, 2009). A recent, single-centre, retrospective review looking at treatment of severe Henoch-Schönlein purpura nephropathy and IgA nephropathy demonstrated that therapy with differing combinations of steroids, cyclophosphamide, angiotensin converting enzyme inhibitors and angiotensin receptor blockers produced a good outcome in 54% of children with severe (>stage III) histological changes on initial renal biopsy (Edström Halling et al., 2009). For this reason, many physicians prescribe similar treatments in Henoch-Schönlein purpura patients with nephritis, despite the lack of disease-specific data, although IgA nephritis lesions however, tend to have a less severe inflammatory component and clinical trials on IgA nephropathy often include adult patients, while Henoch-Schönlein purpura nephropathy is primarily a disease that develops in children (Zaffanello et al., 2010).

Moreover, several patients with moderately severe Henoch-Schönlein purpura nephritis (histological grade I-III and serum albumin >2.5 g/dl) were treated with angiotensin-converting enzyme inhibitors and/or angiotensin receptor blockers. Patients with Henoch-Schönlein purpura nephritis exceeding grade III or serum albumin \leq 2.5 g/dl received combination therapy comprising prednisolone at 2 mg/kg/day, given in three divided doses (maximum dose, 80 mg/day) for the first 4 weeks, followed by prednisolone at 2 mg/kg given as a single dose every other morning for 8 weeks, immunosuppressant azathioprine at 2 mg/kg/day as a single dose (maximum dose 100 mg) or mizoribine at 5 mg/kg/day as a single dose (maximum dose 300 mg) maintained for 6 months, and warfarin at 1 mg/day given as a single dose each morning. The warfarin dose was then adjusted to give a thrombo-test result of 20-50%, and dipyridamole started at 3 mg/kg/day given in three divided doses, increased to 6 mg/kg/day (maximum dose, 300 mg/day) maintained for 8 weeks if the patient experienced no adverse effects, such as headache. The resolution of proteinuria, without renal dysfunction, was 50% at 5.2 months, 80% at 8.5 months, and 90% at 11.1 months (Ninchoji et al., 2011).

8.4 Plasma exchange

Patients featuring rapid progression of Henoch-Schönlein purpura nephritis, despite the treatment with immunosuppressive medications (steroids, azathioprine and cyclophosphamide), were treated with plasma exchange. Among these children, 36% developed end-stage renal disease between 1 and 7 years after the initiation of treatment (Gianviti et al., 1996). The other children showed a reduction of glomerular filtration rate and crescents > 50% of glomeruli and continued plasma exchange treatment (Hattori et al., 1999). A case series of eight children with a rapidly progressive course of disease treated with plasma exchange, the beneficial effects produced were only transient, and, despite repeated plasma exchange, the subjects progressed to end-stage renal disease after 1-4 years (Scharer et al., 1999). In case series study, children with extensive crescent formation underwent plasma exchange followed by multiple drug therapy, including steroids, pulse urokinase and cyclophosphamide. The patients manifested a decrease in acuity index and percentage of glomeruli with crescents, whereas the chronicity index remained unchanged (Kawasaki et al., 2004). Plasma exchange was recently performed in patients with a histology grading of at least III at renal biopsy. At follow-up, only one child treated later in the course of the disease underwent a kidney transplant. At the end of the study, the investigators reported that the early performing of plasma exchange may delay the rate of progression of cellular crescents to the fibrotic stage and end-stage renal disease (Shenoy et al., 2007).

Plasma exchange in patients with Henoch-Schönlein purpura nephritis, either alone or in combination with immunosuppressant, cannot currently be recommended due to the paucity of data available (Zaffanello & Fanos, 2009).

8.5 Adjuvant treatment

Adjuvant therapies were defined as any secondary treatment used in addition to the primary or conventional treatments that increased the likelihood of cure (eg, intravenous immunoglobulins, anticoagulants, enzymes and vitamins). Results on moderate urinary abnormalities and severe Henoch-Schönlein purpura nephritis are reported separately because the renal implications, clinical monitoring, and conventional treatment modalities differ in terms of outcome measures (Zaffanello et al., 2009).

8.5.1 Moderate urinary abnormalities

Adjuvant treatment in children with isolated proteinuria with or without nephrotic syndrome has been reviewed (Zaffanello et al., 2009).

Two studies (Rostoker et al., 1995; de Almeida et al., 2007) reported the usefulness of 3 months treatment with intravenous immunoglobulins (2 g/kg/month) followed by intramuscular immunoglobulins (0.35 mL/kg) twice a month for 8 months in treating nephritis with significant proteinuria. Both the severity of proteinuria and the acuity index significantly improved in the majority of these patients with renal histology of stage III and normal renal function. In patients with severe gastrointestinal involvement who did not respond to methylprednisolone, were administered intravenous immunoglobulins at 2 g/kg in a single dose (Rostoker et al., 1998; Aries et al., 2005). Finally, the efficacy of intravenous immunoglobulins (2 g/kg, infused over 10–12 hours) in inhibiting the progression of the disease has been tested although only in unstructured case series.

Intravenous administration of Factor XIII concentrate from 30 to 50 U/kg for 3 days was associated with significant improvements in the severity of proteinuria and hematuria compared with non-treated group (Erdoğan et al., 2003).

In children aged 3 to 15 years with Henoch-Schönlein purpura nephritis, tocopherol 300 mg/day was to be administered for 6–17 weeks (Kaku et al., 1998). Oxidative damage and worsening of the clinical course were observed despite significant increases in mean plasma vitamin E concentration. In 5 children with biopsy-proven Henoch-Schönlein purpura nephritis, treatment with an angiotensin-converting enzyme inhibitor (enalapril) for hypertension and adjuvant treatment with fish oil 1 g twice a day as an antioxidant was associated with significantly decreased severity of proteinuria, decreased blood pressure, and stable serum creatinine concentration and glomerular filtration rate. The limitation of this study was the small sample size and the confounding antiproteinuric effect of the angiotensin-converting enzyme inhibitor (Dixit et al., 2004; Chiurciu et al., 2005).

A systematic review reported no clear benefit of the use of dipyridamole (3–6 mg/kg/day for 8 weeks) and heparin (adjusted to maintain activated partial thromboplastin time between 60 and 80 seconds for 4 weeks) in treating Henoch-Schönlein purpura nephritis, with limitations being the small number of studies, small sample size, and poor methodology of the studies (Chartapisak et al., 2009).

8.5.2 Severe Henoch-Schönlein purpura nephritis

Adjuvant treatments of severe Henoch-Schönlein purpura nephritis with crescent formations in children have been studied from a systematic review (Zaffanello et al., 2009).

The patients with severe Henoch-Schönlein purpura described in these articles had nephrotic syndrome, Henoch-Schönlein purpura nephritis, rapidly progressive glomerulonephritis, and/or kidney failure. Histology of kidney biopsies found a significant proportion with crescent formations (International Study of Kidney Disease in Children grade IV-V). These patients were at high risk for kidney failure despite aggressive treatment with cocktails that included adjuvant anticoagulants or antiplatelet agents such as heparin (Iijima et al., 1998), warfarin (Kaku et al., 1998; Iijima et al., 1998; Kawasaki et al., 2004) dipyridamole (Oner et al., 1995; Kaku et al., 1998; Iijima et al., 1998; Mir et al., 2007) and acetylsalicylic acid (Mir et al., 2007). Treatments associated conventional with adjuvant therapy including three days intravenous pulse of methylprednisolone and/or long-term oral prednisolone administration for 6 months (Oner et al., 1995; Kawasaki et al., 2003; Kawasaki et al., 2004; Mir et al., 2007). Intravenous steroids were used alone (Kawasaki et al., 2003) or in combination with (or to replace) cyclophosphamide (Oner et al., 1995), or comparable steroid pulse therapy was used with cyclophosphamide (Kawasaki et al., 2004; Mir et al., 2007) and Cyclosporine A (Mir et al., 2007). Oral steroid therapy was used alone or in combination with cyclophosphamide (Iijima et al., 1998; Tanaka et al., 2003; Shekelle et al., 1999).

In a case series of 12 children aged 6 to 14 years with Henoch-Schönlein purpura, quadruple therapy with cyclophosphamide for 2 months, intravenous pulse methylprednisolone for 3 days, oral prednisone for 3 months, and adjuvant oral dipyridamole for 6 months, glomerular filtration rate normalized in 11 patients and 7 patients had complete remission (Oner et al., 1995). In a case series of 14 children followed up for a mean (standard deviation) of 7.5 (0.9) years, combination treatment consisted of prednisone for 12 weeks, cyclophosphamide for 8 weeks, and adjuvant intravenous heparin for 4 weeks followed by warfarin 1 mg/day for 4 weeks, and dipyridamole for 8 weeks. The histologic abnormalities of the kidney significantly improved in the meantime (Iijima et al., 1998).

In 2 clinical trials, cyclosporine A was used for the treatment of severe Henoch-Schönlein purpura nephritis in children, either alone (Ronkainen J, 2003) or in combination with steroids and adjuvant dipyridamole (Mir et al., 2007). In particular, a retrospective, nonrandomized study in 82 children, prednisone or pulse methylprednisolone and cyclophosphamide and cyclosporine were given; acetylsalicylic acid or dipyridamole were given as adjuvant therapy, although their dosing were not reported as well. In 35% of nephrotic patients and 62% of nephritic patients showed complete remission after 6 months and long-term course (Mir et al., 2007). In a case series of 13 patients with renal histology grade IIIb or IVb, prednisone was administered for 26 weeks and cyclophosphamide was administered for 8 weeks (Tanaka et al., 2003). Adjuvant therapy was dipyridamole 5 mg/kg/day (maximum, 300 mg/day). At study end, acuity index was significantly decreased, chronologic index was unchanged, and renal histology grade was improved significantly (Tanaka et al., 2003).

In a controlled study, 26 in 37 children with severe Henoch-Schönlein purpura nephritis, triple therapy with oral cyclophosphamide for 12 weeks, pulse methylprednisolone for 3 days, and intravenous pulse urokinase at 5000 U/kg/day (maximum, 180,000 U) for 7 consecutive days was effective. Thus, after 6 months, severity of proteinuria and mesangial IgA deposition were significantly reduced (Kawasaki et al., 2003; Kawasaki et al., 2004).

Observations were reported in retrospective case series, and the literature lacks reports of substantial clinical trials. Because the literature search did not find any well-structured studies reporting benefits of the use of antiplatelet agents or heparin in children with

Henoch-Schönlein purpura nephritis, the use of such therapy is not recommended at this time since lack of evidence from well structured clinical trials (Zaffanello et al., 2009).

9. Prognosis

9.1 Prognostic factors and clinical findings

Age at onset has not been shown to be a predictor of poor outcome (Ronkainen et al., 2002; Coppo et al., 1997; Counahan et al., 1977; Edström Halling et al., 2010). In the long-term, the morbidities of Henoch-Schönlein purpura are predominantly attributed to the intensity of renal involvement at presentation. Anymore, the majority of patients that first manifest nephropathy during childhood will not reach end stage renal disease before adulthood (Wyatt & Hogg, 2001).

Female had a markedly greater risk of a poor long-term outcome (Edström Halling et al., 2010).

Patients with isolated hematuria showed a good prognosis (Narchi, 2005), with some exceptions (Goldstein et al., 1992). Most children with Henoch-Schönlein purpura nephritis who present only with hematuria and/or low-grade proteinuria at onset have good probabilities of recovery (Mir et al., 2007). Only patients showing normal urinalysis for 6 months may be discharged from follow-up. In view of the possibility of late deterioration in those with mild renal involvement, long-term albeit annual follow-up was recommended (Narchi, 2005). It has been calculated that 18% of patients with mild proteinuria at onset progress towards poor outcome (Ronkainen et al., 2002; Butani & Morgenstern, 2007; Edström Halling et al., 2010).

Of children who at onset displayed mild symptoms, 72% achieved a complete recovery, compared to 47% of those with severe symptoms. Of children who had mild symptoms at onset, 15% had a poor outcome compared to 41% of those with severe symptoms (Edström Halling et al., 2010).

Henoch-Schönlein purpura nephritis patients with nephritic/nephritic syndrome and massive proteinuria (Niaudet & Habib, 1998) are considered to have severe disease (Kawasaki et al., 2003; Niaudet & Habib, 1998). Therefore, no significant difference in outcome was found between patients with nephrotic versus non-nephrotic proteinuria at onset. Of patients with nephrotic or nephritic-nephrotic features, 68% had a good outcome and specifically 59% of them achieved complete recovery. Level of urinary albumins/creatinine ratio at 1 year above or below 144 mg/mmol discriminated between poor and good outcome with a sensitivity of 95% and specificity of 40%, positive predictive value 82%, negative predictive value 73% (Edström Halling et al., 2010).

Patients with a poor outcome had lower Glomerular Filtration Rate than patients with a good outcome. An initial renal insufficiency was a predictor of poor renal outcome in Henoch-Schönlein purpura nephritis (Edström Halling et al., 2010).

There was no difference in outcome between patients who were normotensive and those who were hypertensive at the first investigation (Edström Halling et al., 2010).

9.2 Prognostic factors and biopsy findings

International Study of Kidney Disease in Children grading score and proteinuria at the 1-year follow-up were the best discriminators of a good and poor outcome (Edström Halling et al., 2010).

Kawasaki (Kawasaki et al., 2003) classified Henoch-Schönlein purpura nephritis patients with International Study of Kidney Disease in Children grade IIIb or higher as having severe disease. Shenoy (Shenoy et al., 2007) concluded that most children with Henoch-Schönlein purpura nephritis grade IIIb or higher on initial biopsy had persistent renal abnormalities at long-term follow-up. The risks for long-term renal impairment are highest in children who present and/or with more than 50% of glomeruli (grade IV or above) occupied by large crescents or sclerosing lesions (Bogdanovic, 2009) because they showed higher probabilities for development of progressive renal disease, renal failure, or end-stage renal disease after long-term follow-up (Iijima et al., 1998; Kawasaki et al., 2004; Niaudet & Habib, 1998).

Patients with segmental glomerulosclerosis had a poorer outcome than those without segmental glomerulosclerosis. The comparison of patients with crescents to those without or those with global glomerulosclerosis to those without revealed no difference in outcome. Patients with poor outcome had a higher degree of mesangial matrix expansion, mesangial proliferation, interstitial inflammation and interstitial fibrosis than did those with a good outcome. Crescents were not a factor of poor prognosis, but the majority of the patients with crescents were treated, which may have improved the course of the disease (Edström Halling et al., 2010).

10. Conclusion

At this time, randomized controlled trials are needed to demonstrate whether the present management with conventional and adjuvant treatments improve truly renal survival of patients with Henoch-Schönlein purpura nephritis. Anymore, the choice of the treatment must depend on both the histological and clinical severity of the Henoch-Schönlein purpura nephritis. In particular, recommendations include a combination therapy for clinically and histologically severe Henoch-Schönlein purpura nephritis, which is unnecessary for moderate Henoch-Schönlein purpura nephritis.

11. References

- Algoet, C., Proesmans, W. (2003). Renal biopsy 2–9 years after Henoch Schonlein purpura. *Pediatric Nephrology*, Vol.18, No.5, pp.471–3, ISSN 0931041X.
- Allen, A.C., Willis, F.R., Beattie, T.J., Feehally, J. Abnormal IgA glycosylation in Henoch-Schönlein purpura restricted to patients with clinical nephritis. *Nephrology Dialysis Transplantation*, Vol.13, No4, pp.930–934, ISSN 09310509.
- Aries, P.M., Hellmich, B., Gross, W.L. (2005). Intravenous immunoglobulin therapy in vasculitis: Speculation or evidence? *Clinical Reviews in Allergy and Immunology*, Vol.29, No.3, pp.237–245, ISSN 10800549.
- Assadi, F. (2009). Childhood Henoch-Schonlein nephritis: a multivariate analysis of clinical features and renal morphology at disease onset. *Iranian Journal of Kidney Diseases*, Vol.3, No.1, pp.17-21, ISSN 17358582.
- Bergstein, J., Leiser, J., Andreoli, S.P. (1998). Response of crescentic Henoch-Schönlein purpura nephritis to corticosteroid and azathioprine therapy. *Clinical Nephrology*, Vol. 49, No. 1, pp.9–14, ISSN 03010430.

- Bogdanovic, R. (2009). Henoch-Schonlein purpura nephritis in children: risk factors, prevention and treatment. *Acta Paediatrica, International Journal of Paediatrics*, Vol. 98, No. 12, pp. 1882-1889, ISSN 08035253.
- Butani, L., Morgenstern, B.Z. (2007). Long-term outcome in children after Henoch-Schonlein purpura nephritis. *Clinical Pediatrics*, Vol. 46, No. 6, pp. 505-511, ISSN 00099228.
- Chartapisak, W., Opastiraku, S., Willis, N.S., Craig, J.C., Hodson, E.M. (2009). Prevention and treatment of renal disease in Henoch-Schönlein purpura: A systematic review. *Archives of Disease in Childhood*, Vol. 94, No. 2, pp. 132-137, ISSN 00039888.
- Cheng, J., Zhang, X., Zhang, W., He, Q., Tao, X., Chen, J. (2009). Efficacy and safety of glucocorticoids therapy for IgA nephropathy: a meta-analysis of randomized controlled trials. *American Journal of Nephrology*, Vol.30, No.4, pp. 315-322, ISSN 02508095.
- Chiurciu, C., Remuzzi, G., Ruggenti, P. (2005). Angiotensin-converting enzyme inhibition and renal protection in nondiabetic patients: The data of the meta-analyses. *Journal of the American Society of Nephrology*, Vol.16, pp. S58-S63, ISSN 10466673.
- Coppo, R., Andrulli, S., Amore, A., Gianoglio, B., Conti, G., Peruzzi, L., Locatelli, F., Cagnoli, L. (2006). Predictors of outcome in Henoch-Schonlein nephritis in children and adults. *American Journal of Kidney Diseases*, Vol.47, No.6, pp.993-1003, ISSN 02726386.
- Coppo, R., Mazzucco, G., Cagnoli, L., Lupo, A., Schena, F.P. (1997). Long-term prognosis of Henoch-Schönlein nephritis in adults and children. Italian Group of Renal Immunopathology Collaborative Study on Henoch-Schönlein purpura. *Nephrology Dialysis Transplantation*, Vol. 12, No. 11, pp. 2277-83, ISSN 09310509.
- Counahan, R., Winterborn, M.H., White, R.H., Heaton, J.M., Meadow, S.R., Bluett, N.H., Swetschin, H., Cameron, J.S., Chantler, C. (1977). Prognosis of Henoch-Schönlein nephritis in children. *British medical journal*, Vol.2, pp.11 - 14, ISSN 00071447.
- Davin, J.C., Weening, J.J. (2003). Diagnosis of Henoch-Schönlein purpura: renal or skin biopsy? *Pediatric Nephrology*, Vol.18, No.12, pp. 1201-1203, ISSN 0931041X.
- de Almeida, J.L., Campos, L.M., Paim, L.B., Leone, C., Koch, V.H., Silva, C.A. (2007). Renal involvement in Henoch-Schönlein purpura: A multivariate analysis of initial prognostic factors. *Jornal de Pediatria*, Vol.83, No.3, pp.259-266, ISSN 00217557.
- Dixit, M.P., Dixit, N.M., Scott, K. (2004). Managing Henoch-Schönlein purpura in children with fish oil and ACE inhibitor therapy. *Nephrology (Carlton)*, Vol. 9, No. 6, pp.381-386, ISSN 13205358.
- Edström Halling, S., Söderberg, M.P., Berg, U.B. (2010). Predictors of outcome in Henoch-Schönlein nephritis. *Pediatric Nephrology*, Vol.25, pp.1101-1108, ISSN 0931041X.
- Edström Halling, S., Söderberg, M.P., Berg, U.B. (2009). Treatment of severe Henoch-Schönlein and immunoglobulin A nephritis. A single center experience. *Pediatric Nephrology*, Vol.24, No. 1, pp.91-97, ISSN 0931041X.
- Erdoğan, O., Oner, A., Aydin, A., Işimer, A., Demircin, G., Bülbül, M. (2003). Effect of vitamin E treatment on the oxidative damage occurring in Henoch-Schönlein purpura. *Acta Paediatrica, International Journal of Paediatrics*, Vol.92, pp. 546-550, ISSN 08035253.
- Evans, D.J., Williams, D.G., Peters, D.K., Sissons, J.G., Boulton-Jones, J.M., Ogg, C.S., Cameron, J.S., Hoffbrand, B.I. (1973). Glomerular deposition of properdin in

- Henoch-Schönlein syndrome and idiopathic focal nephritis. *British Medical Journal*, Vol.3, pp.326–328, ISSN 00071447 .
- Falkner, B., Daniels, S.R., Flynn, J.T., Gidding, S., Green, L.A., Ingelfinger, J.R., Lauer, R.M., Morgenstern, B.Z., Portman, R.J., Prineas, R.J., Rocchini, A.P., Rosner, B., Sinaiko, A.R., Stettler, N., Urbina, E., Roccella, E.J., Hoke, T., Hunt, C.E., Pearson, G., Karimbakas, J., Horton, A. (2004). The fourth report on the diagnosis, evaluation, and treatment of high blood pressure in children and adolescents. *Pediatrics*, Vol.114, No.2, pp. 555-76, ISSN 00314005.
- Farine, M., Poucell, S., Geary, D.L., Baumal, R. (1986). Prognostic significance of urinary findings and renal biopsies in children with Henoch-Schönlein nephritis. *Clinical Pediatrics (Phila)*, Vol.25, pp.257–259, ISSN 00099228.
- Filler, G., Hansen, M., LeBlanc, C., Lepage, N., Franke, D., Mai, I., Feber, J. (2003). Pharmacokinetics of mycophenolate mofetil for autoimmune disease in children. *Pediatric Nephrology*, Vol. 18, pp. 445–449, ISSN 0931041X.
- Flynn, J.T., Smoyer, W.E., Bunchman, T.E., Kershaw, D.B., Sedman, A.B. (2001). Treatment of Henoch-Schönlein purpura glomerulonephritis in children with high-dose corticosteroids plus oral cyclophosphamide. *American Journal of Nephrology*, Vol.21, pp.128–133, ISSN 02508095.
- Foster, B.J., Bernard, C., Drummond, K.N., Sharma, A.K. (2000). Effective therapy for severe Henoch-Schönlein purpura nephritis with prednisone and azathioprine: a clinical and histopathologic study. *Journal of Pediatrics*, Vol. 136, pp.370-375, ISSN 00223476.
- Gardner-Medwin, J.M., Dolezalova, P., Cummins, C., Southwood, T.R. (2002). Incidence of Henoch-Schönlein purpura, Kawasaki disease, and rare vasculitides in children of different ethnic origins. *Lancet*, Vol. 360, pp.1197–1202, ISSN 01406736.
- Gianviti, A., Trompeter, R.S., Barratt, T.M., Lythgoe, M.F., Dillon, M.J. (1996). Retrospective study of plasma exchange in patients with idiopathic rapidly progressive glomerulonephritis and vasculitis. *Archives of Disease in Childhood* , Vol. 75, pp. 186–190, ISSN 00039888.
- Gibson, K.L., Amamoo, M.A., Primack, W.A. (2008). Corticosteroid Therapy for Henoch Schönlein Purpura. *Pediatrics*, Vol.121, pp.870-871, ISSN 00314005.
- Goldstein, A.R., White, R.H., Akuse, R., Chantler, C. (1992). Long-term follow-up of childhood Henoch-Schönlein nephritis. *Lancet*, Vol. 339, pp.280–2, ISSN 01406736.
- Hattori, M., Ito, K., Konomoto, T., Kawaguchi, H., Yoshioka, T., Khono, M. (1999). Plasmapheresis as the sole therapy for rapidly progressive Henoch-Schönlein purpura nephritis in children. *American Journal of Kidney Diseases* , Vol. 33, pp.427–433, ISSN 02726386.
- Hung, S.P., Yang, Y.H., Lin, Y.T., Wang, L.C., Lee, J.H., Chiang, B.L. (2009). Clinical manifestations and outcomes of Henoch-Schönlein purpura: comparison between adults and children. *Pediatrics and Neonatology*, Vol.50, No.4, pp.162–168, ISSN 18759572.
- Iijima, K., Ito-Kariya, S., Nakamura, H., Yoshikawa, N. (1998). Multiple combined therapy for severe Henoch-Schönlein nephritis in children. *Pediatric Nephrology*, Vol.12, pp. 244-248, ISSN 0931041X.
- Inoue, C.N., Chiba, Y., Morimoto, T., Nishio, T., Kondo, Y., Adachi, M., Matsutani, S. (2007). Tonsillectomy in the treatment of pediatric Henoch-Schönlein nephritis. *Clinical Nephrology*, Vol.67, pp. 298–305, ISSN 03010430.

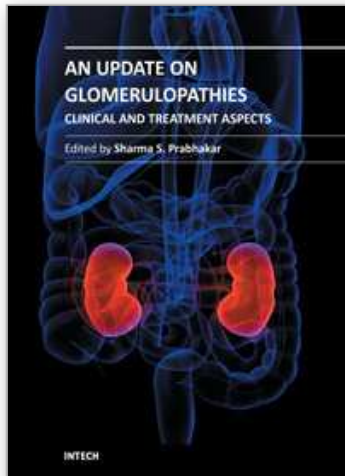
- Iqbal, H., Evans, A. (2005). Dapsone therapy for Henoch-Schönlein purpura: a case series. *Archives of Disease in Childhood*, Vol.90, pp.985-986, ISSN 00039888.
- Jauhola, O., Ronkainen, J., Koskimies, O., Ala-Houhala, M., Arikoski, P., Hölttä, T., Jahnukainen, T., Rajantie, J., Örmälä, T., Turtinen, J., Nuutinen, M. (2010). Renal manifestations of Henoch-Schönlein purpura in a 6-month prospective study of 223 children. *Archives of Disease in Childhood*, Vol.95, pp.877-882, ISSN 00039888.
- Kaku, Y., Nohara, K., Honda, S. (1998). Renal involvement in Henoch-Schönlein purpura: a multivariate analysis of prognostic factors. *Kidney International*, Vol.53, pp.1755-1759, ISSN 00852538.
- Kawasaki, Y., Suyama, K., Yugeta, E., Katayose, M., Suzuki, S., Sakuma, H., Nemoto, K., Tsukagoshi, A., Nagasawa, K., Hosoya, M. (2010). The incidence and severity of Henoch-Schoenlein purpura nephritis over a 22-year period in Fukushima Prefecture, Japan. *International Urology and Nephrology*, Vol.42, pp.1023-1029, ISSN 03011623.
- Kawasaki, Y., Suzuki, J., Murai, M., Takahashi, A., Isome, M., Nozawa, R., Suzuki, S., Suzuki, H. (2004). Plasmapheresis therapy for rapidly progressive Henoch-Schönlein nephritis. *Pediatric Nephrology*, Vol.19, No.920-923, ISSN 0931041X.
- Kawasaki, Y., Suzuki, J., Nozawa, R., Suzuki, S., Suzuki, H. (2003). Efficacy of methylprednisolone and urokinase pulse therapy for severe Henoch-Schonlein nephritis. *Pediatrics*, Vol.111, pp.785-789, ISSN 00314005.
- Kawasaki, Y., Suzuki, J., Suzuki, H. (2004). Efficacy of methylprednisolone and urokinase pulse therapy combined with or without cyclophosphamide in severe Henoch-Schoenlein nephritis: a clinical and histopathological study. *Nephrology Dialysis Transplantation*, Vol.19, pp.858-864, ISSN 09310509.
- Lai, K.N., To, W.Y., Li, P.K., Leung, J.C. (1996). Increased binding of polymeric lambda-IgA to cultured human mesangial cells in IgA nephropathy. *Kidney International*, Vol.49, pp.839-845, ISSN 00852538.
- Lau, K.K., Suzuki, H., Novak, J., Wyatt, R.J. (2010). Pathogenesis of Henoch-Schönlein purpura nephritis. *Pediatric Nephrology*, Vol.25, No.1, pp.19-26, ISSN 0931041X.
- Levinsky, R.J., Barratt, T.M. (1979). IgA immune complexes in Henoch-Schönlein purpura. *Lancet*, Vol.2, pp.1100-1103, ISSN 01406736.
- McCarthy, H.J., Tizard, E.J. (2010). Diagnosis and management of Henoch-Schönlein purpura. *European Journal of Pediatrics*, Vol.169, pp.643-650, ISSN 03406199.
- Meadow, S.R., Glasgow, E.F., White, R.H., Moncrieff, M.W., Cameron, J.S., Ogg, C.S. (1972). Schönlein-Henoch nephritis. *The Quarterly journal of medicine*, Vol.41, pp.241-258, ISSN 00335622.
- Meulders, Q., Pirson, Y., Cosyns, J.P., Squifflet, J.P., van Ypersele de, Strihou, C. (1994). Course of Henoch-Schönlein nephritis after renal transplantation. Report on ten patients and review of the literature. *Transplantation*, Vol.58, pp.1179-1186, ISSN 00411337.
- Mir, S., Yavascan, O., Mutlubas, F., Yeniay, B., Sonmez, F. (2007). Clinical outcome in children with Henoch-Schönlein nephritis. *Pediatric Nephrology*, Vol.22, pp.64-70, ISSN 0931041X.
- Mollica, F., Li Volti, S., Garozzo, R., Russo, G. (1992). Effectiveness of early prednisone treatment in preventing the development of nephropathy in anaphylactoid purpura. *European Journal of Pediatrics*, Vol.151, No.2, pp.140-4, ISSN 03406199.

- Motoyama, O., Iitaka, K. (2005). Henoch-Schönlein purpura with hypocomplementemia in children. *Pediatrics international : official journal of the Japan Pediatric Society*, Vol.47, pp.39-42, ISSN 13288067.
- Moura, I.C., Arcos-Fajardo, M., Sadaka, C., Leroy, V., Benhamou, M., Novak, J., Vrtovsni, F., Haddad, E., Chintalacharuvu, K.R., Monteiro, R.C. (2004). Glycosylation and size of IgA1 are essential for interaction with mesangial transferrin receptor in IgA nephropathy. *Journal of the American Society of Nephrology*, Vol.15, pp.622-634, ISSN 10466673.
- Narchi, H. (2005). Risk of long term renal impairment and duration of follow up recommended for Henoch-Schönlein purpura with normal or minimal urinary findings: a systematic review. *Archives of Disease in Childhood*, Vol.90, pp.916-920, ISSN 00039888.
- Niaudet, P., Habib, R. (1998). Methylprednisolone pulse therapy in the treatment of severe forms of Schonlein-Henoch purpura nephritis. *Pediatric Nephrology*, Vol.12, pp.238-243, ISSN 0931041X.
- Ninchoji, T., Kaito, H., Nozu, K., Hashimura, Y., Kanda, K., Kamioka, I., Shima, Y., Hamahira, K., Nakanishi, K., Tanaka, R., Yoshikawa, N., Iijima, K., Matsuo, M. (2011). Treatment strategies for Henoch-Schönlein purpura nephritis by histological and clinical severity. *Pediatric Nephrology*, Vol.26, No.4, pp.563-9, ISSN 0931041X.
- Novak, J., Moldoveanu, Z., Renfrow, M.B., Yanagihara, T., Suzuki, H., Raska, M., Hall, S., Brown, R., Huang, W.Q., Goepfert, A., Kilian, M., Poulsen, K., Tomana, M., Wyatt, R.J., Julian, B.A., Mestecky, J. (2007). IgA nephropathy and Henoch-Schoenlein purpura nephritis: aberrant glycosylation of IgA1, formation of IgA1-containing immune complexes, and activation of mesangial cells. *Contributions to Nephrology*, Vol.157, pp.134-138, ISSN 03025144.
- Oner, A., Tinaztepe, K., Erdogan, O. (1995). The effect of triple therapy on rapidly progressive type of Henoch-Schonlein nephritis. *Pediatric Nephrology*, Vol.9, pp.6-10, ISSN 0931041X.
- Ozen, S., Ruperto, N., Dillon, M.J., Bagga, A., Barron, K., Davin, J.C., Kawasaki, T., Lindsley, C., Petty, R.E., Prieur, A.M., Ravelli, A., Woo, P. (2006). EULAR/PReS endorsed consensus criteria for the classification of childhood vasculitides. *Annals of the Rheumatic Diseases*, Vol.65, No.7, pp.936-41, ISSN 00034967.
- Pillebout, E., Thervet, E., Hill, G., Alberti, C., Vanhille, P., Nochy, D. (2002). Henoch-Schönlein purpura in adults: outcome and prognostic factors. *Journal of the American Society of Nephrology*, Vol.13, pp.1271-8, ISSN 10466673.
- Rai, A., Nast, C., Adler, S. (1999). Henoch-Schönlein purpura nephritis. *Journal of the American Society of Nephrology*, Vol.10, pp.2637-2644, ISSN 10466673.
- Rigante, D., Candelli, M., Federico, G., Bartolozzi, F., Porri, M.G., Stabile, A. (2005). Predictive factors of renal involvement or relapsing disease in children with Henoch Schönlein purpura. *Rheumatology International*, Vol.25, pp.45-48, ISSN 01728172.
- Ronkainen, J., Ala-Houhala, M., Autio-Harmainen, H., Jahnukainen, T., Koskimies, O., Merenmies, J., Mustonen, J., Ormala, T., Turtinen, J., Nuutinen, M. (2006). Long-term outcome 19 years after childhood IgA nephritis: a retrospective cohort study. *Pediatric Nephrology*, Vol.21, pp.1266-1273, ISSN 0931041X.

- Ronkainen, J., Autio-Harmanen, H., Nuutinen, M. (2003). Cyclosporin A for the treatment of severe Henoch-Schönlein glomerulonephritis. *Pediatric Nephrology*, Vol.18, pp.1138-1142, ISSN 0931041X.
- Ronkainen, J., Koskimies, O., Ala-Houhala, M., Antikainen, M., Merenmies, J., Rajantie, J., Örmälä, T., Turtinen, J., Nuutinen, M. (2006). Early prednisone therapy in Henoch-Schönlein purpura: a randomized, double-blind, placebo-controlled trial. *Journal of Pediatrics*, Vol.149, pp.241-247, ISSN 00223476.
- Ronkainen, J., Nuutinen, M., Koskimies, O. (2002). The adult kidney 24 years after childhood Henoch-Schönlein purpura: a retrospective cohort study. *Lancet*, Vol.360, pp.666 – 70, ISSN 01406736.
- Rostoker, G., Desvaux-Belghiti, D., Pilatte, Y., Petit-Phar, M., Philippon, C., Deforges, L., Terzidis, H., Intrator, L., André, C., Adnot, S., Bonin, P., Bierling, P., Remy, P., Lagrue, G., Lang, P., Weil, B. (1995). Immunomodulation with low-dose immunoglobulins for moderate results of a prospective uncontrolled trial. *Nephron*, Vol.69, pp.327-334, ISSN 00282766.
- Rostoker, G., Desvaux-Belghiti, D., Pilatte, Y., Petit-Phar, M., Philippon, C., Deforges, L., Terzidis, H., Intrator, L., André, C., Adnot, S., Bonin, P., Bierling, P., Remy, P., Lagrue, G., Lang, P., Weil, B. (1994). High-dose immunoglobulin therapy for severe IgA nephropathy and Henoch-Schönlein purpura. *Annals of Internal Medicine*, Vol. 120, pp.476-484, ISSN 00034819.
- Rostoker, G., Rymer, J.C., Bagnard, G., Petit-Phar, M., Griuncelli, M., Pilatte, Y. (1998). Imbalances in serum proinflammatory cytokines and their soluble receptors: A putative role in the progression of idiopathic IgA nephropathy (IgAN) and Henoch-Schönlein purpura nephritis, and a potential target of immunoglobulin therapy? *Clinical and Experimental Immunology*, Vol.114, pp.468-476, ISSN 00099104.
- Rostoker, G. (2001). Schönlein-Henoch purpura in children and adults: diagnosis, pathophysiology and management. *Biodrugs*, Vol.15, pp.99-138, ISSN 11738804.
- Samuels, J.A., Strippoli, G.F., Craig, J.C., Schena, F.P., Molony, D.A. (2003). Immunosuppressive agents for treating IgA nephropathy. *Cochrane Database Syst Rev*, No.4, CD003965, ISSN 1469493X (electronic).
- Sanai, A., Kudoh, F. (1996). Effects of tonsillectomy in children with IgA nephropathy, purpura nephritis, or other chronic glomerulolIgA nephropathy, purpura nephritis, or other chronic glomerulonephritides. *Acta Otolaryngologica. Supplementum*, Vol.523, pp.172-174, ISSN 0365-5237.
- Sano, H., Izumida, M., Shimizu, H., Ogawa, Y. (2002). Risk factors of renal involvement and significant proteinuria in Henoch-Schönlein purpura. *European Journal of Pediatrics*, Vol.161, pp.196-201, ISSN 0340-6199.
- Saulsbury, F.T. (2007). Clinical update: Henoch-Schönlein purpura. *Lancet*, Vol.369, pp.976-978, ISSN 01406736.
- Saulsbury, F.T. (2001). Henoch-Schönlein purpura. *Curr Opin Rheumatol*, Vol.13, No.1, pp.35-40, ISSN 10408711.
- Saulsbury, F.T. (1999). Henoch-Schönlein purpura: report of 100 patients and review of the literature. *Medicine*, Vol.78, pp.395-409, ISSN 00257974.
- Saulsbury, F.T. (2009). Successful treatment of prolonged Henoch-Schönlein purpura with colchicine. *Clinical Pediatrics*, Vol.48, pp.866-868, ISSN 00099228.

- Scharer, K., Krmar, R., Querfeld, U., Ruder, H., Waldherr, R., Schaefer, F. (1999). Clinical outcome of Schonlein-Henoch purpura nephritis in children. *Pediatric Nephrology*, Vol.13, pp.816-823, ISSN 0931041X.
- Schmitt, R., Carlsson, F., Mörgelin, M., Tati, R., Lindahl, G., Karpman, D. (2010). Tissue deposits of IgA-binding streptococcal M proteins in IgA nephropathy and Henoch-Schonlein purpura. *American Journal of Pathology*, Vol. 176, No.2, pp.608-18, ISSN 00029440.
- Shekelle, P.G., Woolf, S.H., Eccles, M., Grimshaw, J. (1999). Clinical guidelines: Developing guidelines. *British Medical Journal*, Vol.318, pp.593-596, ISSN 09598146.
- Shenoy, M., Bradbury, M.G., Lewis, M.A., Webb, N.J. (2007). Outcome of Henoch-Schonlein purpura nephritis treated with long-term immunosuppression. *Pediatric Nephrology*, Vol.22, pp.1717-1722, ISSN 0931041X.
- Shenoy, M., Ognjanovic, M.V., Coulthard, M.G. (2007). Treating severe Henoch-Schönlein and IgA nephritis with plasmapheresis alone. *Pediatric Nephrology*. Vol.22, pp.1167-1171, ISSN 0931041X.
- Shin, J.I., Kim, J.H., Lee, J.S., Kim, P.K., Jeong, H.J. (2007). Methylprednisolone and cyclosporin therapy in a patient with nephroticproteinuria. *Indian Journal of Pediatrics*, Vol.74, pp.593-594, ISSN 0973-7693.
- Shin, J.I., Park, J.M., Kim, J.H., Lee, J.S., Jeong, H.J. (2006). Factors affecting histological regression of crescentic Henoch-Schönlein nephritis in children. *Pediatric Nephrology*, Vol.21, pp.54-59, ISSN 0931041X.
- Shin, J.I., Park, J.M., Lee, J.S., Kim, J.H., Kim, P.K., Jeong, H.J. (2006). Successful use of cyclosporin A in severe Schönlein-Henoch nephritis resistant to both methylprednisolone pulse and azathioprine. *Clinical Rheumatology*, Vol.25, pp.759-760, ISSN 07703198.
- Shin, J.I., Park, J.M., Shin, Y.H., Hwang, D.H., Kim, J.H., Lee, J.S. (2006). Predictive factors for nephritis, relapse, and significant proteinuria in childhood Henoch-Schönlein purpura. *Scandinavian Journal of Rheumatology*, Vol.35, pp.56-60, ISSN 03009742.
- Shin, J.I., Park, J.M., Shin, Y.H., Kim, J.H., Kim, P.K., Lee, J.S., Jeong, H.J. (2005). Cyclosporin A therapy for severe Henoch-Schönlein nephritis with nephrotic syndrome. *Pediatric Nephrology*, Vol.20, pp.1093-1097, ISSN 0931041X.
- Shin, J.I., Park, J.M., Shin, Y.H., Kim, J.H., Lee, J.S., Kim, P.K., Jeong, H.J. (2005). Can azathioprine and steroids alter the progression of severe Henoch-Schönlein nephritis in children? *Pediatric Nephrology*, Vol.20, pp.1087-1092, ISSN 0931041X.
- Singh, S., Devidayal, Kumar, L., Joshi, K., Minz, R.W., Datta, U. (2002). Severe Henoch-Schönlein nephritis: resolution with azathioprine and steroids. *Rheumatology International*, Vol.22, pp.133-137, ISSN 01728172.
- Soler, M.J., Mir, M., Rodriguez, E., Orfila, A., Munne, A., Vázquez, S., Lloveras, J., Puig, J.M. (2005). Recurrence of IgA nephropathy and Henoch-Schönlein purpura after kidney transplantation: risk factors and graft survival. *Transplantation Proceedings*, Vol.37, pp.3705-3709, ISSN 00411345.
- Soylemezoglu, O., Ozkaya, O., Ozen, S., Bakkaloglu, A., Dusunsel, R., Peru, H., Cetinyurek, A., Yildiz, N., Donmez, O., Buyan, N., Mir, S., Arisoy, N., Gur-Guven, A., Alpay, H., Ekim, M., Aksu, N., Soylu, A., Gok, F., Poyrazoglu, H., Sonmez, F. (2009). Turkish Pediatric Vasculitis Study Group.Henoch-Schonlein nephritis: a nationwide study. *Nephron - Clinical Practice*, Vol.112, No.3, pp.c199-204, ISSN 16602110.

- Stewart, M., Savage, J.M., Bell, B., McCord, B. (1988). Long term renal prognosis of Henoch-Schönlein purpura in an unselected childhood population. *European Journal of Pediatrics*, Vol.147, pp.113–5, ISSN 03406199.
- Suzuki, H., Moldoveanu, Z., Hall, S., Brown, R., Vu, H.L., Novak, L., Julian, B.A., Tomana, M., Wyatt, R.J., Edberg, J.C., Alarcón, G.S., Kimberly, R.P., Tomino, Y., Mestecky, J., Novak, J. (2008). IgA1-secreting cell lines from patients with IgA nephropathy produce aberrantly glycosylated IgA1. *The Journal of Clinical Investigation*, 2008 Vol.118, No.2, pp.629-39. ISSN 00219738.
- Suzuki, H., Suzuki Y., Narita, I., Aizawa, M., Kihara, M., Yamanaka, T., Kanou, T., Tsukaguchi, H., Novak, J., Horikoshi, S., Tomino, Y. (2008). Toll-like receptor 9 affects severity of IgA nephropathy. *Journal of the American Society of Nephrology*, Vol.19, No.12, pp. 2384-2395, ISSN 10466673.
- Tanaka, H., Suzuki, K., Nakahata, T., Ito, E., Waga, S. (2003). Early treatment with oral immunosuppressants in severe proteinuric purpura nephritis. *Pediatric Nephrology*, Vol.18, pp.347–350, ISSN 0931041X.
- Tarshish, P., Bernstein, J., Edelmann, C.M., Jr. (2004). Henoch-Schönlein purpura nephritis: course of disease and efficacy of cyclophosphamide. *Pediatric Nephrology*, Vol.19, pp.51-56, ISSN 0931041X.
- Tizard, E.J., Hamilton-Ayres, M.J. (2008). Henoch Schönlein purpura. *Archives of Disease in Childhood Educ Pract Ed*, Vol. 93, No.1, pp.1-8, ISSN 17430585.
- Trapani, S., Micheli, A., Grisolia, F., Resti, M., Chiappini, E., Falcini, F., De Martino, M. (2005). Henoch-Schönlein purpura in childhood: epidemiological and clinical analysis of 150 cases over a 5-year period and review of literature. *Seminars in Arthritis and Rheumatism*, Vol.35, pp.143-153, ISSN 00490172.
- Waldo, F.B. (1988). Is Henoch-Schönlein purpura the systemic form of IgA nephropathy? *American Journal of Kidney Diseases*, Vol.12, pp.373–377, ISSN 02726386.
- Wyatt, R.J., Hogg, R.J. (2001). Evidence-based assessment of treatment options for children with IgA nephropathies. *Pediatric Nephrology*, Vol.16, pp.156–167, ISSN 0931041X.
- Wyatt, R.J., Kanayama, Y., Julian, B.A., Negoro, N., Sugimoto, S., Hudson, E.C., Curd, J.G. (1987). Complement activation in IgA nephropathy. *Kidney International*, Vol.31, pp.1019–1023, ISSN 00852538.
- Yang, Y.H., Hung, C.F., Hsu, C.R., Wang, L.C., Chuang, Y.H., Lin, Y.T., Chiang, B.L. (2005). A nationwide survey on epidemiological characteristics of childhood Henoch-Schönlein purpura in Taiwan. *Rheumatology*, Vol.44, pp.618–22, ISSN 14620324.
- Zaffanello, M., Brugnara, M., Franchini, M. (2007). Therapy for children with henoch-schönlein purpura nephritis: a systematic review. *ScientificWorldJournal*, Vol.7, pp.20-30, ISSN 1537-744X.
- Zaffanello, M., Brugnara, M., Franchini, M., Fanos, V. (2009). Adjuvant Treatments in Henoch-Schönlein Purpura Nephritis in Children: a systematic review. *Current Therapeutic Research - Clinical and Experimental*, Vol.70, No.3, pp. 254-265, ISSN 0011393X.
- Zaffanello, M., Emma, F., Weiss, P.F., Hastings, M.C., Eison, T.M. (2010). Commentaries on 'Interventions for preventing and treating kidney disease in Henoch-Schönlein Purpura'. *Evidence-Based Child Health*, Vol.5, pp.703–708, ISSN.
- Zaffanello, M., Fanos, V. (2009). Treatment-based literature of Henoch-Schönlein purpura. *Pediatric Nephrology*, Vol.24, pp.1901–1911, ISSN 0931041X.



An Update on Glomerulopathies - Clinical and Treatment Aspects

Edited by Prof. Sharma Prabhakar

ISBN 978-953-307-673-7

Hard cover, 468 pages

Publisher InTech

Published online 02, November, 2011

Published in print edition November, 2011

An Update on Glomerulopathies - Clinical and Treatment Aspects is a systemic overview of recent advances in clinical aspects and therapeutic options in major syndromes of glomerular pathology. The book contains twenty four chapters divided conveniently into five sections. The first section deals with primary glomerulopathies, and the second section is devoted to glomerulopathies complicating infectious conditions. The third section deals with systemic autoimmune disorders and vasculitides which constitute major causes of glomerular disease and often renal failure. The fourth section includes chapters discussing the glomerular involvement in some major metabolic and systemic conditions. The final section has chapters which relate to some general aspects of glomerular diseases. This book will form an excellent reference tool for practicing and academic nephrology community.

How to reference

In order to correctly reference this scholarly work, feel free to copy and paste the following:

Marco Zaffanello (2011). Henoch-Schönlein Purpura Nephritis in Childhood, An Update on Glomerulopathies - Clinical and Treatment Aspects, Prof. Sharma Prabhakar (Ed.), ISBN: 978-953-307-673-7, InTech, Available from: <http://www.intechopen.com/books/an-update-on-glomerulopathies-clinical-and-treatment-aspects/henoch-scho-nlein-purpura-nephritis-in-childhood>

INTECH
open science | open minds

InTech Europe

University Campus STeP Ri
Slavka Krautzeka 83/A
51000 Rijeka, Croatia
Phone: +385 (51) 770 447
Fax: +385 (51) 686 166
www.intechopen.com

InTech China

Unit 405, Office Block, Hotel Equatorial Shanghai
No.65, Yan An Road (West), Shanghai, 200040, China
中国上海市延安西路65号上海国际贵都大饭店办公楼405单元
Phone: +86-21-62489820
Fax: +86-21-62489821

© 2011 The Author(s). Licensee IntechOpen. This is an open access article distributed under the terms of the [Creative Commons Attribution 3.0 License](https://creativecommons.org/licenses/by/3.0/), which permits unrestricted use, distribution, and reproduction in any medium, provided the original work is properly cited.

IntechOpen

IntechOpen