

We are IntechOpen, the world's leading publisher of Open Access books Built by scientists, for scientists

6,900

Open access books available

186,000

International authors and editors

200M

Downloads

Our authors are among the

154

Countries delivered to

TOP 1%

most cited scientists

12.2%

Contributors from top 500 universities



WEB OF SCIENCE™

Selection of our books indexed in the Book Citation Index
in Web of Science™ Core Collection (BKCI)

Interested in publishing with us?
Contact book.department@intechopen.com

Numbers displayed above are based on latest data collected.
For more information visit www.intechopen.com



Clinical Study on Modified Boron Neutron Capture Therapy for Newly Diagnosed Glioblastoma

Shinji Kawabata^{1,*}, Yoko Matsushita¹, Motomasa Furuse¹,
Shin-Ichi Miyatake¹, Toshihiko Kuroiwa¹ and Koji Ono²

¹Department of Neurosurgery, Osaka Medical College,
Takatsuki, Osaka

²Kyoto University Research Reactor Institute,
Kumatori, Osaka
Japan

1. Introduction

Boron neutron capture therapy (BNCT) is based on the nuclear capture and fission reactions that occur when non-radioactive boron-10 (^{10}B) is irradiated with neutrons of the appropriate energy to yield high energy alpha particles (^4He) and recoiling lithium-7 (^7Li) nuclei. Since these particles have pathlengths of approximately one cell diameter, their lethality primarily is limited to boron containing cells. BNCT, therefore, can be regarded as both a biologically and a physically targeted type of radiation therapy (Fig. 1). Its success is dependent upon the selective delivery of sufficient amounts of ^{10}B to cancer cells with only small amounts localized in the surrounding normal tissues. A wide variety of boron delivery agents have

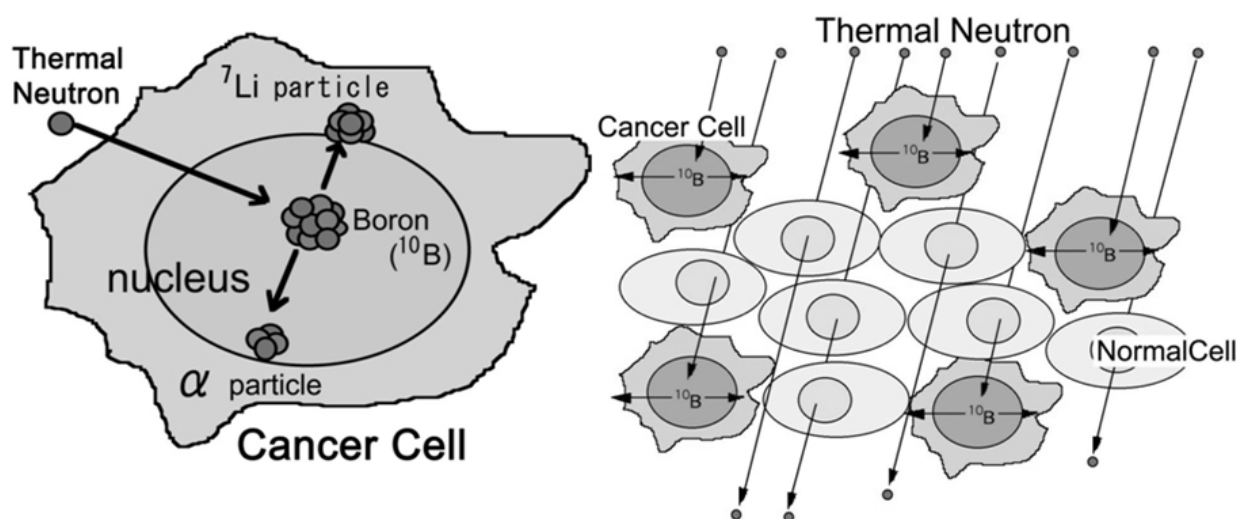


Fig. 1. The principle of boron neutron capture therapy (BNCT).

been synthesized (Hiramatsu *et al.* 2011, Miyata *et al.* 2011, Wu *et al.* 2007, Yang *et al.* 2006), but only two of these currently are being used in clinically. The first, which has been used primarily in Japan, is sodium borocaptate or BSH, and the second is a dihydroxyboryl derivative of phenylalanine referred to as boronophenylalanine or BPA (Barth *et al.* 2005). The latter has been used in clinical trials in Japan, Europe and the United States, primarily for the treatment of high grade gliomas, and more recently for recurrent tumors of the head and neck region (Ariyoshi *et al.* 2007, Haginomori *et al.* 2009, Kimura *et al.* 2009). Following i.v. administration of either BPA or BSH by i.v. infusion, the tumor site is irradiated with neutrons, the source of which is a nuclear reactor.

Recently, BNCT studies carried out by us at Osaka Medical College (OMC) and Kyoto University Research Reactor Institute (KURRI), in which BPA and BSH were administered in combination (Kawabata *et al.* 2003, Miyatake *et al.* 2005, Miyatake *et al.* 2009) for the patients with recurrent tumor after irradiation, or BNCT followed by an X-ray boost showed favorable responses in patients with newly-diagnosed glioblastoma (GB) and especially those in high risk groups (Kawabata *et al.* 2009a).

2. Clinical studies of our modified boron neutron capture therapy

Since the 1950s, BNCT has been used to treat malignant gliomas, although the results have not been satisfactory. We modified the therapy in several ways to resolve problems previously existing, and applied this modified BNCT to malignant gliomas beginning in 2002 by using KURRI (Kawabata *et al.* 2003). First, we utilized an epithermal rather than a thermal beam to improve the distribution of thermal neutrons in deep sites. Second, we used both of the boron compounds that are currently available worldwide for BNCT: sodium borocaptate (BSH) and boronophenylalanine (BPA). These compounds reach different subpopulations of tumor cells and accumulate in them in a different fashion.

2.1 Survival benefit from modified boron neutron capture therapy in combination with external beam fractionated X-ray treatment

We evaluate the clinical results of a form of tumor selective particle radiation, BNCT in combination with external beam fractionated X-ray treatment (XRT) for newly-diagnosed GB patients. Between 2002 and 2006, we treated 21 patients of newly-diagnosed GB with BNCT utilizing sodium borocaptate and boronophenylalanine simultaneously. The first 10 were treated with only BNCT (protocol 1), and the last 11 were treated with BNCT followed by fractionated XRT of 20 to 30 Gy (protocol 2) to reduce the possibility of local tumor recurrence. No chemotherapy was applied until tumor progression was observed.

2.1.1 Methods and the study design of our modified BNCT with XRT

As mentioned previously, we modified the protocol of BNCT as follows: First, we started using epithermal neutrons instead of thermal neutrons to obtain good penetration for deep-seated lesions. Second, we simultaneously used 2 different boron compounds (BSH and BPA) with different accumulation mechanisms to the tumor cells (Ono *et al.* 1999, Yokoyama *et al.* 2006). Third, we utilized a dose simulation work station, the Simulation Environments for Radiotherapy Applications (SERA; Idaho National Laboratory, Idaho Falls, ID) or the JAERI computational dosimetry system (JCDS). Fourth, ^{18}F -labeled BPA positron emission tomography (^{18}F -BPA-PET) (Fig.2) was applied for the estimation of the boron compound

accumulation prior to neutron irradiation (Imahori *et al.* 1998). Fifth, we filled the tumor removed cavity with air to obtain enough neutron flux, especially for the bottom of deep-seated tumors (Sakurai *et al.* 2006). Sixth, we developed a central shielding method with a lithium plate at the center of the irradiation field to obtain uniform neutron distribution and increase the neutron flux relatively at the periphery in the radiation field (Ono 2006, Ono *et al.* 2000). With these modifications, even patients with deep-seated tumors can be treated by BNCT without craniotomy with a short hospital stay. In the present study, the revised protocol was used as a new protocol as follows.

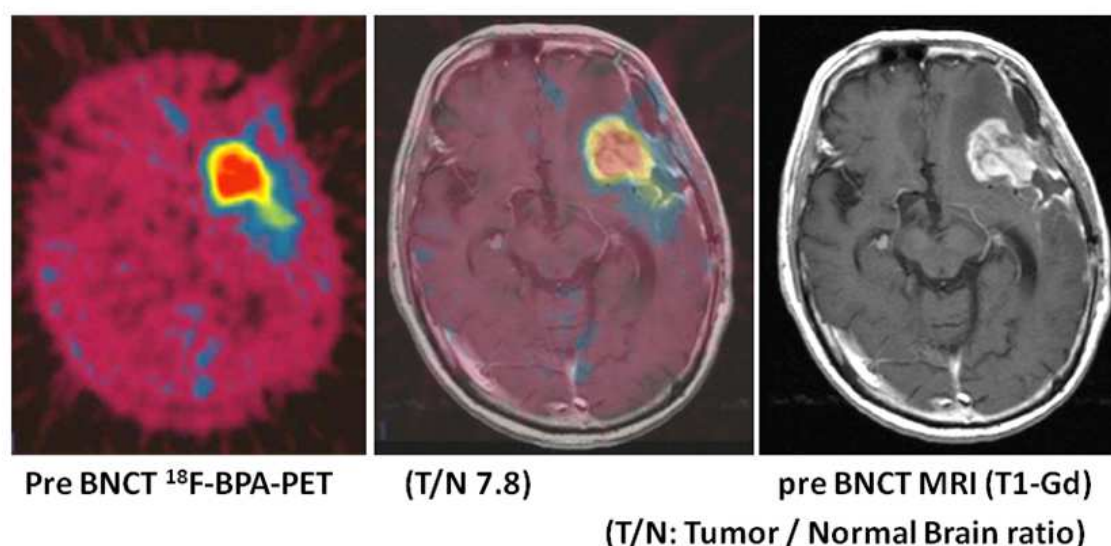


Fig. 2. ^{18}F labeled BPA positron emission tomography (^{18}F - BPA PET) has been applied for the estimation of the boron compound accumulation prior to BNCT. The tracer is fluoride labelled boron compound. This PET ensures the effectiveness of BNCT. ^{18}F -BPA accumulates well and distributes precisely in the tumor lesion and the infiltrating tumor zone.

Twelve hours before the neutron irradiation, the patients were administered 100mg/kg of BSH intravenously for one hour. 700mg/kg of BPA was infused continuously to the patients for 6 hours before the irradiation, and they were positioned for neutron irradiation in the reactor (KURRI or JRR-4 (Japan Atomic Energy Agency Research Reactor 4)). Just after termination of continuous BPA infusion for 6hrs, neutrons were irradiated. We used the dose-planning workstation to calculate the radiation dose for tumors from the ^{18}F -BPA-PET data and blood ^{10}B concentrations obtained every 2 hours after BSH administration. We used an epithermal neutron beam. Following this, a 2 Gy daily fraction of XRT was applied, for a total of 20 to 30Gy. The total dose of XRT was decided based on the BNCT dose for the normal brain. In Protocol 1, we aimed to apply more than 30 gray-equivalent (Gy-Eq) for gross tumor volume (GTV) and less than 12 Gy-Eq for normal brain, as BNCT. In Protocol 2, we aimed to apply more than 40 Gy-Eq for GTV and less than 15 Gy-Eq for normal brain. No chemotherapy was applied for any of the patients until the tumor progression was confirmed histologically or by ^{18}F -BPA-PET (Miyashita *et al.* 2008).

Survival time from histologically diagnosed as GB was compared with the survival time for the institutional historical controls who were treated by surgical removal followed by XRT and chemotherapy (mainly nitrosourea) from 1990 to 2006 in OMC. In this historical control

group, all cases were operated on to aim for the maximum tumor removal, the same as for the cases of the BNCT group. These Kaplan–Meier curves were calculated and the Log-rank test was used for statistical analysis. For the 21 patients who received BNCT, survival time was also compared with the corresponding recursive partitioning analysis (RPA) subclasses by the Radiation Therapy Oncology Group (RTOG) (Curran *et al.* 1993), as the international historical control, and European Organisation for Research and Treatment of Cancer - National Cancer Institute of Canada (EORTC-NCIC) trial (Stupp *et al.* 2009).

2.1.2 Results from our past study

Patients treated with BNCT (n=21) had a median ST of 15.6 months (95% confidence interval (CI): 12.2-23.9) after diagnosis (Fig. 3). Here the date of diagnosis is the initial debulking surgery date. This was significantly longer than the median survival time (MST) for the historical controls at our institute who were treated with surgical removal followed by XRT and chemotherapy (n=27, MST was 10.3 months (95% CI: 7.4-13.2), log-rank test $p = 0.0035$). The survival time from the date of diagnosis was calculated using the Kaplan-Meier method. The MST of the protocol 2 was 23.5 months (95% CI: 10.2 - undetermined) after diagnosis (n=11), and that of the protocol 1 patients (n=10) was 14.1 months (95% CI: 9.9-18.5), although the difference was not statistically significant (Fig. 4).

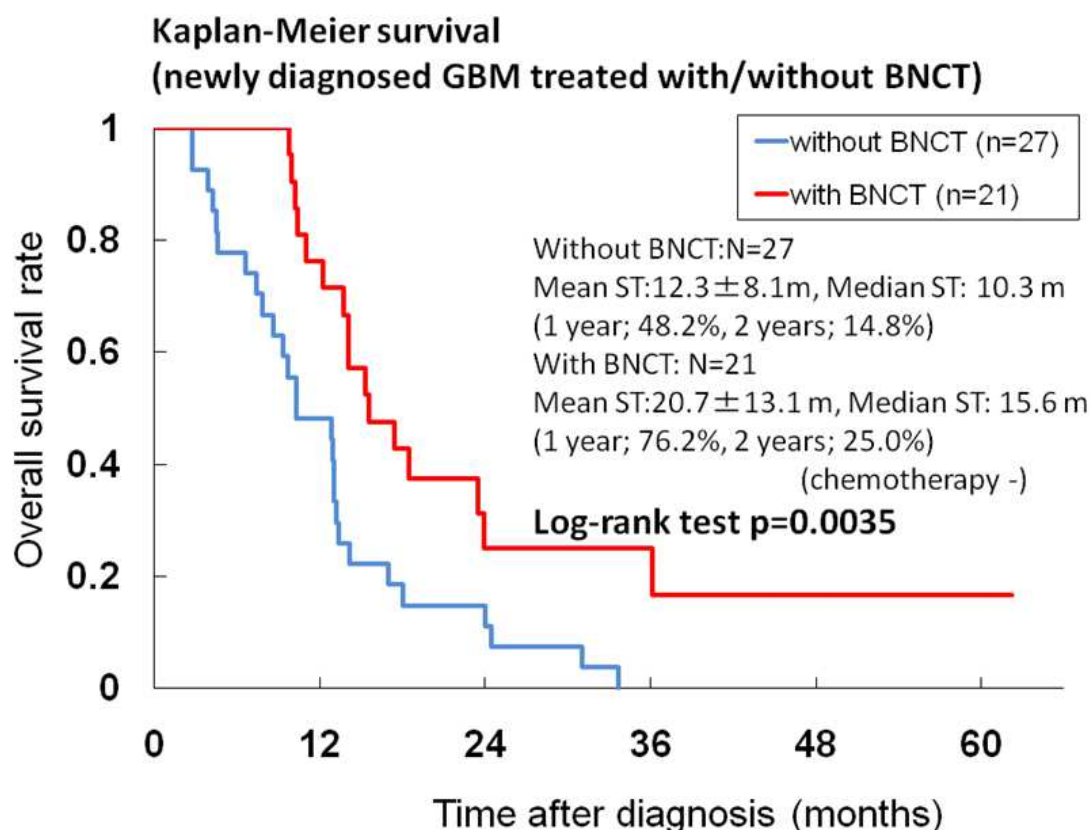


Fig. 3. Cumulative survival data for all newly diagnosed glioblastoma (WHO grade 4, n=21). Blue line is our recent historical control treated by external beam X-ray irradiation. The median survival time (ST) of boron neutron capture therapy (BNCT) group (red line) is 15.6 months. There is statistical significance between both group in Log-rank test ($p=0.0035$).

The RPA class distribution of 21 patients treated with BNCT at the initial diagnosis was as follows: Class III = 6 (29%); Class IV = 6 (29%); Class V = 8 (38%); Class VI = 1 (5%). The MSTs of the patients in classes III, IV, V, and VI were 23.5, 16.9, 13.2, and 9.8 months, respectively (Table 1). In historical control, the RPA class distribution was as follows: Class III = 3 (11%); Class IV = 14 (52%); Class V = 8 (30%); Class VI = 2 (7%). The distributions of each RPA class in BNCT group and institutional historical control group are a little bit different. We compare the survival of both groups in low risk RPA (class III and IV) and in high risk RPA (class V and IV) separately. The MST of BNCT group in low risk group was 18.5 months (n=12, 95% CI: 13.7-36.1) and that of historical control was 13.0 months (n=17, 95% CI: 8.6-18.0). There is statistical significance in log-rank test (p=0.028). The MST of BNCT group in high risk group was 12.2 months (n=9, 95% CI: 9.8-undetermined) and that of historical control was 7.4 months (n=10, 95% CI: 2.7-10.3). There is also statistical significance in log-rank test (p=0.0083). Therefore, it can be concluded that BNCT group shows the long survival in comparison with historical control not mainly by the difference of distribution of each RPA class in both groups. Our BNCT results for survival among the newly-diagnosed GB cases were favorable in comparison with those obtained from the corresponding RTOG - RPA subclasses.

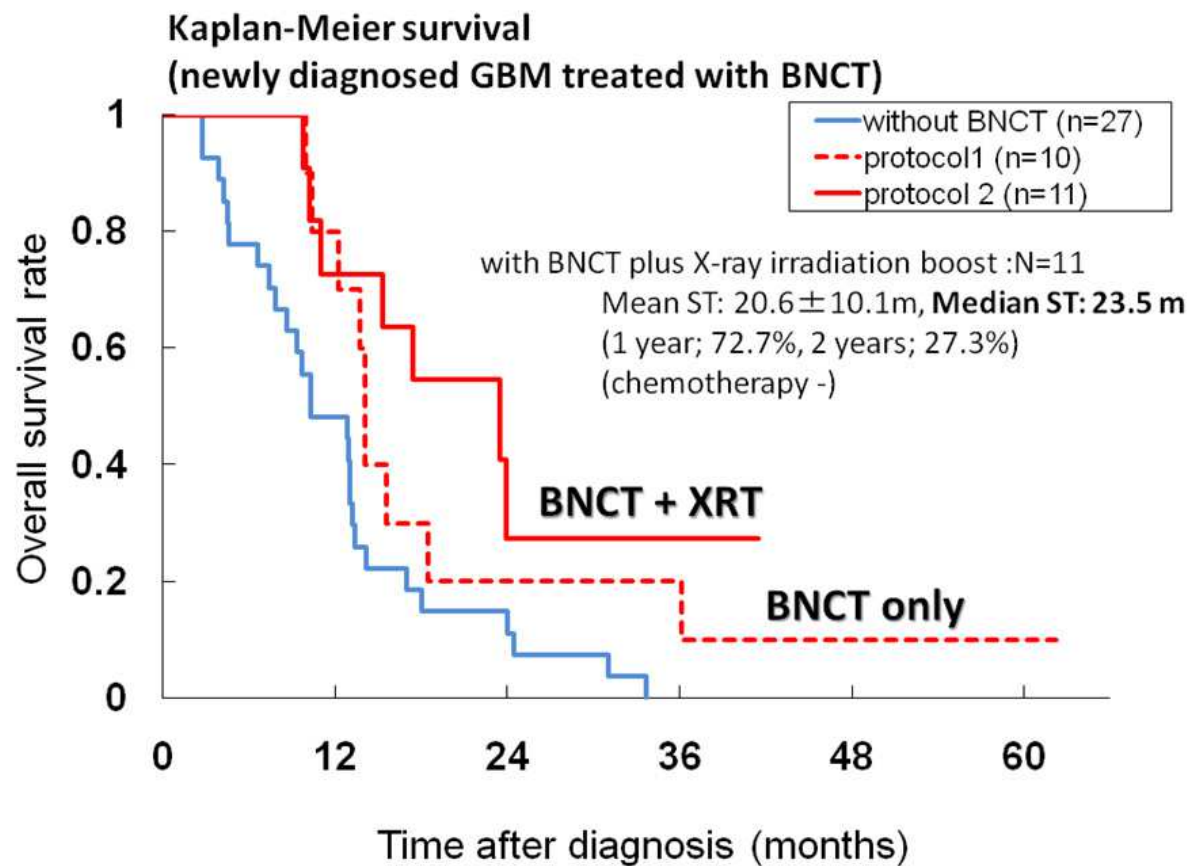


Fig. 4. Cumulative survival data for all newly diagnosed glioblastoma (protocol 1 and 2). External beam X-ray irradiation boost after boron neutron capture therapy (BNCT) (protocol 2, red line) was indicated for later 11 cases. This improve the median survival time as 23.5 months (vs 14.1 months for BNCT only (protocol 1, dotted red line)).

RTOG RPA class	RTOG original	EORTC-NCIC (XRT/TMZ)		BNCT	
	XRT	XRT	TMZ/XRT	XRT	BNCT
III	17.9	14.8	18.7	13.4	23.5
IV	11.1	13.3	16.3	12.8	16.9
V	8.9	9.1	10.7	7.4	13.2
VI	4.6	Not reported		3.6	9.8

*Median survival time (months). RTOG: radiation therapy oncology group, EORTC: european organisation for research and treatment of cancer, NCIC: National Cancer Institute of Canada Clinical Trials, RPA: recursive partitioning analysis, XRT: X-ray radiation therapy, TMZ: Temozolomide, BNCT: boron neutron capture therapy.

Table 1. Comparison of survival data among RPA class in the RTOG database, EORTC-NCIC (XRT/TMZ) trial, and in our cases treated with BNCT.

2.2 Representative case treated by modified boron neutron capture therapy combination with fractionated X-ray irradiation

A 63-year old female had a left parietal tumor removed partially in a hospital in November 2004. The histopathological diagnosis was GB. She was introduced to our hospital for BNCT for the remaining lesion. While she waited for the BNCT, rapid growth of the tumor caused aggravations of right hemiparesis, total aphasia and consciousness disturbance, all of which caused us to remove the tumor again in our hospital prior to BNCT. The tumor was gross totally removed, and the patient received BNCT with air instillation in tumor removed cavity, followed by XRT. At the time of BNCT, the workstation calculates two different estimated doses, one is for the tumor and the other is for the normal brain (Fig. 5). Dose calculation shows estimated gray-equivalent (Gy-Eq) isodose lines from BNCT. This is mainly based on the decay of the irradiated neutron, boron concentration and biological effectiveness of each tissue. The deepest part of the tumor was 7.5 cm from the scalp in this case. The irradiated minimum tumor dose by BNCT was improved by the air-instillation (star in the Fig. 5) methods from 18.9 Gy-Eq (without air) to 26.9 Gy-Eq (with air). The maximum irradiated point of the normal brain was 2 cm from the scalp and was 12.7 Gy-Eq and scalp surface was 9.0 Gy-Eq. An additional 20 Gy was applied by XRT (daily fraction of 2 Gy x 10 days) aimed for the deep part of the mass but included surface of the tumor and the normal brain. No tumor recurrence on MRI and no neurological deficit were seen for 13 months after BNCT (Fig. 6). BNCT followed by fractionated XRT could control the tumor for 12 months (Fig. 6B). However, 14 months after BNCT, the patient suffered from right hemiparesis and MRI revealed a Gd-enhanced lesion from the surface area of the tumor removed cavity which was irradiated by BNCT with enough dose and also included into the boost XRT (Fig. 6C). Radiation necrosis was suspected as the pathological condition based on L/N ratio in BPA-PET, but we could not neglect the possibility of a recurrence of the GB. We performed a re-craniotomy to remove this lesion. The pathological diagnosis was radiation necrosis; no apparent tumor cells were found by pathologists. After the surgery, the right hemiparesis was improved, while no tumor progression was observed on MRI in the follow-up for more than 5 years (Fig. 6D). The patient received best medical treatment (anti-coagulants and vitamin E) for a year to prevent a further radiation necrosis.

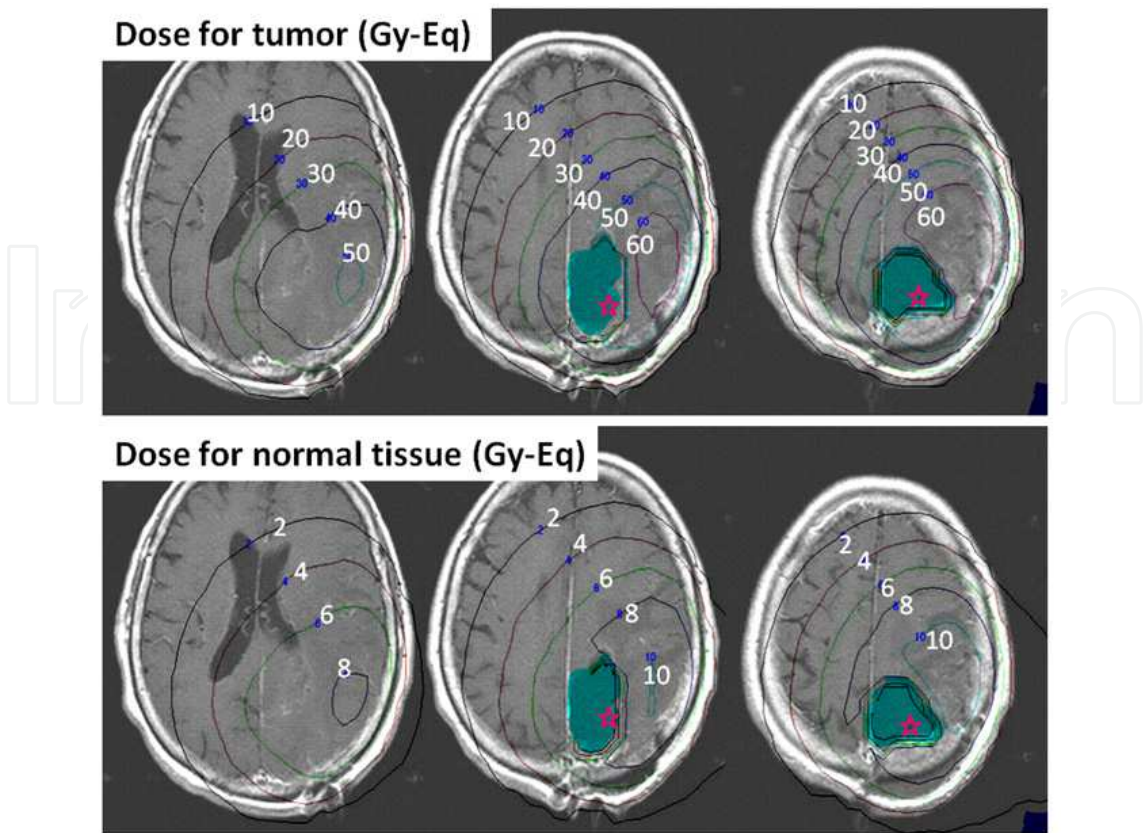


Fig. 5. Dose planning of neutron capture therapy for the tumor (upper) and for the normal brain (lower). (Gy-Eq: gray equivalent, star: air instillation to the tumor removed cavity)

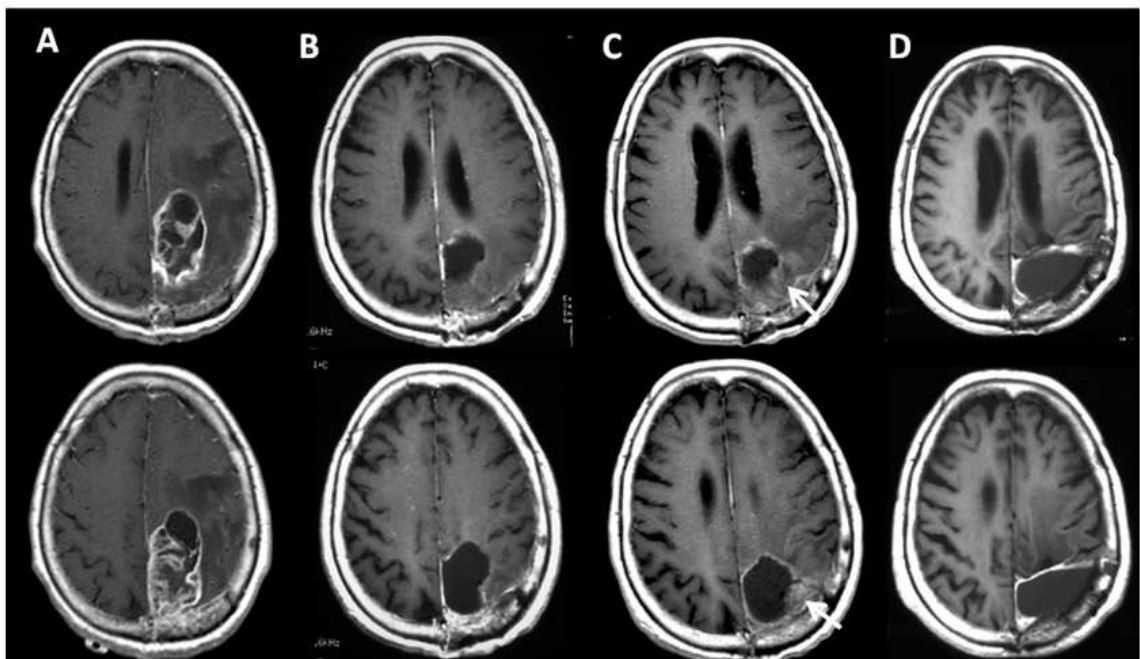


Fig. 6. Serial MRI images (T1-weighted with Gd enhancement) of the patient treated by boron neutron capture therapy combined with fractionated external beam X-ray irradiation. (A: prior to surgical removal and BNCT, B: 12 months, C: 14 months and D: 5 years after BNCT).

2.3 Phase II clinical study of boron neutron capture therapy combined with X-ray radiotherapy / Temozolomide in patients with newly diagnosed glioblastoma multiforme

Results of our clinical study showed the efficacy of combination therapy with external beam XRT and BNCT. For our future study, we planned the Multi-centric Phase II clinical study named “*Boron Neutron Capture Therapy, Radiation Therapy, and Temozolomide in Treating Patients with Newly Diagnosed Glioblastoma Multiforme*” in Japan (OSAKA-TRIBRAIN0902, NCT00974987). The major differences of our protocol from the other past BNCT studies were simultaneous use of both BSH and BPA, and combination with XRT.

2.3.1 Back ground of our recently up-dated protocol using BNCT

Prior to design of new version of the protocol for multi-centric study, we analyzed our previous clinical results of all the patients with malignant glioma treated by BNCT. Main part of the retrospective analysis was as follows. 1. Efficacy of additional fractionated X-ray irradiation, 2. Administration of the boron compounds, 3. Toxicity of our previous study. The median ST of the patients treated with BNCT followed by XRT boost was 23.5 months (95% CI: 10.2 – undetermined, HR (*vs* control) = 0.32) after diagnosis (n = 11), and that of the patients treated with BNCT only (n = 10) was 14.1 months (95% CI: 9.9–18.5), although the difference was not statistically significant among these two groups.

In our previous study for all of the patients with malignant brain tumor included several doses of boron compounds especially for BPA, 250, 500, 700mg/kg body weight. Blood boron concentration was increased by escalation of the BPA dose. The continuous infusion with reduced BPA dose during irradiation (400mg/kg for 2h + 100mg/kg for 1h, previously used for head and neck cancer in KURRI) was also used and this was useful for dose estimation of BNCT because the blood boron concentration similar as 700mg BPA/kg was kept during irradiation whereas a decline of the blood level was remarkable when we terminated BPA just before neutron irradiation. Adverse events were assessed by common terminology criteria for adverse events (CTCAE) v3.0. Grade 3/4 blood/bone marrow toxicity (hemoglobin, leukocytes, neutrophils, and platelets) were 11% in 250mg/kg, 17% in 500mg/kg, and 28% in 700mg/kg. Other Grade 3/4 adverse events (seizure, AST, ALT, amylase, creatinine) were 64% in 250mg/kg, 25% in 500mg/kg, and 73% in 700mg/kg. All of these adverse events were reversible and transient. Radiation induced edema and/or necrosis occurred mainly in the area that was available for high-dose irradiation by BNCT nearly the surface of the brain of the patients treated with BNCT+XRT. Based on this retrospective analysis, the Multi-centric Phase II clinical study was planned and now on-going.

2.3.2 On-going protocol using BNCT for the newly diagnosed glioblastoma

Based on our former BNCT clinical experience, we included the following points in a new protocol using the two boron compounds, BSH and BPA, in combination (Ono et al. 1999, Yokoyama et al. 2006). The schedule of the administration of boron compounds is settled as follows; 13 hours before the neutron irradiation, 100 mg/kg of BSH will be intravenously infused for one hour, and 500 mg/kg of BPA will be infused continuously 200 mg/kg/h for 2 hours before the irradiation and reduced for 100 mg/kg/h during irradiation to the patients. During continuous BPA infusion of reduced dose as 100 mg/kg, neutrons irradiation is performed. Protocol treatments consist of BNCT, additional 24Gy XRT and

chemotherapy with TMZ. Prescription dose by BNCT is regulated as not to be more than 13Gy-Eq for normal brain. Additional XRT is given with 3 gradient such as 8, 16, 24Gy from the surface of scalp to the bottom of tumor infiltrated zone (Fig. 7). Chemotherapy with TMZ is applied concomitantly during XRT treatments and adjuvant chemotherapy with the same agent is repeated in outpatient clinic (Fig. 8) (Stupp *et al.* 2005).

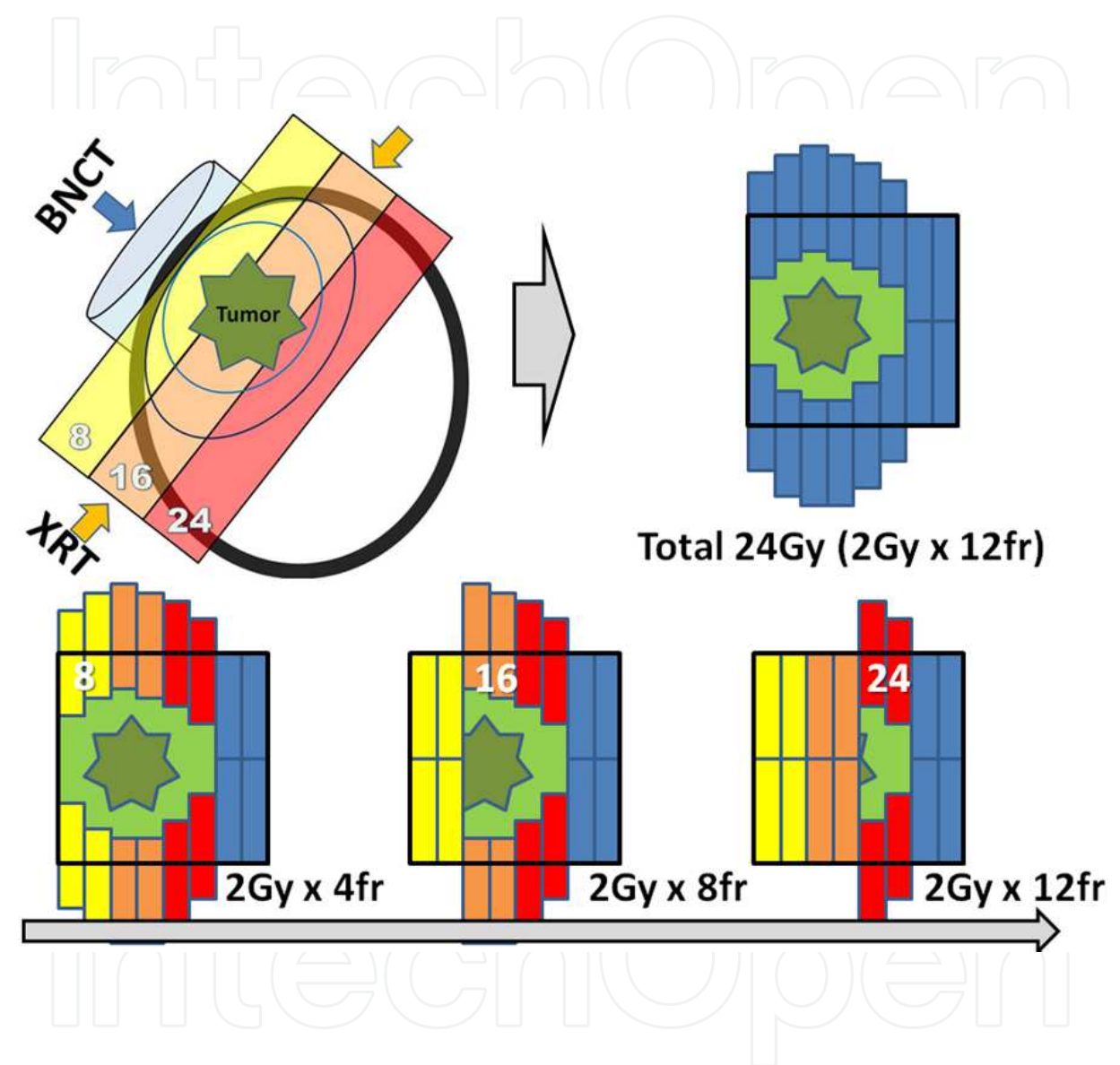


Fig. 7. Illustrated image of the protocol combined with boron neutron capture therapy (BNCT) and 3 gradient fractionated X-ray irradiation (XRT). Gy: gray, fr: fraction.

Based on our previous clinical study, the Hazard ratio of BNCT vs. XRT was simulated as 0.4, so the total estimated number of the patients who should be included in our new study become 45 totally. Primary end point is overall survival and these patients will be followed up for 2 years after the last patient treatment. The most important point in our protocol is diagnosis and treatment of radiation effects such as swelling, radiation induced edema, transient expansion of the tumor, pseudo- progression / response, and radiation necrosis. ¹⁸F-BPA-PET study is included for the diagnosis of these pathologies.

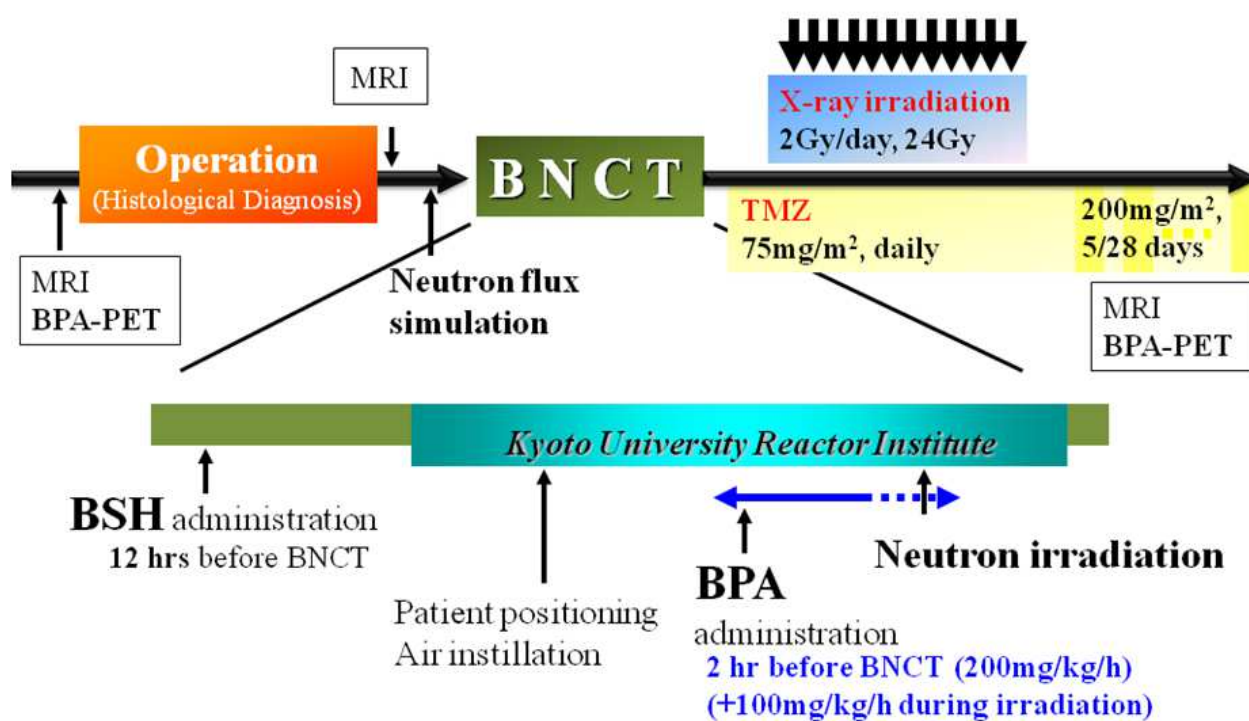


Fig. 8. Treatment protocol of BNCT combination with EBRT/TMZ for Newly diagnosed Malignant Glioma

3. Conclusion

Glioblastoma is currently not curable and the prognosis of it is very poor. A world-wide standard care of newly-diagnosed GB is postoperative XRT with concomitant and adjuvant chemotherapy with new alkylating agent TMZ (Stupp et al. 2005). This standard treatment for newly diagnosed GB prolonged the median ST of patients from 12.1 months to 14.6 months in comparison with XRT alone, which is still pessimistic clinical result of this disease. Therefore an alternative promising treatment should be developed for the improvement of the prognosis of newly diagnosed GB. Several recent clinical studies on the treatment of patients with GB by means of BNCT have reported encouraging results. Careful analysis of survival data from a study, carried out in Sweden (Skold *et al.*) in which BPA was administered at a higher dose over a longer period of time (Skold *et al.*), suggested that a subset of patients had survival times that were at least as good as those obtained with conventional therapy consisting of X-irradiation in combination with TMZ (Stupp et al. 2005).

On the other hand, BNCT is tumor-selective particle radiation. Tumor-seeking boron compounds boronophenylalanine (BPA) and sodium borocapate (BSH) can be delivered selectively in GB tissue with high contrast of accumulation in comparison with normal brain tissue. This tumor selective accumulation of boron compounds is followed by neutron irradiation, which produced high linear energy transfer particles (alpha particle and re-coiled Li nucleus). Thereafter these particles can destroy tumor cells selectively with high efficiency (Barth et al. 2005). The principal investigator of this clinical trial published the excellent survival data of 21 cases of newly diagnosed GB treated by BNCT with the MST of

15.6 months without TMZ. Moreover additional 20 to 30Gy XRT prolonged the MST up to 23.5 months in 11 cases without TMZ (Kawabata *et al.* 2009b). These strategies were also confirmed by pre-clinical bench works (Barth *et al.* 2004). These are the background of our on-going clinical trial. Thereafter in this trial, the protocol is composed of BNCT, followed by 24Gy XRT with concomitant and adjuvant chemotherapy with TMZ for newly diagnosed GB patients.

4. Acknowledgment

This project was supported by the grant-in-aid for Scientific Research from the Ministry of Health, Labor and Welfare of Japan to S-I. Miyatake. This work was also supported in part by the Takeda Science Foundation for S. Kawabata (PI; H. Matsui, Okayama University).

This work was also partly supported by Scientific Research from the Japanese Ministry of Education, Science, and Culture to S. Kawabata, M. Furuse (Scientific Research C), and Y. Matsushita (Grant-in-Aid for Young Scientist B).

This project was approved by the Ethical Committee of Osaka Medical College and by the BNCT Committee of Kyoto University Research Reactor Institute or Japan Atomic Energy Agency. Individual cases were discussed and selected by the latter committee and the signing of the informed consent by each patient.

5. References


- Ariyoshi, Y., Miyatake, S., Kimura, Y., Shimahara, T., Kawabata, S., Nagata, K., Suzuki, M., Maruhashi, A., Ono, K. & Shimahara, M. (2007). Boron neutron capture therapy using epithermal neutrons for recurrent cancer in the oral cavity and cervical lymph node metastasis. *Oncol Rep*, Vol. 18, No. 4 pp. (861-866), ISSN. 1021-335X
- Barth, R. F., Coderre, J. A., Vicente, M. G. & Blue, T. E. (2005). Boron neutron capture therapy of cancer: current status and future prospects. *Clin Cancer Res*, Vol. 11, No. 11 pp. (3987-4002), ISSN. 1078-0432
- Barth, R. F., Grecula, J. C., Yang, W., Rotaru, J. H., Nawrocky, M., Gupta, N., Albertson, B. J., Ferketich, A. K., Moeschberger, M. L., Coderre, J. A. & Rofstad, E. K. (2004). Combination of boron neutron capture therapy and external beam radiotherapy for brain tumors. *Int J Radiat Oncol Biol Phys*, Vol. 58, No. 1 pp. (267-277), ISSN. 0360-3016
- Curran, W. J., Jr., Scott, C. B., Horton, J., Nelson, J. S., Weinstein, A. S., Fischbach, A. J., Chang, C. H., Rotman, M., Asbell, S. O., Krisch, R. E. & et al. (1993). Recursive partitioning analysis of prognostic factors in three Radiation Therapy Oncology Group malignant glioma trials. *J Natl Cancer Inst*, Vol. 85, No. 9 pp. (704-710), ISSN. 0027-8874
- Haginomori, S., Miyatake, S., Inui, T., Araki, M., Kawabata, S., Takamaki, A., Lee, K., Takenaka, H., Kuroiwa, T., Uesugi, Y., Kumada, H. & Ono, K. (2009). Planned fractionated boron neutron capture therapy using epithermal neutrons for a patient with recurrent squamous cell carcinoma in the temporal bone: a case report. *Head Neck*, Vol. 31, No. 3 pp. (412-418), ISSN. 1097-0347 (Electronic), 1043-3074 (Linking)
- Hiramatsu, R., Kawabata, S., Miyatake, S., Kuroiwa, T., Easson, M. W. & Vicente, M. G. (2011). Application of a novel boronated porphyrin (HOCP) as a dual sensitizer for

- both PDT and BNCT. *Lasers Surg Med*, Vol. 43, No. 1 pp. (52-58), ISSN. 1096-9101 (Electronic), 0196-8092 (Linking)
- Imahori, Y., Ueda, S., Ohmori, Y., Sakae, K., Kusuki, T., Kobayashi, T., Takagaki, M., Ono, K., Ido, T. & Fujii, R. (1998). Positron emission tomography-based boron neutron capture therapy using boronophenylalanine for high-grade gliomas: part II. *Clin Cancer Res*, Vol. 4, No. 8 pp. (1833-1841), ISSN. 1078-0432
- Kawabata, S., Miyatake, S., Kajimoto, Y., Kuroda, Y., Kuroiwa, T., Imahori, Y., Kirihata, M., Sakurai, Y., Kobayashi, T. & Ono, K. (2003). The early successful treatment of glioblastoma patients with modified boron neutron capture therapy. Report of two cases. *J Neurooncol*, Vol. 65, No. 2 pp. (159-165), ISSN. 0167-594X
- Kawabata, S., Miyatake, S., Kuroiwa, T., Yokoyama, K., Doi, A., Iida, K., Miyata, S., Nonoguchi, N., Michiue, H., Takahashi, M., Inomata, T., Imahori, Y., Kirihata, M., Sakurai, Y., Maruhashi, A., Kumada, H. & Ono, K. (2009a). Boron neutron capture therapy for newly diagnosed glioblastoma. *J Radiat Res (Tokyo)*, Vol. 50, No. 1 pp. (51-60), ISSN. 0449-3060
- Kawabata, S., Miyatake, S., Nonoguchi, N., Hiramatsu, R., Iida, K., Miyata, S., Yokoyama, K., Doi, A., Kuroda, Y., Kuroiwa, T., Michiue, H., Kumada, H., Kirihata, M., Imahori, Y., Maruhashi, A., Sakurai, Y., Suzuki, M., Masunaga, S. & Ono, K. (2009b). Survival benefit from boron neutron capture therapy for the newly diagnosed glioblastoma patients. *Appl Radiat Isot*, Vol. 67, No. 7-8 Suppl pp. (S15-18), ISSN. 1872-9800 (Electronic), 0969-8043 (Linking)
- Kimura, Y., Ariyoshi, Y., Miyatake, S., Shimahara, M., Kawabata, S. & Ono, K. (2009). Boron neutron capture therapy for papillary cystadenocarcinoma in the upper lip: a case report. *Int J Oral Maxillofac Surg*, Vol. 38, No. 3 pp. (293-295), ISSN. 1399-0020 (Electronic), 901-5027 (Linking)
- Miyashita, M., Miyatake, S., Imahori, Y., Yokoyama, K., Kawabata, S., Kajimoto, Y., Shibata, M. A., Otsuki, Y., Kirihata, M., Ono, K. & Kuroiwa, T. (2008). Evaluation of fluoride-labeled boronophenylalanine-PET imaging for the study of radiation effects in patients with glioblastomas. *J Neurooncol*, Vol. 89, No. 2 pp. (239-246), ISSN. 0167-594X
- Miyata, S., Kawabata, S., Hiramatsu, R., Doi, A., Ikeda, N., Yamashita, T., Kuroiwa, T., Kasaoka, S., Maruyama, K. & Miyatake, S. I. (2011). CT imaging of transferrin targeting liposomes encapsulating both boron and iodine contrast agent by CED to F98 rat glioma for boron neutron capture therapy. *Neurosurgery*, Vol., No., ISSN. 1524-4040 (Electronic), 0148-396X (Linking)
- Miyatake, S., Kawabata, S., Kajimoto, Y., Aoki, A., Yokoyama, K., Yamada, M., Kuroiwa, T., Tsuji, M., Imahori, Y., Kirihata, M., Sakurai, Y., Masunaga, S., Nagata, K., Maruhashi, A. & Ono, K. (2005). Modified boron neutron capture therapy for malignant gliomas performed using epithermal neutron and two boron compounds with different accumulation mechanisms: an efficacy study based on findings on neuroimages. *J Neurosurg*, Vol. 103, No. 6 pp. (1000-1009), ISSN. 0022-3085
- Miyatake, S., Kawabata, S., Yokoyama, K., Kuroiwa, T., Michiue, H., Sakurai, Y., Kumada, H., Suzuki, M., Maruhashi, A., Kirihata, M. & Ono, K. (2009). Survival benefit of

- Boron neutron capture therapy for recurrent malignant gliomas. *J Neurooncol*, Vol. 91, No. 2 pp. (199-206), ISSN. 0167-594X
- Ono, K. (2006). central shielding. In Y. Nakagawa, T. Kobayashi & H. Fukuda (Eds.), *Advances in Neutron Capture Therapy 2006: "From the past to the future", Proceedings of 12th International Congress on Neutron Capture Therapy*. Kagawa, Japan.
- Ono, K., Masunaga, S., Suzuki, M., Kinashi, Y., Takagaki, M. & Akaboshi, M. (1999). The combined effect of boronophenylalanine and borocaptate in boron neutron capture therapy for SCCVII tumors in mice. *Int J Radiat Oncol Biol Phys*, Vol. 43, No. 2 pp. (431-436), ISSN. 0360-3016
- Ono, K., Sakurai, Y., Masunaga, S., Kinashi, Y., Takagaki, M. & Kobayashi, T. (2000). Improvement of B-10 dose distribution in water phantom irradiated with epithermal neutron beam and its assessment by colonyformation assay. *Program & Abstracts of the Ninth International Symposium on Neutron Capture Therapy for Cancer (Kyoto University Research Reactor Institute)*. Kyoto University Research Reactor Institute: Osaka, Japan.
- Sakurai, Y., Ono, K., Miyatake, S. & Maruhashi, A. (2006). Improvement effect on the depth-dose distribution by CSF drainage and air infusion of a tumour-removed cavity in boron neutron capture therapy for malignant brain tumours. *Phys Med Biol*, Vol. 51, No. 5 pp. (1173-1183), ISSN. 0031-9155
- Skold, K., B, H. S., Diaz, A. Z., Giusti, V., Pellettieri, L. & Hopewell, J. W. (2010a). Boron Neutron Capture Therapy for glioblastoma multiforme: advantage of prolonged infusion of BPA-f. *Acta Neurol Scand*, Vol. 122, No. 1 pp. (58-62), ISSN. 1600-0404 (Electronic), 0001-6314 (Linking)
- Skold, K., Gorlia, T., Pellettieri, L., Giusti, V., B, H. S. & Hopewell, J. W. (2010b). Boron neutron capture therapy for newly diagnosed glioblastoma multiforme: an assessment of clinical potential. *Br J Radiol*, Vol. 83, No. 991 pp. (596-603), ISSN. 1748-880X (Electronic), 0007-1285 (Linking)
- Stupp, R., Hegi, M. E., Mason, W. P., van den Bent, M. J., Taphoorn, M. J., Janzer, R. C., Ludwin, S. K., Allgeier, A., Fisher, B., Belanger, K., Hau, P., Brandes, A. A., Gijtenbeek, J., Marosi, C., Vecht, C. J., Mokhtari, K., Wesseling, P., Villa, S., Eisenhauer, E., Gorlia, T., Weller, M., Lacombe, D., Cairncross, J. G. & Mirimanoff, R. O. (2009). Effects of radiotherapy with concomitant and adjuvant temozolomide versus radiotherapy alone on survival in glioblastoma in a randomised phase III study: 5-year analysis of the EORTC-NCIC trial. *Lancet Oncol*, Vol. 10, No. 5 pp. (459-466), ISSN. 1474-5488 (Electronic), 1470-2045 (Linking)
- Stupp, R., Mason, W. P., van den Bent, M. J., Weller, M., Fisher, B., Taphoorn, M. J., Belanger, K., Brandes, A. A., Marosi, C., Bogdahn, U., Curschmann, J., Janzer, R. C., Ludwin, S. K., Gorlia, T., Allgeier, A., Lacombe, D., Cairncross, J. G., Eisenhauer, E. & Mirimanoff, R. O. (2005). Radiotherapy plus concomitant and adjuvant temozolomide for glioblastoma. *N Engl J Med*, Vol. 352, No. 10 pp. (987-996), ISSN. 1533-4406 (Electronic), 0028-4793 (Linking)
- Wu, G., Yang, W., Barth, R. F., Kawabata, S., Swindall, M., Bandyopadhyaya, A. K., Tjarks, W., Khorsandi, B., Blue, T. E., Ferketich, A. K., Yang, M., Christoforidis, G. A., Sferra, T. J., Binns, P. J., Riley, K. J., Ciesielski, M. J. & Fenstermaker, R. A. (2007).

- Molecular targeting and treatment of an epidermal growth factor receptor-positive glioma using boronated cetuximab. *Clin Cancer Res*, Vol. 13, No. 4 pp. (1260-1268), ISSN. 1078-0432
- Yang, W., Barth, R. F., Wu, G., Kawabata, S., Sferra, T. J., Bandyopadhyaya, A. K., Tjarks, W., Ferketich, A. K., Moeschberger, M. L., Binns, P. J., Riley, K. J., Coderre, J. A., Ciesielski, M. J., Fenstermaker, R. A. & Wikstrand, C. J. (2006). Molecular targeting and treatment of EGFRvIII-positive gliomas using boronated monoclonal antibody L8A4. *Clin Cancer Res*, Vol. 12, No. 12 pp. (3792-3802), ISSN. 1078-0432
- Yokoyama, K., Miyatake, S., Kajimoto, Y., Kawabata, S., Doi, A., Yoshida, T., Asano, T., Kirihata, M., Ono, K. & Kuroiwa, T. (2006). Pharmacokinetic study of BSH and BPA in simultaneous use for BNCT. *J Neurooncol*, Vol. 78, No. 3 pp. (227-232), ISSN. 0167-594X

IntechOpen



Advances in the Biology, Imaging and Therapies for Glioblastoma

Edited by Prof. Clark Chen

ISBN 978-953-307-284-5

Hard cover, 424 pages

Publisher InTech

Published online 09, November, 2011

Published in print edition November, 2011

This book is intended for physicians and scientists with interest in glioblastoma biology, imaging and therapy. Select topics in DNA repair are presented here to demonstrate novel paradigms as they relate to therapeutic strategies. The book should serve as a supplementary text in courses and seminars as well as a general reference.

How to reference

In order to correctly reference this scholarly work, feel free to copy and paste the following:

Shinji Kawabata, Yoko Matsushita, Motomasa Furuse, Shin-Ichi Miyatake, Toshihiko Kuroiwa and Koji Ono (2011). Clinical Study on Modified Boron Neutron Capture Therapy for Newly Diagnosed Glioblastoma, Advances in the Biology, Imaging and Therapies for Glioblastoma, Prof. Clark Chen (Ed.), ISBN: 978-953-307-284-5, InTech, Available from: <http://www.intechopen.com/books/advances-in-the-biology-imaging-and-therapies-for-glioblastoma/clinical-study-on-modified-boron-neutron-capture-therapy-for-newly-diagnosed-glioblastoma>

INTECH
open science | open minds

InTech Europe

University Campus STeP Ri
Slavka Krautzeka 83/A
51000 Rijeka, Croatia
Phone: +385 (51) 770 447
Fax: +385 (51) 686 166
www.intechopen.com

InTech China

Unit 405, Office Block, Hotel Equatorial Shanghai
No.65, Yan An Road (West), Shanghai, 200040, China
中国上海市延安西路65号上海国际贵都大饭店办公楼405单元
Phone: +86-21-62489820
Fax: +86-21-62489821

© 2011 The Author(s). Licensee IntechOpen. This is an open access article distributed under the terms of the [Creative Commons Attribution 3.0 License](https://creativecommons.org/licenses/by/3.0/), which permits unrestricted use, distribution, and reproduction in any medium, provided the original work is properly cited.

IntechOpen

IntechOpen