

We are IntechOpen, the world's leading publisher of Open Access books Built by scientists, for scientists

6,900

Open access books available

186,000

International authors and editors

200M

Downloads

Our authors are among the

154

Countries delivered to

TOP 1%

most cited scientists

12.2%

Contributors from top 500 universities



WEB OF SCIENCE™

Selection of our books indexed in the Book Citation Index
in Web of Science™ Core Collection (BKCI)

Interested in publishing with us?
Contact book.department@intechopen.com

Numbers displayed above are based on latest data collected.
For more information visit www.intechopen.com



Gray or White? – The Contribution of Gray Matter in a Glioma to Language Deficits

Ryuta Kinno^{1,2}, Yoshihiro Muragaki³ and Kuniyoshi L. Sakai²

¹*Division of Neurology, Department of Internal Medicine,
Showa University Northern Yokohama Hospital*

²*Department of Basic Science, Graduate School of Arts and Sciences,
The University of Tokyo*

³*Department of Neurosurgery, Tokyo Women's Medical University
Japan*

1. Introduction

Symptoms of a glioma include not only headaches and seizures, but cognitive deficits including aphasia. One of the most important regions for aphasia is the anterior speech area, the damage of which causes Broca's aphasia, marked by effortful, distorted articulation, reduced speech output, and agrammatic syntax. These patients show relatively good comprehension of single words and simple sentences, but show trouble understanding sentences with more complex syntactic structures, such as passive sentences and sentences with object relative clauses (Schwartz et al., 1980; Caplan et al., 1985; Grodzinsky, 2000); this aspect of Broca's aphasia is called agrammatic comprehension (Goodglass & Menn, 1985; Menn and Obler, 1990; Pulvermüller, 1995). However, methodological problems have been raised (Badecker & Caramazza, 1985), and general processes of short-term memory or decision-making have been proposed to be disrupted in agrammatic comprehension (Just & Carpenter, 1992; Cupples & Inglis, 1993; Dick et al., 2001). Thus, for appropriately assessing a cognitive deficit, it is crucial to use an experimental task in which general cognitive demands such as the memory load are strictly controlled.

In our recent functional magnetic resonance imaging (fMRI) study with a picture-sentence matching task, we examined the effect of sentence structures strictly controlling general cognitive demands such as the memory load (Kinno et al., 2008), where a sentence was visually presented with a picture representing an action (Fig. 1; the same task and stimuli were used in the present study). The participants indicated whether or not the meaning of each sentence matched the action depicted by the corresponding picture. There were three main conditions with different sentence types: canonical / subject-initial active sentences (AS) (e.g., “ Δ -ga \circ -o hiiteru”, “ Δ pulls \circ ”), noncanonical / subject-initial passive sentences (PS) (e.g., “ \circ -ga Δ -ni hikareru”, “ \circ is affected by Δ 's pulling it”; see Kinno et al. (2008) for ni direct passive form), and noncanonical / object-initial scrambled sentences (SS) (e.g., “ \circ -o Δ -ga hiireru”, “as for \square , \circ pulling it”; this form is allowed not only in Japanese but in German, Finnish, and other languages). Under these conditions, each sentence had a

transitive verb and two arguments (phrases associated with the predicate) with different grammatical relations, i.e., which the subject (S) of a verb (V) is, and which its indirect object (IO) or direct object (DO) is. Sentence comprehension under each condition also explicitly required analysis of two different thematic roles, i.e., who initiates the action, and who is affected by it. In Japanese syntax, the grammatical relations are first marked by case markers (nominative, dative, or accusative in the present stimuli; Fig. 1), which in turn allow the assignment of thematic roles (agent, experiencer, or patient), whereas passiveness is also marked in the verb morphology (-areru). More specifically, the AS, PS, and SS sentences correspond to S-DO-V (agent and patient), S-IO-V (experiencer and agent), and DO-S-V (patient and agent) types, respectively. Therefore, these syntactic analyses for the two-argument relationships were critically required in our paradigm. In the fMRI study, we observed that activations in L. dF3t (extending to L. F3op) and L. LPMC were differentially modulated by these three main conditions. Moreover, we have recently found that a glioma in the opercular and triangular parts of the left inferior frontal gyrus (L. F3op/F3t) or left lateral premotor cortex (L. LPMC) is indeed sufficient to cause agrammatic comprehension that is selective to syntactic decision (Kinno et al., 2009). These findings indicated that our paradigm with three distinct syntactic conditions of AS, PS, and SS would be ideal for appropriately assessing agrammatic comprehension, because the same set of actions depicted by pictures was used under the main conditions, thus controlling semantic comprehension per se. However, it remains to be elucidated whether a cognitive deficit such as agrammatic comprehension is due to the glioma in gray matter (GM) or not, as a glioma extends to both gray and white matter. It is typically supposed that a glioma in a gray matter causes dysfunction of the localized region, whereas a glioma in white matter leads to the disconnection of neural networks. Therefore, a lesion-symptom method, in which brain lesions are precisely divided into gray and white matter, is required to examine the relative contribution of gray matter in a glioma to cognitive deficits.

In this chapter, we firstly propose a modified lesion-symptom method for examining the effect of a GM lesion. Our method is based on the following two methods for processing the structural magnetic resonance imaging (MRI) data and the behavioural data of patients with a glioma: the voxel-based lesion-symptom mapping (VLSM) (Bates et al., 2003) and the “unified segmentation” algorithm (Ashburner & Friston, 2005). The VLSM is a method to analyze the relationship between a lesion location in the structural MRI and behavioural data such as the error rates (ERs) or reaction times (RTs) on a voxel-by-voxel basis. The unified segmentation algorithm is a generative model that combines tissue segmentation, bias correction and spatial normalization in a single unified model. Using our picture-sentence matching task (Fig. 1), we actually applied this new method to real data of patients with a glioma in the left frontal cortex. The tumor locations covered the most of the left frontal regions and thus included L. F3op/F3t and L. LPMC. To precisely localize the glioma, all patients underwent a high-resolution 3D-MRI on the same day as the task examination. All of these results were actually utilized for the preoperative evaluation of detailed language function and for planning a resection of glioma, thereby minimizing the risk of postoperative language deficits (Haglund, Ojemann, & Hochman, 1992). Because neurological data about the real roles of the left frontal regions in syntactic comprehension have been limited, our lesion-symptom method would have both fundamental and clinical implications, which are useful for preserving the quality of life (QOL) for each patient.

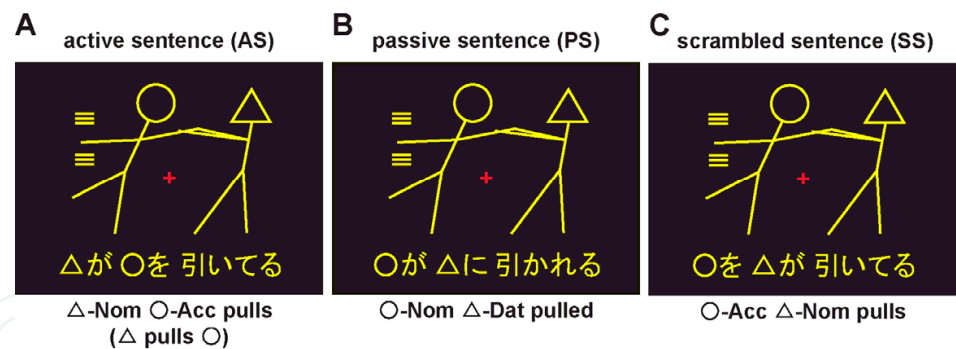


Fig. 1. The three main conditions used in the picture-sentence matching task.

2. Material and methods

2.1 Participants

All patients were native Japanese speakers newly diagnosed as having a glioma in the left frontal region, who were scheduled for surgery at the Department of Neurosurgery of Tokyo Women’s Medical University. The following conditions comprised the criteria for inclusion of patients in the present study: (i) right-handedness, (ii) no deficits in verbal / written communication or other cognitive abilities reported by the patients or physicians, (iii) no history of neurological or psychiatric disorders other than glioma and seizures, (iv) freedom from seizures with or without antiepileptic drug, and (v) no medical problems for MRI acquisition. Twenty-one patients (Fig. 2 and Table 1) preoperatively underwent a high-resolution MRI scan and performed the picture-sentence matching task at the University of Tokyo, Komaba. The laterality quotient (LQ) was also determined by the Edinburgh handedness inventory (Oldfield, 1971). The verbal / nonverbal intelligence quotient (IQ) was assessed with the Japanese version of the WAIS-III (1997, 2006; Harcourt Assessment, Inc., San Antonio, TX, USA), including more general and demanding tests than the aphasic tests. All but one patient underwent amytal testing. Following injection of amytal, the patient counted numbers with both hands raised. As soon as the contralateral hemiplegia occurred, a picture naming task was used to determine hemispheric dominance, which was either left or bilateral. The tumour type and grade were postoperatively and pathologically diagnosed by the WHO Classification of Tumours of the Nervous System (2000). Using the same paradigm and parameters, we also tested 21 right-handed participants with no history of neurological or psychiatric disorders. These age-matched normal controls included 12 males and 9 females (age: 20-58; mean: 37 years). Informed consent was obtained from each participant after the nature and possible consequences of the studies were explained. Approval for the experiments was obtained from the institutional review board of the University of Tokyo, Komaba.

Age	LQ	VIQ	non-VIQ	Tumor Volume	GM Ratio
34 ± 10	88 ± 16	98 ± 5.7	99 ± 6.5	44088 ± 21227	55 ± 3.0

Table 1. Characteristics of Patients

The patients in our previous study (Kinno et al., 2009), who were scanned with the same protocol of MRI in the present study, were all included. Date are shown as mean ± standard deviation MR images were normalized with SPM8 for determination of tumor location and

volume (mm^3), as well as the ratio (%) of gray matter (GM) for each tumor. LQ = laterality quotient VIQ = verbal intelligence quotient.

Lesion overlap map

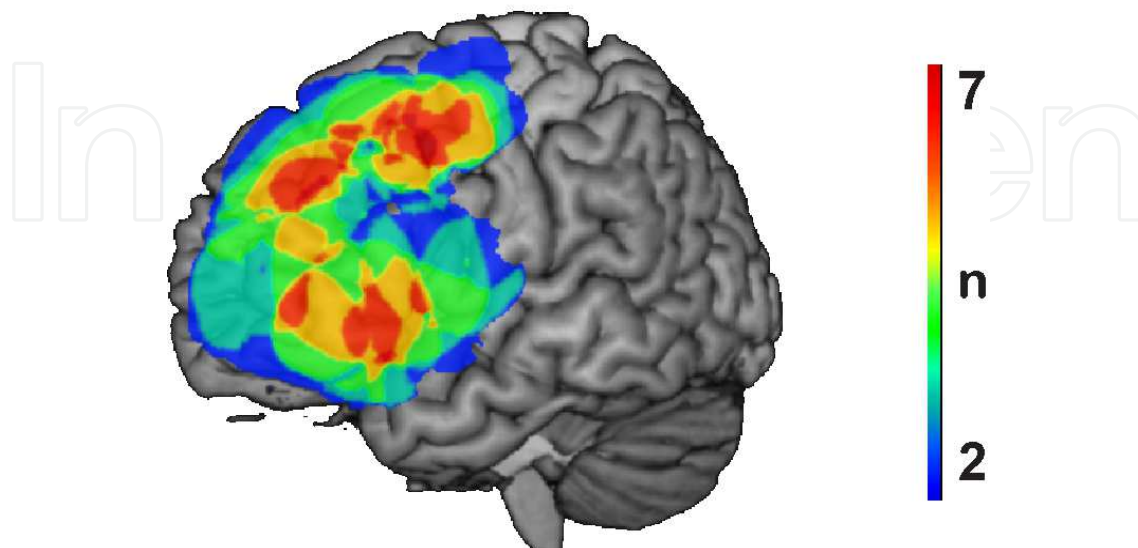


Fig. 2. Lesion overlap map for 21 patients with a glioma in the left frontal cortex

2.2 Stimuli

Each visual stimulus consisted of a picture at the top and a Japanese sentence at the bottom (Fig. 1). The pictures used for AS, PS, and SS were identical (the number of lines used in each picture, mean \pm SD: 14 ± 2.4 , $n = 6$). There was one sentence control (SC) condition with intransitive verbs (e.g., “ \square -to Δ -ga hashitteru”, “ \square and Δ run”) and equally complex pictures (14 ± 2.5 , $n = 6$), which were all different from those used under the three main conditions. Half of the pictures depicted action occurring from left to right, and the other half depicted action from right to left. In the pictures, the use of symbols was also counterbalanced for both sides within each condition.

The sentences describing actions were written in a combination of the “hiragana” and “kanji” writing systems, and all sentence stimuli were grammatical in Japanese. Each sentence included two noun phrases and one verb; for example, a noun phrase (\square -ga) consisted of a symbol (\square) and a hiragana (ga). Two sets of Japanese verbs (six transitive verbs: pull, push, scold, kick, hit, and call; and six intransitive verbs: lie, stand, walk, run, tumble, and cry) were used, each of which, including the passive forms, had either four or five syllables. Note that the verb “call” is used only as a transitive verb in Japanese. There was no significant difference in frequency between the two sets of verbs ($t(10) = 0.7$, $p = 0.5$), according to the Japanese lexical database (“Nihongo-no Goitokusei” (Lexical Properties of Japanese), Nippon Telegraph and Telephone Corporation Communication Science Laboratories, Tokyo, Japan, 2003). We prepared eight stimuli for each verb; there were 48 stimuli for each condition.

Each stimulus consisted of one picture (top) and one sentence (bottom). Pictures depicting actions consisted of two stick figures; each stick figure was distinguished by one of three “head” symbols: a circle (\circ), square (\square), or triangle (Δ). The participants indicated whether or not the meaning of each sentence matched the action depicted in the corresponding picture

by pressing one of two buttons. (A) Under the active sentence (AS) condition, canonical / subject-initial active sentences were presented (“ Δ -ga \circ -o hiiteru”). Below each example, a word-by-word translation in English is shown. Nom, nominative case; Acc, accusative case; Dat, dative case. (B) Under the passive sentence (PS) condition, non-canonical / subject-initial passive sentences were presented (“ \circ -ga Δ -ni hikareru”). (C) Under the scrambled sentence (SS) condition, non-canonical / object-initial scrambled sentences were presented (“ \circ -o Δ -ga hiireru”). An identical picture set was used under these three conditions. The sentence stimuli were all grammatical and commonly used in Japanese. All stimuli were presented visually in yellow against a dark background. Each stimulus was presented for 5800 ms followed by a 200 ms blank interval, which was ample time for the patients (see Table 2). For fixation, a red cross was also shown at the center of the screen. Stimulus presentation and behavioural data collection were controlled using the LabVIEW software and interface (National Instruments, Austin, TX, USA).

2.3 Tasks

In the picture-sentence matching task (Fig. 1), the participants read a sentence silently and indicated whether or not the meaning of each sentence matched the action of the corresponding picture by pressing one of two buttons. For AS, PS, and SS, all mismatched sentences were made by exchanging two symbols in the original sentences, e.g., “ \square pushes \circ ” instead of “ \circ pushes \square ”. For SC, symbol-mismatched and action-mismatched sentences were presented equally often, requiring the sentences to be read completely in order for the participants to arrive at a correct judgment.

In addition to the picture-sentence matching task, we used a visual control task (VC), which required neither word nor sentence processing, as a baseline condition (Kinno et al., 2008). For VC, the same sets of pictures used in the picture-sentence matching task were presented, together with a string of jumbled letters taken from a single sentence in which the symbols (\circ , \square , or Δ) and “kanji” appeared at the same positions in the string as in the picture-sentence matching task. The participants were asked to judge whether or not all the symbols in a letter string were the same as those in the picture, irrespective of the order of the symbols. The participants underwent practice sessions before testing to become fully familiarized with the tasks.

A single run of the testing sessions contained 24 “trial events” of the picture-sentence matching task (six times each for AS, PS, SS, and SC), with variable inter-trial intervals of 6 and 12 s (one and two VC, respectively), pseudorandomized within a run. Since meaningless letter strings were presented throughout VC while sentences were presented only in the trial events, the participants could switch from VC to the trial events according to the stimulus type. The order of AS, PS, SS, and SC was pseudorandomized in each run to prevent any condition-specific strategy. Eight runs were tested in a day per one participant. Half of the stimuli consisted of matched picture-sentence pairs (24 trials for each condition), and the other half consisted of mismatched pairs (24 trials for each condition). All patients underwent the testing sessions inside the scanner while they received three to six fMRI runs, and then they completed the rest of the eight runs outside the scanner. Because the number of fMRI runs was limited by the patients’ medical conditions, here we focused on the behavioural data and the anatomical MRI scans alone. All of the behavioural data from normal controls were acquired outside the scanner.

2.4 MRI data acquisition and analyses

The MRI scans were conducted on a 1.5 T scanner (Stratis II, Premium; Hitachi Medical Corporation, Tokyo, Japan), and a high-resolution T1-weighted 3D image (repetition time:

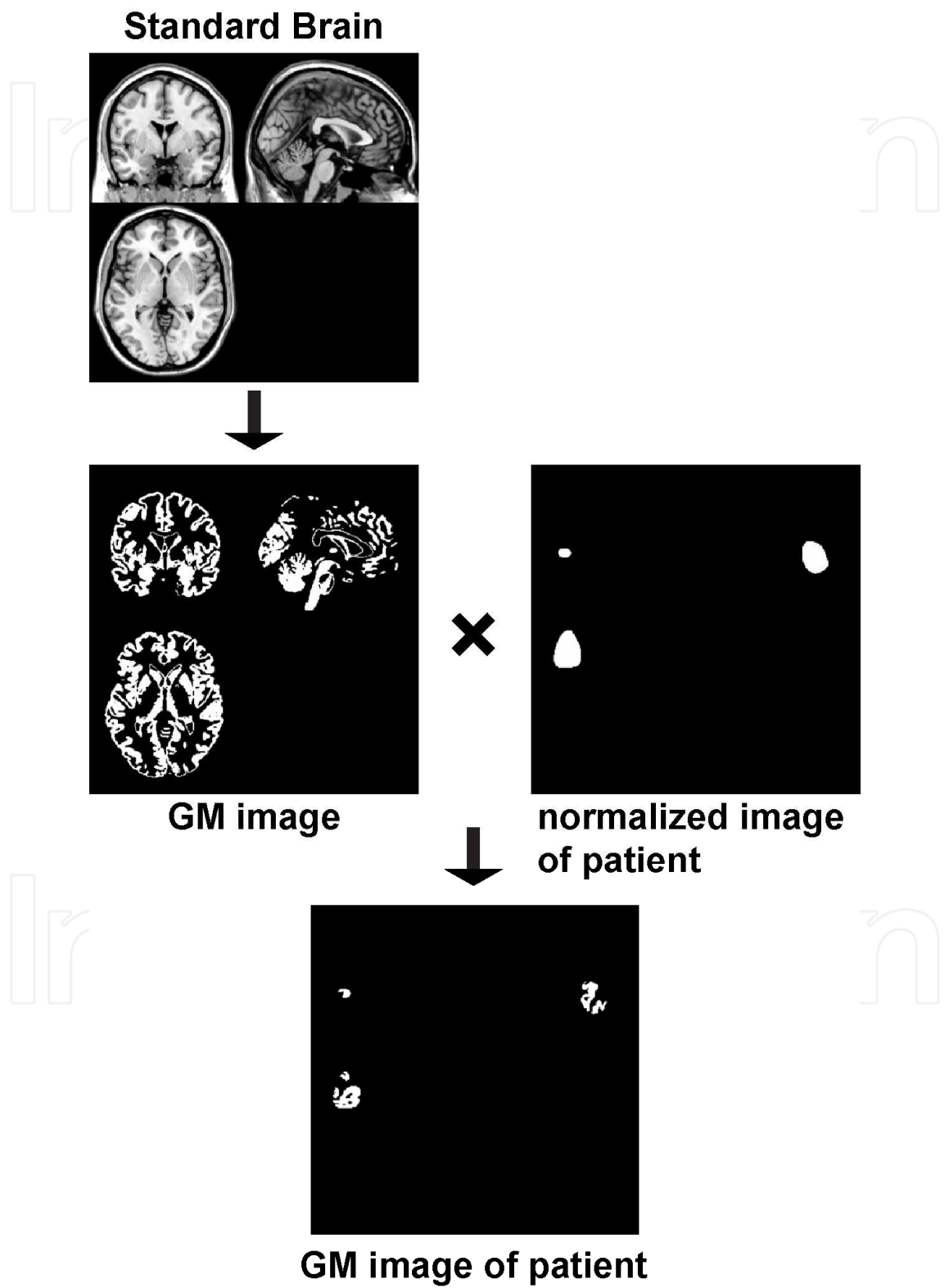


Fig. 2. Schematic representation of methods for making GM images.

30 ms, acquisition time: 8 ms, flip angle: 60°, field of view: 192 × 192 mm², resolution: 0.75 × 0.75 × 1 mm³) was acquired for each patient. The location of the glioma was first identified on this MR image, and the glioma boundary was semi-automatically determined using MRICroN software (<http://www.mricro.com/>) (Rorden & Brett, 2000). T2-weighted MR images (Department of Neurosurgery of Tokyo Women's Medical University) and positron-emission tomography (PET) data (Chubu Medical Center for Prolonged Traumatic Brain Dysfunction, Mino-Kamo-shi, Japan) were also used to assist the precise determination of the boundary. Each individual's structural image was spatially normalized to the standard brain space as defined by the Montreal Neurological Institute (MNI) using the "unified segmentation" algorithm, which is a generative model that combines tissue segmentation, bias correction and spatial normalization in a single unified model (Ashburner & Friston, 2005), which was resampled to 1 × 1 × 1 mm³ voxel size using statistical parametric mapping SPM8 software (Wellcome Department of Cognitive Neurology, London, UK) (Friston et al., 1995) on MATLAB (Math Works, Natick, MA, USA).

These resultant individually normalized images were divided into gray and white matters as follows (Fig. 2). Firstly, a GM image was made by dividing the standard brain into gray and white matters using MRICroN software. This GM image was used as a mask, which applied to the individually normalized image of each glioma.

Using the resultant GM image of each glioma, we next employed voxel-based lesion-symptom mapping (VLSM) to analyze the relationship between glioma location and the error rates on a voxel-by-voxel basis (Bates et al., 2003). The patients were divided into two groups according to whether they did or did not have a glioma including that voxel. The error rates for each condition or the difference in error rates between two conditions (e.g., PS – AS) were then compared for these two groups by a t-test, in which the statistical threshold was set to $p = 0.05$ after correction for multiple comparisons using the false discovery rate (FDR). To minimize the effects of outlier observations, the voxels used in the VLSM analysis were within the gliomas of at least two patients. Finally, the result of VLSM was projected onto a standard brain using MRICroN software.

3. Results

In our paradigm with three main conditions of AS, PS, and SS, under which two-argument relationships were critically required (see the Introduction), the same set of actions depicted by pictures was used, thus controlling semantic comprehension per se. In contrast, a different set of pictures were used under the SC condition (e.g., "□ and Δ run"), which basically required matching between words (symbols and verbs) and pictures alone, without syntactic analyses for the two-argument relationships. Thus, the SC condition was syntactically less complex and easier to comprehend than other conditions. It was therefore mandatory to analyze the three main conditions and SC separately. Moreover, the analyses also match with our fMRI study (Kinno et al., 2008), in which SC was used as a separate control. In the sections 3.1-3.3, we focus on the main conditions of AS, PS, and SS, and the results of SC are presented in the section 3.4.

3.1 Behavioral analyses

The ERs for the patients and the normal controls are shown in Table 2. A repeated-measures analysis of variance (rANOVA) with two factors (group [patients, normal controls] ×

condition [AS, PS, SS]) revealed significant main effects of group ($F(1, 40) = 16, p = 0.0003$) and condition ($F(2, 80) = 8.9, p = 0.0003$), as well as a significant interaction of group by condition ($F(2, 80) = 9.2, p = 0.0003$). The patients showed significantly higher error rates than the normal controls for each of AS, PS, and SS (t-test; AS: $t(40) = 2.5, p = 0.016$; PS: $t(40) = 2.9, p = 0.0055$; SS: $t(40) = 4.1, p = 0.0002$). According to paired t-tests on the three main conditions, the patients' error rates were significantly higher for SS than for AS and PS (AS: $t(20) = 3.8, p = 0.0010$; PS: $t(20) = 2.5, p = 0.021$), whereas the difference was marginal between AS and PS ($t(20) = 1.9, p = 0.07$). However, there was no significant difference among the normal controls' error rates under the main conditions ($p > 0.7$). The results from the normal controls is consistent with our previous results (Kinno et al 2008).

These significant errors were observed in spite of the patient's normal verbal and nonverbal IQs (Table 1; range: 86-113 within 1 SD of ± 15 ; one sample t-test for the difference from 100: verbal, $t(20) = 1.2, p = 0.25$ and nonverbal, $t(20) = 0.51, p = 0.62$). According to correlation analyses, the error rates for each condition could not be attributed to their ages, verbal / nonverbal IQs, or tumor volumes and GM ratio (all, $p > 0.1$). These results corresponded with our previous findings (Kinno et al., 2009), demonstrating that the tumor locations affected the actual performance of the three main conditions.

The RTs for the patients and the normal controls are also shown in Table 2. An rANOVA with two factors (group [patients, normal controls] \times condition [AS, PS, SS]) showed that neither a main effect of group ($F(1, 40) = 2.1, p = 0.2$) nor that of condition was significant ($F(2, 80) = 2.8, p = 0.1$), with no significant interaction of group by condition ($F(2, 80) = 0.30, p = 0.7$). Because there was a significant main effect of condition regarding the error rates, the error rates were better indicators than RTs for estimating condition-selective effects. Therefore, we used error rates as indicators in the following VLSM analyses.

Participant	Error Rate (%)				RT (ms)			
	AS	PS	SS	SC	AS	PS	SS	SC
Normal controls	1.8 \pm 2.6	2.1 \pm 2.4	2.4 \pm 2.6	1.8 \pm 1.4	3334 \pm 470	3524 \pm 466	3599 \pm 405	2712 \pm 535
Patients	8.1 \pm 7.4	12 \pm 12	22 \pm 21	2.4 \pm 2.3	3372 \pm 423	3476 \pm 453	3499 \pm 455	2760 \pm 298

Table 2. Behavioral Data under Each Condition. ERs and RTs (for correct trials only) are shown as mean \pm standard deviation.

3.1.1 VLSM analyses for gray and white matters

To identify any critical regions for the main conditions of AS, PS, and SS, we first conducted VLSM analyses, in which error rates for each condition were evaluated among the left frontal-damaged patients ($n = 21$). We found that significantly higher error rates for AS were associated with lesions in L. IFG, including L. dorsal F3op/F3t, as well as isolated lesions in L. LPMC (Fig. 3A). Moreover, significantly higher error rates for PS were associated with lesions in L. dorsal F3op/F3t, further extending to ventral F3op/F3t (Fig. 3B). In contrast, significantly higher error rates for SS were associated with lesions in L. LPMC and ventral IFG (Fig. 3C). These results indicate that both of L. F3op/F3t and L. LPMC are the critical regions for AS, PS, and SS.

Next we examined which regions were critically involved in the comprehension of syntactically complex sentences. For this purpose, we conducted VLSM analyses, in which the difference in error rates between the conditions of noncanonical vs. canonical sentences,

i.e., PS – AS or SS – AS, was evaluated among the left frontal-damaged patients. We found that the significantly larger difference in PS – AS was associated with lesions in L. F3op/F3t (Fig. 3D). In contrast, we found that the significantly larger difference in SS – AS was associated mostly with lesions in L. LPMC (Fig. 3E). These results are consistent with our previous results (Kinno et al., 2009) with better sensitivity, indicating that both of L. F3op/F3t and L. LPMC are sufficient to cause agrammatic comprehension.

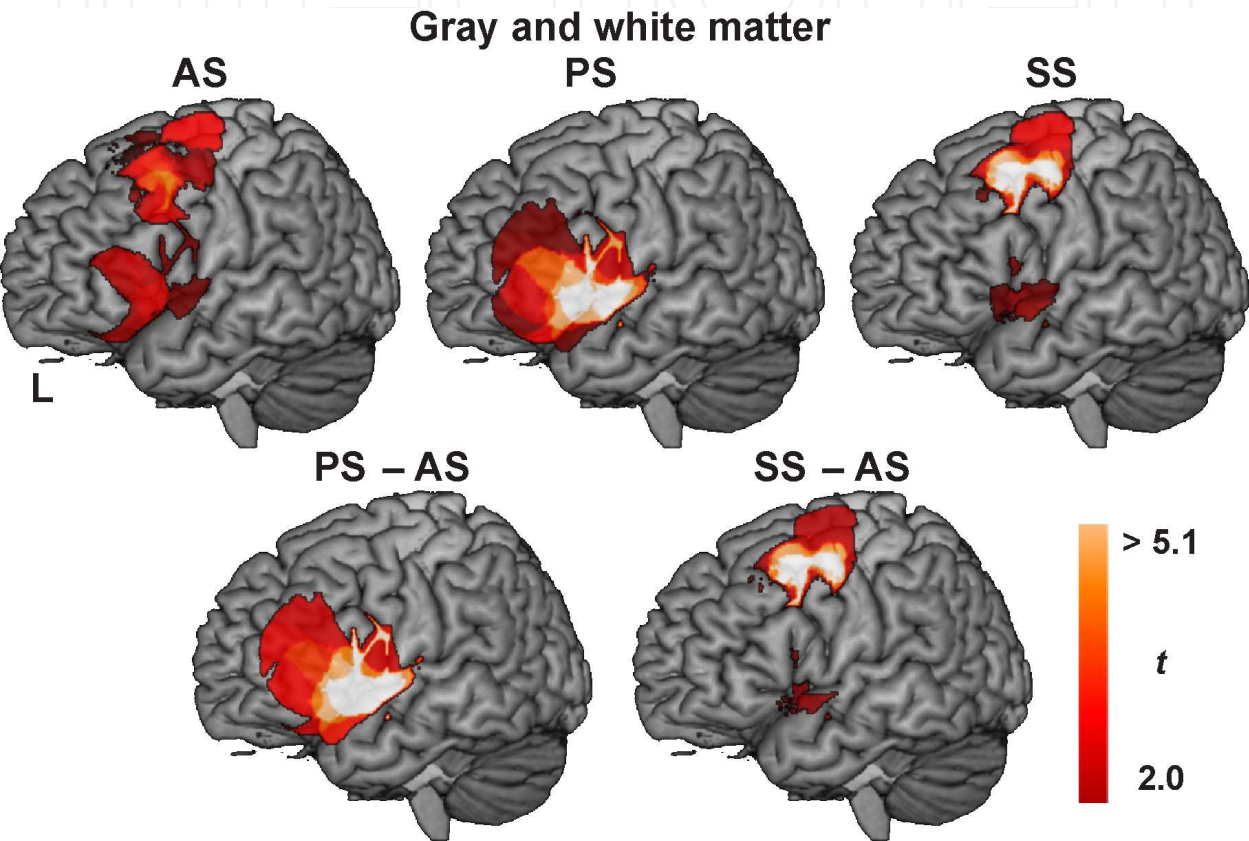


Fig. 3. Brain regions identified by the VLSM analysis for gray and white matters

Brain regions identified by the VLSM analysis for gray and white matters among the left frontal-damaged patients (n = 21) for AS, PS, SS, PS – AS, and SS – AS, respectively. The resultant t-map is projected on the left (L) lateral surface; the threshold was established at $t > 2.0$ (FDR corrected $p < .05$).

3.1.2 VLSM analyses for gray matter

We performed the modified VLSM analyses to identify the relative contribution of gray matter to syntactic processing required for the main conditions of AS, PS, and SS, in which a GM image of each glioma was used. We found that significantly higher error rates for AS were associated with ventral lesions in L. IFG, as well as isolated lesions in L. LPMC (Fig. 4).

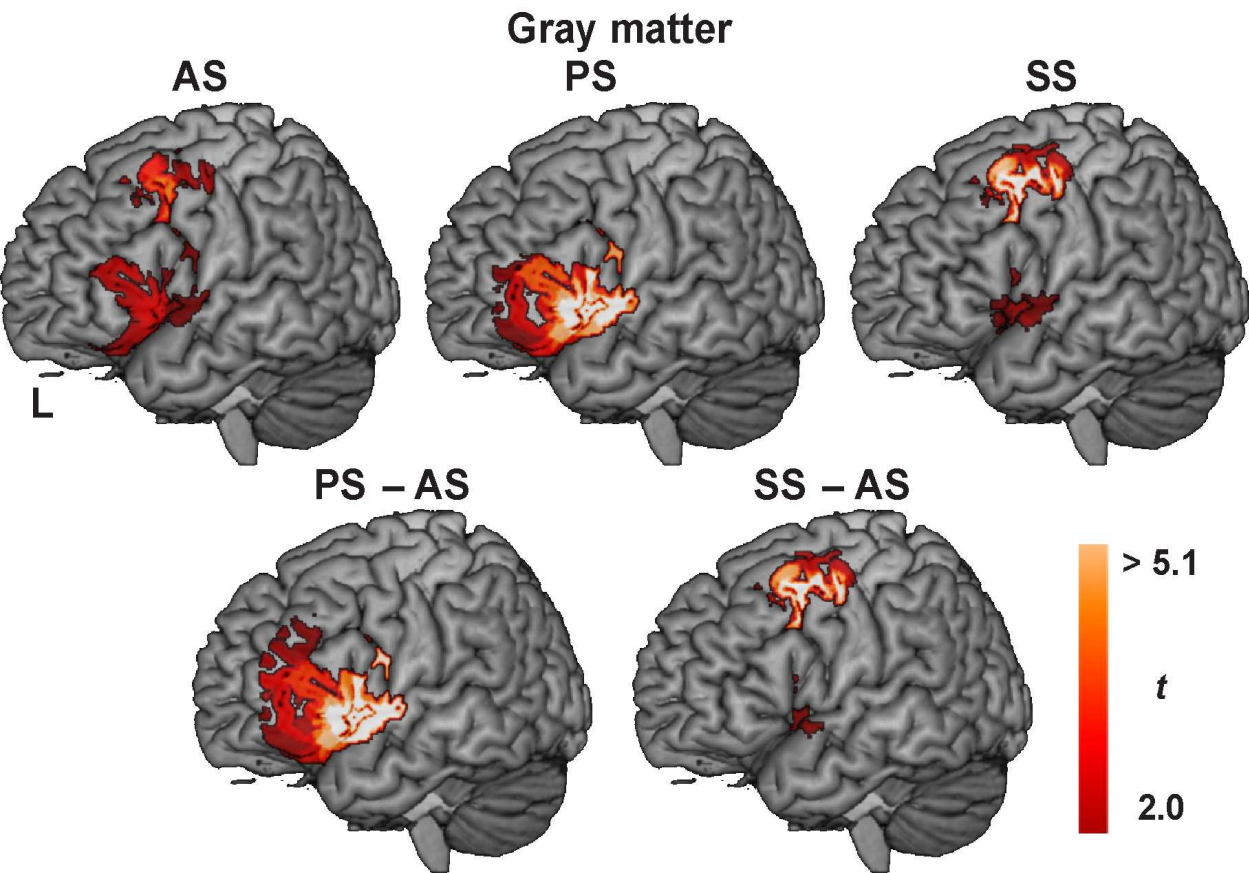


Fig. 4. Brain regions identified by the VLSM analysis for gray matter.

Moreover, significantly higher error rates for PS were associated with lesions in L. ventral F3op/F3t, further extending to dorsal F3op/F3t. In contrast, significantly higher error rates for SS were associated with lesions in L. LPMC and ventral IFG. These results are compatible to our previous findings.

Next we examined the effect of gray matter on the comprehension of syntactically complex sentences. We found that the significantly larger difference in PS - AS was associated with lesions in L. F3op/F3t (Fig. 4). In contrast, we found that the significantly larger difference in SS - AS was associated mostly with lesions in L. LPMC. These results indicate that the gray matter of L. F3op/F3t as well as L. LPMC are critically involved in the comprehension of syntactically complex sentences.

3.2 The analyses of the SC condition

We compared the performance data for SC between all patients and the normal controls to examine whether or not such basic comprehension of sentences was affected for the patients. The patients showed no significant difference in error rates for SC when compared with the normal controls ($t(40) = 0.87$, $p = 0.4$) (Table 2). Regarding RTs for SC, there was no significant difference between the patients and normal controls ($t(40) = 0.36$, $p = 0.7$). Moreover, paired t-tests showed that the patients' error rates were significantly lower for SC than for AS, PS, and SS (AS: $t(20) = 3.6$, $p = 0.020$; PS: $t(20) = 3.4$, $p = 0.0029$; SS: $t(20) = 4.5$, $p = 0.0002$), whereas the normal controls' error rates for SC were not significantly different from those for the three main conditions ($p > 0.7$). For both the patients and normal controls, RTs were significantly shorter for SC than for the three main conditions (all, $p < 0.0001$). These results indicate that basic comprehension of sentences under the SC condition was preserved among the patients.

4. Discussion

In this chapter, we have presented the modified VLSM method that can directly examine the effect of a GM lesion on a cognitive process. The present study successfully demonstrates that GM of L. F3op/F3t and L. LPMC are actually essential for AS, PS, and SS (Fig. 4), and that both regions are indeed critically involved in the comprehension of syntactically complex sentences. The patients with a lesion in GM of L. F3op/F3t or L. LPMC had significant deficits in syntactic analyses for the two-argument relationships required for the three main conditions, but without deficits in any factors required for SC. These results provide crucial evidence that GM of L. F3op/F3t and L. LPMC subserves syntactic comprehension.

The condition-selectivity in error rates for the patients with a GM lesion in either L. F3op/F3t or L. LPMC cannot be explained by general disorders of the patients, including visual / memory / motor impairment, attention disturbance due to drowsiness or dizziness, and perseveration for a particular sentence type. It is natural to assume that the patients with normal verbal IQ would not otherwise experience or exhibit difficulty in language comprehension with such simple sentences; however the patients indeed exhibited clear deficits even for canonical sentences for AS in the present study. In daily conversation, pragmatic information about word use resolves syntactic difficulty (e.g., "The officer chased the thief" is more acceptable than "The thief chased the officer."). The use of appropriate syntactic judgment tests is thus necessary for a proper assessment of syntactic comprehension. The importance of GM of L. F3op/F3t and L. LPMC has been underpinned by accumulating results from fMRI studies, which demonstrated the selectivity for syntactic processing in L. F3op/F3t and /or L. LPMC (Dapretto & Bookheimer, 1999; Embick et al., 2000; Hashimoto & Sakai, 2002; Bornkessel et al., 2005; Grewe et al., 2006), indicating the critical role of the two left frontal regions on the language network for syntactic processing (Sakai, 2005). Moreover, the present results are consistent with another recent fMRI study, in which both L. dF3t and L. LPMC were selectively activated for the syntactic comprehension of honorification, in which two-argument relationships of either subject honorifics or object honorifics were critically involved (Momo, Sakai, & Sakai, 2008). Further research is required for understanding both anatomical and functional bases for the differential roles of these two critical regions.

It has been well known that the left temporal cortex is also engaged during sentence comprehension. In our fMRI study with the same paradigm, we have reported that a localized activation in the left posterior superior / middle temporal gyrus (L. pSTG/MTG) was also enhanced for SS when compared with AS and PS (Kinno et al., 2008). Other fMRI studies have also reported that this region was activated by contrasting object-initial vs. subject-initial sentences (Bornkessel et al., 2005), as well as by contrasting sentences with syntactic / semantic anomaly and normal sentences (Suzuki & Sakai, 2003). A lesion in L. pSTG/MTG may thus result in the SS-selective deficit. A recent intraoperative electrocorticography study in humans showed bidirectional connectivity between L. IFG and L. pSTG/MTG (Matsumoto et al., 2004), and additional evidence for this connectivity has been reported in studies using MRI to investigate structural connectivity (Catani, Jones, & Ffytche, 2005; Friederici et al., 2006). Therefore, it is possible that this network subserves syntactic integration, thereby combining multiple linguistic information. Further lesion studies are required to examine whether or not a lesion in gray or white matter of the left temporal region is sufficient to cause deficits in such a linguistic process. Our lesion-symptom method would be useful for this purpose.

Compared with a cerebrovascular disease such as an infarct or a hemorrhage, a glioma has both advantages and disadvantages in neuropsychological and neurolinguistic research. First, it is advantageous that the location of a glioma is basically random in the cerebrum and not restricted by the cerebrovascular distribution. Indeed, damage to the middle cerebral artery affects the perisylvian cortex including F3op/F3t, but it spares more dorsal regions including LPMC. Using the lesion data with a glioma, we successfully showed the functional roles of L. F3op/F3t and L. LPMC. Second, the precise determination of the location and extent of a glioma is often difficult, because a glioma may induce edemas, abnormalities by compressing its peripheral region, and infiltration. In the present study, we used both T2-weighted MR images and PET data, which enabled us to determine precise boundary of lesions including brain edemas and abnormalities of perfusion. Third, some neural functions may be still preserved within a glioma, as indicated by cortical stimulation and fMRI studies (Ojemann, Miller, & Silbergeld, 1996; Krainik et al., 2003). It has been also reported that patients with tumors in the left hemisphere showed less language impairment than their counterparts with stroke (Anderson, Damasio, & Tranel, 1990). In the present study, however, we regarded an entire glioma as a lesion, and clear language deficits were observed despite such residual functions. Fourth, the onset and time course of a glioma is difficult to determine; a glioma develops gradually without apparent symptoms such as hemiplegia or dysarthria. In the present study, the patients were at least 21 years old at their start of medication, and had no prior history of benign or malignant brain tumors, indicating an adult-onset glioma. For evaluating the real function of a cortical region, it is thus important to compare the lesion symptom data from our lesion-symptom method with the functional neuroimaging data from normal controls.

It has been recently demonstrated that slow-growing lesions like WHO grade II gliomas, but not high-grade gliomas, may induce cortical reorganization even before operation (Desmurget, Bonnetblanc, & Duffau, 2007). Moreover, the grade II gliomas undergo anaplastic transformation over the years, i.e., the progression into grade III gliomas (Behin et al., 2003), which may be enough time for cortical reorganization. Such a functional

reshaping might affect the observation of the present study, because the tumor types of the patients were heterogeneous including WHO grade II ($n = 10$), and III ($n = 11$), with different biological processes for each tumor. However, it should be noted that the patients with a glioma in either L. F3op/F3t or L. LPMC showed marked deficits in syntactic comprehension, which had not been rescued by any functional reshaping. It is possible that the reorganization of other cortical regions due to a lesion in L. F3op/F3t or L. LPMC is entirely different each other, thus leading to the differential patterns of condition-selective deficits. Further functional neuroimaging studies for brain-damaged patients are required to clarify real mechanisms of cortical reorganization.

Understanding cortical networks for a cognitive process requires knowledge of functional as well as anatomical connections between brain regions. Not only lesion symptom mapping but also functional imaging studies of patients with a well-defined lesion are useful for understanding cortical networks by revealing abnormal activations: overactivity (i.e., regions where patients activate more than normal controls) or underactivity (i.e., regions where patients activate less than normal controls) (Price & Friston, 1999; Price, Crinion, & Friston, 2006). These differential activations can imply a change in cognitive or neuronal implementation. Changes in cognitive implementation occur when a patient uses a different set of cognitive processes either because a new cognitive strategy has been learned, or because of increased demands on normal processing due to a brain damage. Changes in neuronal implementation are mediated by changes in the strength of pre-existing connections. Abnormal activations distant to the lesion location suggest the dysfunctional region has been disconnected from its normal inputs. This disconnection may result in overactivity, due to disinhibition of an inhibitory network, or underactivity, due to a failure to activate a cortical region. These abnormal activations can reveal a duplicate system for a cognitive process, in which the dominant system inhibits the others. Within the duplicate system, the less dominant systems are able to respond when the dominant system is damaged. This duplication of functionality renders a function immune from the effects of focal damage. Functional imaging studies of patients, therefore, have an important role to play in the identification of a duplicate system—the multiplicity of sufficient brain systems for a cognitive function. Further study is required to investigate the language-specific system for the human brain.

5. Conclusion

In this chapter, we have presented a lesion-symptom mapping method that can directly examine the effect of a GM lesion on a cognitive process. As a glioma extends to both gray and white matter, it remains to be elucidated whether the cognitive deficits are due to the glioma in gray or white matter. It is typically supposed that a glioma in GM causes dysfunction of the localized region, whereas a glioma in white matter leads to the disconnection of neural networks. Therefore, the effect of GM lesion should be assessed precisely; for this purpose, our method would be useful. While a glioma in the cerebral cortex causes a deficit in cognitive function, the severity and course of such a dysfunction need to be thoroughly assessed (Wefel, Kayl, & Meyers, 2004). An extensive study of tumors with multiple neuropsychological tests have confirmed that patients with left hemispheric tumors exhibited poorer verbal fluency and verbal learning than those with right hemispheric tumors (Hahn et al., 2003). The present study demonstrated the severity of dysfunction, such that a GM lesion in L. F3op/F3t and/or L. LPMC can cause clear deficits

in syntactic comprehension. Our language task would be thus sensitive enough and useful for a general assessment of linguistic knowledge. Our findings further indicate that brain surgery for a glioma in the left frontal cortex requires careful assessment for maintaining syntactic abilities, which are indeed the source of the creative faculty for producing infinite expressions (Hauser, Chomsky, & Fitch, 2002), and thus for ensuring the best possible QOL for individual patients.

6. Acknowledgment


We thank M. Kawamura for his suggestion regarding neurological issues, N. Komoro for her technical assistance, H. Matsuda for her administrative assistance. This research was supported by a research grant from the Narishige Neuroscience Research Foundation (R. K.) and a Core Research for Evolutional Science and Technology (CREST) grant from the Japan Science and Technology Agency (JST) (K. L. S.).

7. References

- Anderson, S. W., Damasio, H., & Tranel, D. (1990). Neuropsychological impairments associated with lesions caused by tumor or stroke. *Archives of Neurology* 47, 397-405.
- Ashburner, J & Friston, K. J. (2005). Unified segmentation., *NeuroImage* 26: 839– 851.
- Badecker, W. & Caramazza, A. (1985). On considerations of method and theory governing the use of clinical categories in neurolinguistics and cognitive neuropsychology: The case against agrammatism., *Cognition* 20: 97-125.
- Bates, E., Wilson, S. M., Saygin, A. P., Dick, F., Sereno, M. I., Knight, R. T., & Dronkers, N. F. (2003). Voxel-based lesion-symptom mapping., *Nature Neuroscience* 6: 448-450.
- Behin, A., Hoang-Xuan, K., Carpentier, A. F., & Delattre, J.-Y. (2003). Primary brain tumours in adults. *Lancet* 361, 323-331.
- Bornkessel, I., Zysset, S., Friederici, A. D., von Cramon, D. Y., & Schlesewsky, M. (2005). Who did what to whom? The neural basis of argument hierarchies during language comprehension. *Neuroimage* 26, 221-233.
- Caplan, D., Baker, C., & Dehaut, F. (1985). Syntactic determinants of sentence comprehension in aphasia. *Cognition* 21, 117-175.
- Catani, M., Jones, D. K., & Ffytche, D. H. (2005). Perisylvian language networks of the human brain. *Annals of Neurology* 57, 8-16.
- Cupples, L. & Inglis, A. L. (1993). When task demands induce "asyntactic" comprehension: A study of sentence interpretation in aphasia. *Cognitive Neuropsychology* 10, 201-234.
- Dapretto, M. & Bookheimer, S. Y. (1999). Form and content: Dissociating syntax and semantics in sentence comprehension. *Neuron* 24, 427-432.
- Desmurget, M., Bonnetblanc, F., & Duffau, H. (2007). Contrasting acute and slow-growing lesions: A new door to brain plasticity. *Brain* 130, 898-914.
- Dick, F., Bates, E., Wulfeck, B., Utman, J. A., Dronkers, N., & Gernsbacher, M. A. (2001). Language deficits, localization, and grammar: Evidence for a distributive model of

- language breakdown in aphasic patients and neurologically intact individuals. *Psychological Review* 108, 759-788.
- Embick, D., Marantz, A., Miyashita, Y., O'Neil, W., & Sakai, K. L. (2000). A syntactic specialization for Broca's area. *Proceedings of the National Academy of Sciences of the United States of America* 97, 6150-6154.
- Friederici, A. D., Bahlmann, J., Heim, S., Schubotz, R. I., & Anwander, A. (2006). The brain differentiates human and non-human grammars: Functional localization and structural connectivity. *Proceedings of the National Academy of Sciences of the United States of America* 103, 2458-2463.
- Friston, K. J., Holmes, A. P., Worsley, K. J., Poline, J.-P., Frith, C. D., & Frackowiak, R. S. J. (1995). Statistical parametric maps in functional imaging: A general linear approach. *Human Brain Mapping* 2, 189-210.
- Goodglass, H. & Menn, L. (1985) Is agrammatism a unitary phenomenon? In M.-L. Kean (Ed), *Agrammatism* (pp. 1-26). Orlando, FL: Academic Press.
- Grewe, T., Bornkessel, I., Zysset, S., Wiese, R., von Cramon, D. Y., & Schlesewsky, M. (2006). Linguistic prominence and Broca's area: The influence of animacy as a linearization principle. *Neuroimage* 32, 1395-1402.
- Grodzinsky, Y. (2000). The neurology of syntax: Language use without Broca's area. *Behavioral and Brain Sciences* 23, 1-71.
- Haglund, M. M., Ojemann, G. A., & Hochman, D. W. (1992). Optical imaging of epileptiform and functional activity in human cerebral cortex. *Nature* 358, 668-671.
- Hahn, C. A., Dunn, R. H., Logue, P. E., King, J. H., Edwards, C. L., & Halperin, E. C. (2003). Prospective study of neuropsychologic testing and quality-of-life assessment of adults with primary malignant brain tumors. *International Journal of Radiation Oncology*Biophysics* 55, 992-999.
- Hashimoto, R. & Sakai, K. L. (2002). Specialization in the left prefrontal cortex for sentence comprehension. *Neuron* 35, 589-597.
- Hauser, M. D., Chomsky, N., & Fitch, W. T. (2002). The faculty of language: What is it, who has it, and how did it evolve? *Science* 298, 1569-1579.
- Just, M. A. & Carpenter, P. A. (1992). A capacity theory of comprehension: Individual differences in working memory. *Psychological Review* 99, 122-149.
- Kinno, R., Kawamura, M., Shioda, S., & Sakai, K. L. (2008). Neural correlates of noncanonical syntactic processing revealed by a picture-sentence matching task. *Human Brain Mapping* 29, 1015-1027.
- Kinno, R., Muragaki, Y., Hori, T., Maruyama, T., Kawamura, M., Sakai, K. L. (2009). Agrammatic comprehension caused by a glioma in the left frontal cortex. *Brain and Language* 110, 71-80.
- Krainik, A., Lehericy, S., Duffau, H., Capelle, L., Chainay, H., Cornu, P., Cohen, L., Boch, A.-L., Mangin, J.-F., Le Bihan, D., & Marsault, C. (2003). Postoperative speech disorder after medial frontal surgery: Role of the supplementary motor area. *Neurology* 60, 587-594.
- Matsumoto, R., Nair, D. R., LaPresto, E., Najm, I., Bingaman, W., Shibasaki, H., & Lüders, H. O. (2004). Functional connectivity in the human language system: A cortico-cortical evoked potential study. *Brain* 127, 2316-2330.

- Menn, L. & Obler, L. K. (1990) Theoretical motivations for the cross-language study of agrammatism. In L. Menn & L. K. Obler (Eds.), *Agrammatic Aphasia: A Cross-Language Narrative Sourcebook* (pp. 3-12). Amsterdam: John Benjamins Publishing Company.
- Momo, K., Sakai, H., & Sakai, K. L. (2008). Syntax in a native language still continues to develop in adults: Honorification judgment in Japanese. *Brain and Language* 107, 81-89.
- Ojemann, J. G., Miller, J. W., & Silbergeld, D. L. (1996). Preserved function in brain invaded by tumor. *Neurosurgery* 39, 253-259.
- Oldfield, R. C. (1971). The assessment and analysis of handedness: The Edinburgh inventory. *Neuropsychologia* 9, 97-113.
- Price, C. J., & Friston, K. J. (1999). Scanning patients with tasks they can perform. *Human Brain Mapping* 8, 102-108.
- Price, C. J., Crinion J., & Friston, K. J. (2006). Design and Analysis of fMRI Studies With Neurologically Impaired Patients. *Journal of magnetic resonance imaging* 23, 816-826 (2006)
- Pulvermüller, F. (1995). Agrammatism: Behavioral description and neurobiological explanation. *Journal of Cognitive Neuroscience* 7, 165-181.
- Rorden, C. & Karnath, H. O. (2004). Using human brain lesions to infer function: A relic from a past era in the fMRI age? *Nature Reviews Neuroscience* 5, 813-819.
- Sakai, K. L. (2005). Language acquisition and brain development. *Science* 310, 815-819.
- Schwartz, M. F., Saffran, E. M., & Marin, O. S. M. (1980). The word order problem in agrammatism. I. Comprehension. *Brain and Language* 10, 249-262.
- Suzuki, K. & Sakai, K. L. (2003). An event-related fMRI study of explicit syntactic processing of normal/anomalous sentences in contrast to implicit syntactic processing. *Cerebral Cortex* 13, 517-526.
- Van Valin, R. D., Jr. & LaPolla, R. J. (1997). *Syntax: Structure, Meaning, and Function*. Cambridge, UK: Cambridge University Press.
- Wefel, J. S., Kayl, A. E., & Meyers, C. A. (2004). Neuropsychological dysfunction associated with cancer and cancer therapies: A conceptual review of an emerging target. *British Journal of Cancer* 90, 1691-1696.



Advances in the Biology, Imaging and Therapies for Glioblastoma

Edited by Prof. Clark Chen

ISBN 978-953-307-284-5

Hard cover, 424 pages

Publisher InTech

Published online 09, November, 2011

Published in print edition November, 2011

This book is intended for physicians and scientists with interest in glioblastoma biology, imaging and therapy. Select topics in DNA repair are presented here to demonstrate novel paradigms as they relate to therapeutic strategies. The book should serve as a supplementary text in courses and seminars as well as a general reference.

How to reference

In order to correctly reference this scholarly work, feel free to copy and paste the following:

Ryuta Kinno, Yoshihiro Muragaki and Kuniyoshi L. Sakai (2011). Gray or White? – The Contribution of Gray Matter in a Glioma to Language Deficits, *Advances in the Biology, Imaging and Therapies for Glioblastoma*, Prof. Clark Chen (Ed.), ISBN: 978-953-307-284-5, InTech, Available from:
<http://www.intechopen.com/books/advances-in-the-biology-imaging-and-therapies-for-glioblastoma/gray-or-white-the-contribution-of-gray-matter-in-a-glioma-to-language-deficits>

INTECH
open science | open minds

InTech Europe

University Campus STeP Ri
Slavka Krautzeka 83/A
51000 Rijeka, Croatia
Phone: +385 (51) 770 447
Fax: +385 (51) 686 166
www.intechopen.com

InTech China

Unit 405, Office Block, Hotel Equatorial Shanghai
No.65, Yan An Road (West), Shanghai, 200040, China
中国上海市延安西路65号上海国际贵都大饭店办公楼405单元
Phone: +86-21-62489820
Fax: +86-21-62489821

© 2011 The Author(s). Licensee IntechOpen. This is an open access article distributed under the terms of the [Creative Commons Attribution 3.0 License](https://creativecommons.org/licenses/by/3.0/), which permits unrestricted use, distribution, and reproduction in any medium, provided the original work is properly cited.

IntechOpen

IntechOpen