

We are IntechOpen, the world's leading publisher of Open Access books Built by scientists, for scientists

6,900

Open access books available

186,000

International authors and editors

200M

Downloads

Our authors are among the

154

Countries delivered to

TOP 1%

most cited scientists

12.2%

Contributors from top 500 universities



WEB OF SCIENCE™

Selection of our books indexed in the Book Citation Index
in Web of Science™ Core Collection (BKCI)

Interested in publishing with us?
Contact book.department@intechopen.com

Numbers displayed above are based on latest data collected.
For more information visit www.intechopen.com



Virtual Colonoscopy: Indications, Techniques, Findings

Mutlu Saglam and Fatih Ors

*Department of Radiology, Gulhane Military Medical Academy,
Turkey*

1. Introduction

Colorectal cancer (CRC) is the second most prevalent type of cancer in Europe. Early detection and removal of CRC or its precursor lesions by population screening can reduce mortality.[1]

An increasingly popular screening test for colorectal cancer is computed tomographic (CT) colonography, also called virtual colonoscopy (VC). It is a powerful technique for population screening of asymptomatic adults. It has potential advantages over conventional colonoscopy (CC) as it is less invasive, less time-consuming and less expensive. Moreover, no sedation is needed.[2] Its main disadvantages to CC are the exposure of individuals to ionizing radiation and the lack of ability to take tissue samples or to remove polyps during the procedure.[2-6]

CT colonography was first described in 1994 as a radiographic technique in which thin-section images of pneumocolon could be reconstructed by sophisticated software into high-resolution 2D- and 3D images.[7,8] Over time, improvements in hardware and software have allowed faster scanning, reduced exposure to radiation, and better imaging. Newer modes of imaging (called fly-through) can produce results that resemble endoscopic images and permit sophisticated characterization of detected lesions.[7,9-11]

The ability of VC to detect colorectal polyps has been tested in a multitude of studies. VC appeared to be promising in high risk populations, with a reported sensitivity greater than 90% for polyps ≥ 10 mm. [12-14] To achieve such results, adequate bowel cleaning or fecal tagging and reader experience are essential.

This chapter summarizes the main indications, the current techniques in patient preparation, data acquisition and data analysis as well as imaging features for common benign and malignant colorectal lesions.

2. Indications

CT colonography is used to examine the colon and rectum, and detect abnormalities such as polyps and cancer. There are several clinical indications for CT colonography. They include evaluation of the colon after an incomplete or unsuccessful CC examination and evaluation of the colon proximal to an obstructing neoplasm.[2,15-19] An incomplete CC examination is defined as a failure to intubate the caecum. Incomplete CC may be the result of poor bowel

preparation, redundant colon, and patient intolerance to the procedure, spasm, or colonic obstruction caused by a neoplastic or non-neoplastic stenosis. The CT colonography examination can be performed on the same day directly after CC and without additional bowel preparation.[2,20] In cases of an obstructing cancer (Figure 1), CT colonography offers information about the pre-stenotic colon, local tumor invasion, lymph nodes, and distant metastases.[2,21-23] In this case, IV contrast is helpful to enable a complete staging of the patient.[2,19]

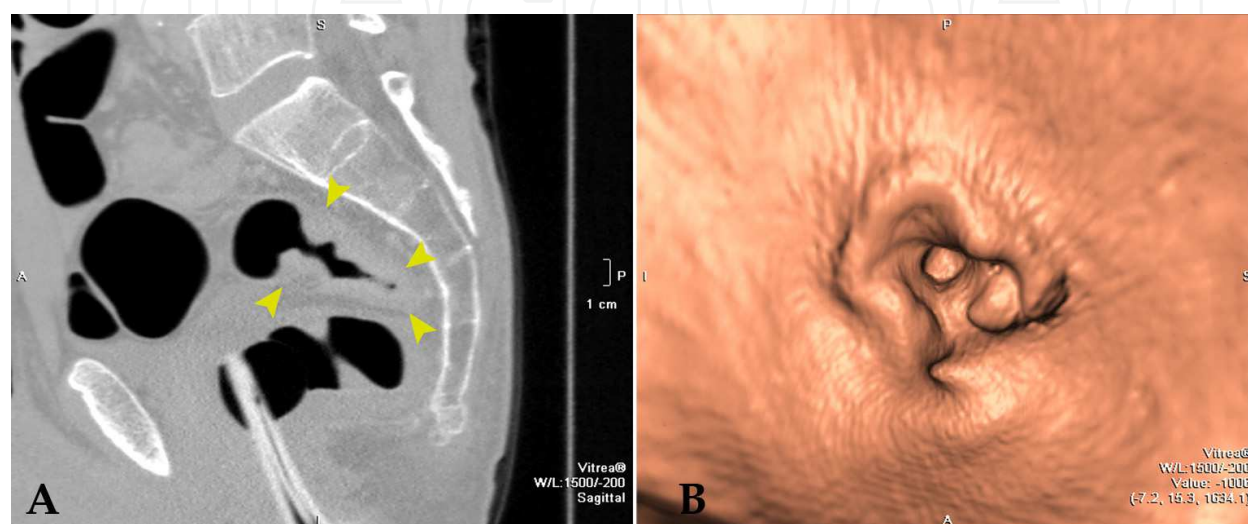


Fig. 1. Incomplete colonoscopy because of a stenotic cancer of the rectum. (A) 2D sagittal CT colonographic image shows circular wall thickening in the rectum (arrowheads). (B) 3D CT colonographic image shows an irregular, circular, stenotic filling defect.

Another indication for CT colonography is the evaluation of patients with contraindications to CC or who refuse other screening options.[2,3] This includes patients in need of anticoagulation, past history of difficult or incomplete colonoscopy, and patients who cannot be sedated due to medical conditions. Furthermore, in cases of advanced patient age, and in frail or immobile patients, CT colonography can be safely performed to exclude neoplastic or stenotic conditions.[2,3,24,25]

At chronic stages of inflammatory bowel disease, CT colonography can provide information on the extent of disease and about stenosis and prestenotic regions, as well as the extracolonic extent and complications of the disease.[2,26-29].

3. Contraindications

Contraindications to CT colonography include acute abdominal pain, recent abdominal or pelvic surgery, abdominal wall hernia with entrapment of colonic loops, and acute inflammatory conditions, such as acute diverticulitis, acute active stage of ulcerative colitis or Crohn's disease, and toxic megacolon. In these conditions, insufflations of the colon can lead to perforation and widespread peritonitis.[2,30-32]. In addition, weight and girth limitations of the scanner, artifacts from metal prosthesis, pregnancy, and patients with claustrophobia are general CT contraindications.[2]

4. CT colonography technique

4.1 Patient preparation

For optimal image quality, the colon should be clean, dry, and completely distended. Residual stool and fluid may lead to a false-negative or false positive diagnosis. A well-prepared colon will facilitate lesion detection and minimize false-positive findings, whereas residual matter in the lumen (e.g., stool, fluid) may stimulate or obscure colonic lesions.[2,12]

There are three commercially available bowel preparations; these include cathartics such as magnesium citrate (LoSo Preparation, EZ-Em Inc, Westbury, NY, USA) and phosphosoda (Fleet Pharmaceuticals, Lynchburg, VA, USA) and colonic lavage solutions such as polyethylene glycol (PEG). Magnesium citrate and phosphosoda are adequate for CT colonography.[2] The polyethylene glycol preparation frequently leaves a large amount of residual fluid in the colon.[3,33] While this preparation is adequate for CC, large amounts of residual fluid will limit CT colonography. At CC, residual fluid can be endoscopically aspirated from the colon. With CT colonography, the examination is typically limited to only two acquisitions (which are supine and prone). While supine and prone imaging allow for fluid redistribution, this does not ensure full mucosal evaluation if a large amount of fluid is present. Thus, for CT colonography, the preparation that provides the least amount of residual fluid will theoretically allow the evaluation of the entire mucosal surface.[2,3]

Phosphosoda is contraindicated in patients with known renal failure, preexisting electrolyte abnormalities, congestive heart failure, ascites, or ileus. [2,34] In these circumstances, PEG can be used as an alternative, as it does not result in fluid shifts and electrolyte imbalances. [3,35]

The Fleet Kit consists of a clear fluid diet the day before the examination, as well as a single 45-mL dose of phosphosoda and four bisacodyl tablets the day before the examination. In addition, patients receive a bisacodyl suppository the morning of the examination. The LoSo preparation consists of magnesium citrate and four bisacodyl tablets the day before the examination and a bisacodyl suppository the morning of the examination.[3]

The addition of oral contrast agents will tag residual stool or fluid (Figure 2). Oral contrast agents for stool and fluid tagging consist of meglumine diatrizoate (Gastrografin, Schering AG, Berlin, Germany) and a barium sulfate suspension (Tagitol, E-Z-EM, Lake Success, NY, USA).[6]

The resulting higher attenuation of fecal and fluid residues simplifies their distinction from colonic abnormality. Whereas some authors prefer tagging with barium only, others have reported good results with iodine or a combination of both to achieve fecal and fluid tagging.[2,36-38]

4.2 Bowel distention

Optimal colonic distention is a fundamental prerequisite for CT colonography data evaluation that allows intraluminal evaluation of the large bowel. Underdistended or collapsed segments may hide intraluminal lesions.[2]

Immediately before data acquisition, the patient should evacuate any residual fluid from the rectum. For colonic insufflations, either room air or carbon dioxide (CO₂) can be used. The easiest and cheapest method is manual room air distention via a handheld plastic bulb insufflators. Proponents of CO₂ use argue that its readily absorbance from the colon causes

less cramping after the procedure than does room air insufflations. [3,39] Bowel distention is performed in the left decubitus or supine position with a thin, flexible rubber catheter placed in the rectum (e.g., thin plastic or rubber 14F rectal tube, small gauge Foley catheter).[2,40] During the gas insufflation, gentle insufflation is continuous until the patient feels uncomfortable or bloated. Patients are encouraged to keep the gas (room air or CO₂) in as much as possible. The patient is asked to let the technologist know when they begin to feel uncomfortable. Generally this signals that the colon is well distended. If the ileocecal section is incompetent, more gas will be required for optimal distention.[2,3]

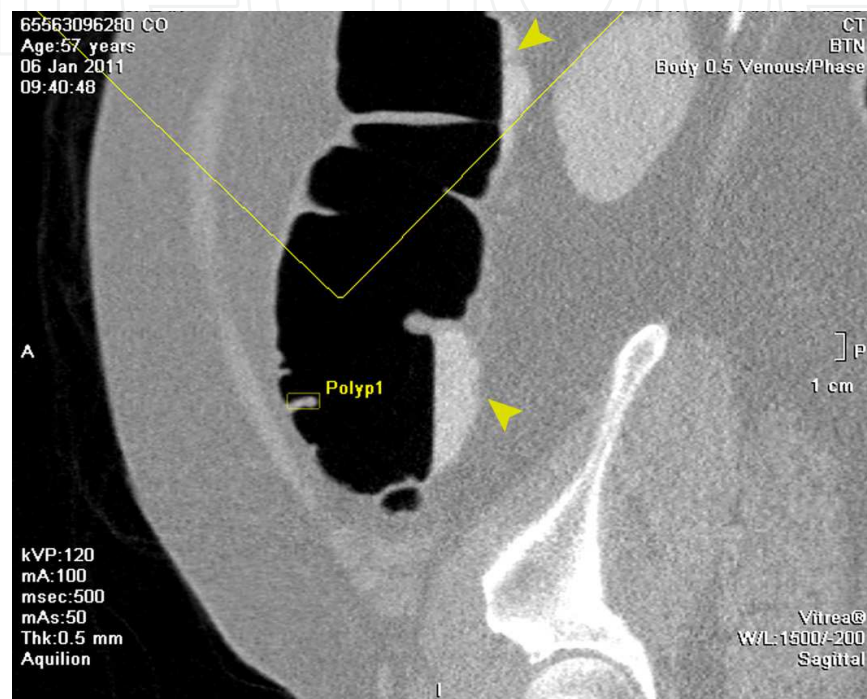


Fig. 2. Fecal tagging with orally ingested barium: 2D sagittal CT colonographic image shows high attenuation of contrast marked fecal residuals and residual fluid (arrowheads), as well as a polyp in the ascending colon.

CO₂ can be administered either manually, over a standard enema bag filled with approximately 3L of gas (via a gas cylinder) attached to a rectal catheter over a connecting tube, or automatically, using a dedicated insufflations device (Protocol colon insufflations system, EZ-Em Inc., Wesbury, NY, USA). This device electronically controls the flow rate of CO₂, the total administered gas volume, and the intracolonic pressure (which is limited up to a maximum of 25 mmHg).[2,41,42] This generally will take 2-4L of gas, depending on the patient's individual colonic anatomy.[2]

After distention, the catheter is left in the rectum, and a single scout CT image is obtained with the patient in the supine position to verify adequate bowel distention (Figure 3). If adequate bowel distention is present, the CT examination is performed. Otherwise, additional gas is insufflated into the rectum, according to the scout image. Following the supine axial image acquisition, the patient is turned to the prone position. Several additional puffs of air are then administered, or CO₂ is continuously administered. After a second scout localizing image is obtained, the process is repeated over the same z-axis range. Supine and prone imaging doubles the radiation dose but is essential to allow optimal

bowel distention, redistribution of residual fluid, and differentiation of fecal material from polyps because visualization of mobility of a filling defect implies residual fecal material.[3] Before prone image acquisition, another scout scan is obtained with additional gaseous insufflation if needed.[2,3]

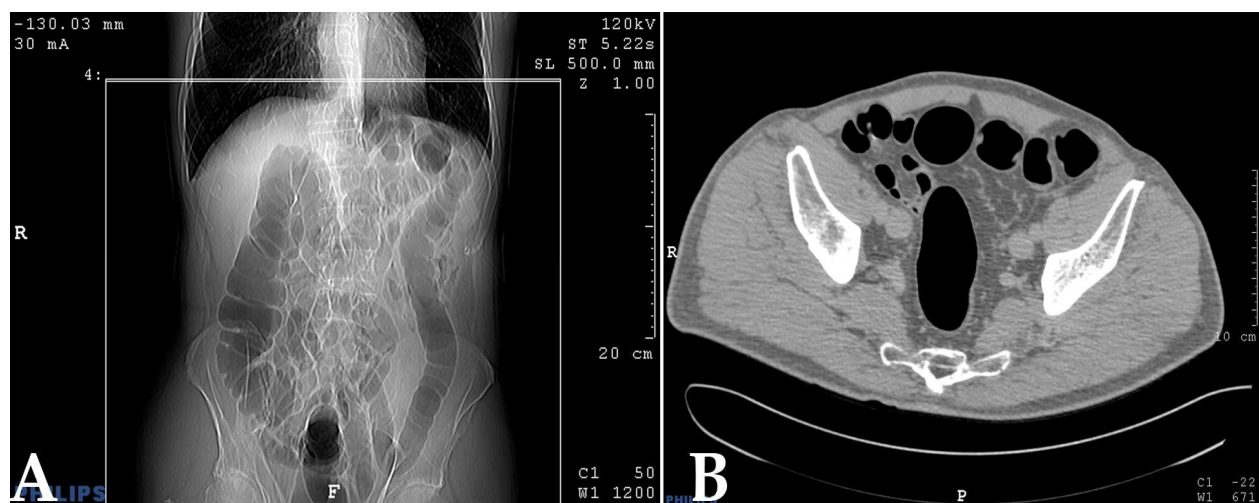


Fig. 3. (A) Supine scout CT image and (B) 2D transverse CT colonographic image show adequate distension of colonic segments, allowing diagnostic examination.

The i.v. administration of antispasmodic agents (buscopan, or glucagon) may improve colonic distention and reduce spasms. The general opinion is that IV spasmolytics should not be administered routinely, but can be used if patients experience pain, discomfort, or spasm.[2,43]

Bowel distention may lead to perforation of the bowel in rare cases. In most of the reported cases, perforation occurred in symptomatic patients with acute inflammatory or stenotic colons.[2,30-32]

4.3 Data acquisition

CT scanning is ideally performed on a multi-detector computed tomography (MDCT) scanner in both the supine and the prone positions with a thin collimation. MDCT has several technical advantages over single-detector CT, including faster imaging times, reduced exposure to radiation and acquisition of multiple thin sections with nearly isotropic voxels.[2,3,7,11,22,23,43-46] Moreover, motion artifacts from respiration and peristalsis are decreased or eliminated with MDCT.[3]

Thin sections are a prerequisite for high-quality multiplanar reformations (MPR) and 3D reconstructions. Near-isotropic imaging is already provided on a 4-row MDCT scanner with a detector configuration of 4 mm x 1 mm (minimal slice thickness of 1.25 mm), which allows scanning of abdomen during a 30-s breath-hold. With a 16-row or 64-row MDCT scanner, and a detector configuration of 16 mm x 0.75 mm or 64 mm x 0.6 mm, scanning is completed in 11-12 s or 6-7 s. Such datasets can be reconstructed as 1 mm sections overlapped every 0.7 mm.[2]

One of the major limitations of CT colonography is the relatively high radiation exposure, and thus, increasing attention has been focused on low-dose protocols. Because a thin collimation is necessary for CT colonography, dose reduction is widely achieved by

reducing the miliampere-seconds level. Generally useful exposure settings are 120kVp and 50-100mAs in the prone and in supine positions.[2] Use of automated dose modulation techniques that adapt mAs values to patient anatomy should always be used, if these techniques are available on the CT scanner.[2,47]

4.4 Data analysis

Image processing and interpretation is performed on a commercially available computer workstation equipped with dedicated CT colonography software. In addition to 2D axial and MPR in a cine mode, such systems provide an interactive, manual, mouse-driven, automated or semi-automated, virtual “fly-trough” of the surface- or volume-rendered 3D intraluminal images.[2]

There are two primary techniques for data interpretation: a primary 2D or a primary 3D approach (Figure 4). The combined use of both, 2D and 3D visualization techniques has been shown to be superior to the evaluation of single 3D or 2D views, with regard to sensitivity and specificity.[2,48,49]

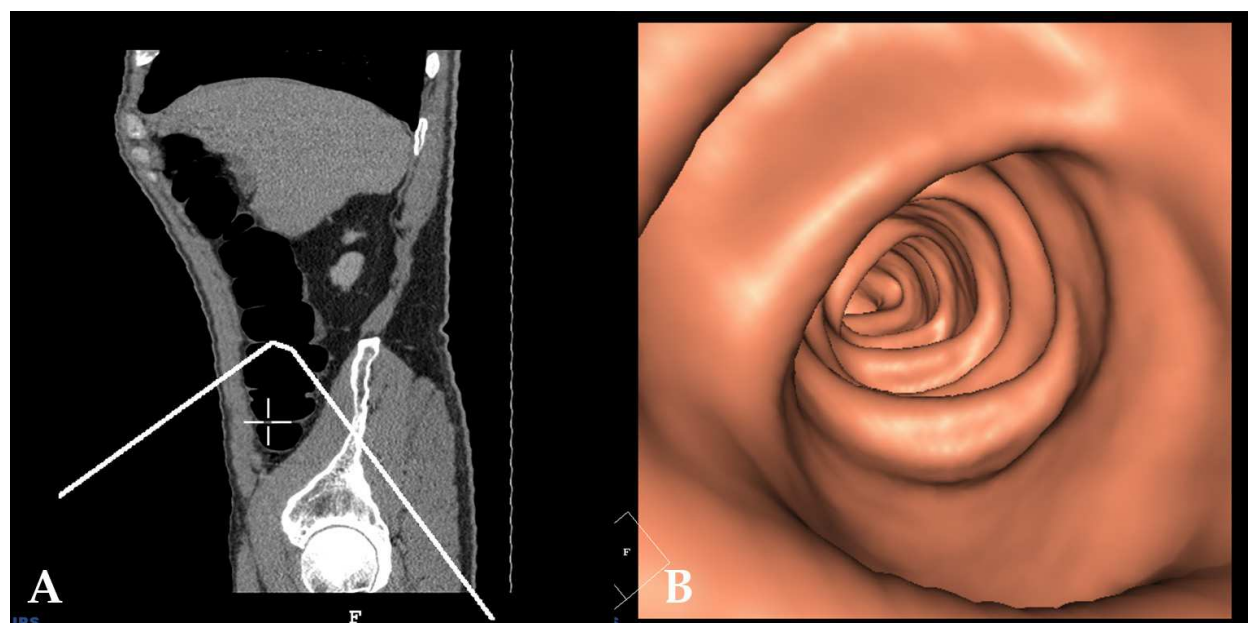


Fig. 4. (A) 2D sagittal CT colonographic image and (B) 3D CT colonographic image show a normal smooth colonic wall.

With a primary 2D technique, the entire colon is evaluated by using the transverse source images. This is accomplished at a specialized workstation, and the colon is “tracked” from the rectum to the cecum by using the supine images. This is facilitated by cine scrolling of images through the entire colon. If an abnormality is detected; coronal, sagittal, and endoluminal reformatted images are used to help determine whether the abnormality is a polyp, fold, or fecal matter.[3] Primary 2D evaluation provides information about the attenuation of findings during the search process and is more time-efficient.[2,48,50]

Primary 3D evaluation is based on 3D virtual endoscopy in an antegrade and retrograde fashion. Primary 3D evaluation was shown to be sensitive for polyp detection because both, the conspicuity, especially of small and medium-sized polyps, and the duration of visualization, are increased.[2,38] The primary 3D evaluation is time-consuming because it

must be performed in antegrade and retrograde fashion for the perception of lesions behind haustral folds. Collapsed segments must be evaluated alternatively, by 2D planar images.[2] There are several limitations of the primary 3D evaluation. First, there are blind spots in the colon when 3D endoluminal views are used.[3,51] Several workstations currently have the capacity to display these blind areas to the reviewer after the 3D navigation is performed, which should allow a more complete visualization of the colon when a primary 3D interpretation technique is used. These are virtual dissection, panoramic, unfolded cube projection, and translucency rendering.[2,3,51] A second limitation of 3D endoluminal fly-through imaging is that the centerline cannot be generated when segments of the colon are not well distended. Third, in over-distended segments the centerline may jump to an adjacent distended loop.[3]

In addition to polyp size, segmental location, morphologic type (pedunculated, sessile, or flat), and diagnostic confidence score are recorded for each polyp.[52] For a number of reasons, the presence of diminutive lesions should not be mentioned. Tiny polyps are not clinically relevant, yet mentioning them can cause undue anxiety in patients and referring physicians.[38,52-54] Most diminutive “lesions” detected at CT colonography cannot be found at subsequent CC, representing either false-positive CT colonography findings or false-negative CC findings.[52]

There are three criteria to use with 2D and 3D imaging that help distinguish residual fecal material from polyps. First, the presence of internal gas or areas of high attenuation suggest that a lesion is residual fecal material, since colorectal polyps are homogeneous in attenuation.[3,55,56] The second criterion is morphology. Morphologically, polyps and small cancers have rounded or lobulated smooth borders. Residual fecal material may have a similar morphology. However, if a lesion shows geometric or irregularly angled borders, it almost always represents residual fecal material.[3,50] Mobility of a lesion is the third criterion. Stool tends to move to the dependent surface of the colonic mucosa when a patient is turned from the supine to the prone position.[3,56,57] Polyps maintain their position with respect to the bowel surface (ventral or dorsal) regardless of the patient’s position. However, caution is required since pedunculated polyps and sessile polyps in segments of the colon with a long mesentery appear to be mobile.[3,58]

Computer-aided detection (CAD) systems are software programs that automatically highlight polyp “candidates” and thus support the radiologist by pointing out possible abnormalities that may otherwise have been missed. Based on morphologic and attenuation characteristics, the reader then decides whether the “candidate lesion” is a true- or a false-positive finding. Recent CAD algorithms showed a promising performance, with a reported a CAD sensitivity of 89,3% for adenomas ≥ 10 mm.[2,59]

5. Findings

One of the most common findings detected with CT colonography is diverticular disease. On 2D CT colonography images (Figure 5A), diverticula appear as air-filled outpouchings of the colonic wall. On the 3D virtual endoscopic images (Figure 5B), the diverticular orifice can be recognized as a complete dark ring.[2,60]

Polyps are the most common benign lesions of the colon. The risk of malignant transformation increases with the size of the polyp. On 2D plane images (Figure 6A and 6C), polyps have homogenous, soft tissue attenuation. On 3D virtual endoscopic images (Figure 6B and 6D), polypoid lesions present as a sessile or stalked, round, oval, or lobulated

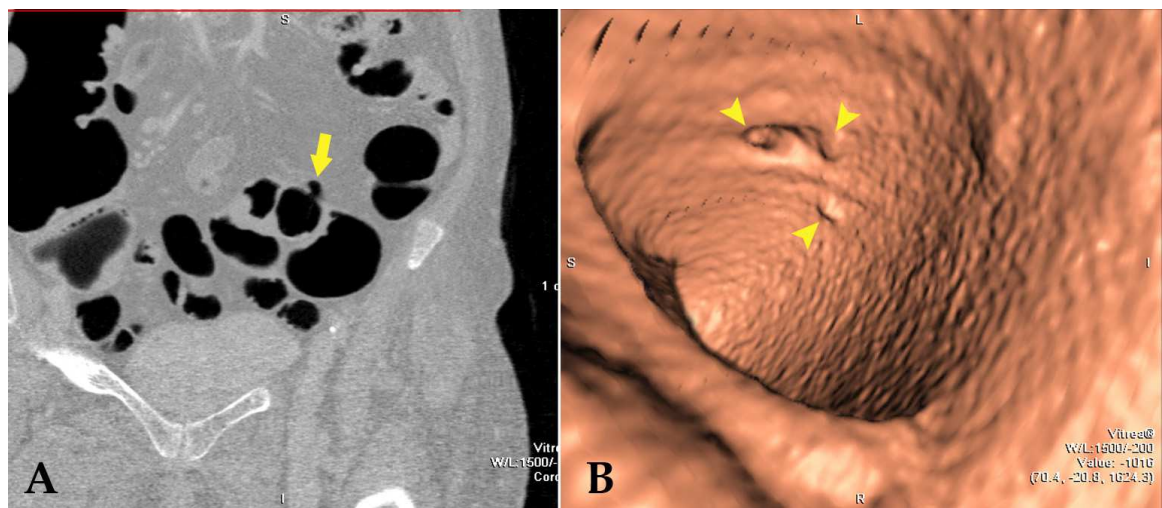


Fig. 5. The appearance of diverticula on (A) the 2D axial CT colonographic image (arrow) and (B) the 3D CT colonographic image (arrowheads).

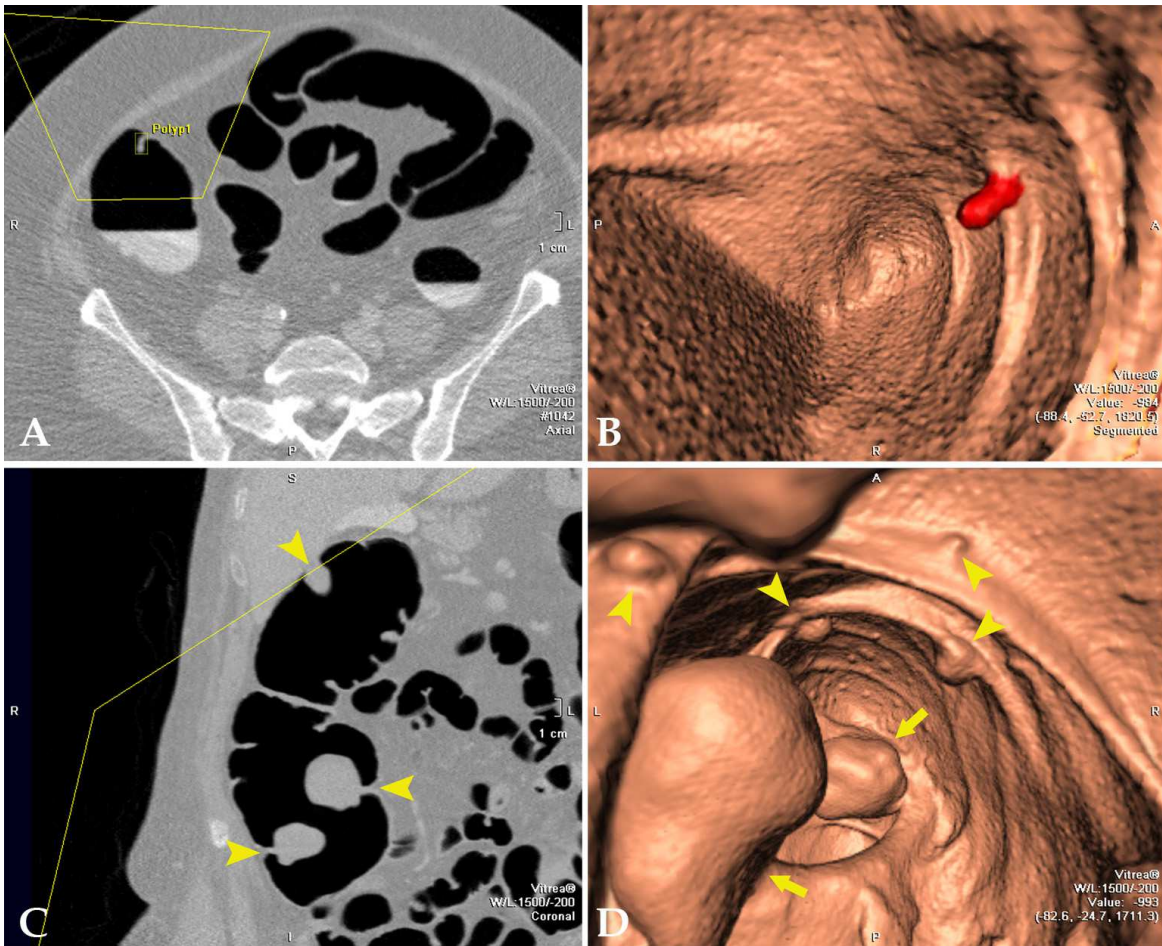


Fig. 6. (A) The appearance of a stalked polyp of the ascending colon on 2D axial CT colonographic image. (B) Translucency rendering view shows a homogenous red bulging revealing the polyp. (C) The appearance of stalked polyps on 2D coronal CT colonographic image (arrowheads). (D) 3D CT colonographic image shows stalked (arrows) and sessile (arrowheads) polyps.

intraluminal filling defect. Typically, the margin to the normal mucosa is displayed as an incomplete ring shadow.[2,61] Flat polyps are defined as lesions with a height less than 50% of the lesion width. In CT colonography, flat polyps appear as a fairly circumscribed area of mild wall thickening with homogenous soft tissue attenuation. Sometimes a mild nodularity is found on the surface by 3D endoluminal images.[2,62]

Lipomas are the most common submucosal lesions in the colon (especially common on the ileocecal valve). On 2D plane images, lipomas are present as homogenous fatty lesions. On 3D virtual endoscopic images, lipomas are present as a sessile or pedunculated polypoid intraluminal filling defect, most often with a smooth surface. In general, small lipomas need no further treatment; only large lipomas require endoscopic resection because they can lead to intussusception.[2,61]

Colorectal cancer is the most common colonic primary tumour. Colorectal cancer(Figure 7) typically shows extensive focal polypoid, asymmetric, or circular wall thickening with short extension (<5cm), especially with shoulder formation.[2,60,63] Pericolic lymph nodes and distant metastases are signs of progression of the disease and can be evaluated using 2D axial source images and MPR views.[2]

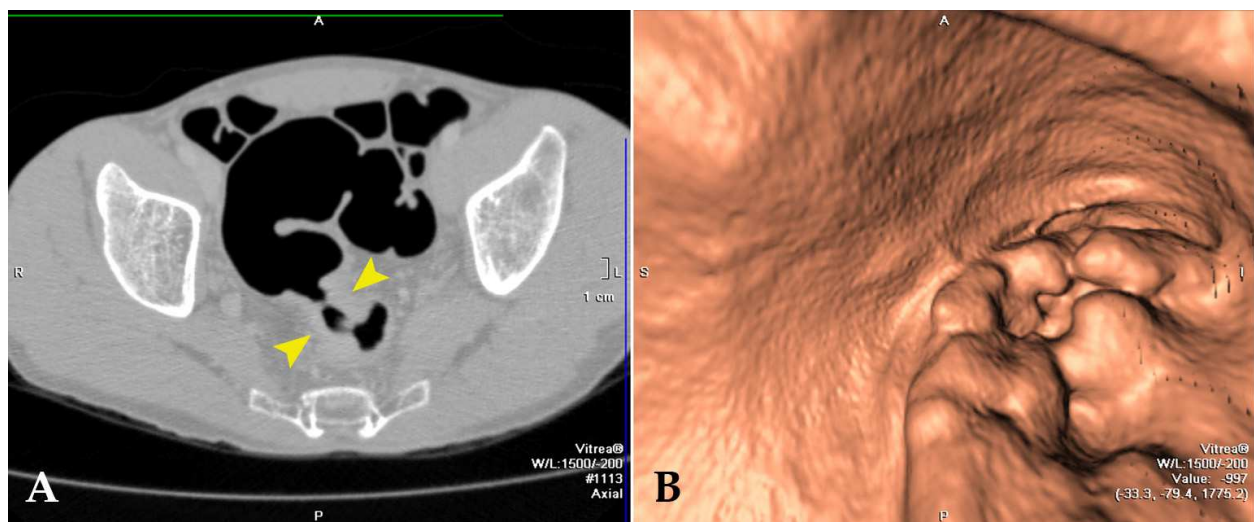


Fig. 7. (A) 2D axial CT colonographic image shows circular wall thickening in the rectum (arrowheads). (B) 3D CT colonographic image shows an irregular, circular, stenotic filling defect.

6. Pitfalls

CT colonography has a number of potential pitfalls. Some pitfalls, such as prominent and complex folds, diverticular fold thickening, and shifting of pedunculated polyps, present more of a problem at 2D evaluation. Other pitfalls, such as annular masses, submucosal or extrinsic lesions, and impacted diverticula, are more an issue at 3D evaluation. With a biphasic interpretive approach, most pitfalls are easily recognized because of the complementary nature of the 2D and 3D displays.[52]

7. Conclusion

CT colonography is highly sensitive for colorectal cancer, especially when both cathartic and tagging agents are combined in the bowel preparation. Given the relatively low prevalence of colorectal cancer, primary CT colonography may be more suitable than CC for initial investigation of suspected colorectal cancer.

8. References


- [1] De Wijkerslooth TR, de Haan MC, Stoop EM, Deutekom M, Fockens P, Bossuyt PM, Thomeer M, van Ballegooijen M, Essink-Bot ML, van Leerdam ME, Kuipers EJ, Dekker E, Stoker J. Study protocol: population screening for colorectal cancer by colonoscopy or CT colonography: a randomized controlled trial. *BMC Gastroenterol* 2010; 10:47.
- [2] Mang T, Graser A, Schima W, Maier A. CT colonography: techniques, indications, findings. *EJR* 2007; 61:388-99.
- [3] Macari M, Bini EJ. CT colonography: where have we been and where are we going? *Radiology* 2005; 237:819-33.
- [4] Silva AC, Hara AK, Leighton JA, Heppell JP. CT colonography with intravenous contrast material: varied appearances of colo-rectal carcinoma. *Radiographics* 2005; 25(5):1321-34.
- [5] Svensson MH, Svensson E, Lasso A, Hellstrom M. Patient acceptance of CT colonography and conventional colonoscopy; prospective comparative study in patients with or suspected of having colorectal disease. *Radiology* 2002; 222:337-45.
- [6] Silva AC, Vens EA, Hara AK, Fletcher JG, Fidler JL, Johnson CD. Evaluation of benign and malignant rectal lesions with CT colonography and endoscopic correlation. *Radiographics* 2006; 26(4):1085-99.
- [7] Mulhall BP, Veerappan GR, Jackson Jeffrey. Meta-analysis: computed tomographic colonography. *Annals of Internal Medicine* 2005; 142(8):635-50.
- [8] Vining DJ, Gelfand DW, Bechtold RE, Scharling ES, Grishaw EK, Shifrin GY. Technical feasibility of colon imaging with helical CT and virtual reality (Abstract). *Am J Roentgenol* 1994; 162 (Suppl):S104.
- [9] Geenen RW, Hussain SM, Cademartiri F, Poley JW, Siersema PD, Shifrin GP. CT and MR colonography: scanning techniques, postprocessing, and emphasis on polyp detection. *Radiographics* 2004; 24:e18.
- [10] Dachman AH, Yoshida H. Virtual colonoscopy; past, present, and future. *Radiol Clin North Am* 2003; 41:377-93.
- [11] Laghi A, Lannaccone R, Panebianco V, Carbone L, Passariello R. Multislice CT colonography: technical developments. *Semin Ultrasound CT MR*. 2001; 22: 425-31.
- [12] Mang T, Maier A, Plank C, Mueller-Mang C, Herold C, Schima W. Pitfalls in multi-detector row CT colonography: a systematic approach. *Radiographics* 2007; 27:431-54.
- [13] Pickhardt PJ, Hassan C, Halligan S, Marmo R. Colorectal Cancer: CT Colonography and colonoscopy for detection--systematic review and meta-analysis (Abstract). *Radiology* 2011 Mar 17 [Epub ahead of print].

- [14] Filippone A, Ambrosini R, Fuschi M, Marinelli T, Genovesi D, Bonomo L. Preoperative T and N staging of colorectal cancer: accuracy of contrast-enhanced multi-detector row CT colonography-initial experience. *Radiology* 2004; 231: 83-90.
- [15] Fenlon HM, McAneny DB, Nunes DP, Clarke PD, Ferrucci JT. Occlusive colon carcinoma: virtual colonoscopy in the preoperative evaluation of the proximal colon. *Radiology* 1999; 210:423-28.
- [16] Macari M, Berman P, Dicker M, Milano A, Megibow AJ. Usefulness of CT colonography in patients with incomplete colonoscopy. *AJR Am J Roentgenol* 1999; 173:561-64.
- [17] Morrin MM, Farrell RJ, Raptopoulos V, MacGee JB, Bleday R, Kruskal JB. Role of virtual computed tomographic colonography in patients with colorectal cancers and obstructing colorectal lesions. *Dis Colon Rectum* 2000; 43:303-11.
- [18] Morrin MM, Kruskal JB, Farrell RJ, Goldberg SN, McGee JB, Raptopoulos V. Endoluminal CT colonography after an incomplete endoscopic colonoscopy. *AJR Am J Roentgenol* 1999; 172: 913-18.
- [19] Neri E, Giusti P, Battolla L, Vagli P, Boraschi, R, Caramella D, Bartolozzi C. Colorectal cancer: role of CT colonography in preoperative evaluation after incomplete colonoscopy. *Radiology* 2002; 223:615-19.
- [20] Laghi A. Virtual colonoscopy: clinical application. *Eur Radiol* 2005; 15 (Suppl 4):D138-41.
- [21] Chung DJ, Huh KC, Choi WJ, Kim JK. CT colonography using 16-MDCT in the evaluation of colorectal cancer. *AJR Am J Roentgenol* 2005; 184:98-103.
- [22] Filippone A, Ambrosini R, Fuschi M, Marinelli T, Genovesi D, Bonomo L. Preoperative T and N staging of colorectal cancer: accuracy of contrast-enhanced multi-detector row CT colonography-initial experience. *Radiology* 2004; 231: 83-90.
- [23] Iannacone R, Laghi A, Passariello R. Colorectal carcinoma: detection and staging with multislice CT (MSCT) colonography. *Abdom Imaging* 2005; 30:13-19.
- [24] Fletcher JG, Johnson CD, Krueger WR, Ahlquist DA, Nelson H, Ilstrup D, Harmsen WS, Corcoran KE. Contrast-enhanced CT colonography in recurrent colorectal carcinoma: feasibility of simultaneous evaluation of metastatic disease, local recurrence, and metachronous neoplasia in colorectal carcinoma. *AJR Am J Roentgenol* 2002; 178(2):283-90.
- [25] Laghi A, Iannaccone R, Bria E, Carbone I, Trasatti L, Piacentini F, Lauro S, Vecchione A, Passariello R. Contrast-enhanced computed tomographic colonography in the follow-up colorectal cancer patients: a feasibility study. *Eur Radiol* 2003; 13(4):883-9.
- [26] Biaecone L, Fiori R, Tosti C, Marinetti A, Catarinacci M, De Nigris F, Simonetti G, Pallone F. Virtual colonoscopy compared with conventional colonoscopy for structuring postoperative recurrence in Crohn's disease. *Inflamm Bowel Dis* 2003; 9(6):343-50.
- [27] Tarjan Z, Zagoni T, Gyorke T, Mester A, Karlinger K, Mako EK. Spiral CT colonography in inflammatory bowel disease. *Eur J Radiol* 2000; 35:193-8.
- [28] Ota Y, Matsui T, Ono H, Uno H, Mataka H, Tsuda S, Sakurai T, Yao T. Value of virtual computed tomographic colonography for Crohn's colitis: comparison with endoscopy and barium enema. *Abdom Imaging* 2003; 28:778-83.

- [29] Saglam M, Ors F, Nikola S, Yildirim D, Tasar M, Tuzun A, Bozlar U. Sonographic and multidetector computed tomographic findings of 6 cases with inflammatory bowel disease. *Gulhane Med J* 2007; 49:129-31.
- [30] Burling D, Halligan S, Slater A, Noakes MJ, Taylor SA. Potentially serious adverse events at CT colonography in symptomatic patients: national survey of the United Kingdom. *Radiology* 2006; 239:464-41.
- [31] Pickhardt PJ. Incidence colonic perforation at CT colonography: review of exiting data and implications for screening of asymptomatic adults. *Radiology* 2006; 239:313-6.
- [32] Sosna J, Blachar A, Amitai M, Barmeir E, Peled N, Goldberg SN, Bar-Ziv J. Colonic perforation at CT colonography: assessment of risk in a multicenter large cohort. 2006; 239(2):457-63.
- [33] Macari M, Pedrosa I, Lavelle M, Milano A, Dicker M, Megibow AJ, Xue X. Effect of different bowel preparations on residual fluid at CT colonography. *Radiology* 2001;218(1):274-7
- [34] Fass R, Do S, Hixson LJ. Fatal hyperphosphatemia following Fleet Phospho-Soda in a patient with colonic ileus. *Am J Gastroenterol* 1993; 88:929-32.
- [35] Macari M, Bini EJ, Jacobs SL, Lui YW, Laks S, Milano A, Babb J. Clinical significance of missed polyps at CT colonography. *AJR Am J Roentgenol* 2004; 183(1):127-34.
- [36] Lefere PA, Gryspeerdt SS, Dewyspelaere J, Baekelandt M, Van Holsbeeck BG. Dietary fecal tagging as a cleansing method before CT colonography: initial results polyp detection and patient acceptance. *Radiology* 2002; 224:393-403.
- [37] Iannaccone R, Laghi A, Cataalano C, Mangiapane F, Lamazza A, Schillaci A, Sinibaldi G, Murakami T, Sammartino P, Hori M, Piacentini F, Nofroni I, Stipa V, Passariello R. Computed tomographic colonography without cathartic preparation for the detection of colorectal polyps. *Gastroenterology* 2004; 127(5):1300-11.
- [38] Pickhardt PJ, Choi JR, Hwang I, Schindler WR. Computed tomographic virtual colonoscopy to screen for colorectal neoplasia in asymptomatic adults. *N Eng J Med* 2003; 349(23):2191-200.
- [39] Stevenson GW, Wilson JA, Wilkinson J, Norman G, Goodacre RL. Pain following colonoscopy: elimination with carbon dioxide. *Gastrointest Endosc* 1992; 38:564-7.
- [40] Dachman AH. Advice for optimizing colonic distention and minimizing risk of perforation during CT colonography. *Radiology* 2006; 239:317-21.
- [41] Burling D, Taylor SA, Halligan S, Gartner L, Paliwalla M, Peiris C, Singh L, Bassett P, Bartram C. Automated insufflations of carbon dioxide for MDCT colonography: distention and patient experience compared with manual insufflations. *AJR Am J Roentgenol* 2006; 186(1):96-103.
- [42] Shinnars TJ, Pickhardt PJ, Taylor AJ, Jones DA, Olsen CH. Patient-controlled room air insufflations versus automated carbon dioxide delivery for CT colonography. *AJR Am J Roentgenol* 2006; 186:1491-6.
- [43] Rogalla P, Meiri N, Ruckert JC, Hamm B. Colonography using multislice CT *Eur J Radiol* 2000; 36:81-5.
- [44] Wessling J, Fischbach R, Meier N, Allkemper T, Klusmeier J, Ludwig K, Heindel W. CT colonography: protocol optimization with multi-detector row CT-study in an anthropomorphic colon phantom. *Radiology* 2003; 228(3):753-9.

- [45] Taylor SA, Halligan S, Bartram CI, Morgan PR, Talbot IC, Fry N, Saunders BP, Khosraviani K, Atkin W. Multi-detector row CT colonography: effect of collimation, pitch, and orientation on polyp detection in a human colectomy specimen. *Radiology* 2003; 229(2):109-18.
- [46] Taylor Sa, Halligan S, Saunders BP, Morley S, Riesewyk C, Atkin W, Bartram CI. Use of multidetector-row CT colonography for detection of colorectal neoplasia in patients referred via the department of health "2-week-wait" initiative. *Clin Radiol* 2003; 58(11):855-61.
- [47] Craser A, Wintersperger BJ, Suess C, Reiser MF, Becker CR. Dose reduction and image quality in MDCT colonography using the current modulation. *AJR Am J Roentgenol* 2006; 187:695-701.
- [48] Dachman AH, Kuniyoshi JK, Boyle CM, Samara Y, Hoffmann KR, Rubin DT, Hanan I. CT colonography with three-dimensional problem solving for detection of colonic polyps. *AJR Am J Roentgenol* 1998; 171(4):989-95.
- [49] Royster AP, Fenlon HM, Clarke PD, Nunes DP, Ferruci JT. CT colonoscopy of colorectal neoplasms: two-dimensional and three-dimensional virtual-reality techniques with colonoscopic correlation. *AJR Am J Roentgenol* 1998; 169:1237-42.
- [50] Macari M, Milano A, Lavelle M, Berman P, Megibow AJ. Comparison of time-efficient CT colonography with two-three-dimensional colonic evaluation for detecting colorectal polyps. *AJR Am J Roentgenol* 2000; 174:1543-9.
- [51] Beaulieu Cf, Jeffrey RB, Karadi C, Paik DS, Napel S. Display modes for CT colonography. II. Blinded comparison of axial CT and virtual endoscopic and panoramic endoscopic volume-rendered studies. *Radiology* 1999; 212(1):203-12.
- [52] Pickhardt PJ. Screening CT colonography: how I do it. *AJR Am J Roentgenol* 2007; 189:290-8.
- [53] Zalis ME, Barish MA, Choi JR, Dachman AH, Fenlon HM, Ferrucci JT, Glick SN, Laghi A, Macari M, McFarland EG, Morrin MM, Pickhardt PJ, Soto J, Yee J. CT colonography reporting and data system: a consensus proposal. *Radiology* 2005; 236(1):3-9.
- [54] Pickhardt PJ. CT colonography (virtual colonoscopy) for primary colorectal screening: challenges facing clinical implementation. *Abdom Imaging* 2005; 30:1-4.
- [55] Macari M, Megibow AJ. Pitfalls of using three dimensional CT colonography with two dimensional imaging correlation. *AJR Am J Roentgenol* 2001; 176:137-43.
- [56] Fletcher JG, Johnson CD, MacCarty RL, Welch TJ, Reed JE, Hara AK. CT colonography: potential pitfalls and problem solving techniques. *AJR Am J Roentgenol* 1999; 172:1271-8.
- [57] Yee J, Kumar NN, Hung RK, Akekar GA, Kumar PR, Wall SD. Comparison of supine and prone scanning separately and in combination at CT colonography. *Radiology* 2003; 226(3):653-61.
- [58] Laks S, Macari M, Bini EJ. Positional change in colon polyps at CT colonography. *Radiology* 2004; 231(3):761-6.
- [59] Summers RM, Yao J, Pickhardt PJ, Franaszek M, Bitter I, Brickman D, Krishna V, Choi JR. Computed tomographic virtual colonoscopy computer-aided polyp detection in a screening population. *Gastroenterology* 2005; 129:1832-44.

- [60] Fenlon HM, Clarke PD, Ferrucci JT. Virtual colonoscopy: imaging features with colonoscopic correlation. *AJR Am J Roentgenol* 1998; 170:1303-9.
- [61] Macari M, Bini EJ, Jacobs SL, Lange N, Lui YW. Filling defects at CT colonography: pseudo- and diminutive lesions (the good), polyps (the bad), flat lesions, masses, and carcinomas (the ugly). *Radiographics* 2003; 23:1073-91.
- [62] Rembacken BJ, Fujii T, Cairns A, Dixon MF, Yoshida S, Chalmers DM, Axon AT. Flat and depressed colonic neoplasms: a prospective study of 1000 colonoscopies in the UK. *Lancet* 2000; 355:1211-4.
- [63] Taylor SA, Halligan S, Bartram CI. CT colonography: methods, pathology and pitfalls. *Clin Radiol* 2003; 58:179-90.



Endoscopic Procedures in Colon and Rectum

Edited by Prof. Jose Ribeiro Da Rocha

ISBN 978-953-307-677-5

Hard cover, 156 pages

Publisher InTech

Published online 07, November, 2011

Published in print edition November, 2011

Endoscopic procedures in colon and rectum presents nine chapters which start with introductory ones like screening by colonoscopy as the preparation and monitoring for this exam. In addition to these approaches the book aims in the last four chapters to explain endoscopic diagnostic and therapeutic aspects in the colon and rectum. The description of each text is very comprehensive, instructive and easy to understand and presents the most current practices on the topics described. This book is recommended for general and colorectal surgeons as it presents guidelines for diagnosis and treatment which are very well established.

How to reference

In order to correctly reference this scholarly work, feel free to copy and paste the following:

Mutlu Saglam and Fatih Ors (2011). Virtual Colonoscopy: Indications, Techniques, Findings, Endoscopic Procedures in Colon and Rectum, Prof. Jose Ribeiro Da Rocha (Ed.), ISBN: 978-953-307-677-5, InTech, Available from: <http://www.intechopen.com/books/endoscopic-procedures-in-colon-and-rectum/virtual-colonoscopy-indications-techniques-findings>

INTECH
open science | open minds

InTech Europe

University Campus STeP Ri
Slavka Krautzeka 83/A
51000 Rijeka, Croatia
Phone: +385 (51) 770 447
Fax: +385 (51) 686 166
www.intechopen.com

InTech China

Unit 405, Office Block, Hotel Equatorial Shanghai
No.65, Yan An Road (West), Shanghai, 200040, China
中国上海市延安西路65号上海国际贵都大饭店办公楼405单元
Phone: +86-21-62489820
Fax: +86-21-62489821

© 2011 The Author(s). Licensee IntechOpen. This is an open access article distributed under the terms of the [Creative Commons Attribution 3.0 License](https://creativecommons.org/licenses/by/3.0/), which permits unrestricted use, distribution, and reproduction in any medium, provided the original work is properly cited.

IntechOpen

IntechOpen