

# We are IntechOpen, the world's leading publisher of Open Access books Built by scientists, for scientists

6,900

Open access books available

186,000

International authors and editors

200M

Downloads

Our authors are among the

154

Countries delivered to

TOP 1%

most cited scientists

12.2%

Contributors from top 500 universities



WEB OF SCIENCE™

Selection of our books indexed in the Book Citation Index  
in Web of Science™ Core Collection (BKCI)

Interested in publishing with us?  
Contact [book.department@intechopen.com](mailto:book.department@intechopen.com)

Numbers displayed above are based on latest data collected.  
For more information visit [www.intechopen.com](http://www.intechopen.com)



# Severe Cutaneous Adverse Reactions

Suran Fernando  
Sydney University  
Australia

## 1. Introduction

Severe cutaneous adverse reactions (SCARs) are generally induced by drugs and encompass the conditions of Stevens-Johnson syndrome (SJS) and toxic epidermal necrolysis (TEN), drug induced eosinophilia and systemic syndrome (DRESS) also known as drug induced hypersensitivity syndrome (DIHS), and acute generalized exanthematous pustulosis (AGEP). These conditions, although rare, cause significant morbidity and are potentially fatal. It is therefore important for the treating physician to promptly recognize SCARs through the identification of their characteristic clinical features so that the offending drug is promptly withdrawn and supportive and adjunctive therapies are administered. SCARs are accompanied by particular abnormalities on routine laboratory investigations and skin biopsy that enables confirmation of the diagnosis and provision of useful prognostic information. Data bases have been established, predominantly in Europe, since the 1980s to characterize the epidemiology of SCARs including the identification of drugs with the highest relative risk and the latency between the commencement of drug intake and the onset of clinical manifestations. The pathogenesis of the various SCARs involves delayed T cell-mediated inflammation in a genetically predisposed individual and in the case of DIHS, may involve viral factors. The emerging field of the genetic susceptibility to SCARs has raised the important issue of pharmacogenetic screening as a method of predicting an individual's risk of developing SCAR to a certain drug.

## 2. Stevens-Johnson syndrome/toxic epidermal necrolysis

### 2.1 History and nosology

Stevens-Johnson syndrome (SJS) and toxic epidermal necrolysis (TEN) were once considered as variants of erythema multiforme (EM), a condition first described by Ferdinand von Hebra in 1860 as a mild and relapsing eruption of target lesions affecting the acral regions. Mucosal involvement occurs in up to 70 % of cases of EM. In 1922, Albert Stevens and Frank Johnson described two cases of fever, stomatitis, purulent conjunctivitis, and a generalized eruption of purple papules in boys aged 7 and 8 years, respectively (Stevens and Johnson 1922). Both cases were distinguished from EM by the prolonged high fever, and the generalized distribution and heavy terminal crusting of the skin lesions. Bernard Thomas proposed two categories of EM in 1950: erythema multiforme minor, as described by von Hebra, and erythema multiforme major, a severe form that encompassed SJS (Thomas 1950). Alan Lyell termed the condition toxic epidermal necrolysis (TEN) after reporting four cases of an acute life threatening mucocutaneous disorder characterized by diffuse erythema

followed by extensive epidermal detachment manifesting as blistering and sloughing of the skin (Lyell 1956). Although SJS and TEN were initially considered distinct entities, it was later proposed that they form a continuum along the same disease process and differ mainly in the extent of involvement. It was also proposed that EM major and SJS are distinct conditions, with EM major characterised by acral target-like lesion typical of EM minor but with mucosal involvement. SJS was applied to cases of mucous membrane involvement and a more extensive eruption of atypical targetoid lesions, blisters or sloughing of the skin (Bastuji-Garin, Rzany et al. 1993). The distinction between EM and SJS are consistent with observations regarding differences in etiology, demography and histopathology and not just confined to variations in the severity of disease. Most cases of EM are related to infection especially those with recurrent disease, which is related to herpes simplex virus (HSV) infection (Ng, Sun et al. 2003) in contrast to SJS which usually is an idiosyncratic reaction to drugs (Mockenhaupt, Viboud et al. 2008). EM typically affects young adults in their 20s and 30s although approximately 20% of cases involve children (Lam, Yang et al. 2004) whereas SJS/TEN occurs at any age (Mockenhaupt, Viboud et al. 2008). Histopathology in EM in contrast to SJS/TEN consists of a denser infiltrate of lymphocytes and less apoptosis of keratinocytes (Cote, Wechsler et al. 1995).

In 1993, a classification scheme was proposed that is widely but not universally adopted that arbitrarily defines SJS and TEN according to the extent of epidermal detachment (Bastuji-Garin, Rzany et al. 1993). In SJS, epidermal loss affects less than 10% of the total body surface area (TBSA) whereas TEN involves greater than 30% of the TBSA. Epidermal detachment between 10 and 30% of the TBSA is classified as SJS/TEN overlap.

## 2.2 Epidemiology

The epidemiology of SJS/TEN and other severe cutaneous adverse reactions (SCARs) has been more accurately determined in recent years due to registries that have been established mainly across Europe comprising cases that are reviewed by expert committees and based on predefined and validated criteria. A population-based registry was commenced in Germany in 1990 to collect all hospitalised cases of SJS, TEN and EM major. An international case-control study was conducted between 1989 and 1995 in France, Germany, Italy and Portugal (SCAR study) focusing on cases of SJS/TEN requiring hospitalisation. A European case-control surveillance study of SCARs (EuroSCAR study) was conducted between 1997 and 2001 in Austria, France, Germany, Israel, Italy, and the Netherlands investigating both SJS/TEN and AGEP that resulted in admission to hospital. In 2003, the European registry on SCARs (RegiSCAR) was commenced collecting biological samples across the same countries that participated in the EuroSCAR study. This network, which is focused on SJS/TEN and AGEP, has spawned numerous studies on epidemiology, pharmacogenetics and histopathology and includes community cases that required hospitalisation as well as cases that developed during hospital admissions. These registries not only provide valuable information on the epidemiology of SCAR but they have enabled close scrutiny of the availability and prescription of high-risk drugs. For example, the SCAR study resulted in the withdrawal of chlormezanone from the market and restricted indications for cotrimoxazole and phenobarbitol (Roujeau 2005).

The incidence of SJS/TEN is 1-2 cases/million inhabitants/year (Rzany, Mockenhaupt et al. 1996). The EuroSCAR study published in 2008 comprised 379 cases that included 134 cases of SJS, 136 cases of SJS/TEN overlap, and 109 cases TEN spanning a geographical area encompassing over a 100 million inhabitants. The median age of cases was found to be 50

years (range 1-95 years), and a female preponderance (62% of cases) was noted (Mockenhaupt, Viboud et al. 2008).

## 2.3 Etiology

### 2.3.1 Drugs

Drugs are nearly always the cause of SJS/TEN. Over 220 medications have been implicated but only relatively a few are responsible for the majority of cases. The EuroSCAR study comprised 379 cases of SJS/TEN and 1505 age-matched controls, who were patients admitted to hospital for other acute illnesses (Mockenhaupt, Viboud et al. 2008). Univariate relative risk (uRR) and multivariate relative risk (mRR) were calculated for each drug suspected of causing SJS/TEN. The drugs found to confer the highest risk were cotrimoxazole (uRR 102), other anti-bacterial sulphonamides (uRR 53), carbamazepine (mRR 72), nevirapine (uRR >22), allopurinol (mRR 18), phenytoin (mRR 17), oxicam-NSAIDs (mRR 16), lamotrigine (uRR >14), and sertraline (mRR 11). Drugs that were found to have a significant but lower risk included acetic acid-NSAIDs, macrolides, quinolones, cephalosporins, tetracyclines and aminopenicillins. SJS/TEN typically occurs with drugs that are taken on a long-term basis. The median latency between the onset of medication use and the occurrence of SJS/TEN in the EuroSCAR study was found to be less than 4 weeks (range 1-8 weeks): carbamazepine 15 days, phenobarbital 17 days, allopurinol 20 days, phenytoin 24 days. Pantoprazole and tramadol were associated with high uRRs, 18 and 20, respectively, but the frequent co-medication with highly suspected drugs and the timing of the onset of SJS/TEN were not suggestive of a true risk. Commonly used medications not associated with a risk of SJS/TEN included beta-blockers, ACE-inhibitors, calcium channel blockers, thiazide diuretics, furosemide, propionic acid-NSAIDs, sulphonylureas, and insulin. Interestingly, valproic acid was not shown to have a significant risk, which is contrast to previous observations (Roujeau, Kelly et al. 1995; Rzany, Correia et al. 1999). The most likely explanation is that valproic acid was frequently coadministered with high-risk drugs.

A pooled analysis of the SCAR and EuroSCAR data was performed for children under 15 years of age and showed that anti-bacterial sulphonamides, phenobarbital, lamotrigine and carbamazepine were strongly associated with SJS/TEN in this paediatric population (Levi, Bastuji-Garin et al. 2009).

### 2.3.2 Other causes

Infection with *Mycoplasma pneumoniae* is a known cause of SJS especially in the paediatric population and a few cases of TEN have been reported to complicate infection with this agent (Lam, Yang et al. 2004). However, the EuroSCAR study, failed to show that infection was a risk factor either on its own although there is a suggestion that it may modestly increase the risk of SJS/TEN from medication. SJS/TEN has been reported in association with vaccinations (Ball, Ball et al. 2001) and exposure to industrial chemicals and fumigants (House, Jakubovic et al. 1992).

## 2.4 Clinical presentation

SJS/TEN is characterized, as per the original descriptions, by fever, blistering skin eruption and severe mucositis. The skin lesions initially appear as atypical target-like or targetoid lesions, which are erythematous macules that contain a central purpuric blister (Fig. 1). Lesions are symmetrically distributed often starting on the face and thorax before spreading to other areas. The scalp is typically spared. Blisters result from epidermal detachment and they are easily breached resulting in dark red oozing erosions. Lesions exhibit Nikolsky's

sign, which is epidermal separation induced by gentle lateral pressure applied to the skin surface. The skin then sloughs rapidly over several days as a result of separation of large sheets of the epidermis from the dermis. Fulminant cases of TEN have been reported where total loss of the epidermis occurs within 24 hours. New lesions may continue to erupt for up to 4 weeks. However, the growth of a new epithelium occurs after several days and individual lesions are completely re-epithelialized after a mean of 3 weeks. Cicatrization of the mucous membranes may take longer to complete.

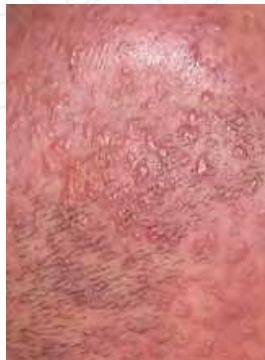

Fig. 1. Atypical target-like or targetoid lesions in a patient with SJS characterized by an erythematous macule with a central blister.

At least two mucosal surfaces are involved in 90% of cases of SJS/TEN (Letko, Papaliodis et al. 2005). Oropharyngeal involvement causes severe pain and odynophagia as a result of erosion and crusting (Fig. 2). Ocular regions may show a purulent conjunctivitis, pseudomembrane formation and corneal ulceration as a result of sloughing of conjunctival and corneal epithelia (Fig. 3). Urethritis may result in dysuria and even urinary retention. Sloughing of the tracheal and bronchial epithelium occurs in up to 30% of cases and may result in hypoxia, bronchial hypersecretion, pulmonary edema and bronchiolitis obliterans and the need for mechanical ventilation (Lebargy, Wolkenstein et al. 1997). The gastrointestinal tract can also be involved resulting in per rectal bleeding (Sugimoto, Mizutani et al. 1998).

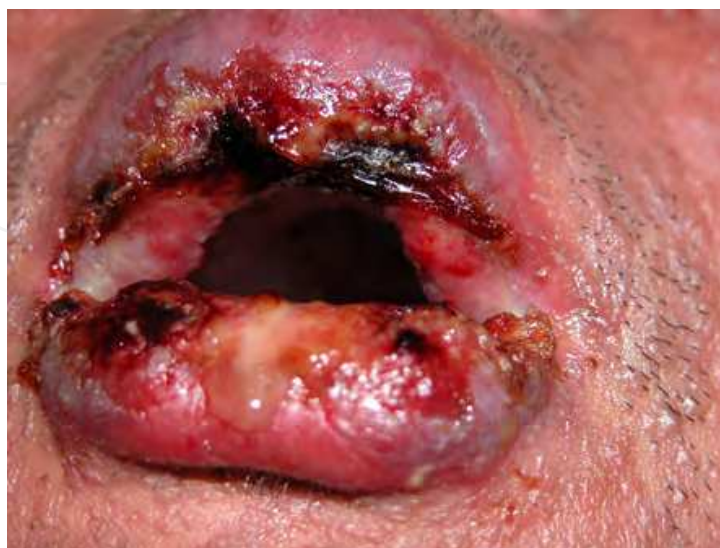

Fig. 2. Oral mucositis in a patient with SJS depicted as sloughing, necrosis and crusting of the inner labial surfaces.



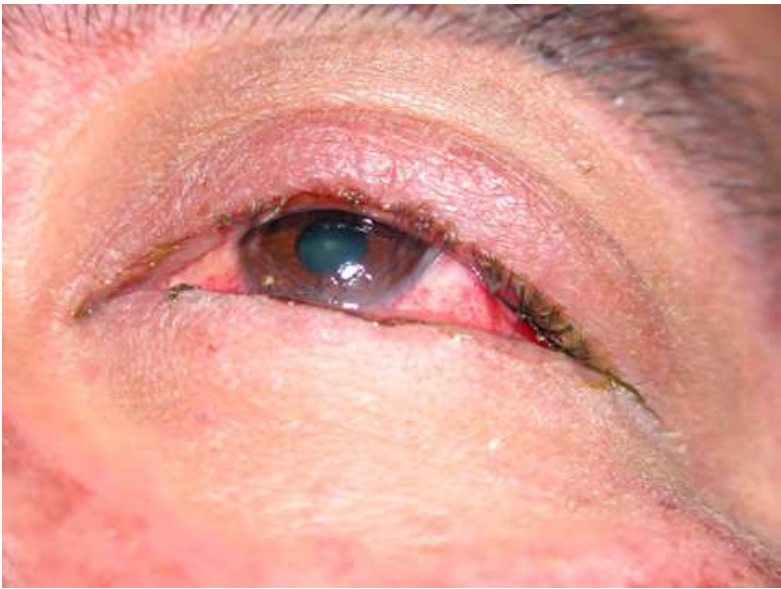


Fig. 3. Purulent conjunctivitis in a patient with SJS accompanied by pseudomembrane formation, which results from sloughing of conjunctival and corneal surfaces.

The mortality of SJS is generally below 10% whereas 30-50% of TEN patients die in the acute phase of the illness mostly as a result of skin failure. Infection and sepsis with multiorgan failure is the most common of death. The causative organisms are usually *Staphylococcus aureus* and *Pseudomonas aeruginosa* (Atiyeh, Dham et al. 2003). Fluid and electrolyte imbalances occur as a result of increased transepidermal water loss and impaired intake of nutrition due to odynophagia from stomatitis. Less common fatal complications include adult respiratory distress syndrome, pulmonary embolism and gastrointestinal haemorrhage (Wolkenstein and Revuz 2000; Abood, Nickoloff et al. 2008). Mortality is accurately predicted by the SCORTEN scale (Table 1) and should be computed within 24 hours and 3 days following admission (Bastuji-Garin, Fouchard et al. 2000; Guegan, Bastuji-Garin et al. 2006).

Parameter	Score
Age >40 years	1
Presence of malignancy	1
Heart rate >120/min	1
TBSA involved >10%	1
Serum urea > 10 mmol/L (28 mg/dL)	1
Serum glucose >14 mmol/L (252 mg/dL)	1
Serum bicarbonate <20 mmol/L (20 mEq/L)	1

SCORTEN	Mortality (%)
0-1	3.2
2	12.1
3	35.3
4	58.3
≥5	90

Table 1. SCORTEN

Chronic complications occur frequently following the acute phase of SJS/TEN. The most serious sequelae relate to the eye. The chronic ocular consequences are that of a cicatrization of the conjunctiva and symblepharon formation, severe dry eye, trichiasis, eyelid margin keratinization, and limbal stem cell deficiency, all of which combine to cause corneal ulceration and scarring and loss of vision. Patients may also experience chronic photophobia and eye pain. Skin sequelae include scarring, pigmentation abnormalities, and shedding of hair and nails. Vulvovaginal involvement can result in stenosis. Vulvar adenosis can occur in young women several years after resolution of the acute episode and can present with tender, erosive, haemorrhagic lesions. Phimosis can occur in men. Bronchopulmonary complications confer a poor prognosis and include chronic bronchitis, bronchiolitis obliterans, bronchiolitis obliterans with organizing pneumonia, and bronchiectasis. Oesophageal stricture and webbing has also been described and can result in dysphagia.

## 2.5 Pathogenesis

SJS/TEN results from the T- and NK-cell mediated extensive apoptosis of keratinocytes. The pharmaco-immune (p-i) concept, the mechanism by which the drug binds directly with the T cell receptor (TCR) causes activation of proapoptotic pathways. Granulysin is the major mediator of apoptosis in SJS/TEN. Apoptosis is also mediated through Fas-FasL interaction, and the release of granzyme and perforin.

### 2.5.1 The pharmaco-immune (p-i) concept

It is generally accepted that in SJS/TEN, the parent drug binds directly and non-covalently to the MHC and the TCR of primed effector and memory T cells (Pichler, Adam et al. 2010). Naïve T cells are not sufficiently stimulated by a p-i drug and additional signals are required (Pichler 2005). T cells may be primed by infection or autoimmune disease resulting in high cytokine levels such as IL-2 and IFN- $\gamma$  resulting in increased expression of MHC and costimulatory molecules. This may provide an explanation for the increased incidence of drug hypersensitivity in inflammatory and infectious diseases. The drug may also bind to toll-like receptors resulting in the expression of costimulatory molecules by dendritic cells. For drugs such as cotrimoxazole, lamotrigine, and carbamazepine, the p-i concept may not be the sole mechanism involved; metabolites may also play a role through haptization (Sanderson, Naisbitt et al. 2007).

### 2.5.2 Granulysin

A recent study by Chung et al using global gene expression profiling showed that granulysin RNA was the most significant cytotoxic molecule expressed in blister cells from patients with SJS/TEN. Granulysin protein concentrations were 2-4 times higher than perforin, granzyme B, and FasL and depleting granulysin reduced cytotoxicity (Chung, Hung et al. 2008). Granulysin is a cationic cytolytic protein produced by CTL, NK and NKT cells (Fig. 4A) (Gamen, Hanson et al. 1998). The 15-kDa-precursor form, found in blister fluid, induced skin necrosis when injected into mice and exhibited significant cytotoxicity in vitro. This contrasted with the minimal cytotoxicity induced by perforin, granzyme B, and FasL (Chung, Hung et al. 2008). Granulysin is also a proinflammatory molecule that causes an increase in the expression of chemokines (RANTES/CCL5, MCP-1, MCP-3, MIP-1 $\alpha$ /CCL3) and cytokines (IL-1, IL-6, IFN- $\alpha$ ) resulting in the recruitment of T cells, monocytes and other inflammatory cells (Deng, Chen et al. 2005).

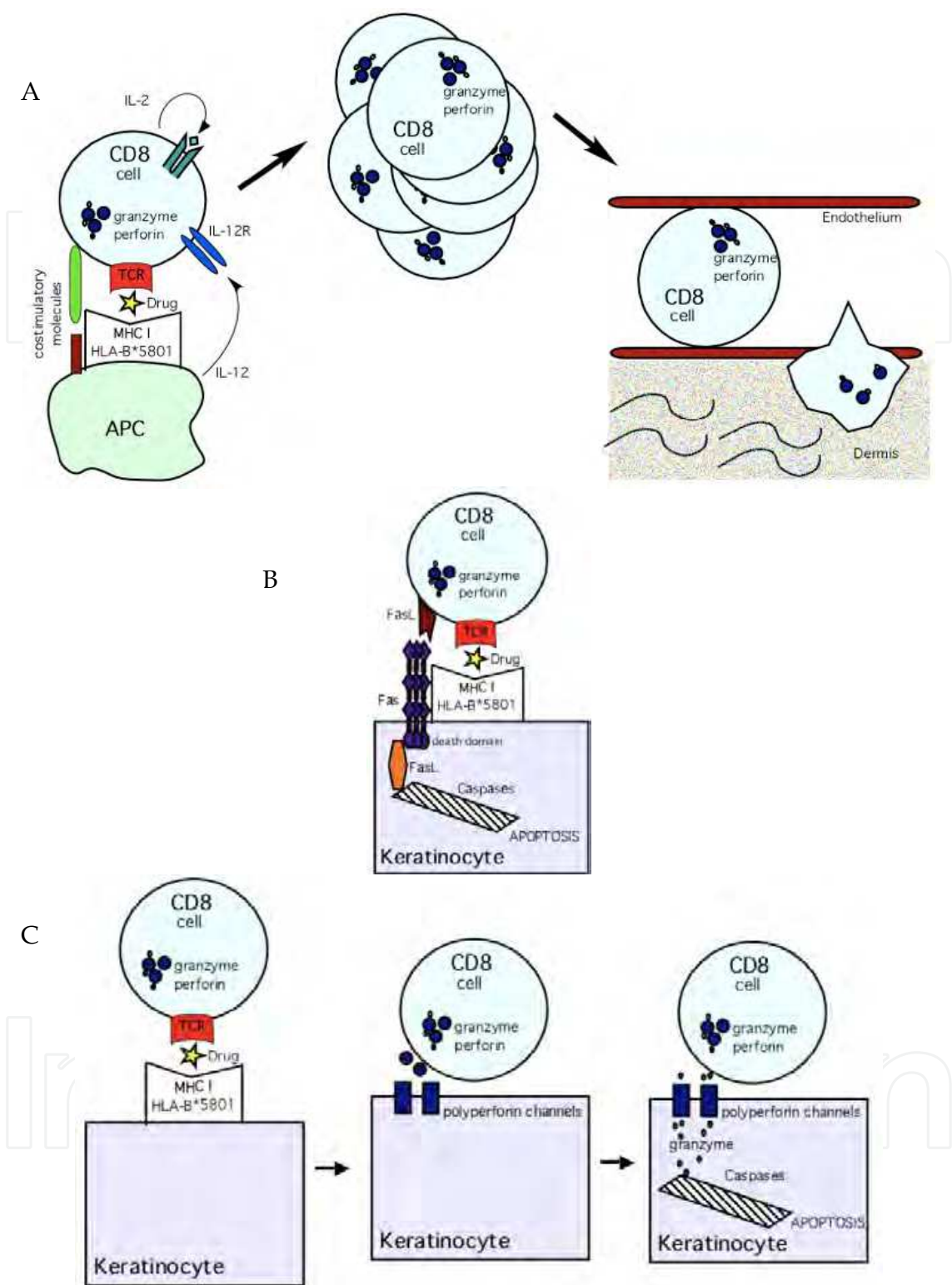


Fig. 4. SJS/TEN is primarily mediated by cytotoxic T cells. The drug binds to the CD8 T cell receptor and MHC via the pi concept resulting in their proliferation, activation and infiltration of these effector cytotoxic T cells (CTLs) into the skin (A). These CTLs may also bind drug that also binds to MHC class I molecules expressed on keratinocytes. Apoptosis of keratinocytes in SJS/TEN is caused primarily by the release of granulysin (A), but the ligation of Fas by FasL (B), and the degranulation of perforin and granzyme (C) may also play a role.



### **Fas-FasL, perforin/ granzyme and TNF pathways**

Viard et al, showed that the binding of FasL to Fas expressed on the surface of keratinocytes resulted in their apoptosis (Fig. 4B) (Viard, Wehrli et al. 1998). The cytoplasmic death domain of Fas undergoes conformational changes and trimerization upon recognition of FasL. This results in the recruitment of the Fas-associated death domain (FADD), which binds to procaspase 8 resulting in triggering of the caspase cascade and apoptosis. The source of the FasL is unclear. Viard et al showed that the FasL was present on the surface of keratinocytes and in the serum of patients with TEN but not on the surface of keratinocytes or in the serum of patients with maculopapular exanthems and normal controls (Viard, Wehrli et al. 1998). A further study demonstrated that FasL was not constitutively expressed on the surface of keratinocytes but are transported to the cell membrane after damage to the keratinocyte (Viard-Leveugle, Bullani et al. 2003). Abe et al, however, found that the source of FasL was PBMCs and not keratinocytes (Abe, Shimizu et al. 2003).

Nassif et al showed that mononuclear cells from blister fluid induce cytotoxicity via perforin and granzyme B (Nassif, Bensussan et al. 2002). This cytotoxicity was blocked by inhibiting perforin/ granzyme but not by inhibiting Fas. Perforin and granzyme are proteins stored in the granules of CTLs. Upon recognition of a target cell, the CTL releases perforin, which create 16-nm channels in the target cell membrane. Granzyme B, a protease passes through these channels to activate the caspase cascade (Fig. 4C). The loss of T regulatory cell function in the acute stage of SJS/TEN may further contribute to the epidermal damage caused by effector T cells (Takahashi, Kano et al. 2009).

Posadas et al, showed that both Fas-FasL and perforin/ granzyme pathways may be involved in SJS/TEN. They found a direct correlation between disease severity and levels of perforin and granzyme B in patients with maculopapular exanthems, SJS and TEN. FasL was detected in the PBMCs and blister fluid of patients in SJS and TEN but not in those in maculopapular exanthema, suggesting that Fas-FasL is involved in more severe reactions (Posadas, Padial et al. 2002). Nassif et al, also showed a potential role for cytokines in the pathogenesis of SJS/TEN. He found elevated levels of IFN- $\gamma$ , soluble TNF, IL-10, soluble FasL in the blister fluid of TEN patients. Although they disputed the central role of FasL, they hypothesised that drug specific CTLs secrete IFN- $\gamma$ , which activates keratinocytes to produce TNF, a cytokine that upregulates MHC class I molecules. This increases exposure of keratinocytes to CTL resulting in perforin/ granzyme-mediated apoptosis. IL-10 serves to downregulate the inflammatory reaction (Nassif, Bensussan et al. 2004).

## **2.6 Risk factors for SJS/TEN**

### **2.6.1 Genetic susceptibility**

It was observed in the 1990s that the most commonly offending drugs vary among different ethnic populations. In Western countries, the most commonly implicated agents of SJS/TEN were NSAIDs and sulphonamides (Roujeau, Kelly et al. 1995). In contrast, carbamazepine was found to be the leading cause of SJS/TEN in Southeast Asian countries, including India, Malaysia, Singapore, Taiwan and Hong Kong (Hung, Chung et al. 2005a). Interestingly, carbamazepine in Western countries causes more cases of DIHS than SJS/TEN. Allopurinol is also a frequent cause of SJS/TEN and DIHS but does not appear to have a racial bias (Hung, Chung et al. 2007).

The most striking genetic association was detected in a cohort of Han Chinese in Taiwan, where the *HLA-B\*1502* allele was found in 100% of the 44 patients with carbamazepine-induced SJS/TEN and only 3% of the carbamazepine-tolerant individuals; OR 2504 [126–

49522] (Chung, Hung et al. 2004). These findings were replicated in an extended cohort of subjects of Chinese descent originating from separated geographic areas of China, Taiwan, and the United States (Hung, Chung et al. 2006). This association with carbamazepine-induced SJS/TEN, however, was not found in individuals with European (Lonjou, Thomas et al. 2006) and Japanese ancestries (Kaniwa, Saito et al. 2008), respectively, and therefore the allele appears relevant in the context of ethnicity. In a recent study comprising 12 patients of Northern European ancestry with carbamazepine-induced SJS/TEN, 5 (42%) carried the *HLA-A\*3101* allele, as compared with 10 (4%) of the 257 control subjects; OR 25.93 [4.93-116.18] (McCormack, Alfirevic et al. 2011). The results of this study are yet to be replicated in other cohorts of subjects with Northern European ancestry. In a Japanese study, The *HLA-A\*3101* allele was found in 5/6 (83.3%) carbamazepine-induced SJS/TEN compared to 47/376 (12.5%) carbamazepine-tolerant patients; OR 33.9 [3.9-295.6]. Larger patient sample sizes are required to confirm this association in the Japanese where the allele frequency is 9% (Ozeki, Mushiroda et al. 2011). Interestingly the *HLA-A\*3101* allele was shown to be associated with maculopapular exanthem (OR 17.5 [4.6-66.5]) but not SJS/TEN in a Han Chinese population (Wen, Lai et al. 2008).

A study comprising a Han Chinese cohort in Taiwan demonstrated the presence of the *HLA-B\*5801* allele in all 51 patients with allopurinol-induced SCAR (21 with TEN, 30 with DIHS) compared with only 15% (20/135) in allopurinol-tolerant subjects; OR 580.3 [34.4-9780.9] (Hung, Chung et al. 2005b).

The role of these HLA alleles in the pathogenesis of SCAR is unclear. Certain HLA alleles may bind to particular drugs more robustly than other alleles. Furthermore, the binding of the drug in SJS/TEN is MHC class I restricted, which is consistent with the prominent role of CD8 cells in the pathogenesis of the disease. If an allele has a functional effect that may play a role in the pathogenesis of disease, this association will be consistently observed across different populations. The differences observed between the Chinese and European studies may be partly explained by the fact that pharmacogenetic studies are likely to yield positive results when conducted in a population with a high frequency of such an allele. The risk of disease from a genetic polymorphism is influenced by its prevalence. The *HLA-B\*1502* allele frequency is 4.8 to 12.8% in Southeast Asians compared to 0-0.1% observed in Northern Europeans (Fig. 5). Therefore, *HLA-B\*1502* is of low prevalence in Caucasians and hence, if it is a true susceptibility allele, a very large sample size is required in this population to detect a significant odds ratio of sufficient power. In contrast, the allele frequency of *HLA-A\*3101* is 2-5% in Northern Europeans and the sample size required to demonstrate an association in a sufficiently powered study is less than that for the *HLA-B\*1502* allele. The *HLA-B\*5801* allele, in contrast to *HLA-B\*1502* is more evenly distributed among different racial groups (Fig. 6) and hence, associations, albeit weaker, have been demonstrated in other ethnic groups such as the Southern Japanese (Kaniwa, Saito et al. 2008) and in whites (OR 80 [34-157]) (Lonjou, Borot et al. 2008). Another explanation is that *HLA-B\*1502*, is a marker of a true disease contributing allele through strong linkage disequilibrium, which varies between populations. In other words, the same high-risk allele may have a different pattern of association with marker alleles and therefore *HLA-B\*1502* is in strong linkage disequilibrium in the Han Chinese population, but not in a European population. It is also plausible that SJS/TEN is a polygenic disorder, with many susceptibility and protective alleles in genes involved in the pathogenesis of the disease. Polymorphisms in the proapoptotic gene *Fas-L*, the toll-like receptor 3 gene, and in the IL-4 receptor/IL-13 signalling pathway have all been recently described in a Japanese study (Ueta, Sotozono et al. 2008). Such alleles may also vary in different populations.

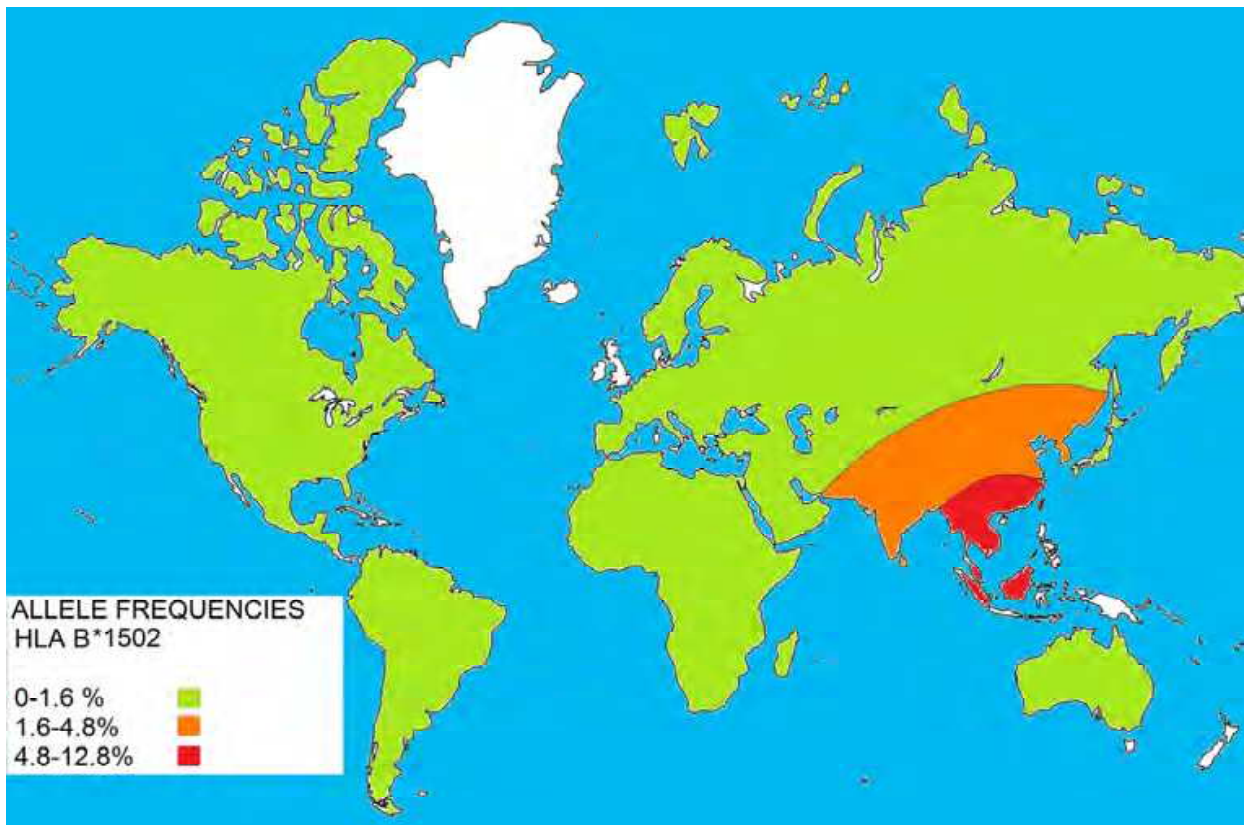


Fig. 5. The high variation in the prevalence of *HLA-B\*1502* across geographical regions.

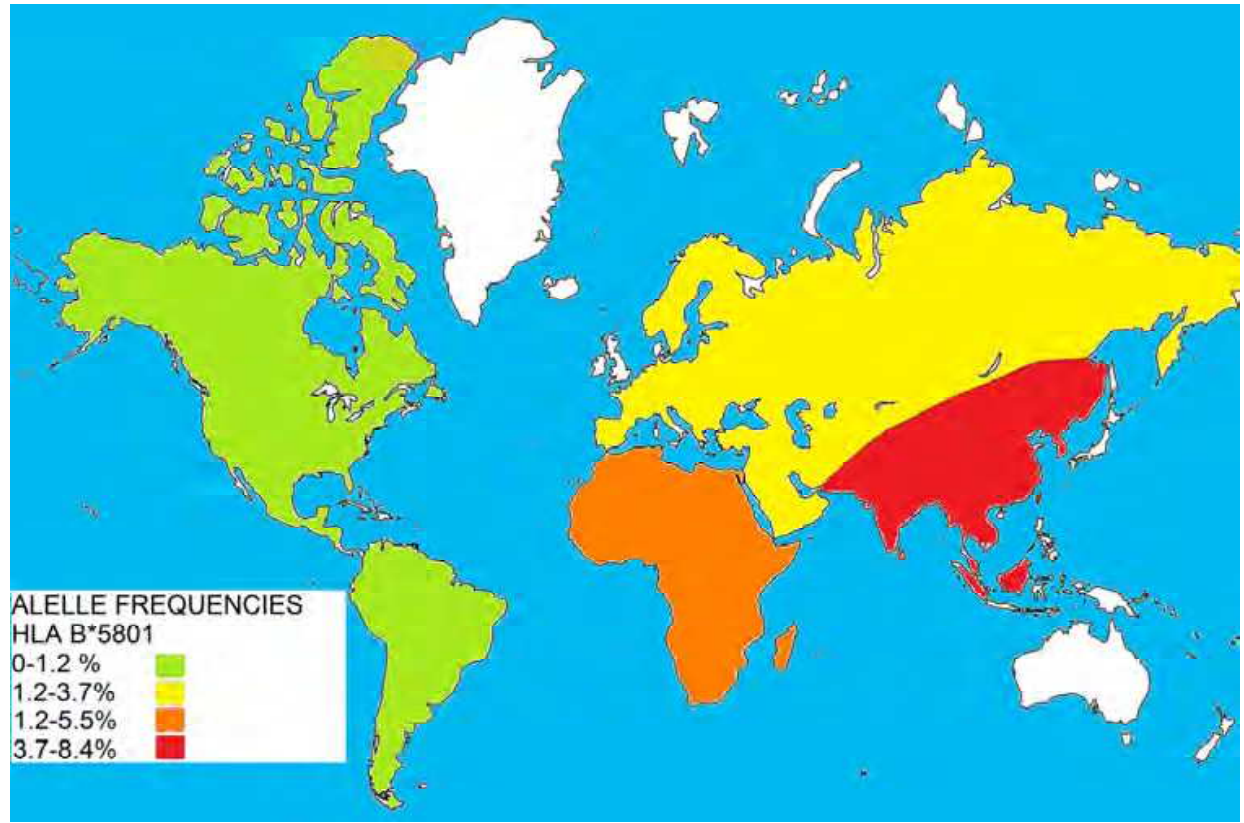


Fig. 6. The low variation in the prevalence of *HLA-B\*5801* across geographical regions.



The FDA and Health Canada have issued warnings for carbamazepine stating that persons with ancestry in genetically at-risk populations should be screened for the presence of *HLA-B\*1502* prior to initiating treatment. Genetic screening for *HLA-B\*1502* in a high risk population such as the Han Chinese has a 100% sensitivity and 97% specificity and its presence confers a 7.7% positive predictive value for carbamazepine-induced SJS/TEN whereas its absence has a 100% negative predictive value (Hung, Chung et al. 2005a). A recent study demonstrated the benefit of genetic screening; in a Taiwanese population, screening for the *HLA-B\*1502* allele resulted in no cases of SJS/TEN in 4501 patients who were negative for the allele (Chen, Lin et al. 2011). The authors concluded that this would have prevented 10 cases of SJS/TEN. Despite the FDA recommendations, screening is not routinely performed partly because of the lack of availability of cost effective and rapid methods of detection (Fernando and Broadfoot 2010). However, many laboratories have now developed high resolution genetic testing using a sequence-specific primer assay method for the detection of this allele from whole blood samples and buccal swabs. The assay can be performed within 3-4 hours. Such a strategy has been very successful in virtually abolishing the incidence of *HLA-B\*5701*-associated abacavir hypersensitivity in HIV-infected patients (Rauch, Nolan et al. 2006). Multiplexed PCRs can be utilized to assess multiple alleles.

It is important to note that the *HLA-B\*1502* allele does not predispose to carbamazepine-induced DIHS, maculopapular eruptions or other adverse reactions and continued vigilance for the symptoms of SCAR needs to be maintained if treatment is commenced (Hung, Chung et al. 2006). Currently, there is no recommendation for genetic screening prior to the commencement of allopurinol therapy. Although such a strategy is plausible, studies are required to determine the benefits of screening for the *HLA\*5801* allele in at risk populations.

### 2.6.2 Diseases

The EuroSCAR study showed that HIV infection conferred the highest risk of SJS/TEN; multivariate relative risk (mvRR) 12 [2.4-59]. Other disease associations included collagen vascular disease mvRR 2.2 [0.9-5.0], recent malignancy mvRR 2.7 [1.3-5.7], recent radiotherapy mvRR 2.1 [0.5-9.0], or acute infection in the past 4 weeks [1.2-2.3] (Mockenhaupt, Viboud et al. 2008).

### 2.6.3 Pharmacokinetics

The EuroSCAR study revealed an increased risk of SJS/TEN at higher doses of allopurinol; adjusted odds ratio (OR) 36 [17-76] for doses  $\geq 200$  mg daily compared with an adjusted OR 3.0 [1.1-8.4] for doses  $< 200$  mg daily (Halevy, Ghislain et al. 2008). This study also revealed that the risk was mostly confined to short-term use ( $\leq 8$  weeks, unadjusted OR 261 [36- $\infty$ ]). Allopurinol is ideally commenced at a dose of 100 mg daily and increased by 100 mg increments until the desired serum uric acid level is attained. Previous reports have shown that allopurinol is often commenced at inappropriate doses (Stamp, Gow et al. 2000) and that higher doses are associated with an increased incidence of acute events (McInnes, Lawson et al. 1981). It is likely that the rapid accumulation of the chemically reactive metabolite oxypurinol when higher doses of allopurinol are commenced



increases the risk of SJS/TEN (Kumar, Edward et al. 1996). This drug accumulation hypothesis is further supported by the 4.7 fold increased incidence of allopurinol-induced SCAR in renal insufficiency (Vazquez-Mellado, Morales et al. 2001). The established indications for allopurinol are treatment of hyperuricemia associated with chronic gout, acute uric acid nephropathy, recurrent uric acid stone formation, enzyme disorders of purine metabolism, and in the management of tumour lysis. Allopurinol is not indicated in the majority of patients with asymptomatic hyperuricemia (Dincer, Dincer et al. 2002). However, allopurinol is inappropriately prescribed in up to 86% of cases (Khoo and Leow 2000). A comparison of allopurinol exposure between the SCAR (1989-1993) and EuroSCAR (1997-2001) studies showed a 2-3 fold increase in exposure for both patients and control subjects, which may be attributed to the increased prescribing of the drug for the treatment of asymptomatic hyperuricemia. The authors of the EuroSCAR study postulate that up to 48 of the 56 cases of allopurinol-induced SJS/TEN could have been prevented if the treatment guidelines for prescribing allopurinol were followed.

Lamotrigine when commenced at high doses can also overwhelm the detoxifying capacity resulting in an increased risk of SJS/TEN and DIHS (Schlienger, Shapiro et al. 1998). The incidence has reduced significantly as a result of the now conventional practice of gradually titrating the dose (Mockenhaupt, Messenheimer et al. 2005). Coadministration of certain drugs can predispose to SCAR by competition for the same enzyme-binding site. Reactions to lamotrigine are more common when given in combination with valproic acid as the addition of valproic acid inhibits the clearance of lamotrigine by competing for glucuronic acid conjugation (Yalcin and Karaduman 2000). The role of slow acetylation phenotypes of N-acetyltransferase was thought to confer susceptibility of sulphonamide-induced SJS/TEN in two small studies (Dietrich, Kawakubo et al. 1995; Wolkenstein, Carriere et al. 1995) but this needs confirmation in larger studies.

## 2.7 Diagnosis

### 2.7.1 Skin biopsy

A presumptive diagnosis of SJS/TEN is made clinically and is confirmed with a skin biopsy (Figs. 7 & 8). Early lesions demonstrate scattered necrotic keratinocytes in the epidermal layers at the level of the stratum spinosum and the basal cell layer. Later, full thickness epidermal necrosis is evident, which eventuates in the formation of subepidermal bullae. The mononuclear predominantly T cell dermal infiltrate is generally sparse but dense infiltrates can also be present. Quinn et al, has shown an extensive infiltrate was associated with a 71% mortality rate, a moderate infiltrate with a 53% mortality, and a sparse infiltrate with a 27% mortality, respectively (Quinn, Brown et al. 2005). A fresh sample for direct immunofluorescence (DIF) reveals an absence of immunoglobulin and complement deposition. Cultures on blood, wounds and mucosal lesions should be performed to evaluate for superinfection. Serology may be performed for *Mycoplasma pneumoniae* if indicated.

A recent pilot study showed that serum granulysin levels may be raised early in the course of disease but rapidly wanes with progression of disease (Abe, Yoshioka et al. 2009). Further studies are required to determine whether this assay will prove to be a useful early diagnostic test for SJS/TEN.

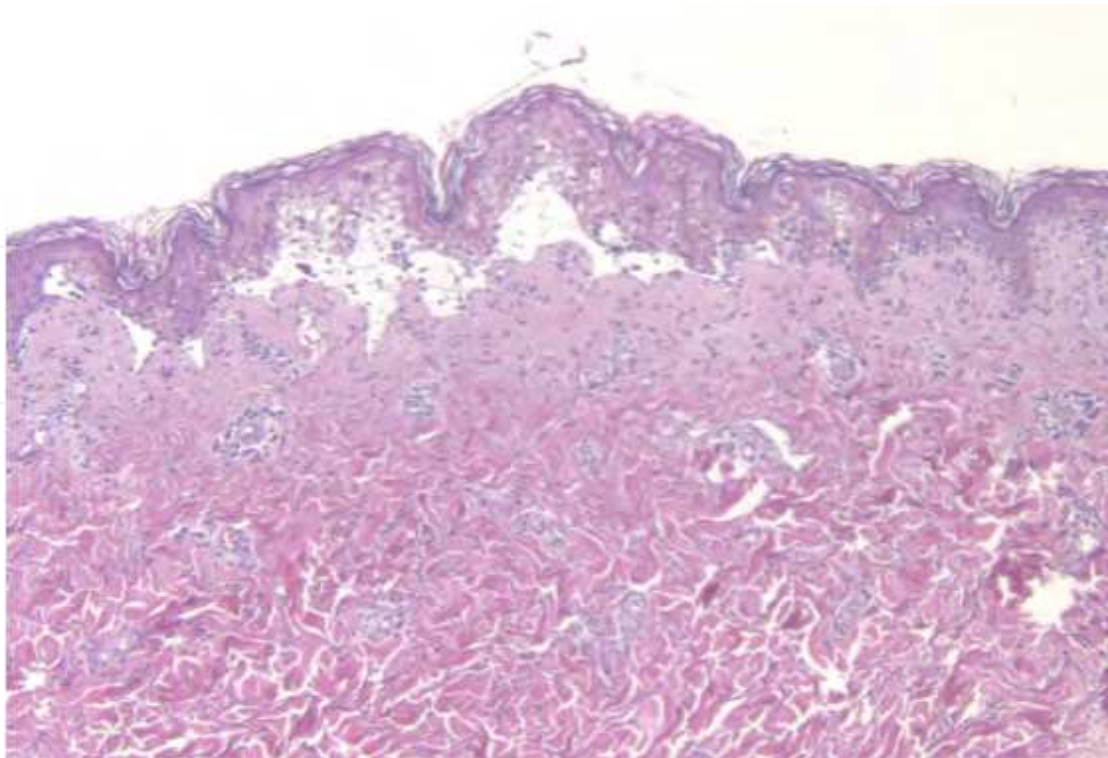


Fig. 7. Low power view of a skin biopsy from a patient with SJS demonstrates separation of the epidermis from the dermis at the level of the stratum spinosum and basal cell layer resulting in the formation of subepidermal bullae (Hematoxylin-eosin, original magnification x40).

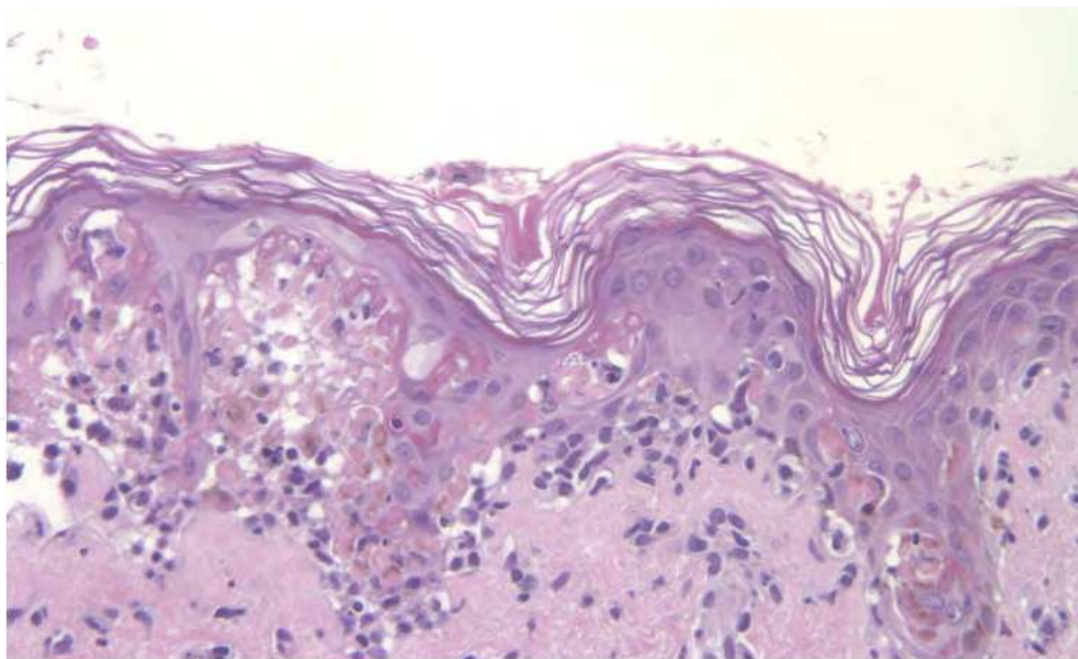


Fig. 8. High power view of a skin biopsy from a patient with SJS shows necrosis of keratinocytes, and vacuolar degeneration of the basal cell layer. A sparse lymphocytic infiltrate is present at the dermoepidermal junction and displays satellitosis or clustering around dying basal cells (Hematoxylin-eosin, original magnification x200).

### 2.7.2 Allergy testing

Skin tests and oral challenges are contraindicated in SJS/TEN because of the risk of inducing a recurrence of disease. Patch testing has not been investigated extensively. The biggest cohort comprised 22 patients and showed a poor sensitivity of only 9% (Wolkenstein, Chosidow et al. 1996). Lymphocyte transformation tests (LTTs) assess the proliferation of the patient's peripheral blood T cells cultured in the presence of a suspected drug for 6 days by measuring the incorporation of  $^3\text{H}$ -thymidine during DNA synthesis. The result is expressed as a stimulation index, which is the ratio of cell proliferation with antigen and without antigen. The sensitivity of LTTs in SJS/TEN is greatly improved if the test is performed within 1 week of the onset of disease but becomes negative by 6 weeks (Kano, Hirahara et al. 2007). This may be attributed to loss of regulatory T cell function in the acute phase, which is then restored upon recovery (Takahashi, Kano et al. 2009). Recently, a new cytotoxicity assay combining the measurement of expression of the degranulation marker, CD107a, using flow cytometry and the release of the serine protease, granzyme B by Elispot after incubating the patient's peripheral blood mononuclear cells with the suspected drug for 3 days (Zawodniak, Lochmatter et al. 2010). The test has very good specificity with all of the 16 controls having a negative test and good sensitivity with 10 of the 12 patients having a positive result. One role of these in vitro tests is to determine the culprit drug when more than one drug is suspected.

### 2.8 Differential diagnosis

SJS/TEN is differentiated from other conditions on the basis of the acute onset of disease, the presence of targetoid and vesiculobullous lesions, sloughing of the epidermis, severe mucosal involvement, the histologic finding of full thickness epidermal necrosis, and a negative DIF. In EM major, erosive mucous membrane involvement is present but in contrast to SJS, the patient has typical target lesions mainly affecting the extremities and it is often induced by acute or recurrent HSV infection. The clinical manifestations of drug-induced maculopapular exanthems (MPE) are variable and often polymorphic and lesions may have a target-like appearance. Fever may be present but mucosal involvement is absent. The histopathology typically shows an interface dermatitis with hydropic degeneration of the basal cell layer. Some exanthems may progress to more severe reactions such as SJS/TEN or DIHS. Generalized bullous fixed drug eruption (GBFDE) features large brownish violaceous patches upon which flaccid blisters arise. These blisters affect only a small percentage of the TBSA. Mucosal involvement is rare and fever is absent. Most patients report a history of a similar local reaction or fixed drug eruption.

Staphylococcal scalded skin syndrome (SSSS) usually affects children under the age of 5 years and patients present with fever, erythema and painful skin, followed by blistering, which is typically accentuated in areas of friction and around orifices. SSSS is caused by the systemic distribution of epidermolytic toxins produced by certain strains of Staphylococci. These toxins cause separation at the level of the stratum granulosum, the upper layer of the epidermis, resulting in very superficial detachment of the skin and blistering. Mucous membrane involvement is rare. The condition usually but not always follows local or systemic staphylococcal infection. Adults are less susceptible as improved renal function allows for better clearance of the toxins. However SSSS has been described in adults who are immunosuppressed or in renal failure. Toxic shock syndrome (TSS) is caused by elaboration of toxins produced by *Staphylococcus aureus* and *Streptococcus pyogenes* that act as superantigens, which bind to the variable regions of  $\beta$  chains of antigen receptors on subsets of T cells and



cross-link them to the MHC molecules of antigen-presenting cells. This results in activation of large numbers of T cells (5-30%) and the massive release of cytokines including IL-2, TNF, lymphotoxin and IL-1 $\beta$ . TSS is characterised by fever, diffuse red macular rash, hypotension and involvement of  $\geq 3$  organs: renal failure, hepatitis, thrombocytopenia, encephalopathy, mucous membrane hyperemia, gastrointestinal involvement with vomiting and diarrhoea.

Bullous disease	Fever	Mucositis	Rash	DIF	Onset	Other notable features
SJS/TEN	+	+	Erythroderma Targetoid lesions Vesicles, bullae Erosions, detachment	-	Acute	Starts on trunk, proximal upper limbs and face and then spreads
EM Major	+	+	Acral Target lesions	-	Acute	HSV-induced recurrences
Drug-induced MPE	+/-	-	Variable Pleomorphic	-	Acute	May progress to SJS or DIHS
GBFDE	-	-	Brown patches Large bullae	-	Acute	Antecedent local reaction Small % TBSA
SSSS	+	-	Erythroderma Skin tenderness Periorificial crusting	-	Acute	Children under 5 Adults with chronic renal failure and on immunosuppressive therapy
TSS	+	+	Diffuse red macular rash Desquamation of palms and soles	-	Acute	Hypotension Multiple organ failure
Drug-induced linear IgA dermatosis	-	-	Tense bullae	+	Acute	Vancomycin Pruritus
PNP	-	+	Polymorphous Bullae	+	Gradual	
Drug-induced Pemphigus	-	-	Erosions Crusts	+	Gradual	Thiol drugs
Drug-triggered pemphigus	-	+	Mucosal erosions Flaccid bullae Morbilliform rash	+	Gradual	Non-thiol drugs
AGVHD	+	+	Bullae Erosions, detachment	-	Acute	Starts acrally and then spreads
AGEP	+	+/-	Small nonfollicular pustules Erythroderma	-	Acute	

SJS/TEN, Stevens-Johnson syndrome/toxic epidermal necrolysis; EM, erythema multiforme; MPE, maculopapular exanthem; GBFDE, generalized bullous fixed drug eruption; SSSS, staphylococcal scalded skin syndrome; TSS, toxic shock syndrome; PNP, paraneoplastic pemphigus; AGVHD, acute graft versus host disease; AGEP, acute generalized exanthematous pustulosis

Table 2. The differential diagnosis of SJS/TEN



Desquamation occurs after 1-2 weeks and predominantly affects the palms and soles. Approximately 50% of cases are menstrually related due to the prolonged application of absorbent tampons. Notably, 50% of cases of TSS are not associated with menstruation. Non-menstrual cases of TSS usually complicate the use of barrier contraceptives, surgical and postpartum wound infections, burns, cutaneous lesions, osteomyelitis, and arthritis. Although most cases of TSS occur in women, about 25% of non-menstrual cases occur in men.

Autoimmune bullous diseases such as drug-induced linear IgA bullous dermatosis, drug-induced pemphigus, and paraneoplastic pemphigus need to be considered in the differential diagnosis of SJS/TEN. These conditions, in contrast to SJS/TEN, usually have a chronic course and are characterized by acantholysis on histopathology and immunoglobulin deposition on DIF. Bullous pemphigoid (BP) is a chronic disease that is typified by a tense bullous eruption that primarily affects individuals in the fifth through seventh decades of life.

Acute graft versus host disease (AGVHD) shares many of the same clinical, pathologic and immunologic features as SJS/TEN. Both conditions are mediated by cytotoxic T cells, which results in epidermal necrosis and keratinolysis (Schulz and Sheridan 2006). Furthermore, bone marrow transplantation patients receive medications that can trigger SJS/TEN. AGVHD generally occurs 4 weeks after stem cell transplantation. Patients describe a sensation of skin pain and itching followed by a morbilliform rash that in severe cases becomes generalized with diffuse areas of epidermal necrosis. Mucositis is usually present. AGVHD frequently begins acraly and spreads proximally in contrast to TEN, which begins on the trunk and spreads distally. Also, the early exanthem of AGVHD has a folliculocentric distribution.

AGEP is characterized by fever and as the disease progresses, widespread erosions mimicking SJS/TEN may be evident. Mucous membrane involvement is unusual and if present is mild.

## **2.9 Treatment**

### **2.9.1 Supportive care**

Immediate discontinuation of the culprit drug is mandatory to reduce mortality. As the management of TEN is similar to that of extensive burns, a transfer to a burns unit reduces morbidity and mortality. The unit has expertise in providing analgesia, ensuring adequate enteral or parenteral nutrition, maintaining fluid and electrolyte balance, and managing wounds. Ophthalmologic consultation is important in SJS/TEN and the combination of aggressive lubrication, topical antibiotics, topical corticosteroids, and lysis of adhesions may attenuate the acute ocular manifestations. However, these measures have only a modest effect on the long term ocular complications. Recently, the application of amniotic membranes has proved effective in preserving visual acuity and an intact ocular surface (Shammas, Lai et al. 2010). The benefit may be derived from creating a physical barrier between inflamed and denuded mucosal surfaces that minimizes the formation of adhesions. The membrane may also have antiinflammatory and antifibrotic effects.

Other supportive measures include hygienic mouthwashes and topical oral anaesthetics, and monitoring for urinary retention.

### **2.9.2 Corticosteroids**

The role of corticosteroids in the treatment of SJS/TEN is controversial. Corticosteroids given 48 hours or more prior to admission are associated with an increase incidence of

infection, length of hospital admission, and mortality in children and adults (Rasmussen 1976; Ginsburg 1982; Engelhardt, Schurr et al. 1997). A study in 1986 of 30 patients with TEN with an average TBSA involvement > 80% were equally divided into those receiving supportive care alone and those receiving dexamethasone at varying doses (Haleblian, Corder et al. 1986). Although the incidence of sepsis was not significantly different between the groups, the survival following onset of sepsis was less in the corticosteroid treated group. The use of corticosteroids doubled the rate of mortality (66% versus 33%). Corticosteroids do not prevent SJS/TEN from occurring and have no effect on arresting disease progression (Samimi and Siegfried 2002). A retrospective analysis of 379 patients from the EuroSCAR study found no benefit from corticosteroids or IVIg compared to supportive care alone (Schneck, Fagot et al. 2008).

The poor outcomes may have resulted from inadequate doses and the delay in the initiation of corticosteroid therapy. In a prospective study of 16 children with SJS in 1997, 10 received methylprednisolone (4 mg/kg/daily) within 3 days of the onset of rash whilst 6 received supportive care only; corticosteroids were associated with decreased length of fever and duration of skin eruption (Kakourou, Klontza et al. 1997). The use of pulsed IV corticosteroids has also been shown in retrospective analyses to reduce mortality. The initiation of IV methylprednisolone 500-1000 mg/daily for 3-4 days may also prevent ocular complications of cicatrization and preservation of visual acuity (Araki, Sotozono et al. 2009). The benefits of early pulsed therapy with IV corticosteroids need to be further evaluated in randomised control trials.

The current level of evidence suggests that high dose corticosteroids may be beneficial if commenced early in the course of disease with vigilant monitoring for emergence of infection. However, further evaluation in randomised control trials are required to confirm these benefits

### **2.9.3 Intravenous immunoglobulin (IVIg)**

The rationale for the use of IVIg is based on its ability *in vitro* to block Fas and subsequently FasL-mediated apoptosis of keratinocytes. The beneficial role of IVIg in SJS/TEN has been demonstrated in retrospective studies. The largest such study to date comprised 48 patients with TEN recruited from centres across Europe and the United States. Treatment with IVIg resulted in a more rapid cessation of epidermal detachment and a survival rate of 88%. The authors subsequently recommended a dose of 1 g/kg/daily for 3 days (Prins, Vittorio et al. 2003). Studies have also demonstrated benefit when investigators have compared the rates of mortality following the use of IVIg with the pre-treatment estimate using SCORTEN (Campione, Marulli et al. 2003; Metry, Jung et al. 2003; Yang, Xu et al. 2009).

Despite the initial preponderance of evidence favouring the use of IVIg in SJS/TEN, a few published reports have not demonstrated any benefit. Most of these studies comparing the use of IVIg with supportive care alone used doses less than the recommended 2-3 g/kg. The largest retrospective analysis on the use of IVIg derived from the EuroSCAR study found no additional benefit from IVIg administered at a dose of 1.9 g/kg when compared to the use of supportive measures alone. This study involved the use of lower than recommended doses of IVIg and the patients from the IVIg group tended to have a greater TBSA involvement (Schneck, Fagot et al. 2008).

Randomized control studies are required using sufficient doses of IVIg to characterize its benefit in not only reducing mortality but also arresting the rate of progression and hastening the rate of re-epithelialization. However, the evidence thus far, would

suggest that it should be at least considered as part of the adjunctive therapy in the treatment of SJS/TEN.

#### **2.9.4 Cyclosporine**

Cyclosporine inhibits CD8 activation and subsequent release of granulysin, granzyme and perforin as well as inhibiting the proapoptotic effect of NF- $\kappa$ B. Several case and case series reports have shown arrest of disease progression and shorter time to re-epithelialization with doses varying from 3-10 mg/kg/daily for a period ranging from 8 days to several weeks. One study showed that outcomes for 10 patients treated with cyclosporine was superior to 6 patients treated with cyclophosphamide and corticosteroids with respect to re-epithelialization, disease progression and death (Arevalo, Lorente et al. 2000). However, randomised control studies are required to better define its benefits, the appropriate dose and duration of therapy. Furthermore, no studies have been published to date evaluating the efficacy of using both IVIg and cyclosporine but may be worthwhile considering as different pathways involved in the pathogenesis of SJS/TEN are targeted.

#### **2.9.5 Other pharmacotherapies**

Plasmapheresis and N-acetylcysteine-induced detoxification of drugs have demonstrated benefit in a small number of studies but larger randomized control studies are required to elucidate their role in the management of SJS/TEN. However, thalidomide, a potent inhibitor of TNF, was found in a double blinded randomised placebo controlled to be lethal in 10 of 12 patients as compared with 3 of 10 control subjects (Wolkenstein, Latarjet et al. 1998). The exact mechanism underlying these fatalities is unknown but the drug is firmly contraindicated in SJS/TEN.

#### **2.9.6 Restricted use of related medications**

In addition to the restricted use of the same medication, structurally similar drugs should also be avoided. The aromatic anticonvulsants carbamazepine, phenytoin and phenobarbital cross react with one another. Cross reactivity resulting in SJS/TEN can also occur across different classes of beta-lactam antibiotics, such as penicillins, cephalosporins and carbapenems. Administration of a structurally related drug can also result in different reactions. One case report described a patient with ceftriaxone-induced TEN who developed immediate anaphylaxis following the administration of piperacillin/tazobactam (Lam, Randhawa et al. 2008). The risk of SJS/TEN with structurally distinct agents within the same class of drug is less clear. For example, the cross reactivity between a propionic acid NSAID and an enolic acid NSAID is unknown. The safest practice is to restrict all NSAIDs following NSAID-induced SJS/TEN.

### **3. Drug induced hypersensitivity syndrome**

#### **3.1 Nosology**

The term hypersensitivity syndrome has been used for decades to describe a cutaneous drug reaction accompanied by involvement of internal organs. In 1938, Merritt and Putnam described a toxic reaction to phenytoin characterized by exfoliative dermatitis, fever and

eosinophilia (Merritt and Putnam 1938). This was distinguished from those patients who developed a mild, morbilliform rash. The anticonvulsant hypersensitivity syndrome was named in 1988 by Shear and Spielberg to refer the similar cutaneous and systemic manifestations of idiosyncratic reactions to a range of anticonvulsant medications including phenytoin, phenobarbital and carbamazepine (Shear and Spielberg 1988). In 1996, Bocquet et al introduced the term drug reaction with eosinophilia and systemic symptoms (DRESS) to distinguish it from drug-induced pseudolymphoma and other drug reactions that are not associated with eosinophilia (Bocquet, Bagot et al. 1996). Finally, Shiohara et al proposed the term drug induced hypersensitivity syndrome (DIHS) to include patients who may not have marked eosinophilia but have other evidence of leukocyte abnormalities, internal organ involvement and evidence of HHV-6 reactivation (Suzuki, Inagi et al. 1998; Shiohara, Inaoka et al. 2006).

### 3.2 Epidemiology

The incidence of DIHS is estimated to be between 1 in 1000 and 1 in 10000 to phenytoin (Gennis, Vemuri et al. 1991). The true incidence remains to be determined because of the variable presentations and the lack of universally accepted criteria. The JSCAR and RegiSCAR studies will provide more accurate reporting on the basis of stringent criteria. Preliminary data from the RegiSCAR study suggests that it affects males and females equally with a mean age of 47.4 years (range 3-84 years) (Mockenhaupt 2007).

### 3.3 Etiology and clinical features

Various diagnostic criteria have been proposed. Bocquet et al stipulated the presence of (1) cutaneous drug eruption; (2) hematologic abnormalities including eosinophilia greater than  $1.5 \times 10^9/L$  or the presence of atypical lymphocytes; and (3) systemic involvement including adenopathy greater than 2 cm in diameter, hepatitis (liver transaminase values  $>2$  normal), interstitial nephritis, interstitial pneumonia, or carditis.

Kardaun et al developed a scoring system to validate the diagnosis using fever  $\geq 38.5^\circ C$ , lymphadenopathy, eosinophilia  $\geq 700/\mu L$ , atypical lymphocytosis, extensive skin rash ( $>50\%$ ), visceral organ involvement (liver, kidney, lung, heart, pancreas), prolonged resolution of the rash ( $\geq 15$  days), and the absence of infectious diseases serology (hepatitis A, B and C, Epstein Barr virus, cytomegalovirus, mycoplasma and chlamydia), negative autoimmune serology (ANA) and negative blood cultures as supportive criteria (Kardaun, Sidoroff et al. 2007).

The potential role of HHV-6 in the pathogenesis of DIHS was incorporated into the criteria for DIHS by the JSCAR group (Shiohara, Iijima et al. 2007): (1) maculopapular rash developing more than 3 weeks after starting a limited number of drugs; (2) prolonged clinical symptoms 2 weeks after discontinuation of the causative drug; (3) fever greater than  $38^\circ C$ ; (4) liver abnormalities (eg, ALT levels  $>100 U/L$ ); (5) leukocyte abnormalities such as leukocytosis ( $>11 \times 10^9/L$ ), atypical lymphocytosis ( $>5\%$ ), and/or eosinophilia ( $>1.5 \times 10^9/L$ ); (6) lymphadenopathy; and (7) HHV-6 reactivation. Diagnosis of typical DIHS requires the presence of all 7 criteria. If criteria 1-5 are present only, then a diagnosis of atypical DIHS is made.

The syndrome typically begins 3 weeks to 3 months after commencing therapy with a limited number of drugs of which the most prominent ones are listed below.



Carbamazepine
Phenytoin
Phenobarbitol
Zonisamide
Lamotrigine
Allopurinol
Dapsone
Sulphasalazine
Mexiletine
Minocycline
Strontium ranelate
Abacavir

Table 3. The main causative drugs of DIHS

High-grade fever (38-40°C) is usually the first symptom followed by a pruritic maculopapular rash. Patients have facial oedema (Fig. 9), often with pinhead-sized pustules. The rash evolves, especially if the causative drug is not withdrawn into a severe exfoliative dermatitis (Fig. 10) or erythroderma with edematous, follicular and purpuric lesions. Cheilitis (Fig. 9), pharyngeal erythema and oral ulceration may occur but severe stomatitis is not present. Tender lymphadenopathy in more than two sites and bilateral swelling of salivary glands with xerostomia is evident early in the course of disease. Hepatosplenomegaly is a common finding. Leukocytosis with atypical lymphocytes and eosinophilia (60-70% of cases) is a prominent feature of this syndrome although the eosinophilia may not be observed for 1-2 weeks. Thrombocytopenia and anemia may also be present. Hypogammaglobulinemia is noted at the onset of disease with the nadir occurring several days after the withdrawal of the causative drug (Kano, Inaoka et al. 2004). An overshoot in the IgG level occurs 1-2 weeks after the nadir before returning to normal on full recovery. Internal organ involvement is summarised in table 4.

Manifestation	Comments
Hepatitis (mixed hepatocellular and cholestatic)	71%
Interstitial nephritis	11%, frequent with Allopurinol-induced DIHS
Pneumonitis/pleuritis	Common in minocycline and abacavir induced DIHS
Myocarditis	Occurs at onset or 40 days after onset of DIHS
Limbic encephalitis	2-4 weeks after onset of DIHS, HHV-6 reactivation in CSF May be associated with SiADH
CMV Gastrointestinal ulceration with bleeding	4-5 weeks after onset of DIHS
Haemaophagocytic syndrome	Rare, occurs 2 weeks after onset of DIHS
Parotid gland enlargement	Rare
Pancreatitis	Rare

Table 4. Internal organ involvement in DIHS

The onset of symptoms is variable with patients developing 2-3 symptomatic features followed by stepwise development of other manifestations. In most cases, withdrawal of the drug is not followed by rapid resolution of symptoms. Many patients may continue to deteriorate and show periodic relapses for weeks after the withdrawal of the causative drug.

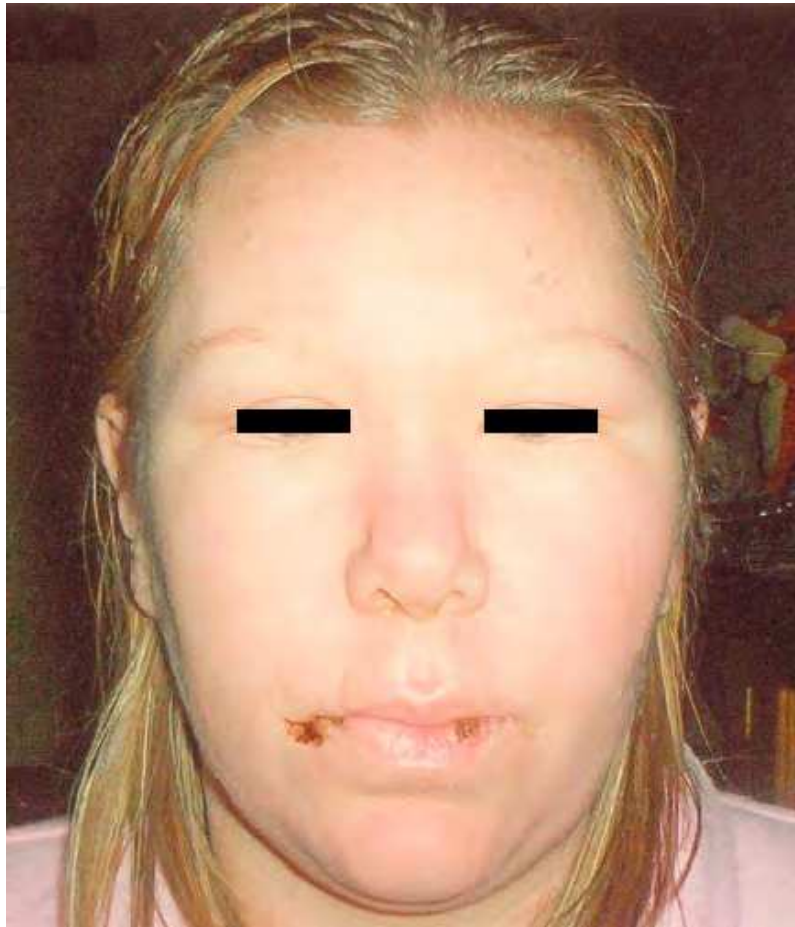

Fig. 9. Facial erythema and edema with labial ulceration in a young woman with DIHS/DRESS.

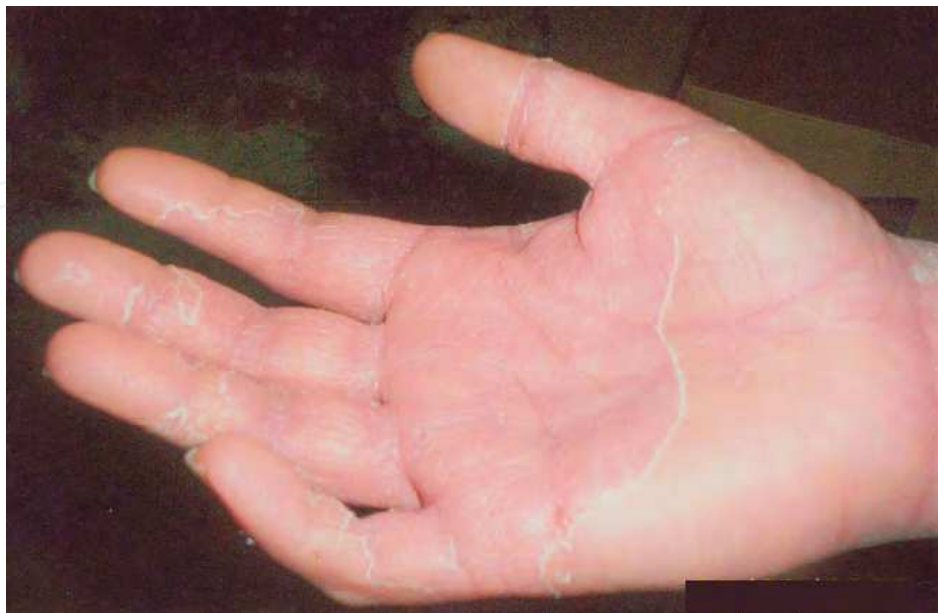

Fig. 10. Exfoliative dermatitis involving the hand in a young woman with DIHS/DRESS who had continued to ingest the culprit drug for 4 weeks when this image was taken.

Several reports have described the occurrence of autoantibody formation and autoimmune diseases up to 4 years after the acute resolution of DRESS (Aota and Shiohara 2009) and these include type 1 diabetes mellitus, autoimmune thyroid disease, scleroderma GVHD, SLE, and bullous pemphigoid. One of the likely explanations for the occurrence of autoimmune disease is the depletion of regulatory T cells upon recovery of disease.

Abacavir, an HIV nucleoside analogue reverse transcriptase inhibitor causes a potentially life-threatening hypersensitivity syndrome in approximately 5-8% of recipients within 6 weeks of therapy. The clinical and laboratory features of this syndrome differs from typical cases of DIHS/DRESS in that there is a predilection for the gastrointestinal system with nausea, abdominal pain, diarrhoea, and the respiratory tract with cough, pharyngitis and shortness of breath. Headache, myalgia and/or arthralgia may also be present. Eosinophilia is present in < 10% of cases and liver function test abnormalities are detected in < 20% of cases (Peyriere, Dereure et al. 2006). Also, the manifestations resolve within 72 hours rather than having a protracted relapsing course and the role of herpetic viruses in this condition is unknown.

### 3.4 Differential diagnosis

Viral infections such as EBV, CMV, and measles can be distinguished by the absence of eosinophilia, hypogammaglobulinemia, and supportive serology. In children, DIHS is differentiated from Kawasaki's disease by the absence of a bulbar conjunctivitis, strawberry tongue, coronary aneurysms, hypoalbuminemia and thrombocytosis. Serum sickness is characterized by urticarial lesions and the absence of internal organ involvement. Atopic erythroderma with bacterial infection does not usually involve hepatitis or nephritis. Drug-induced pseudolymphoma from carbamazepine or phenytoin is distinguished from DIHS by the absence of internal organ involvement and the prompt resolution of symptoms when the drug is withdrawn. Cutaneous B and T cell lymphomas have an indolent course and characteristic histopathology.

### 3.5 Pathology

The histopathology of DIHS is relatively non-specific and consists of a lymphocytic infiltrate that is superficial, perivascular, dense and diffuse. Eosinophils may be present but is often absent. The presence of loose rather than discrete granulomatous aggregates of histiocytes have been recently reported (Figs. 11 & 12) (Fernando, Henderson et al. 2009). HHV-6 and DNA from other herpes viruses may be detected in skin lesions by PCR or in situ hybridization (Suzuki, Inagi et al. 1998).

### 3.6 Drug allergy testing

#### 3.6.1 Patch tests

Santiago et al recently studied the utility of patch testing in DIHS and found a positive reaction in 32% of the 56 patients. Patch testing was performed between 6 weeks and 6 months after healing of the lesion and at least one month after corticosteroids were ceased. They found that 76% of the 17 patients with carbamazepine-induced DIHS were patch test positive but none of the 19 allopurinol-sensitive patients were positive to allopurinol and its metabolite, oxypurinol. No systemic reactions occurred during or after testing (Santiago, Goncalo et al. 2010). Hence patch testing may prove useful once the reagent and timing of such testing is optimized. Patch testing has, however, proven to be very useful in confirming suspected cases for abacavir hypersensitivity with a higher degree of specificity than can be confirmed clinically (Phillips, Wong et al. 2005).



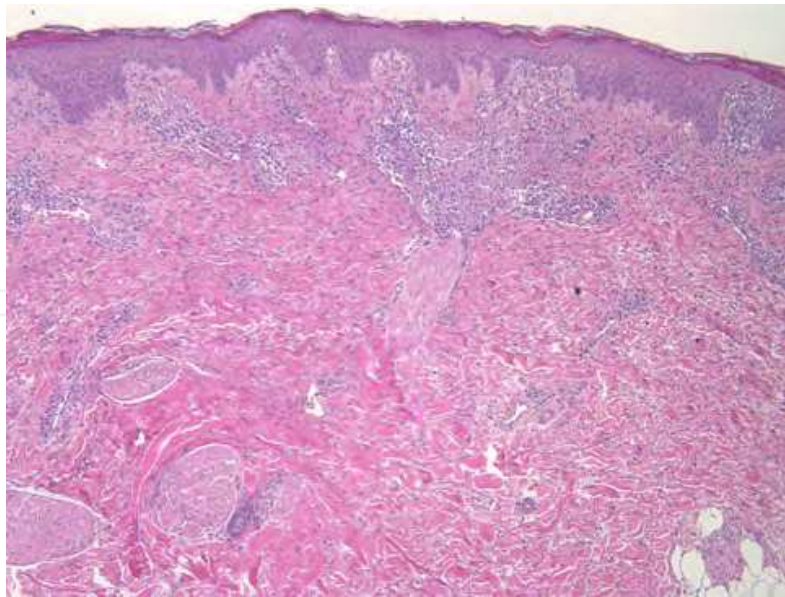


Fig. 11. Low power view of a skin biopsy from a patient with DIHS demonstrating the superficial dermal nature and perivascular distribution of the inflammatory infiltrate with acanthosis and hyperkeratosis of the epidermis (Hematoxylin-eosin, original magnification x40).

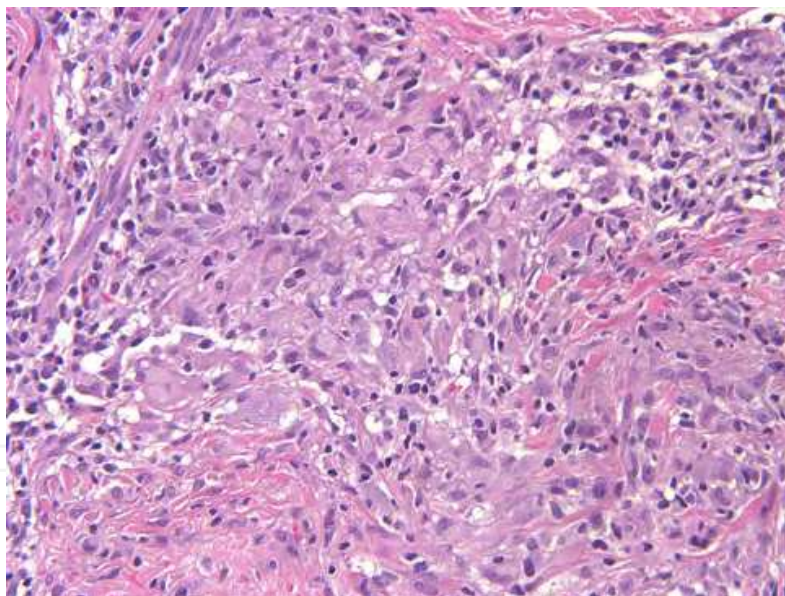


Fig. 12. High power view of a skin biopsy from a patient with DIHS demonstrates granulomatous inflammation with prominent, but relatively loosely aggregated histiocytes, mixed with lymphocytes. Eosinophils are absent (Hematoxylin-eosin, original magnification x200).

### 3.6.2 Lymphocyte transformation tests (LTTs)

LTTs are usually negative up to 3 weeks after the onset of DIHS but most patients are positive at 5-7 weeks and have persistent responses even at 1 year. Treatment with corticosteroids did not affect the results (Kano, Hirahara et al. 2007). One possible



explanation for the negative LTT result during the acute phase of DIHS is the expansion T regulatory cells with a naïve phenotype (CD4CD25FoxP3), which then are depleted by apoptosis during the recovery phase. These regulatory T cells are capable of suppressing proliferation of memory T cells in LTTs (Takahashi, Kano et al. 2009).

### 3.7 Pathogenesis

The pathogenesis of DIHS is still to be fully elucidated. The precise role of HHV-6 in DIHS is unclear. The initiating event may be the reactivation of one or more herpetic viruses, which is clinically unapparent (Fig. 13). Virus-stimulated T cells may then cross react with drug-derived hapten-protein conjugates that are presented by dendritic cells to naïve antigen-specific CD4 T-cells with the subsequent differentiation into effector/memory CD4 cells. These dendritic cells may also activate CD8 T-cells by cross-presentation. The expansion of effector CD4 T-cells with their production of IFN- $\gamma$  and other cytokines results in recruitment and activation of macrophages. Failure to eradicate the antigenic stimulus, in this instance due to the continued ingestion of the drug, causes persistent cytokine release and promotes differentiation of macrophages into epithelioid cells, which secrete large amounts of TNF promoting their fusion to form multinucleate giant cells (Fernando, Henderson et al. 2009). Analogous to that observed in GVHD, longitudinal real-time PCR analyses of viral loads in blood samples drawn from patients with DIHS show that various herpetic viruses are sequentially activated as a result of massive T cell stimulation, B cell loss and hypogammaglobulinemia (Hirahara, Kano et al. 2010); Activation of Epstein-Barr virus or HHV-6 extends to the sequential activation of HHV-7, cytomegalovirus and varicella-zoster virus (Kano, Inaoka et al. 2004). The frequent deterioration or several exacerbations that occur despite continuation of the drug may at least be partly explained by sequential reactivation of herpetic viruses and the immune response to viral replication. An alternative explanation is that drug specific T cells are activated resulting in reactivation of the viral genome and sequential reactivation of herpes viruses (Fig. 14).

Genetic susceptibility may also play a role as all patients with allopurinol-induced DIHS in a Han Chinese population harboured the *HLA-B\*5801* allele compared with 15% of control subjects (Hung, Chung et al. 2005b). Recently, an association was described between *HLA-A\*3101* and DIHS in Northern Europeans; OR 12.41 [1.27-121.03] (McCormack, Alfirevic et al. 2011) and in the Japanese; OR 9.5 [4.6-19.5] (Ozeki, Mushiroda et al. 2011). In a Western Australian HIV Cohort Study, *HLA-B\*5701* was present in 14 (78%) of the 18 patients with abacavir hypersensitivity, and in four (2%) of the 167 abacavir tolerant patients; OR 117 [29-481] (Mallal, Nolan et al. 2002). There is a discrepancy in the association of *HLA-B\*5701* and abacavir hypersensitivity across various racial groups. The association was confirmed in a separate cohort of HIV-infected white Americans and was also found to confer susceptibility in Hispanics but not in blacks (Hughes, Mosteller et al. 2004). No association was found in a cohort of Korean patients (Park, Choe et al. 2009). The racial variation may be partly explained by the differences in MHC haplotypes across different racial groups. The Caucasian 57.1 ancestral haplotype, which confers susceptibility to abacavir hypersensitivity possibly as a result of strong linkage disequilibrium with other candidate genetic factors such as cellular chaperones (e.g. heat shock proteins), inflammatory cytokines (e.g. TNF), and proteins involved in the stress response (e.g. MHC class I chain-related genes, MIC-A and MIC-B). African populations do not demonstrate this haplotype (Cao, Hollenbach et al. 2001). However, in a recent study by Saag et al, all 42 white patients with immunologically confirmed (i.e. positive patch tests) hypersensitivity to abacavir reactions were *HLA-B\*5701*

positive (sensitivity 100%, OR 1945 [110-34,352]) but in addition all 5 black patients with immunologically confirmed hypersensitivity reactions were *HLA-B\*5701* positive (sensitivity 100%, OR 900 [ 38-21,045]. Screening for the *HLA-B\*5701* has eliminated immunologically confirmed cases of abacavir hypersensitivity (Mallal, Phillips et al. 2008).

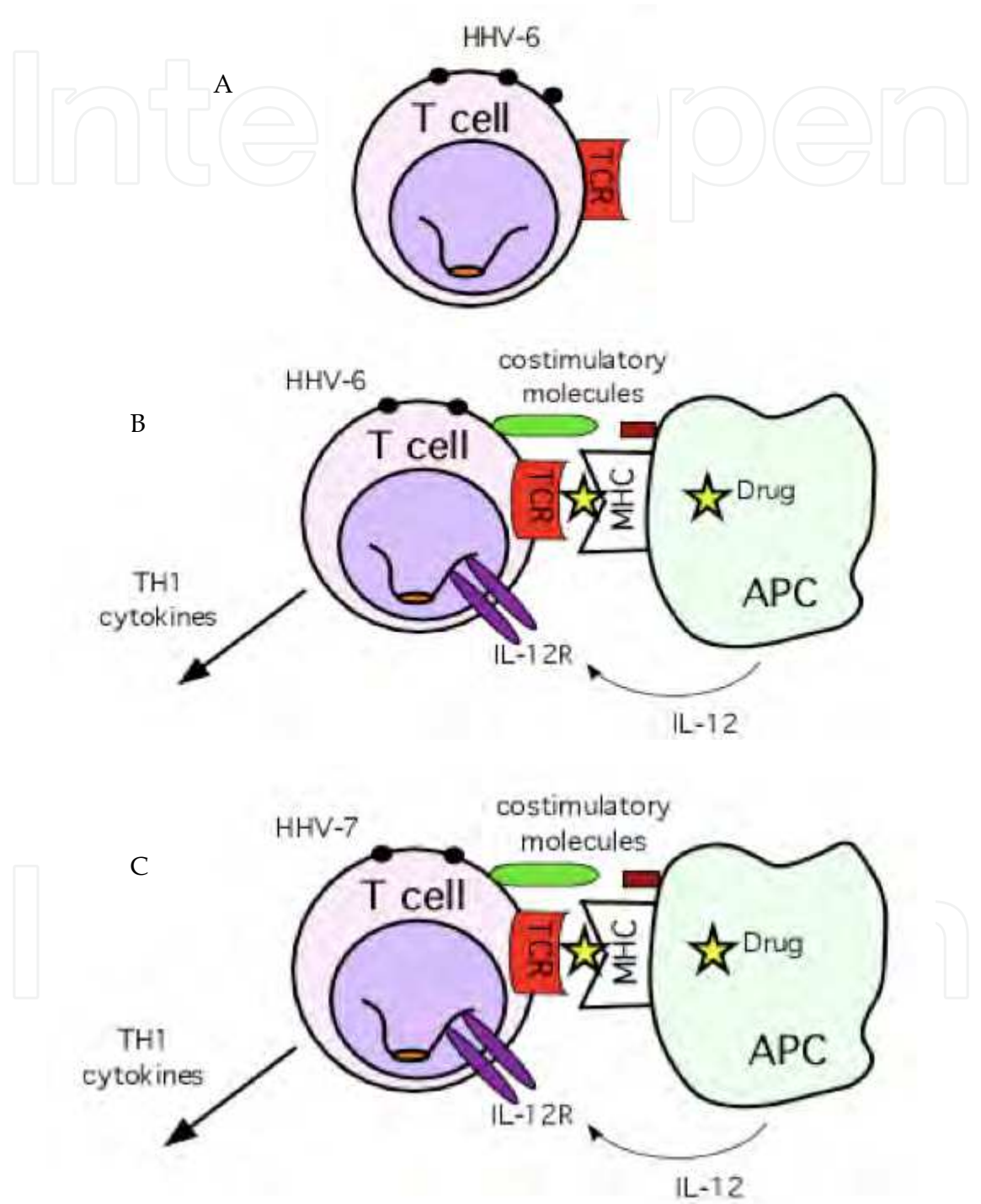


Fig. 13. One theory of the role of herpetic viruses in the pathogenesis of DIHS is the reactivation of HHV-6 within the T cell genome (A), which cross react with the culprit drug (B) resulting in the sequential activation of heterologous herpetic viruses (C).

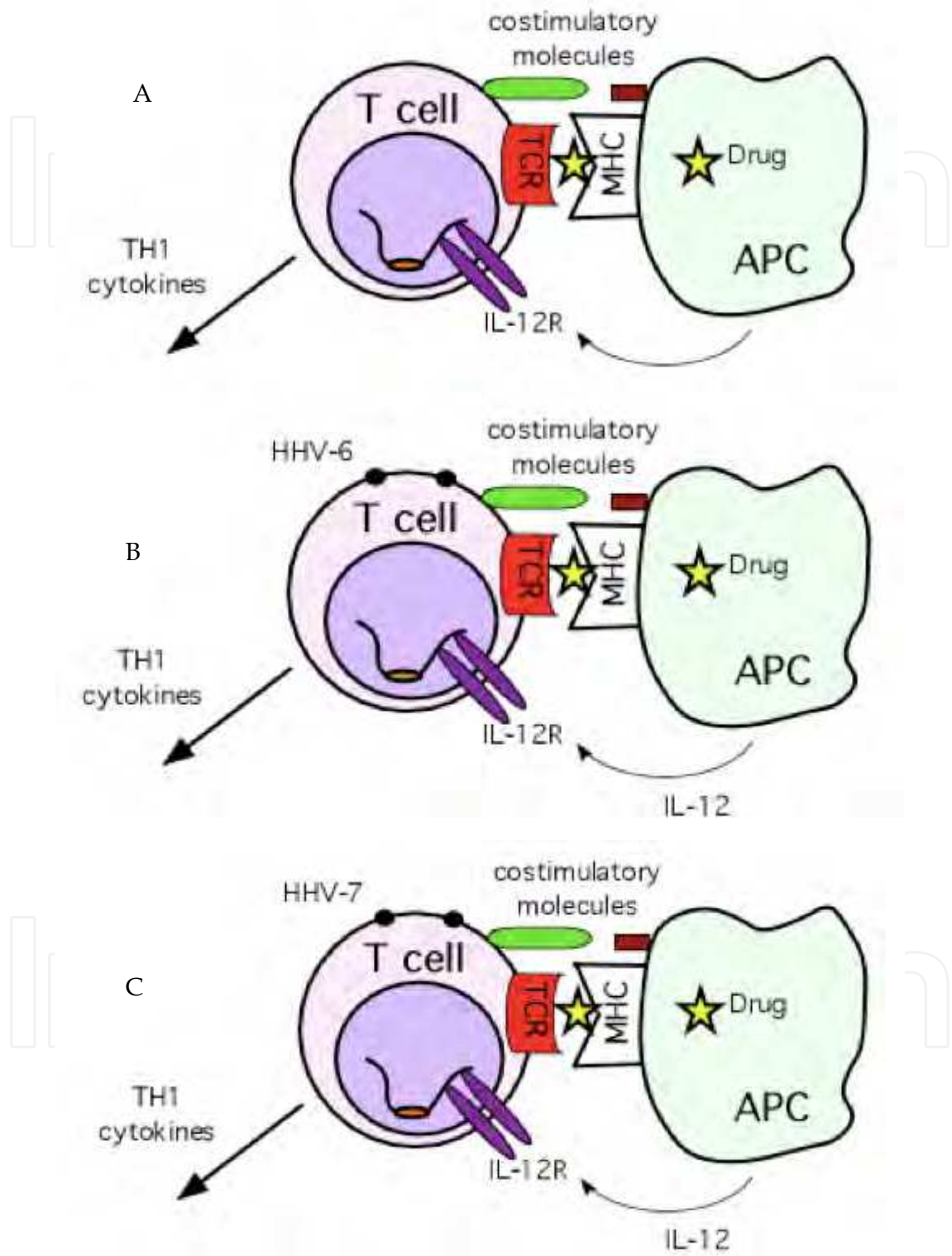


Fig. 14. An alternative theory proposes that drug-specific T cells are activated (A) resulting in reactivation of HHV-6 from within the T cell genome (B) with subsequent sequential reactivation of heterologous herpetic viruses (C).

### 3.8 Treatment

Early recognition of the syndrome with cessation of the causative drug is essential in improving patient outcomes. No randomized controlled trials have been conducted to determine the appropriate adjunctive therapy for DIHS. Oral corticosteroids at 1 mg/kg/daily is commenced and tapered over at least 6-8 weeks to prevent relapse of various cutaneous and visceral manifestations of the syndrome. If symptoms deteriorate despite corticosteroid therapy then IVIg, plasma exchange (Higuchi, Agatsuma et al. 2005), rituximab or a combination of these modalities could be considered although the evidence for their use is currently scant.

## 4. Acute generalized exanthematous pustulosis

### 4.1 Nosology

In 1980, Beylot et al introduced the term acute generalized exanthematous pustulosis (AGEP) to describe acute pustular reactions with distinct clinical and histological features thereby differentiating it from pustular psoriasis (Beylot, Bioulac et al. 1980).

### 4.2 Demography

AGEP is rare with an incidence of 1-5 cases per million per year (Sidoroff, Halevy et al. 2001). The EuroSCAR study comprising 97 validated cases of AGEP recruited from Austria, France, Israel, Italy and the Netherlands, revealed a mean age ( $\pm$ SD) of 56 ( $\pm$ 21) years and a female preponderance with a male/female ratio of 0.8 (Sidoroff, Dunant et al. 2007). The predominance in women was shown to be even greater in case series reports from Taiwan (68.7% of 16 cases) (Chang, Huang et al. 2008), and Israel (76.9% of 13 cases) (Davidovici, Dodiuk-Gad et al. 2008). AGEP has been reported in children, with the largest pediatric series of 20 cases from China (Zhang, Chen et al. 2008).

### 4.3 Clinical features

The clinical manifestations are characterized by fever and a pruritic or burning edematous erythema followed by the rapid appearance of dozens of small (< 5 mm) non-follicular sterile pustules (Fig. 15). The skin lesions are often accentuated in the intertriginous areas.

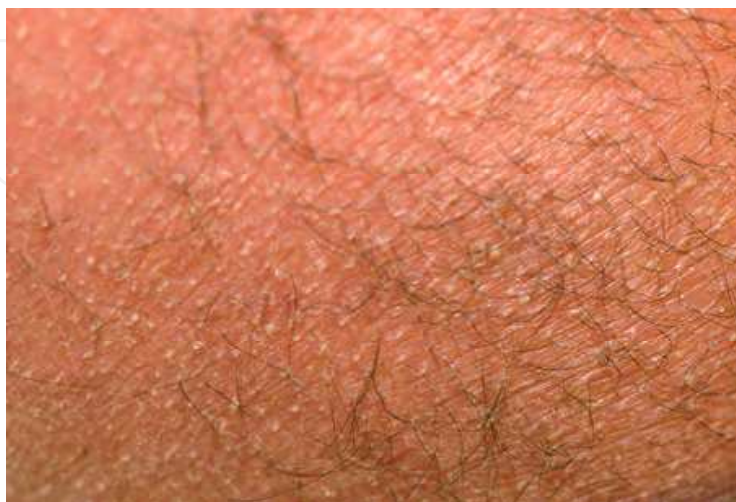

Fig. 15. The lesions of AGEP occur rapidly and are characterized by dozens of small (< 5 mm) non-follicular sterile pustules.



There is usually an accompanying marked neutrophilia ( $7 \times 10^9/L$ ) and in a third of cases, a mild eosinophilia. A mild non-erosive mucous membrane involvement occurs in 20% of cases. Internal organ involvement is uncommon and usually is confined to a slight reduction in creatinine clearance and mild elevation of aminotransferases. The clinical course is characterized by spontaneous resolution of skin and systemic manifestations over a period of up to 15 days once the offending agent is withdrawn. AGEP has a favourable prognosis; the reported mortality rate is up to 5% and poor outcomes usually result from secondary infection in the elderly or those patients with significant comorbidities.

#### 4.4 Etiology

AGEP is caused by drugs in at least 90% of cases. According to the EuroSCAR study, the agents conferring the highest risk are pristinamycin, aminopenicillins, hydroxychloroquine, antibacterial sulphonamides, terbinafine and diltiazem (Sidoroff, Dunant et al. 2007). The latent period is short (usually 1-5 days) with the EuroScar study demonstrating that it may vary for different drugs. For antibiotics, including sulphonamides, the median latent period was 1 day, and for other drugs it was 11 days (Sidoroff, Dunant et al. 2007).

Contact sensitivity has been implicated in a few case reports. Causative agents include mercury, and bufexamac, a potent topical NSAID. Neither of these agents was implicated in the 97 cases of AGEP in the EuroScar study. The role of infectious agents in AGEP has been suggested in various case reports due to the absence of an inciting drug. The organisms include coxsackie B4, cytomegalovirus, parvovirus B19, *Chlamydia pneumoniae*, and *Escherichia coli*. No significant risk for infection was found in the EuroScar study although the study was not designed to identify potential causative organisms. Spider bites were suggested as a cause AGEP in a series of three cases from Israel, presumably as a result of the venom's ability to induce IL-8 and GM-CSF (Davidovici, Pavel et al. 2006). Finally, as illustrated in two recent cases, AGEP may develop without preceding medication or disease (Birnie and Littlewood 2008).

#### 4.5 Pathogenesis

The pathogenesis of AGEP has been elucidated by patch (Schaerli, Britschgi et al. 2004) and in vitro tests (Girardi, Duncan et al. 2005) and initially involves activation, expansion and subsequent migration of drug-specific CD4 and CD8 cells to the skin. The initial influx of CD8 cytotoxic T cells results in apoptosis of keratinocytes and the formation of subcorneal vesicles. The infiltrating CD4 cells release CXCL-8, which results in recruitment of neutrophils, and granulocyte macrophage-colony stimulating factor (GM-CSF), which prevents apoptosis of neutrophils. This results in the conversion of vesicles into pustules. CD4 cells also release IFN- $\gamma$ , which stimulates keratinocytes to secrete CXCL-8, as well as RANTES and IL-5, which contributes to the eosinophilia observed in some patients (Britschgi, Steiner et al. 2001). Resident Langerhans' cells may present drug antigens to CD4 cells and keratinocytes may act as antigen presenting cells to CD8 cells thereby augmenting the neutrophil-mediated inflammatory response. Genetic susceptibility to AGEP has not been robustly examined and therefore remains largely unknown.

#### 4.6 Diagnostic tests

A pustular smear should be performed to exclude an infectious aetiology. A full blood count will reveal a neutrophilia. A skin biopsy may show (spongiform or non-

spongiform) subcorneal and/or intradermal pustules, edema of the papillary dermis, perivascular infiltrates with neutrophils and exocytosis of some eosinophils and focal necrotic keratinocytes (Fig. 16). The typical changes of psoriasis such as acanthosis and papillomatosis are usually absent. Patch testing may be useful in confirming the association between AGEP and the culprit drugs. In a controlled study, patch tests were positive in half of the 14 cases of AGEP (Wolkenstein, Chosidow et al. 1996). Readings should not be restricted to 24 and 48 hours after the application of the drug but should also be determined at 96 and 120 hours to maximise sensitivity. Pustule formation is often observed in positive patch tests in cases of AGEP. The test can be conducted one month after resolution of the disease. The risk of AGEP with patch testing is considered to be low but not negligible (Mashiah and Brenner 2003). A small number of studies have supported a role for LTT, IFN- $\gamma$  release, lymphokine macrophage migration inhibition factor release assays but these in vitro tests are not widely available and its value remains to be determined in large cohorts.

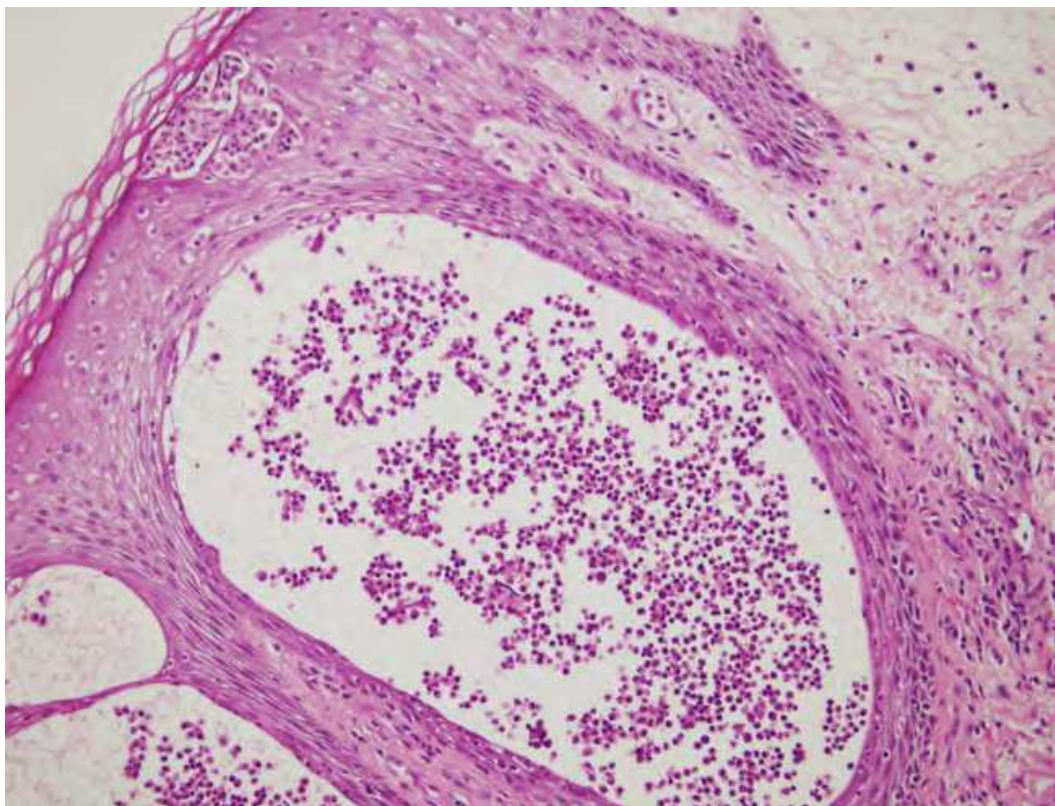


Fig. 16. A moderate power view of a skin biopsy from a patient with AGEP shows spongiform subcorneal pustules, edema of the papillary dermis and perivascular infiltrates with neutrophils and exocytosis of some eosinophils.

#### 4.7 Differential diagnosis

AGEP, which is characterized by non-follicular pustules can be readily distinguished from diseases with follicular pustulosis such as bacterial folliculitis, furunculosis, acneiform eruptions, pustular contact dermatitis, dermatophyte infection, viral exanthema with primary vesiculation and secondary postulation, impetigo, Sweet syndrome and SSSS. Other diseases are not as easily differentiated from AGEP. Generalized pustular psoriasis

(Zumbusch psoriasis) is characterized by pustules that slowly develop on areas of psoriasis accompanied by the histological changes of psoriasis on skin biopsy. There is also usually a family history of psoriasis. Sneddon-Wilkinson disease (subcorneal pustulosis) and subcorneal IgA dermatosis are characterized by the subacute development of larger pustules than those that erupt in AGEF and maybe associated with hyopyon formation. A diagnostic score was devised to validate the diagnosis of AGEF based on the morphology, course of disease, and histology, and assist in the differentiation from similar diseases (Sidoroff, Halevy et al. 2001).

#### 4.8 Treatment

As AGEF is a self-limiting disease with a favourable prognosis. Cessation of the causative agent and supportive treatment is usually all that is required. In the pustular phase, supportive measures consist of moist dressings with drying and disinfecting solutions to avoid superinfection. In the postpustular desquamation phase, emollients are used to optimise preservation of skin barrier function. In a study of nine cases from Israel, all of who made a full recovery, seven received supportive care alone and the other two received corticosteroids (Tamir, Wohl et al. 2006). It remains to be established whether oral or parenteral corticosteroids hasten the resolution of disease. A brief course of systemic corticosteroids may be considered in patients with severe and widespread inflammation of the skin.

### 5. Conclusion

SCARs such as SJS/TEN, DIHS/DRESS, and AGEF are idiosyncratic and specific types of reactions that have distinct clinical, laboratory and histological features. The definition of DIHS/DRESS has not been universally adopted and will need to be clarified once the role of herpetic viruses and characteristic histological features are known. The early identification of these reactions and the subsequent prompt withdrawal of therapy and the implementation of supportive and adjunctive therapies are crucial in minimising morbidity and rates of mortality. Multicentre randomized studies are required to adopt the most suitable therapies for these potentially life-threatening conditions. The emergence in the understanding of HLA susceptibility genes will enable patients to be screened for the risk of developing a SCAR and will hopefully be more widely performed once cost effective and rapid methods of detection are widely available to the prescribing doctor.

### 6. References

- Abe, R., Shimizu, T., Shibaki, A., Nakamura, H., Watanabe, H. and Shimizu, H. (2003). Toxic epidermal necrolysis and Stevens-Johnson syndrome are induced by soluble Fas ligand. *Am J Pathol* 162(5): 1515-1520
- Abe, R., Yoshioka, N., Murata, J., Fujita, Y. and Shimizu, H. (2009). Granulysin as a marker for early diagnosis of the Stevens-Johnson syndrome. *Ann Intern Med* 151(7): 514-515



- Abood, G. J., Nickoloff, B. J. and Gamelli, R. L. (2008). Treatment strategies in toxic epidermal necrolysis syndrome: where are we at? *J Burn Care Res* 29(1): 269-276
- Aota, N. and Shiohara, T. (2009). Viral connection between drug rashes and autoimmune diseases: how autoimmune responses are generated after resolution of drug rashes. *Autoimmun Rev* 8(6): 488-494
- Araki, Y., Sotozono, C., Inatomi, T., Ueta, M., Yokoi, N., Ueda, E., Kishimoto, S. and Kinoshita, S. (2009). Successful treatment of Stevens-Johnson syndrome with steroid pulse therapy at disease onset. *Am J Ophthalmol* 147(6): 1004-1011, 1011 e1001
- Arevalo, J. M., Lorente, J. A., Gonzalez-Herrada, C. and Jimenez-Reyes, J. (2000). Treatment of toxic epidermal necrolysis with cyclosporin A. *J Trauma* 48(3): 473-478
- Atiyeh, B. S., Dham, R., Yassin, M. F. and El-Musa, K. A. (2003). Treatment of toxic epidermal necrolysis with moisture-retentive ointment: a case report and review of the literature. *Dermatol Surg* 29(2): 185-188
- Ball, R., Ball, L. K., Wise, R. P., Braun, M. M., Beeler, J. A. and Salive, M. E. (2001). Stevens-Johnson syndrome and toxic epidermal necrolysis after vaccination: reports to the vaccine adverse event reporting system. *Pediatr Infect Dis J* 20(2): 219-223
- Bastuji-Garin, S., Fouchard, N., Bertocchi, M., Roujeau, J. C., Revuz, J. and Wolkenstein, P. (2000). SCORTEN: a severity-of-illness score for toxic epidermal necrolysis. *J Invest Dermatol* 115(2): 149-153
- Bastuji-Garin, S., Rzany, B., Stern, R. S., Shear, N. H., Naldi, L. and Roujeau, J. C. (1993). Clinical classification of cases of toxic epidermal necrolysis, Stevens-Johnson syndrome, and erythema multiforme. *Arch Dermatol* 129(1): 92-96
- Beylot, C., Bioulac, P. and Doutre, M. S. (1980). [Acute generalized exanthematic pustuloses (four cases) (author's transl)]. *Ann Dermatol Venereol* 107(1-2): 37-48
- Birnie, A. J. and Littlewood, S. M. (2008). Acute generalized exanthematous pustulosis does not always have a drug-related cause. *Br J Dermatol* 159(2): 492-493
- Bocquet, H., Bagot, M. and Roujeau, J. C. (1996). Drug-induced pseudolymphoma and drug hypersensitivity syndrome (Drug Rash with Eosinophilia and Systemic Symptoms: DRESS). *Semin Cutan Med Surg* 15(4): 250-257
- Britschgi, M., Steiner, U. C., Schmid, S., Depta, J. P., Senti, G., Bircher, A., Burkhart, C., Yawalkar, N. and Pichler, W. J. (2001). T-cell involvement in drug-induced acute generalized exanthematous pustulosis. *J Clin Invest* 107(11): 1433-1441
- Campione, E., Marulli, G. C., Carrozzo, A. M., Chimenti, M. S., Costanzo, A. and Bianchi, L. (2003). High-dose intravenous immunoglobulin for severe drug reactions: efficacy in toxic epidermal necrolysis. *Acta Derm Venereol* 83(6): 430-432
- Cao, K., Hollenbach, J., Shi, X., Shi, W., Chopek, M. and Fernandez-Vina, M. A. (2001). Analysis of the frequencies of HLA-A, B, and C alleles and haplotypes in the five major ethnic groups of the United States reveals high levels of diversity in these loci and contrasting distribution patterns in these populations. *Hum Immunol* 62(9): 1009-1030



- Chang, S. L., Huang, Y. H., Yang, C. H., Hu, S. and Hong, H. S. (2008). Clinical manifestations and characteristics of patients with acute generalized exanthematous pustulosis in Asia. *Acta Derm Venereol* 88(4): 363-365
- Chen, P., Lin, J. J., Lu, C. S., Ong, C. T., Hsieh, P. F., Yang, C. C., Tai, C. T., Wu, S. L., Lu, C. H., Hsu, Y. C., Yu, H. Y., Ro, L. S., Lu, C. T., Chu, C. C., Tsai, J. J., Su, Y. H., Lan, S. H., Sung, S. F., Lin, S. Y., Chuang, H. P., Huang, L. C., Chen, Y. J., Tsai, P. J., Liao, H. T., Lin, Y. H., Chen, C. H., Chung, W. H., Hung, S. I., Wu, J. Y., Chang, C. F., Chen, L., Chen, Y. T. and Shen, C. Y. (2011). Carbamazepine-induced toxic effects and HLA-B\*1502 screening in Taiwan. *N Engl J Med* 364(12): 1126-1133
- Chung, W. H., Hung, S. I., Hong, H. S., Hsieh, M. S., Yang, L. C., Ho, H. C., Wu, J. Y. and Chen, Y. T. (2004). Medical genetics: a marker for Stevens-Johnson syndrome. *Nature* 428(6982): 486
- Chung, W. H., Hung, S. I., Yang, J. Y., Su, S. C., Huang, S. P., Wei, C. Y., Chin, S. W., Chiou, C. C., Chu, S. C., Ho, H. C., Yang, C. H., Lu, C. F., Wu, J. Y., Liao, Y. D. and Chen, Y. T. (2008). Granulysin is a key mediator for disseminated keratinocyte death in Stevens-Johnson syndrome and toxic epidermal necrolysis. *Nat Med* 14(12): 1343-1350
- Cote, B., Wechsler, J., Bastuji-Garin, S., Assier, H., Revuz, J. and Roujeau, J. C. (1995). Clinicopathologic correlation in erythema multiforme and Stevens-Johnson syndrome. *Arch Dermatol* 131(11): 1268-1272
- Davidovici, B., Dodiuk-Gad, R., Rozenman, D. and Halevy, S. (2008). Profile of acute generalized exanthematous pustulosis in Israel during 2002-2005: results of the RegiSCAR Study. *Isr Med Assoc J* 10(6): 410-412
- Davidovici, B. B., Pavel, D., Cagnano, E., Rozenman, D. and Halevy, S. (2006). Acute generalized exanthematous pustulosis following a spider bite: report of 3 cases. *J Am Acad Dermatol* 55(3): 525-529
- Deng, A., Chen, S., Li, Q., Lyu, S. C., Clayberger, C. and Krensky, A. M. (2005). Granulysin, a cytolytic molecule, is also a chemoattractant and proinflammatory activator. *J Immunol* 174(9): 5243-5248
- Dietrich, A., Kawakubo, Y., Rzany, B., Mockenhaupt, M., Simon, J. C. and Schopf, E. (1995). Low N-acetylating capacity in patients with Stevens-Johnson syndrome and toxic epidermal necrolysis. *Exp Dermatol* 4(5): 313-316
- Dincer, H. E., Dincer, A. P. and Levinson, D. J. (2002). Asymptomatic hyperuricemia: to treat or not to treat. *Cleve Clin J Med* 69(8): 594, 597, 600-592 passim
- Engelhardt, S. L., Schurr, M. J. and Helgersson, R. B. (1997). Toxic epidermal necrolysis: an analysis of referral patterns and steroid usage. *J Burn Care Rehabil* 18(6): 520-524
- Fernando, S. L. and Broadfoot, A. J. (2010). Prevention of severe cutaneous adverse drug reactions: the emerging value of pharmacogenetic screening. *Cmaj* 182(5): 476-480
- Fernando, S. L., Henderson, C. J. and O'Connor, K. S. (2009). Drug-induced hypersensitivity syndrome with superficial granulomatous dermatitis--a novel finding. *Am J Dermatopathol* 31(6): 611-613

- Gamen, S., Hanson, D. A., Kaspar, A., Naval, J., Krensky, A. M. and Anel, A. (1998). Granulysin-induced apoptosis. I. Involvement of at least two distinct pathways. *J Immunol* 161(4): 1758-1764
- Gennis, M. A., Vemuri, R., Burns, E. A., Hill, J. V., Miller, M. A. and Spielberg, S. P. (1991). Familial occurrence of hypersensitivity to phenytoin. *Am J Med* 91(6): 631-634
- Ginsburg, C. M. (1982). Stevens-Johnson syndrome in children. *Pediatr Infect Dis* 1(3): 155-158
- Girardi, M., Duncan, K. O., Tigelaar, R. E., Imaeda, S., Watsky, K. L. and McNiff, J. M. (2005). Cross-comparison of patch test and lymphocyte proliferation responses in patients with a history of acute generalized exanthematous pustulosis. *Am J Dermatopathol* 27(4): 343-346
- Guegan, S., Bastuji-Garin, S., Poszepczynska-Guigne, E., Roujeau, J. C. and Revuz, J. (2006). Performance of the SCORTEN during the first five days of hospitalization to predict the prognosis of epidermal necrolysis. *J Invest Dermatol* 126(2): 272-276
- Haleblian, P. H., Corder, V. J., Madden, M. R., Finklestein, J. L. and Shires, G. T. (1986). Improved burn center survival of patients with toxic epidermal necrolysis managed without corticosteroids. *Ann Surg* 204(5): 503-512
- Halevy, S., Ghislain, P. D., Mockenhaupt, M., Fagot, J. P., Bouwes Bavinck, J. N., Sidoroff, A., Naldi, L., Dunant, A., Viboud, C. and Roujeau, J. C. (2008). Allopurinol is the most common cause of Stevens-Johnson syndrome and toxic epidermal necrolysis in Europe and Israel. *J Am Acad Dermatol* 58(1): 25-32
- Higuchi, M., Agatsuma, T., Iizima, M., Yamazaki, Y., Saita, T., Ichikawa, T., Kamijo, Y., Arakura, H., Hora, K. and Kiyosawa, K. (2005). A case of drug-induced hypersensitivity syndrome with multiple organ involvement treated with plasma exchange. *Ther Apher Dial* 9(5): 412-416
- Hirahara, K., Kano, Y., Mitsuyama, Y., Takahashi, R., Kimishima, M. and Shiohara, T. (2010). Differences in immunological alterations and underlying viral infections in two well-defined severe drug eruptions. *Clin Exp Dermatol* 35(8): 863-868
- House, R. A., Jakubovic, H., Wong, L. and Holness, D. L. (1992). Work-related toxic epidermal necrolysis? *J Occup Med* 34(2): 135-139
- Hughes, A. R., Mosteller, M., Bansal, A. T., Davies, K., Haneline, S. A., Lai, E. H., Nangle, K., Scott, T., Spreen, W. R., Warren, L. L. and Roses, A. D. (2004). Association of genetic variations in HLA-B region with hypersensitivity to abacavir in some, but not all, populations. *Pharmacogenomics* 5(2): 203-211
- Hung, S. I., Chung, W. H. and Chen, Y. T. (2005a). HLA-B genotyping to detect carbamazepine induced Stevens-Johnson syndrome: implications for personalizing medicine. *Personalized Med.* 2: 225-237
- Hung, S. I., Chung, W. H. and Chen, Y. T. (2007). Genetics of severe drug hypersensitivity reactions in Han Chinese. *Drug Hypersensitivity*. Pichler, W. J. Basel., Karger.: 105-114.
- Hung, S. I., Chung, W. H., Jee, S. H., Chen, W. C., Chang, Y. T., Lee, W. R., Hu, S. L., Wu, M. T., Chen, G. S., Wong, T. W., Hsiao, P. F., Chen, W. H., Shih, H. Y., Fang, W. H.,

- Wei, C. Y., Lou, Y. H., Huang, Y. L., Lin, J. J. and Chen, Y. T. (2006). Genetic susceptibility to carbamazepine-induced cutaneous adverse drug reactions. *Pharmacogenet Genomics* 16(4): 297-306
- Hung, S. I., Chung, W. H., Liou, L. B., Chu, C. C., Lin, M., Huang, H. P., Lin, Y. L., Lan, J. L., Yang, L. C., Hong, H. S., Chen, M. J., Lai, P. C., Wu, M. S., Chu, C. Y., Wang, K. H., Chen, C. H., Fann, C. S., Wu, J. Y. and Chen, Y. T. (2005b). HLA-B\*5801 allele as a genetic marker for severe cutaneous adverse reactions caused by allopurinol. *Proc Natl Acad Sci U S A* 102(11): 4134-4139
- Kakourou, T., Klontza, D., Soteropoulou, F. and Kattamis, C. (1997). Corticosteroid treatment of erythema multiforme major (Stevens-Johnson syndrome) in children. *Eur J Pediatr* 156(2): 90-93
- Kaniwa, N., Saito, Y., Aihara, M., Matsunaga, K., Tohkin, M., Kurose, K., Sawada, J., Furuya, H., Takahashi, Y., Muramatsu, M., Kinoshita, S., Abe, M., Ikeda, H., Kashiwagi, M., Song, Y., Ueta, M., Sotozono, C., Ikezawa, Z. and Hasegawa, R. (2008). HLA-B locus in Japanese patients with anti-epileptics and allopurinol-related Stevens-Johnson syndrome and toxic epidermal necrolysis. *Pharmacogenomics* 9(11): 1617-1622
- Kano, Y., Hirahara, K., Mitsuyama, Y., Takahashi, R. and Shiohara, T. (2007). Utility of the lymphocyte transformation test in the diagnosis of drug sensitivity: dependence on its timing and the type of drug eruption. *Allergy* 62(12): 1439-1444
- Kano, Y., Inaoka, M. and Shiohara, T. (2004). Association between anticonvulsant hypersensitivity syndrome and human herpesvirus 6 reactivation and hypogammaglobulinemia. *Arch Dermatol* 140(2): 183-188
- Kardaun, S. H., Sidoroff, A., Valeyrie-Allanore, L., Halevy, S., Davidovici, B. B., Mockenhaupt, M. and Roujeau, J. C. (2007). Variability in the clinical pattern of cutaneous side-effects of drugs with systemic symptoms: does a DRESS syndrome really exist? *Br J Dermatol* 156(3): 609-611
- Khoo, B. P. and Leow, Y. H. (2000). A review of inpatients with adverse drug reactions to allopurinol. *Singapore Med J* 41(4): 156-160
- Kumar, A., Edward, N., White, M. I., Johnston, P. W. and Catto, G. R. (1996). Allopurinol, erythema multiforme, and renal insufficiency. *Bmj* 312(7024): 173-174
- Lam, A., Randhawa, I. and Klaustermeyer, W. (2008). Cephalosporin induced toxic epidermal necrolysis and subsequent penicillin drug exanthem. *Allergol Int* 57(3): 281-284
- Lam, N. S., Yang, Y. H., Wang, L. C., Lin, Y. T. and Chiang, B. L. (2004). Clinical characteristics of childhood erythema multiforme, Stevens-Johnson syndrome and toxic epidermal necrolysis in Taiwanese children. *J Microbiol Immunol Infect* 37(6): 366-370
- Lebargy, F., Wolkenstein, P., Gisselbrecht, M., Lange, F., Fleury-Feith, J., Delclaux, C., Roupie, E., Revuz, J. and Roujeau, J. C. (1997). Pulmonary complications in toxic epidermal necrolysis: a prospective clinical study. *Intensive Care Med* 23(12): 1237-1244

- Letko, E., Papaliadis, D. N., Papaliadis, G. N., Daoud, Y. J., Ahmed, A. R. and Foster, C. S. (2005). Stevens-Johnson syndrome and toxic epidermal necrolysis: a review of the literature. *Ann Allergy Asthma Immunol* 94(4): 419-436; quiz 436-418, 456
- Levi, N., Bastuji-Garin, S., Mockenhaupt, M., Roujeau, J. C., Flahault, A., Kelly, J. P., Martin, E., Kaufman, D. W. and Maisson, P. (2009). Medications as risk factors of Stevens-Johnson syndrome and toxic epidermal necrolysis in children: a pooled analysis. *Pediatrics* 123(2): e297-304
- Lonjou, C., Borot, N., Sekula, P., Ledger, N., Thomas, L., Halevy, S., Naldi, L., Bouwes-Bavinck, J. N., Sidoroff, A., de Toma, C., Schumacher, M., Roujeau, J. C., Hovnanian, A. and Mockenhaupt, M. (2008). A European study of HLA-B in Stevens-Johnson syndrome and toxic epidermal necrolysis related to five high-risk drugs. *Pharmacogenet Genomics* 18(2): 99-107
- Lonjou, C., Thomas, L., Borot, N., Ledger, N., de Toma, C., LeLouet, H., Graf, E., Schumacher, M., Hovnanian, A., Mockenhaupt, M. and Roujeau, J. C. (2006). A marker for Stevens-Johnson syndrome ...: ethnicity matters. *Pharmacogenomics* 6(4): 265-268
- Lyell, A. (1956). Toxic epidermal necrolysis: an eruption resembling scalding of the skin. *Br J Dermatol* 68(11): 355-361
- Mallal, S., Nolan, D., Witt, C., Masel, G., Martin, A. M., Moore, C., Sayer, D., Castley, A., Mamotte, C., Maxwell, D., James, I. and Christiansen, F. T. (2002). Association between presence of HLA-B\*5701, HLA-DR7, and HLA-DQ3 and hypersensitivity to HIV-1 reverse-transcriptase inhibitor abacavir. *Lancet* 359(9308): 727-732
- Mallal, S., Phillips, E., Carosi, G., Molina, J. M., Workman, C., Tomazic, J., Jagel-Guedes, E., Rugina, S., Kozyrev, O., Cid, J. F., Hay, P., Nolan, D., Hughes, S., Hughes, A., Ryan, S., Fitch, N., Thorborn, D. and Benbow, A. (2008). HLA-B\*5701 screening for hypersensitivity to abacavir. *N Engl J Med* 358(6): 568-579
- Mashiah, J. and Brenner, S. (2003). A systemic reaction to patch testing for the evaluation of acute generalized exanthematous pustulosis. *Arch Dermatol* 139(9): 1181-1183
- McCormack, M., Alfirevic, A., Bourgeois, S., Farrell, J. J., Kasperaviciute, D., Carrington, M., Sills, G. J., Marson, T., Jia, X., de Bakker, P. I., Chinthapalli, K., Molokhia, M., Johnson, M. R., O'Connor, G. D., Chaila, E., Alhusaini, S., Shianna, K. V., Radtke, R. A., Heinzen, E. L., Walley, N., Pandolfo, M., Pichler, W., Park, B. K., Depondt, C., Sisodiya, S. M., Goldstein, D. B., Deloukas, P., Delanty, N., Cavalleri, G. L. and Pirmohamed, M. (2011). HLA-A\*3101 and carbamazepine-induced hypersensitivity reactions in Europeans. *N Engl J Med* 364(12): 1134-1143
- McInnes, G. T., Lawson, D. H. and Jick, H. (1981). Acute adverse reactions attributed to allopurinol in hospitalised patients. *Ann Rheum Dis* 40(3): 245-249
- Merritt, H. H. and Putnam, T. J. (1938). Sodium diphenylhydantoinate in the treatment of convulsive disorders. *JAMA* 111: 1068-1073
- Metry, D. W., Jung, P. and Levy, M. L. (2003). Use of intravenous immunoglobulin in children with Stevens-Johnson syndrome and toxic epidermal necrolysis: seven cases and review of the literature. *Pediatrics* 112(6 Pt 1): 1430-1436
- Mockenhaupt, M. (2007). Epidemiology and causes of severe cutaneous adverse drug reactions. *Drug hypersensitivity*. Pichler, W. J. Basel, Karger: 18-31.



- Mockenhaupt, M., Messenheimer, J., Tennis, P. and Schlingmann, J. (2005). Risk of Stevens-Johnson syndrome and toxic epidermal necrolysis in new users of antiepileptics. *Neurology* 64(7): 1134-1138
- Mockenhaupt, M., Viboud, C., Dunant, A., Naldi, L., Halevy, S., Bouwes Bavinck, J. N., Sidoroff, A., Schneck, J., Roujeau, J. C. and Flahault, A. (2008). Stevens-Johnson syndrome and toxic epidermal necrolysis: assessment of medication risks with emphasis on recently marketed drugs. The EuroSCAR-study. *J Invest Dermatol* 128(1): 35-44
- Nassif, A., Bensussan, A., Boumsell, L., Deniaud, A., Moslehi, H., Wolkenstein, P., Bagot, M. and Roujeau, J. C. (2004). Toxic epidermal necrolysis: effector cells are drug-specific cytotoxic T cells. *J Allergy Clin Immunol* 114(5): 1209-1215
- Nassif, A., Bensussan, A., Dorothee, G., Mami-Chouaib, F., Bachot, N., Bagot, M., Boumsell, L. and Roujeau, J. C. (2002). Drug specific cytotoxic T-cells in the skin lesions of a patient with toxic epidermal necrolysis. *J Invest Dermatol* 118(4): 728-733
- Ng, P. P., Sun, Y. J., Tan, H. H. and Tan, S. H. (2003). Detection of herpes simplex virus genomic DNA in various subsets of Erythema multiforme by polymerase chain reaction. *Dermatology* 207(4): 349-353
- Ozeki, T., Mushiroda, T., Yowang, A., Takahashi, A., Kubo, M., Shirakata, Y., Ikezawa, Z., Iijima, M., Shiohara, T., Hashimoto, K., Kamatani, N. and Nakamura, Y. (2011). Genome-wide association study identifies HLA-A\*3101 allele as a genetic risk factor for carbamazepine-induced cutaneous adverse drug reactions in Japanese population. *Hum Mol Genet* 20(5): 1034-1041
- Park, W. B., Choe, P. G., Song, K. H., Lee, S., Jang, H. C., Jeon, J. H., Park, S. W., Park, M. H., Oh, M. D. and Choe, K. W. (2009). Should HLA-B\*5701 screening be performed in every ethnic group before starting abacavir? *Clin Infect Dis* 48(3): 365-367
- Peyriere, H., Dereure, O., Breton, H., Demoly, P., Cociglio, M., Blayac, J. P. and Hillaire-Buys, D. (2006). Variability in the clinical pattern of cutaneous side-effects of drugs with systemic symptoms: does a DRESS syndrome really exist? *Br J Dermatol* 155(2): 422-428
- Phillips, E. J., Wong, G. A., Kaul, R., Shahabi, K., Nolan, D. A., Knowles, S. R., Martin, A. M., Mallal, S. A. and Shear, N. H. (2005). Clinical and immunogenetic correlates of abacavir hypersensitivity. *Aids* 19(9): 979-981
- Pichler, W. J. (2005). Direct T-cell stimulations by drugs--bypassing the innate immune system. *Toxicology* 209(2): 95-100
- Pichler, W. J., Adam, J., Daubner, B., Gentinetta, T., Keller, M. and Yerly, D. (2010). Drug hypersensitivity reactions: pathomechanism and clinical symptoms. *Med Clin North Am* 94(4): 645-664, xv
- Posadas, S. J., Padial, A., Torres, M. J., Mayorga, C., Leyva, L., Sanchez, E., Alvarez, J., Romano, A., Juarez, C. and Blanca, M. (2002). Delayed reactions to drugs show levels of perforin, granzyme B, and Fas-L to be related to disease severity. *J Allergy Clin Immunol* 109(1): 155-161
- Prins, C., Vittorio, C., Padilla, R. S., Hunziker, T., Itin, P., Forster, J., Brocker, E. B., Saurat, J. H. and French, L. E. (2003). Effect of high-dose intravenous immunoglobulin

- therapy in Stevens-Johnson syndrome: a retrospective, multicenter study. *Dermatology* 207(1): 96-99
- Quinn, A. M., Brown, K., Bonish, B. K., Curry, J., Gordon, K. B., Sinacore, J., Gamelli, R. and Nickoloff, B. J. (2005). Uncovering histologic criteria with prognostic significance in toxic epidermal necrolysis. *Arch Dermatol* 141(6): 683-687
- Rasmussen, J. E. (1976). Erythema multiforme in children. Response to treatment with systemic corticosteroids. *Br J Dermatol* 95(2): 181-186
- Rauch, A., Nolan, D., Martin, A., McKinnon, E., Almeida, C. and Mallal, S. (2006). Prospective genetic screening decreases the incidence of abacavir hypersensitivity reactions in the Western Australian HIV cohort study. *Clin Infect Dis* 43(1): 99-102
- Roujeau, J. C. (2005). Clinical heterogeneity of drug hypersensitivity. *Toxicology* 209(2): 123-129
- Roujeau, J. C., Kelly, J. P., Naldi, L., Rzany, B., Stern, R. S., Anderson, T., Auquier, A., Bastuji-Garin, S., Correia, O., Locati, F. and et al. (1995). Medication use and the risk of Stevens-Johnson syndrome or toxic epidermal necrolysis. *N Engl J Med* 333(24): 1600-1607
- Rzany, B., Correia, O., Kelly, J. P., Naldi, L., Auquier, A. and Stern, R. (1999). Risk of Stevens-Johnson syndrome and toxic epidermal necrolysis during first weeks of antiepileptic therapy: a case-control study. Study Group of the International Case Control Study on Severe Cutaneous Adverse Reactions. *Lancet* 353(9171): 2190-2194
- Rzany, B., Mockenhaupt, M., Baur, S., Schroder, W., Stocker, U., Mueller, J., Hollander, N., Bruppacher, R. and Schopf, E. (1996). Epidemiology of erythema exsudativum multiforme majus, Stevens-Johnson syndrome, and toxic epidermal necrolysis in Germany (1990-1992): structure and results of a population-based registry. *J Clin Epidemiol* 49(7): 769-773
- Samimi, S. S. and Siegfried, E. (2002). Stevens-Johnson syndrome developing in a girl with systemic lupus erythematosus on high-dose corticosteroid therapy. *Pediatr Dermatol* 19(1): 52-55
- Sanderson, J. P., Naisbitt, D. J., Farrell, J., Ashby, C. A., Tucker, M. J., Rieder, M. J., Pirmohamed, M., Clarke, S. E. and Park, B. K. (2007). Sulfamethoxazole and its metabolite nitroso sulfamethoxazole stimulate dendritic cell costimulatory signaling. *J Immunol* 178(9): 5533-5542
- Santiago, F., Goncalo, M., Vieira, R., Coelho, S. and Figueiredo, A. (2010). Epicutaneous patch testing in drug hypersensitivity syndrome (DRESS). *Contact Dermatitis* 62(1): 47-53
- Schaerli, P., Britschgi, M., Keller, M., Steiner, U. C., Steinmann, L. S., Moser, B. and Pichler, W. J. (2004). Characterization of human T cells that regulate neutrophilic skin inflammation. *J Immunol* 173(3): 2151-2158
- Schlienger, R. G., Shapiro, L. E. and Shear, N. H. (1998). Lamotrigine-induced severe cutaneous adverse reactions. *Epilepsia* 39 Suppl 7: S22-26
- Schneck, J., Fagot, J. P., Sekula, P., Sassolas, B., Roujeau, J. C. and Mockenhaupt, M. (2008). Effects of treatments on the mortality of Stevens-Johnson syndrome and toxic

- epidermal necrolysis: A retrospective study on patients included in the prospective EuroSCAR Study. *J Am Acad Dermatol* 58(1): 33-40
- Schulz, J. T., Sheridan, R. L. (2006). Severe desquamating disorder after liver transplant: toxic epidermal necrolysis or graft versus host disease? *J Burns Wounds* 5(e1).
- Shammas, M. C., Lai, E. C., Sarkar, J. S., Yang, J., Starr, C. E. and Sippel, K. C. (2010). Management of acute Stevens-Johnson syndrome and toxic epidermal necrolysis utilizing amniotic membrane and topical corticosteroids. *Am J Ophthalmol* 149(2): 203-213 e202
- Shear, N. H. and Spielberg, S. P. (1988). Anticonvulsant hypersensitivity syndrome. In vitro assessment of risk. *J Clin Invest* 82(6): 1826-1832
- Shiohara, T., Iijima, M., Ikezawa, Z., Hashimoto, K. (2007). The diagnosis of a DRESS syndrome has been sufficiently established on the basis of typical clinical features and viral reactivations. *Br J Dermatol* 156(5): 1083-1804
- Shiohara, T., Inaoka, M. and Kano, Y. (2006). Drug-induced hypersensitivity syndrome (DIHS): a reaction induced by a complex interplay among herpesviruses and antiviral and antidrug immune responses. *Allergol Int* 55(1): 1-8
- Sidoroff, A., Dunant, A., Viboud, C., Halevy, S., Bavinck, J. N., Naldi, L., Mockenhaupt, M., Fagot, J. P. and Roujeau, J. C. (2007). Risk factors for acute generalized exanthematous pustulosis (AGEP)-results of a multinational case-control study (EuroSCAR). *Br J Dermatol* 157(5): 989-996
- Sidoroff, A., Halevy, S., Bavinck, J. N., Vaillant, L. and Roujeau, J. C. (2001). Acute generalized exanthematous pustulosis (AGEP)--a clinical reaction pattern. *J Cutan Pathol* 28(3): 113-119
- Stamp, L., Gow, P., Sharples, K. and Raill, B. (2000). The optimal use of allopurinol: an audit of allopurinol use in South Auckland. *Aust N Z J Med* 30(5): 567-572
- Stevens, A. M. and Johnson, F. C. (1922). A new eruptive fever associated with stomatitis and ophthalmia: report of two cases in children. *Am J Dis Child* 24: 526-533
- Sugimoto, Y., Mizutani, H., Sato, T., Kawamura, N., Ohkouchi, K. and Shimizu, M. (1998). Toxic epidermal necrolysis with severe gastrointestinal mucosal cell death: a patient who excreted long tubes of dead intestinal epithelium. *J Dermatol* 25(8): 533-538
- Suzuki, Y., Inagi, R., Aono, T., Yamanishi, K. and Shiohara, T. (1998). Human herpesvirus 6 infection as a risk factor for the development of severe drug-induced hypersensitivity syndrome. *Arch Dermatol* 134(9): 1108-1112
- Takahashi, R., Kano, Y., Yamazaki, Y., Kimishima, M., Mizukawa, Y. and Shiohara, T. (2009). Defective regulatory T cells in patients with severe drug eruptions: timing of the dysfunction is associated with the pathological phenotype and outcome. *J Immunol* 182(12): 8071-8079
- Tamir, E., Wohl, Y., Mashiah, J. and Brenner, S. (2006). Acute generalized exanthematous pustulosis: a retrospective analysis showing a clear predilection for women. *Skinmed* 5(4): 186-188
- Thomas, B. A. (1950). The so-called Stevens-Johnson syndrome. *Br Med J* 1(4667): 1393-1397


- Ueta, M., Sotozono, C., Inatomi, T., Kojima, K., Hamuro, J. and Kinoshita, S. (2008). Association of combined IL-13/IL-4R signaling pathway gene polymorphism with Stevens-Johnson syndrome accompanied by ocular surface complications. *Invest Ophthalmol Vis Sci* 49(5): 1809-1813
- Vazquez-Mellado, J., Morales, E. M., Pacheco-Tena, C. and Burgos-Vargas, R. (2001). Relation between adverse events associated with allopurinol and renal function in patients with gout. *Ann Rheum Dis* 60(10): 981-983
- Viard, I., Wehrli, P., Bullani, R., Schneider, P., Holler, N., Salomon, D., Hunziker, T., Saurat, J. H., Tschopp, J. and French, L. E. (1998). Inhibition of toxic epidermal necrolysis by blockade of CD95 with human intravenous immunoglobulin. *Science* 282(5388): 490-493
- Viard-Leveugle, I., Bullani, R. R., Meda, P., Micheau, O., Limat, A., Saurat, J. H., Tschopp, J. and French, L. E. (2003). Intracellular localization of keratinocyte Fas ligand explains lack of cytolytic activity under physiological conditions. *J Biol Chem* 278(18): 16183-16188
- Wen, S. H., Lai, M. J. and Yang, K. L. (2008). Human leukocyte antigen-A, -B, and -DRB1 haplotypes of cord blood units in the Tzu Chi Taiwan Cord Blood Bank. *Hum Immunol* 69(7): 430-436
- Wolkenstein, P., Carriere, V., Charue, D., Bastuji-Garin, S., Revuz, J., Roujeau, J. C., Beaune, P. and Bagot, M. (1995). A slow acetylator genotype is a risk factor for sulphonamide-induced toxic epidermal necrolysis and Stevens-Johnson syndrome. *Pharmacogenetics* 5(4): 255-258
- Wolkenstein, P., Chosidow, O., Flechet, M. L., Robbiola, O., Paul, M., Dume, L., Revuz, J. and Roujeau, J. C. (1996). Patch testing in severe cutaneous adverse drug reactions, including Stevens-Johnson syndrome and toxic epidermal necrolysis. *Contact Dermatitis* 35(4): 234-236
- Wolkenstein, P., Latarjet, J., Roujeau, J. C., Duguet, C., Boudeau, S., Vaillant, L., Maignan, M., Schuhmacher, M. H., Milpied, B., Pilorget, A., Bocquet, H., Brun-Buisson, C. and Revuz, J. (1998). Randomised comparison of thalidomide versus placebo in toxic epidermal necrolysis. *Lancet* 352(9140): 1586-1589.0140-6736 (Print) 0140-6736 (Linking)
- Wolkenstein, P. and Revuz, J. (2000). Toxic epidermal necrolysis. *Dermatol Clin* 18(3): 485-495, ix
- Yalcin, B. and Karaduman, A. (2000). Stevens-Johnson syndrome associated with concomitant use of lamotrigine and valproic acid. *J Am Acad Dermatol* 43(5 Pt 2): 898-899
- Yang, Y., Xu, J., Li, F. and Zhu, X. (2009). Combination therapy of intravenous immunoglobulin and corticosteroid in the treatment of toxic epidermal necrolysis and Stevens-Johnson syndrome: a retrospective comparative study in China. *Int J Dermatol* 48(10): 1122-1128
- Zawodniak, A., Lochmatter, P., Yerly, D., Kawabata, T., Lerch, M., Yawalkar, N. and Pichler, W. J. (2010). In vitro detection of cytotoxic T and NK cells in peripheral blood of patients with various drug-induced skin diseases. *Allergy* 65(3): 376-384



Zhang, J. L., Chen, X., Li, J. and Xie, H. F. (2008). [Clinical analysis of childhood acute generalized exanthematous pustulosis]. Zhongguo Dang Dai Er Ke Za Zhi 10(4): 497-499

IntechOpen

IntechOpen



### **Skin Biopsy - Perspectives**

Edited by Dr. Uday Khopkar

ISBN 978-953-307-290-6

Hard cover, 336 pages

**Publisher** InTech

**Published online** 02, November, 2011

**Published in print edition** November, 2011

Skin Biopsy - Perspectives is a comprehensive compilation of articles that relate to the technique and applications of skin biopsy in diagnosing skin diseases. While there have been numerous treatises to date on the interpretation or description of skin biopsy findings in various skin diseases, books dedicated entirely to perfecting the technique of skin biopsy have been few and far between. This book is an attempt to bridge this gap. Though the emphasis of this book is on use of this technique in skin diseases in humans, a few articles on skin biopsy in animals have been included to acquaint the reader to the interrelationship of various scientific disciplines. All aspects of the procedure of skin biopsy have been adequately dealt with so as to improve biopsy outcomes for patients, which is the ultimate goal of this work.

### **How to reference**

In order to correctly reference this scholarly work, feel free to copy and paste the following:

Suran Fernando (2011). Severe Cutaneous Adverse Reactions, Skin Biopsy - Perspectives, Dr. Uday Khopkar (Ed.), ISBN: 978-953-307-290-6, InTech, Available from: <http://www.intechopen.com/books/skin-biopsy-perspectives/severe-cutaneous-adverse-reactions>

**INTECH**  
open science | open minds

### **InTech Europe**

University Campus STeP Ri  
Slavka Krautzeka 83/A  
51000 Rijeka, Croatia  
Phone: +385 (51) 770 447  
Fax: +385 (51) 686 166  
[www.intechopen.com](http://www.intechopen.com)

### **InTech China**

Unit 405, Office Block, Hotel Equatorial Shanghai  
No.65, Yan An Road (West), Shanghai, 200040, China  
中国上海市延安西路65号上海国际贵都大饭店办公楼405单元  
Phone: +86-21-62489820  
Fax: +86-21-62489821

© 2011 The Author(s). Licensee IntechOpen. This is an open access article distributed under the terms of the [Creative Commons Attribution 3.0 License](https://creativecommons.org/licenses/by/3.0/), which permits unrestricted use, distribution, and reproduction in any medium, provided the original work is properly cited.

IntechOpen

IntechOpen