

We are IntechOpen, the world's leading publisher of Open Access books Built by scientists, for scientists

6,900

Open access books available

185,000

International authors and editors

200M

Downloads

Our authors are among the

154

Countries delivered to

TOP 1%

most cited scientists

12.2%

Contributors from top 500 universities



WEB OF SCIENCE™

Selection of our books indexed in the Book Citation Index
in Web of Science™ Core Collection (BKCI)

Interested in publishing with us?
Contact book.department@intechopen.com

Numbers displayed above are based on latest data collected.
For more information visit www.intechopen.com



Diagnosis and Treatment of Giant Cell Arteritis (Temporal Arteritis) – Past, Current and Future Aspects

Jan Tore Gran

Department of rheumatology Oslo University Hospital, Rikshospitalet Oslo, Norway

1. Introduction

Giant cell (temporal) arteritis (GCA) is characterized by a granulomatous inflammatory reaction that penetrates all layers of the wall of medium- to large-sized arteries (1). The transmural vasculitis is particularly prone to involve cranial arteries such as the superficial temporal artery (TA), but not infrequently the disease extends to involve large muscular arteries including the subclavian and axillary arteries and the aorta.

The earliest recorded description of GCA dates to the 10th century when Ali Ibn Isa of Baghdad in his memorandum book remarked on the relationship between inflamed arteries and visual symptoms (2). An even earlier case of GCA is disclosed in a photograph of carving of a blind harpist with swollen eyelids and prominent temporal arteries from a Egyptian tomb of Pa-Aton-Em-Heb dating back to 1350 BC (3). Moreover, the painting by the Flemish painter Jan van Eyck (1436) “The holy Virgin with Canon van der Paele” may also represent an early case of GCA (4). The canon had prominent temporal arteries and diffuse swelling of the hand (5), the latter possibly indicating coexistent PMR. The tortuous and inflamed artery seen in the portrait of Lorenzo Gambiotti by Piero di Cosimo in 1502 is also suggestive of GCA (5). Thus, although GCA may have existed for several centuries there are rather few definite historical documentations of its existence. As GCA preferentially affects persons aged 50 years and more, one possible explanation is the low average life expectancy in ancient times, exposing few individuals to the risk of contracting GCA.

The first clinical description of GCA was given by Jonathan Hutchinson in 1890 (St. Bartholomew’s Hospital, London) who was asked to examine Mr. Rumbold, an 80 year old father of a porter at the London Hospital who had “red streaks on his head” which were so painful that they prevented him from wearing a hat (6). Forty-two years later (1932), the first histopathological evidence of a granulomatous vasculitis in the temporal arteries was reported by Horton, Magath and Brown at a Mayo Clinic staff meeting in 1932 (7). In 1937, Horton and Magath added to their former report the prominence of headache, the difficulty chewing food, and transient diplopia (8). Blindness as a complication of GCA was, however, first recognized by Jennings in 1938 (9). In 1941, Gilmore (10) suggested the presence of giant cells as characteristic for the disease which he called “giant cell chronic arteritis”.

During the 1930ies, the term “Temporal arteritis” was gradually introduced, whilst the designation “Cranial arteritis” was coined by Kilbourne and Wolff in 1946 (11) to point out that the temporal artery is not the only scalp artery affected in GCA.

The most frequent complaints of GCA are head-ache and malaise. However, GCA may also present as a systemic inflammatory syndrome characterized by non-specific constitutional symptoms related to systemic inflammation in the absence of focal ischemic symptoms. This is often referred to as “silent or masked GCA” (12). On the other hand, the disease may also present with minimal or absent systemic manifestations, but with organ dysfunction such as visual loss or peripheral neuropathy. The term “Occult GCA”, coined by Simmons and Cogan in 1962 (13) is often used to denote such a disease variant (14). GCA rather frequently coexists with polymyalgia rheumatica (15), affects most often persons of Nordic origin (15) and almost exclusively involves individuals 50 years or older (15, 16).

The annual incidence of GCA among persons 50 year or older has been estimated to 29/100000 (15), but autopsy studies have indicated a substantially higher incidence (17). It is possible that physician awareness is responsible for the progressive increase in the incidence that has been observed over the past two to five decades in different parts of the world (18, 19), conceivably remaining stable in the recent years (20). Mortality in GCA appears similar to that of the general population (21, 22). The cornerstone of treatment is represented by oral glucocorticosteroids (CS), but new therapeutic options which better control disease activity, exhibiting lower incidences of side effects and reducing disease complications are highly warranted.

2. Age and sex

In GCA, there is a typical female excess across all age groups (15, 16, 20, 23, 24, 25). Although GCA is almost invariably seen in individuals 50 years and older, arteritis of the temporal arteries is occasionally diagnosed in persons younger than 50 years (26). Temporal arteritis in the young may be separated into three groups. First, a localized eosinophilic arteritis confined to the temporal arteries (27), often without evidence of granulomatous inflammation (28). Systemic manifestations may be absent or minimal and the disease generally follows a benign clinical course without ischemic complications (28). Excision of the involved section of the temporal artery is often curative and CS are not required (28). Second, temporal arteritis may accompany other systemic connective diseases such as polyarteritis nodosa, Churg Strauss vasculitis, thrombangitis obliterans, or HIV infection (29). Third, a clinical and histological picture indistinguishable from that seen in adults may be observed. Although well documented, GCA among younger persons is exceptionally rare.

3. Common clinical manifestations

Head-ache At diagnosis, head-ache is reported by the vast majority of patients. In one study (25), it was present at onset in 54.1% and at diagnosis in 84.6%. The head-pain is classically located to the temporal regions, but occipital, frontal, or general headache is often encountered (25, 30, 31). In one case series, 17% of patients with biopsy-proven GCA had an initial presentation of occipital pain (31). Some patients report pain behind the ears which may be associated with vertigo and deafness (32).

4. Constitutional and musculoskeletal manifestations

Constitutional symptoms very often accompany local ischemic manifestations. Asthenia, malaise, low-grade fever, night sweats, loss of appetite and weight loss are reported by more than one third of patients (2, 25, 33, 34). Fever is usually low-grade, but occasionally it is high and associated with night sweats (2). In some cases, fever is the presenting manifestation or the only feature of GCA (35). Patients may report joint pain, but contrary to Polymyalgia rheumatica, frank arthritis appears to be very rare (25, 34).

5. Jaw claudication

Jaw claudication manifests as jaw-pain which is noted particularly when the patient chews solid food or talks at length (2). It is seen in up to 50 % of patients with a full-blown clinical picture of GCA (2, 25, 30, 33), but may in many cases be absent at the very onset of disease (2, 25). Jaw claudication usually develops shortly after some minutes of chewing and is promptly relieved by resting the muscles of mastication (2, 33). It is due to masseter ischemia caused by vasculitis and occlusive stenosis of the maxillary artery, a branch of the external carotid artery. As jaw claudication is explicitly rare in other diseases, it is a high predictor of GCA, although not pathognomonic (30).

6. Ophthalmologic manifestations

The most feared complication of CGA is visual disturbances. The incidence of ophthalmologic manifestations varies from 14-70%, depending on the selection of patients and methods of ophthalmological examinations (25, 36, 37, 38, 39, 40). Consequently, incidences of visual impairment estimated in population surveys range from 1-21%, in hospital-based studies from 0-30% and from 48-65% among patients selected from departments of eye diseases (25). There is no unanimous consensus regarding suggestions of a progressive decline in the proportion of patients with visual manifestations during the last 2 to 3 decades (39, 40, 41).

The most common ophthalmologic manifestation is visual loss (97.7%) followed by diplopia (6-21%). The visual loss is most often unilateral (38), and it may be either transient or permanent (42). Other visual disturbances are bitemporal visual field defects due to vasculitic damage to the arteries that supply that optic chiasm (42), homonymous visual field defects due to vascular involvement of the retrochiasmal visual sensory pathway (42), papillary disturbances and acute ocular hypotony (42). Visual hallucinations may occur, and in most cases these occur after the patient is bilaterally blind (42). Several cases of Charles Bonnet syndrome have been reported (43, 44).

Visual manifestations usually present early in the disease course, and are rarely seen after 2-3 years of disease (25, 45, 46, 47). In one study (25) visual impairment occurred at onset in only 2.7% as opposed to 17.9% at the time of diagnosis. Loss of vision after the first two weeks of CS therapy seems to be exceptionally rare (48). In one study (36), the probability of additional visual loss due to GCA was 13 % at 5 years in patients who presented with visual loss. The probability of visual loss due to GCA was 1 % at 5 years in patients with intact vision when oral CC treatment was started (36). If bilateral visual loss develops, the interval between the first and second eye is usually only a few days (49, 50).

Visual loss is related to anterior ischemic optic neuropathy (AION)(51), which is most commonly caused by narrowing or occlusion of the posterior ciliary arteries (32). These arteries provide blood flow to the optic disc and the choroid (42). Consequently, the early

fundoscopic appearance noted in AION consists of slight pallor and oedema of the optic disc with scattered cotton-wool patches and small hemorrhages. Later optic atrophy occurs. Such patients often report a feeling of a shade covering one eye (42). It occurs abruptly or it may be preceded by episodes of transient monocular loss of vision (42). Of all patients with AION, only 5 % have concomitant GCA (42).

Central retinal artery occlusion is the second most common cause of visual loss, affecting 10-13% of patients with visual disturbances (42, 38, 51). However, it should be noted that only 5-10 % of patients with central retinal artery occlusion have GCA (42). Usually, it develops rather abruptly and permanently (42). Posterior ischemic optic neuropathy is much less common (42). A rather rare cause of visual loss in GCA is occipital lobe infarction (52, 53).

Importantly, of patients with visual manifestations, transient visual loss is reported by 5-54 % (47, 54, 55, 56). Transient monocular blindness (amaurosis fugax) results from insufficient perfusion of the optic nerve, retina or choroid and precedes the development of permanent visual loss by an average of 8.5 days (33, 40, 42, 57). Amaurosis fugax should thus be regarded an ominous sign of impending blindness. In rare cases, transient visual disturbances preceding permanent visual loss may alternate between the two eyes (42).

The risk of developing visual disturbances has been associated with low disease activity (37, 58, 59), high disease activity (37, 45, 60), anemia (61), older age (37, 38), disc swelling (37), and a history of hypertension (62). In some studies, the best predictors for the development of severe cranial ischemic events included the absence of high CRP and ESR levels at diagnosis, absence of systemic manifestations such as fever and weight loss, and a past history of ischemic heart disease (58, 62). On the other hand, one study (60) showed an increased frequency of visual ischemic events in patients with ESR values ranging between 70 and 100 mm/h at the time of disease diagnosis. Similarly, another survey (63), found no increased risk of visual loss or other cranial ischemic events in patients with low ESR (< 40 mm/h). Histologically, the presence of giant cell cells has been associated with increased risk of visual loss (64), but this finding needs to be confirmed. A recent retrospective study showed a frequency of permanent visual loss as high as 70% among patients lacking headache at diagnosis (65). Clearly, further research is needed to define predictors of visual manifestations that can be favorably used in everyday clinical practice.⁷

Large vessel vasculitis Involvement of large vessels may be seen in 14-25% of cases with GCA (66, 67, 68, 69). Both aortic aneurysm formation and peripheral large vessel vasculitis of the extremities may be observed (66, 70, 71, 72, 73, 74). In rare cases, arteritis involving the mesenteric vessels may develop both as an initial manifestation of GCA and antedating its diagnosis (75). About 1/3 of such patients die.

In large-vessel arteritis involving the upper extremity, the subclavian and axillary arteries are most often affected (76). In about 1/5 of cases with large vessel vasculitis of the upper extremities, the brachial arteries are involved (68). The clinical picture is characterized by claudication of the arms, bruits over the carotid, subclavian, axillary and brachial arteries and absent or decreased pulses in the neck or arms. Paleness of hands upon use of upper extremity may also be observed (77). Unilateral manifestations are more frequent than bilateral manifestations (68).

In rare instances, lower extremity vasculitis develops in which involvement of the superficial femoral arteries is most frequently seen (68, 71). Other lower extremity vasculitis includes the internal iliac artery, the common femoral artery, the deep femoral artery and

the popliteal and anterior tibial arteries (68). Occasionally, GCA may present as a rapidly progressing lower extremity claudication with elevated inflammatory markers whereas cranial symptoms may be absent (71, 78).

In general, TAB may be normal in 50 % of patients with large vessel vasculitis (76). Thus, in many cases the differentiation between GCA and Takayasu arteritis may be difficult, although the latter often occurs at a younger age than the former. Both upper and lower extremity vasculitis in GCA may precede other manifestations of the disease (71), or it may be identified in association with GCA diagnosis and even develop after the onset of GCA (68). According to one study, the outcome of upper and lower extremity vasculitis in GCA seems rather good (68). Approximately 3 years after diagnosis, 80-90% of cases will either experience disappearance or improvement of clinical manifestations (68). Slightly more than 10% will have a deterioration of clinical manifestations (68). However, in another study (71) addressing lower extremity vasculitis exclusively, significant morbidity was observed as several patients were subjected to revascularization surgery and limb amputation. It is thus possible that the outcome differs between patients presenting with rapidly progressing lower limb claudication and those with less predominant clinical manifestations of lower limb vasculitis.

GCA involving the aorta was first described by Sproul and Hawthorne in 1937 (80) and is increasingly recognized conceivably due to improved imaging techniques. Case-series employing PET for diagnosis have found evidence of aortitis in over half the cases (81). Of such cases, both the thoracic and abdominal aorta may be affected (73). A study from the Mayo clinic in 1995 showed that 14 of 96 (15%) patients with GCA had an aortic aneurysm (9 thoracic and 5 abdominal)(69). Thus, patients with GCA were found to be 17.3 times more likely to have a thoracic aortic aneurysm and 2.4 times more likely to develop abdominal aortic aneurysm than age-related controls. Some have suggested it to be more common in men than females (74). Aortic dissection may be the first manifestation of GCA (82), but in the majority of cases, development of aortic disease occurs after the diagnosis of GCA (71). In many cases, aortic aneurysms occur late, years after the onset of the disease and even years after the completion of CS therapy, so that patients will often have left their rheumatologist (69, 76, 83). Moreover, most cases are asymptomatic unless dissection and rupture develop (66, 69, 72, 84). As no absolute correlation between high disease activity and involvement of aortic disease seem to exist, diagnosis of aortic GCA disease is highly dependent on screening procedures for such events.

Involvement of the aorta may be diagnosed by ultrasonography, CT or MRI (72, 73, 85). Vasculitis of the aorta and peripheral vessels may also be visualized by increased vascular uptake on 18FDG-PET (86, 87, 88, 89), but it is not clear if this is specific to vasculitis or simply a marker of any type of wall injury and tissue repair (76). Its specificity and sensitivity for diagnosing large vessel vasculitis have therefore been questioned (90). Although the recent advent of combined functional and anatomic imaging with PET-CT scanners allows anatomic correlation and exact localization of pathological lesions, PET scanning is associated with high costs and not available in all hospitals. Thus, at present it should not be recommended as a routine screening procedure in GCA. As most aneurysms develop in the ascending aorta, a yearly transthoracic echo and two-view chest radiograph could be considered as a reasonable screening approach (76). A yearly ultrasound screening in GCA for abdominal aneurysms is also likely to be cost effective (76).

In one report (69), 44% of patients with thoracic aortic aneurysm, died suddenly of dissection and 33% developed aortic regurgitation. However, subsequent investigations have concluded with a rather favorable outcome of aortic disease in GCA except for those patients that proceed to develop dissection or rupture (89, 91). In one study, follow-up at 6 months showed complete disappearance in 8.8%, improvement in 47.1%, unchanged in 41.2% and deterioration in 2.9% (72). A French study using CT scans to diagnose aortitis, also disclosed a more favorable prognosis as 10 of 11 patients achieved complete resolution or improvement at follow-up (92).

Risk factors for development of large vessel vasculitis in GCA have been insufficiently investigated. It has, however, been suggested that an aortic insufficiency murmur at the time of GCA diagnosis, hyperlipidemia, coronary artery disease at any time and high ESR in combination with polymyalgic symptoms, and hypertension are factors associated with aortic aneurysm or dissection (76, 83, 93). It should be noted, however, that less than 10 % of patients with noninfectious aortitis have GCA (94).

8. Neurologic manifestations

GCA presenting with neurological manifestations is exceptionally rare, occurring in only four of 260 cases (1.5 %) in one report (34). Neurological manifestations of GCA most probably result from arteritis of the vasa vasorum of peripheral nerves and consist of neuropathies, including mononeuropathies and peripheral polyneuropathies of the upper and lower extremities (95). On the other hand, vasculitis of the central nervous system is extremely rare and inflammatory lesions are very rarely found beyond 5 mm after the artery's penetration of the dura. Bley et al. (96) studied the thin walled intradural arteries of the circle of Willis by MRI and did not find any signs on MRI suggestive of mural inflammation. Some rare neurological manifestations are summarized in Table 1.

According to most reports, cerebrovascular ischemic events are found in 3-15% (65, 97, 98) of GCA, but are due to involvement of the extradural segment of the vertebral and carotid arteries. In one study, eight of 287 patients (2.8%) had strokes between the onset of GCA and 4 weeks after the onset of CS (97). Lesions due to involvement of the vertebrobasilar territory were seen more often than those caused by involvement of the carotids (97, 99). Patients with strokes had more commonly permanent visual loss and were more frequently smokers (97). In another study (99), the same incidence (2.8%) of strokes was observed, but the internal carotid arteries were involved in 4 patients and the vertebrobasilar arteries in 3. Interestingly, CT and MRI revealed small cerebral and cerebellar infarction, but at necropsy generalized GCA involving medium and cerebral vessels was found in one case (99). Multiple ischemic strokes despite escalating immunosuppressive therapy may also develop (100, 101), in which both anterior and posterior circulations are involved bilaterally in a characteristic location where the arteries penetrate the dura (100). Thus, strokes occur in a few patients with GCA and are in the overwhelming majority of cases due to thromboembolic disease localized to the carotid and vertebrobasilar supplied areas of the brain. However, strokes due to atherosclerosis and iatrogenic effects of CS should not be overlooked (101). Finally, in some cases the cause of progressive stroke may be due to CC rather than the disease itself (102), suggesting that replacing GC with anticoagulants should be considered.

9. Scalp necrosis

Scalp necrosis in GCA was first described by Cooke and coworkers in 1946 (103), and remains an explicitly rare disease manifestation of GCA. It is most often localized to the frontal and parietal parts and is often bilateral (Picture 1). As the scalp has an excellent blood supply, development of scalp necrosis signalizes severe vasculitis, involving most superficial arteries of the scalp. Consequently, it is often associated with severe GCA frequently including both cerebral and coronary artery occlusions (41%) and irreversible visual loss (67%)(104). Somewhat surprising, scalp necrosis usually heals completely after a few weeks (105), although sequela in the form of scarring may be seen (106). According to a review of 78 cases reported in the literature, scalp necrosis never developed after onset of therapy with corticosteroids (107). However, a case was recently reported in whom scalp necrosis antedated the initiation of therapeutic corticosteroids (108).

10. Tongue necrosis

The tongue has an excellent blood supply and is usually minimally affected in GCA (109). However, in rare cases, necrosis and gangrene of the anterior portion of the tongue may develop (110). Bilateral lingual necrosis has also been reported (109). It has been suggested that tongue necrosis most often develop during initial tapering of corticosteroid dosage (111). Tongue necrosis is caused by lingual arteritis (109). Occasionally, patients suffering from GCA report loss of taste (112) which may be related to facial artery giant cell arteritis.

Neurological

- Dementia (111)
- Psychosis (33)
- Coma (114)
- Seizures (115)
- Spinal cord infarction (116, 117)
- Subarachnoidal hemorrhage (33)
- Neuropathies (95)
- Mononeuritis multiplex (118)
- Trigeminal neuralgia (119)
- Bilateral peroneal nerve palsy (120)
- Cerebral vein thrombosis (121)
- Occipital infarction (118, 122)
- Transient ischemic attacks (123, 124)

Oral manifestations (125)

- Trismus (125)
- Throat pain (126)
- Hoarseness (126)
- Dysarthria (125, 127, 128)
- Chin numbness (125)
- Glossitis (129, 130)
- Macroglossia (125, 131)
- Lip or tongue necrosis (125)

- Odontogenic pain (33)
- Dysphagia (125)
- A submandibular mass (125)
- Head, neck and facial swelling (132, 133)

Audiovestibular manifestations (134)

- Hearing loss (33, 134)
- Tinnitus (134)
- Vertigo(134)
- Dizziness (134)
- Spontaneous nystagmus (134)
- Earache? (125)

Orbital manifestations

- Ptosis (135)
- Eye pain (125)
- Chemosis (134)
- Ophthalmoplegia (135, 136)
- - Complete abducens nerve palsy (136, 137)- Third nerve palsy (135, 136)
- Lid edema (135)
- Episcleritis (135)
- Proptosis (135, 137)

Other manifestations

- Bowel infarction (138, 139, 140, 141)
- Arteritis of the myometrium,ovaries, paraovarian tissue and fallopian tubes (142, 143, 144)
- Pericardial and pleural effusions (145, 146, 147, 148, 149)
- Pleural thickening, nodules of variable size and reticular lesions (149)
- Cough, sore throat and hoarseness (149)
- Myocardial infarction (150, 151, 152, 153, 154)
- Breast involvement (155, 156)
- Syndrome of inappropriate antidiuretic secretion (157)
- Raynaud`s phenomenon (158)
- Microangiopathic hemolytic anemia (159)
- Carotidynia (160, Cid AR 1998 ref 79)
- Membraneous glomerulopathy and nephrotic syndrome (161)

Table 1. Less commonly reported clinical manifestations in GCA

11. Concomitant polymyalgia rheumatica

Polymyalgia rheumatica (PMR) and GCA frequently coexist (25, 162, 163), an association noted by Porsman as early as in 1951 (164). PMR may precede GCA or develop after GCA diagnosis. Whether or not PMR and GCA represent two separate disease entities which frequently overlap or are one common disease with different clinical expressions remains a controversial issue. The frequent concomitant occurrence of PMR and GCA suggests a common disease denominator whereas the discrepant clinical picture of TA and PMR may

indicate two separate disease entities. The occurrence of articular and periarticular inflammation seen almost exclusively in PMR suggests separate disease entities (165). On the other hand, positron emission tomography (PET) scan findings of increased uptake of fluorodeoxyglucose in the thoracic vessels in many patients with PMR suggest a common vasculitic disorder (166, 167). Finally, the reported incidence of biopsy-proven TA among patients with pure PMR varies considerably, from 4 to 70% which makes it difficult to reach an overall conclusion regarding the relationship between TA and PMR (25, 168, 169, 170). Patients presenting with both PMR and GCA often run a severe disease course, and maintenance doses of oral CS are on average often higher compared to patients presenting pure PMR or isolated GCA (171, 172).

12. Clinical examinations

In patients suspected of suffering from GCA rather few clinical examinations are mandatory. As GCA affects individuals older than 50 years who rather frequently suffer from other diseases, a general medical examination is compulsory. Examination of aorta and large arteries of the upper and lower extremities to reveal bruits and diminished pulses is strongly recommended.

Physical examination of the frontal and parietal branches of the temporal arteries may reveal tenderness on palpation, absent or reduced pulsation and thickening of the vessel. General scalp tenderness is rather frequently present and may be worsened by brushing or combing the hair.

A thorough examination for ophthalmological symptoms is strongly recommended. Symptoms indicating coexistent PMR should not be missed. Patients with uncomplicated GCA should be informed about the risk of ischemic complications and asked to report back immediately if such events develop.

13. Laboratory investigations

Acute phase reactants are increased in the overwhelming majority of GCA (25). An ESR of 40 mm/hour or more has been noted in more than 90 % of patients (61, 63). Less than 1-2% have normal levels of both ESR and CRP (25, 173, 174). GCA with normal ESR has, however, been reported (175, 176, 177), even in patients with visual disturbances (176, 178) and devastating central nervous system complications (179). Interestingly, when patients with GCA and normal ESR were followed-up, these patients were never able to mount a high ESR during subsequent episodes of inflammation caused by infection which may imply a genetically determined blunted cytokine response to inflammation (63). ESR and CRP are relatively lower in patients with occult GCA according to some observations (14). These patients often have a longer diagnostic delay (180). Both leucocytosis (61), thrombocytosis (61, 181, 182), and normocytic normochromic anemia (61) may be encountered. Liver function tests are frequently abnormal, particularly elevations of serum alkaline phosphatase (62, 183).

Recent research has explored the potential utility of other biomarkers for disease activity in GCA. A promising cytokine for monitoring disease activity in GCA is IL-6 as it is found in inflamed arterial walls and shows highly elevated serum levels in active GCA (184, 185). In one study, 89% of flares were associated with an elevated level of IL-6 while ESR elevations

accompanied 58% of flares (186). However, analyses of IL-6 are not readily available at most centers, and thus not suitable for routine measurements. Finally, more research is needed to explore whether or not serial assessments of circulating TNF α can aid in the monitoring of possible relapses in GCA (187).

14. Imaging

14.1 Ultrasound

Color duplex ultrasonography of the temporal artery has been introduced as a means of improving the diagnosis of GCA. Besides revealing stenosis and vessel occlusions, ultrasound may also detect wall inflammation.

Schmidt and coworkers described in 1997 the presence of a hypoechoic thickening around the lumen of the temporal artery, termed a “halo-sign” which represents edema of the vessel wall (188). The “halo-sign” may also be seen in subclavian, external carotid, occipital, axillary, facial, brachial, ulnar, common carotid, vertebral, radial and popliteal arteries (189). The frequent involvement of the occipital arteries in GCA may also be detected by ultrasonography (190). Thus, an ultrasonographic finding of a hypoechoic halo around the lumen of the temporal arteries has been advocated as a method of making the diagnosis of GCA rendering temporal artery biopsy (TAB) superfluous. However, several studies have questioned the sensitivity of the “halo-sign” for the diagnosis of GCA. According to various reports, its sensitivity varies from 10-100% (191, 192, 193). In a meta-analysis of 23 studies, the “halo-sign” had a pooled sensitivity of 69% and a specificity of 82% compared with TAB (194). However, a bilateral “halo-sign” appears almost pathognomonic of GCA (193). In another report, Arida and coworkers (195) conducted an extensive metaanalysis of ultrasonography which disclosed a sensitivity of 68% and a specificity of 91% for the unilateral “halo-sign”, as well as 43% and 100%, respectively for the bilateral “halo-sign” for GCA diagnosis.

The reasons for apparent discrepancies regarding sensitivity of ultrasound to detect the halo to diagnose GCA may have several explanations. First, sensitivity and specificity are highly dependent on the examiner as the method requires experience and expertise. Second, the quality of the sonographs employed in the different studies may vary. Third, the appearance of vessel wall abnormalities may also vary with the duration of the disease.

A negative ultrasonographic finding at the onset of disease may be due to absence of early adventitial inflammation which is necessary to produce the oedema that causes the halo effect. It should also be noted that the halo disappears after commencement of steroid therapy, usually within 2-4 weeks (188, 189, 193). Finally, in some cases it is difficult to differentiate between inflammatory and noninflammatory temporal artery disease by ultrasonography (196).

At present, ultrasonography should not replace temporal artery biopsy (TAB), but it can serve as a means for identifying sites suitable for surgical biopsies (197). Moreover, ultrasonography appears a promising method for diagnosing GCA in patients who decline surgical biopsies. In such cases, cautious interpretation of the test results based on clinical presentation and pretest probability of the disease is imperative (194). Clinicians responsible for the care of patients with GCA should be encouraged to use ultrasonography to detect large vessel vasculitis in GCA.

15. Magnetic resonance imaging

MRI can detect inflammatory vessel wall changes (198) with a sensitivity of 80.6% and a specificity of 97% compared against a diagnosis of GCA based on the ACR criteria (199). According to other findings, the specificity and positive likelihood ratio of high resolution MRI are sufficiently high that a positive MRI combined with other clinical and laboratory data consistent with GCA may be useful in diagnosing GCA (200). It should be noted, however, that given the relatively low sensitivity of the test, a negative MRI would not be sufficient to rule out the diagnosis of GCA (201).

Moreover, no definite concordance between MRI and acute phase assessed by CRP has been established (86). Finally, to few studies have specifically addressed the suitability of MRI diagnosing arteritis in the temporal arteries (202). Although disputed (201), MRI appears as a favorable means to detect large vessel vasculitis, in any case when abnormalities such as vessel narrowing or obliteration have developed.

16. ¹⁸Fluorodeoxyglucose-positron emission tomography – 18FDG- pet-scanning)

Similar to MRI, 18FDG-PET may be useful to detect large vessel arteritis but is associated with restricted availability and high costs. However, PET scanning may in the absence of reliable biomarkers for disease activity, represent the only method of disclosing active vessel wall inflammation. Preliminary results indicate that 18F-FDG PET could be a method exhibiting high sensitivity and specificity for GCA-related large-vessel inflammation (203, 204, 205, 206).

Others have found PET as a useful diagnostic tool in early stages of large vessel vasculitis and a powerful instrument to follow the treatment responses (88). However, increased vascular up-take on PET should be interpreted cautiously as it is still unsettled whether or not such uptake represents inflammation requiring anti-inflammatory therapy or indicates inflammation associated with a healing process. One study found only a low, but non-significant correlation of PET with CRP (201). At present, more investigation is needed before PET scan eventually can be included in the routine work-up and monitoring of GCA. The availability of the modality is, however, restricted, and the costs are of great concern.

17. Temporal artery biopsy

According to the British Society for rheumatology guidelines, TAB should be considered whenever a diagnosis of GCA is suspected (207). The EULAR recommendations, however, advocate that a TAB should be performed when GCA is suspected (208). Although a diagnosis of GCA according to the ACR criteria (199) can be made without histological confirmation, these criteria were constructed for use in research. For clinical work, the benefit of a pathological confirmation of the diagnosis should not be underestimated. Both at the start of disease and during disease course, a histological proof of GCA appears reassuring for both patients and clinicians. When patients develop serious adverse-effects due to long-term CS treatment, histopathological proof of the diagnosis helps to buttress the case for continued therapy (209). Moreover, GC therapy may cause serious side effects which may result in a medicolegal case. Morphological evidence of the disease will then provide proof that both diagnosis and treatment were appropriate. Finally, although scalp

necrosis, brow droop, chronic skin ulceration and stroke have been described, TAB is associated with low-morbidity (210). As emphasised earlier, an ultrasound should be performed to identify the most suitable location for biopsy.

Typical histopathological findings in GCA include infiltration of T lymphocytes, dendritic cells and macrophages in all layers of the arterial wall. Moreover, disruption of the internal elastic lamina, chronic granulomatous inflammation, multinucleated giant cells accumulated along the fragmented internal elastic lamina, thickening of the intima and luminal occlusion are frequently observed. In some cases, involvement is seen exclusively in the small vessels external to the temporal artery adventitia (211). PMR very often accompany GCA in such cases (211).

The minimum length of the biopsy required for a definite diagnosis of GCA has been discussed in several reports. The basis for the discussion is the uneven distribution of arteritic lesions (212). Skip lesions have been described in 8.5-28.3% of positive biopsies (213, 214, 215). Although lengths of biopsies shorter than 10mm are suggested to be sufficient for a diagnosis of GCA (216, 217), most authors recommend a minimum length of at least 1.5-2 cm (218, 219, 220). Such a length would allow for tissue shrinking during fixation which is estimated to approximately 10 %.

If the biopsy yields normal findings, a contralateral biopsy may be considered. However, the diagnostic yield of a second biopsy if the first one is negative is rather small. The percentage of patients with a negative biopsy on one side and a positive biopsy on the other has been reported from 3 to 12.7 % (221, 222, 223). Given the low increase in sensitivity obtained by performing bilateral biopsies, careful diagnostic considerations should be undertaken before requesting a second biopsy. Moreover, a unilateral biopsy preserves an artery in the event that a diagnosis of GCA is considered in the future, and minimizes costs and physician time (224). In any way, commencement of therapy should not be delayed if clinical suspicion of GCA is high in spite of a first negative biopsy.

The administration of immunosuppressive therapy such as CS may have little impact on the possibilities of detecting histological vasculitis during the initial phases of therapy. Specimens might show arteritis after 2-4 weeks of CS therapy (225, 226, 227, 228), although the frequency of positive biopsies is slightly reduced for each week of treatment (227, 229). Active vasculitis observed in TAB has been demonstrated after as long as 9 years after initiation of CS (230). Thus, TAB should be performed in all patients suspected of having GCA, but negative results on biopsy in patients treated for weeks should be interpreted with caution.

In long-term CS treated patients, a histopathological picture of so-called healed-arteritic pattern has been observed. The three most reliable histopathological parameters of CS treated GCA were a complete or incomplete mantle of lymphocytes and epithelioid histiocytes located between the outer muscular layer and the adventitia, large circumferential defects in the elastic lamina and absent or few multinucleated giant cells (231). Patients exhibiting such histopathological features seemed to be at no risk of reactivation, early death, permanent blindness and cerebrovascular accidents (232).

Of major concern is the low number of positive biopsies analyzed by pathological departments. Studies during the years 1976 to 2007 have reported findings of GCA in 13 - 43.7 % of TABs (19, 226, 233, 234, 235). Consequently, predictive markers for a positive biopsy have long been searched for. In one study of TAB performed among patients suspected of having GCA, excluding patients with no evidence of temporal artery abnormalities, scalp tenderness, or jaw claudication, only 48% of the 125 biopsies would

have been performed (236). Fifty-nine negative biopsies would have been prevented, but six positive biopsies would have been missed (236). The findings jaw claudication, weight loss, pathological temporal artery enlargement, recent head-ache, and scalp tenderness have all been found to predict a positive biopsy (226, 233, 236, 237). It is tentative to suggest that patients exhibiting none of these clinical features combined with a negative ultrasound should not be subjected to TAB before all other causes of current inflammatory manifestations are ruled out. Finally, the frequencies of positive TAB reported in PMR have varied from 4-40% (25, 238), the results depending on the definition of “pure” PMR. At present, it is generally agreed upon that TAB is not indicated in patients with PMR in the absence of cranial manifestations (pure PMR), unless a high inflammatory response is present.

18. Diagnostic and classification criteria

18.1 Clinical suspicion

A diagnosis of GCA should be considered in all patients 50 years or older with unexplained head-ache, a significant inflammatory response that is not explained by infection, other autoimmune diseases or malignancy, visual disturbances or signs of peripheral vasculopathy. The British society for rheumatology (207) recommends that clinical suspicion of GCA should be raised in a patient older than 50 years presenting with either abrupt-onset headache, scalp tenderness, jaw and tongue claudication, visual symptoms, constitutional symptoms, polymyalgic symptoms or limb claudication.

19. Diagnosis

For scientific purpose, the ACR criteria are widely used (199). These criteria attempt to differentiate GCA from other vasculitides and include five items (Table 2). Presence of three or more of these five criteria is associated with a sensitivity of 93.5% and a specificity of 91.2%. It is noteworthy that according to these criteria, a diagnosis of CGA can be made in the absence of histopathological evidence. In a number of studies, patients with biopsy-proven GCA have been studied exclusively, hence hampering comparison with investigations based on the ACR criteria which include both biopsy positive and negative patients. Consequently, results should be presented separately for biopsy positive and negative cases allowing valuable comparison. It should also be noted that occult GCA and patients presenting large vessel vasculitis exclusively may not have been accurately represented in the ACR criteria. Furthermore, as the ACR criteria are not useful for making the diagnosis in individual patients (239), other diagnostic guidelines should be followed.

1. Age 50 years or older
2. New onset of localized headache
3. Temporal artery tenderness or decreased temporal artery pulse,
4. Elevated ESR 50 mm/hour or higher
5. Biopsy sample including an artery, showing necrotizing arteritis, characterized by a predominantly of mononuclear cell infiltrates or a granulomatous process with multinucleated giant cells.

Table 2. The ACR 1990 criteria for giant cell arteritis (199)

A diagnosis of Cranial arteritis requires the histological demonstration of localized vasculitis combined with associated clinical manifestations such as either head-ache and/or jaw claudication, visual loss and constitutional symptoms. Thus, a definite diagnosis of GCA classified as Cranial arteritis rests on the demonstration of inflammatory changes found on biopsy of the temporal arteries. In cases of normal histopathological findings at vessel biopsy, a diagnosis of cranial arteritis should only be made after a thorough exclusion of other causes for the aforementioned clinical manifestations. In such cases, evidence of an elevated acute phase response should be regarded compulsory and detection of a halo by ultrasonography would strongly support the diagnosis of GCA.

In patients with non-specific constitutional symptoms related to systemic inflammation in the absence of focal ischemic symptoms, but with histopathological proof of GCA, the term "Silent or masked GCA" or "systemic inflammatory syndrome" should be preferred. As emphasized by Rahman & Rahman (32), the ACR criteria are likely to result in some false-negative diagnoses of GCA, putting vision at risk. In silent or occult GCA, the risk of ischemic complications resulting in loss of vision is highly significant, requiring a high index of suspicion in order to diagnose GCA in patients with an atypical presentation.

Some patients may show evidence of large vessel vasculitis in the absence of histopathological evidence of GCA, and without significant inflammatory symptoms. Such cases may be indistinguishable from Takayasu arteritis, and should thus be labelled Large vessel vasculitis, or if histopathological proof of granulomatous vasculitis is observed, the term Large vessel giant cell arteritis may be preferred.

20. Differential diagnoses, malignancy and cardiovascular disease

A TAB remains the gold standard test in the diagnosis of GCA, and few diseases can be mistaken for what turns out to be biopsy-proven GCA. Vasculitis of the temporal arteries has been reported in polyarteritis nodosa, Churg Strauss vasculitis, microscopic polyangiitis, Wegener's granulomatosis, hepatitis B virus-related polyarteritis nodosa, hepatitis C virus-related cryoglobulinemic vasculitis and rheumatoid vasculitis (29, 240, 241, 242), but the clinical features of these diseases distinguish them from TA. Primary systemic amyloidosis may present with a clinical picture of either PMR or GCA or both (243).

Malignancy and Cardiovascular disease in Giant cell arteritis. Although suggested by some (244, 245), the majority of studies have been unable to find an increased risk of malignancy in GCA (246, 247, 248, 249, 250, 251). However, as GCA affects persons 50 years and older, particular attention should be paid to the development of concurrent neoplastic disease which is not uncommon in these age groups. There are several case reports of GCA developing simultaneously with malignant disease such as leukemia (252), lymphoma (253) and lung cancer (254). Previous suggestions of an increased risk of concomitant cancer in patients not responding to treatment with subsequent decline in acute phase reactants have not been subjected to further investigations.

Although an increased incidence of cardiovascular disease in GCA has been suggested (255, 256, 257, 258), these findings have not been corroborated by population surveys (21, 259). Thus, there exists no convincing evidence of an increased risk for development of clinically important cardiovascular disease in GCA, except possibly for the oldest patients with GCA (260). Of note, cardiovascular diseases are in general prevalent in this age group and should not be ignored.

21. Initial treatment

After the first trial of CS therapy for the disease was reported by Schick et al in 1950 (261), CS have remained the mainstay of therapy in GCA. However, much is still unknown regarding their mechanisms of action, the optimal initial dose, speed of taper, and duration of CS therapy.

22. Uncomplicated GCA

In the absence of large vessel vasculitis, severe organ involvement or visual disturbances (uncomplicated GCA), low doses of CS are as effective as low doses (262, 263). Moreover, those patients commencing treatment with low doses of CS do not have more visual or neurological complications than patients treated with higher doses (264). Starting doses of 30-40 mg of prednisolone daily are thus recommended. Both cumulative doses of CS and higher doses are associated with increased toxicity (265, 266, 267).

Side effects may occur in at least one third of patients, and in two thirds if weight gain is included (264). Treatment with alternate-day CS administration is associated with a higher rate of treatment failure than is daily administration (268) and is not recommended.

If a significant response of 30-40 mg prednisolone per day is not obtained within 6-72 hours, an initial dose of oral prednisolone of 60 mg should be administered. There are, however, no studies that clearly show that a higher dose of oral CS yields a higher response rate than lower doses. If response to 60 mg of prednisolone fails to occur, diagnoses other than GCA should be considered. Similarly, in patients whose symptoms persist without elevated acute phase reactants, alternative or concurrent explanations should be sought. Also those patients whose symptoms resolve but the acute phase reactants remain elevated should be subjected to further diagnostic evaluations before continuing GC treatment.

The initial dose of CS is usually given for 2-4 weeks until all reversible signs and symptoms have resolved and acute phase reactants are back to normal. Then, the dose can be gradually reduced (269) each week or every two weeks by a maximum of 10% of the total daily dose with careful follow-up of systemic symptoms and acute phase reactants.

23. Treatment of GCA presenting with visual disturbances and blindness

Historically, experience clearly suggests a protective effect of CS against development of visual complications. Prior to the steroid era, a higher incidence of such ischemic events as compared to recent reports has been observed (17, 36, 270, 271, 272, 273). However, there are no randomized controlled studies proving such a preventive effect. Moreover, a substantial proportion of patients may lose vision in spite of daily treatment with high doses of CS (274, 275, 276). Finally, there is no convincing evidence to suggest that administration of GC results in improvement of established visual loss. Nevertheless, in patients presenting with visual disturbances, administration of CS should be initiated immediately, and not delayed until results of TAB are available. Studies have shown that if therapy is instituted within 24 hours, the chance of visual improvement is much greater than if treatment is delayed (49). Usually, 60 mg of oral prednisolone per day is given (207, 208), with gradual tapering of the dose to 40 mg in 1-2 weeks providing a clinical response appears. Thereafter, the steroid dose is gradually tapered to reach a maintenance dose of 10 mg by 6-9 months, and 5-7.5 mg within 1 year. In one report, the median time to reach the lowest maintenance dose of

prednisone at which the ESR and CRP stayed low and stable was 48.7 months (277). However, as pointed out by Hayreh and Zimmerman (277), no generalization is possible for tapering down of CS, and there is no formula because of the infinite variation between individuals.

Patients with loss of vision represent a challenge to the physician. Visual loss from GCA is typically profound and permanent (42, 278). Although still debated (47, 279), most workers recommend administration of 500-1000 mg methylprednisolone i.v. for three days before oral treatment is given (207, 208, 280, 281, 282, 283, 284). The main purpose of this treatment is to protect the contralateral eye (285). If the second eye is to be affected, this most often happens during the first 2 to 14 days (286, 287). Loss of vision after cessation of GC is very rare (36). Alternate day GC is not recommended (268).

24. Treatment of patients with other extratemporal manifestations

Treatment of patients exhibiting large vessel vasculitis involving arteries of the extremities or aorta in addition to temporal arteritis, patients with scalp or tongue necrosis or other serious extratemporal arteritis should be treated vigorously with the same recommendations as for those with visual impairment. For patients with large vessel vasculitis without involvement of the temporal arteries, a low dose regimen of CS may be sufficient (77). For patients developing aortic aneurysms requiring cardiac surgery, medical therapy should be continued at the established dose (93).

24.1 Alternative treatment strategies

In addition to CS-resistance, there are several other compelling reasons to search for alternatives to CS. High initial and cumulative doses of CS often resulting in important side effects, visual impairment despite adequate administration of GC, the development of aortic aneurysm, dilation and dissection in a significant number of patients and the frequent relapses and heterogeneous responses to therapy all are of major concern. Thus, alternate or additive therapy to reduce the CS doses, to better prevent disease complications and to improve therapeutic responses has been the subject of repetitive studies during the recent years.

Trials of methotrexate (MTX) have yielded conflicting results (288, 289, 290). A meta-analysis of three randomized studies (291) showed that treatment with MTX lowers the risk of relapse and reduces exposure to CS. The authors suggested that MTX should be considered as a therapeutic option in addition to standard-of-care treatment with CS for patients with GCA (291). However, most patients are favorably treated with CS monotherapy and may manage with low or modest doses. Consequently, MTX as an adjunctive therapy in GCA should be considered in patients requiring high doses of CS, particularly those having both GCA, PMR and large vessel arteritis (292). MTX may also be added to steroids in patients with peripheral arthritis unresponsive to local CS injections.

Azathioprine and other traditional DMARDs have not been shown to exert any favorable effects in GCA (293, 294, 295), although some steroid sparing effect of azathioprine was found in one double-blind study (293). Similarly, statin therapy does not seem to offer any protection against development of visual complications, large vessel vasculitis, jaw claudication, ischemic heart disease, or cerebrovascular accidents (296).

TNF α has been demonstrated in up to 60% of the cells in all areas of inflamed arteries (297), and inhibition of this cytokine may be an attractive therapeutic option in GCA. Early case

reports (298, 299, 300, 301, 302, 303, 304, 305) of favorable response to TNF α inhibitors indicated that biological therapy could be an alternative to CS or at least be used in patients failing to respond to CS. However, suggestions of efficacy of TNF α inhibitors have not withstood further drug trials. In a randomized trial, Hoffman and coworkers (306) found that infliximab therapy did not increase the proportion of patients without relapse at week 22 compared with placebo nor did it increase the proportion of patients whose CS dosages were tapered to 10 mg/d without relapse. The results of drug trials of etanercept are, however, perhaps more promising (299, 300). In a study of etanercept versus placebo, Martinez-Taboada and coworkers showed that among GCA patients with side effects due to CS, etanercept treated patients more often than controls were able to control the disease without CS therapy (299). Clearly, the role of etanercept in CS resistant GCA awaits final clarification.

Much research during the last decade has focused on the role of cytokines in GCA. Cytokines are small proteins that serve as chemical messengers between cells, regulating cell growth and differentiation, tissue repair and remodeling, and many aspects of the immune response (184). In GCA, the different vessel layers produce different cytokines. Interferon- γ secreting T-cells are almost exclusively found in the adventitial layer of the inflamed arteries (184), and appear to be critically involved in modulating the process of intimal hyperplasia, the most destructive consequence of vasculitis. Interferon- γ thus emerges as a prime target for novel therapeutic approaches (184), but no randomized controlled studies have yet emerged. Interestingly, the histological and immunological profile in silent or masked GCA appears different from that of cranial arteritis. The latter is characterized by intimal hyperplasia and production of Interferon- γ , IL-1 β and Platelet derived growth factor (PDGF) while in silent GCA there is no intimal hyperplasia and prominent production of IL-2 (33). Whether or not this discrepancy implies different therapeutic approaches and diverging outcome is yet to be shown.

Macrophages in the adventitia produce the proinflammatory cytokines IL-1 and IL-6 (184, 185, 186), and levels of IL-6 has been shown to be potentially helpful in predicting disease severity and may allow for a tailoring of immunosuppressive therapy (186). Thus, preliminary case reports have emerged which may indicate a beneficial effect of the anti IL-6 monoclonal antibody tocilizumab in both polymyalgia rheumatica and GCA (307, 308). Favorable effects of anti-IL-1 receptor antagonists are yet to be documented by randomized controlled trials. Abatacept, a recombinant fusion protein that modulates CD28-mediated T-cell costimulation is another tantalizing therapeutic option in GCA awaiting controlled trials.

In a small series of patients with steroid-resistant Takayasu arteritis, another giant cell vasculitis, treatment with mycophenolate mofetil (MMF) resulted in clinical remission as well as improvement in inflammatory markers (309). However, experience with MMF in GCA is still lacking. Platelet derived growth factor (PDGF) appears to be a critical growth factor in arteries with luminal occlusion (184). Thus, the production of PDGF by multinucleated giant cells and macrophages may be inhibited by tyrosine kinase inhibitors, and preliminary in vitro observations may indicate that imatinib mesylate may have a role in the therapy of GCA (310). Endothelin-1 (ET-1) is one of the most powerful vasoconstrictors identified, and ET-1 concentrations has been found increased at the protein level in temporal artery samples from GCA patients (311). Moreover, plasma ET-1 concentrations appeared higher in patient with ischemic complications (311). However, no study yet has been undertaken to test potential beneficial effects of antagonizing ET-1 in GCA. Finally, the anti-CD20 monoclonal antibody rituximab has not been subjected to

controlled studies, but a case report found improvement of B lymphocyte depletion in a patient requiring unacceptable high doses of CS (312).

At present, no alternatives to daily CS therapy have emerged, but the role of new agents will hopefully be clarified in future drug trials. It is hoped that these new agents will result in better control of markers of inflammation which may translate into lower rates of late atherosclerosis and aortic aneurysms even years after the clinically active phase of the disease has resolved (313). Except for a potential role in patients with visual disturbances, treatment with intravenous methylprednisolone does not appear to offer any long-term CS sparing effect. Moreover, in our experience, intramuscular methylprednisolone has no role in the drug treatment of GCA.

24.2 Additive treatment

Patients with GCA do not seem to be at increased risk of contracting cardiovascular disease (314), but physicians responsible for the treatment of patients with GCA should nevertheless be encouraged to search for cardiovascular risk factors as they are common in this age. Although suggested to be of possible use in other inflammatory rheumatic diseases (315), there are, however, no data to support the use of statins in patients with GCA if they do not have cardiovascular risk factors.

There is an ongoing discussion regarding the use of acetylsalicylic acid in patients with GCA. Some have suggested that treatment with low-dose aspirin may exhibit some protection against cranial ischemic complications (316, 317). However, more recent studies have been unable to detect any definite effects of aspirin in GCA (318). On the other hand, it cannot be excluded that the inflammatory process may have impact on the age-related long-term risk of cardiovascular disease in these patients. In addition to its well-established antiplatelet effect, aspirin may also be beneficial in GCA by virtue of its inhibitory effect on interferon- γ mRNA production, essential for the development of the inflammatory infiltrate of the vessel wall. Thus, low dose aspirin may prevent complications of atherosclerotic cardiovascular disease, not just through its antiplatelet effect, but also by its anti-inflammatory effects during atherogenesis and by increasing plaque stability (313). Finally, the interferon- γ production by the adventitial T lymphocytes in GCA appears relatively resistant to standard CS therapy, but susceptible to aspirin (313). Thus, this may further strengthen the indication for adding aspirin to CS in the standard therapeutic regimen of GCA. However, a prospective study is clearly warranted to define the role of aspirin in GCA. Until then, a low dose regimen of aspirin can be recommended in the absence of specific contraindications as an adjunctive drug in this disease.

Steroid-related side effects are frequently recorded in GCA (264, 265, 266). Among these, the detrimental effects of GC is well known. Although the incidence of CS induced osteoporosis appears rather low in GCA (319, 320), the risk of contracting such complications should not be ignored. Most workers recommend addition of calcium and vitamin-D to female patients with GCA, at least for those patients prone to receive long-term CS therapy and requiring large doses. In the presence of other risk factors for osteoporosis, treatment with bisphosphonates should be considered.

25. Follow-up and monitoring

25.1 Maintenance therapy (dose and duration)

High doses of oral prednisolone (40-60 mg per day) are maintained for at least 4-6 weeks until systemic symptoms have subsided and markers of disease activity have normalized

(207, 208). Then, the dose is reduced by 10 mg every 2 weeks to 20 mg. Thereafter, the dose is reduced by 2.5 mg every 2-4 weeks to 10 mg. Providing no relapse or development of extracranial complications, CS are further reduced by 1 mg every 1-2 months. In one study (263), mean daily maintenance dose during the first and second year was 6.6 and 4.1 mg, respectively. In another report, the median duration required to reach 7.5 mg/day was 6.5 months (321).

Patients should be monitored closely for relapse, control of disease activity, alleviation of complaints, development of extracranial complications and CS-induced side effects. Which patients that will require higher doses to control the disease are difficult to predict. It has, however, been suggested that a strong systemic inflammatory response is associated with higher CS requirements and a longer duration of therapy (217). Both ESR and CRP should be assessed regularly, but some data indicate that blood concentrations of interleukin 6 are the most sensitive indicators of disease activity and course (185, 186). However, assessment of IL-6 levels is not done in routine laboratories. Thus, both traditional acute phase parameters such as ESR and CRP and clinical evaluation of disease activity and progression represent the basis for deciding the therapeutic dose of CS.

As outlined previously, one approach recommends a minimum of abdominal ultrasound, chest radiographs and transthoracic echocardiogram annually to search for development of aneurysmatic disease. As the incidence of malignant disease in GCA is most likely similar to that of the general population, no recommendations can be given for screening processes to exclude malignancy. The age-group affected by GCA implies, however, attention to coincident development of neoplasia.

26. Cessation of treatment and relapses

Typically, relapses are most commonly occur within the first 18 months (322), but may be observed as late as after 8 years of treatment (321). One or more relapses of GCA occur in 27-62% (323, 324, 325, 326, 327). In patients with visual disturbances, further deterioration of vision usually takes place in the first 5-6 days of steroid initiation (46). Recurrences of visual loss most often occur between 3 and 36 months after the initial visual loss (45). Relapses are most commonly accompanied by increased acute phase parameters. However, both clinical features and acute phase reactants should be considered when diagnosing relapse, as neither CRP nor ESR alone can be depended on to diagnose clinical exacerbations. A rise in ESR/CRP may also spark vigilance that concurrent opportunistic infection is present which should not be overlooked. It is recommended that the initial dose regimen is repeated if relapse develops.

The total duration of GCA treatment is difficult to predict with accuracy on clinical and laboratory grounds. It has been suggested that the slope of prednisolon dose-tapering may identify at an early stage those patients who are at risk of undertaking a long period of treatment (328). Moreover, patients with coexisting AT and PMR appear to demand longer treatment (263, 329). It is still debated whether GCA patients exhibiting visual disturbances require longer periods of GC than those without. In one study (321), the median time to steroid discontinuation was 21.6 months while in another study all patients has discontinued GC within 24 months (329). On the other hands, our experience (263) and also others (330) have demonstrated that after 2 years, 80-90% of patients are still on CS. In the study of Hayreh and Zimmerman (277), 92.5 % of those with visual loss and 86.1 % of those without were still on GC five years after commencement of therapy. Clearly, the duration of

CS treatment is highly variable and careful monitoring of patients cessating treatment is strongly recommended.

27. Concluding remarks

There are still major delays in the recognition and treatment of GCA (65) which partly result in a rather high incidence of irreversible ischemic complications. Patients exhibiting less classical clinical manifestations appear to represent a subclass in which diagnosis is particularly problematic. Thus, an important challenge in the care of patients with GCA is to improve the skill and competence of general practioners as they are the first to meet these patients. Finally, research during the latest years has clearly shown the complexity of the immune pathology in GCA, including both Th1 and Th17 responses (331). Although GC remain the mainstay of therapy in GCA, cocktails of therapies will probably be needed for appropriate disease control (331).

28. References

- [1] Gran JT. Some thoughts about the etiopathogenesis of temporal arteritis – a review. *Scand J Rheumatol* 2002; 31: 1-5.
- [2] Hamilton CR, Shelley WM, Tumulty PA. Giant cell arteritis: including temporal arteritis and polymyalgia rheumatica. *Medicine* 1971; 50: 1-27.
- [3] Appelboom T, van Eigem A. How ancient is temporal arteritis? *J Rheumatol* 1990; 17: 929-31.
- [4] Dequeker JV. Polymyalgia rheumatica with temporal arteritis, as painted by Jan van Eyck in 1436. *Can Med Assoc J* 1981; 124: 1597-8.
- [5] Portioli I. The history of polymyalgia rheumatica/giant cell arteritis. *Clin Exp Rheum* 2000; 18 (4 suppl. 20); S1-S3.
- [6] Hutchinson J. Diseases of the arteries. On a peculiar form of thrombotic arteritis of the aged which is sometimes productive of gangrene. *Arch Surg* 1890; 1 :323-9.
- [7] Horton BT, Magath TB, Brown GE. An undescribed form of arteritis of the temporal vessels. *May Clin Proc* 1932; 7: 700-1.
- [8] Horton BT, Magath TB. Arteritis of the temporal vessels; report of seven cases. *Staff Meeting Mayo Clinic* 1937; 12: 548-53.
- [9] Jennings GH. Arteritis of temporal arteries. *Lancet* 1938; 1: 424-8.
- [10] Gilmour JR. Giant cell chronic arteritis. *J Pathol Bacteriol* 1941;53: 263-77.
- [11] Kilbourne ED, Wolff HG. Cranial arteritis: a critical evaluation of the syndrome of temporal arteritis with report of a case. *Ann Intern Med* 1946; 24: 1- 10.
- [12] Liozon E, Boutros-Toni F, Ly K, Loustaud-Ratti V, Soria P, Vidal E. Silent or masked giant cell arteritis is associated with a strong inflammatory response and a benign short term course. *J Rheumatol* 2003; 30: 1272-6.
- [13] Simmons RJ, Cogan DG. Occult temporal arteritis. *Arch Ophthalmol* 1962; 68: 38-48.
- [14] Hayreh SS, Podhajsky PA, Zimmerman B. Occult giant cell arteritis: ocular manifestations. *Am J Ophthalmol* 1998; 125: 521-6.
- [15] Gran JT, Myklebust G. The incidence of polymyalgia rheu-matica and temporal arteritis in the county of Aust Agder, South Norway, 1987 - 1994. *J Rheumatol* 1997; 24: 1739-43.

- [16] Smeeth L, Cook C, Hall AJ. Incidence of diagnosed polymyalgia rheumatica and temporal arteritis in the United Kingdom, 1990-2001. *Ann Rheum Dis* 2006; 65: 1093-8.
- [17] Østberg G. Temporal arteritis in a large necropsy series. *Ann Rheum Dis* 1971; 30: 224-35.
- [18] Gonzalez-Gay MA, Martinez-Dubois C, Agudo M, Pompei O, Blanco R, Llorca J. Giant cell arteritis: epidemiology, diagnosis and management. *Curr Rheum Rep* 2010; 12: 436-42.
- [19] Nordborg C, Johansson H, Petursdottir V, Nordborg E. The epidemiology of biopsy-proven giant cell arteritis: special reference to changes in the age of the population. *Rheumatology* 2003; 42: 549-52.
- [20] Salvarani C, Crowson CS, O'Fallon M, Hunder GG, Gabriel SE. Reappraisal of the epidemiology of giant cell arteritis in Olmsted County, Minnesota, over a fifty-year period. *Arthr Care Res* 2004; 51: 264-8.
- [21] Gran JT, Myklebust G, Wilsgaard T, Jacobsen BK. Survival in polymyalgia rheumatica and temporal arteritis: a study of 398 cases and matched population controls. *Rheumatology* 2001; 40: 1238-42.
- [22] Matteson EL, Gold KN, Bloch DA, Hunder GG. Long-term survival of patients with giant cell arteritis in the American College of Rheumatology giant cell arteritis classification criteria cohort. *Am J Med* 1996; 100: 193-6.
- [23] Bengtsson BA, Malmwall BE. The epidemiology of giant cell arteritis including temporal arteritis and polymyalgia rheumatica. Incidences of clinical presentations and eye complications. *Arthritis Rheum* 1981; 24: 899-904.
- [24] Salvarani C, Macchioni P, Zizzi F, Mantovani W, Rossi F, Castri C, Capozzoli N, Baricchi R, Boiardi L, Chiaravalloti F. Epidemiologic and immunogenetic aspects of polymyalgia rheumatica and giant cell arteritis. *Arthritis Rheum* 1991; 34: 351-6.
- [25] Myklebust G, Gran JT. A prospective study of 287 patients with polymyalgia rheumatica and temporal arteritis: clinical and laboratory manifestations at onset of disease and at the time of diagnosis. *Br J Rheumatol* 1996; 35: 1161-8.
- [26] Pipinos II, Hopp R, Edwards WD, Radio SJ. Giant cell arteritis in a 17 year old male. *J Vasc Surg* 2006; 43: 1053-5.
- [27] Neshet G, Oren S, Lijovetzky G, Neshet R. Vasculitis of the temporal arteritis in the young. *Semin Arthritis Rheum* 2009; 39: 96-107.
- [28] Durant C, Connault J, Graveleau J, Toquet C, Brisseau JM, Hamidou M. Juvenile temporal vasculitis: a rare case in a middle-aged woman. *Ann Vasc Surg* 2011; 25: 384: e5-7.
- [29] Dinesh KP, Owolabi A, Dwyer-Joyce L, Cronin PM, Schimmer BM, Mo GP. Temporal artery vasculitis in young: a report of two cases. *Rheumatol Int* 2010; 30: 1393-6.
- [30] Gonzalez-Gay MA, Garcia-Porrua C, Amor-Dorado JC, Llorca J. fever in biopsy proven GCA: clinical implications in a defined population. *Arthritis Rheum* 2004; 51: 652-55.
- [31] Jundt J, Mock D. Temporal arteritis with normal erythrocyte sedimentation rate presenting as occipital neuralgia. *Arthritis Rheum* 1991; 34: 217-9.
- [32] Rahman W, Rahman FZ. Giant cell (temporal)arteritis: an overview and update. *Surv Ophthalmol* 2005; 50: 415-28.
- [33] Kawasaki A, Purvin V. Giant cell arteritis: an updated review. *Acta Ophthalmol Scand* 2009; 87: 13-32.

- [33] Becourt-Verlomme C, Barouky R, Alexandre C, Gonthier R, Laurent H, Vital Durand D, Rousset H. Symptomes inauguraux de la maladie de Horton sur une serie de 260 patients. *Rev Med Interne* 2001; 22: 631-7.
- [34] Calamia KT, Hunder GG. GCA (TA) presenting as fever of undetermined origin. *Arthritis Rheum* 1981; 24: 1414-18.
- [35] Aiello PD, Trautmann JC, McPhee TJ, Kunselman AR, Hunder GG. Visual prognosis in giant cell arteritis. *Ophthalmology* 1993; 100: 550-5.
- [36] Loddenkemper T, Sharma P, Katzan I, Plant GT. Risk factors for early visual deterioration in temporal arteritis. *J Neurol Neurosurg Psychiatry* 2007; 78: 1255-9.
- [37] Salvarani C, Cimino L, Macchioni P, Consonni D, Cantini F, Bajocchi G, Pipitone N, Catanoso MG, Biordi L. Risk factors for visual loss in an Italian population-based cohort of patients with giant cell arteritis. *Arthritis Rheum* 2005; 53: 293-7.
- [38] Gonzalez-Gay MA, Miranda-Fillooy JA, Lopez-Diaz MJ, Perez-Alvarez R, Gonzalez-Juanatey C, Sanchez-Andrade A, Marin J, Llorca J. Giant cell arteritis in Northwestern Spain. *Medicine* 2007; 86: 61-8.
- [39] Gonzalez-Gay MA, Garcia-Porrúa C, Llorca J, Hajeer AH, Branas F, Dababneh A, Gonzalez-Louzao C, Rodriguez-Gil E, Rodrig P, Ollier W. Visual manifestations of giant cell arteritis: trends and clinical spectrum in patients. *Medicine* 2000; 79: 283-92.
- [40] Bas-Lando M, Breuer GS, Berkun Y, Mates M, Sonnenblick M, Nesher G. The incidence of giant cell arteritis in Jerusalem over a 25-year period: annual and seasonal fluctuations. *Clin Exp Rheum* 2007; 25 (suppl. 44): S15-S17.
- [41] Miller NR. Visual manifestations of temporal arteritis. *Rheum Dis Clin North Amer* 2001; 27: 781-97.
- [42] Sonnenblick M, Nesher R, Rozenman Y, Nesher G. Charles Bonnet syndrome in temporal arteritis. *J Rheumatol* 1995; 22: 1596-7.
- [43] Razavi M, Jones RD, Manzel K, Fatal D, Rizzo M. Steroid-responsive Charles-Bonnet syndrome in temporal arthritis. *J Neuropsychiatry Clin Neurosci* 2004; 16: 505-8.
- [44] Chan CCK, Paine M, O'Day J. Predictors of recurrent ischemic optic neuropathy in giant cell arteritis. *J Neuro-Ophthalmol* 2005; 25: 14-7.
- [45] Danesch-Meyer H, Savino PJ, Gamble GG. Poor prognosis of visual outcome after visual loss from giant cell arteritis. *Ophthalmology* 2005; 112: 1098-1103.
- [46] Hayreh SS, Zimmerman B. Management of giant cell arteritis. *Ophthalmologica* 2003; 217: 239-59.
- [47] Andersson R, Malmwall BE, Bengtsson BÅ. Long-term corticosteroid treatment in giant cell arteritis. *Acta Med Scand* 1986; 220: 465-9.
- [48] Gonzalez-Gay MA, Blanco R, Rodriguez-Valverde V, Martinez-Taboada WM, Delgado-Rodriguez M, Figueroa M, Uriarte E. Permanent visual loss and cerebrovascular accidents in giant cell arteritis. *Arthritis Rheum* 1998; 41: 1497-1504.
- [49] Egge K, Mitbo A, Westby R. Arteritis temporalis. *Acta Ophthalmologica* 1966; 44: 49-56.
- [50] Hayreh SS, Zimmerman B, Kardon RH. Visual improvement with corticosteroid therapy in giant cell arteritis. Report of a large study and review of literature. *Acta Ophthalmol Scand* 2002; 80: 353-67.

- [51] Jallon P, Loron P, Borg M, Viallet F, Jan P, Force L. Cortical blindness from Horton's disease. *Rev Neurol (Paris)*. 1980; 136: 769-76.
- [52] Chisholm IH. Cortical blindness in cranial arteritis. *Br J Ophthalmol* 1975; 59: 332-3.
- [53] Hayreh SS, Podhajsky PA, Zimmerman B. Ocular manifestations of giant cell arteritis. *Am J Ophthalmol* 1998; 125: 509-20.
- [54] Glutz von Blotzheim S, Bourrat FX. Neuro-ophthalmic complications of biopsy proven giant cell arteritis. *Eur J Ophthalmol* 1997; 7: 375-82.
- [55] Wagener HP, Hollenhorst RW. The ocular lesions of temporal arteritis. *Am J Ophthalmol* 1958; 45: 617-30.
- [56] Font C, Cid MC, Coll-Vinent B, Lopez-Soto A, Grau JM. Clinical features in patients with permanent visual loss due to biopsy-proven giant cell arteritis. *Br J Rheumatol* 1997; 36: 251-4.
- [57] Cid MC, Oristrell J, de la Sierra A, Coll-Vinent B, Lopez-Soto A, Vilaseca J, Urbano-Marquez A, Grau JM. Association between strong inflammatory response and low risk of developing visual loss and other cranial ischemic complications in giant cell (temporal) arteritis. *Arthritis Rheum* 1998; 41: 26-32.
- [58] Liozon E, Herrmann F, Ly K, Robert PY, Loustaud V, Soria P. Risk factors for visual loss in giant cell (temporal) arteritis: a prospective study of 174 patients. *Am J Med* 2001; 111: 211-7.
- [59] Lopez-Diaz MJ, Llorca J, Gonzalez-Juanatey C, Pena-Sagredo JL, Martin J, Gonzalez-Gay MA. The erythrocyte sedimentation rate is associated with the development of visual complications in biopsy-proven giant cell arteritis. *Semin Arthritis Rheum* 2008; 38: 116-23.
- [60] Gonzalez-Gay MA, Lopez-Diaz MJ, Barros S, Garcia-Porrúa C, Sanchez-Andrade A, Paz-Carreira J, Martin J, Llorca J. Giant cell arteritis. Laboratory tests at the time of diagnosis in a series of 240 patients. *Medicine* 2005; 84: 277-90.
- [61] Salvarani C, Bella CD, Cimino L, Macchioni P, Formisano D, Bajocchi G, Pipitone N, Catasano MG, Restuccia G, Ghinoi A, Boiardi L. Risk factors for severe cranial ischemic events in an Italian population-based cohort of patients with giant cell arteritis. *Rheumatology* 2009; 48: 250-3.
- [62] Salvarani C, Hunder GG. Giant cell arteritis with low erythrocyte sedimentation rate: frequency of occurrence in a population-based study. *Arthritis Care Res* 2001; 45: 140-5.
- [63] Chatelain D, Duhaut P, Schmidt J, Loire R, Bosshard S, Guernou M et al. Pathological features of temporal arteries in patients with giant cell arteritis presenting with permanent visual loss. *Ann Rheum Dis* 2009; 68: 84-8.
- [64] Ezeonyeji AN, Borg FA, Dasgupta B. Delays in recognition and management of giant cell arteritis: result from a retrospective audit. *Clin Rheumatol* 2011; 30: 259-62.
- [65] Nuenninghoff DM, Hunder GG, Christianson TJH, McClelland RL, Matteson EL. Incidence and predictors of large-artery complication (aortic aneurysm, aortic dissection, and/or large-artery stenosis) in patients with giant cell arteritis. *Arthritis Rheum* 2003; 48: 3522-31.
- [66] Klein RG, Hunder GG, Stanson AW, Sheps SG. Large artery involvement in giant cell arteritis. *Ann Intern Med* 1975; 83: 806-12.

- [67] Assie C, Janvresse A, Plissonnier D, Levesque H, Marie I. Long-term follow-up of upper and lower extremity vasculitis related to giant cell arteritis. *Medicine* 2011; 90: 40-51.
- [68] Evans JM, O'Fallon M, Hunder GG. Increased incidence of aortic aneurysm and dissection in giant cell (temporal) arteritis: a population-based study. *Ann Intern Med* 1995; 122: 502-7.
- [69] Schmidt WA, Moll A, Seifert A, Schicke B, Gromnica-Ihle E, Krause A. Prognosis of large-vessel giant cell arteritis. *Rheumatology* 2008; 47: 1406-8.
- [70] Kermani TA, Matteson EL, Hunder GG, Warrington KJ. Symptomatic lower extremity vasculitis in giant cell arteritis: a case series. *J Rheumatol* 2009; 36: 2277-83.
- [71] Marie I, Proux A, Duhaut P, Primard E, Lahaxe L, Girszyn N, Louvet JP, Levesque H. Long-term follow-up of aortic involvement in giant cell arteritis: a series of 48 patients. *Medicine* 2009; 88: 182-92.
- [72] Agard C, Barrier JH, Dupas B, Ponge T, Mahr A, Fradet G, Chevalet P et al. Aortic involvement in recent-onset giant cell (temporal) arteritis: a case-control prospective study using helical aortic computed tomodensitometric scan. *Arthritis Care Res* 2008; 59: 670-6.
- [73] Garcia-Martinez A, Hernandez-Rodriguez J, Arguis P, Paredes P, Segarra M, Lozano E. Development of aortic aneurysm/dilatation during the follow-up of patients with giant cell arteritis: a cross-sectional screening of fifty-four prospectively followed patients. *Arthritis Care Res* 2008; 59: 422-30.
- [74] Sujobert P, Fardet L, Marie I, Duhaut P, Cohen P, Grange C, Gaultier JB, Arrive L, Cabane J. Mesenteric ischemia in giant cell arteritis : 6 cases and systematic review. *J Rheumatol* 2007; 34: 1727-32.
- [75] Bongartz T, Matteson EL. large-vessel involvement in giant cell arteritis. *Curr Opin Rheum* 2006; 18: 10-17
- [76] Brack A, Martinez-Taboada V, Stanson A, Goronzy JJ, Weyand CM. Disease pattern in cranial and large-vessel giant cell arteritis. *Arthritis Rheum* 1999; 42: 311-7.
- [77] Le Hello C, Levesque H, Jeanton M, Cailleux N, Galateau F, Peillon C, Veyssier P, Watelet J, Letellier P, Courtois H, Maiza D. Lower limb giant cell arteritis and temporal arteritis ; Follow-up of 8 cases. *J Rheumatol* 2001;28: 1407-12.
- [78] Schmidt WA, Moll A, Seifert A, Schicke B, Gromnica-Ihle E, Krause A. Prognosis of large-vessel giant cell arteritis. *Rheumatology* 2008; 47: 1406-8.
- [79] Sproul EE, Hawthorne JJ. Chronic diffuse mesaortitis; report of 2 cases of unusual type. *Am J Pathol* 1937; 13: 311-23.
- [80] Bossert M, Prati C, Balblanc JC, Lohse A, Wendling D. Aortic involvement in giant cell arteritis: current data. *Joint Bone Spine* 2011 e.pub.
- [81] Agard C, Ponge T, Fradet G, Baron O, Sagan C, Masseau A, barrier JH, Hamidou M. Giant cell arteritis presenting with aortic dissection: two cases and review of the literature. *Scand J Rheumatol* 2006; 35: 233-6.
- [82] Gonzalez-Gay MA, Garcia-Porrúa C, Pineiro A, Pego-Reigosa R, Llorca J, Hunder GG. Aortic aneurysm and dissection in patients with biopsy-proven GCA from northwestern Spain: a population-based study. *Medicine* 2004; 83: 335-41.
- [83] Evans J, Hunder GG. The implications of recognizing large-vessel involvement in elderly patients with giant cell arteritis. *Curr Opin Rheum* 1997; 9: 37-40.

- [84] Narvaez J, Narvaez JA, Nolla JM, Sirvent E, Reina D, Valverde J. Giant cell arteritis and polymyalgia rheumatica: usefulness of vascular magnetic resonance imaging studies in the diagnosis of aortitis. *Rheumatology* 2005; 44: 479-83.
- [85] Both M, Ahmadi-Simab K, Reuter M, Dourvos O, Fritzer E, Ullrich S, Gross WL, Heller M, Bahre M. MRI and FDG-PET in the assessment of inflammatory aortic arch syndrome in complicated courses of giant cell arteritis. *Ann Rheum Dis* 2008; 67: 1030-3.
- [86] Hautzel H, Sander O, Heinzl A, Schneider M, Muller HW. Assessment of large-vessel involvement in giant cell arteritis with 18F-FDG PET: introducing an ROC-analysis-based cutoff ration. *J Nucl Med* 2008; 49: 1107-13.
- [87] Bruschi M, de Leonardis F, Govoni M, Roncali M, Prandini N, La Corte R, Feggi L, Trotta F. 18 FDG-PET and large vessel vasculitis: preliminary data on 25 patients. *Reumatismo* 2008; 60: 212-6.
- [88] Blockmans D, de Ceuninck L, Vanderschueren S, Knockaert D, Mortelmans L, Bobbaers H. Repetitive 18F-Fluorodeoxyglucose positron emission tomography in giant cell arteritis: a prospective study of 35 cases. *Arthritis Rheum* 2006; 55: 131-7.
- [89] Lehman P, Buchtala S, Achajew N, Haerle P, Ehrenstein B, Lighvani H, Fleck M, Marienhagen J. 18F-FDG PET as a diagnostic procedure in large vessel vasculitis – a controlled, blinded re-examination of routine PET scans. *Clin Rheum* 2011; 30: 37-42.
- [90] Neunninghoff DM, Hunder GG, Christianson TJH, McClelland RL, Matteson EL. Mortality of large-artery complications (aortic aneurysm, aortic dissection and/or large-artery stenosis) in patients with giant cell arteritis. *Arthritis Rheum* 2003;48: 3532-7.
- [91] Herve F, Choussy V, Janvresse A, Cailleux N, Levesque H, Marie I. Aortite inflammatoire et maladie de Horton. A propos du suivi evolutif scanographique prospectif d'une serie de 11 patients. *Rev Med Interne* 2006; 27: 196-202.
- [92] Butler N, Mundy J, Shah P. Aortic complications of giant cell arteritis: a diagnostic and management dilemma. *J Card Surg* 2010; 25: 572-81.
- [93] Burke AP, Tavora F, Narula N, Tomaszewski JE, Virmani R. Aortitis and ascending aortic aneurysm: description of 52 cases and proposal of a histologic classification. *Hum Pathol* 2008; 39: 514-26.
- [94] Caselli R, Hunder GG, Whisnant JP. Neurolog disease in biopsy-proven giant cell (temporal) arteritis. *Neurology* 1988; 38: 352-9.
- [95] Bley TA, Geiger J, Jacobsen S, Wieben O, Markl M, Vaith P, Grist T, Langer M, Uhl M. High resolution MRI for assessment of middle artery involvement in giant cell arteritis. *Ann Rheum Dis* 2009; 68: 1369-70.
- [96] Gonzalez-Gay MA, Vasquez-Rodriguez TR, Gomez-Acebo I, Pego-Reigosa R, Lopez-Diaz MJ, Vasquez-Trinanes MC. Strokes at the time of disease diagnosis in a series of 287 patients with biopsy-proven giant cell arteritis. *Medicine* 2009; 88: 227-35.
- [97] Pego-Reigosa R, Garcia-Porrúa C, Pineiro A, Dierssen T, Llorca J, Gonzalez-Gay MA. Predictors of cerebrovascular accidents in giant cell arteritis in a defined population. *Clin Exp Rheum* 2004; 22 (suppl. 36): S13-S17.
- [98] Solans-Laqué R, Bosch-Gil JA, Molina-Catenario CA, Ortega-Aznar A, Alvarez-Sabin J, Vilardel-Tarres M. Stroke and multi-infarct dementia as presenting symptoms of

- giant cell arteritis: report of 7 cases and review of the literature. *Medicine* 2008; 87: 335-44.
- [99] Lu-Emerson C, Walker M, Huber BR, Ghodke B, Longstreth WT Jr, Khot SP. Lethal giant cell arteritis with multiple ischemic strokes despite aggressive immunosuppressive therapy. *J Neurol Sci* 2010; 295: 120-4.
- [100] Fitzgerald AJ, Ironside JW, Summers DM, Dennis MS, McRorie ER. Two cases of recurrent stroke in treated giant cell arteritis: diagnostic and therapeutic dilemmas. *J Clin Rheumatol* 2010; 16: 225-8.
- [101] Staunton H, Stafford F, Leader M, O'Riordan D. Deterioration of giant cell arteritis with corticosteroid therapy. *Arch Neurol* 2000; 57: 581-4.
- [102] Cooke WT, Cloake PCP, Govan ADT. Temporal arteritis: a generalised vascular disease. *Q J med* 1946; 15: 47-75.
- [103] Campbell FA, Clark C, Holmes S. Scalp necrosis in temporal arteritis. *Clin Exp Derm* 2003; 28: 488-90.
- [104] Simon RW, Fritz T, Anmann-Vesti BR. An unusual presentation of giant cell arteritis. *Vasa* 2005; 34: 128-30.
- [105] Currey J. Scalp necrosis in giant cell arteritis and review of the literature. *Br J Rheumatol* 1997; 36: 814-6.
- [106] Tsianakas A, Ehrchen JM, Presser D, Fischer T, Kruse-Loesler B, Luger TA, Sunderkoetter C. Scalp necrosis in giant cell arteritis: case report and review of this cutaneous sign of large-vessel vasculitis. *J Am Acad Dermatol* 2009; 61: 701-6.
- [107] Brick KE, Cook-Norris RH, Wetter DA, Warrington KJ. Scalp necrosis in giant cell arteritis after initiation of therapeutic corticosteroids. *J Am Acad Dermatol* 2010; 63: 343-4.
- [108] Rockey JG, Anand R. Tongue necrosis secondary to temporal arteritis: a case report and literature review. *Oral Surg Oral Med Oral Pathol Oral Radiol Endo* 2002; 94: 471-3.
- [109] Davis AE, Davis TP. Gangrene of the tongue caused by temporal arteritis. *Med J Aust* 1966; 2: 459-60.
- [110] Goicochea M, Correale J, Bonamico L, Dominguez R, Bagg E, famulari A, Ameriso S, Sevelev G. Tongue necrosis in temporal arteritis. *Headache* 2007; 47: 1213-5.
- [111] Mathew SD, Bristow K, Higgs J. Giant cell arteritis presenting as ageusia and lower extremity claudication. *J Clin Rheumatol* 2010; 16: 343-4.
- [112] Alisky JM. Giant cell arteritis dementia and other steroid-responsive dementia syndromes are a unique opportunity for clinicians and researchers. *Singapore Med J* 2008; 49: 268-70.
- [113] Tomer Y, Neufeld MY, Shoenfeld Y. Coma with triphasic pattern in EEG as a complication of temporal arteritis. *Neurology* 1992; 42: 429-40.
- [114] Silbert PL, Stewart-Wynne EG. Seizures and giant cell temporal arteritis: what is the relationship? *Aust N Z J Med* 1992; 22: 307.
- [115] Fruchter O, Ben-Ami H, Schapira D, Gallimidi Z, Gaitini D, Goldsher D. Giant cell arteritis complicated by spinal cord infarction: a therapeutic dilemma. *J Rheumatol* 2002; 29: 1556-8.
- [116] Galetta SL, Balcer LJ, Lieberman AP, Syed NA, Lee JM, Oberholtzer JC. Refractory giant cell arteritis with spinal cord infarction. *Neurology* 1997; 49: 1720-3.

- [117] McAlindon TE, Ferguson IT. Mononeuritis multiplex and occipital infarction complicating giant cell arteritis. *Br J Rheumatol* 1989; 28: 257-8.
- [118] Kawaguchi Y, Ebina M, Sato T, Ishiguro Y, Yagihashi S, Hirota K. A case of trigeminal neuralgia complicated by ipsilateral temporal arteritis. *J Anest* 2010; 24: 139-42.
- [119] Edvardsson B, Eriksson B. Giant cell arteritis and bilateral nerve palsy. *Scand J Rheumatol* 2010; 39: 269-70.
- [120] Donadini M, Dentali F, Squizzato A, Ageno W. An unusual case of cerebral vein thrombosis in a patient with giant cell arteritis. *Thromb Haemost* 2008; 100: 513-4.
- [121] Chisholm IH. Cortical blindness in cranial arteritis. *Br J Ophthalmol* 1975; 59: 332-3.
- [122] Guly CM, Olson JA. Transient ischemic attacks. Giant cell arteritis and transient visual loss. *Br Med J* 2009; 338:b1809.
- [123] Morris OC, Lockie P. Giant cell arteritis presenting as stroke, transient ischemic attacks and dementia. *Aust Fam Physician* 2005; 34: 653-5.
- [124] Paraskevas KI, Boumpas DT, Vrentzos GE, Mikhailidis DP. Oral and ocular/orbital manifestations of temporal arteritis : a disease with deceptive clinical symptoms and devastating consequences. *Clin Rheumatol* 2007; 26: 1044-8.
- [125] Larson TS, Hall S, Hepper NG, Hunder GG. Respiratory tract symptoms as a clue to GCA. *Ann Intern Med* 1984; 101:594-7.
- [126] Lee CC, Su WW, Hunder GG. Dysarthria associated with GCA. *J Rheumatol* 1999; 26:931-2.
- [127] Ramos R, Vila R, Penin R, Cairols MA. Giant cell arteritis presenting as dysarthria and mediastinal mass. *Interact Cardiovasc Thor Surg* 2010; 11: 337-9.
- [128] Levine SM, Hellmann DB. Giant cell arteritis. *Curr Opin Rheum* 2002; 14: 3-10.
- [129] Kinmont PDC, MacCallum DI. The aetiology, pathology and course of giant-cell arteritis. The possible role of light-sensitivity. *Br J Derm* 1965; 77: 193-202.
- [130] Helfrich DJ, Mulhern LM, Luparello FJ, Smith W Jr. Giant cell arteritis of the tongue presenting as macroglossia. *J Rheumatol* 1988; 15: 1026-8.
- [131] Liozon E, Ouattara B, Portal MF, Soria P, Loustaud-Ratti V, Vidal E. Head-and-neck swelling: an under-recognized feature of giant cell arteritis: a report of 37 patients. *Clin Exp Rheum* 2006; 24 (suppl.41):S20-S25.
- [132] Ricketti AJ, Cleri DJ, Godyn JJ, Shenk SH, Vernaleo JR. Giant cell arteritis presenting as facial swelling. *Allergy Asthma Proc* 2008; 29: 538-50.
- [133] Amor-Dorado JC, Llorca J, Garcia-Porrúa C, Costa C, Perez-Fernandez N, Gonzalez-Gay MA. Audiovestibular manifestations in giant cell arteritis. A prospective study. *Medicine* 2003; 82: 13- 26.
- [134] Lee AG, Tang RA, Schiffman JS, Feldon SE, Rao N, Pless M, Rubin RM. Orbital presentation of giant cell arteritis. *Graefe's Arch Clin Exp Ophthalmol* 2001; 239: 509-13.
- [135] Arai M, Katsumata R. Temporal arteritis presenting with headache and abducens palsy. Report of a case. *Rhinso Shinkeigaku* 2007; 47: 444-6.
- [136] Liou LM, Khor TK, Lan SH, Lai CL. Giant cell arteritis with multiple cranial nerve palsy and reversible proptosis: a case report. *Headache* 2007; 47: 1451-3.
- [137] Scola CJ, L C, Upchurch KS. Mesenteric involvement in giant cell arteritis. An unrecognized complication? *Medicine* 2008; 87: 45-51.
- [138] Azeez MA, Browne P, O'Connell P, Roysten D. Giant cell arteritis involving the mesenteric arteries. *J Rheumatol* 2009; 36:2314-5.

- [139] Annamalai A, Francis ML, Ranatunga SK, Resch DS. Giant cell arteritis presenting as small bowel infarction. *J Gen Intern Med* 2007; 22: 140-4.
- [140] Srigley JR, Gardiner GW. Giant cell arteritis with small bowel infarction. A case report and review of the literature. *Am J Gastroenterol* 1980; 73: 157-61.
- [141] Bajocchi G, Zamorani G, Cavazza A. GCA of the female genital tract associated with occult arteritis and FDG-PET evidence of large vessel vasculitis. *Clin Exp Rheum* 2007;25 (suppl 44):S36-39.
- [142] Onuma K, Chu CT, Dabbs DJ. Asymptomatic giant-cell (temporal) arteritis involving the bilateral adnexa: case report and literature review. *Int J Gynecol Pathol* 2007;26: 352-5.
- [143] Hernandez-Rodriguez J, Tan CD, Rodriguez R, Hoffman GS. Gynecologic vasculitis. *Medicine* 2009; 88: 169-81.
- [144] Valstar MH, Terpstra WF, de Jong RS. Pericardial and pleural effusions in GCA. *Am J Med* 2003; 114: 708-9.
- [145] Graffin B, Carli P. Respiratory manifestations of giant cell arteritis : 8 cases and review of the literature. *Presse Med* 2010; 39: e188-96.
- [146] Moulis G, Sailler L, Astudillo L, Vernet J, Couret B, Arlet P. Pericarditis as the presenting manifestation of giant cell arteritis. *Rev Med Interne* 2010; 31: 46-8.
- [147] Kechaou M, Frigui M, Marzouk S, Jallouli M, Frikha F, Kaddour N, Boudawara T, Bahloul Z. Pleural effusion revealing Horton`s disease. *Rev Med Liege* 2008; 63: 650-3.
- [148] Carassou P, Aletti M, Cinquetti G, Banal F, Landais C, Graffin B, Carli P. Respiratory manifestations of giant cell arteritis : 8 cases and review of the literature. *Presse Med* 2010; 39: e188-96.
- [149] Lie JT, Failoni DD, Davies DC Jr. Temporal arteritis with giant cell aortitis, coronary arteritis, and myocardial infarction. *Arch Pathol Lab Med* 1986; 110:857-60.
- [150] Lander H, Bonnin JM. Giant cell arteritis. Report of a case with autopsy. *J Path Bacteriol* 1956;71:369-73.
- [151] Eberhardt RT, Dhadly M. Giant cell arteritis: diagnosis, management and cardiovascular implications. *Cardiol Rev* 2007; 15: 55-61.
- [152] Morris CR, , Scheib JS. Fatal myocardial infarction resulting from coronary arteritis in a patient with polymyalgia rheumatica and biopsy-proved temporal arteritis. A case report and review of the literature. *Arch Int Med* 1994; 154: 1158-60.
- [153] Jithpratuck W, Wason WW, Elsenawy Y. Acute bilateral ischemia of fingers: an unusual complication of temporal arteritis. *South Med J* 2010; 103: 1178-80.
- [154] Kadotani Y, Enoki Y, Itoi N, Kojima F, Kato G, Lee CJ. Giant cell arteritis of the breast: a case report with a review of literures. *Breast Cancer* 2010; 17: 225-32.
- [155] Kariv R, Sidi Y, Gur H. Systemic vasculitis presenting as a tumorlike lesion. Four case reports and an analysis of 79 reported cases. *Medicine* 2000; 79: 349-59.
- [156] Luzar MJ, Whisler RL, Hunder GG. Syndrome of inappropriate secretion of antidiuretic hormone in association with temporal arteritis. *J Rheumatol* 1982; 9: 957-60.
- [157] Mallia C, Coleiro B, Crockford M, Ellul B. Raynaud`s phenomenon caused by giant cell arteritis. A case report. *Adv Exp Med Biol* 1999; 455: 517-20.

- [158] Zauber NP, Echikson AB. Giant cell arteritis and microangiopathic hemaolytic anemia. *Am J Med* 1982; 73: 928-30.
- [159] Chambers BR, Donnan GA, Riddell RJ, Bladin PF. Carotidynia: aetiology, diagnosis and treatment. *Clin Exp Neurol* 1981; 17: 113-23.
- [160] Truong L, Kopelman RG, Williams GS, Pirani CL. Temporal arteritis and renal disease. Case report and review of the literature. *Am J Med* 1985;78: 171-5.
- [161] Salvarani C, Gabriel SE, O'Fallon WM, Hunder GG. The incidence of GCA in Olmstead County, Minnesota: apparent fluctuation in a cyclic pattern. *Ann Intern med* 1995; 123: 192-4.
- [162] Ranzen P, Sutinen S, von Knorring J. GCA and PMR in a region of Finland: an epidemiologic, clinical and pathologic study. *J Rheumatol* 1992; 19: 273-80.
- [163] Porsman VA. Arthritis in old age. *Proc II Congr Europ Rheum (Barcelona)*. 1951:481-97.
- [164] Gran JT, Myklebust G. Incidence and clinical characteristics of peripheral arthritis in polymyalgia rheumatica and temporal arteritis. *Rheumatology* 2000; 39: 283-7.
- [165] Moosig F, Czech N, Mehi C, Henze E, Zenner RA, Kneba M, Schröder JO. Correlation between 18-fluorodeoxyglucose accumulation in large vessels and serological markers of inflammation in polymyalgia rheumatica: a quantitative PET study. *Ann Rheum Dis* 2004; 63: 870-3.
- [166] Blockmans D, Maes A, Stroobants S, Nuyts J, Bormans G, Knockaert D, Bobbaers H, Mortelmans L. New arguments for a vasculitic nature of polymyalgia rheumatica using positron emission tomography. *Rheumatology* 1999; 38: 444-7.
- [167] Aletig K, Barr J. Giant cell arteritis: a biopsy study of polymyalgia rheumatica, including one case of Takayasu's disease. *Lancet* 1963; 1: 1228-30.
- [168] Hamrin B, Jonsson N, Landberg T. Arteritis in "polymyalgia rheumatica". *Lancet* 1964; 1: 397-401.
- [169] Nordborg E, Nordborg C. The influence of sectional interval on the reliability of temporal artery biopsies in polymyalgia rheumatica. *Clin Rheumatol* 1995; 14: 330-4.
- [170] Myklebust G, Gran JT. Prednisolone maintenance dose in relation to starting dose in the treatment of polymyalgia rheumatica and temporal arteritis. *Scand J Rheumatol* 2001; 30: 260-7.
- [171] Kyle V, Hazleman BL. The clinical and laboratory course of polymyalgia rheumatica/giant cell arteritis after the first two months of treatment. *Ann Rheum Dis* 1993; 52:847-50.
- [172] Parikh M, Miller NR, Lee AG, Savino PJ, Vacarezza MN, Cornblath W, Eggenberger E, Antonio-Santos A, Golnik K, Kardon R, Wall M. Prevalence of a normal C-reactive protein with an elevated erythrocyte sedimentation rate in biopsy-proven giant cell arteritis. *Ophthalmology* 2006; 113: 1842-5.
- [173] Wise CM, Agudelo CA, Chmelewski WL, McKnight KM. Temporal arteritis with low erythrocyte sedimentation rate: a review of five cases. *Arthritis Rheum* 1991; 34: 1571-4.
- [174] Kansu T, Corbett JJ, Savino P, Schatz NJ. Giant-cell arteritis with normal erythrocyte sedimentation rate. *Arch Neurol* 1977; 34: 624-5.
- [175] Ellis ME, Ralston S. The ESR in the diagnosis and management of polymyalgia rheumatica/giant cell arteritis syndrome. *Ann Rheum Dis* 1983; 42: 168-70.

- [176] Grodum E, Petersen HA. Temporal arteritis with normal erythrocyte sedimentation rate. *J Intern Med* 1990; 227: 279-80.
- [177] Ciccarelli M, Jeanmonod D, Jeanmonod R. Giant cell arteritis with a normal erythrocyte sedimentation rate: report of a case. *Am J Emerg Med* 2009; 255: e1-3.
- [178] Nesh PR, Sergent JS. Giant cell arteritis: a case with unusual neurologic manifestations and a normal sedimentation rate. *Arch Intern Med* 1991; 151: 378-80.
- [179] Desmet GD, Knockaert DC, Bobbaers HJ. Temporal arteritis: the silent presentation and delay in diagnosis. *J Int Med* 1990; 227: 237-40.
- [180] Foroozan R, Danesch-Meyer H, Savino PJ, Gamble G, Mekari-Sabbagh ON, Sergott RC. Thrombocytosis in patients with biopsy-proven giant cell arteritis. *Ophthalmology* 2002; 109: 1267-71.
- [181] Hayreh SS, Podhajsky PA, Raman R, Zimmerman B: GCA: validity and reliability of various diagnostic tests. *Am J Ophthalmol* 1997; 123: 285-96.
- [182] Kyle V. Laboratory investigations including liver in polymyalgia rheumatica/giant cell arteritis. *Bailliere's Clin Rheum* 1991; 5: 475-84.
- [183] Goronzy JJ, Weyand CM. Cytokines in giant-cell arteritis. *Clev Clin J Med* 2002; 69: suppl II: 91-4.
- [184] Dasgupta B, Panayi GS. Interleukin 6 in serum of patients with polymyalgia rheumatica and giant cell arteritis. *Br J Rheum* 1990; 29:456-8.
- [185] Weyand CM, Fulbright JW, Hunder GG, Evans JM, Goronzy JJ. Treatment of giant cell arteritis: interleukin-6 as a biologic marker of disease activity. *Arthritis Rheum* 2000; 43: 1041-8.
- [186] Garcia-Martinez A, Hernadez-Rodriguez J, Espigol-Frigole G, Prieto-Gonzalez S, Butjosa M, Segarra M, Lozano E, Cid MC. Clinical relevance of peristently elevated circulating cytokines (tumor necrosis factor- α and interleukin-6) in the long-term followup of patients with giant cell arteritis. *Arthritis Care Res* 2010; 62: 835-41.
- [187] Schmidt WA, Kraft HE, Vorpahl, Volker L, Gromnica-Ihle EJ. Color duplex ultrasonography in the diagnosis of temporal arteritis. *N Engl J Med* 1997;337:1336-42.
- [188] Schmidt WA, Natusch A, Moller DE, Vorpahl K, Grominca-Ihle E. Involvement of peripheral arteries in giant cell arteritis: a color doppler sonography study. *Clin Exp Rheum* 2002; 20: 309-18.
- [189] Pfadenhauer K, Weber H. Giant cell arteritis of the occipital arteries – a prospective color-coded duplex sonography study in 78 cases. *J Neurol* 2003; 250: 844-9.
- [190] Houtman PM, Doorenbos BM, Dol J, Bruyn GAW. Doppler ultrasonography to diagnose temporal arteritis in the setting of a large community hospital. *Scand J Rheumatol* :2008; 37: 316-8.
- [191] Maldini C, Depinay-Dhellemmes C, Tra TTS, Chauveau M, Allanore Y, Gossec L et al. Limited value of temporal artery ultrasonography examinations for diagnosis of giant cell arteritis: analysis of 77 subjects. *J Rheumatol* 2010; 37: 2326-30.
- [192] Karahaliou M, Vaiopoulos G, Papaspyrou S, Kanakis MA, Revenas K, Sfikakis PP. Colour duplex sonography of temporal arteries before decision for biopsy: a prospective study in 55 patients with suspected giant cell arteritis. *Arthr Res Ther* 2006; 8: R116.
- [193] Karassa FB, Matsagas MI, Schmidt WA, Ioannidis JPA. Meta-analysis: test performance of ultrasonography for giant cell arteritis. *Ann Intern Med* 2005; 142: 359-69.

- [194] Arida A, Kyprianou M, Kanakis M, Sfikakis PP. The diagnostic value of ultrasonography-derived edema of the temporal artery wall in giant cell arteritis: a second meta-analysis. *BMC Musculoskeletal Disorders* 2010; 11: 44-51.
- [195] Murgatroyd H, Nimmo M, Evans A, MacEwen C. The use of ultrasound as an aid in the diagnosis of giant cell arteritis: a pilot study comparing histological features with ultrasound findings. *Eye* 2003; 17: 415-9.
- [196] Ponge T, Barrier JH, Grolleau JY, Ponge A, Vlasak AM, Cottin S. The efficacy of selective unilateral temporal artery biopsy versus bilateral biopsies for diagnosis of giant cell arteritis. *J Rheumatol* 1988; 15: 997-1000.
- [197] Bley TA, Uhl M, Carew J, Markl M, Schmidt D, Peter HH, Langer M, Wieben O. Diagnostic value of high-resolution MR imaging in giant cell arteritis. *Am J Neuroradiol* 2007; 28: 1722-7.
- [198] Hunder GG, Bloch DA, Michel BA, Stevens MB, Arend WP, American College of Rheumatology 1990 criteria for the classification of giant cell arteritis. *Arthritis Rheum* 1990; 33: 1122-8.
- [199] Khoury K, Hoxworth JM, Mazlumzadeh M, Wellik KE, Wingerchuk DM, demaerschalk BM. The clinical utility of high resolution magnetic resonance imaging in the diagnosis of giant cell arteritis: a critically appraised topic. *Neurologist* 2008; 14: 330-5.
- [200] Both M, Ahmadi-Simab K, Reuter M, Dourvos O, Fritzer E, Ullrich S, Gross Wl, Heller M, Bahre M. MRI and FDG-PET in the assessment of inflammatory aortic arch syndrome in complicated courses of giant cell arteritis. *Ann Rheum Dis* 2008; 67: 1030-3.
- [201] Bley TA, Wieben O, Uhl M, Thiel J, Schmidt D, Langer M. High-resolution MRI in giant cell arteritis: imaging of the wall of the superficial temporal artery. *Am J Radiol* 2005; 184: 283-7.
- [202] Turlakow A, Yeung HWD, Pui J et al. Fluorodeoxyglucose positron emission tomography in the diagnosis of giant cell arteritis. *Arch Intern Med* 2001; 161: 1003-7.
- [203] Meller J, Strutz F, Siefker U et al. Early diagnosis and follow-up of aortitis with (18F) fluorodeoxyglucose PET and MRI. *Eur J Nucl Med Mol Imaging* 2003; 30: 730-6.
- [204] Walter MA, Melzer RA, Schindler C, Muller-Brand J, Tyndall A, Nitzsche EU. The value of (18F) FDG-PET in the diagnosis of large-vessel vasculitis and the assessment of activity and extent of disease. *Eur J Nucl Med Mol Imaging* 2005; 32: 674-81.
- [205] De Leeuw, Bijl M, Jager PL. Additional value of positron emission tomography in diagnosis and follow-up of patients with large vessel vasculitides. *Clin Exp Rheum* 2004; 22 (suppl. 36): S21-S26.
- [206] Dasgupta B, Borg FA, Hassan N, Alexander L, Barraclough K, Bourke B, Fulcher J. BSR and BHPR guidelines for the management of giant cell arteritis. *Rheumatology* 2010; 49: 1594-7.
- [207] Mukhtyar C, Guillevin L, Cid MC, de Groot K, Gross W, Hauser T et al. EULAR recommendations for the management of large vessel vasculitis. *Ann Rheum Dis* 2009; 68: 318-23.
- [208] Lessel S. Bilateral temporal artery biopsy in giant cell arteritis. *J Neuroophthalmol* 2000; 20: 220-1.

- [209] Carroll SC, Gaskin BJ, Danesh-Meyer H. Giant cell arteritis. *Clin Exp Ophthalmol* 2006; 34: 159-73.
- [210] Belilos E, Maddox J, Kowalewski RM, Kowalewska J, Turi GK, Nochomovitz LE, Khan Y, Carsons SE. Temporal small-vessel inflammation in patients with giant cell arteritis: clinical course and preliminary immunohistopathologic characterization. *J Rheumatol* 2011; 38: 331-8.
- [211] Klein RG, Campbell RJ, Hunder GG, Carney JA. Skip lesions in temporal arteritis. *Mayo Clin Proceed* 1976; 51: 504-10.
- [212] Poller D, van Wyk Q, Jeffrey M. The importance of skip lesions in temporal arteritis. *J Clin Pathol* 2000; 53: 137-9.
- [213] Kawasaki A, Michel P, Maeder P, Borruat FX. Visualizing the skip lesions of giant cell arteritis with CT angiography. *Eur Neurol* 2009; 61: 374-7.
- [214] Albert DM, Ruchman MC, Keitner JL. Skip lesions in temporal arteritis. *Arch Ophthalmol* 1976; 94: 2072-7.
- [215] Mahr A, Saba M, Kambouchner M, Polivka M, Baudrimont M, Brocheriou I, Coste J, Guillemin L. Temporal artery biopsy for diagnosing giant cell arteritis: the longer, the better? *Ann Rheum Dis* 2006; 65: 826-8.
- [216] Arashvand K. The value of temporal artery biopsy specimen length in the diagnosis of giant cell arteritis. *Rheumatol* 2007; 34: 1945.
- [217] Taylor-Gjevre R, Vo M, Shukla D, Resch L. Temporal biopsy for giant cell arteritis. *J Rheumatol* 2005;32:1279-82.
- [218] Breuer GS, Nesher R, Nesher G. Effect of biopsy length on the rate of positive temporal artery biopsies. *Clin Exp Rheum* 2009; 27 (suppl 52):S10-S13.
- [219] Sharma NS, Ooi JL, Mcgarity BH, Vollmer-Conna U, McCluskey P. The length of superficial temporal artery biopsies. *ANZ J Surg* 2007; 77: 437-9.
- [220] Pless M, Rizzo JF, Lamkin JC, Lessell S. Concordance of bilateral temporal artery biopsy in giant cell arteritis. *J Neuro-Ophthalmol* 2000; 20: 216-8.
- [221] Breuer GS, Nesher G, Nesher R. Rate of discordant findings in bilateral temporal artery biopsy to diagnose giant cell arteritis. *J Rheumatol* 2009; 36: 794-6.
- [222] Boyev LR, Miller NR, Green WR. Efficacy of unilateral versus bilateral temporal artery biopsies for the diagnosis of giant cell arteritis. *Am J Ophthalmol* 1999; 128: 211-5.
- [223] Hall JK, Balcer LJ. Giant cell arteritis. *Curr Treatment Options Neurol* 2004; 6: 45-53.
- [224] arvaez J, Bernad B, Roig-Vilaseca D, Garcia-Gomez C, Gomez-Vaquero C, Juanola X, Rodriguez-Moreno J, Nolla JM, Valverde J. Influence of previous corticosteroid therapy on temporal artery biopsy yield in giant cell arteritis. *Semin Arthritis Rheum* 2007; 37: 13-19.
- [225] Rieck KL, Kermani TA, Thomsen KM, Harmsen WS, Karban MJ, Warrington KJ. Evaluation for clinical predictors of positive temporal artery biopsy in giant cell arteritis. *J Oral Maxillofac Surg* 2011; 69: 36-40.
- [226] Ackar AA, Lie JT, Hunder GG, O'Fallon WM, Gabriel SE. How does previous corticosteroid treatment affect the biopsy findings in giant cell (temporal) arteritis? *Ann Intern Med* 1994; 120: 987-92.
- [227] Ray-Chaudhuri K, Kine DA, Tijani SO, Parums DV, Cartlidge N, Strong NP, Dayan MR. Effects of prior steroid treatment on temporal artery biopsy findings in giant cell arteritis. *Br J Ophthalmol* 2002; 86: 530-2.

- [229] Allison MC, Gallagher PJ. Temporal artery biopsy and corticosteroid treatment. *Ann Rheum Dis* 1984; 43: 416-17.
- [230] Blumberg S, Giansiracusa DF, Docken WP, Kantrowitz FG. Recurrence of temporal arteritis: clinical recurrence nine years after initial illness. *JAMA* 1980; 244: 1713-4.
- [231] Font RL, Venkatesh C, Prabhakaran C. Histological parameters helpful in recognising steroid-treated temporal arteritis: an analysis of 35 cases. *Br J Ophthalmol* 2007; 91: 204-9.
- [232] ter Borg EJ, Haanen HCM, Seldenrijk CA. Relationship between histological subtypes and clinical characteristics at presentation and outcome in biopsy-proven giant cell arteritis. *Clin Rheumatol* 2006; 26: 529-32.
- [233] Villaseca J, Gonzalez A, Cid MC, Lopez-Viancos J, Ortega A. Clinical usefulness of temporal artery biopsy. *Ann Rheum Dis* 1987; 46: 282-5.
- [234] Fernandez-Herlihy L. Temporal arteritis: clinical aids to diagnosis. *J Rheumatol* 1988; 15: 1797-1801.
- [235] Mari B, Monteagudo M, Bustamante E, Perez J, Casanovas A, Jordana R, Tolosa C, Oristrell J. Analysis of temporal artery biopsies in an 18-year period at a community hospital. *Eur J Intern Med* 2009; 20: 533-6.
- [236] Rodriguez-Pla A, Rossello-Urgell J, Bosch-Gil JA, Huguet-redecilla P, Vilardell-Tarres M. Proposal to decrease the number of negative temporal artery biopsies. *Scand J Rheumatol* 2007; 36: 111-8.
- [237] Younge BR, Cook BE, Bartley GB, Hodge DO, Hunder GG. Initiation of glucocorticoid therapy: before or after temporal artery biopsy. *Mayo Clin Proc* 2004; 79: 483-91.
- [238] Nordborg E, Nordborg C. The influence of sectional interval on the reliability of temporal arterial biopsies in polymyalgia rheumatica. *Clin Rheumatol* 1995; 14: 330-4.
- [239] Rao JK, Allen NB, Pincus T. Limitations of the 1990 American College of Rheumatology classification criteria in the diagnosis of vasculitis. *Ann Intern Med* 1998; 129: 345-52.
- [240] Fraya RA, Abu-Haidar F. Polyarteritis nodosa masquerading as temporal arteritis. *J Rheumatol* 1979; 6: 76-9.
- [241] Nishino H, de Remee RA, Rubino FA. Wegener's granulomatosis associated with vasculitis of the temporal arteries. Report of five cases. *May Clin Proceed* 1993; 68: 115-21.
- [242] Genereau T, Lortholary O, Pottier MA, Michon-Pasturel U, Ponge T, de Wazieres B, Liozon E, Pinede E, Hachulla E, Roblot P, barrier JH, Herson S, Guillevin L. Temporal artery biopsy: a diagnostic tool for systemic necrotizing vasculitis. French vasculitis study group. *Arthritis Rheum* 1999; 42: 2674-81.
- [243] Salvarani C, Gabriel SE, Gertz MA, Björnsson J, Li CY, Hunder GG. Primary systemic amyloidosis presenting as GCA and PMR. *Arthritis Rheum* 1994; 37: 1621-6.
- [244] Jianguang J, Liu X, Sundquist K, Sundquist J, Hemminki K. Cancer risk in patients hospitalized with polymyalgia rheumatica and giant cell arteritis: a follow-up study in Sweden. *Rheumatology* 2010; 49: 1158-63.
- [245] Haga HJ, Eide GE, Brun J, Johansen A, Langmark F. Cancer in association with polymyalgia rheumatica and temporal arteritis. *J Rheumatol* 1993; 20: 1335-9.

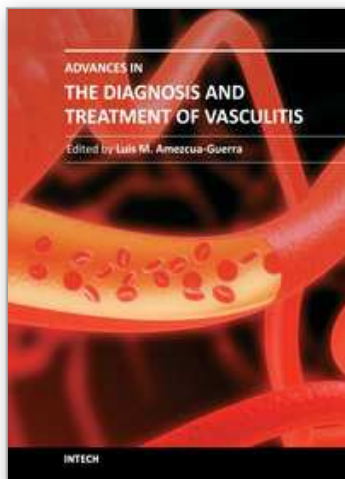
- [246] Kermani TA, Schafer VS, Crowson CS, Hunder GG, Gabriel SE, Ytterberg SR, Matteson EL, Warrington KJ. Malignancy risk in patients with giant cell arteritis: a population-based cohort study. *Arthritis Care Res* 2010; 62: 149-54.
- [247] Kermani TA, Schafer VS, Crowson CS, Hunder GG, Ytterberg SR, Matteson EL, Gabriel SE, Warrington KJ. Cancer preceding giant cell arteritis: a case-control study. *Arthritis Rheum* 2010; 62: 1763-9.
- [248] Hill CL, Cole A, Rischmueller M, Dodd T, Coleman M, Tucker G, Roberts-Thomson P. Risk of cancer in patients with biopsy-proven giant cell arteritis. *Rheumatology* 2010; 49: 756-9.
- [249] von Knorring J, Somer T. Malignancy in association with polymyalgia rheumatica and giant cell arteritis. *Scand J Rheumatol* 1974; 3: 129-35.
- [250] Myklebust G, Wilsgaard T, Koster Jacobsen B, Gran JT. No increased frequency of malignant neoplasms in polymyalgia rheumatica and temporal arteritis. A prospective longitudinal study of 398 cases and matched population controls. *J Rheumatol* 2002; 29: 2143-7.
- [251] Andersson R, Malmwall BE, Bengtsson BÅ. Long-term survival in giant cell arteritis including temporal arteritis and polymyalgia rheumatica. *Acta Med Scand* 1986; 220: 361-4.
- [252] Shimamoto Y, Matsunaga C, Suga K, Fukushima N, Nomura K, Yamaguchi M. A human T-cell lymphotropic virus type I carrier with temporal arteritis terminating in acute myelogenous leukemia. *Scand J Rheumatol* 1994; 23: 151-3.
- [253] Caldwell DS, McCallum RM. Rheumatological manifestations of cancer. *Med Clin North Amer* 1986; 70: 385-417.
- [254] Lie JT. Simultaneous clinical manifestations of malignancy and giant cell arteritis in a young woman. *J Rheumatol* 1995; 22: 367-9.
- [255] Nordborg E, Bengtsson BÅ. Death rates and causes of deaths in 284 consecutive patients with giant cell arteritis confirmed by biopsy. *Br Med J* 1989; 299: 549-550.
- [256] Bisgård C, Sloth H, Keliding N, Juel K. Excess mortality in giant cell arteritis. *J Intern Med* 1991; 230: 119-23.
- [257] Le Page, Duhaut P, Seydoux D, Bosshard S, Ecochard R, Abbas F et al. Incidence of cardiovascular events in giant cell arteritis: preliminary results of a prospective double cohort study (GRACG). *Rev Med Interne* 2006; 27: 98-105.
- [258] Uddhammar A, Eriksson AL, Nyström L, Stenling R, Rantapaa-Dahlquist S. Increased mortality due to cardiovascular disease in patients with giant cell arteritis in Northern Sweden. *J Rheumatol* 2002; 29: 737-42.
- [259] Gonzalez-Gay MA, Rubiera G, Pineiro A, Garcia-Porrúa C, Pego-Reigosa R, Gonzalez-Juanatey C, Sanchez-Andrade A, Llorca J. Ischemic heart disease in patients from Northwest Spain with biopsy proven giant cell arteritis. A population based study. *J Rheumatol* 2005; 32: 502-6.
- [260] Ray JG, Mamdani MM, Geerts WH. Giant cell arteritis and cardiovascular disease in older adults. *Heart* 2005; 91: 324-8.
- [261] Schick RM, Baggenstoss AH, Paulley HF. Effects of cortisone and ACTH on periarteritis nodosa and cranial arteritis. *Proceed Staff Meeting Mayo Clin* 1950; 25: 492-4.
- [262] Kyle V, Hazleman BL. Treatment of polymyalgia rheumatica and giant cell arteritis. I. Steroids regimens in the first two months. *Ann Rheum Dis* 1989; 48: 658-61.

- [263] Myklebust G, Gran JT. Prednisolone maintenance dose in relation to starting dose in the treatment of polymyalgia rheumatica and temporal arteritis. *Scand J Rheumatol* 2001; 30: 260-7.
- [264] Delecoeuillerie G, Joly P, de Lara Cohen A, Paolaggi JB. Polymyalgia rheumatica and temporal arteritis: a retrospective analysis of prognostic features and different corticosteroid regimens (11 year survey of 210 patients). *Ann Rheum Dis* 1988; 47: 733-9.
- [265] Nesher G, Rubinow A, Sonnenblick M. Efficacy and adverse effects of different corticosteroid dose regimens in temporal arteritis: a retrospective study. *Clin Exp Rheumatol* 1997; 15: 303-306.
- [266] Nesher G, Sonnenblick M, Friedlander Y. Analysis of steroid related complications and mortality in temporal arteritis: a 15 – year study of 43 patients. *J Rheumatol* 1994; 21: 1283-6.
- [267] Kyle V, Hazleman BL. Treatment of polymyalgia rheumatica and giant cell arteritis. II. Relation between steroid dose and steroid side effects. *Ann Rheum Dis* 1989;48: 662-6.
- [268] Hunder GG, Sheps SG, Allen GL, Joyce JW. Daily and alternate-day corticosteroid regimens in treatment of GCA: comparison in a prospective study. *Ann Intern med* 1975; 82: 613-8.
- [269] Carroll SC, Gaskin BJ, Danesh-Meyer H. Giant cell arteritis. *Clin Exp Ophthalmol* 2006; 34: 159-73.
- [270] Andersen T. Arteritis temporalis (Horton): a symptom of a generalized vascular disease. *Acta Med Scand* 1947; 128: 151-78.
- [271] Wilke WS, Hoffman GS. Treatment of corticosteroid-resistant giant cell arteritis. *Rheum Dis Clin North Amer* 1995; 21: 59-71.
- [272] Hunder GG. Giant cell (temporal) arteritis. *Rheum Dis Clin North Amer* 1990; 16: 399-409.
- [273] Gordon LK, Levin LA. Visual loss in giant cell arteritis. *JAMA* 1998; 280: 385-6.
- [274] Meadows SP. Temporal or giant cell arteritis – ophthalmic aspects. In: Lawton-Smith JL, ed. *Neuro-ophthalmology* St.Louis; Mosby. 1968:148-57.
- [275] Slavin ML, Margolis AJ. Progressive anterior ischemic optic neuropathy due to giant cell arteritis despite high-dose intravenous corticosteroids. *Arch Ophthalmol* 1988; 106: 1167.
- [276] Myles AB, Perera T, Ridley MG. Prevention of blindness in giant cell arteritis by corticosteroid treatment. *Br J Rheumatol* 1992; 31: 103-5.
- [277] Hayreh SS, Zimmerman B. Management of giant cell arteritis. *Ophthalmologica* 2003; 217: 239-59.
- [278] Hayreh SS, Zimmerman B, Kardon RH. Visual improvement with corticosteroid therapy in giant cell arteritis. Report of a large study and review of the literature. *Acta Ophthalmol Scand* 2002; 80: 355-67.
- [279] Chevalet P, Barrier JH, Pottier P, Magadur-Joly G, Pottier MA, Hamidou M. A randomized, multicenter, controlled trial using intravenous pulses of methylprednisolone in the initial treatment of simple forms of giant cell arteritis: a one year followup study of 164 patients. *J Rheumatol* 2000; 27: 1484-91.
- [280] Chan CCK, O'Day J. Oral and intravenous steroids in giant cell arteritis. *Clin Exp Ophthalmol* 2003; 31: 179-82.

- [281] Rosenfeld SI, Kosmorsky GS, Klingele TG, Burde RM, Cohn EM. Treatment of temporal arteritis with ocular involvement. *Am J Med* 1986; 80: 143-5.
- [282] Model DG. Reversal of blindness in temporal arteritis with methylprednisolone. *Lancet* 1978; feb11: 340.
- [283] Diamond JP. Treatable blindness in temporal arteritis. *Br J Ophthalmol* 1991; 75: 432.
- [284] Matzkin DC, Slamovits TL, Sachs R, Burde RM. Visual recovery in two patients after intravenous methylprednisolone treatment of central retinal occlusion secondary to giant-cell arteritis. *Ophthalmology* 1992; 99: 68-71.
- [285] Liu GT, Glaser JS, Schatz NJ, Smith JL. Visual morbidity in giant cell arteritis. Clinical characteristics and prognosis for vision. *Ophthalmology* 1994; 101: 1779-85.
- [286] Salvarani C, Cantini F, Hunder GG. Polymyalgia rheumatica and giant-cell arteritis. *Lancet* 2008; 372: 234-45.
- [287] Cullen JP, Coliro JA. Ophthalmologic complications in giant cell arteritis. *Surv Ophthalmol* 1976; 20: 247-60.
- [288] Hoffman GS, Cid MC, Heiklmann DB et al. A multicenter randomized double blind placebo-controlled trial of adjuvant methotrexate treatment for giant cell arteritis. *Arthritis Rheum* 2002; 46: 1309-18.
- [289] Jover JA, Hernandez-Garcia C, Morado IC, Vargas E, Banares A, Fernandez-Gutierrez B. Combined treatment of giant-cell arteritis with methotrexate and prednisone. *Ann Intern Med* 2001; 134: 106-114.
- [290] Spiera RF, Mitnik HJ, Kupersmith M, Richmond M, Spiera H, Peterson MG. A prospective double-blind, randomized placebo controlled trial of methotrexate in the treatment of giant cell arteritis. *Clin Exp Rheum* 2001; 19: 495-501.
- [291] Mahr AD, Jover JA, Spiera RF, Hernandez-Garcia C, Fernandez-Gutierrez B, La Valley MP, Merkel PA. Adjunctive methotrexate for treatment of giant cell arteritis: an individual patient data meta-analysis. *Arthritis Rheum* 2007; 56: 2789-97.
- [292] Camellino D, Morbelli S, Sambuceti G, Cimmino MA. Methotrexate treatment of polymyalgia rheumatica/giant cell arteritis-associated large vessel vasculitis. *Clin Exp Rheum* 2010; 28: 288-9.
- [293] De Silva M, Hazleman BL. Azathioprine in GCA/PMR: a double-blind study. *Ann Rheum Dis* 1986; 45: 136-8.
- [294] Schauffelberger C, Andersson R, Nordborg E. No additive effect of Cyclosporin A compared with glucocorticoid treatment alone in giant cell arteritis: Results of an open, controlled randomized study. *Br J Rheumatol* 1998; 37: 464-5.
- [295] Wilke WS, Hoffman GS. Treatment of corticosteroid-resistant giant cell arteritis. *Rheum Dis Clin North Amer* 1995; 21: 59-71.
- [296] Narvaez J, Berad B, Nolla JM, Valverde J. Statin therapy does not seem to benefit giant cell arteritis. *Semin Arthritis Rheum* 2007; 36: 322-7. Commented on in *Semin Arthritis Rheum* 2008; 38: 63-4.
- [297] Field M, Cook A, Gallagher G. Immuno-localization of tumor necrosis factor and its receptors in temporal arteritis. *Rheum Int* 1997; 17: 113-8.
- [298] Ahmed MM, Mubashir E, Hayat S, Fowler M, Berney SM. Treatment of refractory temporal arteritis with adalimumab. *Clin Rheumatol* 2007; 26: 1353-5.
- [299] Martinez-Taboada VM, Rodriguez-Valverde V, Carreno L, Lopez-Longo J, Figueroa M, Belzunegui J, Mola EM, Bonilla G. A double-blind placebo controlled trial of

- etanercept in patients with giant cell arteritis and corticosteroid side effects. *Ann Rheum Dis* 2007; 67: 625-30.
- [300] Benucci M, Manfredi M, Puce F, Zuccarini S. Improvement in visual acuity in a patient with ischemic optic neuropathy (Horton arteritis) undergoing therapy with infliximab: a case report. *Recenti Prog Med* 2007; 98: 624-6.
- [301] Airo P, Antonioli CM, Vianelli M, Toniati P. Anti-tumor necrosis factor treatment with infliximab in a case of giant cell arteritis resistant to steroid and immunosuppressive drugs. *Rheumatology* 2002; 41: 347-9.
- [302] Andonopoulos AP, Meimaris N, Daoussis D, Bounas A, Giannopoulos G. Experience with infliximab (anti-TNF α monoclonal antibody) as monotherapy for giant cell arteritis. *Ann Rheum Dis* 2003; 62: 1116.
- [303] Uthman I, Kanj N, Atweh S. Infliximab as monotherapy in giant cell arteritis. *Clin Rheumatol* 2005; 25: 109-10.
- [304] Cantini F, Niccoli L, Salvarani C, Padula A, Olivieri I. Treatment of longstanding active giant cell arteritis with infliximab: report of four cases. *Arthritis Rheum* 2001; 44: 2933-5.
- [305] Tan AL, Holdsworth J, Pease C, Emery P, McGonagle D. Successful treatment of resistant giant cell arteritis with etanercept. *Ann Rheum Dis* 2003; 62: 373-4.
- [306] Hoffman GS, Cid MC, Rendt-Zagar KE, Merkel PA, Weyand CM, Stone JH et al. Infliximab for maintenance of glucocorticosteroid-induced remission of giant cell arteritis: a randomized trial. *Ann Intern Med* 2007; 146: 621-30.
- [307] Hagihara K, Kaware I, Tanaka T, Kishimoto T. Tocilizumab ameliorates clinical symptoms in polymyalgia rheumatica. *J Rheumatol* 2010; 37: 1075-6.
- [308] Seitz M, Reichenbach S, Borel HM, Adler S, Wermelinger F, Villiger PM. Rapid induction of remission in large vessel vasculitis by IL-6 blockade. *Swiss Med Wkly* 2011; 141: E1-E4.
- [309] Shinjo SK, Pereira RMR, Tizziani VAP. Mycophenolate mofetil reduces disease activity and steroid dosage in Takayasu arteritis. *Clin Rheumatol* 2007; 26: 1871-5.
- [310] Lozano E, Segarra M, Garcia-Martinez A, Hernandez-Rodriguez J, Cid MC. Imatinib mesylate inhibits in vitro and ex vivo biological responses related to vascular occlusion in giant cell arteritis. *Ann Rheum Dis* 2008; 67: 1581-8.
- [311] Lozano E, Segarra M, Corbera-Bellalta M, Garcia-Martinez A, Espigol-Frigole G, Pla-Campo A, Hernandez-Rodriguez J, Cid MC. Increased expression of the endothelin system in arterial lesions from patients with giant cell arteritis: association between elevated plasma endothelin levels and the development of ischaemic events. *Ann Rheum Dis* 2010; 69: 434-42.
- [312] Bhatia A, Ell PJ, Edwards JCW. Anti-CD20 monoclonal antibody (rituximab) as an adjunct in the treatment of giant cell arteritis. *Ann Rheum Dis* 2005; 64: 1099-1100.
- [313] Spiera RF, Spiera H. Therapy for giant cell arteritis: can we do better? *Arthritis Rheum* 2006; 54: 3071-4.
- [314] Gonzalez-Juanatey C, Lopez-Diaz MJ, Martin J, Llorca J, Gonzalez-Gay MA. Atherosclerosis in patients with biopsy-proven giant cell arteritis. *Arthritis Rheum* 2007; 57: 1481-6.
- [315] Abud-Medozza C, de la Fuente H, Cuevas-Orta E, Baranda L, Cruz-Rizo J, Gonzalez-Amaro R. Therapy with statins in patients with refractory rheumatic diseases: a preliminary study. *Lupus* 2003; 12: 607-11.

- [316] Nesher G, Brkun Y, Mates M, Baras M, Rubinow A, Sonnenblick M. Low-dose aspirin and prevention of cranial ischemic complications in giant cell arteritis. *Arthritis Rheum* 2004; 50: 1332-7.
- [317] Lee MS, Smith SD, Galor A, Hoffman GS. Antiplatelet and anticoagulant therapy in patients with giant cell arteritis. *Arthritis Rheum* 2006; 54: 3306-9.
- [318] Berger CT, Wolbers M, Meyer P, Daikeler T, Hess C. High incidence of severe ischemic complications in patients with giant cell arteritis irrespective of platelet count and size, and platelet inhibition. *Rheumatology* 2009; 48: 258-61.
- [319] Haugeberg G, Myklebust G, Dovland H, Mikkelsen B, Gran JT. No permanent reduction in bone mineral density during treatment of polymyalgia rheumatica and temporal arteritis using low dose corticosteroids. *Scand J Rheumatol* 2000; 29: 163-9.
- [320] Andersson R, Rundgren Å, Rosengren K, Bengtsson BÅ, malmwall BE, mellström D. Osteoporosis after long-term corticosteroid treatment of giant cell arteritis. *J Int med* 1990; 227: 391-5.
- [321] Prøven A, Gabriel SE, Orces C, O'Fallon WM, Hunder GG. Glucocorticoid therapy in giant cell arteritis: duration and adverse outcomes. *Arthritis Care Res* 2003; 49: 703-8.
- [322] Andersson R, Malmwall BE, Bengtsson BÅ. Long-term corticosteroid treatment in giant cell arteritis. *Acta Med Scand* 1986; 220: 465-9.
- [323] auchald P, Rygvold O, Øystese B. Temporal arteritis and polymyalgia rheumatica. Clinical and biopsy findings. *Ann Intern Med* 1972; 77: 845-52.
- [324] Kyle V, Cawston TE, Hazleman BL. Erythrocyte sedimentation rate and C reactive protein in the assessment of polymyalgia rheumatica/giant cell arteritis on presentation and during follow-up. *Ann Rheum Dis* 1989; 48: 667-71.
- [325] von Knorring J. Treatment and prognosis of polymyalgia rheumatica and temporal arteritis: a ten-year survey of 53 patients. *Acta Med Scand* 1979; 205: 429-35.
- [326] Graham E, Holland A, Avery A, Russell RWR. Prognosis in giant-cell arteritis. *Br Med J* 1981; 282: 269-71.
- [327] Hachulla E, Boivin V, Pasturel-Michon U, Fauchais AL, Bouroz-Joly J, Perez-Cousin M, Hatron PY, Devulder B. Prognostic factors and long-term evolution in a cohort of 133 patients with giant cell arteritis. *Clin Exp Rheumatol* 2001; 19: 171-6.
- [328] Liozon E, Gondran G, Ly K, Loustad V, Vidal E. Duration of treatment after eye involvement in giant cell arteritis. *J Rheumatol* 2008; 35: 1220.
- [329] Lundberg I, Hedfors E. Restricted dose and duration of corticosteroid treatment in patients with polymyalgia rheumatica and temporal arteritis. *J Rheumatol* 1990; 17: 1340-5.
- [330] Andersson R, Malmwall BE, Bengtsson BÅ. Long-term corticosteroid treatment in giant cell arteritis. *Acta Med Scand* 1986; 220: 465-9.
- [331] Weyand CM, Younge BR, Goronzy JJ. INF- γ and IL-17: the two faces of T-cell pathology in giant cell arteritis. *Curr Opin Rheum* 2011; 23: 43-9.



Advances in the Diagnosis and Treatment of Vasculitis

Edited by Dr. Luis M Amezcua-Guerra

ISBN 978-953-307-786-4

Hard cover, 366 pages

Publisher InTech

Published online 09, November, 2011

Published in print edition November, 2011

This book represents the culmination of the efforts of a group of outstanding experts in vasculitis from all over the world, who have endeavored to draw themselves into this volume by keeping both the text and the accompanying figures and tables lucid and memorable. The book provides practical information about the screening approach to vasculitis by laboratory analysis, histopathology and advanced image techniques, current standard treatment along with new and more specific interventions including biologic agents, reparative surgery and experimental therapies, as well as miscellaneous issues such as the extra temporal manifestations of "temporal arteritis" or the diffuse alveolar hemorrhage syndrome. The editor and each of the authors invite you to share this journey by one of the most exciting fields of the medicine, the world of Vasculitis.

How to reference

In order to correctly reference this scholarly work, feel free to copy and paste the following:

Jan Tore Gran (2011). Diagnosis and Treatment of Giant Cell Arteritis (Temporal Arteritis) – Past, Current and Future Aspects, *Advances in the Diagnosis and Treatment of Vasculitis*, Dr. Luis M Amezcua-Guerra (Ed.), ISBN: 978-953-307-786-4, InTech, Available from: <http://www.intechopen.com/books/advances-in-the-diagnosis-and-treatment-of-vasculitis/diagnosis-and-treatment-of-giant-cell-arteritis-temporal-arteritis-past-current-and-future-aspects>

INTECH
open science | open minds

InTech Europe

University Campus STeP Ri
Slavka Krautzeka 83/A
51000 Rijeka, Croatia
Phone: +385 (51) 770 447
Fax: +385 (51) 686 166
www.intechopen.com

InTech China

Unit 405, Office Block, Hotel Equatorial Shanghai
No.65, Yan An Road (West), Shanghai, 200040, China
中国上海市延安西路65号上海国际贵都大饭店办公楼405单元
Phone: +86-21-62489820
Fax: +86-21-62489821

© 2011 The Author(s). Licensee IntechOpen. This is an open access article distributed under the terms of the [Creative Commons Attribution 3.0 License](https://creativecommons.org/licenses/by/3.0/), which permits unrestricted use, distribution, and reproduction in any medium, provided the original work is properly cited.

IntechOpen

IntechOpen