

We are IntechOpen, the world's leading publisher of Open Access books Built by scientists, for scientists

6,900

Open access books available

185,000

International authors and editors

200M

Downloads

Our authors are among the

154

Countries delivered to

TOP 1%

most cited scientists

12.2%

Contributors from top 500 universities



WEB OF SCIENCE™

Selection of our books indexed in the Book Citation Index
in Web of Science™ Core Collection (BKCI)

Interested in publishing with us?
Contact book.department@intechopen.com

Numbers displayed above are based on latest data collected.
For more information visit www.intechopen.com



Churg Strauss Syndrome: Clinical and Pathogenetic Approach to Therapy

Giovanni Rolla, Monica Boita, Enrico Heffler and Giuseppe Guida
*Allergy and Clinical Immunology University of Torino and AO Ordine Mauriziano
Italy*

1. Introduction

The Churg-Strauss syndrome (CSS), also called allergic granulomatosis and angiitis, is a multisystem disorder characterized by allergic rhinitis, asthma, and prominent peripheral blood eosinophilia. CSS is classified as a vasculitis of the small and medium sized arteries, which commonly involve the lung, the skin and the peripheral nerves and it is associated to ANCA in 40-60 percent (Sinico & Bottero 2009). Among the three anti-neutrophil cytoplasmic antibodies (ANCA)-associated vasculitides (CSS, Wegener's granulomatosis, and microscopic polyangiitis), CSS is least common. In the general population, the frequency of the disorder has been estimated at 2.4–6.8 per 1 000 000 patient-years, while the incidence of CSS in asthma drug users has been estimated to be 14-52 per million person-years (Watts RA et al. 2000). The mean age at diagnosis of CSS is 40 years, with no gender predominance.

Diagnosis of Churg-Strauss syndrome can be difficult, because the syndrome may arise at first as a common association between asthma and allergic rhinitis. Because asthma itself might be associated with sinusitis, occasional pulmonary infiltrates (eg, mucus plugging, atelectasis, or intermittent infection), and corticosteroid dependency, a clear diagnosis of Churg-Strauss syndrome might not be made until extra respiratory system become involved, such as the abdominal viscera, heart, or nervous system.

2. Diagnostic criteria

The ACR has established six criteria for the classification of CSS in a patient with documented vasculitis (Masi AT et al.1990). The presence of four or more of these criteria had a sensitivity of 85 percent and a specificity of 99.7 percent for CSS:

- Asthma (a history of wheezing or the finding of diffuse high pitched wheezes on expiration)
- Greater than 10 percent eosinophils on the differential leukocyte count
- Mononeuropathy (particularly multiplex) or polyneuropathy
- Migratory or transient pulmonary opacities detected radiographically
- Paranasal sinus abnormality
- Biopsy containing a blood vessel showing the accumulation of eosinophils in extra-vascular areas.

Chapel Hill Consensus Conference (Jennette JC et al 1994) analyzed pathological and clinical findings to define CSS as an eosinophil-rich and granulomatous inflammation involving the

respiratory tract and necrotising vasculitis affecting small-to-medium-size vessels and associated with asthma and eosinophilia.

A clinical approach to define Churg-Strauss syndrome was that of Lanham and colleagues (Lanham JG 1984) at the Hammersmith Hospital, London, who have defined the disorder as a syndrome including:

(1) a history of asthma; (2) blood eosinophilia (>1500 cells/mcl); and (3) systemic vasculitis involving two or more organs.

Unfortunately, the involvement of two or more than two organs is difficult to assess without doing a biopsy – an invasive procedure in patients who may be very ill and need initiation of aggressive systemic corticosteroid treatment. An important clinical clue to the diagnosis of CSS in patients with chronic rhinosinusitis associated with the eosinophilic phenotype of asthma is to pay particular attention to every extra-respiratory manifestations, such as paresthesias, skin eruption or systemic symptoms.

The detection of ANCA, particularly P-ANCA (perinuclear pattern at indirect immunofluorescence) with anti-myeloperoxidase (anti MPO) specificity (ELISA assay) supports the diagnosis, but ANCA are present in only 35-40 % of patients.

3. The phases of CSS

In many patients, the disease follows a characteristic 3-stage course (Lanham JG 1984). Asthma and/or allergic rhinitis with or without nasal polyposis precedes full development of the syndrome, usually by many years. Significant blood eosinophilia, an unusual finding in uncomplicated asthma may also be present at this early stage of disease.

In the next stage, tissue infiltration by eosinophils, with or without granuloma formation, occurs in various organs, particularly in the upper and lower respiratory tract, the gastrointestinal tract, and the myocardium. Clinically, this stage is characterized by symptoms and findings related to tissue eosinophilia. Vasculitis is still absent at this stage. The third phase of disease is defined by the onset of systemic vasculitis, which usually develops several years after the onset of asthma. Necrotizing small-vessel vasculitis may be clinically apparent in peripheral nerves (mono- or polyneuropathy, mononeuritis multiplex), skin (purpura), and kidneys (necrotizing and crescentic glomerulonephritis) (Gross WL. 2002).

Although these phases are conceptually helpful, they might not be clinically identifiable in all patients, and they often do not occur in sequence. The eosinophilic phase of the disease is the most challenging phase from the clinical diagnostic point of view. Tissue infiltration by eosinophils is observed in a variety of other conditions, including drug hypersensitivity, parasitic infections, malignancies, and allergic conditions. Chronic eosinophilic pneumonia (PEC) which frequently occurs in association with asthma and peripheral blood eosinophilia, may mimic CSS, with the only differences that necrotizing lesions are less apparent. Gastrointestinal eosinophilic disease may cause important symptoms even in the absence of vasculitis, while the development of vasculitis can be revealed by catastrophic abdominal complications, such as bowel perforation. Thus, there is no general consensus for classifying patients with this non-vasculitic second stage of CSS.

Another intriguing aspect is the differential diagnosis with the hypereosinophilic syndrome (HES). HES is defined by severe blood eosinophilia ($>1.5 \times 10^9$ cells/litre for > 6 months) and tissue infiltration by eosinophils resulting in organ dysfunction after exclusion of other causes of hypereosinophilia. Diffuse necrosis and vasculitis are generally absent, and a

history of asthma is rare in HES. Nevertheless, the clinical differentiation of HES from CSS is not always easy, particularly in the absence of apparent small-vessel vasculitis. Besides eosinophilia, HES and CSS share many common clinical features, such as neuropathy, dyspnea, fatigue, fever, and skin rashes. The role of eosinophilic granulocytes as the primary effector cells and the clinical similarities, may suggest a common etiology and pathogenesis for CSS and HES (Roufosse FE et al 2007), and raises the question whether CSS is simply the third disease stage of HES in patients with asthma.

Immunophenotype, T-cell clonal and cytogenetic studies, and molecular analysis to detect Fip1-like 1 (FIP1L1)-platelet-derived growth factor receptor- α (PDGFRA) gene fusion, the molecular markers in the most common form of HES, should therefore probably be performed for every patient suspected of having CSS, at least those who are ANCA-negative and/or without histologically proven vasculitis.

4. Etiology

4.1 The controversial association of drug treatment with CSS

Several exogenous triggering factors for the onset of disease have been suspected, including vaccinations, desensitizations, and drugs, such as macrolides, carbamazepine, quinine, and anti-asthma medications, like leukotriene-receptor antagonists (LTRAs) (Bibby et al 2010) and omalizumab, a monoclonal anti IgE antibody recently approved for severe allergic asthma (Wechsler ME et al 2009). It is more likely that anti-asthma medications unmask the underlying disease rather than cause the disease.

Systemic glucocorticoid withdrawal is facilitated by LTRAs, as well by increased dose of inhaled corticosteroids or omalizumab, leading CSS disease manifestations in those patients with undiagnosed but escalating CSS.

However, it is difficult to completely exclude the possibility that LTRAs play a causal role in the development of CSS in some patients.

An unusual CSS-like vasculitis has been associated with the use of free base cocaine (Orriols R et al. 1996). The diagnosis of CSS in patients who use cocaine is a complicated issue because both acute and chronic eosinophilic pneumonia are manifestations of cocaine toxicity and antineutrophil cytoplasmic antibodies are detected in the majority of patients with cocaine-induced midline destructive lesions of the nose, even if the ANCAs associated with cocaine use are generally cANCA (cytoplasmic pattern at indirect immunofluorescence), with anti-proteinase 3 (anti Pr3) specificity (ELISA assay).

4.2 Genetics

Whereas asthma often clusters in families, familial cases of CSS are exceptional, diminishing the role the genes may play in favor of environmental factors. Some studies, pooling CSS patients with WG and MPA, found a not significant association with a lower frequency of *HLA-DRB1*03* (Boki KA, 1997). More recent genetic studies suggested some predisposing hereditary factors, like the *HLA-DRB1*04* and *HLA-DRB1*07* alleles and the *HLA-DRB4* gene, which would be more frequent in Churg-Strauss syndrome patients than in healthy controls (Vaglio A. et al 2007). *HLA-DRB4* positive patients were associated with a higher number of vasculitis symptoms, in particular in the ANCA positive group. The interleukin IL10.2 haplotype, which is associated with enhanced IL-10 expression, and possibly the CD226 Gly307Ser polymorphism have been suggested as important genes in CSS (Wieczorek S et al, 2010). An attempt to undiscover the complex genome transcription profile

of CSS has been performed by using focused microarray analysis of PBMCs in which a limited number of mRNA has been tested. Up regulation of a different number of PREP (Prolyl endopeptidase) genes suggest an enhanced immune response that might cause vascular damage (Tougan T et al, 2008).

5. Immunopathogenesis

The actual pathogenetic model of CSS is mainly incomplete.

The prodromic phase, characterized by asthma and allergic manifestations is thought to be related to a prominent Th2-lymphocyte activity. The second phase is characterized by eosinophilic infiltration into tissues. Eosinophils, when activated by Th2 related cytokines (interleukin (IL)-4, IL-5, IL-10 and IL-13), release major basic protein, eosinophilic cationic protein, eosinophil derived neurotoxin and eosinophil peroxidase, which may cause direct tissue and endothelial damage, and trigger the oxidative stress cascade.

The systemic phase, with the development of necrotizing vasculitis is associated with ANCA production, with the contribution of eosinophils. It is thought that IgE containing immune complexes (Manger BJ et al, 1985), surrounded by eosinophils and / or ANCA production would amplify and/or facilitate the development of vasculitic lesions in some patients.

5.1 The role of T cells

5.1.1 T helper cells

The pathogenic role of T cells in Churg Strauss Syndrome is suggested by different observations. First, T cells are commonly present in biopsies of active lesions, both vasculitic and granulomatous. A study of the clinicopathological features of neuropathy associated with the syndrome showed that CD8+ and CD4+ T cell outnumber eosinophils in neuronal biopsy specimen, suggesting a T-cell mediated damage of epineural vessels. (Hattori N et al, 1999).

Second, CSS shows a strong Th2-type immune response; T cell lines from CSS patients, generated *in vitro* by polyclonal stimulation, are polarized towards a Th2 phenotype (IL-4 and IL-13), which may explain the eosinophilia, the hallmark of the disease. The same cells have also been shown to release significant amounts of IFN- γ , which may be related to the granuloma formation (Kiene M et al, 2001). Current understanding of CSS implies that Th2-cells drive the activation of eosinophils, which secrete a variety of harmful mediators such as major basic protein, ECP, and eosinophil-derived neurotoxin. Interleukin-5 produced by Th2-cells is one of the key inducers of eosinophilia in CSS. Another molecule, which is supposed to play an important role, is CCL17/thymus and activation-related chemokine (TARC), a CC chemokine secreted from peripheral blood mononuclear cells (PBMCs) and various subsets of monocyte-derived dendritic cells (DCs). It is the ligand for CCR4 and CCR8 chemokine receptors on human PBMCs and T cells, respectively. Given the expression profile of its receptors and the ability of CCL17/TARC to selectively induce migration of CD4+CD45RO+ T cells producing Th2 cytokines, it may be crucial for the specific recruitment and trafficking of Th2 cells, which are known to be activated in CSS. CCL17/TARC in the affected tissue of CSS patients is readily identified by immunohistochemical analysis, thus it may contribute to CSS pathogenesis by recruitment of Th2 cells into affected tissue (Dallos T et al, 2010).

T cells contribute to the pathogenesis of CSS by secretion of cytokines and chemokines, but they need to be functionally activated to accomplish this. Increases in serum concentration of eosinophilic cationic protein (suggesting eosinophil activation) and soluble thrombomodulin (indicating endothelial-cell damage) have been shown to correlate with soluble IL-2 receptor, suggesting T-cell activation (Schmitt WH et al, 1998).

5.1.2 T regulatory cells and Th17 populations

During the past decade, CD4+CD25+ regulatory T-cells (Tregs) have emerged as key players in the development of immunological tolerance. It has been proposed that onset of autoimmune diseases is determined by a dysfunction/deficiency of naturally occurring Treg cells and by an imbalance between self-reactive T-cells and natural Tregs. CSS patients at disease onset or relapse have fewer T regulatory cell subsets (CD4+CD25+ T cells) producing IL-10 (Tr1) than the patients in remission or patients with asthma. Moreover, the number of organs involved has been shown to correlate negatively with the number of T reg cells. This lower percentage of T reg cells during active CSS would, at least in part, explain the breakdown of immunological tolerance that leads to CSS onset. According to this hypothesis, maintenance of the numbers of regulatory T cells in patients with chronic eosinophilic pneumonia (CEP) with asthma might inhibit CSS development (Tsurikisawa N et al, 2008).

T helper 17 cells (Th17) are a newly discovered subset of T helper cells producing interleukin 17 (IL-17) which are thought to play a role in inflammation and tissue injury (Steinman L, 2007). The percentage of Th17 in peripheral blood has been reported to be significantly higher in patients with active CSS than in healthy subjects or in patients with inactive disease (Saito H et al, 2009). An imbalance in the Th17/Treg ratio is associated to the immune suppressive degree of treated CSS patients (Jakiela B et al, 2011). These findings suggest Th17 and regulatory T cells may play important roles in the pathogenesis of CSS.

5.1.3 CD4+ and CD8+ T cell subsets

T cells normally recognize antigens as short peptides using their T cell receptor (TCR) specifically binding to MHC molecules on the surface of antigen-presenting cells. TCR recognition of the antigen results in stimulation and clonal proliferation of the activated T cell. Oligoclonal expanded T cells reflect conventional antigen (Ag) stimulation involving one every million T cells. In immune-mediated diseases where the antigen is unknown, studies of the TCR repertoire of expanded T cells can give clues to the nature of the antigen. Superantigen (SAg) are peptides that differ in several ways from conventional peptide antigens, in that they characteristically activate a much higher proportion of T cells than conventional antigens. Typically SAg will stimulate up to 20% of circulating T cells. SAg stimulation of T cells bearing specific V β (Wei S et al, 1997) T-cell receptors (TCR) results in the polyclonal expansion of selected V β families in CD4+ and CD8+ cells, followed by T cell restricted deletion (Fraser J et al, 2000). Whether lymphocytes activation in CSS is induced by antigen (Ag) or superantigen (SAg) is not presently known. Oligoclonal expanded T cell have been actually found in CSS patients by immunoscope technique, but it is not known whether these expanded T cells are CD4+ or CD8+ (Muschen M et al, 1999). Immunoscope-based analysis of TCR repertoires in 7 CSS patients revealed clonal expansion (one or more dominant picks) of V β 21(7/7), V β 11 (3/7) and V β 12 (2/7) families.

One or more V β families were found numerically expanded by flow cytometry among CD8 T cells population of all CSS patients who were investigated, both in clinical remission and

during treatment for active disease. These expanded T cells were mostly represented by CD8⁺ lymphocytes with effector memory phenotype. Each CD8⁺/V β ⁺ expanded population has been shown to be the result of the proliferation of a clonal T cell bearing a defined TCR, as detected by analysis of TCR-V-J γ rearrangement (Guida G et al, 2008).

These CD8⁺/V β ⁺ expanded populations have an effector memory (TEM) phenotype, as evidenced by flow cytometric analysis of CD45RA expression combined to CD62L, CCR7 or CD28 (Morice WG et al, 2004; Sallusto F et al, 1999). It has been suggested that circulating CD8⁺/V β ⁺ TEM are antigen driven cells which may infiltrate target organs and participate to the inflammatory cascade of both vasculitic and granulomatous lesions (Guida G et al, 2008).

A few preliminary reports (Boita M et al, 2010), showed an increased expression of CCR5 and CXCR3 in CD8⁺ lymphocytes compared to healthy controls, both in V β expanded families and in total CD8⁺ cells, suggesting Th1 polarization. On the other hand, increased expression of CCR4 and CRTH2 was present in CD4⁺ cells, suggesting Th2 polarization. An oligoclonal pattern was present in most V β families of CD8⁺ lymphocytes, whereas the number of oligoclonal families of the CD4 subset was lower. TCR studies on cloned CD8 lymphocytes showed the presence of a unique TCR in each of the expanded CD8⁺/V β ⁺ populations.

Based on these preliminary data, it is hypotizable that monoclonal/oligoclonal expanded populations of effector CD8⁺ lymphocytes with a Th1/proinflammatory profile are involved in vasculitic damage, whereas CD4⁺ cells with a Th2 profile mediate eosinophil-rich inflammation and asthma.

5.2 The role of ANCA and B cells

Antineutrophil cytoplasmic antibodies (ANCA) are predominantly IgG autoantibodies directed against constituents of primary granules of neutrophils and monocytes' lysosomes. They exist in two forms: c-ANCA that has a Immuno Fluorescent (IF) cytoplasmatic pattern against proteinase-3 (Pr-3) and p- ANCA that consists of a IF perinuclear pattern directed against myeloperoxidase (MPO). In studies with large cohort of patients with small vessel vasculitis, ANCA were detected in about 38-59% of patients with Churg–Strauss syndrome (Guillevine L et al, 1999; Cohen P et al, 1995). ANCA appearance might precede CSS clinical onset in some patients, but the *primum movens* for their synthesis remains unknown. In this context, B cells could play a role as autoreactive cells producing ANCA auto antibodies.

There is no uniform theory explaining how ANCA may cause pauci-immune vasculitides but the common pathogenetic model suggests that binding of ANCA causes activation of neutrophils, with subsequent increased adhesion and migration to endothelium, release of proteolytic granule enzymes and proinflammatory cytokines, generation of respiratory burst, and, eventually, endothelial cell damage. ANCA-mediated neutrophil activation disrupts apoptosis of neutrophils which undergo secondary necrosis with subsequent release of inflammatory mediators, hence amplifying the process (Csernok E, 2003) . ANCA promote the interaction between neutrophils and endothelial cells through β 2 integrins (CD11a/CD18 and CD11b/CD18) and GTP binding protein chemokine receptors. Afterwards, noxious neutrophils' constituents—reactive oxygen species and proteolytic enzymes—are secreted, damaging vessel walls. Proinflammatory cytokines secreted by neutrophils as a result of ANCA binding include IL-1 β , TNF- α , IL-6, IL-8, monocyte chemoattractant protein 1, and leukotriene B4. ANCA-mediated cytokine secretion

will activate and recruit inflammatory cells, amplifying and perpetuating the inflammatory response, with monocytes and T cells participating later in the process (Jennette JC et al, 2006).

5.3 The role of eosinophils

CSS is defined by blood eosinophilia usually >10% and eosinophilic infiltration into affected tissues. According to this, IL-5 and other Th2 cytokines may in fact play an important role in the pathogenesis of CSS.

The production of IL-5 and other cytokines before and after stimulation with T cell-specific stimuli (anti-CD3 and anti-CD28) have been analyzed in peripheral blood mononuclear cells (PBMCs) obtained from patients with CSS, showing significant increased IL-5 level in CSS compared with healthy controls. However, IL-5 production in PBMCs cultured without T cell-specific stimuli (anti-CD3) and costimulatory signals (anti-CD28) was low both in CSS patients and controls suggesting that PBMCs in CSS require T cell activation to secrete large amounts of IL-5 (Kiene M et al, 2001; Hellmick B, 2005).

IL5 is the most potent cytokine which induces terminal differentiation of committed eosinophil precursors. Moreover, IL-5 prolongs the survival of mature eosinophils. In addition, IL-5 activates mature eosinophils and selectively induces degranulation and antibody-dependent cytotoxicity of eosinophils. Of particular interest with regard to the pathogenesis of CSS and vasculitis is the capability of IL-5 to promote the adhesion of eosinophils to vascular endothelium and CC chemokine receptor 3 (CCR3)-dependent migration of eosinophils from the vasculature into the tissues.

Because organ damage in CSS is at least partially mediated by direct invasion and degranulation of eosinophils into the tissues, other mediators than IL-5 might also be important. Recently, a chemokine family specifically mediating trafficking of eosinophils to inflammatory sites has been characterized. Currently, CCL11, CCL24, and CCL26 are grouped together as eotaxins. They all bind to a common receptor CCR3. As to be expected for eosinophil chemotactic proteins, eotaxins are induced by Th-2 associated cytokines such as IL-4 and IL-13. Heavy tissue eosinophilia is found in most biopsies from active CSS patients. Serum eotaxin-3, but not eotaxin-1 and eotaxin-2, levels have been found greatly elevated in active CSS patients compared to healthy controls. The elevated eotaxin-3 serum levels rapidly decreased upon efficient immunosuppression (Polzer K et al, 2008). Thus, eotaxin-3 constitutes a possible target for the pharmacotherapy of CSS.

6. Markers of disease

The CHCC classification introduced the concept of surrogate markers of vasculitis but a list of markers was not provided and ANCA were not included. Conflicting results of studies relating titers of ANCA to disease activity of ANCA associated vasculitides (ASV) have been reported. A recent retrospective study suggested that acute rise in ANCA titer is highly predictive of a relapse of ASV (Lurati-Ruiz F et al, 2005; Baldini C et al, 2009). When the ANCA titer remains positive during immunosuppressive treatment for induction of remission, relapses within 5 years are more likely to occur (Sanders JS et al, 2006).

The presence of ANCA was associated with renal disease, peripheral neuropathy, and biopsy-proven vasculitis. Absence of ANCA was associated with heart involvement and fever. This demonstrates that ANCA-positive Churg-Strauss syndrome differs phenotypically from ANCA negative Churg-Strauss syndrome (Sable-Fourtassou R et al,

2005; Sinico RA et al, 2005). Furthermore, ANCA might possibly indicate more severe disease at diagnosis, as assessed by the proportion of patients with poor scores in FFS and the Birmingham vasculitis activity score (BVAS).

Several research teams are attempting to identify reliable marker(s) of CSS activity. Promising markers of the disease are those referring to activity and survival of eosinophils, like serum eosinophil cationic protein (Guilpain P et al, 2007), IL-5 (Tsukadaira A et al, 1999) or eotaxin-3 (CCL26), an eosinotactic chemokine mainly expressed on vascular endothelial cells and dermal fibroblasts (Polzer K et al, 2008).

Recently, serum levels of TARC have been reported to be significantly elevated in CSS patients with active disease, and to correlate with the clinical course of the disease and with the absolute eosinophil counts, as well as with IgE levels (Dallos T et al, 2010). No confirmatory data are otherwise reported about the role of other eosinophil survival related molecules and interaction with the endothelium.

It has been suggested that the detection of clonal expanded peripheral V β ⁺/CD8⁺ T cell populations (assessed by flow cytometry combined to analysis of TCR- γ gene rearrangement) is stable over time and might be useful in the differential diagnosis of CSS, as suggested by the negative findings in asthmatic controls (Guida G et al, 2008).

Many of these observations require further validation and all the above-mentioned laboratory tests are not yet widely available outside highly specialized centers. Attempts to individualize CSS subgroups remain highly valuable and may further help to elucidate and understand its different underlying physio-pathogenetic mechanisms.

7. Clinical presentation and classification of severity

The most typical clinical presentation of Churg-Strauss syndrome is the appearance of vasculitic manifestations in a patient with known allergic rhinitis, sinus polyposis, and late-onset asthma, usually preexisting for 5-10 years. General symptoms (i.e., fever or weight loss), mononeuritis multiplex, and/or necrotic cutaneous purpura are the most frequent manifestations at disease onset, in combination with elevated blood eosinophilia and inflammatory syndrome.

7.1 Systemic symptoms and laboratory findings

Fever is quite frequent, as well weight loss, which is often great and might herald onset of the vasculitic phase, as do fatigue and malaise. Arthralgias are common, but frank arthritis is rare. Abnormal laboratory findings in patients with Churg-Strauss syndrome include anaemia, leukocytosis, increased peripheral blood eosinophil count, and a raised erythrocyte sedimentation rate. Rarely, eosinophilia is not present, and wide-ranging and rapid changes in eosinophil counts happen. Use of corticosteroids to treat asthma may result in failure to detect eosinophilia in a patient with undiagnosed Churg-Strauss syndrome. Blood chemistry and urinalysis findings might show occult renal disease. Antineutrophil cytoplasmic antibodies are present in more than half of patients with a perinuclear staining pattern. Antineutrophil cytoplasmic antibody-positivity needs to be confirmed by demonstration of anti-myeloperoxidase (MPO) antibodies in serum.

7.2 Skin

Skin lesions are common and variable, occurring 40-81% of CSS patients and being the presenting sign in 14% of the patients (Bosco L et al 2011). In the majority of these patients,

skin lesions allowed for the histopathological diagnosis of CSS. The most common clinical features are papulo-nodules with the histological picture of extravascular Churg-Strauss granuloma followed by purpuric and/or necrotic lesions in the lower limbs corresponding to small-vessel vasculitis with eosinophils. Less common lesions include urticarial lesions and livedo reticularis. Therefore, a high index of suspicion on skin lesions and the proper lesion selection for histological examination may be very important for early diagnosis of CSS. Clinical-pathological correlation is essential, as both clinical and histological features are not pathognomonic.

7.3 Respiratory system

Upper airway

Overall, 80% of CSS patients have active sinonasal symptoms at the time of presentation and worsening of their nasal symptoms may be the main event leading to their diagnosis (Srouji I et al. 2008) . Nearly half CSS patients had undergone nasal surgery. Nasal symptoms that are of particular interest are nasal obstruction , rhinorrhea , anosmia , and excessive sneezing . Other symptoms include nasal crusting, purulent nasal discharge, and epistaxis. Sinonasal symptoms are common at initial presentation of CSS, emphasizing the role of otolaryngologists in its diagnosis. Overall, CSS-related sinonasal morbidity is significant and comparable with that of the general rhinosinusitis population. It predominantly results from symptoms of allergic rhinitis, but a significant proportion of CSS patients also report milder forms of crusting, epistaxis, and of purulent sinusitis, symptoms which are more commonly attributed to patients with Wegener Granulomatosis.

Asthma

Asthma is one of the key features of Churg-Strauss syndrome, usually it is adult-onset asthma, preceded by sinusitis in all the patients and nasal polyposis in most of them. Asthma at its onset is generally severe and very poorly controlled. Atopy is present in more than half of patients. Onset of vasculitic symptoms is often accompanied by asthma exacerbation and lung involvement. After introducing the treatment and achieving stable remission, asthma severity/control and lung function tests improved, but systemic low-dose corticosteroid therapy is often required to maintain asthma control in most of CSS patients (Szczeklik W et al. 2011) .

Lung involvement

The lung is the most commonly involved organ. Pulmonary hemorrhage is much less common than in the other small-vessel vasculitides. At histopathologic analysis, both necrotizing small-vessel vasculitis and an eosinophil-rich inflammatory infiltrate with necrotizing granulomas are seen (Katzenstein AL 2000). The most common lung radiographic manifestations of CSS consist of transient, bilateral, nonsegmental areas of consolidation without predilection for any lung zone (Silva CI et al 2005) . The areas of consolidation can be transient, resembling Löffler syndrome, or predominantly peripheral , resembling chronic eosinophilic pneumonia or organizing pneumonia . The most common abnormality at high-resolution CT, seen in up to 90% of patients, is bilateral areas of ground-glass opacity or consolidation (Worthy SA et al 1998). These usually have a symmetric distribution and often a peripheral predominance; less commonly, they have a peri-bronchial or patchy random distribution . Another relatively common finding is the presence of septal lines, seen in approximately 50% of patients. Interlobular septal

thickening may reflect the presence of edema secondary to cardiac involvement or eosinophilic infiltration of the septa.

7.4 Heart

Cardiovascular involvement is the leading cause of morbidity and death in Churg-Strauss syndrome. Heart manifestations of Churg-Strauss syndrome (CSS) are varied. In the early stages of the disease, it is difficult to distinguish between lesions that are specific to CSS and those of other etiologies. A specific physiopathology that is not mediated by ANCA seems to be involved in the genesis of CSS-related heart lesions. A negative antineutrophil cytoplasmic antibodies (ANCA) test and much higher eosinophil counts distinguish patients with cardiac involvement from those without (Neumann T et al 2009). Detailed cardiac evaluation revealed a unexpectedly high prevalence (more than 50%) of cardiac involvement in CSS patients. Impaired left ventricular function, mild to severe valvular insufficiencies, and pericardial effusions are common findings in these patients. Endomyocarditis may be found by cardiac MRI, cardiac thrombus formation, and endomyocardial biopsy, and is associated with impaired cardiac function. After therapy, most patients may regain or maintain good cardiac function. However, patients with endomyocarditis have a more severe outcome. Cardiac MRI is a sensitive, non-invasive method to detect cardiac lesions in patients whose conventional investigations indicated no cardiac disease and to assess the extent of cardiac involvement in symptomatic patients. Cardiac MRI can help to evaluate the therapeutic effect of immunosuppressants in CSS (Marmursztejn J et al 2010)

7.5 Central nervous system

Central nervous system (CNS) involvement account for 20% of neuropathy in CSS, including arachnoid hemorrhage, cerebrovascular neuropathy, meningitis, and diffuse brain damage, which may respond to treatment with high dose of prednisone plus immunosuppressants (Zhang W et al 2009).

7.6 Peripheral nervous system

A peripheral neuropathy is seen in up to 75 percent of patients with CSS. Mononeuritis multiplex and distal symmetrical and asymmetrical sensorimotor neuropathy are equally frequent. Severe neuropathic pain may accompany the peripheral neuropathy. The diagnosis of polyneuropathy is based on clinical and electrophysiologic studies, but precise histology, immuno-histochemistry and morphometric study of the peripheral nerve biopsy may be decisive in establishing the diagnosis (Kararizou E et al 2011). There may be 2 pathogenetic mechanisms of neuropathy with CSS: ANCA-related vascular fibrinoid necrosis, and a toxic eosinophilic effect on nerve fibers which is independent of ANCA. Therapy targeting activated eosinophils may be a possible treatment for intractable neuropathy of CSS (Oka N et al. 2010).

7.7 Gastrointestinal tract

An eosinophilic gastroenteritis, characterized by abdominal pain, diarrhea, gastrointestinal bleeding, and colitis, may precede or coincide with the vasculitic phase of CSS. Gastrointestinal involvement may result in acute abdomen, acute acalculous cholecystitis, pancreatitis, mesenteric vasculitis, and bowel perforation due to necrotizing vasculitis (Rolla

G et al. 2007). Severe gastrointestinal tract involvement is a well-recognized important negative prognostic factor. With severe gastrointestinal disease, including intestinal bleeding, perforation, and pancreatitis, survival was approximately 65% at 78 months compared with nearly 90% without such involvement (Guillevin L et al 1999).

7.8 Renal

The frequency of renal involvement varies among studies, from 15 to 30% (Sinico RA et al. 2006). A few patients have rapidly progressive or acute renal insufficiency (plasma creatinine concentration >1.4 mg/dL), while most patients have isolated proteinuria or microscopic hematuria. Nephrotic syndrome is rarely reported. In the severe cases, renal biopsy shows necrotizing glomerulonephritis. A positive test for antineutrophil cytoplasmic antibodies (ANCA) is found in all patients with glomerulonephritis. Systemic hypertension affects approximately 10 to 30 percent of patients with CSS and may reflect renal involvement with CSS or be a complication of glucocorticoid therapy.

8. Assessment of prognosis

The 1996 Five-Factor Score (FFS) for systemic necrotizing vasculitides (polyarteritis nodosa, microscopic polyangiitis, and Churg-Strauss syndrome) is used to evaluate prognosis at diagnosis. Recently (Merkel PA et al 2009) the FFS have been revisited, including Wegener granulomatosis (Guillevin L et al 2011). Clinical, laboratory, and immunologic manifestations present at diagnosis of systemic necrotizing vasculitides for 1108 consecutive patients registered in the French Vasculitis Study Group database were evaluated. Overall mortality was 19.8% (219/1108); mortality for each of the systemic necrotizing vasculitides was: 27.5 % for microscopic polyangiitis, 24.6 % for polyarteritis nodosa, 13.9 % for CSS and 13.2 % for WG. The following factors were significantly associated with higher 5-year mortality: age >65 years, cardiac symptoms, gastrointestinal involvement, and renal insufficiency (stabilized peak creatinine ≥ 150 $\mu\text{mol/L}$). All were disease-specific ($p < 0.001$); the presence of each was accorded +1 point. Ear, nose, and throat (ENT) symptoms, affecting patients with WG and CSS, were associated with a lower relative risk of death, and their absence was scored +1 point ($p < 0.001$). Only renal insufficiency was retained (not proteinuria or microscopic hematuria) as impinging on outcome. According to the 2009 FFS, 5-year mortality rates for scores of 0, 1, and ≥ 2 were 9%, 21% ($p < 0.005$), and 40% ($p < 0.0001$), respectively. The revised FFS for the 4 systemic necrotizing vasculitides now comprises 4 factors associated with poorer prognosis and 1 with better outcome. The retained items demonstrate that visceral involvement weighs heavily on outcome.

9. Therapy

9.1 Corticosteroids

The primary therapy for CSS is systemic glucocorticoids. An additional immunosuppressive agent is typically added in patients with more advanced or refractory disease and in those whose disease flares with tapering of systemic glucocorticoids.

Systemic glucocorticoid therapy is the most important treatment for CSS. Treatment is generally initiated with prednisone at a dose of 0.5 to 1.5 mg/kg per day, the higher dose used for patients with more severe vasculitis. Intravenous glucocorticoid (eg,

methylprednisolone 1 g daily for three days) is used for initial therapy, followed by oral glucocorticoid therapy in the most severe cases.

The majority of patients with CSS achieve a remission with glucocorticoid therapy alone, but relapses were common, and up to one-third of patients require additional immunosuppressive therapy (Ribi C et al.). In CSS patients with an FFS of 0, survival is excellent, confirming the predictive value of the FFS in this disease. Once disease manifestations have come under control, the glucocorticoid dose is gradually tapered over approximately 12 to 18 months, as tolerated. Unfortunately, over the long term, most patients continued to take oral CS, which might explain the high rate of CS-related adverse events.

9.2 Cyclophosphamide

The addition of cyclophosphamide is recommended for patients with a "five factors score" of 1, particularly in the presence of cardiac or central nervous system involvement .

Cyclophosphamide may be administered orally every day or intravenously once a month . Extrapolating from Wegener's granulomatosis, outcomes with daily and monthly regimens were similar; a slightly greater risk of bladder toxicity with the daily regimen and a slightly greater risk of relapse with the monthly regimen have been noted. The duration of cyclophosphamide therapy remains controversial. When used to treat Wegener's granulomatosis, typically a six month regimen is used.

9.3 Alternative immunosuppressive therapy

An alternative regimen for patients with milder non life-threatening disease, would be initial treatment with glucocorticoids plus either azathioprine (Bosch X et al 2007) or methotrexate (De Groot K et al 2005). In the latter study of 100 patients with early systemic ANCA-positive vasculitides (including CSS) that compared glucocorticoids plus methotrexate with glucocorticoids plus cyclophosphamide, the remission success rate was similar at six months (90 and 94 percent, respectively). However, the methotrexate regimen was less successful for patients with more extensive disease or pulmonary involvement.

Interferon-alpha appeared to be an effective and well-tolerated treatment for induction of remission in patients with refractory Churg-Strauss syndrome in a phase II study (Metzler C. et al 2008). . Recombinant interferon-alpha has been reported to be partially effective in the prevention of major relapses in patients with Churg-Strauss syndrome (Metzler C. et al 2010). Due to numerous side effects and infections during long-term administration its use should be restricted to patients with contraindications against conventional immunosuppressive therapies.

9.4 Immunosuppressive maintenance therapy

Once remission is induced with cyclophosphamide and glucocorticoid therapy (which usually occurs within six to twelve months), patients are switched to maintenance therapy with less toxic immunosuppressive drugs, usually azathioprine or methotrexate, in combination with a tapering dose of glucocorticoids. For patients whose disease is not severe enough to require cyclophosphamide, but requires long-term therapy with moderate to high dose prednisone (more than 10 mg daily), an immunosuppressive agent is often added for a glucocorticoid sparing effect.

9.5 New promising therapeutic approach: the monoclonal antibodies

Rituximab

B cell depletion with rituximab has allowed remissions in relapsing or refractory antineutrophil cytoplasmic antibody (ANCA)-associated vasculitis in small studies. A multicenter survey of rituximab therapy for refractory ANCA-associated vasculitis has been recently published (Jones RB et al. 2009). This permitted comparison of rituximab dosing regimens, the value of continuing immunosuppression, and investigation of ANCA and B cell levels as re-treatment biomarkers. Retrospective, standardized data collection from 65 sequential patients receiving rituximab for refractory ANCA-associated vasculitis at 4 centers in the UK was used. All patients achieved B cell depletion. Complete remission occurred in 49 of the 65 patients (75%), partial remission in 15 (23%), and no response in 1 (2%). The prednisolone dosage was reduced from 12.5 mg/day (median) to 9.0 mg/day at 6 months ($P = 0.0006$). Immunosuppressive therapy was withdrawn in 37 of 60 patients (62%). Twenty-eight of 49 patients who achieved full remission (57%) experienced relapse (median 11.5 months). B cell return preceded relapse in 14 of 27 patients (52%). Although ANCA levels fell after rituximab therapy, relapse was not associated with ANCA positivity or a rise in ANCA levels. Neither the initial rituximab regimen (4 infusions of 375 mg/m² each given 1 week apart or 2 infusions of 1 gm each given 2 weeks apart) nor withdrawal of immunosuppressive therapy (37 of 60 patients [62%]) influenced the timing of relapse. Thirty-eight patients received ≥ 2 courses of rituximab, and complete remission was induced or maintained in 32 of them (84%). IgM levels fell, although IgG levels remained stable. Forty-six serious adverse events occurred, including 2 episodes of late-onset neutropenia, which were attributed to rituximab. Rituximab seems to be effective for inducing remission in refractory ANCA-associated vasculitis. Nevertheless, relapses may occur, but re-treatment has been found effective and safe. ANCA and B cell levels lacked sufficient sensitivity to guide the timing of re-treatment.

Severe bronchospasm associated with rituximab for refractory Churg-Strauss syndrome has been reported (Bouldouyre MA et al 2009).

Mepolizumab

Levels of IL-5, a cytokine regulating eosinophils, can be increased in patients with CSS. Mepolizumab, a humanized monoclonal anti-IL-5 antibody, decreases steroid requirements in patients with non-CSS hypereosinophilic syndromes. Recently, whether mepolizumab would safely allow corticosteroid tapering in patients with steroid-dependent CSS while decreasing serum markers of disease activity has been investigated in an open-label pilot study (Kim S et al 2010). Seven patients received 4 monthly doses of mepolizumab to assess whether it safely decreased CSS disease activity and permitted tapering of systemic corticosteroids. Mepolizumab was safe and well tolerated in patients with CSS. Mepolizumab reduced eosinophil counts and allowed for safe corticosteroid reduction in all 7 subjects. On cessation of mepolizumab, CSS manifestations recurred, necessitating corticosteroid bursts. Mepolizumab is a safe and well-tolerated therapy in patients with CSS, offering clinical benefit by enabling corticosteroid tapering while maintaining clinical stability.

Omalizumab

The anti-IgE monoclonal antibody omalizumab is approved as add-on therapy of severe allergic asthma. Besides the IgE blockage effect, studies have shown antiallergic and anti-inflammatory properties of anti-IgE, among which is the reduction in circulating and tissue eosinophils.

Efficacy of omalizumab therapy in some cases of CSS have been reported. In two patients whose disease was not controlled by systemic glucocorticoid, omalizumab obtained disease control (Pabst S et al 2008). Another report described similar results with anti-IgE in a patient with Churg–Strauss syndrome (CSS) who still presented with asthma which was difficult to control. The asthma did not improve despite the use of high-dose inhaled corticosteroids, long-acting β_2 agonists and several courses of steroid pulse therapy. Omalizumab was given and his asthma was controlled and a marked improvement in eosinophilia was observed (Giavina-Bianchi P et al 2007).

On the other hand, there are at least three cases of temporal association between anti-IgE use and the development of CSS. CSS was probably caused by systemic steroid tapering in these cases, rather than anti-IgE use.

Omalizumab can be used in patients with CSS to treat and control asthma, but it is probable that anti-IgE alone is not enough to control CSS activity. Although we are getting more evidence about the safety of omalizumab in patients with asthma and CSS, larger long-term studies are needed before the widespread use of anti-IgE can be recommended and also to verify if it is effective in the treatment of CSS.

10. References

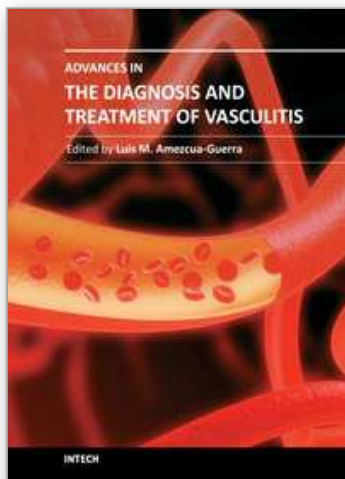
- Baldini C, Della Rossa A, Grossi S, et al. Churg–Strauss syndrome: outcome and long-term follow-up of 38 patients from a single Italian centre [in Italian]. *Reumatismo*; 61:118–124. 2009
- Bibby S, Healy B, Steele R, Kumareswaran K, Nelson H, Beasley R. Association between leukotriene receptor antagonist therapy and Churg–Strauss syndrome: an analysis of the FDA AERS database. *Thorax* 65(2):132-8, 2010
- Boita M, Guida G, Circosta P, Heffler E, Stella S, Elia AR, Rolla G, Cignetti A. Functional and molecular characterization of monoclonal T cell expansions in Churg Strauss Syndrome. Abstract, WIRM IV (World Immune Regulation Meeting), Davos, Switzerland, 2010
- Boki KA, Dafni U, Karpouzas GA, Papasteriades C, Drosos AA, Moutsopoulos HM. Necrotizing vasculitis in Greece: clinical, immunological and immunogenetic aspects. A study of 66 patients. *Br J Rheumatol*. 1997 Oct;36(10):1059-66.
- Bosch X, Guilabert A, Espinosa G, Mirapeix E. Treatment of antineutrophil cytoplasmic antibody associated vasculitis: a systematic review. *JAMA*. 2007;298(6):655
- Bosco L, Peroni A, Schena D, Colato C, Girolomoni G. Cutaneous manifestations of Churg–Strauss syndrome: report of two cases and review of the literature. *Clin Rheumatol*. 2011 Apr;30(4):573-80. Epub 2010 Oct 15.
- Bouldouyre MA, Cohen P, Guillevin L. Severe bronchospasm associated with rituximab for refractory Churg–Strauss syndrome. *Ann Rheum Dis*. 2009;68(4):606.
- Clinical Research Consortium. Comparison of disease activity measures for anti-neutrophil cytoplasmic autoantibody (ANCA)-associated vasculitis. *Ann Rheum Dis*. 2009 Jan;68(1):103-6. Epub 2008 Jul 29.
- Cohen P, Guillevin L, Baril L, Lhote F, Noel LH, Lesavre P. Persistence of antineutrophil cytoplasmic antibodies (ANCA) in asymptomatic patients with systemic polyarteritis nodosa or Churg–Strauss syndrome: follow-up of 53 patients. *Clin Exp Rheumatol*. 1995 Mar-Apr;13(2):193-8.

- Csernok E. Anti-neutrophil cytoplasmic antibodies and pathogenesis of small vessel vasculitides. *Autoimmun Rev*; 2: 158 – 64.2003.Kararizou E, Davaki P, Spengos K, Karandreas N, Dimitracopoulos A, Vassilopoulos D.
- Churg-Strauss syndrome complicated by neuropathy: a clinicopathological study of clinicopathological study of nine cases.*Clin Neuropathol*. 2011 Jan-Feb;30(1):11-7.
- Dallos T, Heiland GR, Strehl J, Karonitsch T, Gross WL, Moosig F, Holl-Ulrich C, Distler JH, Manger B, Schett G, Zwerina J.CCL17/thymus and activation-related chemokine in Churg-Strauss syndrome. *Arthritis Rheum*. 2010 Nov;62(11):3496-503.
- De Groot K, Rasmussen N, Bacon PA, Tervaert JW, Feighery C, Gregorini G, Gross WL, Luqmani R, Jayne DR. Randomized trial of cyclophosphamide versus methotrexate for induction of remission in early systemic antineutrophil cytoplasmic antibody-associated vasculitis. *Arthritis Rheum*. 2005;52(8):2461
- Giavina-Bianchi P, Giavina-Bianchi M, Agondi R, Kalil J. Three months' administration of anti-IgE to a patient with Churg-Strauss syndrome. *J Allergy Clin Immunol*. 2007;119(5):1279
- Gross WL. Churg-Strauss syndrome: update on recent developments. *Curr Opin Rheumatol*. 2002 Jan;14(1):11-4.
- Guida G, Vallario A, Stella S, Boita M, Circosta P, Mariani S, Prato G, Heffler E, Bergia R, Sottile A, Rolla G, Cignetti A. Clonal CD8+ TCR-Vbeta expanded populations with effector memory phenotype in Churg Strauss syndrome. *Clin Immunol*. 2008 Jul;128(1):94-102. Epub 2008 May 23.
- Guillevin L, Cohen P, Gayraud M, Lhote F, Jarrousse B, Cassaus P, Churg-Strauss syndrome: clinical study and long-term follow-up of 96 patients, *Medicine (Baltimore)*, Volume: 78, (1999), pp. 26 – 37
- Guillevin L, Pagnoux C, Seror R, Mahr A, Mouthon L, Le Toumelin P; French Vasculitis Study Group (FVSG). The Five-Factor Score revisited: assessment of prognoses of systemic necrotizing vasculitides based on the French Vasculitis Study Group (FVSG) cohort. *Medicine (Baltimore)*. 2011 Jan;90(1):19-27.
- Guillevin L, Vignaux O. Cardiac magnetic resonance imaging in Churg-Strauss-syndrome. Impact of immunosuppressants on outcome assessed in a prospective study on 8 patients. *Clin Exp Rheumatol*. 2010
- Guilpain P, Auclair JF, Tamby MC, et al. Serum eosinophil cationic protein: a marker of disease activity in Churg–Strauss syndrome. *Ann N Y Acad Sci*; 1107:392–399. 2007
- Hellmich B, Csernok E, Gross WL. Proinflammatory cytokines and autoimmunity in Churg-Strauss syndrome. *Ann N Y Acad Sci*. 2005 Jun;1051:121-31.
- J.Fraser, V.Arcus, P.Kong, E.Baker, and T.Proft, Superantigens - powerful modifiers of the immune system, *Mol.Med.Today* 6 125-132 .2000
- Jakiela B, Sanak M, Szczeklik W, Sokolowska B, Plutecka H, Mastalerz L, Musial J, Szczeklik A. Both Th2 and Th17 responses are involved in the pathogenesis of Churg-Strauss syndrome. *Clin Exp Rheumatol*. 2011
- Jennette JC, Falk RJ, Andrassy K, et al. Nomenclature of systemic vasculitides: proposal of an international consensus conference. *Arthritis Rheum* 1994; 37: 187–92.
- Jennette, J. C., H. Xiao, and R. J. Falk. Pathogenesis of vascular inflammation by anti-neutrophil cytoplasmic antibodies. *J. Am. Soc. Nephrol*. 17: 1235-1242. 2006.

- Jones RB, Ferraro AJ, Chaudhry AN, Brogan P, Salama AD, Smith KG, Savage CO, Jayne DR. A multicenter survey of rituximab therapy for refractory antineutrophil cytoplasmic antibody-associated vasculitis. *Arthritis Rheum.* 2009;60(7):2156.
- Kararizou E, Davaki P, Spengos K, Karandreas N, Dimitracopoulos A, Vassilopoulos Katzenstein AL. Diagnostic features and differential diagnosis of Churg-Strauss syndrome in the lung: a review. *Am J Clin Pathol* 2000;114:767-772
- Kiene M, Csernok E, Mueller A. Elevated interleukin-4 and interleukin-13 production by T cell lines from patients with Churg-Strauss syndrome. *Arthritis Rheum.* 44: 469-473. 2001.
- Kim S, Marigowda G, Oren E, Israel E, Wechsler ME. Mepolizumab as a steroid-sparing treatment option in patients with Churg-Strauss syndrome. *J Allergy Clin Immunol.* 2010;125(6):1336.
- Krischer JP, Luqmani R, Mahr AD, Matteson EL, Specks U, Stone JH; Vasculitis Lanham JG, Elkon KB, Pusey CD, et al. Systemic vasculitis with asthma and eosinophilia: a clinical approach to the Churg-Strauss syndrome. *Medicine (Baltimore)* 1984; 63: 65-81.
- Lurati-Ruiz F, Spertini F. Predictive value of antineutrophil cytoplasmic antibodies in small-vessel vasculitis. *J Rheumatol*; 32:2167-2172. 2005
- Manger BJ, Krapf FE, Gramatzki M, et al. IgE-containing circulating immune complexes in Churg-Strauss vasculitis. *Scand J Immunol*; 21:369-373. 1985
- Marmursztejn J, Cohen P, Duboc D, Pagnoux C, Mouthon L, Guilpain P, Legmann P, Masi AT, Hunder GG, Lie JT, et al. The American College of Rheumatology 1990 criteria for the classification of Churg-Strauss syndrome (allergic granulomatosis and angiitis). *Arthritis Rheum* 1990; 33: 1094-100.
- Merkel PA, Cuthbertson DD, Hellmich B, Hoffman GS, Jayne DR, Kallenberg CG, Metzler C, Csernok E, Gross WL, Hellmich B. Interferon-alpha for maintenance of remission in Churg-Strauss syndrome: a long-term observational study. *Clin Exp Rheumatol.* 2010 Jan-Feb;28(1 Suppl 57):24-30
- Metzler C, Schnabel A, Gross WL, Hellmich B. A phase II study of interferon-alpha for the treatment of refractory Churg-Strauss syndrome. *Clin Exp Rheumatol.* 2008 May-Jun;26(3 Suppl 49):S35-40.
- Morice WG, Kimlinger T, Katzmann JA, Lust JA, Heimgartner PJ, K.C. Halling, Hanson CA, Flow cytometric assessment of TCR-Vbeta expression in the evaluation of peripheral blood involvement by T-cell lymphoproliferative disorders: a comparison with conventional T-cell immunophenotyping and molecular genetic techniques, *Am. J. Clin. Pathol.* 121 (2004) 373-383.
- Muschen M, Warskulat U, Perniok A, Involvement of soluble CD95 in Churg-Strauss syndrome. *Am. J. Pathol.* 155: 915-925. 1999 Hattori N, Ichimura M, Nagamatsu M, Li M, Yamamoto K, Kumazawa K, Mitsuma T, Sobue G, Clinicopathological features of Churg-Strauss syndrome-associated neuropathy, *Brain* 122 (Pt 3)(1999) 427-439.
- Neumann T, Manger B, Schmid M, Kroegel C, Hansch A, Kaiser WA, Reinhardt D, Wolf G, Hein G, Mall G, Schett G, Zwerina J. Cardiac involvement in Churg-Strauss syndrome: impact of endomyocarditis. *Medicine (Baltimore).* 2009 Jul;88(4):236-43.

- Oka N, Kawasaki T, Matsui M, Shigematsu K, Unuma T, Sugiyama H. Two subtypes of Churg-Strauss syndrome with neuropathy: the roles of eosinophils and ANCA. *Mod Rheumatol*. 2010 Dec 29.
- Orriols, R, Muñoz, X, Ferrer, J, et al. Cocaine-induced Churg-Strauss vasculitis. *Eur Respir J* 1996; 9:175.
- Pabst S, Tiyerili V, Grohé C. Apparent response to anti-IgE therapy in two patients with refractory "forme fruste" of Churg-Strauss syndrome. *Thorax*. 2008;63(8):747.
- Polzer K, Karonitsch T, Neumann T, et al. Eotaxin-3 is involved in Churg- Strauss syndrome: a serum marker closely correlating with disease activity. *Rheumatology (Oxford)*; 47:804-808. 2008
- Ribi C, Cohen P, Pagnoux C, Mahr A, Arène JP, Lauque D, Puéchal X, Letellier P, Delaval P, Cordier JF, Guillevin L, French Vasculitis Study Group. Treatment of Churg-Strauss syndrome without poor-prognosis factors: a multicenter, prospective, randomized, open-label study of seventy-two patients. *Arthritis Rheum*. 2008;58(2):586
- Roufosse FE, Goldman M, Cogan E. Hypereosinophilic syndromes. *Orphanet J Rare Dis*. 2007 Sep 11;2:37.
- Rolla G, Tartaglia N, Motta M, Ferrero N, Bergia R, Guida G, Heffler E. Warning nonrespiratory symptoms in asthma: catastrophic abdominal involvement in a case of Churg-Strauss syndrome. *Ann Allergy Asthma Immunol*. 2007;98:595-7.
- Sable-Fourtassou R, Cohen P, Mahr A, et al. Antineutrophil cytoplasmic antibodies and the Churg-Strauss syndrome. *Ann Intern Med*; 143: 632-638.2005
- Saito H, Tsurikisawa N, Tsuburai T, Oshikata C, Akiyama K. Cytokine production profile of CD4+ T cells from patients with active Churg-Strauss syndrome tends toward Th17. *Int Arch Allergy Immunol*. 2009;149 Suppl 1:61-5. Epub 2009 Jun 3.
- Sallusto F, Lenig D, Forster R, Lipp M, Lanzavecchia A, Two subsets of memory T lymphocytes with distinct homing potentials and effector functions, *Nature* 401 (1999) 708 – 712.
- Sanders JS, Huitema MG, Kallenberg CGM, Stegeman CA. Prediction of relapses in PR3-ANCA associated vasculitis by assessing responses of ANCA titres to treatment. *Rheumatology*; 45:724-729. 2006
- Schmitt WH, Csernok E, Kobayashi S, Klinkenborg A, Reinhold-Keller E, Gross WL. Churg-Strauss syndrome: serum markers of lymphocyte activation and endothelial damage. *Arthritis Rheum*. 1998 Mar;41(3):445-52.
- Silva CI, Müller NL, Fujimoto K, Johkoh T, Ajzen SA, Churg A Churg-Strauss syndrome: high resolution CT and pathologic findings. *J Thorac Imaging* 2005;20(2):74-80.
- Sinico RA, Bottero P. Churg-Strauss angiitis. *Best Pract Res Clin Rheumatol* 23(3):355-66, 2009.
- Sinico RA, Di Toma L, Maggiore U, Tosoni C, Bottero P, Sabadini E, Giammarresi G, Tumiatì B, Gregorini G, Pesci A, Monti S, Balestrieri G, Garini G, Vecchio F, Buzio C. Renal involvement in Churg-Strauss syndrome. *Am J Kidney Dis*. 2006;47(5):770-9.
- Sinico, R. A., L. Di Toma, U. Maggiore, P. Bottero, A. Radice, C. Tosoni, C. Grasselli, L. Pavone, G. Gregorini, S. Monti, M. Frassi, F. Vecchio, C. Corace, E. Venegoni, and C. Buzio.. Prevalence and clinical significance of antineutrophil cytoplasmic antibodies in Churg-Strauss syndrome. *Arthritis Rheum*. 52: 2926-2935. 2005

- Srouji I, Lund V, Andrews P, Edwards C. Rhinologic symptoms and quality-of-life in patients with Churg-Strauss syndrome vasculitis. *Am J Rhinol.* 2008 Jul-Aug;22(4):406-9.
- Steinman L. A brief history of T(H)17, the first major revision in the T(H)1/T(H)2 hypothesis of T cell-mediated tissue damage. *Nat Med.* 2007 Feb;13(2):139-45.
- Szczeklik W, Sokołowska BM, Zuk J, Mastalerz L, Szczeklik A, Musiał J. The course of asthma in Churg-Strauss syndrome. *J Asthma.* 2011 Mar;48(2):183-7.
- Tougan T, Onda H, Okuzaki D, Kobayashi S, Hashimoto H, Nojima H. Focused microarray analysis of peripheral mononuclear blood cells from Churg-Strauss syndrome patients. *DNA Res.* Apr 30;15(2):103-14. 2008
- Tsukadaira A, Okubo Y, Kitano K, et al. Eosinophil active cytokines and surface analysis of eosinophils in Churg-Strauss syndrome. *Allergy Asthma Proc;* 20:39-44. 1999
- Tsurikisawa N, Saito H, Tsuburai T, et al. Differences in regulatory T cells between Churg-Strauss syndrome and chronic eosinophilic pneumonia with asthma. *J Allergy Clin Immunol* 122:610-616. 2008.
- Vaglio A, Martorana D, Maggiore U, Grasselli C, Zanetti A, Pesci A, Garini G, Manganelli P, Bottero P, Tumati B, Sinico RA, Savi M, Buzio C, Neri TM; HLA-DRB4 as a genetic risk factor for Churg-Strauss syndrome. *.arthritis and Rheumatism,* 56(9):3159-66 .2007.
- Watts RA, Lane SE, Bentham G, Scott DG. Epidemiology of systemic vasculitis: a ten-year study in the United Kingdom. *Arthritis Rheum* 2000; 43: 414-19
- Wechsler ME, Wong DA, Miller MK, Lawrence-Miyasaki L. Churg-strauss syndrome in patients treated with omalizumab. *Chest.* 2009 Aug;136(2):507-18
- Wei, S., P. Charmley, M. A. Robinson, and P. Concannon. The extent of the human germline T-cell receptor V beta gene segment repertoire. 1994 *Immunogenetics* 40: 27-36.
- Wieczorek S, Holle JU, Epplen JT. Recent progress in the genetics of Wegener's granulomatosis and Churg-Strauss syndrome. *Curr Opin Rheumatol.* Jan;22(1):8-14. 2010
- Worthy SA, Müller NL, Hansell DM, et al. Churg-Strauss syndrome: the spectrum of pulmonary CT findings in 17 patients. *AJR Am J Roentgenol* 1998;170:297-300
- Zhang W, Zhou G, Shi Q, Zhang X, Zeng XF, Zhang FC. Clinical analysis of nervous system involvement in ANCA-associated systemic vasculitides. *Clin Exp Rheumatol.* 2009 Jan-Feb;27(1 Suppl 52):S65-9.



Advances in the Diagnosis and Treatment of Vasculitis

Edited by Dr. Luis M Amezcua-Guerra

ISBN 978-953-307-786-4

Hard cover, 366 pages

Publisher InTech

Published online 09, November, 2011

Published in print edition November, 2011

This book represents the culmination of the efforts of a group of outstanding experts in vasculitis from all over the world, who have endeavored to draw themselves into this volume by keeping both the text and the accompanying figures and tables lucid and memorable. The book provides practical information about the screening approach to vasculitis by laboratory analysis, histopathology and advanced image techniques, current standard treatment along with new and more specific interventions including biologic agents, reparative surgery and experimental therapies, as well as miscellaneous issues such as the extra temporal manifestations of "temporal arteritis" or the diffuse alveolar hemorrhage syndrome. The editor and each of the authors invite you to share this journey by one of the most exciting fields of the medicine, the world of Vasculitis.

How to reference

In order to correctly reference this scholarly work, feel free to copy and paste the following:

Giovanni Rolla, Monica Boita, Enrico Heffler and Giuseppe Guida (2011). Churg Strauss Syndrome: Clinical and Pathogenetic Approach to Therapy, *Advances in the Diagnosis and Treatment of Vasculitis*, Dr. Luis M Amezcua-Guerra (Ed.), ISBN: 978-953-307-786-4, InTech, Available from:

<http://www.intechopen.com/books/advances-in-the-diagnosis-and-treatment-of-vasculitis/churg-strauss-syndrome-clinical-and-pathogenetic-approach-to-therapy>

INTECH
open science | open minds

InTech Europe

University Campus STeP Ri
Slavka Krautzeka 83/A
51000 Rijeka, Croatia
Phone: +385 (51) 770 447
Fax: +385 (51) 686 166
www.intechopen.com

InTech China

Unit 405, Office Block, Hotel Equatorial Shanghai
No.65, Yan An Road (West), Shanghai, 200040, China
中国上海市延安西路65号上海国际贵都大饭店办公楼405单元
Phone: +86-21-62489820
Fax: +86-21-62489821

© 2011 The Author(s). Licensee IntechOpen. This is an open access article distributed under the terms of the [Creative Commons Attribution 3.0 License](https://creativecommons.org/licenses/by/3.0/), which permits unrestricted use, distribution, and reproduction in any medium, provided the original work is properly cited.

IntechOpen

IntechOpen