

We are IntechOpen, the world's leading publisher of Open Access books Built by scientists, for scientists

6,900

Open access books available

185,000

International authors and editors

200M

Downloads

Our authors are among the

154

Countries delivered to

TOP 1%

most cited scientists

12.2%

Contributors from top 500 universities



WEB OF SCIENCE™

Selection of our books indexed in the Book Citation Index
in Web of Science™ Core Collection (BKCI)

Interested in publishing with us?
Contact book.department@intechopen.com

Numbers displayed above are based on latest data collected.
For more information visit www.intechopen.com



The Role of Biological Therapies in the Management of Systemic Vasculitis

Paloma Vela and Mariano Andrés

*Sección de Reumatología, Hospital General Universitario de Alicante
Spain*

1. Introduction

Systemic vasculitides are multisystem disorders with an autoimmune basis leading to blood vessel inflammation. Vasculitis present a wide spectrum, being classified regarding different aspects on pathogenesis, histopathology or laboratory findings. The most common used classification considers size of the vessel predominantly affected, established at Chapel Hill Consensus Conference (Jennete et al, 1994): large-sized vessels (giant-cell arteritis, Takayasu's arteritis), medium-sized vessels (polyarteritis nodosa, Kawasaki's disease) and small-sized vessels (Wegener granulomatosis, microscopic polyangiitis, Churg-Strauss syndrome, cryoglobulinemia, Henoch-Schönlein purpura, and cutaneous leukocytoclastic angiitis). Behçet's disease affects small and large vessels of the arterial and venous systems. Systemic vasculitis predominantly associated with the presence of serum anti-neutrophil cytoplasmic antibodies (ANCA) are known as ANCA-associated vasculitis, in spite of about 10-20% of this vasculitis present with classical clinical picture but ANCA negative.

Systemic vasculitis are rare diseases with wide and heterogenic range of manifestations, so leading prospective controlled clinical trials in pathogenesis and management of these diseases is difficult. Despite these limitations, first descriptions about vasculitis in mid-20th century ascertained that some forms of vasculitis are severe and potentially fatal in a short-term period (weeks-months) with no treatment. These are mainly Wegener disease and microscopic polyangiitis with critical organ involvement (kidney, lung, gastrointestinal system or central nervous system), but they are not the only ones. Introduction of glucocorticoids and, later, immunosuppressive agents (cyclophosphamide, methotrexate, azathioprine, etc.) contributed to achieve remission of these diseases and prevent further organ damage, former potentially fatal.

But nowadays many questions are still unsolved. In ANCA-associated vasculitis, high rate of remission (about 80-90% patients) is followed by an unacceptable rate of relapses, which is especially important in Wegener granulomatosis, reaching up to 50% of patients within 2 years after the diagnosis (Hoffman et al, 1992), with further morbidity and mortality. Another concern is about cytotoxic regimens for induction of remission on these diseases: although current schemes are less toxic, severe infections and bone marrow toxicity still are major problems, so serious adverse events and mortality in early stages are not related to disease activity, but to therapy in a significant proportion of cases (Little MA et al, 2010).

In last decade, the advent of target-defined drugs, known as biological agents, became a substantial advance for the management of several diseases in different medical areas, as

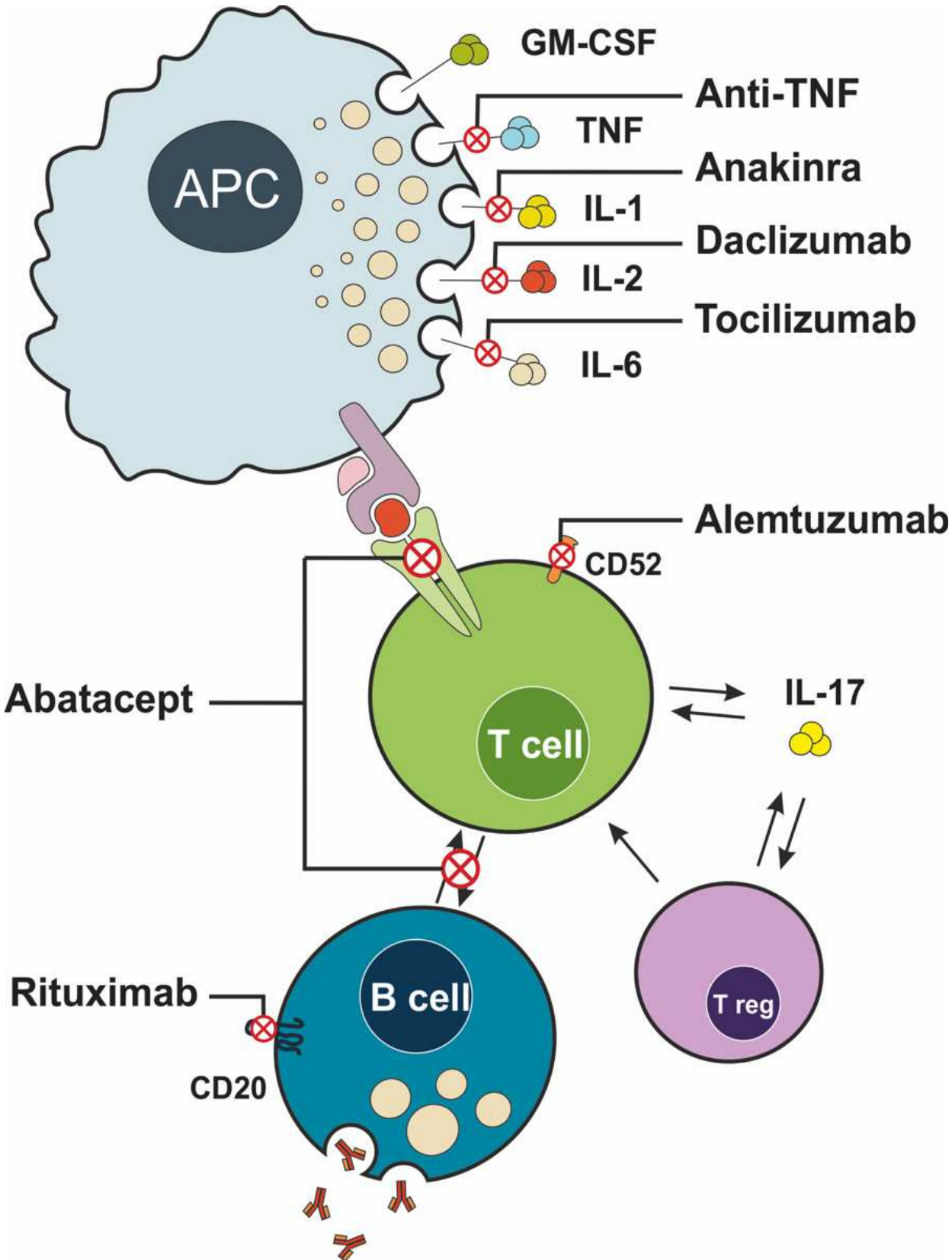


Fig. 1. Common biological agents and their targets on immune system cells and molecules. APC: antigen-presenting cell; GM-CSF: granulocyte-monocyte colonial stimulating factor; TNF: tumour necrosis factor; IL: interleukin. [Figure by Enrique Sillero MD].

rheumatology, nephrology, haematology, oncology, dermatology or digestive medicine. They are immunological agents, monoclonal antibodies or recombinant soluble receptors, designed against simple targets on serum (for example, tumor necrosis factor- α , interleukin-1 or interleukin-6) or cell surface (for example, CD20, CD3 or epidermal growing factor receptor) (Figure 1). In autoimmune disorders, biological agents proved to be highly effective in rheumatoid arthritis, inflammatory bowel disease, psoriasis or autoimmune haemolytic anaemia, also in refractory forms. As any other agents, biological therapies carry some adverse events, as increased risk of infections, hypersensitivity or infusion-related reactions and skin disorders. An increased risk of further malignancies is not clear. But overall benefit-risk ratio is very high.

In systemic vasculitis, the introduction of biological therapy in last decade has provided the hope of a more targeted treatment with greater efficacy, fewer side effects and longer-lasting remissions. They may also be a promising solution for refractory cases. In this chapter, the current evidence about the use of biological agents in systemic vasculitis will be reviewed.

2. ANCA-associated vasculitis

2.1 Introduction

Wegener's granulomatosis, Churg-Strauss syndrome and microscopic polyangiitis are types of systemic vasculitis associated to the presence of detectable serum anti-neutrophil cytoplasmic antibodies (ANCA). Less than 10% of cases of polyarteritis nodosa show positive ANCA. As previously described, ANCA vasculitis are severe conditions with a fatal outcome with no treatment. Former high mortality rates became lower after the introduction of an intensive management with immunosuppressive agents as cyclophosphamide. Despite this improvement, unacceptable rates of relapses and drug-related adverse events made the search of more effective and more safety agents highly desirable, and biological agents have been used and tested with this purpose. Their results will be discussed in this section.

2.2 TNF blockade

Anti-tumour necrosis factor (TNF) agents have been widely used in ANCA-associated vasculitis. TNF α is a prominent cytokine involved in the formation of granuloma in infectious and inflammatory diseases, and many other evidence support TNF blockade in ANCA-associated vasculitis: TNF gene expression and cytokine production by lymphocytes is increased in patients with Wegener (Deguchi et al, 1990; Ludviksson et al, 1998); TNF soluble receptor levels seemed to correlate with disease activity (Nassonov et al, 1997) and TNF-positive cells predominate in inflammatory infiltrates found in renal biopsies from patients with ANCA vasculitis (Noronha I et al, 1993).

Uncontrolled studies where anti-TNF drugs were used in patients with refractory ANCA vasculitis showed promising results in efficacy and safety. Chimeric monoclonal antibody infliximab was tried in six patients with refractory Wegener granulomatosis – one persistent and five relapsing diseases - in a preliminary study (Lamprecht et al, 2002). In different dosage (3mg/kg in 2 patients and 5 mg/kg in 4 patients), the addition of infliximab to standard therapy achieved remission in five out six patients, being discontinued in the remaining one due to a non-confirmed infection. In another study (Booth et al, 2004), an open-labelled multicenter non-controlled trial, infliximab was associated with a high rate of remission (88% patients in about 6 weeks) in 28 patients with Wegener granulomatosis and microscopic polyangiitis. Disease activity scores, inflammatory markers and prednisolone

doses were significantly reduced all throughout the study. These promising data with infliximab carried on some queries: discontinuation of the drug followed by high rate of relapses in a short period - about 20% patients in 16 months of follow-up; there were no control group; patients presented a significant rate of severe adverse events, with 2 deaths, 6 severe infections and one malignancy. The pattern of organ involvement and detected microorganism were consistent with recognized events in other infliximab-treated disorders.

In an exploratory study (Stone et al, 2001), fusion protein etanercept - a combination of p75 soluble TNF α receptor and Fc portion of human IgG1 - were added to standard therapy for patients with refractory Wegener granulomatosis, persistently active or relapsing forms. Twenty patients received etanercept 25mg subcutaneous twice a week for 6 months. The study endpoint was safety and there was no control group. After 6 months of follow up, the most common adverse event was related to injection site reactions, and no serious adverse events were detected. Though no study endpoint, good results were noted in efficacy; the authors found a reduction in disease activity, even remissions in 80% of patients, with reductions in prednisolone doses.

These promising results in safety and efficacy led to further randomized controlled trial (WGET Research Group, 2005). In this multicenter, randomized, double-blind, placebo-controlled trial, 181 patients with active Wegener disease - not other forms of ANCA vasculitis were included - were randomized to receive etanercept 25mg subcutaneously twice a week or placebo, along with standard therapy, in order to evaluate the maintenance of remission. Surprisingly, no significant differences were found in the rate of sustained remission - 69% patients in etanercept group versus 75% patients in control group - and results did not depend on severity or duration of the disease. But the most astonishing finding was related to safety: both groups presented a similar rate of severe adverse events; in etanercept group, however, 6 malignancies were detected, with none in placebo group. It is a standardised incidence rate over 300% compared to expected rate in this group matching per age and sex. It is noteworthy that relapsing disease, what means more previous exposure to immunosuppressive agents, was higher in etanercept group.

Recently, fully humanised TNF α monoclonal antibody adalimumab has been tested in ANCA-associated vasculitis (Laurino et al, 2010). An open-label, prospective uncontrolled trial was underwent to study adalimumab (40mg subcutaneously every 2 weeks) as an adjuvant to standard therapy in flares of Wegener granulomatosis and microscopic polyangiitis. Results were comparable to infliximab: a high rate of remission followed by frequent relapses (6 out 14 patients in less than 2 years after remission) and 2 cases of severe infections, one fatal.

Data about TNF α blockade in other forms of necrotising systemic vasculitis are scarce. Churg-Strauss syndrome is often mild and controlled with glucocorticoids. But data suggest that small portion of patients will present a severe disease requiring intensive treatment. Anti-TNF agents might be an effective option for these patients (Arbach et al, 2002). Currently very rare after widespread hepatitis B vaccination, polyarteritis nodosa is a systemic necrotising vasculitis affecting medium-sized vessels and seldom associated to ANCA (less than 10% of cases). A case of refractory and severe polyarteritis nodosa successfully treated with infliximab has been reported (Al-Bishri et al, 2005).

In summary, huge evidence about TNF α blockade in ANCA-associated vasculitis is lacking. High rates of remission in refractory cases were found, especially in uncontrolled studies;

but high rate of relapses after discontinuation and intolerable severe adverse events (especially infections and increased risk of malignancies - found with etanercept) make anti-TNF agents not formally recommended for the management of ANCA-associated vasculitis.

2.3 B-cell targeted therapies

B-lymphocytes are one of the cornerstone cells in immune system, with pleiotropic effects: antibody production, antigen presentation, cytokine secretion or T-lymphocytes regulation. As previously mentioned, systemic necrotising vasculitis are largely related to ANCA autoantibodies against neutrophil proteins, mainly proteinase-3 and myeloperoxidase. B-lymphocytes are responsible of ANCA production, and plasma activated B-cell titre is related to disease activity (Popa et al, 1999). So B-cells are a logical target for the management of ANCA-associated vasculitis.

Rituximab is a chimeric monoclonal antibody against CD20; CD20 is a surface marker found almost exclusively in B-lymphocytes (immature and mature cells), except of plasma cells. Rituximab is an effective agent for B-cell non-Hodgkin lymphoma and several autoimmune disorders, as rheumatoid arthritis. Several case reports and small series found rituximab as a potential agent for patients with refractory ANCA vasculitis (Specs et al, 2001; Omdal et al, 2005; Stasi et al, 2006; Tektonidou & Skopouli, 2006; Tamura et al, 2007; Ferraro et al, 2008; Sanchez-Cano et al, 2008; Seo et al, 2008). Encouraged by previous reports, a prospective open-label pilot trial with rituximab in refractory Wegener granulomatosis was undertaken (Keogh et al, 2006). In this trial, ten patients with refractory disease - three with persistent and seven with relapsing disease - were treated with rituximab 4 weekly infusions of 375mg/m², along with glucocorticoids. All of these patients achieved complete remission in less than 5 months after last infusion, and 9 out ten continued with remission at the end of the study (12months); only one patient relapsed, at 9 months. In this trial, clinical response appeared to be related to successful B-cell depletion. Another trial (Jones et al, 2009), larger (65 patient) but retrospective, supported this results: rituximab induced remission in 75% of patients with relapsing or persistent ANCA-associated vasculitis, in this case also including microscopic polyangiitis and Churg-Strauss syndrome. Relapse occurred in 57% of patients, but subsequent courses also achieved remission.

These very promising data from uncontrolled studies warranted confirmation in randomised controlled trials. Two were recently published. RITUXVAS trial (Jones et al, 2010) was a non-inferiority open-label trial about rituximab as an induction of remission agent in ANCA-associated vasculitis with renal involvement, compared to standard regime (cyclophosphamide and steroids). Patients in treatment group received rituximab using lymphoma scheme (375mg/m² weekly 4 weeks) along with cyclophosphamide (15mg/kg 2 i.v. pulses with the first and third rituximab infusions) and glucocorticoids. Patients with new Wegener disease, microscopic polyangiitis and renal-limited vasculitis were enrolled and randomised to each group in a 3:1 ratio. No differences in sustained remission were found between both groups (76% in rituximab group versus 82% in control group, $p=0.68$), time to remission was similar (about 90 days) and safety data was comparable. Fifteen percent of patients in rituximab group and 10% patients in control group relapsed after 12 months of follow-up. Stone et al (2010) conducted the RAVE trial, a double-blind, randomised control trial where rituximab was tested as non-inferior to cyclophosphamide for induction of remission in ANCA-associated vasculitis. Investigators recruited patients with active disease, newly diagnosed or relapsed. In this trial, rituximab (lymphoma scheme) plus placebo was compared to daily oral cyclophosphamide plus placebo.

Remission rate was similar in both groups – 64% rituximab versus 53% control – being noteworthy that was lower than usual remission rates, about 80-90% (Hoffman et al, 1992). In relapsing subgroup rituximab was superior to cyclophosphamide; a possible explanation might be that patients with relapsing disease were initially treated with cyclophosphamide and are less likely to respond to new cyclophosphamide rather than those with new-onset disease. Relapses were low and did not differ between groups. Safety data was again comparable, with more leukopenia in cyclophosphamide group.

If B-cell repopulation or ANCA levels should guide further courses of rituximab in order to prevent relapse is still to be determined. In trial by Keogh et al (2006), B-cells depleted in all patients after rituximab, and further ANCA levels augments (previously decreased in all patients) coincided or followed B-cell reconstitution; in this trial only one patient relapsed, preceded by B-cell repopulation and ANCA increase. But this association was not found in other studies (Jones et al, 2009).

Churg-Strauss syndrome was seldom included in above studies, but successful outcome in refractory cases using rituximab has been reported as well (Kaushik et al, 2006; Koukoulaki et al, 2006; Pepper et al, 2008]. We found no data about rituximab in polyangiitis nodosa.

In summary, B-cells are a very promising target as a part of the management of ANCA-associated vasculitis. Presented data support the use of rituximab as an induction of remission agent, especially in persistent or relapsing disease. Due to randomised controlled trial results, rituximab should be even consider as a first-line agent, though is not licensed for this employ. One grey area of ANCA-associated vasculitis remains unanswered with rituximab: while successful results in remission have been reported, patients still present an unacceptable rate of relapses. RITUXVAS and RAVE trials did not explore rituximab as a maintenance agent, and follow-up was too short (12 and 6 months respectively) to assess it. Further studies are warranted and desirable.

2.4 T-cell targeted therapies

Along with B cells, autoreactive T lymphocytes have a major role in pathogenesis of ANCA-associated vasculitis (Popa et al, 2002). So T-cell depletion might have a role in the management of these conditions. Alemtuzumab (CAMPATH-1H) is a humanised monoclonal antibody against CD52, present in T lymphocytes and macrophages, leading to T cell depletion. Tested in other immune disorders – like rheumatoid arthritis, multiple sclerosis or renal transplantation – alemtuzumab was used in refractory cases of ANCA-associated vasculitis, especially Wegener disease. Walsh et al (2008) reported long-term results of 71 patients with refractory or relapsing disease treated with alemtuzumab. Use of alemtuzumab achieved high remission rates (85% of patients) but high relapsing rate as well (60%), and patients developed an unacceptable rate of severe adverse events, in particular infections. Infections are probably due to deep immune suppression by alemtuzumab, but it is noteworthy that several patients had other risk factors for severe infections: 23% showed undetectable CD4+ cells before alemtuzumab probably related to prior intensive immunosuppressive agents, 8% were hemodialysis-dependent and 18% presented a life-threatening disease requiring intensive unit care. Data with anti-thymocyte globulin, which also leads to lymphocyte depletion, is quite similar (Lukas & Keller, 1998; Hagen et al, 1995]. No further controlled trials have been undertaken.

CTLA-4 (CD152) is a surface molecule on activated T-cell membrane. CTLA-4 binds B7.1 (CD80) and B7.2 (CD86) from antigen-presenting cells, leading to T-cell co-stimulation. CTLA-4 has a role on immune regulation, mainly switching from Th2 to Th1-response

pattern. This effect is antagonist to CD28. Predominantly Th1 response was found in granulomatous inflammation (Csernok et al, 1999), CTLA-4 expression is increased in patients with active disease (Steiner et al, 2001) and associations with some CTLA-4 polymorphisms were found (Huang et al, 2000; Giscombe et al, 2002; Zhou et al, 2004], all in Wegener granulomatosis. In this context, CTLA-4-Ig abatacept might be a potential agent in the management of ANCA-associated vasculitis. No case reports or series have been published, but results from an ongoing trial, ABAVAS (www.clinicaltrials.gov), are awaited.

2.5 Other biological agents

We found no other reports about other biologics in ANCA-associated vasculitis. Recombinant interleukin-6 receptor tocilizumab might have a role, so as interleukin-6 levels are increased in these disorders and correlated to disease activity (Nakahama et al, 1993). Conversely, no differences in interleukin-1 levels were found between patients with active ANCA vasculitis, convalescent vasculitis and healthy controls [Nogueira E et al, 2010], making anakinra and other IL-1 antagonists unlikely to be effective.

3. Large vessel vasculitides

The primary large vessel vasculitides, Takayasu's arteritis (TA) and giant cell arteritis (GCA), are chronic inflammatory diseases of the large elastic arteries characterised by systemic inflammation and critical ischemia. GCA primarily affects temporal arteries and other extracranial branches, while in TA the aorta and its proximal branches are usually involved. TA predominates in young adults, but patients with GCA are usually older. Though these differences, some authors suggested that both entities might be two poles of the spectrum within the same disease (Maksimowicz-McKinnon et al, 2009). Glucocorticoids continue being the mainstay of initial therapy, but long-term use is associated with a great amount of adverse side effects. Both conditions can follow a chronic relapsing course, requiring long-term therapy. In addition, most patients that initially respond to glucocorticoids flare on dose reduction or discontinuation. In the Cleveland cohort (Maksimowicz-McKinnon et al., 2007), only 20% of patients persisted on remission with <10 mg prednisolone for 6 months. It is therefore common the need of an additional immunosuppressive agent to induce or maintain remission in large cohorts (Kerr et al., 1994; Vanoli et al., 2005; Park et al., 2005).

Granulomatous inflammation is one of the key histopathological features of large vessel vasculitides. Taking into account the role of tumour necrosis factor-alpha (TNF α) in the formation and maintenance of the granuloma, it could be expected that anti-TNF therapies may be beneficial in refractory forms of large vessel vasculitides. TNF α is a pro-inflammatory cytokine produced primarily by cells from monocyte-macrophage lineage. Its biologic effects include adhesion molecule expression, synthesis of chemokines and other pro-inflammatory cytokines, activation of immune system cells (T-cells, B-cells and macrophages), and inhibition of regulatory T-cells (Chung & Seo, 2009). TNF α can be found in both cell membrane-bound and soluble forms. At this time, five agents directed against TNF α are approved for use in rheumatoid arthritis and other inflammatory arthropathies: infliximab, etanercept, adalimumab, certolizumab and golimumab.

3.1 Takayasu's arteritis

TA primarily involves the aorta and its primary branches. The inflammatory process cause wall thickening on the affected arteries. Although experience with anti-TNF agents in

difficult-to-treat cases of TA is limited, multiple investigators have reported successful results.

Hoffman and associates published the first long-term study of anti-TNF therapy in TA in 2004 (Hoffmann et al., 2004). In this open-label trial, 15 patients with refractory forms of TA were enrolled. Thirteen of them had high doses requirements of glucocorticoids to maintain remission and relapsed while treated with conventional and experimental therapy; and 2 of them refused re-treatment with glucocorticoids following relapses (2 of the 15 patients). Anti-TNF agents were used, seven patients received etanercept (ETN) (25 mg twice weekly) and eight received infliximab (IFX) (from 3 to 5 mg/kg initially, and at two weeks, six weeks, and every four to eight weeks thereafter). Previous treatments included methotrexate, cyclophosphamide, mycophenolate, cyclosporin and tacrolimus. Rapid improvement was noted in 14 out 15 patients, within 2–8 weeks. Sustained remission, lasting 1 – 3.3 years, was achieved in 10 patients (75%) who were able to discontinue glucocorticoids. Four patients (27%) partially responded and were able to reduce the steroid dose by at least 50%. At 12 months, most patients required no steroids. One patient did not respond to IFX. Nine of the 14 patients with an initial response to 3 mg/kg of IFX required dose escalation to maintain disease control. Two relapses occurred with interruption of therapy, but disease control was regained when treatment was restarted.

Molloy et al (2008) reported the largest case series to date in the literature, a retrospective study examining 25 patients with active, relapsing TA. Patients were treated with IFX (n=21) or ETN (n=9) and followed for a median of 28 months. Of the nine patients initially treated with ETN, four underwent complete remission and two experienced partial remission. Two of the four patients in complete remission switched to IFX, one due to unavailability of ETN (and subsequently had a sustained remission) and the other due to a major disease flare at 67 months, but relapsed after two IFX infusions and treatment was subsequently stopped. Of the six patients in remission, three had disease relapses: two of them regained disease control with an increase in dose of ETN to 50 mg twice weekly, and the other one also required addition of prednisolone. Three patients who did not respond to ETN were switched to IFX and achieved complete remission. Of the 21 patients treated with IFX (including the five previously treated with ETN), 12 achieved complete remission and six achieved partial remission. Three patients discontinued IFX; 12 of the remaining 18 patients relapsed and required treatment with higher doses of IFX administered at shorter intervals. Median stable IFX dose was 5 mg/kg (range 4–10 mg/kg), administered at a median interval of 6 weekly (range 4–8 weekly). Of the nine patients that either permanently or temporarily discontinued IFX, eight had a disease flare at a median interval of 5 months (range 2–12); two of these patients restarted IFX treatment and again achieved remission.

Other small series have reported a similar rapid response to IFX, with dose escalation frequently needed to maintain remission (Karageorgaki et al., 2007; Tanaka et al., 2006; Jolly & Curran, 2005; Della Rossa et al., 2005). Also, a further case of refractory TA entered remission with adalimumab when infliximab was discontinued after a lupus-like reaction (Tato et al., 2005). Current data may suggest that the use of IFX compared with etanercept or adalimumab is recommendable, but one should note that doses frequently had to be escalated above the baseline 3 mg/kg dose to achieve remission.

In summary, the positive results from these case series and case reports of the use of anti-TNF agents for refractory TA are encouraging, but an adequately powered, randomized controlled trial is needed to ascertain their role.

3.2 Giant-cell arteritis

Giant-cell arteritis (GCA), also known as temporal arteritis, is an immune-mediated chronic disease characterized by granulomatous infiltrates in the wall of medium and large-sized arteries. Vessel wall inflammation leads to luminal occlusion and tissue ischemia. Patients with GCA complain of persistent unilateral headache, jaw claudication, visual disturbances, malaise and weight loss (Seo & Stone, 2004). As well as TA, GCA is characterized by granulomatous inflammation, so TNF α inhibition would appear to be an appropriate treatment approach.

Some small case series pointed that IFX might be useful as a steroid-sparing agent for GCA (Cantini et al, 2001; Andonopoulos et al, 2003; Airo et al, 2002). Based on these results, a randomized, multicenter trial of IFX versus placebo was conducted, but surprisingly failed to show efficacy (Hoffman et al, 2007). Forty-four patients newly diagnosed with GCA were randomly assigned in a 2:1 (IFX 5 mg/kg; placebo) ratio to receive infusions at weeks 0, 2, and 6, and every 8 weeks thereafter, after prednisone-induced remission. Primary outcomes were the number of relapse/recurrence free patients through week 22 and adverse events, while secondary outcomes included time to first relapse, number of relapse-free patients when prednisone was tapered to 10 mg day, and cumulative prednisone dose. Sixteen patients were assigned to prednisone plus placebo, and 28 to prednisone plus IFX. At 22 weeks, the proportion of patients without relapse was similar between the IFX and placebo groups (43 versus 50% respectively, $P=0.65$). In addition, IFX did not increase the proportion of patients whose prednisone dose could be tapered to 10 mg/d without relapse (61% for IFX versus 75% for placebo, $P=0.31$). There was a trend for more infections in the IFX (71%) than in the placebo (56%) group. Consequently, the trial was stopped early. The investigators concluded that the addition of IFX to glucocorticoids neither improve the durability of remissions nor reduce cumulative glucocorticoids requirements in GCA. This data suggests that, similarly to what has been reported in PMR (Salvarani et al., 2007), TNF α inhibition is effective to some extent in long-standing, refractory GCA, but not (or only marginally) effective in new-onset GCA. The results of these studies led the European Vasculitis Study (EUVAS) group to not recommend the use of infliximab in GCA as an adjuvant therapy to glucocorticoids (Mukhtyar et al, 2009).

The first randomized trial showed etanercept as a useful steroid-sparing agent in refractory GCA (Martinez-Taboada et al, 2008). Fifteen patients with biopsy-proven GCA, in remission with a stable dose of prednisone (median 15 mg daily) were included. Prednisone was tapered according to a predefined schedule allowing for dose adjustments in case of flares. Placebo or etanercept 25 mg were given subcutaneously twice weekly for 12 months followed by a 3-month observation period. Patients in the etanercept group discontinued more easily prednisone (although the difference did not reach significance) and the cumulative dose after 12 months of treatment was significantly lower. The number and severity of adverse events was similar in both groups. The results of this study thus appear to support the concept that TNF blockade with etanercept has a clinically relevant effect in suppressing disease activity in refractory GCA (Salvarani et al, 2008). It should be mentioned however that treatment arm only contained eight patients.

Interleukin-6 blockade with tocilizumab (a humanized anti-interleukin-6 receptor monoclonal antibody) seems to be a promising target for future randomized controlled trials; current reported uses are limited (Seitz et al, 2011). Other possible therapeutic agents include abatacept, a recombinant fusion protein that modulates CD28-mediated T-cell co-

stimulation, and rituximab, a B-cell depleting antibody. The last has been used in one patient with GCA, with resolution of arteritis at 4.5 months (Bhatia et al, 2005). However, this patient subsequently developed pneumonia that required mechanical ventilation.

4. Behçet's disease

4.1 Introduction

Behçet's disease is a chronic multisystemic vasculitis affecting small and large arterial and venous branches (Yazici et al, 2010). The condition presents a distinctive geographical pattern, with higher incidence rates in Turkey, other Mediterranean countries and Middle and Far East countries, following the ancient "silk route" until Japan. On the other hand, it is rare in Northern Europe and United States. Genetic and environmental factors have been proposed as responsible for this unique distribution, but not fully explaining those differences (Verity et al, 1999). HLA-B51 is the strongest genetic association, but only explains 20% of disease heritability and Japanese patients with Behçet's disease do not share this association. An environmental trigger might play a role on the onset of the disease; this is suggested by the fact that the incidence rate of Behçet's disease in Turkish people living in Germany is considerably lower compared to those living in Turkey (Zouboulis et al, 1997).

Though mucocutaneous features are the most frequent clinical involvement in Behçet's disease, some patients suffers from severe eye involvement (chronic posterior uveitis), arterial aneurisms and central nervous system disease, leading to significant morbidity and mortality. Male and young patients often have a more severe disease. Management is mainly symptomatic and empiric. Drugs commonly used are topical and systemic glucocorticoids, colchicine, azathioprine or thalidomide. Severe cases may require cyclosporin, cyclophosphamide and high doses of glucocorticoids. Functional visual loss due to Behçet's disease uveitis is seen in 10-15% of patients. Mortality of pulmonary artery aneurisms is about 50%. Central nervous system is associated to 30% rate of mortality (Saadoun et al, 2010). So despite the usual schemes of management, there is ongoing morbidity and mortality in patients with Behçet's disease. Further more effective and less harmful agents are awaited, and biological agents might be this desired option; efficacy and safety data will be reviewed in this section.

4.2 TNF blockade

Tumour necrosis factor (TNF) inhibitors are the most widely used biological agents in Behçet's disease. Beside clinical, there are experimental data supporting this use: First, Behçet's disease was found to be mediated by cytokines derived from Th1 lymphocytes, including TNF (Gul, 2001). Second, patients with active disease showed an increased TNF expression (Yamashita et al, 1997; Mege et al, 1993). And third, TNF levels, both in sera and in aqueous humour, are increased in Behçet's disease (Evereklioglu et al, 2002; Chronopoulou et al, 2001).

Anti-TNF agents have been essentially tried in patients with refractory features of the disease. Case reports and retrospective case series were the initial data, but later prospective controlled studies have been reported. Generally, anti-TNF agents are recommended for patients with active disease which is refractory to conventional treatments (Sfikakis et al, 2007). But evidence level is not equal for each Behçet's feature, so we will separately review the most common or troublesome manifestations of the disease, regarding data about efficacy and safety of the anti-TNF agents.

4.2.1 Mucocutaneous and joint disease

The mainstay manifestation of Behçet's disease is the recurrent oral ulceration. It is the usual onset feature, is present in virtually all patients and is the required criteria for the diagnosis of the disease (International Study Group for Behçet's Disease, 1990). Other skin manifestations are genital ulcers (scrotum, major and minor labia), papulo-pustular acne-like lesions, subcutaneous nodules in lower limbs (resembling those of erythema nodosum), skin ulcers, pyoderma gangrenosum or palpable purpura. Oral and genital ulcers are typically mildly painful and completely heal after 1-3 weeks, but larger ones can leave a scar. The management usually includes topical glucocorticoids, colchicine or thalidomide.

Patients with Behçet's disease often present with arthritis, typically symmetrical or asymmetrical non-erosive oligoarthritis. Commonly affects the knees, wrists, ankles or elbows. Sometimes arthritis develops in a monoarticular or polyarticular pattern. Erosive arthritis is rare and later studies have found no association with axial involvement.

Skin and joint involvement is often mild and easily controlled. But these features might be very distressing with a significant physical and psychological burden. Occasionally some patients present with a persistent and severe condition, refractory to conventional treatments. There are some reports about using anti-TNF drugs in this small group of patients. In 2001, first case reports were published. Goossens et al reported a patient with mouth, anus, prepuce and left foot ulcers, refractory to conventional treatment, who achieved a sustained remission after two infusions of infliximab 10mg/kg. A 65 year-old woman, with history of 10 years of persistent orogenital ulcers despite several treatments (glucocorticoids, colchicine, thalidomide, azathioprine, cyclosporin and dapsone), successfully responded to infliximab (5mg/kg) three infusions (0, 2 and 6 weeks) (Robertson & Hickling, 2001). Other cases of refractory Behçet's skin involvement controlled with anti-TNF have been reported (Haugeberg et al, 2004; Almozni & Ben-Chetrit, 2007).

In 2005, a double-blind, placebo-controlled trial evaluating etanercept in Behçet's disease was published (Melikoglu et al, 2005). The aim of the authors was to evaluate the effect of etanercept in pathergy and monosodium urate (MSU) reactions, and in minor Behçet's features (patients with severe manifestations were excluded). Pathergy reaction consists in the development of a papule or pustule 48 hours after an intradermal needle prick. MSU reaction is the persistence of erythema 48 hours after an intradermal inoculation of MSU crystals. Both reactions demonstrate skin hypersensitivity and are highly specific for Behçet's disease (Gillhar et al, 1989). Enrolled patients randomised to receive etanercept (25mg twice a week) or placebo. After 4 weeks of treatment and 3 months of follow-up, patients in etanercept showed lower rates of oral ulcers, subcutaneous nodules and papulo-pustular lesions, but differences disappeared after discontinuation of the drug. Inflammatory markers also decreased. Genital ulcers and arthritis showed no benefits with etanercept. Interestingly, no effect on pathergy and MSU reaction was found. Treatment was safe and well-tolerated, with no significant adverse events. Despite some bias (small size, short-term follow-up, etc.), this was the first and successful controlled study with anti-TNF drugs in Behçet's disease, focused on its skin and joint manifestations.

4.2.2 Eye disease

More than 50% of patients with Behçet's disease will present with eye involvement (Yacici et al, 2010). This may occur at every point on the course of the disease, but in male and younger patients tends to develop in first 3 years after diagnosis, leading to a worse prognosis. Behçet's eye disease is a chronic, relapsing bilateral non-granulomatous

panuveitis, affecting both anterior and posterior poles of the ocular globe. Retinal occlusive vasculitis is often seen; conjunctivitis is rare. The disease runs with recurrent severe attacks, followed by spontaneous remissions. Though not associated to mortality, uveitis is one of the leading causes of morbidity in Behçet's disease. About 20-30 years ago the rate of blindness due to uveitis was higher than 75% of patients. Fortunately, better schemes of management and higher level of awareness made this outcome decrease, but still 10-15% of patients will develop functional visual loss (Kural-Seyahi et al, 2003). Loss of sight is due to permanent damage of intraocular structures by recurrent inflammatory attacks, atrophy of the optic nerve, secondary glaucoma or cataracts.

The management of patients with Behçet's eye disease should achieve rapid resolution of intraocular inflammation, prevent further attacks and preserve vision. Rapid control of inflammation is highly imperative in acute posterior uveitis (anterior pole inflammation usually is not severe and is well controlled with topical treatment). Glucocorticoids, azathioprine and cyclosporin are generally used, even in combination for refractory cases. However, despite these drugs, some patients will persist with recurrent flares leading to visual loss. In this subgroup of patients, monoclonal anti-TNF agent infliximab showed promising results in single reports and case series. In five patients with recurrent panuveitis, a single infusion of infliximab achieved a rapid remission in 24 hours and complete resolution in following 7 days (Sfikakis et al, 2001). Muñoz-Fernandez et al (2001) reported a successful outcome with infliximab 5mg/kg on a patient with sight-threatening panuveitis: inflammatory signs resolved and visual acuity significantly improved after three infusions. Another patient with severe neuroretinitis, oral and genital ulcers, arthritis, erythema nodosum and superficial thrombophlebitis, was treated with infliximab 5mg/kg at 0, 2, 4 and 8 weeks scheme. All symptoms significantly improved after first infusion, achieving remission with the second one (Triolo et al, 2002).

In 2005, a prospective evaluation of infliximab in Behçet's uveitis was published (Tugal-Tutkun et al, 2005). Thirteen male patients with recurrent posterior uveitis refractory to combination of cyclosporin, azathioprine and prednisolone were enrolled. Cyclosporin was discontinued. The authors used infliximab at 5mg/kg dose, administered at weeks 0, 2, 6 and 14 weeks. During the infusion period, lower incidence of eye flares were noted compared to pre-enrolment period, achieving 4 of them (30.8%) remission. No extraocular features of the disease occurred during this period and prednisolone dose reduced. Interestingly, the effect of infliximab got lost in the observation period (between weeks 23 and 54): there was no significant difference with the previous-treatment, and only 1 patient remained attack-free. Safety profile was acceptable, with no severe events. Since then, other prospective uncontrolled trials have been reported. Tognon et al (2007) tried infliximab in 7 patients with sight-threatening uveitis refractory to several immunosuppressive agents, with excellent results: intensity and number of relapses decreased, and visual acuity improved in 30% of eyes while in the rest remained stable. Extraocular manifestation controlled as well. No safety problems were noted. Niccoli et al (2007) assessed the efficacy of infliximab 5mg/kg (9 infusions) plus prednisolone 1mg/kg over a long-term follow-up (24 months) in 12 consecutive patients with refractory posterior uveitis. A rapid response was noted after first infusion. At 12 months, 75% of the patients achieved a complete remission with no relapses detected, and at 24 months 78% of them still remained in remission. Treatment was well tolerated with no significant adverse events.

There are no prospective controlled trials evaluating infliximab in Behçet's uveitis. But two reports retrospectively evaluated infliximab against conventional immunosuppressive

therapy (Tabbara & Al-Hemidan, 2008; Yamada et al, 2010). Both studies showed excellent results in the group of patients treated with infliximab, with significantly lower number of acute flares. Visual acuity improved in both groups, but only in the study by Tabbara median values were significantly higher with infliximab. It is noteworthy that more severe adverse events were noted in patients treated with conventional agents. An arguable bias for these studies is that treatment groups are not comparable – patients treated with infliximab present a more aggressive uveitis, refractory to high immunosuppression; but the fact that infliximab succeed, even better than previous agents, is an encouraging data. Infliximab is nowadays recommended for acute flares of posterior uveitis with significant reduction of visual acuity; when remission is achieved, infliximab may be switched to immunosuppressive drugs, as cyclosporin or azathioprine, with low-dose oral glucocorticoids (Sfikakis et al, 2007). As known from rheumatoid arthritis, long-term use of infliximab may lead to the development of resistances (Ito et al, 2010), as it is a chimeric, not fully humanised monoclonal antibody.

Evidence of efficacy with etanercept in Behçet's eye disease is lacking – there are scant reports and, as previously commented, in controlled trial by Melikoglu (2005) patients with active eye disease were not enrolled – so this drug cannot be recommended. Adalimumab seems to be effective in refractory Behçet's uveitis, but data only come from case reports and retrospective series (Mushtaq et al, 2007; Bawazeer & Raffa, 2010; Takase K et al, 2011), so further research is needed.

4.2.3 Gastrointestinal disease

Gastrointestinal involvement is one of the most frequent features in patients with Behçet's disease from Japan, Taiwan and Northern Europe – ranges from 30% to 50% – while the frequency in Turkey and Western Asia is low – about 5% (Ebert, 2009; Yacizi et al, 2010). Beside mouth ulcers, Behçet's disease predominantly affects small and large bowel, especially around ileocecal region. Esophageal, gastric or rectal involvement is rare. Type of intestinal involvement depends on subjacent vasculitis: small vessel vasculitis leads to mucosal inflammation and aphthous ulcers, meanwhile large vessel vasculitis associates with ischemia and infarction. Abdominal pain is the most common complaint; others are bloody stools, persistent diarrhoea or unexplained weight loss. The disease is often mild, but some patients complicates with perforation, mesenteric ischemia or major gastrointestinal bleeding. Gastrointestinal involvement typically associates with cutaneous papulo-pustular lesions and pyoderma gangrenosum.

As well as other Behçet's features, intestinal disease runs in an unpredictable course with flares and remissions. Recurrences after treatment are frequent, even after surgery, especially on the anastomotic site (Ha HK et al, 1998). In two case series from France (Saadoun et al, 2010) and Turkey (Kural-Seyahi et al, 2003) no patients died due to intestinal involvement, but in French series pancreatitis was the cause of death in one patient. Behçet's bowel disease management is similar to other features of the condition, where glucocorticoids and colchicine for mild disease and azathioprine or cyclosporin for severe disease are commonly used. Thalidomide and mesalazine could act as glucocorticoids-dose sparing agents. Anti-TNF agents have been used, but data mainly come from case reports (Hassard et al, 2001). Iwata et al (2009) tried infliximab in 10 patients with active entero-Behçet's disease refractory to conventional immunosuppressive agents or with contraindications against its use. All patients showed a rapid improvement in the intestinal manifestations, achieving remission 5 out 10 patients at 6 months, and 9 out 10 at 12 months.

Extraintestinal features of the disease improved as well and no severe adverse events were detected. Infliximab was used at dosage of 3mg/kg, but one patient required an increase to 5mg/kg due to a suspected recurrence. In another case series (Naganuma et al, 2008) 6 patients with fulminant intestinal disease were treated with infliximab with successful outcome, getting 5 of the six patients on remission. Despite limitation by lacking of controlled trials, current evidence supports the use of infliximab in refractory, severe cases of Behçet's intestinal disease. There is no data about etanercept or adalimumab, so formal recommendations cannot be done.

4.2.4 Central nervous system disease

Neurological involvement in Behçet's disease widely ranges between series, from 1.3% to 59%, with an average of about 10% of patients (Al-Araji & Kidd, 2009), usually developing a few years after the diagnosis of the disease. Men have two-three times higher risk of development compared to women. The condition specifically affects to central nervous system (CNS); peripheral involvement is uncertain. Though infrequent, it is often included in differential diagnosis in demyelinating and inflammatory CNS disorders. CNS-Behçet's disease presents with two different forms, rarely both in a same patient. First, parenchymal CNS disease is a subacute meningoencephalitis mainly located to brainstem, basal ganglia, thalamus and white matter. Hemispheres, spinal cord and other parts of CNS might be affected as well, but more common as a diffuse rather than focal involvement. And second, vessels, especially veins, are affected in non-parenchymal CNS-Behçet's disease, leading to cranial venous thrombosis and intracranial hypertension. Strokes due to arterial involvement are seldom seen. Patients complain of nonspecific symptoms (headache, malaise, fatigue, fever, etc.) and signs and symptoms derived from the area of CNS affected. A silent form has been described in asymptomatic patients but with detectable signs on the neurological examination.

Neuro-Behçet's disease is one of the most serious causes of morbidity and mortality in Behçet's. In spite of around a third of patients will present single episodes, another third will suffer further relapses and the other third a persistent, progressive involvement with aggravating neurological function (Akman-Demir et al, 1999). And how rapid the treatment is initiated probably will influence in further prognosis. Prospective controlled trials in Neuro-Behçet's disease are lacking, so treatment schemes are largely empirical. Intravenous methylprednisolone, followed by tapering prednisolone, is the first line agent after diagnosis. Initiation of an immunosuppressive agent (i.e. azathioprine, methotrexate or mycophenolate mofetil) depends on severity, previous episodes and response to glucocorticoids.

As well as in other less common Behçet's features, no adequate controlled studies have evaluated the role of anti-TNF agents in neuro-Behçet's. But results from case series are very promising. Pipitone et al (2008) retrospectively reviewed 8 patients with parenchymal neuro-Behçet's disease treated with infliximab. Dosage of 5 mg/kg was used in all patients, and adjunct drugs varied. Neurological involvement was refractory to immunosuppressive agents or developed while this treatment was being used due to other features of the disease. All 8 patients successfully responded to treatment, with rapid and marked improvement of symptoms. In one patient infliximab lost his efficacy after 5 years, with recurrence of symptoms, but improved again after initiating etanercept. No safety problems were reported. Other series (Kikuchi et al, 2008) also showed good results with infliximab 5mg/kg in 5 patients with progressive neuro-Behçet's disease refractory to glucocorticoids

and methotrexate. Infliximab was added to former treatment scheme. Interestingly, the authors found marked reduction of interleukin-6 levels on cerebrospinal fluid after initiating the drug, meanwhile TNF α levels remained unchanged. One patient developed a suspected *Pneumocystis jiroveci* pneumonia during the treatment, responding to cotrimoxazole. In summary, further controlled trials are highly desirable, but we consider that anti-TNF agents should be tried in cases with refractory neurological Behçet's disease.

4.2.5 Vascular disease

Vascular involvement in Behçet's disease affects venous and arterial systems, both with an inflammatory basis (Yacizi et al, 2010). Approximately, one third of patients will present venous thrombosis on deep or superficial systems, typically on their lower limbs. Interestingly, pulmonary embolisms are very rare. Venous thrombosis can develop in other body locations, as suprahepatic veins - leading to Budd-Chiari syndrome (Seyahi et al, 2007) - or intracranial venous sinuses, as previously commented. Arterial involvement is less frequent (<5%), but associated with poorer outcomes. Inflammatory pseudoaneurisms form in abdominal aorta, carotid, femoral or pulmonary arteries. If left untreated, mortality of pulmonary artery aneurisms is about 50% (Hamuryudan et al, 1994). Due to the inflammatory basis and the very low rate of embolism, not anticoagulation but immunosuppression is the mainstay of the management of Behçet's vascular disease, though controlled studies are lacking. Glucocorticoids and azathioprine or methotrexate may be used for venous thrombosis, but arterial involvement requires high-dose endovenous methylprednisolone and cyclophosphamide. The experience with anti-TNF agents lies on reported cases of refractory, life-threatening vascular involvement (Lee et al, 2010; Baki et al, 2006), with successful outcomes. No increased risk of atherosclerosis has been found in Behçet's disease.

4.3 Other biological agents

Rituximab, a chimeric monoclonal antibody against CD20 surface marker of B-cells, is widely used in other systemic autoimmune disorders, as rheumatoid arthritis, systemic lupus erythematosus or ANCA-associated vasculitis. Rituximab has been used in Behçet's disease as well. In 2008, Sadreddini et al communicated a patient with a severe retinal vasculitis refractory to azathioprine who developed hypersensitivity to etanercept. In this patient, rituximab (1gr, 2 infusions 2 weeks apart) improved the inflammatory signs and visual acuity in 6 weeks after the infusion. Recently, a pilot study evaluating rituximab in Behçet's eye disease has been published (Davatchi et al, 2010). Twenty patients with Behçet's uveitis and partial or absent response to cytotoxic agents were enrolled and randomised to receive rituximab (1gr, 2 infusions 2 weeks apart, plus weekly methotrexate and oral prednisolone) or an aggressive cytotoxic regime with cyclophosphamide, azathioprine and oral prednisolone. The author used the change in Total Adjusted Disease Activity Index (TADAI), a combination of different parameters of eye examination, as an outcome measure. TADAI and every single measure improved in both groups, but the difference between groups was not significant. Serious adverse events were detected in rituximab group - pneumonia in one patient and a severe infusion reaction in another. Though rituximab was as effective as cytotoxic schemes in Behçet's uveitis, further studies are needed.

As well as TNF α , interleukin-1 β and other pro-inflammatory cytokines levels are elevated in sera of patients with active Behçet's disease (Duzgun et al, 2005). Furthermore, an increase in interleukin-1 receptor antagonist, one of the natural immunomodulating molecules of this

cytokine, has been reported after controlling the disease (Benezra et al, 1997). In our search, we found an only report about using interleukin-1 β antagonist anakinra in patients with Behçet's disease: Botsios et al [2008] communicated an excellent response to anakinra in a 75 year-old woman whose disease was previously refractory to several immunosuppressive agents and partially responded to infliximab. Further studies are clearly needed to establish formal recommendations.

The anti-interleukin 2 receptor CD25 monoclonal antibody daclizumab was tested in a prospective placebo-controlled trial in Behçet's uveitis (Buggage et al, 2007). Patients in both groups continued to receive their previous immunosuppressive agents, and endovenous infusions of daclizumab 1mg/kg or placebo was added every two weeks for six weeks (4-dose induction), then once every four weeks for a minimum of 24 months following randomization. Ocular attacks continued to happen in both groups, but rate was even higher in patients on daclizumab arm. No safety problems were reported. Daclizumab is not recommended for the management of Behçet's disease.

Auto-reactive T lymphocytes may have a role in pathogenesis of Behçet's disease, explaining the successful response to calcineurin inhibitors (as cyclosporin) seen in this disease. In 2003, a series with patients with Behçet's disease treated with the anti-CD52 humanised monoclonal antibody alemtuzumab (CAMPATH-1H) was published (Lockwood et al, 2003). Patients with different active disease features were enrolled, being thirteen of them refractory to immunosuppressive agents. After a course of 5 daily infusions of alemtuzumab (total 134mg), eight patients achieved complete remission and seven patients showed a partial remission after 3 months of follow-up. Seven patients required further immunosuppressive agents to control the disease. No serious adverse events were detected. No controlled group was used in this study, but T-cells might be a new promising target for the management of Behçet's disease.

5. Mixed cryoglobulinemic vasculitis

Mixed cryoglobulinemic vasculitis (MC) is a small-vessel vasculitis characterised by the proliferation of B-cell clones producing pathogenic IgM with rheumatoid factor activity. More than 80% of MC vasculitis cases are attributable to hepatitis C viral (HCV) infection. Patients whose manifestations are not controlled by standard therapy, could be candidates for new biological therapy.

Rituximab is a chimeric murine/human anti-CD20 monoclonal antibody that binds to the B cell surface antigen CD20, resulting in selective depletion of peripheral B cells which can last for 6 months or longer. In order to analyse the efficacy and tolerance of rituximab treatment in patients with MC vasculitis, Cacoub et al performed a systematic review (Cacoub et al., 2008), which founded 13 manuscripts that reported on a total number of 57 cases of MC secondary to hepatitis C virus (HCV) infection (43 patients, 75.4%) or essential mixed cryoglobulinemia (14 patients, 24.6%). There were two large uncontrolled series of 20 (Sansonne et al, 2003) and 15 (Zaja et al, 2003) patients, and two smaller series of 6 (Roccatello et al, 2004) and 5 (Quartuccio et al, 2006) patients. All other publications reported either single or two case reports. Most patients (48 out of 57) received four weekly consecutive intravenous infusions of 375 mg/m² of rituximab for either unresponsiveness or intolerance to previous treatments (n=52). The duration of follow-up after rituximab therapy was 9.7 months. Partial or complete remissions were observed in 80% of patients with skin involvement, 79% of patients with arthralgias, 93% of patients with neuropathy,

and 83% of patients with glomerulonephritis. A relapse of MC was noted in 14 out of 36 (39%) patients after a mean of 6.7 months; eight of these patients went into complete remission after a second course of rituximab. A relatively small number of side effects were reported. The authors concluded that rituximab therapy for patients with MC vasculitis, either HCV induced or essential, shows a great efficacy on the main vasculitis signs in the majority of reported patients. A relapse of cryoglobulinemia vasculitis was frequently noted. About 30% of MC patients undergo active disease despite treatment with rituximab or antiviral therapy alone. So the combination of rituximab with Peg-IFN α -ribavirin appears logical. The long-term follow-up of a cohort of patients with HCV-related vasculitis treated with rituximab with or without PEGylated interferon alfa-2b (PEG-IFN alfa-2b) plus ribavirin has been reported (Terrier et al., 2009). Patients received rituximab 375 mg/m² and 40mg of intravenous methylprednisolone weekly for 4 weeks, followed by 1 year of therapy with PEG-IFN alfa-2b and ribavirin. The study group comprised 32 HCV RNA-positive patients with HCV-related vasculitis: 20 patients were treated with rituximab plus PEG-IFN alfa-2b and 12 antiviral-intolerant patients were treated with rituximab alone. Of the 20 patients with combined-treatment, 9 had not previously received antiviral treatment, while 11 were resistant to or had relapsed after combination antiviral therapy: all of them were previously enrolled in a 16-patient study (Saadoun et al, 2008), the 5 remaining patients in that study died - 1 patient - or were lost to follow-up - four patients. Complete remission was achieved in 80% of patients with combined-treatment, and partial remission in 15% of cases. A complete or partial immunologic response was observed in 67 and 33% of patients, respectively. The 12 patients who received rituximab alone because of intolerance of antiviral treatments experience complete or partial clinical response in 58 and 9% of patients respectively. Relapses were recorded in 22% of patients after a mean follow-up period of 23 \pm 12 months and these relapses were associated with loss of virologic control in all patients and with B cell recovery in 78% of cases.

6. References

- Airo P, Antonioli CM, Vianelli M, Toniati P (2002). Antitumour necrosis factor treatment with infliximab in a case of giant cell arteritis resistant to steroid and immunosuppressive drugs. *Rheumatology (Oxford)* 41:347-349.
- Akman-Demir G, Serdaroglu P, Tasçi B (1999). Clinical patterns of neurological involvement in Behçet's disease: evaluation of 200 patients. The Neuro-Behçet Study Group. *Brain* 122: 2171-82.
- Al-Araji A, Kidd DP (2009). Neuro-Behçet's disease: epidemiology, clinical characteristics, and management. *Lancet Neurol* 8(2):192-204.
- Al-Bishri J, le Riche N, Pope JE (2005). Refractory polyarteritis nodosa successfully treated with infliximab. *J Rheumatol* 32(7):1371-3.
- Almozni G, Ben-Chetrit E (2007). Infliximab for the treatment of resistant oral ulcers in Behçet's disease: a case report and review of the literature. *Clin Exp Rheumatol* 25(4 Suppl 45):S99-102.
- Andonopoulos AP, Meimaris N, Daoussis D, Bounas A, Giannopoulos G (2003). Experience with infliximab (anti-TNF alpha monoclonal antibody) as monotherapy for giant cell arteritis. *Ann Rheum Dis* 62:1116.
- Arbach O, Gross WL, Gause A (2002). Treatment of refractory Churg-Strauss-Syndrome (CSS) by TNF-alpha blockade. *Immunobiology*; 206(5):496-501.

- Baki K, Villiger PM, Jenni D, Meyer T, Beer JH (2006). Behcet's disease with life-threatening haemoptoe and pulmonary aneurysms: complete remission after infliximab treatment. *Ann Rheum Dis* 65(11):1531-2.
- Bawazeer A, Raffa LH (2010). Clinical experience with adalimumab in the treatment of ocular Behçet disease. *Ocul Immunol Inflamm* 18(3):226-32.
- Benezra D, Maftzir G, Barak V (1997). Blood serum interleukin-1 receptor antagonist in pars planitis and ocular Behçet disease. *Am J Ophthalmol* 123(5):593-8.
- Bhatia A, Ell PJ, Edwards JC (2005). Anti-CD20 monoclonal antibody (rituximab) as an adjunct in the treatment of giant cell arteritis. *Ann Rheum Dis* 64(7): 1099-100.
- Booth A, Harper L, Hammad T, Bacon P, Griffith M, Levy J et al (2004). Prospective study of TNFalpha blockade with infliximab in anti-neutrophil cytoplasmic antibody-associated systemic vasculitis. *J Am Soc Nephrol*; 15(3):717-21.
- Botsios C, Sfriso P, Furlan A, Punzi L, Dinarello CA (2008). Resistant Behçet disease responsive to anakinra. *Ann Intern Med* 149(4):284-6.
- Buggage RR, Levy-Clarke G, Sen HN, Ursea R, Srivastava SK, Suhler EB et al (2007). A double-masked, randomized study to investigate the safety and efficacy of daclizumab to treat the ocular complications related to Behçet's disease. *Ocul Immunol Inflamm* 15(2):63-70.
- Cacoub P, Delluc A, Saadoun D, Landau DA, Sene D (2008). Anti-CD20 monoclonal antibody (rituximab) treatment for cryoglobulinemic vasculitis: where do we stand? *Ann Rheum Dis* 67:283-287.
- Cantini F, Niccoli L, Salvarani C, Padula A, Olivieri I (2001). Treatment of longstanding active giant cell arteritis with infliximab: report of four cases. *Arthritis Rheum* 44 (12): 2933-5.
- Chronopoulou H, Tzavara V, Oikonomopoulos N et al (2001). High levels of TNF-a in the in the aqueous humor in patients suffering from Adamantiades-Behçet's disease: preliminary results. *Invest Ophthalmol Vis Sci* 42 (suppl 4):S708.
- Chung SA, Seo P (2009). Advances in the use of biologic agents for the treatment of systemic vasculitis. *Current Opinion in Rheumatology*; 21:3-9.
- Csernok E, Trabandt A, Müller A, Wang GC, Moosig F, Paulsen J et al (1999). Cytokine profiles in Wegener's granulomatosis: predominance of type 1 (Th1) in the granulomatous inflammation. *Arthritis Rheum* 42(4):742-50.
- Davatchi F, Shams H, Rezaipoor M, Sadeghi-Abdollahi B, Shahram F, Nadji A et al (2010). Rituximab in intractable ocular lesions of Behcet's disease; randomized single-blind control study (pilot study). *Int J Rheum Dis* 13(3):246-52.
- Deguchi Y, Shibata N, Kishimoto S (1990). Enhanced expression of the tumor necrosis factor/cachectin gene in peripheral blood mononuclear cells from patients with systemic vasculitis. *Clin Exp Immunol* 81:311-4.
- Della Rossa A, Tavoni A, Merlini G, Baldini C, Sebastiani M, Lombardi M et al (2005). Two Takayasu arteritis patients successfully treated with infliximab: a potential disease-modifying agent? *Rheumatology (Oxford)* 44: 1074.
- Düzgün N, Ayaşlıoğlu E, Tutkak H, Aydintuğ OT (2005). Cytokine inhibitors: soluble tumor necrosis factor receptor 1 and interleukin-1 receptor antagonist in Behçet's disease. *Rheumatol Int* 25(1):1-5.
- Ebert EC (2009). Gastrointestinal manifestations of Behçet's disease. *Dig Dis Sci* 54(2):201-7.

- Evereklioglu C, Er H, Turkoz Y, Cekmen M (2002). Serum levels of TNF- α , sIL-2R, IL-6, and IL-8 are increased and associated with elevated lipid peroxidation in patients with Behçet's disease. *Mediators Inflamm* 11:87-93.
- Ferraro AJ, Smith SW, Neil D, Savage CO (2008). Relapsed Wegener's granulomatosis after rituximab therapy--B cells are present in new pathological lesions despite persistent 'depletion' of peripheral blood. *Nephrol Dial Transplant* 23(9):3030-2.
- Gilhar A, Winterstein G, Turani H, Landau J, Etzioni A (1989). Skin hyperreactivity response (pathergy) in Behçet's disease. *J Am Acad Dermatol* 21(3 Pt 1):547-52.
- Giscombe R, Wang X, Huang D, Lefvert AK (2002). Coding sequence 1 and promoter single nucleotide polymorphisms in the CTLA-4 gene in Wegener's granulomatosis. *J Rheumatol* 29(5):950-3.
- Goossens PH, Verburg RJ, Breedveld FC (2001). Remission of Behçet's syndrome with tumour necrosis factor alpha blocking therapy. *Ann Rheum Dis* 60(6):637.
- Gul A (2001). Behçet's disease: an update on the pathogenesis. *Clin Exp Rheumatol* 19 (suppl 24):S6-12.
- Ha HK, Lee HJ, Yang SK, Ki WW, Yoon KH, Shin YM et al (1998) Intestinal Behcet syndrome: CT features of patients with and patients without complications. *Radiology* 209(2):449-454.
- Hagen EC, de Keizer RJ, Andrassy K, van Boven WP, Bruijn JA, van Es LA, et al (1995). Compassionate treatment of Wegener's granulomatosis with rabbit anti-thymocyte globulin. *Clin Nephrol* 43:351-9.
- Hamuryudan V, Yurdakul S, Moral F, Numan F, Tüzün H, Tüzüner N et al (1994). Pulmonary arterial aneurysms in Behçet's syndrome: a report of 24 cases. *Br J Rheumatol* 33(1):48-51.
- Hassard PV, Binder SW, Nelson V, Vasiliauskas EA (2001). Anti-tumor necrosis factor monoclonal antibody therapy for gastrointestinal Behçet's disease: a case report. *Gastroenterology* 120(4):995-9.
- Haugeberg G, Velken M, Johnsen V (2004). Successful treatment of genital ulcers with infliximab in Behcet's disease. *Ann Rheum Dis* 63(6):744-5.
- Hoffman G, Kerr G, Leavitt R, Hallahan C, Lebovics R, Travis W et al (1992). Wegener's granulomatosis: an analysis of 158 patients. *Ann Intern Med*; 116:488-98.
- Hoffman GS, Merkel PA, Brasington RD, Lenschow DJ, Liang P (2004). Anti-tumor necrosis factor therapy in patients with difficult to treat Takayasu arteritis. *Arthritis Rheum* 50:2296.
- Hoffman GS, Cid MC, Rendt-Zagar KE, Merkel PA, Weyand CM, Stone JH et al; Infliximab-GCA Study Group (2007). Infliximab for maintenance of glucocorticosteroid-induced remission of giant cell arteritis: a randomized trial. *Ann Intern Med* 146 (9):621-30.
- Huang D, Giscombe R, Zhou Y, Lefvert AK (2000). Polymorphisms in CTLA-4 but not tumor necrosis factor-alpha or interleukin 1beta genes are associated with Wegener's granulomatosis. *J Rheumatol* 27(2):397-401.
- International Study Group for Behçet's Disease (1990). Criteria for diagnosis of Behçet disease. *Lancet* 335: 1078-1080.
- Ito T, Sonoda KH, Hijioka K, Fujimoto T, Ishibashi T (2010). Acquired resistance to infliximab against uveitis due to Behçet's disease after one year of administration. *Jpn J Ophthalmol* 54(5):502-4.

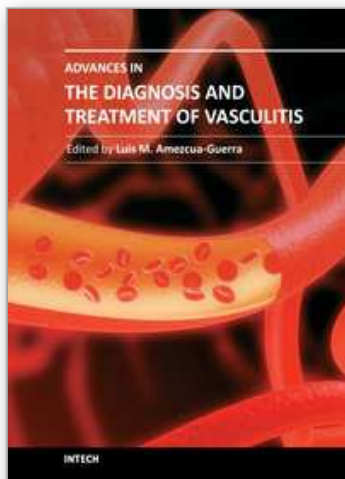
- Iwata S, Saito K, Yamaoka K, Tsujimura S, Nawata M, Suzuki K et al (2009). Effects of anti-TNF-alpha antibody infliximab in refractory entero-Behtcet's disease. *Rheumatology (Oxford)* 48(8):1012-3.
- Jennette JC, Falk RJ, Andrassy K, Bacon PA, Churg J, Gross WL et al (1994). Nomenclature of systemic vasculitides. Proposal of an international consensus conference. *Arthritis Rheum* 37(2):187-92.
- Jolly M, Curran JJ (2005). Infliximab-responsive uveitis and vasculitis in a patient with Takayasu arteritis. *J Clin Rheumatol* 11:213-215.
- Jones RB, Ferraro AJ, Chaudhry AN, Brogan P, Salama AD, Smith KG et al (2009). A multicenter survey of rituximab therapy for refractory antineutrophil cytoplasmic antibody-associated vasculitis. *Arthritis Rheum* 60(7):2156-68.
- Jones RB, Tervaert JW, Hauser T, Luqmani R, Morgan MD, Peh CA et al; European Vasculitis Study Group (2010). Rituximab versus cyclophosphamide in ANCA-associated renal vasculitis. *N Engl J Med* 363(3):211-20.
- Karageorgaki ZT, Mavragani CP, Papathanasiou MA, Skopouli FN (2007). Infliximab in Takayasu arteritis: a safe alternative? *Clin Rheumatol* 26:984-987
- Kaushik VV, Reddy HV, Bucknall RC (2006). Successful use of rituximab in a patient with recalcitrant Churg-Strauss syndrome. *Ann Rheum Dis* 65(8):1116-7.
- Keogh KA, Ytterberg SR, Fervenza FC, Carlson KA, Schroeder DR, Specks U (2006). Rituximab for refractory Wegener's granulomatosis: report of a prospective, open-label pilot trial. *Am J Respir Crit Care Med* 173(2):180-7.
- Kerr GS, Hallahan CW, Giordano J, Leavitt RY, Fauci AS, Rottem M et al (1994). Takayasu arteritis. *Ann Intern Med* 120:919-29.
- Kikuchi H, Aramaki K, Hirohata S (2008). Effect of infliximab in progressive neuro-Behtcet's syndrome. *J Neurol Sci* 272(1-2):99-105.
- Koukoulaki M, Smith KG, Jayne DR (2006). Rituximab in Churg-Strauss syndrome. *Ann Rheum Dis* 65(4):557-9.
- Kural-Seyahi E, Fresko I, Seyahi N, Ozyazgan Y, Mat C, Hamuryudan V et al (2003). The long-term mortality and morbidity of Behtcet syndrome: a 2-decade outcome survey of 387 patients followed at a dedicated center. *Medicine (Baltimore)* 82(1):60-76.
- Lamprecht P, Voswinkel J, Lilienthal T, Nolle B, Heller M, Gross WL et al (2002). Effectiveness of TNF-alpha blockade with infliximab in refractory Wegener's granulomatosis. *Rheumatology (Oxford)* 41(11):1303-7.
- Laurino S, Chaudhry A, Booth A, Conte G, Jayne D (2010). Prospective study of TNFalpha blockade with adalimumab in ANCA-associated systemic vasculitis with renal involvement. *Nephrol Dial Transplant* 25(10):3307-14.
- Lee SW, Lee SY, Kim KN, Jung JK, Chung WT (2010). Adalimumab treatment for life threatening pulmonary artery aneurysm in Behtcet disease: a case report. *Clin Rheumatol* 29(1):91-3.
- Little MA, Nightingale P, Verburgh CA, Hauser T, De Groot K, Savage C et al; European Vasculitis Study (EUVAS) Group (2010). Early mortality in systemic vasculitis: relative contribution of adverse events and active vasculitis. *Ann Rheum Dis* 69(6):1036-43.
- Lockwood CM, Hale G, Waldman H, Jayne DR (2003). Remission induction in Behtcet's disease following lymphocyte depletion by the anti-CD52 antibody CAMPATH 1-H. *Rheumatology (Oxford)* 42(12):1539-44.

- Ludviksson B, Sneller M, Chua K, Talar-Williams C, Langford C, Ehrhardt R et al (1998). Active Wegener's granulomatosis is associated with HLA-DR+ CD4+ T cells exhibiting an unbalanced Th1-type T cell cytokine pattern: reversal with IL-10. *J Immunol* 160:3602-9.
- Lukas R, Keller F (1998). Anti-thymocyte globulin therapy in a patient with pANCA vasculitis and crescentic glomerulonephritis. *Nephron* 78:231.
- Maksimowicz-McKinnon K, Clark TM, Hoffmann GS (2007). Limitations of therapy and a guarded prognosis in an American cohort of Takayasu Arteritis patients. *Arthritis Rheum* 56(3): 1000-7.
- Maksimowicz-McKinnon K, Clark TM, Hoffman GS (2009). Takayasu arteritis and giant cell arteritis: a spectrum within the same disease? *Medicine (Baltimore)* 88(4):221-6.
- Martinez-Taboada VM, Rodriguez-Valverde V, Carreno L, López-Longo J, Figueroa M, Belzunegui J et al (2008). A double-blind placebo controlled trial of etanercept in patients with giant cell arteritis and corticosteroid side effects. *Ann Rheum Dis* 67:625-630.
- Mege JL, Dilsen N, Sanguedolce V, Gul A, Bongrand P, Roux H et al (1993). Overproduction of monocyte-derive TNF- α , IL-6, IL-8 and increased neutrophil superoxide generation in Behçet's disease. A comparative study with familial Mediterranean fever and healthy subjects. *J Rheumatol* 20:1544-9.
- Melikoglu M, Fresko I, Mat C, Ozyazgan Y, Gogus F, Yurdakul S et al (2005). Short-term trial of etanercept in Behçet's disease: a double blind, placebo controlled study. *J Rheumatol* 32(1):98-105.
- Molloy ES, Langford CA, Clark TM, Gota CE, Hoffman GS. (2008). Antitumour necrosis factor therapy in patients with refractory Takayasu's arteritis: long-term follow-up. *Ann Rheum Dis* 67:1567-1569.
- Mukhtyar C, Guillevin L, Cid MC, Dasgupta B, de Groot K, Gross W et al; European Vasculitis Study Group (2009). EULAR recommendations for the management of large vessel vasculitis. *Ann Rheum Dis* 68(3):318-23.
- Muñoz-Fernández S, Hidalgo V, Fernández-Melón J, Schlincker A, Martín-Mola E (2001). Effect of infliximab on threatening panuveitis in Behçet's disease. *Lancet* 358(9293):1644.
- Mushtaq B, Saeed T, Situnayake RD, Murray PI (2007). Adalimumab for sight-threatening uveitis in Behçet's disease. *Eye (Lond)* 21(6):824-5.
- Naganuma M, Sakuraba A, Hisamatsu T, Ochiai H, Hasegawa H, Ogata H et al (2008). Efficacy of infliximab for induction and maintenance of remission in intestinal Behçet's disease. *Inflamm Bowel Dis* 14(9):1259-64.
- Nakahama H, Yokokawa T, Okada M, Miyazaki M, Imai N, Kubori S et al (1993). Distinct responses of interleukin-6 and other laboratory parameters to treatment in a patient with Wegener's granulomatosis. *Intern Med* 32(2):189-92.
- Nassonov E, Samsonov M, Tilz G, Beketova T, Semenkova E, Baranov A et al (1997). Serum concentrations of neopterin, soluble interleukin 2 receptor, and soluble tumor necrosis factor receptor in Wegener's granulomatosis. *J Rheumatol* 24:666-70.
- Niccoli L, Nannini C, Benucci M, Chindamo D, Cassarà E, Salvarani C et al (2007). Long-term efficacy of infliximab in refractory posterior uveitis of Behçet's disease: a 24-month follow-up study. *Rheumatology (Oxford)* 46(7):1161-4.

- Nogueira E, Hamour S, Sawant D, Henderson S, Mansfield N, Chavele KM et al (2010). Serum IL-17 and IL-23 levels and autoantigen-specific Th17 cells are elevated in patients with ANCA-associated vasculitis. *Nephrol Dial Transplant* 25(7):2209-17.
- Noronha I, Kruger C, Andrassy K, Ritz E, Waldherr R (1993). In situ production of TNF-alpha, IL-1 beta and IL-2R in ANCA-positive glomerulonephritis. *Kidney Int* 43:682-92.
- Omdal R, Wildhagen K, Hansen T, Gunnarsson R, Kristoffersen G (2005). Anti-CD20 therapy of treatment-resistant Wegener's granulomatosis: favourable but temporary response. *Scand J Rheumatol* 34(3):229-32.
- Park MC, Lee SW, Park YB, Chung NS, Lee SK (2005). Clinical characteristics and outcomes of Takayasu's arteritis: analysis of 108 patients using standardized criteria for diagnosis, activity assessment, and angiographic classification. *Scand J Rheumatol* 34:284-92.
- Pepper RJ, Fabre MA, Pavesio C, Gaskin G, Jones RB, Jayne D et al (2008). Rituximab is effective in the treatment of refractory Churg-Strauss syndrome and is associated with diminished T-cell interleukin-5 production. *Rheumatology (Oxford)* 47(7):1104-5.
- Pipitone N, Olivieri I, Padula A, D'angelo S, Nigro A, Zuccoli G et al (2008). Infliximab for the treatment of Neuro-Behçet's disease: a case series and review of the literature. *Arthritis Rheum* 59(2):285-90.
- Popa ER, Stegeman CA, Bos NA, Kallenberg CG, Tervaert JW (1999). Differential B- and T-cell activation in Wegener's granulomatosis. *J Allergy Clin Immunol* 103(5 Pt 1):885-94.
- Popa ER, Franssen CF, Limburg PC, Huitema MG, Kallenberg CG, Tervaert JW (2002). In vitro cytokine production and proliferation of T cells from patients with anti-proteinase 3- and antimyeloperoxidase-associated vasculitis, in response to proteinase 3 and myeloperoxidase. *Arthritis Rheum* 46(7):1894-904.
- Quartuccio L, Soardo G, Romano G, Zaja F, Scott CA, De Marchi G et al (2006). Rituximab treatment for glomerulonephritis in HCV-associated mixed cryoglobulinaemia: efficacy and safety in the absence of steroids. *Rheumatology (Oxford)* 45:842.
- Robertson LP, Hickling P (2001). Treatment of recalcitrant orogenital ulceration of Behçet's syndrome with infliximab. *Rheumatology (Oxford)* 40(4):473-4.
- Roccatello D, Baldovino S, Rossi D, Mansouri M, Naretto C, Gennaro M et al (2004). Longterm effects of anti-CD20 monoclonal antibody treatment of cryoglobulinaemic glomerulonephritis. *Nephrol Dial Transplant* 19:3054-61.
- Saadoun D, Resche-Rigon M, Sene D, Perard L, Karras A, Cacoub P (2008). Rituximab combined with peginterferon-ribavirin in refractory HCV-associated cryoglobulinemia vasculitis. *Ann Rheum Dis* 67:1431-1436.
- Saadoun D, Wechsler B, Desseaux K, Le Thi Huong D, Amoura Z, Resche-Rigon M et al (2010). Mortality in Behçet's disease. *Arthritis Rheum* 62(9):2806-12.
- Sadreddini S, Noshad H, Molaeefard M, Noshad R (2008). Treatment of retinal vasculitis in Behçet's disease with rituximab. *Mod Rheumatol* 18(3):306-8.
- Salvarani C, Macchioni P, Manzini C, Paolazzi G, Trotta A, Manganelli P et al (2007). Infliximab plus prednisone or placebo plus prednisone for the initial treatment of polymyalgia rheumatica. *Ann Intern Med* 146:631-9.
- Salvarani C, Pipitone N, Boiardi L, Hunder GG (2008). Do we need treatment with tumour necrosis factor blockers for giant cell arteritis? *Ann Rheum Dis* 67(5):577-9.
- Sánchez-Cano D, Callejas-Rubio JL, Ortego-Centeno N (2008). Effect of rituximab on refractory Wegener granulomatosis with predominant granulomatous disease. *J Clin Rheumatol* 14(2):92-3.

- Sansonno D, De Re V, Lauletta G, Tucci FA, Boiocchi M, Dammacco F (2003). Monoclonal antibody treatment of mixed cryoglobulinemia resistant to interferon alpha with an anti-CD20. *Blood* 101:3818–3826.
- Seitz M, Reichenbach S, Bonel HM, Adler S, Wermelinger F, Villiger PM (2011). Rapid induction of remission in large vessel vasculitis by IL-6 blockade. A case series. *Swiss Med Wkly* 141:w13156.
- Seo P, Stone JH (2004). Large-vessel vasculitis. *Arthritis Rheum* 51(1):128-39.
- Seo P, Specks U, Keogh KA (2008). Efficacy of rituximab in limited Wegener's granulomatosis with refractory granulomatous manifestations. *J Rheumatol* 35(10):2017-23.
- Seyahi E, Hamuryudan V, Hatemi G, Melikoglu M, Celik S, Fresko I et al (2007). Infliximab in the treatment of hepatic vein thrombosis (Budd-Chiari syndrome) in three patients with Behcet's syndrome. *Rheumatology (Oxford)* 46(7):1213-4.
- Sfikakis PP, Theodossiadis PG, Katsiari CG, Kaklamanis P, Markomichelakis NN (2001). Effect of infliximab on sight-threatening panuveitis in Behçet's disease. *Lancet* 358(9278):295-6.
- Sfikakis PP, Markomichelakis N, Alpsoy E, Assaad-Khalil S, Bodaghi B, Gul A et al (2007). Anti-TNF therapy in the management of Behcet's disease--review and basis for recommendations. *Rheumatology (Oxford)* 46(5):736-41.
- Specks U, Fervenza FC, McDonald TJ, Hogan MC (2001). Response of Wegener's granulomatosis to anti-CD20 chimeric monoclonal antibody therapy. *Arthritis Rheum* 44(12):2836-40.
- Stasi R, Stipa E, Del Poeta G, Amadori S, Newland AC, Provan D (2006). Long-term observation of patients with anti-neutrophil cytoplasmic antibody-associated vasculitis treated with rituximab. *Rheumatology (Oxford)* 45(11):1432-6.
- Steiner K, Moosig F, Csernok E, Selleng K, Gross WL, Fleischer B et al (2001). Increased expression of CTLA-4 (CD152) by T and B lymphocytes in Wegener's granulomatosis. *Clin Exp Immunol* 126(1):143-50.
- Stone JH, Uhlfelder ML, Hellmann DB, Crook S, Bedocs NM, Hoffman GS (2001). Etanercept combined with conventional treatment in Wegener's granulomatosis: a six-month open-label trial to evaluate safety. *Arthritis Rheum* 44(5):1149-54.
- Stone JH, Merkel PA, Spiera R, Seo P, Langford CA, Hoffman GS et al; RAVE-ITN Research Group (2010). Rituximab versus cyclophosphamide for ANCA-associated vasculitis. *N Engl J Med* 363(3):221-32.
- Tabbara KF, Al-Hemidan AI (2008). Infliximab effects compared to conventional therapy in the management of retinal vasculitis in Behçet disease. *Am J Ophthalmol* 146(6):845-50.e1.
- Takase K, Ohno S, Ideguchi H, Uchio E, Takeno M, Ishigatsubo Y (2011). Successful switching to adalimumab in an infliximab-allergic patient with severe Behçet disease-related uveitis. *Rheumatol Int* 31(2):243-5.
- Tamura N, Matsudaira R, Hirashima M, Ikeda M, Tajima M, Nawata M et al (2007). Two cases of refractory Wegener's granulomatosis successfully treated with rituximab. *Intern Med* 46(7):409-14.
- Tanaka F, Kawakami A, Iwanaga N, Tamai M, Izumi Y, Aratake K et al (2006). Infliximab is effective for Takayasu arteritis refractory to glucocorticoid and methotrexate. *Intern Med* 45:313–316.

- Tato F, Rieger J, Hoffmann U (2005). Refractory Takayasu's arteritis successfully treated with the human, monoclonal antitumor necrosis factor antibody adalimumab. *Int Angiol* 24:304-307.
- Tektonidou MG, Skopouli FN (2006). Sustained 3-year remission after Rituximab treatment in a patient with refractory Wegener's granulomatosis. *Clin Exp Rheumatol* 24(2 Suppl 41):S103.
- Terrier B, Saadoun D, Sene D, Sellam J, Pérard L, Coppéré B et al (2009). Efficacy and tolerability of rituximab with or without PEGylated interferon alfa-2b plus ribavirin in severe hepatitis C virus-related vasculitis: a long-term followup study of thirty-two patients. *Arthritis Rheum* 60: 2531-40.
- Tognon S, Graziani G, Marcolongo R (2007). Anti-TNF-alpha therapy in seven patients with Behcet's uveitis: advantages and controversial aspects. *Ann N Y Acad Sci* 1110:474-84.
- Triolo G, Vadalà M, Accardo-Palumbo A, Ferrante A, Ciccia F, Giardina E et al (2002). Anti-tumour necrosis factor monoclonal antibody treatment for ocular Behçet's disease. *Ann Rheum Dis* 61(6):560-1.
- Tugal-Tutkun I, Mudun A, Urgancioglu M, Kamali S, Kasapoglu E, Inanc M et al (2005). Efficacy of infliximab in the treatment of uveitis that is resistant to treatment with the combination of azathioprine, cyclosporine, and corticosteroids in Behçet's disease: an open-label trial. *Arthritis Rheum* 52(8):2478-84.
- Vanoli M, Daina E, Salvarani C, Sabbadini MG, Rossi C, Bacchiani G et al (2005). Takayasu's arteritis: a study of 104 Italian patients. *Arthritis Rheum* 53(1): 100-7.
- Verity DH, Marr JE, Ohno S, Wallace GR, Stanford MR (1999). Behçet's disease, the Silk Road and HLA-B51: historical and geographical perspectives. *Tissue Antigens* 54(3):213-20.
- Walsh M, Chaudhry A, Jayne D (2008). Long-term follow up of relapsing/refractory anti-neutrophil cytoplasm antibody associated vasculitis treated with the lymphocyte depleting antibody alemtuzumab (CAMPATH-1H). *Ann Rheum Dis* 67: 1322-1327.
- Wegener's Granulomatosis Etanercept Trial (WGET) Research Group (2005). Etanercept plus standard therapy for Wegener's granulomatosis. *N Engl J Med* 352(4):351-61.
- Yamada Y, Sugita S, Tanaka H, Kamoi K, Kawaguchi T, Mochizuki M (2010). Comparison of infliximab versus ciclosporin during the initial 6-month treatment period in Behçet disease. *Br J Ophthalmol* 94(3):284-8.
- Yamashita N, Kaneoka H, Kaneko S, Takeno M, Oneda K, Koizumi H et al (1997). Role of gamma-delta T lymphocytes in the development of Behçet's disease. *Clin Exp Immunol* 107:241-7.
- Yazici Y, Yurdakul S, Yazici H (2010). Behçet's syndrome. *Curr Rheumatol Rep* 12(6):429-35.
- Zaja F, De Vita S, Mazzaro C, Sacco S, Damiani D, De Marchi G et al (2003). Efficacy and safety of rituximab in type II mixed cryoglobulinemia. *Blood* 101:3827-3834.
- Zhou Y, Huang D, Paris PL, Sauter CS, Prock KA, Hoffman GS (2004). An analysis of CTLA-4 and proinflammatory cytokine genes in Wegener's granulomatosis. *Arthritis Rheum* 50(8):2645-50.
- Zouboulis CC, Kötter I, Djawari D, Kirch W, Kohl PK, Ochsendorf FR et al (1997). Epidemiological features of Adamantiades-Behçet's disease in Germany and in Europe. *Yonsei Med J* 38(6):411-22.



Advances in the Diagnosis and Treatment of Vasculitis

Edited by Dr. Luis M Amezcua-Guerra

ISBN 978-953-307-786-4

Hard cover, 366 pages

Publisher InTech

Published online 09, November, 2011

Published in print edition November, 2011

This book represents the culmination of the efforts of a group of outstanding experts in vasculitis from all over the world, who have endeavored to draw themselves into this volume by keeping both the text and the accompanying figures and tables lucid and memorable. The book provides practical information about the screening approach to vasculitis by laboratory analysis, histopathology and advanced image techniques, current standard treatment along with new and more specific interventions including biologic agents, reparative surgery and experimental therapies, as well as miscellaneous issues such as the extra temporal manifestations of "temporal arteritis" or the diffuse alveolar hemorrhage syndrome. The editor and each of the authors invite you to share this journey by one of the most exciting fields of the medicine, the world of Vasculitis.

How to reference

In order to correctly reference this scholarly work, feel free to copy and paste the following:

Paloma Vela and Mariano Andrés (2011). The Role of Biological Therapies in the Management of Systemic Vasculitis, *Advances in the Diagnosis and Treatment of Vasculitis*, Dr. Luis M Amezcua-Guerra (Ed.), ISBN: 978-953-307-786-4, InTech, Available from: <http://www.intechopen.com/books/advances-in-the-diagnosis-and-treatment-of-vasculitis/the-role-of-biological-therapies-in-the-management-of-systemic-vasculitis>

INTECH
open science | open minds

InTech Europe

University Campus STeP Ri
Slavka Krautzeka 83/A
51000 Rijeka, Croatia
Phone: +385 (51) 770 447
Fax: +385 (51) 686 166
www.intechopen.com

InTech China

Unit 405, Office Block, Hotel Equatorial Shanghai
No.65, Yan An Road (West), Shanghai, 200040, China
中国上海市延安西路65号上海国际贵都大饭店办公楼405单元
Phone: +86-21-62489820
Fax: +86-21-62489821

© 2011 The Author(s). Licensee IntechOpen. This is an open access article distributed under the terms of the [Creative Commons Attribution 3.0 License](https://creativecommons.org/licenses/by/3.0/), which permits unrestricted use, distribution, and reproduction in any medium, provided the original work is properly cited.

IntechOpen

IntechOpen