

We are IntechOpen, the world's leading publisher of Open Access books Built by scientists, for scientists

6,900

Open access books available

186,000

International authors and editors

200M

Downloads

Our authors are among the

154

Countries delivered to

TOP 1%

most cited scientists

12.2%

Contributors from top 500 universities



WEB OF SCIENCE™

Selection of our books indexed in the Book Citation Index
in Web of Science™ Core Collection (BKCI)

Interested in publishing with us?
Contact book.department@intechopen.com

Numbers displayed above are based on latest data collected.
For more information visit www.intechopen.com



Biologic Agents for the Treatment of Systemic Vasculitis

P. Sfriso and F. Schiavon

*Division of Rheumatology, University of Padova,
Italy*

1. Introduction

Vasculitis is a disorders characterized by the presence of blood vessel inflammation. It can appear in a wide range of forms: the inflammation can occur in association with an underlying disease or exposure, called secondary vasculitis, or in primary vasculitis blood inflammation occurs for unknown reasons. When this disorder strikes it can lead to blood vessels stenosis/occlusion, causing organ ischemia, or thinning of the blood vessels that results in the formation of aneurysm or hemorrhages. Every size of blood vessels can be affected by the inflammatory process and the size of the vessels involved influences the clinical manifestations. Several classification systems have been proposed but the classification that has been unanimously adopted by the scientific community is the Chapel Hill Nomenclature that classifies vasculitis into small, medium or large vessels vasculitis depending on the calibre of the vessels involved. (Jennette et al, 1994) These three types of vasculitis differ in severity, ranging from a self-limited illness to conditions that can be life-threatening in the absence of prompt treatment. Therapy originally involved treating the patients with glucocorticoids but subsequently, with the improvement of our knowledge about vasculitis pathogenesis, immunosuppressive agents such as methotrexate, azathioprine and cyclophosphamide have been introduced. These drugs have vastly improved the previously dismal prognosis associated with many of these diseases, they are widely used and represent the standard against which newer therapies should be compared. Nevertheless despite this optimal standard therapy, the diseases does not got into full remission for 20 to 30% of patients and in addition, a smaller proportion of patients develop a more severe disease (Hiemstra & Jayne, 2009) Five years post diagnosis, 50% of patients will relapse in spite of having undergone at least 2 years of therapy (Booth el al, 2003) and approximately 25% will experience a refractory course manifested by incomplete disease control or frequent relapses despite remission-manteining therapy. Moreover the toxicity that is caused by the drugs causes severe side effects. For exaples, it has reported that during prolonged treatment with cyclophosphamide, infection and malignancy are the most cause of death in the first year (Bougarit el al, 2005).The toxicity of cyclophosphamide, particularly that associated with long term and repeat use of the agent, has emerged as the principle challenge in managing patients. To minimize the side effects, current approaches include initial use of cyclophosphamide to induce remission followed by use of less toxic immunosuppressive agents for mainteinance. Although this strategy has reduced the malignancy and infection risk, they remain present. High doses of glucocorticoids can also

contribute to severe infection. In the last 10 years important progress has been made on the pathogenesis of vasculitis and several factors have been identified as potential therapeutic targets. These include ANCA antibodies, whose pathogenic role in small vessel vasculitis has been demonstrated by evidence in vivo (Halbwachs-Mecarelli, 1995; Huugen, 2007; Kain, 2008; Little, 2005; Pfister, 2004; Xiao, 2002, 2005, 2007; Ruth, 2006) and in vitro tests (Kallemberg, 2008; Schreiber 2003; Van Rossum. 2004; Witko-Sarsat, 1999), tumor necrosis factor alpha (TNF α) (Huugen et al, 2005) interleukin 6 (IL-6) (Noris et al, 1999) and T and B lymphocytes (Walsh & Jayne 2007). Therefore, targeted therapies have been introduced in the treatment of vasculitis, in order to decrease treatment toxicity as well the propensity to relapse.

1.1 Role of TNF- α in the pathogenesis of vasculitis

TNF is the prototype of a gene superfamily that is important in regulating many biologic function. Science has identified approximately 40 members of the TNF superfamily and knowledges about their function is rapidly emerging. The identification of a TNF- α dependent cytokine cascade in the cultures of synovium present in the joint of patients with rheumatoid arthritis led to the discovery of the role of this cytokine in RA. The development of anti TNF- α therapies constitute still today a major advance in the treatment of RA. There is also evidence that TNF- α plays a role in glomerular inflammation, produced not only by infiltrating macrophages but also by several intrinsic renal cell types. The production of TNF has been demonstrated within glomeruli in both experimental and human glomerulonephritis including that associated with ANCA antibody (Noronha et al, 1993) and its role in the recruitment of leukocytes to inflammatory sites in rodent model of ANCA associated vasculitis (Feldmann & Pusey, 2006). In *vitro* studies suggest that the interaction of ANCA and TNF- α primed neutrophils results in the activation of neutrophils as well as degranulation, causing subsequent endothelial cell damage and amplification of the inflammatory process by means of further leukocytes recruitment (Gross, 2004). Moreover, animal models suggest that TNF- α plays a key role in granuloma formation (Noronha, 1993) and that anti TNF- α treatment attenuates manifestations in animal MPO-ANCA- induced glomerulonephritis (Huugen et al, 2005). TNF represented therefore a good therapeutic target and due to the success of blocking TNF in RA, this approach was also tested on vasculitis diseases.

Three agents directed against TNF are currently approved for the use: Infliximab, Etanercept and Adalimumab. Infliximab is a chimeric monoclonal antibody comprised of the human IgG1 constant region fused with the murine variable region recognized TNF. Adalimumab has a similar structure but is fully humanized. Infliximab and Adalimumab can bind to circulating and membrane bound TNF. Etanercept is a fusion protein composed of 2 extracellular p75 receptors domains linked by the Fc portion of human IgG1. Infliximab and Adalimumab can induce apoptosis in cell expressing TNF, while Etanercept does not induced apoptosis in TNF-expressing cells.

1.2 B lymphocytes in the pathogenesis of vasculitis

The primary role of B cells in the pathogenesis of several autoimmune diseases has been demonstrated by the presence of autoantibodies in the patient's serum. B cells are the precursor of antibody-producing cells (plasma cells). In addition to producing ANCA these cells can contribute to the pathogenesis of Wegener's granulomatosis by instigating

costimulation and antigen presentation within granulomata (Voswinkel et al, 2008). B cells can interact on an antigen presenting cell (APC) to the T cells, secrete a variety of cytokines (e.g. IL-6, IL-10, TNF α), function as an (auto-) antigen-presenting cell themselves and carry out a role of regulatory cells (Pistoia, 1997; Harris, 2000; Serra, 2006). In Wegener's granulomatosis granulomas of the upper respiratory tract display features of lymphoid-like tissue neoformation and are infiltrated by cluster of B lymphocytes in vicinity to PR3 cells, dendritic cells and plasma cells. Moreover, antigen (PR3)-driven selection within the immunoglobulin's heavy chain gene repertoire in different granuloma tissues are found (Youinou, 2007) suggesting an initial selection and affinity maturation of B cells within granuloma. B cell activating factor (BAFF) is a central cytokine in B cell development and survival (Mackay et al, 2003) and is elevated in the serum of patients with Wegener's Granulomatosis (Bader, 201; Krumboltz, 2005). BAFF is secreted by activated neutrophils, which play a central role in the pathogenesis of Wegener's granulomatosis, (Scapini et al 2005) and in turn could drive B cell expansion and subsequent ANCA production. Therefore B cells represent an optimal target for biological drugs. Rituximab is a chimeric monoclonal antibody directed against the cell surface protein CD20. This antibody is comprised of the variable regions derived from a murine anti CD-20 antibody fused to human IgG constant regions (Grillo-Lopez et al, 2000). CD 20 is a highly specific surface antigen that is expressed on pre-B and mature B cells but is not found on precursors or plasma cells. The Fab region of Rituximab recognizes the four amino acid sequence on a large extra-cellular loop of the CD 20 molecules (Gurcan et al, 2009). The binding of Rituximab to CD 20 leads to significant depletion of peripheral B cells, inducing cell death. Although the mechanisms involved are not fully understood, (Reff et al, 1994) the experimental evidences demonstrated at least 3 different mechanisms:

Complement-dependent cytotoxicity (CDC), involving the complement protein C1q, with formation of pores in the cell membrane and cell lysis

Antibody dependent cellular cytotoxicity (ADCC) which leads to membrane damage and cell lysis via the recruitment of macrophages, natural killer and cytotoxic cells

Apoptosis by the direct cross linking of CD 20 on B cell (Mease, 2008) .

Rituximab was approved by FDA to use in the treatment of low grade Non Hodgkin Lymphoma in 1997 and in 2006 for the treatment of RA. Besides RA, growing experience with Rituximab therapy indicates that it may be effective in the treatment of other rheumatic diseases such as Sjogren syndrome, dermatomyositis-polymyositis, systemic lupus erythematosus and systemic vasculitis.

2. Large vessels vasculitis

2.1 Giant cells arteritis

Giant cell arteritis is a vasculitis of the large-vessel that occurs exclusively in patients over 50 years of age. Giant cell arteritis involves the aorta and external carotid arteries and their branches and produces intimal hyperplasia and luminal obstruction leading to ischemic manifestations. Visual loss can occur as a consequence of acute anterior ischemic optic neuritis. This represents the most severe complication. The pathophysiology of giant cell arteritis is still poorly understood but T-cells and dendritic cells play a pivotal role. Dendritic cells activate T-cells that produce TNF- α and other proinflammatory cytokines contributing to the activation of macrophages and further recruitment of T cells and macrophages in the inflammatory lesion (Ly et al, 2010). Moreover TNF- α is present in high

levels inside temporal artery lesions in patients with giant cell arteritis, particularly in correspondences to the granulomatous areas (Hernandez-Rodriguez et al, 2004). Small case series and case reports present evidence that infliximab could be used as a steroid sparing agent for giant cell arteritis (Airo 2002; Andronopoulos, 2003; Cantini, 2001). A randomized, placebo controlled, double-blind multicenter trial was conducted in 2007 to determine the efficacy of infliximab in treating giant cell arteritis. Forty-four patients with newly diagnosed of giant cell arteritis were randomly assigned to receive infliximab (5 mg/kg of body weight) or placebo in a 2:1 ratio, in addition to prednisone. Primary end points were the number of patients who did not relapse during a 22 week period nor suffered side effects. Secondary end points included time to first relapse, cumulative glucocorticoid dose and the number of patients who remained relapse-free even when the steroid dosage was tapered to 10 mg/day. Infliximab therapy did not increase the proportion of patients without relapse (43% vs 50% respectively $P = 0.65$), nor did it increase the proportion of patients whose glucocorticoid dosages were tapered to 10 mg/day without suffering a relapse (61% vs 75% respectively $P = 0.31$). The incidence of infection was 71% with infliximab and 56% with placebo (difference of 15%, 95% confidence interval (CI) 14-45% (Hoffman et al, 2007). The authors concluded that infliximab was unlikely to be effective in the treatment of giant cell arteritis. The data about the role that Etanercept and Adalimumab play in treating giant cell arteritis are inconclusive: A double blind placebo controlled trial was conducted in 2008 with Etanercept. Seventeen patients participated in the study. The primary outcome was that the patients were able to stop the corticosteroid therapy and still keep the disease under control for over one year. After 12 months 50% of the patients in the Etanercept group and 22,2% in the placebo group were able to keep the disease under control without corticosteroid therapy (p value not significant) (Martinez-Toboada et al, 2008). Adalimumab, a fully humanized monoclonal antibody directed against TNF, was successfully used only in one case of giant cell arteritis refractory to steroid therapy (Ahmed et al, 2007). There are also two isolated reports of new-onset giant cell arteritis in patients receiving etanercept and adalimumab associated with methotrexate for rheumatoid arthritis (Leydet-Quilici 2007; Seton, 2004). Finally a single report has described successful in treating giant cell arteritis with Rituximab combined with cyclophosphamide (Bhatia et al, 2005).

2.2 Takayasu's arteritis

Takayasu's arteritis is an idiopathic systemic granulomatosis disease of the large and medium-sized vessels that may lead to segmental stenosis, occlusion, dilatation and/or aneurysm formation in the aorta and/or its main branches. Coronary and pulmonary arteries may also be affected. Takayasu's arteritis is characterized by the formation of granuloma on vessel walls and several proinflammatory cytokines, including TNF are associated with the development of granuloma (Park et al, 20). It is therefore reasonable to consider that TNF inhibition might be useful in the therapy of Takayasu's arteritis. The first case series were conducted by Hoffman in 2004. Fifteen patients with active relapsing Takayasu's arteritis were selected. Seven received etanercept, (later the medication was changed to infliximab for 3 patients) and eight received infliximab. Ten of the 15 patients went into complete remission that was sustained for 1 to 3.3 years without steroid therapy. Four patients achieved partial remission with a reduction in the glucocorticoid therapy > 50%, whereas therapy failed for only 1 patient. For 9 of the 14 respondents, an increase in the anti TNF dosage (up to 10 mg/Kg for infliximab and 50 mg 2/weekly for etanercept) was required to sustain remission. Two relapse occurred during periods when the therapy was

interrupted (both with etanercept) but the patients re established full remission upon re introduction of the therapy. (Hoffman et al 2004). Since the first initial studies of the use of antiTNF therapy in the treatment of Takayasu's arteritis, the successful use of this therapy has been reported by multiple investigators (Calderon, 2010; Della Rossa, 2005; Jolly, 2005; Karageorgaki, 2007; Maffei, 2009; Tanaka, 2006; Tato, 2005). The largest sample of studies examined 25 patients with active relapsing Takayasu's arteritis treated with infliximab (21 pts) or etanercept (9 pts, later therapy was changed to infliximab for 5 pts) and followed them for a median of 28 months. Four of the 9 patients initially treated with etanercept enjoyed a complete remission and 2 experienced partial remission. Of the 6 patients who achieved remission 3 relapsed. Of the 21 patients treated with infliximab (including the 5 previously treated with etanercept) 12 achieved complete remission and 6 patients went into partial remission. Three patient discontinued infliximab; 12 of the remaining 18 patients relapsed and required treatment with a higher dose of infliximab administered at shorter intervals (Molloy et al, 2008). These studies suggest that anti TNF therapy may provide long term remission for patients with refractory Takayasu's arteritis and thus justify a randomized controlled clinical trial. Lastly it was also reported that treatment using Tocilizumab, a humanized anti interleukin-6-receptor antibody in a patient with refractory Takayasu's arteritis was successful (Nishimoto et al, 2008)

3. Medium vessel arteritis

3.1 Polyarteritis nodosa

Polyarteritis nodosa is a necrotizing vasculitis that affects small and medium-size arteries and affects patients of all ages. Standard treatment with corticosteroids and cyclophosphamide has dramatically improved the prognosis but medication induced morbidity is frequent. The successful use of anti TNF therapy in treating adult and childhood systemic or cutaneous PAN has been reported in several papers (Al-Bishri J et al, 2005; Brik R et al, 2007; de Kort AWK et al, 2006; Feinstein J et al, 2005; Garcia-Porrúa et al, 2003; Vega Gutierrez J et al, 2007; Wahezi DM et al, 2010; Wu K et al, 2006). The largest study sample was conducted over three years and examined 11 young patients treated with TNF α inhibitors, 8 with Infliximab, (2 later changed the therapy to Adalimumab and Rituximab) and 3 patients were treated with Etanercept. The dosage of Infliximab given to patients varied from 3 to 6 mg/Kg and a dose of 0.8 mg/Kg for Etanercept. Side effects appeared in three patients: a *staphylococcus epidermidis* sepsis and cerebral abscesses following Infliximab therapy and a bowel perforation a month after starting Etanercept. There was a significant reduction in the median daily prednisolone requirement and a reduction of ESR and PCR (Eleftheriou D et al, 2009). Therefore, biologic therapy represents an effective treatment option for patients with Polyarteritis nodosa-resistant vasculitis. Lastly, in 2008 a case of cutaneous corticosteroid and immunosuppressive-resistant Polyarteritis nodosa in a 47 year old man was successfully treated by Rituximab (Sonamoto K et al, 2008).

4. Small vessels arteritis

4.1 ANCA-associated vasculitis

The antineutrophil cytoplasmic antibody (ANCA) associated systemic vasculitis is a group of multisystemic diseases predominantly characterized by small vessel vasculitis and the occurrence of ANCA in most but not all cases. These diseases include Wegener's

granulomatosis, microscopic polyangiitis, renal-limited vasculitis and Churg-Strauss angiitis. Despite significant progress in managing these diseases there are no satisfactory treatment options for patients suffering either refractory or frequently relapsing disease. These patients moreover are a high risk of cumulative toxicity from the medications. Recent advances in biological therapy has helped to establish new options for patients that are resistant to conventional treatment

4.1.1 Anti TNF α inhibitors

Little is known regarding the efficacy of anti TNF therapy in treating microscopic polyangiitis and Churg-Strauss Syndrome (Arbach et al 2002, Josselin L et al 2008). A TNF blocker was tested specifically on patients with Wegener's granulomatosis. In the Wegener's granulomatosis etanercept trial (WGET), a multi-center, placebo controlled trial, 180 patients were randomized to receive adjunctive therapy with etanercept versus placebo, in addition to standard care immunosuppression (with cyclophosphamide or methotrexate). There were no differences in remission rates and time to remission at the end of follow-up (after 27 months) between the two groups (69.7 vs 75.3% $p=0.39$). In addition, there were no observed differences in the relative risk of disease flares up between the two groups ($p=0.54$). Six solid tumors developed in patients in the etanercept group, whereas none were observed in the placebo group ($p=0.01$) with a standardized incidence ratio (SIR) of 3.12 (95% CI 1.15-6.80) (Wegener's granulomatosis etanercept trial, 2005). Additional follow-up of 140 participants in the WGET showed that this increased risk of developing solid tumor malignancies in the etanercept group persisted 3.5 years following the conclusion of the study (SIR 4.4 $p=0.01$) (Chung S & Seo, 2009). A potential explanation of these surprising negative results might be that Etanercept is not effective in inflammatory granulomatosis diseases. In fact, Etanercept is not effective in treating Crohn disease and sarcoidosis which are both characterized by granulomatous inflammation (Sandborn et al, 2001). Four case series and a prospective open-label trial have been published describing the use of Infliximab in Wegener's granulomatosis (Table I). Infliximab use has been reported in 51 patients with Wegener's granulomatosis. All patients were treated with doses between 3 mg/Kg and 5 mg/Kg at a frequency of one to two monthly i.v injections. Except for 1 trial, all the patients continued standard therapy for systemic vasculitis. The Bartolucci group stopped all immunosuppressants (apart from steroids) when they commenced infliximab and the drugs were reintroduced on day 42. The cohort of patient participating in the study was mixed and included new cases, relapse and persistent disease cases. In the Booth's group, patients were divided into two groups, new patients and persistent disease patients. The patients with persistent disease who benefited from infliximab continued on the medication for a total of one year. All others, including all patients in the new arm received infliximab for only 10 weeks. In the other trials Infliximab was administered for three to six months. Forty-five out of 51 patients (88.23%) experienced remission, partial or complete. Relapse occurred in 7 patients (13.72%), 4 out of these 7 patients were still receiving anti TNF α blocker drugs. Side effects were reported in 9 patients (17.64%): 2 patients died one for diffuse pulmonary hemorrhage attributed to pulmonary vasculitis and the other from bronchopneumonia. However, these two patients had MPO-ANCA related renal vasculitis rather than Wegener's granulomatosis. Seven patients had severe infections, 1 suffering from *Haemophilis influenzae* pneumonia, 1 with recurrent *Klebsiella* urinary tract infections, 2 patients with recurrent *St. aureus* skin abscesses, 1 has an uncharacterized diarrheal illness and 1 had *Nocardia* endophthalmitis requiring enucleation of the eye. All the patients also

received prednisolone and immunosuppressive therapy (Bartolucci 2002; Booth 2002, 2004; Josselin, 2008; Lamprecht P 2002). These studies suggest that Infliximab, in conjunction with steroid and immunosuppressive agents, appears to be effective for inducing remission in ANCA associated vasculitis or in the treatment of refractory forms. Careful attention must be given concerning the increased risk of serious infection. Nevertheless the use of Infliximab in treating vasculitis must await until corroboration from larger controlled studies and should not be used as first line therapy, but after a review of the risk and benefits of the therapy, considered in the treatment of refractory disease.

4.1.2 Rituximab

Use of Rituximab in treating refractory or relapsing ANCA-associated vasculitis has been tested via case reports, case series and also prospective open-label trials, retrospective study and open label randomized trial. In case series study of refractory/relapsing Wegener’s granulomatosis patients, Rituximab therapy was introduced adjunct to ongoing therapy and within a 7 to 36 month follow-up, there a complete remission. Eight case series with 110 patients were reported (87 affected by WG, 14 affected by MPA, 5 by CSS and 4 by unclassified vasculitis). Ninety-five patients were ANCA PR3 or MPO positive (86,36%). The Rituximab regimen varied from 375 mg/m² i.v weekly x 4 weeks to 500 mg i.v weekly x 4 weeks to 1000 mg i.v given each 2 or 3 weeks or 2 infusions of 750 mg/m² given 2 weeks or 1 infusion of 3.2 gm). Tab 1

Study type	Study authors	N° patients	Rituximab regimen	Patients outcomes
8 case series	Omdal, Gottemborg, Keogh Eriksson, Tamura, Brihave, Jones	45	Mainly 375 mg/m ² Weekly x 4 weeks	CR= 30-100% PR= 10-30% R=10-60% (6-18 months)
4 prospective open label trials	Keogh, Aries, Stasi, Smith	38	Mainly 375 mg/m ² Weekly x 4 weeks With or without Immunosuppression	CR=25-100% PR=9-25% R=10-50% (9-24 months)
2 open label randomized trial	Jones, Stone	142	375 mg/m ² weekly X 4 weeks	CR= 63-91% R=3-6% (median 12 months)

CR= complete remission; PR= partial remission; R= relapse

Table 1. Rituximab use in ANCA associated vasculitis

Seventy-six out 110 patients went into full remission (69.09%), 18 patients went into partial remission (16,36%), and no response occurred for 4 patients (3,63%). Of the 76 patients who went into full remission, 38 of these (50%) experienced relapse, not always associated with ANCA positivity or a rise in ANCA levels. Fifty-seven serious side effects were observed

and 1 patient died for adenoviral pneumonitis; the lung infection developed after several immunosuppressive therapy were administered before Rituximab treatment and after the addition of anti TNF- α drug (Adalimumab). (Brihaye, 2007; Eriksson, 2005; Gottemberg, 2005, Keogh, 2005; Jones, 2009; Omdal, 2005 Seo, 2008; Tamura, 2006). In 2006, four prospective open-label trial were published. The treatment protocol included administering Rituximab in doses of 375 mg/m² i.v. every 4 weeks x 4 doses. In two of four trials, Rituximab was used alone without the introduction of other immunosuppressive drugs (Keogh et al, 2006, Stasi et al, 2006). Thirty out of 39 patients went into complete remission (76.92% of total patients), partial remission were observed in 3 of the 39 patients (7.69%) and complete failure of treatment was measured in 6 out of 31 (15.38%). Ten patients relapsed between 9 to 24 months and all of these were re-treated with rituximab resulting in a new sustained response in all the patients. (Aries, 2006; Keogh, 2006; Smith, 2006; Stasi, 2006). Circulating B-cells were monitored and it was noted that they rapidly became undetectable after the treatment. However, in the majority of patients, B-cells gradually returned after 6 to 9 months, although some patients maintained very low levels of the cells for a long time. A relationship between relapse and re-appearance of the B cell population has been put forth, but clinical data shows that relapses are not always associated with the return of circulating B cells and in turn, B-cell re-appearance is not always followed by a relapse. Finally, two pivotal studies, whose results have been recently published in NEJM, were carried out in order to determine the real efficacy of anti B-lymphocyte therapy compared with cyclophosphamide in the induction phase of treatment of ANCA-associated vasculitis. Jones et al reported on the results of a open-label, two group, parallel design, multi-center randomized trial of Rituximab versus Cyclophosphamide treatment involving 44 patients affected by ANCA-associated renal vasculitis. (RITUXIVAS). Patients who were randomly assigned to the Rituximab group also received at least two doses of intravenous cyclophosphamide at a dose of 15 mg per kilogram along with the first and the third Rituximab infusion and not receive azathioprine to maintain remission. Patients in the control group received a validated regimen of intravenous cyclophosphamide for 3 to 6 months followed by azathioprine. Sustained remission was achieved in 25 of 33 patients in the Rituximab group (76%) and 9 of 11 patients in the control group (82%). Six patients in the rituximab group and 1 patient in the control group died within the first 12 months. Three patients did not achieve a sustained remission. The median time it took for remission of symptoms was 90 days in the rituximab group and 94 days in the control group (P= 0.87). A total of 31 severe side effects occurred in 14 of the 33 patients in the Rituximab group (42%) and 12 severe side effects occurred in 4 of the 11 patients in the control group (36%). Incidence rates for severe side effects were 1.00 per patient-year in the Rituximab group (95% CI. 0.69 to 1.44) and 1.10 per patient-year in the control group (95% CI, 0.61 to 1.99 P=0.77). The frequency of infections was 36% in the Rituximab group and 27% in the control group (Jones et al, 2010). A second multi-center randomized, double blind trial of Rituximab treatment compared with cyclophosphamide was reported by Stone (RAVE). One hundred and ninety-seven ANCA-positive patients with Wegener's granulomatosis or micropolyangiitis were enrolled in the study. Patients assigned to the Rituximab group did not receive any cyclophosphamide treatment while patients in the control group received oral cyclophosphamide (2 mg per Kilogram of body weight adjusted for renal insufficiency). When they went into remission, usually between 3 to 6 months later, they were eligible to

switch from cyclophosphamide to azathioprine (2 mg per Kilogram per day). Sixty-three of the 99 patients in the Rituximab group (64%) and 52 the 98 patients in the control group (53%) achieved remission and stopped steroid therapy ($P=0.09$). Among patients with relapsing disease at baseline Rituximab was more efficacious than cyclophosphamide (respectively 67% and 42% achieved remission). Fourteen patients in the Rituximab group (14%) and 17 in the control group (17%) had side effects that lead to a discontinuation of the treatment. Two patients in the control group and 1 patient in the Rituximab group died. During the first 6 months of the trial, a malignant tumor was diagnosed in one patient in each group; but after 6 months 5 malignant tumour developed in the patients, four in the Rituximab group and one receiving cyclophosphamide treatment (Stone et al, 2010). Therefore similar conclusion are reached in the two studies. Both trial showed that rituximab was effective in inducing remission but unfortunately the rate of side effects was the same for the Rituximab and cyclophosphamide groups (RAVE trial). Similarly in the RITUXIVAS study, 6 of the 33 patients in the Rituximab group died as well as 2 of 11 patients in the control group. Moreover the RAVE trial also demonstrated an un-expected elevated number of malignant tumour appearing over a relatively short treatment period. Therefore Rituximab might be considered as an option for first-line therapy and the induction of remission of ANCA-associated vasculitis. It is still unclear if anti-B-cell therapy might alter the immunopathogenetic process, permitting the discontinuation or reduction of therapy (steroids and immunosuppressants) to maintain remission

5. Cryoglobulinemic vasculitis

Cryoglobulins are cold-precipitable monoclonal or polyclonal immunoglobulins that can occur in conjunction with a variety of other diseases, including plasmacell or lymphoid neoplasms, chronic infection and inflammatory disease. Three subtypes of cryoglobulins can be identified using immunochemical analysis. Type I cryoglobulins are single monoclonal immunoglobulins (most commonly monoclonal IgM) and are almost exclusively associated with malignant hematologic disorder. Type 2 cryoglobulins consist of polyclonal IgG with monoclonal IgM with rheumatoid factor activity. Type 3 are polyclonal IgG and polyclonal IgM with rheumatoid factor activity. Since the discovery of the hepatitis C virus (HCV) it has been demonstrated that the majority of cases of cryoglobulinemia are related to HCV infection (Cacoub & Saadoun, 2008). In mixed cryoglobulin HCV-related vasculitis, a combined therapy of interferon-alpha (IFN- α) and ribavirin provide the best opportunity for improvement but long term resolution of symptoms is limited to patients who have a sustained virologic response (Saadoun et al, 2008). In addition, the therapy is often not tolerated or contraindicated. Plasmapheresis is not applicable for long term management and immunosuppressant agents (Cyclophosphamide, Azathioprine, Methotrexate) have been used but, mostly type 2 cryoglobulinemia vasculitis treated with Rituximab. No randomized controlled trials have been carried out. Nine uncontrolled studies with patients samples ranging from 5 to 23 patients have been reported while the other patients came from case reports (Bryce, 2006; Cavallo, 2009; Quartuccio, 2006; Roccatello, 2008; Saadoun, 2008; Sansonno, 2003; Sene, 2009; Terrier, 2010; Visenti, 2007; Zaja, 2003). In most of the studies, Rituximab was administered at the dose of 375 mg/m² weekly for 4 weeks, sometimes followed by two extra infusion at 1 and 2 months, but also in higher amounts

(two 1,000 mg-Rituximab infusion at days 1 and 15) and a lower dose (250 mg/m² at days 1 and 8). As reported by Sen, the higher dose seems to be correlated with a higher risk of side effects. Three patients developed severe systemic reactions after the first infusion of 1,000 mg. Two patients developed a typical serum sickness syndrome with accompanying fever, arthralgia, purpura and increased of serum parameters of inflammation 7 and 9 days after the infusion. The final outcome was a spontaneous resolution in one patient and the other developed cardiac and kidney problems that required steroid treatment. In vitro immunochemical assays showed that Rituximab formed a complex with the cryoprecipitating IgMk that had rheumatoid factor activity and the in vitro addition of Rituximab to serum containig rheumatoid factor-positive IgMk tipe II mixed cryoglobulin was associated with visibly accelerated cryoprecipitation. The author suggested that Rituximab should be administrated with caution in patients with cryoglobulinemic type II vasculitis with high levels of cryoglobulins and low C4 levels and that the 375 mg protocol is preferred (Sene, 2009). The most reported clinical manifestation of vasculitis is neuropathy and skin involvement. A complete remission from symptoms was seen in 87 patients (53%); a total of 31 (18.90%) had partially responded to treatment and 20 (12.19%) did not respond to treatment at all. A significant reduction in levels of rheumatoid factor, cryoglobulins and IgM was reported after Rituximab therapy. Overall, 38 (23.17%) out of 164 patients treated with Rituximab reported side effects. In addition to serum sickness and severe flares of vasculitis, the other side effects reported included a thrombosis of the retinal artery, the development of cold agglutinin disease and serious infectious complications. After the treatment with Rituximab, death was reported in 9 cases, 3 from liver carcinoma, one patient died of cirrhosis, one had a vasculitis relapse, one died of multiple organ failure due to cold agglutinin disease, another patient died from *Cryptococcus neoformans* meningoencephalitis, one patient died of septic shock after an intestinal perforation and the last died of an unknown cause. Skin manifestations and arthralgias frequently responded well to treatment with Rituximab, whereas symptoms of neuropathy and renal involvement were more resistant to treatment. Clinical relapse occurred in 20% to 50% of the patients, 12 to 14 months following the Rituximab administration. Most of the patients responded well to a 2nd course of the drug therapy (Terrier et al, 2010). As demonstrated by Saadoun in a prospective cohort study of 38 patients who received a combination of Rituximab (375 mg/m²) once a week for 1 month, followed by Peg-IFN- α (180 μ g/week or 1.5 μ g/Kg/week) plus ribavirin (600-1200 mg) daily, as compared with 55 patients treated by Peg-IFN- α /ribavirin with the same modalities the combination of Rituximab plus Peg-interferon- α /ribavirin seems to be more effective than Peg-IFN/ribavirin in treating HCV-associated cryoglobulinemic vasculitis. Out of the entire patients population, a complete clinical response was achieved in 73.1% of patients, cryoglobulin clearance in 52.7% of patients and a sustained virologic response in 59.1% of patients. Compared with Peg-IFN- α /ribavirin Rituximab plus Peg-IFN- α /ribavirin-treated patients had a shorter clinical response time, better renal response rates and a higher rates of cryoglobulin clearance. Seventeen patients (18.3%) experienced relapse, including 10 patients treated with Peg-IFN- α /ribavirin and 7 with Rituximab with Peg-IFN- α /ribavirin. Treatment was well tolerated with 11% of patients (distributed equally between the two group) discontinuing therapy and no worsenig of HCV RNA under Rituximab was observed (Saadoun, et al, 2010) Finally the efficacy of Rituximab therapy in treating 19 patients with HCV-associated mixed

cryoglobulinemia and severe liver disease was reported. Fifteen of 19 patients had liver cirrhosis with ascitic decompensation in 6 cases. Rituximab was administered at a dose of 375 mg/m² body surface area once a week over a 1 month period. A complete relief from the symptoms of mixed cryoglobulinemia (purpura, arthralgia, leg ulcers, paresthesias) was observed in 12 patients and partial relief in 7 patients. Complete cryocrit negativization was observed in 9 patients, a cryocrit decrease greater than 50% was evaluated in 2 patients, and in 3 patients there was a decrease of cryocrit between 25% and 50%, whereas in 5 patients no consistent cryocrit reduction was shown. An improvement of hepatic function and an impressive reduction in the degree of ascites in patients with liver cirrhosis was observed in most patients with advanced disease. A transient increase of viremia was also observed (Petrarca et al, 2010). As a single agent, Rituximab seems to be a safe and effective therapy for treating patients with cryoglobulinemic vasculitis. However it is not a curative treatment. The combination therapy with Peg-IFN- α /ribavirin seems to be more effective than Peg-IFN- α /ribavirin since this combination synergizes the immunologic effect of antiviral therapy.

6. Behçet disease

Behçet disease is a multisystemic chronic-relapsing inflammatory disorders classified among the vasculitis that presents clinical features of mucocutaneous lesions and ocular, vascular, articular, gastrointestinal, urogenital, pulmonary and neurologic involvement. Some evidences suggests that TNF- α plays a critical role in the pathogenesis of the disease. In seven open label, prospective self controlled studies patients with ocular manifestations that were unresponsive to standard immunosuppressive treatment were given infliximab i.v. infusion. Infliximab was given alone or in addition to the previous treatment (mostly prednisone, azathioprine and cyclosporin) at a dose of 5 mg/Kg. Time of treatment varied: a single infusion (Skikakis et al, 2004) , 2 infusions (Al- Rayes et al, 2008), at time 0, 2 and 4 and then every 6-8 weeks (Tognon, et al, 2007) at time 0, 2, 6, 10 weeks (Ohno et al, 2004), 0, 2, 6, 14 weeks (Tugal-Tutkun et al 2005) , 0, 2, and 6 weeks and monthly for an additional 4-6 months and every 8 weeks thereafter (El-Asrar 2005; Accorinti, 2007) The follow-up period was from 1 month to 36 months. Complete remission of uveitis was achieved in 59 out of 78 patients (75.64%). Adalimumab it also reported to be an effective drug alternative that improved visual acuity in a case series of 11 male patients (Bawazeer & Raffa, 2010). In addition to the aforementioned studies, many small case series and case reports suggest that patients with mucocutaneous lesions, gastrointestinal symptoms and arthritis exhibit a rapid and sustained responses to infliximab therapy (Sfikakis et al, 2007). Recently a case series of 6 patients with intestinal involvement was reported by Naganuma. All patient were steroid-dependent and refractory to immunosuppressants. The drug infusion schedule was 5 mg/kg body weight at 0, 2 and 6 weeks and every 8 weeks thereafter. Four patients went into remission and all of the aforementioned maintained this state for up to 3 years. Two patients with ileal ulceration required surgery. Infliximab has also been utilized to treat parenchymal central nervous system involvement with a favorable outcome (Pipitone et al, 2008). The first controlled study of anti TNF- α treatment was conducted with etanercept. In a double-blind, placebo-controlled study of 40 male patients, the authors reported that etanercept, administered at a dose of 25 mg twice a week for 4 week is effective in

suppressing oral ulcers and nodular and papulopustular lesions. No differences was observed in regards to pathergy test, genital ulcers and arthritis (Melikoglu et al, 2005). A recent position paper concluded that infliximab is recommended as first line treatment option for patients with bilateral posterior uveitis or with unilateral involvement with visual acuity < 0.2 because the fast onset of response is critical in preventing fixed retinal lesions and permanent visual loss. In patients with SNC, intestinal, mucocutaneous manifestations or arthritis infliximab can be used as an add-on therapy for severe manifestations or refractory illness or used in treating patients that are intolerant to traditional immunosuppressive regimens (Sfikakis et al, 2007) Tab 2

Subset	TNF inhibitors type	Efficacy
Posterior segment Intraocular inflammation	Infliximab 5 mg/Kg Etanercept 25 mg x 2 weekly Adalimumab 40 mg every 2 weeks	+ + +
Mucocutaneous manifestations - Oral ulcers	Infliximab 3 or 5 mg/Kg Etanercept 25 mg x 2 weekly	+ +
- Genital ulcers	Infliximab 3 or 5 mg/Kg Etanercept 25 mg x 2 weekly	+ -
-Nodular lesions or psudofolliculitis	Infliximab 3 or 5 mg/Kg Etanercept 25 mg x 2 weekly	+ +
- Skin pathergy	Etanercept 25 mg x 2 weekly	-
Arthritis	Infliximab 3 or 5 mg/Kg Etanercept 25 mg x 2 weekly	+ +/-
Intestinal inflammation	Infliximab 5 mg/Kg	+
Parenchymal CNS involvement	Infliximab 5 mg/Kg	+
Major vessel involvement	Not enough data	

Table 2. Anti TNF agents in Behçet disease

7. Conclusion

The advent of biologic drug therapy to treat systemic vasculitis is the beginning of a new era in which highly toxic immunosuppressive therapy may be replaced by a more sophisticated and targeted approach. However, data from the national arthritis registries demonstrate a higher risk of opportunistic infections in patients treated with these biologic drugs. Moreover, we don't have experiences with the long term consequences of these agents, particularly about the increased risk of malignancy in patients affected by vasculitis. Given the rarity of these diseases, international collaboration will be crucial in defining the future role of these agents in the treatment of vasculitis..

8. References

- Accorinti M, Pirraglia MP, Paroli MP, Priori R, Conti F, Pivetti-Pezzi P. Infliximab treatment for ocular and extraocular manifestations of Behcet disease. *JPN. J. Ophthalmol.* 2007; 51: 191-96
- Ahmed MM, Mubashir E, Hayat S, Fowler M, Berney SM. Treatment of refractory temporal arteritis with adalimumab. *Clin Rheumatol.* 2007; 26: 1353-55
- Airo P, Antonioli CM, Vianelli M, Toniati P. Antitumor necrosis factor treatment with infliximab in a case of giant cell arteritis resistant to steroid and immunosuppressive drugs. *Rheumatology (Oxford)* 2002; 41: 347-49
- Al Bishri J, Le Riche N, Pope JE. Refractory polyarteritis nodosa successfully treated with infliximab. *J. Rheumatol* 2005; 32: 1371-3
- Al-Rayes H, Al-Swailem R, Al-Balawi M, Al-Dohayan N, Al-Zaidi S, Tariq M. Safety and efficacy of infliximab therapy in active Behcet's uveitis: an open-label trial. *Rheumatol. Int.* 2008; 29: 53-57
- Andronopoulos AP, Meimaris N, Daoussis D, Bounas A, Giannopoulos G. Experience with infliximab (anti TNF alpha monoclonal antibody) as monotherapy for giant cell arteritis. *Ann Rheum Dis* 2003; 62: 1116
- Arbach O, Gross WL, Gause A. Treatment of refractory Churg-Strauss Syndrome (CSS) by TNF alpha blockade. *Immunobiology* 2002; 206: 496-501
- Aries PM, Hellmich B, Voswinkel J, Both M, Nölle B, Holl-Ulrich K, Lamprecht P, Gross WL. Lack of efficacy of rituximab in Wegener's granulomatosis with refractory granulomatous manifestations. *Ann Rheum Dis.* 2006; 65: 853-8
- Bader L, Koldingsnes W, Nossent J. B-lymphocyte activating factor levels are increased in patients with Wegener's granulomatosis and inversely correlated with ANCA titer. *Clin Rheumatol* 2010; 29: 1031-35
- Bartolucci P, Ramoelina J, Cohen P, Mahr A, Godmer P, Le Hello C, Guillevin L. Efficacy of the anti TNF- α antibody infliximab against refractory systemic vasculitides: an open pilot study on 10 patients. *Rheumatology.* 2002; 41: 1126-1132
- Bawazeer A, Raffa LH. Clinical experience with adalimumab in the treatment of ocular Behcet disease. *Ocul. Immunol. Inflamm.* 2010; 18: 226-32
- Bhatia A, Eli PJ, Edwards JC. Anti CD-20 monoclonal antibody (rituximab) as an adjunct in the treatment of giant cell arteritis. *Ann Rheum Dis.* 2005; 64: 1099-1100
- Booth AD, Jefferson HJ, Ayliffe W, Andrews PA, Jayne DR. Safety and efficacy of TNF- α blockade in relapsing vasculitis. *Ann Rheum Dis.* 2002; 61: 559
- Booth AD, Almond MK, Burns A, Ellis P, Gaskin G, Neild GH, Plaisance M, Pusey CD, Jayne DR; Pan-Thames Renal Research Group. Outcome of ANCA-associated renal vasculitis: a 5-year retrospective study. *Am J Kidney Dis.* 2003 Apr;41(4):776-84.
- Booth A, Harper L, Hammad T, Bacon P, Griffith M, Levy J, Savage C, Pusey C, Jayne D. Prospective study of TNF- α blockade with infliximab in anti-neutrophil cytoplasmic antibody-associated systemic vasculitis. *J. AM. Soc. Nephrol.* 2004; 15: 717-12
- Bougarit A, Le Toumelin P, Pagnoux C, Cohen P, Mahr A, Le Guern V, Mouthon L, Guillevin L. Deaths occurring during the first year after treatment onset for Polyarteritis Nodosa, Microscopic Polyangiitis and Churg- Strauss Syndrome. *Medicine* 2005; 84: 323-30

- Brihaye B, Aouba A, Pagnoux C, Cohen P, Lacassin F, Guillevin L. Adjunction of rituximab to steroids and immunosuppressants for refractory/relapsing Wegener's granulomatosis: a study on 8 patients. *Clin Exp. Rheumatol.* 2007; 25 (1 suppl 44): S23-S27
- Brik R, Gepstein V, Shahar E, Goldsher D, Berkowitz D Tumor necrosis factor blockade in the management of children with orphan diseases. *Clin Rheumatol* 2007; 26: 1783-85
- Bryce AH, Dispenzieri A, Kyle RA, Lacy MQ, Rajkumar SV Response to rituximab in patients with type II cryoglobulinemia *Clin. Lymphoma Myeloma* 2006; 7: 140-44
- Cacoub P, Saadoun D Hepatitis C virus infection induced vasculitis. *Clin Rev Allergy Immunol* 2008; 35: 30-9
- Calderon R, Estrada S, Ramirez del la Piscina P, Salvador M, Zabaleta S, Enciso C, Delgado E, Garcia-Campos F Infliximab therapy in a patient with refractory ileocolic Crohn's disease and Takayasu arteritis *Rev Esp Enferm Dig.* 2010; 102: 145-6
- Cantini F, Niccoli L, Salvarani C, Padula A, Olivieri I. Treatment of longstanding active giant cell arteritis with infliximab: report of four cases. *Arthritis Rheum* 2001; 44: 2933-2935
- Cavallo R, Roccatello D, Menegatti E, Naretto C, Napoli F, Baldovino S. Rituximab in cryoglobulinemic peripheral neuropathy *J. Neurol* 2009; 256: 1076-82
- Chung SA, Seo P. Advances in the use of biologic agents for the treatment of systemic vasculitis. *Curr. Opin. Rheumatol* 2009; 21: 3-9
- De Kort SWK, van Rossum MAJ, Ten Cate R. Infliximab in a child with therapy resistant systemic vasculitis *Clin Rheumatol* 2006; 25: 769-771
- Della Rossa A, Tavoni A, Merlini G, Baldini C, Sebastiani M, Lombardi M, Neglia D, Bombardieri S. Two Takayasu arteritis patients successfully treated with infliximab: a potential disease-modifying agent? *Rheumatology.* 2005; 44: 1074-75
- El Asrar, AMA, Abboud EB, Aldihbni H, Al-Arfaj A. Long-term safety and efficacy of infliximab therapy in refractory uveitis due to Behcet disease. *Int. Ophthalmol.* 2005; 26: 83-92
- Eleftheriou D, Melo M, Marks SD, Tullus K, Sills J, Cleary G, Dolezalova P, Ozen S, Plikington C, Woo P, Klein N, Dillon MJ Brogan PA Biologic therapy in primary systemic vasculitis of the young. *Rheumatology* 2009; 48: 978-86
- Eriksson P. Nine patients with antineutrophil cytoplasmic antibody-positive vasculitis successfully treated with rituximab *J Int. Med.* 2005; 257: 540-8
- Feinstein J, Arroyo R. Successful treatment of childhood onset refractory polyarteritis nodosa with tumor necrosis factor alpha blockade. *J Clin Rheumatol.* 2005; 11: 219-22
- Feldmann M, Pusey CD. Is there a role for TNF- α in anti-neutrophil cytoplasmic antibody-associated vasculitis?. Lessons from other chronic inflammatory diseases. *J Am Soc. Nephrol.* 2006; 17: 1243-52
- Garcia-Porrúa C, Gonzalez-Gay MA. Successful treatment to infliximab in a patient with undifferentiated spondyloarthropathy coexisting with polyarteritis nodosa-like cutaneous vasculitis. *Clin. Exp. Rheumatol.* 2003; 21: S138
- Grillo-Lopez AJ, White CA, Dallaire BK, Varns CL, Shen CD, Wei A, Leonard JE, McClure A, Weaver R, Cairelli S, Rosenberg J. Rituximab: the first monoclonal antibody approved for the treatment of lymphoma. *Curr. Pharm Biotechnol* 2000; 1: 1-9

- Gross WL Immunopathology and new therapeutic considerations in ANCA- associated vasculitis. *Autoimmun. Rev.* 2004; 3: S47-S48
- Gottemberg JE, Guillevin L, Lambotte O, Combe B, Allanore Y, Cantagrel A, Larroche C, Soubrier M, Bouillet L, Dougados M, Fain O, Farge D, Kyndt X, Lortholary O, Masson C, Moura B, Thomas T, Wendling D, Anaya JM, Sibilia J, Mariette X. Tolerance and short term efficacy of rituximab in 43 patients with systemic autoimmune diseases. *Ann Rheum Dis.* 2005; 64: 913-20
- Gurcan HM, Keskin DB, Stern JNH, Nitzberg MA, Shekani H, Ahmed AR A review of the current use of rituximab in autoimmune diseases. *Intern immunopharm.* 2009; 9: 10-25
- Halbwachs-Mecarelli L, Bessou G, Lesavre P, Lopez S, Witko-Sarsat V Bimodal distribution of proteinase 3 (PR3) surface expression reflects a constitutive heterogeneity in the polymorphonuclear neutrophil pool *FEBS letter* 1995; 374: 29-33
- Harris DP, Haynes L, Sayles PC, Duso DK, Eaton SM, Lepak NM, Johnson LL, Swain SL, Lund FE. .Reciprocal regulation of polarized cytokine production by effector B and T cells. *Nat. Immunol.* 2000; 1: 475-82
- Hernandez-Rodriguez J, Segarra M, Vilardell C, Sanchez M, Garcia-Martinez A, Esteban MJ, Queralt C, Grau JM, Urbano-Marquez A, Palacin A, Colomer D, Cid M.C. Tissue production of pro-inflammatory cytokines (IL-1b, TNF α and IL-6) correlates with the intensity of the systemic inflammatory response and with corticosteroid requirements in giant-cell arteritis *Rheumatology* 2004;43:294-301
- Hiemstra TF, Jayne DR. Newer therapies for vasculitis *Best Pract. Res Clin Rheumatol.* 2009; 23: 379-389
- Huugen D, Xiao H, van Esch A, Falk RJ, Peutz-Kootstra CJ, Buurman WA, Tervaert JW, Jennette JC, Heeringa P. Aggravation of antimyeloperoxidase antibody-induced glomerulonephritis by bacterial lipopolysaccharide: role of tumor necrosis factor- α *Am J Pathol* 2005; 167:47-58
- Huugen D, van Esch A, Xiao H, Peutz,- Koostra CJ, Buurman WA, Tervaert JW, Jennette JC, Heeringa P. Inhibition of complement factor C3 protects against antimyeloperoxidase antibody-induced glomerulonephritis in mice *Kidney Int.* 2007;71: 646-654
- Hoffman GS, Merkel PA, Brasington RD, Lenschow DJ, Liang P. Anti-tumor necrosis factor therapy in patients with difficult to treat Takayasu arteritis. *Arthritis Rheum.* 2004; 50: 2296-2304
- Hoffman GS, Cid MC, Rendt-Zagar K, Merkel PA, Weyand CM, Stone JH, Salvarani C, Xu W, Visvanathan S, Rahman MU. Infliximab for maintenance of glucocorticoid-induced remission of giant cell arteritis. *Ann Int Med.* 2007; 146: 621-630
- Jennette JC, Falk RJ, Andrassy K, Bacon PA, Churg J, Gross WL, Hagen EC, Hoffman GS, Hunder GG, Kallenberg CG, et al Nomenclature of systemic vasculitides. Proposal of an international consensus conference. *Arthritis Rheum* 1994; 37: 310-392
- Jones RB, Ferraro AJ, Chaudhry AN, Brogan P, Salama AD, Smith KGC, Savage COS, Jayne DRW. A multicenter survey of rituximab therapy for refractory antineutrophil cytoplasmic antibody-associated vasculitis. *Arthritis. Rheum.* 2009; 60: 2156-68
- Jones RB, Tervaert JWC, Hauser T, Luqmani R, Morgan MD, Peh CA, Savage CO, Segelmark M, Tesar V, van Passen P, Walsh D, Walsh M, Westman K, Jayne DRW. Rituximab

- versus cyclophosphamide in ANCA-associated renal vasculitis. *NEJM* 2010; 363: 211-20
- Jolly M, Curran JJ Infiximab responsive uveitis and vasculitis in a patient with Takayasu arteritis. *J. Clin. Rheumatol.* 2005; 11: 213-5
- Josselin L, Mahr A, Cohen P, Pagnoux C, Guaydler-Souquieres G, Hayem G, Job-Deslandre C, Liferman F, Pourrat J, Guillevin L. Infiximab efficacy and safety against refractory systemic necrotising vasculitides: long-term follow-up of 15 patients. *Ann Rheum Dis.* 2008; 67: 1434-6
- Kain R, Exner M, Ziehermayr R, Cunningham D, Alderson CA, Davidovits A, Raab I, Jahn R, Ashour O, Spitzauer S, Sunder-Plassmann G, Fukuda M, Klemm P, Rees AJ, Kerjasiski D. Molecular mimicry in pauci-immune focal necrotizing glomerulonephritis *Nat Med* 2008; 14: 1088-1096
- Kallemberg CGM Pathogenesis of PR3 ANCA-associated vasculitis *J Autoimmun.* 2008; 30: 29-36
- Karageorgaki ZT, Mavragani CP, Papathanasiou MA, Skopouli FN Infiximab in Takayasu arteritis. A safe alternative? *Clin Rheumatol* 2007; 26: 984-7
- Keogh KA, Wylam ME, Stone JH, Specks U. Induction of remission by B lymphocyte depletion in eleven patients with refractory antineutrophil cytoplasmic antibody-associated vasculitis. *Arthritis Rheum.* 2005; 52: 262-8
- Keogh KA, Yttemberg SR, Fervenza FC, Carlson KA, Schroeder DR, Specks U. Rituximab for refractory Wegener's granulomatosis. *Am J Respir Crit Care Med.* 2006; 173: 180-7
- Krumboltz M, Specks U, Wick M, Kalled SL, Jenne D, Meinel E. BAFF is elevated in serum of patients with Wegener's granulomatosis. *J. Autoimmun.* 2005; 25: 298-302
- Lamprecht P, Voswinkel J, Lilienthal T, Nolle B, Heller M, Gross WL, Gause A. Effectiveness of TNF- α blockade with infliximab in refractory Wegener's granulomatosis. *Rheumatology* 2002; 41: 1303-07
- Leydet-Quilici H, Luc M, Armingeat T, Pham T, Lafforgue P. Giant cell arteritis during adalimumab treatment for rheumatoid arthritis. *Joint Bone Spain* 2007; 74: 303-4
- Little MA, Smyth CL, Yadav R, Ambrose L, Cook HT, Nourshargh S, Pusey CD. Antineutrophil cytoplasm antibodies directed against myeloperoxidase augment leucocyte-microvascular interactions in vivo. *Blood* 2005; 106: 2050-58
- Ly K-H, Regent A, Tamby MC, Mouthon L. Pathogenesis of giant cell arteritis: more than just an inflammatory conditions? *Autoimmunity Rev.* 2010; 9: 635-45
- Mackay F, Schneider P, Rennert P, Browning J. BAFF and APRIL: a tutorial on B cell survival. *Ann Rev Immunol.* 2003; 21: 231-264
- Maffei S, Di Rienzo M, Santoro S, Puccetti L, Pasqui AL. Refractory Takayasu arteritis successfully treated with infliximab. *Eur. Rev Med Pharmacol. Sci.* 2009; 13: 63-65
- Martinez-Toboada VM, Rodriguez-Valverde V, Carreño L, Lopez-Longo J, Figueroa M, Belzunegui J, Mola EM, Bonilla G A double-blind placebo controlled trial of etanercept in patients with giant cell arteritis and corticosteroid side effects. *Ann. Rheum Dis.* 2008; 67: 625-30
- Mease PJ B-cell-targeted therapy in autoimmune disease: rationale, mechanisms and clinical application. *J Rheumatol.* 2008; 35: 1245-55
- Melikoglu M, Fresko I, Mat C, Ozyagan Y, Gogus F, Yurdakul S, Hamuryudan V, Yacizi H. Short term of etanercept in Behcet disease: a double-blind, placebo controlled study. *J. Rheumatol.* 2005; 32: 98-105

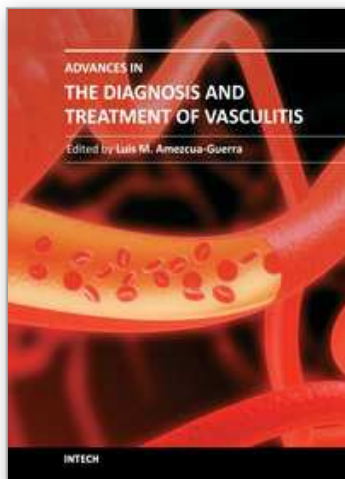
- Molloy ES, Langford CA, Clark TM, Gota CE, Hoffmann GS. Anti tumor necrosis factor therapy in patients with refractory Takayasu arteritis: long term follow-up. *Ann Rheum Dis*. 2008; 67: 1567-9
- Naganuma M, Sakuraba A, Hisamatsu T, Ochiai H, Hasegawa H, Ogata H, Iwao Y, Hibi T. Efficacy of Infliximab for reduction and maintenance of remission in intestinal Behcet disease. *Inflamm Bowel Dis*. 2008; 14: 1259-64
- Nishimoto N, Nakahara H, Yoshio-Hoshino N, Mima T. Successful treatment of a patient with Takayasu arteritis using a humanized anti-interleukin 6-receptor antibody. *Arthritis Rheum* 2008; 58: 1197-1200
- Noris M, Daina E, Gamba S, Bonazzola S, Remuzzi G. Interleukin-6 and RANTES in Takayasu arteritis: a guide for therapeutic decisions?. *Circulation* 1999; 100: 55-60
- Noronha IL, Kruger C, Andrassy K, Ritz E, Waldherr R. In situ production of TNF- α IL-1b, and IL-2R in ANCA positive glomerulonephritis. *Kidney Int*. 1993; 43: 682-692
- Omdal R, Wildhagen K, Hansen T, Gunnarsson R, Kristoffersen G. Anti CD-20 therapy of treatment-resistant Wegener's granulomatosis: favourable but temporary response. *Scand J Rheumatol*. 2005; 34: 229-32
- Ohno S, Nakamura S, Hori S, Shimakawa M, Kawashima H, Mochizuki M, Sugita S, Ueno S, Yoshizaki K, Inaba G. Efficacy, safety and pharmacokinetics of multiple administration of infliximab in Behcet disease with refractory uveoretinitis. *J. Rheumatol*. 2004; 31: 1362-68
- Park MC, Lee SW, Park YB, Lee SK. Serum cytokines profiles and their correlations with disease activity in Takayasu's arteritis. *Rheumatology* 2006; 45: 545-8
- Petrarca A, Rigacci L, Caini P, Colagrande S, Romagnoli P, Vizzuti F, Arena U, Giannini C, Monti M, Montalto P, Matucci-Cerinic M, Bosi A, Laffi G, Zignego AL. Safety and efficacy of rituximab in patients with hepatitis C-virus related mixed cryoglobulinemia and severe liver disease. *Blood*. 2010; 116: 335-34
- Pfister H, Ollert M, Frohlich LF, Quintanilla-Martinez L, Colby TV, Specks U, Jenne D. Antineutrophil cytoplasmic autoantibodies against the murine homolog of proteinase 3 (Wegener autoantigen) are pathogenetic in vivo. *Blood* 2004; 104: 1411-18
- Pipitone N, Olivieri I, Padula A, D'Angelo S, Nigro A, Zuccoli G, Boiardi L, Salvarani C. Infliximab for the treatment of neuro-Behcet's disease: a case series and review of the literature. *Arthritis Rheum*. 2008; 59: 285-290
- Pistoia V. Production of cytokines by B cell in health and disease. *Immunol. Today* 1997; 18: 343-50
- Quartuccio L, Soardo G, Romano G, Zaja F, Scott CA, De Marchi G, Fabris M, Ferraccioli G, De Vita S. Rituximab treatment for glomerulonephritis in HCV-associated mixed cryoglobulinemia: efficacy and safety in the absence of steroid. *Rheumatology* 2006; 45: 842-46
- Reff ME, Carner K, Chambers KS, Chinn PC, Leonard JE, Raab R, Newman RA, Hanna N, Anderson DR. Depletion of B cells in vivo by a chimeric mouse human monoclonal antibody to CD 20. *Blood* 1994; 82: 435-45
- Roccatello D, Baldovino S, Rossi D, Giachino O, Mansouri M. Rituximab as a therapeutic tool in severe mixed cryoglobulinemia. *Clin Rev Allergy Immunol*. 2008; 34: 111-117
- Ruth AJ, Kitching AR, Kwan RY, Odobasic D, Ooi JD, Timoshanko JR, Hickey MJ, Holdsworth SR. Anti-neutrophil cytoplasmic antibodies and effector CD4+ cells

- play non-redundant roles in anti-myeloperoxidase crescentic glomerulonephritis *J Am Soc. Nephrol.* 2006; 17: 1940-9
- Saadoun D, Delluc A, Piette JC, Cacoub P. Treatment of hepatitis C-associated mixed cryoglobulinemia vasculitis. *Curr. Opin. Rheumatol.* 2008; 20: 23-8
- Saadoun D, Resche-Rigon M, Sene D, Perard L, Piette JC, Cacoub P. Rituximab combined with peg-interferon-ribavirin in refractory HCV-associated cryoglobulinemia vasculitis. *Ann. Rheum. Dis.* 2008; 67: 1431-1436
- Saadoun D, Resche-Rigon M, Sene D, Terrier B, Karras A, Perard L, Schoindre Y, Coppere B, Blanc F, Musset L, Piette JC, Rosenzweig M, Cacoub P. Rituximab plus Peg-interferon- α ribavirin compared with Peg-interferon- α /ribavirin in hepatitis C-related mixed cryoglobulinemia. *Blood* 2010; 116: 326-34
- Sandborn WJ, Hanauer SB, Katz S, Safdi M, Wolf DG, Baerg RD, Tremaine DJ, Johnson T, Diehl NN, Zinmeister AR. Etanercept for active Crohn disease: a randomized, double blind, placebo controlled trial. *Gastroenterology* 2001; 121: 1088-94
- Sansonno D, De Re V, Lauletta G, Tucci FA, Boiocchi M, Dammacco F. Monoclonal antibody treatment of mixed cryoglobulinemia resistant to interferon α with an anti CD20. *Blood* 2003; 101: 3818-3826
- Scapini P, Carletto A, Nardelli B, Calzetti F, Roschle V, Merigo F, Tamassia N, Pieropan S, Biasi D, Sbarbati A, Sozzani S, Bambara L, Cassatella MA. Proinflammatory mediators elicit secretion of the intracellular B-lymphocytes stimulate pool (BlyS) that is stored in activated neutrophils: implication for inflammatory diseases. *Blood* 2005; 106: 830-837
- Schreiber A, Busjahn A, Luft FC, Kettritz R. Membrane expression of proteinase 3 is genetically determined. *J. Am. Soc. Nephrol.* 2003; 14: 69-75
- Sfikakis PP, Kaklamani PH, Elezoglou A, Katsilambros N, Theodossiades PG, Papaftimiou S, Markomichelakis N. Infliximab for recurrent, sight-threatening ocular inflammation in Adamantiades-Behcet disease. *Ann Int. Med.* 2004; 140: 404-6
- Sfikakis PP, Markomichelakis N, Alpsoy E, Assad-Kahil S, Bodaghi B, Gul A, Ohno S, Pipitone N, Schirmer M, Stanford M, Wechsler B, Zouboulis C, Kaklamani P, Yacizi H. Anti TNF therapy in the management of Behcet disease-review and basis for recommendations. *Rheumatology* 2007; 46: 736-741
- Sene D, Ghillani-Dalbin P, Amoura Z, Musset L, Cacoub P. Rituximab may form a complex IgM κ mixed cryoglobulin and induce severe systemic reactions in patients with hepatitis C virus-induced vasculitis. *Arthritis Rheum* 2009; 60: 3848-55
- Seo P, Specks U, Keogh K. Efficacy of rituximab in limited Wegener's granulomatosis with refractory granulomatous manifestations. *J. Rheumatol.* 2008; 35: 2017-23
- Serra P, Santamaria P. To B regulated: B cells as members of the regulatory workforce. *Trend Immunol.* 2006; 27: 7-10
- Seton M. Giant cell arteritis in a patient taking etanercept and methotrexate. *J. Rheumatol.* 2004; 31: 1467
- Smith KG, Jones RB, Burms SM, Jayne DR. Long term comparison of rituximab treatment for refractory systemic lupus erythematosus and vasculitis. Remission, relapse and re-treatment. *Arthritis. Rheum.* 2006; 54: 2970-82
- Sonomoto K, Watanabe MT, Takahama S, Nakamura M, Ando H, Minami R, Yamamoto M, Saito T, Imayama S, Hosokawa C, Suematsu E. A case of polyarteritis nodosa

- successfully treated by rituximab *Nihon Rinsho Meneki Gakkai Kaishi* 2008; 31: 119-23
- Stasi R, Stipa E, Del Poeta G, Amadori S, Newland AC, Provan D. Long term observation of patients with anti-neutrophil cytoplasmic antibody-associated vasculitis treated with rituximab. *Rheumatology*. 2006; 45: 1432-6
- Stone JH, Merkel PA, Spiera R, Seo P, Langford CA, Hoffman GS, Kallemberg CGM, St Clair EW, Turkiewicz A, Tchao N, Webber L, Ding L, Seijsmundo LP, Mieras K, Weitzenkamp D, Ilke D, Seyfert-Margolis V, Mueller M, Brunetta P, Allen NB, Fervenza FC, Geetha D, Keogh KA, Kissin EY, Monach PA, Peikert T, Stegeman C, Ytterberg SY, Specks U. Rituximab versus cyclophosphamide in ANCA-associated renal vasculitis. *NEJM* 2010; 363: 221-32
- Tamura N, Matsudaira R, Hirashima M, Ikeda M, Tajima M, Nawata M, Morimoto S, Kaneda K, Kobayashi S, Hashimoto H, Takasaki Y. Two cases of refractory Wegener's granulomatosis successfully treated with rituximab. *Intern. Med.* 2007; 46: 409-14
- Tanaka F, Kawakami A, Iwanaga N, Tamai M, Izumi Y, Aratake K, Arima K, Kamachi M, Nakamura H, Huang M, Ida H, Origuchi T, Eguchi K. Infliximab is effective for Takayasu arteritis refractory to glucocorticoid and methotrexate. *Intern Med* 2006; 45: 313-6
- Tatò F, Rieger J, Hoffman U. Refractory Takayasu's arteritis successfully treated with the human monoclonal anti-tumor necrosis factor antibody adalimumab *Int Angiol* 2005; 24: 304-7
- Terrier B, Launay D, Kaplanski G, Hot A, Larroche C, Cathebras P, Cofombe B, De Jaurèguiberry J.P, Meyer O, Schaefferbeke T, Somogy A, Tricot L, Zenone T, Ravaud P, Gottemberg JE, Mariette X, Cacoub P. Safety and efficacy of rituximab in nonviral cryoglobulinemia vasculitis: data from the French autoimmunity and rituximab registry. *Arthritis Care and Res.* 2010; 62: 1787-95
- Tognon S, Graziani G, Marcolongo R. Anti TNF- α therapy in seven patients with Behcet disease *Ann. N.Y. Acad. Sci.* 2007; 1110: 474-84
- Tugal-Tutkun I, Mudun A, Urgancioglu M, Kamali S, Kasapoglu E, Inanc M, Gul A. Efficacy of infliximab in the treatment of uveitis that is resistant to treatment with the combination of Azathioprine, Cyclosporin and corticosteroids in Behcet disease. *Arthritis Rheum* 2005; 52: 2478-2484
- Utz JP, Limper AH, Kalra S, Specks U, Scott JP, Vuk-Pavlovic Z, Schroeder D. Etanercept for the treatment of stage II and III progressive pulmonary sarcoidosis. *Chest* 2003; 124: 177-85
- Van Rossum AP, Rarok AA, Huitema MG, Fassina G, Limburg PC, Kallemberg CGM. Constitutive membrane expression of proteinase 3 (PR3) and neutrophil activation by antiPR3 antibodies. *J. Leukoc Biol* 2004; 76: 1162-70
- Vega-Gutierrez J, Rodriguez Prieto MA, Garcia Riuz JM. Successful treatment of childhood cutaneous polyarteritis nodosa with infliximab. *JEADV* 2007; 536: 570-71
- Visenti M, Granata M, Veneziano ML, Borghese F, Carlesino M, Pimpinelli F, Fiorilli M, Casato M. Efficacy of low dose rituximab for mixed cryoglobulinemia *Clin. Immunol.* 2007; 125: 30-33
- Voswinkel J, Assmann G, Held G, Pitann S, Gross WL, Holl-Ulrich K, Herlyn K, A. Mueller. Single cells analysis of B lymphocytes from Wegener's granulomatosis: B cells

- receptor display affinity maturation within the granulomatous lesions. *Clin Exp. Immunol.* 2008; 154: 339-345
- Wahezi DM, Gomes WA, Illowite NT. Cranial nerve involvement with juvenile polyarteritis nodosa: clinical manifestations and treatment. *Pediatrics* 2010; 126: 719-22
- Walsh M, Jayne DR Rituximab in the treatment of antineutrophil cytoplasm antibody associated vasculitis and systemic lupus erythematosus. *Kidney Int.* 2007; 27: 676-82
- Wegener's granulomatosis etanercept trial (WGET) research group- Etanercept plus standard therapy for Wegener's granulomatosis *N Engl. J. Med.* 2005; 352: 351-61
- Witko-Sarsat V, Lesavre P, Lopez S, Bessou G, Hieblot C, Prum B, Noël LH, Guillevin L, Ravaud P, Sermet-Gaudelus I, Timsit J, Grünfeld JP, Halbwachs-Mecarelli L. A large subset of neutrophils expressing membrane proteinase 3 is a risk factor for vasculitis and rheumatoid arthritis *J. AM. Soc. Nephrol.* 1999; 10: 1224-33
- Wu K, Throssell D A new treatment for polyarteritis nodosa *Nephrol. Dial Transplant* 2006; 21: 1710-1712
- Xiao H, Heeringa P, Hu P, Liu Z, Zaho M, Aratani Y, Maeda N, Falk RJ, Jennette JC Antineutrophil cytoplasmic autoantibodies specific for myeloperoxidase cause glomerulonephritis and vasculitis in mice *J. Clin. Invest.* 2002 110; 955-963
- Xiao H, Schreiber P, Liu Z, Huugen D, Maeda N, Falk RJ, Jennette JC The role of neutrophils in the induction of glomerulonephritis by anti mieloperoxydase antibodies. *Am. J. Pathol.* 2005; 167: 39-45
- Xiao, H, Schreiber A, Heeringa P, Falk RJ, Jennette JC Alternative complement pathway in the pathogenesis of disease mediated by antineutrophil cytoplasmic autoantibodies *Am J Pathol.* 2007; 170: 52-64
- Youinou P. B cell conduct the lymphocyte orchestra. *J. Autoimmun.* 2007; 28: 143-151
- Zaja F, De Vita S, Mazzaro C, Sacco S, Damiani D. Efficacy and safety of rituximab in type II mixed cryoglobulinemia *Blood* 2003; 101: 3827-3834

IntechOpen



Advances in the Diagnosis and Treatment of Vasculitis

Edited by Dr. Luis M Amezcua-Guerra

ISBN 978-953-307-786-4

Hard cover, 366 pages

Publisher InTech

Published online 09, November, 2011

Published in print edition November, 2011

This book represents the culmination of the efforts of a group of outstanding experts in vasculitis from all over the world, who have endeavored to draw themselves into this volume by keeping both the text and the accompanying figures and tables lucid and memorable. The book provides practical information about the screening approach to vasculitis by laboratory analysis, histopathology and advanced image techniques, current standard treatment along with new and more specific interventions including biologic agents, reparative surgery and experimental therapies, as well as miscellaneous issues such as the extra temporal manifestations of "temporal arteritis" or the diffuse alveolar hemorrhage syndrome. The editor and each of the authors invite you to share this journey by one of the most exciting fields of the medicine, the world of Vasculitis.

How to reference

In order to correctly reference this scholarly work, feel free to copy and paste the following:

P. Sfriso and F. Schiavon (2011). Biologic Agents for the Treatment of Systemic Vasculitis, *Advances in the Diagnosis and Treatment of Vasculitis*, Dr. Luis M Amezcua-Guerra (Ed.), ISBN: 978-953-307-786-4, InTech, Available from: <http://www.intechopen.com/books/advances-in-the-diagnosis-and-treatment-of-vasculitis/biologic-agents-for-the-treatment-of-systemic-vasculitis>

INTECH
open science | open minds

InTech Europe

University Campus STeP Ri
Slavka Krautzeka 83/A
51000 Rijeka, Croatia
Phone: +385 (51) 770 447
Fax: +385 (51) 686 166
www.intechopen.com

InTech China

Unit 405, Office Block, Hotel Equatorial Shanghai
No.65, Yan An Road (West), Shanghai, 200040, China
中国上海市延安西路65号上海国际贵都大饭店办公楼405单元
Phone: +86-21-62489820
Fax: +86-21-62489821

© 2011 The Author(s). Licensee IntechOpen. This is an open access article distributed under the terms of the [Creative Commons Attribution 3.0 License](https://creativecommons.org/licenses/by/3.0/), which permits unrestricted use, distribution, and reproduction in any medium, provided the original work is properly cited.

IntechOpen

IntechOpen