

We are IntechOpen, the world's leading publisher of Open Access books Built by scientists, for scientists

6,900

Open access books available

185,000

International authors and editors

200M

Downloads

Our authors are among the

154

Countries delivered to

TOP 1%

most cited scientists

12.2%

Contributors from top 500 universities



WEB OF SCIENCE™

Selection of our books indexed in the Book Citation Index
in Web of Science™ Core Collection (BKCI)

Interested in publishing with us?
Contact book.department@intechopen.com

Numbers displayed above are based on latest data collected.
For more information visit www.intechopen.com



Cutaneous Manifestations of HIV/AIDS in Sub-Saharan African

Innocent Ochevana George¹ and Dasetima Dandison Altraide²

¹*Department of Paediatrics, University of Port Harcourt Teaching Hospital, Port Harcourt,*

²*Department of Medicine, University of Port Harcourt Teaching Hospital, Port Harcourt, Nigeria*

1. Introduction

The burden of skin disease is high in developing countries particularly the sub-Saharan Africa. The HIV/AIDS epidemic does not make it any better. More than 90% of HIV positive patients may develop mucocutaneous problems at one stage of the disease or the other with significant morbidity and mortality.

The aim is to highlight common cutaneous manifestations of HIV/AIDS in sub-Saharan Africa. A good knowledge of these cutaneous lesions may aid in early diagnosis and appropriate treatment of HIV infection.

2. Cutaneous manifestations of HIV/AIDS

Cutaneous manifestations are common in patients with HIV infection in the sub-Saharan Africa and can be broadly classified into infection/infestation, malignancy, and cutaneous hypersensitivity. It may be the sentinel event that brings the patient to the physician. Majority of HIV-infected patients will have dermatologic problem at some time during their illness. This may provide a more accurate measure of the disease progression than other organs because the skin is much accessible (Johnson, 1999).

Skin disorders are mostly attributable to the alterations in immune function. Some of the skin diseases are unique to HIV infection, while some are really not new diseases (Aftergut and Cockerell, 1999; Olumide, 2002). The later diseases may be more widespread, have an unusual character or a more prolonged course and may be resistant to therapy. The affected individuals have a significantly increased incidence of skin complaints which rises as HIV infection progresses (Wiwanitkit, 2004). In the asymptomatic stage of HIV infection, cutaneous manifestations are non-specific. Common cutaneous disorders present with atypical features for instance, shingles (VZV) may be severe, recurrent, haemorrhagic or affect more than one dermatome; warts may be multiple and large. Seborrhoeic dermatitis, pityrosum folliculitis, eosinophilic pustulosis and bacillary angiomatosis are all well recognized. In the later symptomatic stages, in addition to those infections mentioned above, the following should also be remembered: mycobacterium tuberculosis and atypical mycobacteria, candida species; *Trichophyton rubrum*, *Malassezia furfur*, chronic herpes simplex, florid molluscum contagiosum. Neoplastic processes, especially Kaposi's sarcoma make their appearance at this time.

2.1 Mycobacteria

These organisms are important causes of systemic infection in HIV disease, but cutaneous lesions have also been recognized, both direct infection and papulonecrotic tuberculide. Cutaneous lesions of mycobacterium avium complex (MAC) include nodules (Fig 1), ulcerations, pustules abscesses, folliculitis and lymph adenitis. Cutaneous lesions of mycobacterium tuberculosis (TB) include scrofuloderma, papules, vesicles, necrotic ulcerations, subcutaneous nodules and pustules. Bacillus calmette – Guerin (BCG) vaccine may cause local and systemic infection in HIV patients especially after signs of defective immunity have appeared, it is regarded as contra-indicated except for children as yet asymptomatic in areas of high risk for tuberculosis.

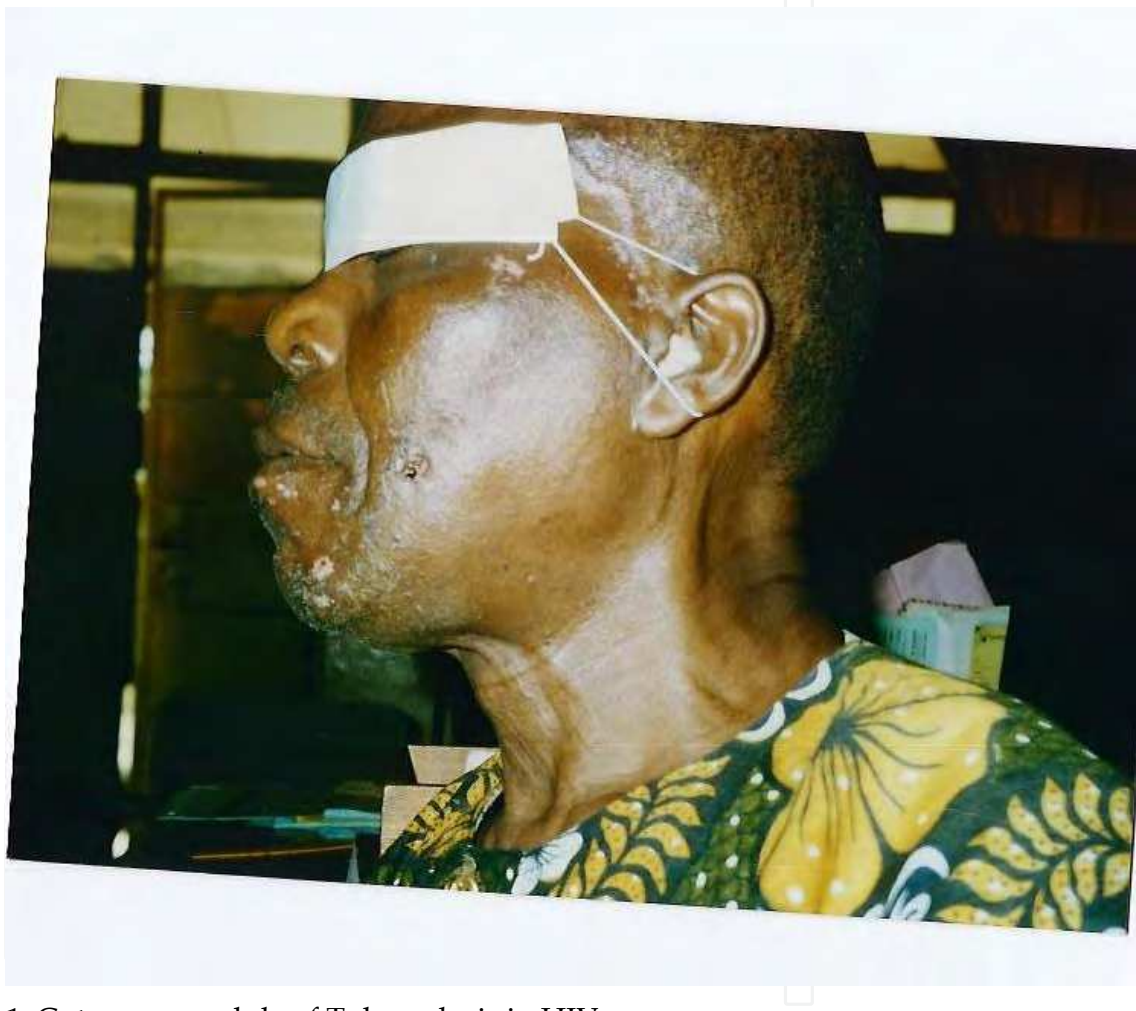

Fig. 1. Cutaneous nodule of Tuberculosis in HIV

The treatment of mycobacterium tuberculosis is the conventional DOTS using rifampicin, isonazid, ethambutol and pyrazinamide. It is recommended that for MAC treatment regimen should include at least 2 agents, with ethambutol being one of the agents.

2.2 Syphilis

Syphilis is a sexually transmitted disease due to infection with *Treponema pallidum*. Both syphilis and HIV infection are sexually transmitted diseases and so could occur concurrently (Olumide; 2002).

Unusual courses of syphilis have been reported in HIV infections. Not only may the serological response to *T. pallidum* be impaired but also syphilis may progress much more rapidly to advanced stages than in individuals without HIV. Moreover syphilis in patients with HIV infection may not respond to conventional treatment. Skin signs of syphilis in HIV infected patients are usually similar to that of HIV – negative patients but are often extensive and atypical.

A severe form of secondary syphilis or lues, 'syphilis maligna' can occur in HIV patients with papular, papulovesicular, pustular and necrotizing lesions which may form thick crusts and painful ulcers accompanying severe systemic symptoms. Tertiary gummata and neurosyphilis also appear more common.

Recommended treatment is benzathine penicillin 2.4 million units intramuscularly in a single dose given as 1.2 million units in each buttock. The treatment is repeated in a week. If there is central nervous system involvement 2.4 million units of aqueous penicillin is given intravenously every 4 hours for 10 – 14 days. This is because intramuscular benzathine penicillin does not give therapeutic levels in the CSF.

2.3 Staphylococcus aureus

Skin infections with *Staph aureus* are quite common in HIV infected patients and the frequency increases with progression of immune-deficiency. Not only is *Staph aureus* the most common bacterial pathogen in HIV infected patients but also a large percentage of patients become chronic carriers. Apart from the types of skin lesions commonly associated with *Staph aureus* in patients without HIV such as folliculitis, impetigo, ecthyma, abscesses and cellulitis, more unusual manifestations such as atypical plaque – like folliculitis, pyomyositis or botryomycosis are frequently encountered during HIV diseases.

Botryomycosis is characterized by chronic, Suppurating, granulomatous lesions which may present as inflammatory nodules, discharging ulcers, sinuses and fistulae. The lesions usually solitary can occur in the skin, liver, bones, etc, and on gross examination of the pus, pinhead – sized whitish yellow granules are evident. The granules simply contain a central mass of bacteria surrounded by a capsule and can be demonstrated on biopsy or smear of the purulent focus. The capsule is usually periodic – Acid – Schiff (PAS) positive. Botryomycosis is caused by bacteria with *Staph aureus* usually the major causal agent and *Pseudomonas aeruginosa* ranking second in frequency. The therapy of choice is surgical excision in conjunction with antibiotics.

2.4 Bacillary angiomatosis

These angioma-like lesions may affect skin, mucosal surfaces and internal organs, Cutaneous lesions typically begin as tiny pinpoint papules, resembling Campbell de Morgan spots, often in large numbers and very widespread. They enlarge rapidly both outwards and inwards, looking like pyogenic granulomas and subcutaneous nodules. They may resemble some forms of AIDS-related Kaposi's sarcoma (and indeed the two may coexist but can generally be distinguished by their faster growth, bright red color and rounder shape, with no elongation along skin crease). If injured, lesions bleed profusely. Visceral lesions may occur and deaths from laryngeal obstruction and disseminated intravascular obstruction are recorded. Bacillary angiomatosis has been seen mainly in HIV disease, but also in other immunodeficient patients and rarely in the otherwise healthy. It is caused by *Bartonella henselae* or occasional *B. quintana*, argyrophilic bacilli. Confirmation of diagnosis

is by recognition of histological features or by PCR amplification of the organism's nucleic acid obtained from biopsy tissue.

Treatment – the recommended treatment for bacillary angiomatosis is erythromycin 500mg qds. If the patient has severe disease or can not tolerate orally, intravenous erythromycin can be given. Alternative to erythromycin include doxycycline 100mg bid; minocycline 100mg bid or tetracycline 50mg qid, treatment should continue for 8-12 weeks and in case of systematic disease 3-4 months.

2.5 Demodicidosis

Folliculitis due to *Demodex folliculorum* may cause an itchy papular eruption in HIV patients. Affected areas include head and neck, and trunk and arms. Microscopy of smears or scrapings, or histology confirms the presence of numerous mites. There is a rapid response to topical treatment with insecticides such as gamma-benzene hexachloride.

2.6 Viral infection

Viruses other than HIV-1 are common pathogens in HIV-1 disease and are probably important infectious co-factors for disease progression (Sterling and Kurtz, 1998). These opportunistic infections range from relatively benign disorder such as cosmetically disfiguring molluscum contagiosum to severe infections of the skin and mucous membranes such as ulcerating herpes simplex and oral hairy leukoplakia, which is attributed to Epstein Barr virus infection.

2.7 Herpes simplex

Chronic painful, non-healing ulcers found in herpes simplex virus (HSV) infections are commonly located at the junction between skin and mucous membranes, mainly in the perioral and perianal areas. Chronic ulcerating herpes simplex must first be differentiated from conventional recurrent HSV infection. Whereas the latter can occur at any stage of HIV-1 disease and is clinically and morphologically indistinguishable from the blistering eruptions commonly seen in patients without HIV-1 infection, the former heralds profound immunodeficiency. Chronic ulcerating herpes simplex is one of the AIDS-defining opportunistic infection according to Centers for Disease Control and Prevention. Systemic antiviral treatment is essential since these lesions show no tendency to resolve spontaneously. The differential diagnosis, which depends on the location of the lesions, includes pyoderma gangrenosum, bacterial and fungal infection, and cutaneous manifestation of lymphomas.

The recommended treatment for primary or recurrent HSV infection is oral acyclovir. In severe infections, intravenous acyclovir can be used. Other alternatives include famciclovir and foscarnet.

2.8 Varicella-zoster

Clinical manifestation of infection with the varicella-zoster virus (VZV), another member of the herpes virus family, depends largely on the age of the patient. Primary VZV infection in HIV-1 infected children is often severe, with dissemination and pneumonia, encephalitis, or pancreatitis. As with adult patients, epidemiological studies indicate that the frequency of reactivation of latent VZV, leading to herpes zoster, is greatly increased, with a relative risk in one study of 16.9 for HIV-1 infected person over non-infected

persons. 8-13% of patients with AIDS have experienced at least one episode of herpes zoster and recurrent herpes zoster is observed more frequently in HIV-1 seropositive patients than in sero-negative individuals. However, herpes zoster is not a reliable sign of profound immunodeficiency because it can occur at any state of HIV infection. Clinical manifestations range from an uneventful vesicular eruption in a dermatomal pattern, similar to that in non-HIV-1 infected individuals, to severe haemorrhagic and necrotic lesions that may extend over several dermatomes, followed by cutaneous dissemination. In contrast to the high frequency of systemic dissemination associated with primary VZV infection, dissemination is infrequent in conventional herpes zoster. Nevertheless, chronic verrucous or ecthymatous VZV infections may persist for months.

2.9 Molluscum contagiosum

Poxvirus infection causing Molluscum contagiosum is ordinarily self-limited in immunocompetent individuals, occurring mainly in children. However, during HIV-1 disease molluscum contagiosum is seen in up to 20% of patients, and is usually associated with established immunodeficiency.

Characteristic lesions, which appear commonly on the face and in the genital regions, include skin-coloured umbilicated papules with one or more central hyperkeratotic pores. Individual lesions can grow to more than 1 cm in size and, if located on the face, may be disfiguring. If multiple nodular lesions become confluent they are difficult to treat, commonly recurring after conventional local destruction. The differential diagnosis includes basal-cell carcinoma, common warts, keratoacanthoma, atypical mycobacterial infections, and, especially, cutaneous manifestations of systemic infections with *Cryptococcus neoformans*, *Histoplasma capsulatum*, or *Penicillium marneffei*. Since differentiation of molluscum contagiosum from these important fungal infections is often uncertain clinically, histopathological confirmation should always be sought.

Human Papilloma virus- Common warts may occur in unusual locations, with unusual severity, and with high frequency in HIV-1 infected patients but they are seldom serious. With respect to genital involvement in women (Fig2), both frequency of human papilloma virus (HPV) infection and the progression of HPV-associated cervical lesions correlate with the level of immune suppression. Moderate to severe cervical dysplasia and carcinoma-in-situ are part of category B symptomatic conditions in the revised classification system for HIV infection. In men, the rate of anogenital HPV infection is high in HIV-1 sero-positive and sero-negative homosexuals. However, as for women, HPV prevalence and symptoms tend to increase with disease progression.

3. Fungal infections

3.1 Dermatophyte Infection

Tinea infections of varying sites do occur and may be chronic and widespread in HIV positive patient (Fig 3). The overall frequency is higher in non-infected control population. Nail involvement is common and can cause diffuse whitening. Proximal nail whitening or proximal subungual onychomycosis, unusual in immunocompetent individuals is regarded by some as characteristic of HIV-associated nail infection.

Treatment is standard with the use of topical and systemic anti-fungal agents.



Fig. 2. Genital warts in HIV

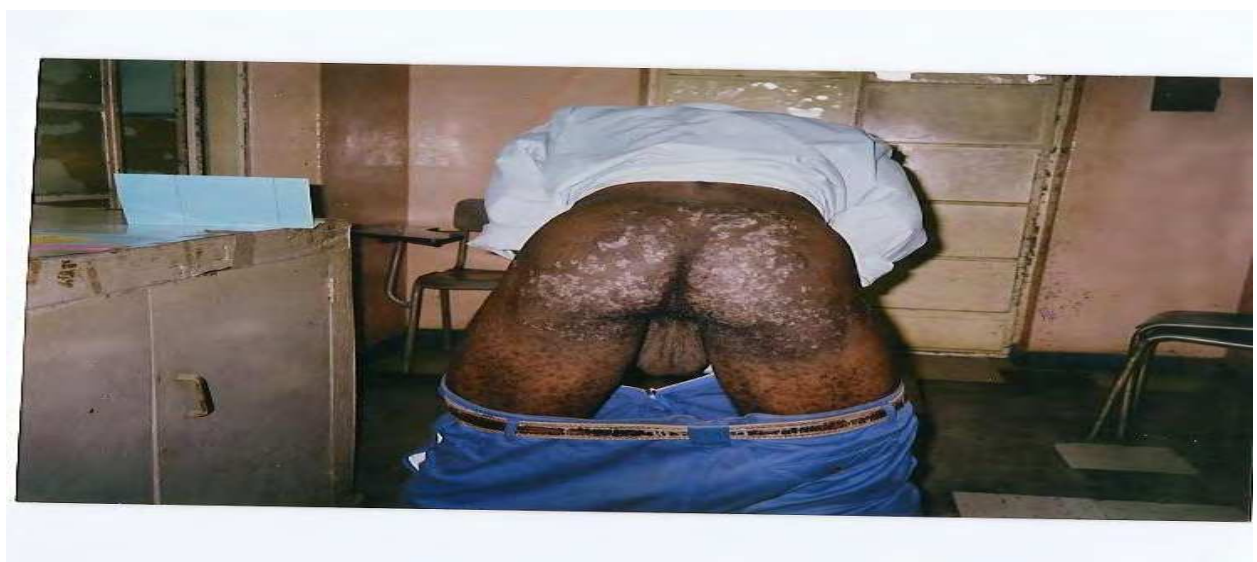

Fig. 3. Extensive tinea cruris and corporis

3.2 Candidiasis

This is common in all stages of HIV infection affecting the skin, nail, genitals and oral mucosa. Cutaneous lesions are often located in the intertriginous areas/ skin folds as highly pruritic inflamed areas with satellite lesions and/or follicular pustules. In addition to HIV, other risk factors are diabetes mellitus, obesity, malignancy, use of immunosuppressive therapy and cytotoxic drugs, use of systemic and topical corticosteroids and antibiotic therapy, hot humid environment, occlusion e.g. diapers, casts and dressings, blood malignancies and neutropenia and skin disease which disturb the cutaneous barrier e.g. psoriasis and contact dermatitis.

Nail lesions affect the proximal nail fold and nail plate. Nail fold lesions (paronychia) present as painful, erythematous swellings which may discharge purulent material. Genital lesions present as pruritic vulvo-vaginitis with discharge of a creamy white material. There may be involvement of the perineum with erythematous and satellite lesions. In severe cases, the oral mucosa may show extensive white plaques or widespread erythema, and esophageal involvement may give rise to dysphagia and retrosternal pain.

Standard topical therapy will suffice but in severe cases and nail involvement systemic therapy may be needed. Fluconazole (50mg daily) has a higher cure rate than ketoconazole (20mg daily) and intermittent administration of fluconazole (150mg) also proved effective.

3.3 Cutaneous malignancies

Persons infected with Human Immunodeficiency Virus (HIV) are at higher risk for the development of certain types of cancers. The AIDS was first reported in the summer of 1981 in Los Angeles among young homosexuals who were observed to have had a disseminated type of Kaposi's sarcoma and pneumocystis carini infection.

3.4 Kaposi's sarcoma

Kaposi's sarcoma (KS), the most common tumor in patients with AIDS, is strongly associated with immunosuppression (Schwartz et al., 2008). KS is a vascular neoplasm affecting the endothelial cell and that affects the skin, and the mucosa, less commonly involves other organs like the gastrointestinal tracts, lungs and lymph nodes. KS can occur in HIV-negative patients where it typically has a chronic indolent course. In HIV infected patients KS has a more aggressive course and may have systemic involvement.

Epidemiological data suggest that the cause is a sexually transmitted infectious agent and this has recently been supported by the finding of herpes virus nucleic acid in Kaposi's sarcoma lesions (Schwartz et al., 2008). However, this virus called Kaposi's sarcoma associated herpes virus (or human herpes virus type 8) has also been detected in classical KS; Gut lymphomas and other skin lesions of AIDS patients. The role of HHV-8 in the pathogenesis of Kaposi's sarcoma is yet to be clearly defined.

The mucocutaneous lesions of KS are usually asymptomatic vary from the earliest pink macules to the thickened papules and plaques which later develop to nodules. Diffuse lesions may manifest mainly as oedema. The lesions initially may appear benign-looking and may be misdiagnosed as pigmented naevi, Spitz naevi, dermatofibroma, bruises, pyogenic granulomas, malignant melanoma, ecchymosis, molluscum contagiosum or lichen planus. The lesions may appear any where on the skin but the tip of the nose and the hard palate are common sites. Lesions in the feet may occasionally become warty. Lesions may develop at the site of trauma (Kobner Phenomenon).

Unlike the metastatic behavior of other malignant tumors, KS is a multifocal neoplasm in which each lesion seems to develop de novo from endothelial cells that line lymphatic or blood vessels into skin or visceral.

Progression of lesions depends upon the immune status. If the CD4⁺ cell count rises, either with or without treatment lesion may regress at least temporary.

Treatment: This is not curative. Palliative therapy is indicated for lesions that are disfiguring, causing pains or with systemic symptoms.

Local therapy would include:

- a. Surgery for large lesions. This would include the use of excision and laser.
- b. Cryosurgery
- c. Intralesional chemotherapy using vinblastine
- d. The tumor is sensitive to radiotherapy.

Systemic therapy would include the following:

- a. Chemotherapy including vinblastine, bleomycin, Doxorubicin
- b. Biology response modifiers which include IFN- α , interleukin-2 and intravenous immunoglobulin
- c. Antiretroviral therapy
- d. Photodynamic therapy.

3.5 Other malignancies

AIDS-related lymphomas are not uncommon and are usually high grade of the immunoblastic or small-cell type.

3.6 Cutaneous hypersensitivity

This is a group of eruptions in patients with HIV disease. The pathophysiology of some of them is not well defined and therapeutic responses have been disappointing. However, some explanations have been advised based on some immunologic findings. Monocytes, macrophages, epidermal langerhans cells and dendritic cells of the dermis have CD4 antigen and are potential targets for infection by HIV. The decrease in langerhans cells as in AIDS may lead to altered cell mediated immunity.

3.7 Xeroderma

Dry skin is common in HIV/AIDS especially if chronic diarrhea is a masked feature and may be related to malabsorption. There is associated pruritus. In more severe cases with changes you have acquired ichthyosis. Ichthyosis is a disorder of keratinization characterized clinically by dry scaly skin. It should be noted that acquired ichthyosis can also be found in lymphomas, lepromatous leprosy and sarcoidosis which are conditions with reduced immunity. Treatment is the use of emollients.

3.8 Pruritic Papular Eruption (PPE) of HIV

PPE of HIV is a unique manifestation of HIV which has not been seen in seronegative patients (Eisman, 2006, Machtinger et al., 2004). Clinically, the lesions are red or skin coloured papules that are symmetrically disseminated in the trunk, buttocks and extremities (Fig 4). The lesions are extremely pruritic. The lesions heal with post inflammatory hypopigmentation with new hyperpigmented lesions. The eruptions wax and wane during

the course of the illness. The cause of the lesion is not known but most people think that it is a hypersensitivity reaction to antigens or a direct effect of the HIV.

Treatment with antihistamines, phototherapy and photochemotherapy may be used but of limited success. Patient education as to the cause of the illness is important.

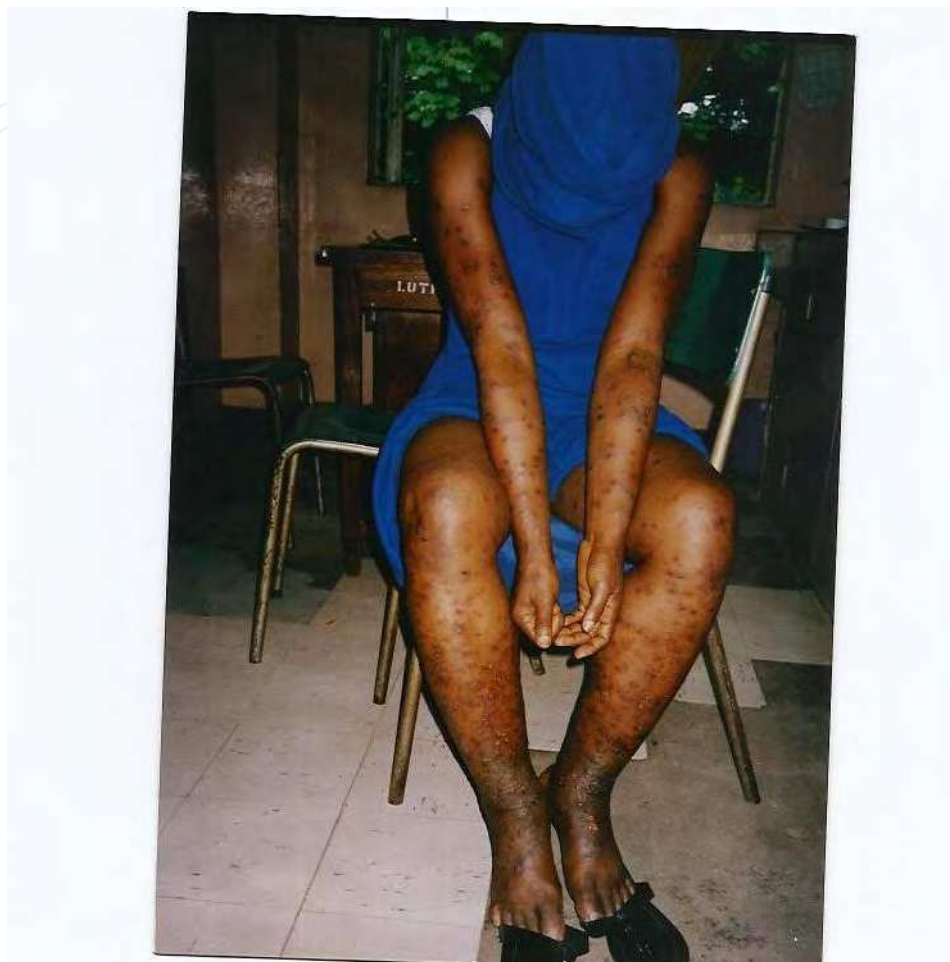

Fig. 4. Pruritic papular of HIV infection

3.9 Seborrheic Dermatitis

Seborrheic dermatitis (SD) is a chronic papulosquamous disorder characterized by distinctive morphology (red, sharply marginated lesion covered with greasy looking scales and hypopigmentation which is usually seen in dark skinned people) and a distinctive distribution in areas with a rich supply of sebaceous glands namely the scalp, forehead, eyebrows, lashline, nasolabial folds, beard and post auricular skin. Other areas include presternal region, inter scapular area, axillae, groin and gluteal crease.

The prevalence of seborrheic dermatitis is around 1-3% in the general population and 40-83% in HIV/AIDS patients.

The aetiology of SD is unclear. It has been suggested that the yeast *Pityrosporum ovale* is important in the aetiology of SD. Clinically, a wide spectrum of lesions exist but characteristic distribution; hypopigmented nummular patches which may coalesce to form polycyclic lesion on the back and presternal area; diffuse erythematous hypopigmented macules involving the scalp margins and butterfly areas of the face and trunk; scalp and

facial involvement presenting as dandruff and blepharitis; flexural, petaloid and pityrosporum folliculitis.


In Africa, hypopigmentation is a prominent feature which has been explained as a result of dicarboxylic acids produced by malassezia causing competitive inhibition of tyrosinase and perhaps a direct cytotoxic effect on hyperactive melanocytes (Altraide et al., 2010).

Seborrheic dermatitis in HIV/AIDS patients occur in varying severity (Altraide et al; 2010). It is usually characterized by thick micaceous scales and usually hyperkeratotic and inflammatory and more widespread and generalized.

Conclusion: Skin disorders are common in sub-Saharan African and may present with early, severe, unusual and atypical manifestations in the course of HIV infection. Awareness of the varied pattern of these manifestations would help in the early diagnosis and management of HIV infection, which would in turn decrease the morbidity and improve the quality of life of HIV-infected patients.

4. References

- Aftergut K., Cockerell CJ (1999). Update on the cutaneous manifestations of HIV infection. Clinical and pathologic features. *Dermatol. Clin.* Vol.17, No.3, pp. 445-71.
- Altraide DD, Olumide YM, Mohammed TT (2010). Predictive value of seborrheic dermatitis for HIV infection in Lagos Nigeria. *Port Harcourt Medical Journal.* 5(1): 30-36.
- Eisman S (2006). Pruritic papular eruption in HIV. *Dermatol. Clin.* Vol.24, pp.449-457.
- Johnson RA (1999). Cutaneous manifestations of human immunodeficiency virus disease. In: Friedberg IM, Eisen AZ, Wolf K, et al., eds. *Fitzpatrick's Dermatology*. McGraw- Hill, pp. 2138-2150.
- Machtinger EL, Van Beek M, Furmanski L, et al (2004). Etiology of pruritic papular eruption with HIV infection in Uganda. *JAMA.* ; vol292, pp.2614-2621.
- Olumide YM (2002). A self-instructed textbook of acquired immune deficiency syndrome (HIV/AIDS) for medical students, resident doctors and medical practioners. Longman Nigeria PLC pp.22-80.
- Schwartz RA, Micali G, Nasca MR, Scuderi L (2008). Kaposi sarcoma: a continuing conundrum. *J Am Acad Dermatol.* Vol.59, No. 2, pp. 179-206.
- Sterling JC, Kurtz JB. Viral infections: In. Champion RH, Burton JL, Burns DA, Breathnach SM eds *Rookwdkinson/Ebling, Textbook of dermatology* 6th edition. London 1998: Blackwell science LTD 2: 1057-1079.
- Tschachler E, Bergstresser PR, Stingl G (1996) . HIV-related skin diseases. *Lancet* Vol. 348, pp. 659-63.
- Wiwanitkit V. Prevalence of dermatological disorders in Thai HIV-infected patients correlated with different CD4 lymphocyte count statuses: a note on 120 cases. *Int J Dermatol* 2004; 43 (4): 265-8.



HIV and AIDS - Updates on Biology, Immunology, Epidemiology and Treatment Strategies

Edited by Dr. Nancy Dumais

ISBN 978-953-307-665-2

Hard cover, 694 pages

Publisher InTech

Published online 26, October, 2011

Published in print edition October, 2011

The continuing AIDS pandemic reminds us that despite the unrelenting quest for knowledge since the early 1980s, we have much to learn about HIV and AIDS. This terrible syndrome represents one of the greatest challenges for science and medicine. The purpose of this book is to aid clinicians, provide a source of inspiration for researchers, and serve as a guide for graduate students in their continued search for a cure of HIV. The first part of this book, “From the laboratory to the clinic,” and the second part, “From the clinic to the patients,” represent the unique but intertwined mission of this work: to provide basic and clinical knowledge on HIV/AIDS.

How to reference

In order to correctly reference this scholarly work, feel free to copy and paste the following:

Innocent Ochevana George and Dasetima Dandison Altraide (2011). Cutaneous Manifestations of HIV/AIDS in Sub-Sahara African, HIV and AIDS - Updates on Biology, Immunology, Epidemiology and Treatment Strategies, Dr. Nancy Dumais (Ed.), ISBN: 978-953-307-665-2, InTech, Available from: <http://www.intechopen.com/books/hiv-and-aids-updates-on-biology-immunology-epidemiology-and-treatment-strategies/cutaneous-manifestations-of-hiv-aids-in-sub-sahara-african>

INTECH
open science | open minds

InTech Europe

University Campus STeP Ri
Slavka Krautzeka 83/A
51000 Rijeka, Croatia
Phone: +385 (51) 770 447
Fax: +385 (51) 686 166
www.intechopen.com

InTech China

Unit 405, Office Block, Hotel Equatorial Shanghai
No.65, Yan An Road (West), Shanghai, 200040, China
中国上海市延安西路65号上海国际贵都大饭店办公楼405单元
Phone: +86-21-62489820
Fax: +86-21-62489821

© 2011 The Author(s). Licensee IntechOpen. This is an open access article distributed under the terms of the [Creative Commons Attribution 3.0 License](https://creativecommons.org/licenses/by/3.0/), which permits unrestricted use, distribution, and reproduction in any medium, provided the original work is properly cited.

IntechOpen

IntechOpen