

We are IntechOpen, the world's leading publisher of Open Access books Built by scientists, for scientists

6,900

Open access books available

186,000

International authors and editors

200M

Downloads

Our authors are among the

154

Countries delivered to

TOP 1%

most cited scientists

12.2%

Contributors from top 500 universities



WEB OF SCIENCE™

Selection of our books indexed in the Book Citation Index
in Web of Science™ Core Collection (BKCI)

Interested in publishing with us?
Contact book.department@intechopen.com

Numbers displayed above are based on latest data collected.
For more information visit www.intechopen.com



Clinical Treatment of Unruptured Ectopic Pregnancy

Julio Elito Junior

*Professor at the Obstetrics Department of the Federal University of São Paulo
Brazil*

1. Introduction

Ectopic pregnancy is a major public health problem worldwide. The incidence of ectopic pregnancy (EP) has been increasing recently. Currently, approximately up to 2% of pregnancies are ectopic (CDC, 1995). It is a leading cause of mortality in the first trimester of pregnancy (Berger et al., 2003). Furthermore, it is an important cause of morbidity and a high percentage of these patients may become infertile. For all these reasons efforts should be made to perform an early diagnosis before the occurrence of rupture. However, there can be misdiagnosis because the clinical presentation of ectopic pregnancy can simulate a variety of other pelvic diseases. Therefore, the physician must keep a high index of suspicion. Diagnosis has improved with the evaluation of the levels of beta-human choriongonadotropin hormone (beta-hCG) and through transvaginal ultrasound. Consequently, ectopic pregnancies can often be diagnosed before the patient's condition has deteriorated, which has changed the former clinical picture of a life-threatening disease into a more benign condition in frequently asymptomatic patients. As a result, early detection through non-invasive diagnosis makes it possible to perform conservative treatment, such as expectant management or medical treatment with methotrexate (MTX).

Additionally, atypical localization of ectopic pregnancies is associated with greater morbidity. In these situations medical treatment with systemic MTX and in cases with embryonic cardiac activity treatment with direct injection of potassium chloride or MTX has been used effectively. Clinical treatment avoids surgeries such as hysterectomy that end up being required in great number of cases of unusual localization.

In this chapter, it will be discussed aspects related to the conservative treatment of ectopic pregnancy, mainly clinical treatment with expectant management and medical treatment of methotrexate. The chapter will point out features of the selection criteria, methotrexate protocols, predictive factors of success and reproductive future.

2. Expectant mangement

Ectopic pregnancy is associated with life-threatening risk and is considered to be a dangerous disease. Fear of tubal rupture caused by the uncertainty of this clinical situation induces gynecologists to take rapid decisions to solve the problem. However, knowledge of this disease has demonstrated that patients present a broad spectrum of symptoms. Thus, ectopic pregnancy does not always end in tubal rupture. In some cases, even without

intervention ectopic pregnancies may progress to abortion from their tubal implantation with minimal bleeding or even be reabsorbed. The great challenge is to identify the cases in which intervention is unnecessary.

2.1 History

Lund (1955) was the first to describe expectant management in women with ectopic pregnancy. This retrospective study compared expectant management (119 cases) versus open surgery (85 patients). Women with a typical course of ectopic pregnancy and a positive pregnancy test without hemoperitoneum on admission formed the group of expectant management. These patients were hospitalized until the pregnancy test became negative and pain ceased, whereas the other group of women was operated. Surprisingly, expectant management was successful in 57% of women. In 20% an operation was carried out for signs of intra abdominal hemorrhage, while in 23% of women an operation was performed after a four weeks stay in the hospital with no signs of the disease becoming quiescent.

All subsequent studies of expectant management selected patients with unruptured ectopic pregnancy with declining titers of beta-hCG. In 1982, Mashiach et al. observed and treated a series of five cases with tubal pregnancy diagnosed by laparoscopy with serum beta-hCG concentrations ≤ 250 mIU/mL or decreasing, based on the knowledge that the natural course of many early ectopic pregnancies will result in tubal abortion or reabsorption. Expectant management was successful in four patients (80%).

Based on these works, some case series have been published describing expectant management in selected patients.

2.2 Inclusion criteria

As expectant management has been practiced based on the acknowledgement that the natural course of many early EPs is a self-limiting process. One important point is to select the best cases for this treatment.

The inclusion criteria for expectant management are: hemodynamically stable patients, beta-hCG ≤ 1500 mIU/mL, decline of the titers of beta-hCG in an interval of 24/48h, extraovarian adnexal mass ≤ 3.5 cm without fetal cardiac activity (Table 1). The exclusion criteria are patients with a viable ectopic pregnancy, signs of tubal rupture and active intra abdominal bleeding. The main inclusion criterion is the decrease of the levels of beta-hCG in an interval of 24/48h, because it represents that the pregnancy is in regression (Elito et al., 2008).

The maximum value of beta-hCG to adopt this management is controversial. The majority of studies recommend the treatment when the titers of beta-hCG is equal or less than 1500 mIU/mL (Hajenius et al., 1995). However, others perform the observation with beta-hCG > 1500 mIU/mL (Lang et al., 1997). Elito and Camano (2006) demonstrated that the mean values of beta-hCG were 648.8 ± 754.7 mIU/mL in the expectant management compared to 2642.7 ± 2315.1 mIU/mL in the methotrexate treatment. Another interesting observation in this study is the period of amenorrhea that was longer in the expectant management group (8.87 ± 1.71 weeks) compared to the MTX treatment (6.81 ± 1.88 weeks). Therefore, women diagnosed with ectopic pregnancy may be categorized into two groups: those with an early diagnosis, and those with a late diagnosis. Early diagnosis is characterized by a shorter time since the last menstrual period, serum beta-hCG levels increasing or maintained over 24 and 48-hour intervals, higher beta-hCG levels, rapid growth, and higher probability of tubal rupture. For that reason, these cases require medical treatment with methotrexate or

surgery. Late diagnosis is characterized by a longer time since the last menstrual period, beta-hCG levels decreasing over 24 and 48-hour intervals, lower beta-hCG levels, a latent prolonged clinical course, and lower chance of tubal rupture. Consequently, these cases require expectant management.

Expectant Management
Hemodynamically stable patients
Decline of the titers of beta-hCG < 15% in an interval of 24/48h
Beta-hCG < 1,500 mUI/ml
Extraovarian adnexal mass < 3.5 cm
Adnexal mass without embryonic cardiac activity
Desire of future fertility
Informed consent obtained

Table 1. Inclusion Criteria for Expectant Management (Elito et al, 2008)

2.3 Follow-up

Beta-hCG levels are followed up weekly to ensure that concentrations decline gradually until it becomes undetectable. Complete resolution of an ectopic pregnancy usually takes 20 days (range from 4 to 67 days). Kamrava et al. (1983) described that the serum clearance of beta-hCG may take at least up to 24 days after surgery. The same time necessary to complete resolution of an ectopic pregnancy managed expectantly. When declining beta-hCG levels rise again, there is a diagnosis of a persistent ectopic pregnancy. Success rates in several studies vary between 47.7% and 100% (van Mello et al., 2009) (Table 2). Transvaginal ultrasound is not required as a routine during the period of declining beta-hCG levels. However, patients with severe pain or pain that is prolonged should be evaluated by transvaginal ultrasound and hematocrit. Although the ultrasound findings are not helpful in the majority of patients, it can be use to reassure patient and physician that there ectopic pregnancy has not ruptured. It is important to realize that cul-de-sac fluid is very common, and the amount of fluid may increase if a tubal abortion occurs. For this reason, a surgical intervention is not necessary unless the patient has a typical clinical presentation of tubal rupture. The period for the regression of the adnexal mass at ultrasound is approximately of 3 months. During this period patients are asked not to become pregnant. When the tubal mass is not recognized at ultrasound the patient should be submitted to hysterosalpingography.

Authors	Cases	Success
Ylostalo et al, 1992	83	57 (68.7%)
Korhonen et al, 1994	118	77 (65.3%)
Cacciatore et al, 1995	71	49 (69%)
Trio et al, 1995	67	49 (73.1%)
Shalev et al, 1995	60	28 (47.7%)
Lui et al, 1997	17	17 (100%)
Han et al, 1999	70	69 (98.6%)
Olofsson et al, 2001	17	14 (82.4%)
Elson et al, 2004	107	75 (70.1%)

Table 2. Results of Studies of Expectant Management for Tubal Pregnancy

2.4 Predictive factors of success

The most commonly identified predictors of success of expectant management are beta-hCG levels decreasing over 24 and 48-hour intervals, lower initial beta-hCG levels, absence of gestational sac at ultrasound and longer time since the last menstrual period (Han et al, 1999; Elito e Camano, 2006). The mean levels of beta-hCG in the cases with success of the expectant management was 374mUI/ml, however when there was a failure the mean value was of 741 mUI/ml. Elson et al. (2004) observed that the success rate of the expectant management was 88% when beta-hCG levels was less than 200 mUI/ml, on the other hand the failure occur in 75% of the cases with beta-hCG > 2000 mUI/ml. Whereas the prognosis for successful expectant management has been demonstrated repeatedly to correlate with the initial hCG level, no consensus on a threshold value that best predicts success or failure has been established.

2.5 Randomized trials

Only two randomized controlled trials have been published on expectant management for ectopic pregnancy (Egarter et al., 1991; Karhonen et al., 1996).

Egarter et al. (1991) compared expectant management and local and systemic prostaglandins including 23 women with an unruptured ectopic pregnancy and a serum beta-hCG concentration <2,500 mIU/ml. This trial shows that expectant management was significantly less successful than prostaglandin therapy (RR 0.12, 95% CI 0.02 to 0.81).

Karhonen et al. (1996) compared expectant management versus systemic methotrexate. In this double blind placebo controlled trial, expectant management was compared with oral methotrexate in a low dosage (2.5 mg/day during five days) in 60 hemodynamically stable women with a small tubal ectopic pregnancy (<4 cm) without fetal cardiac activity and a serum hCG concentration <5,000 mIU/ml. This study virtually represents a comparison between two placebo treatments as is demonstrated in similar success rates of 77% in both treatment groups (RR 1.0, 95% CI 0.76 to 1.3). The mean serum hCG concentrations were low, i.e., 211 mIU/ml (range 20 to 1,343 mIU/ml) in the expectant group and 395 mIU/ml (range 61 to 4,279 mIU/ml) in the methotrexate group.

An evaluation of expectant management for tubal ectopic pregnancy cannot be adequately made with these trials. Recently, there is a well-designed trial that will evaluate expectant management in the treatment of ectopic pregnancy. In a double blinded setting, single dose intramuscular methotrexate is compared with placebo in selected women with an ectopic pregnancy and a serum hCG concentration < 1500 mIU/ml. Therefore, nowadays the efficacy of expectant management for tubal ectopic pregnancy cannot be adequately evaluated (Hajenius et al., 2007).

2.6 Reproductive future

The fertility of women managed expectantly for an unruptured ectopic pregnancy can be determined by hysterosalpingography (HSG) or a spontaneous pregnancy (Rantala e Mäkinen, 1997; Debby et al., 2000). In spite of the inconveniences and interpretation doubts, HSG is considered a good examination to evaluate the tube patency (Gladstein et al., 1997).

Hysterosalpingography is an important diagnostic method after conservative treatment of an ectopic pregnancy (Mol et al., 1997). If HSG demonstrates tubal patency, there is a possibility of spontaneous pregnancy; and in cases revealing obstruction in both tubes; the treatment is fertilization *in vitro*. Hysterosalpingography usually is performed 3 months

after expectant management, when the adnexal mass usually disappears on ultrasound examination.

Elito et al. (2005a) showed a patency rate of 78% in the ipsilateral tube in women managed expectantly, which was similar to the rates reported in other studies (Stovall et al., 1991; Debby et al., 2000). The patency rate of the contralateral tube was 92% in women managed expectantly, which is also similar to the rates in other reports (Stovall et al., 1991; Zohav et al., 1996; Mass et al., 1997).

When clinical treatment is chosen for unruptured ectopic pregnancy and tubal patency is evaluated via HSG, doubts arise: Could the tubal obstruction precede the ectopic pregnancy, or could it be a consequence of the treatment? To answer this question the obstruction of the contralateral tube has to be determined. Elito et al. (2005a) demonstrated that it occurred in 8% of the women managed expectantly. These results suggest that some of the women probably had an obstruction of the contralateral tube before the ectopic pregnancy, probably caused by salpingitis. The obstruction rate of the ipsilateral tube was 22% in the expectant management. Comparing these rates with those for contralateral tube obstruction (8%) shows that the difference between the obstruction rates for the ipsilateral and contralateral tubes could be a consequence of the tubal pregnancy treatment. Thus, the contralateral tube may give a picture of the tubal status previous to the tubal pregnancy. The difference between the obstruction rates of the ipsilateral and the contralateral tubes after clinical treatment may demonstrate which women experience tubal obstruction as a sequel of the nonsurgical treatment.

The spontaneous healing of EP should not harm the tube and should result in a good long-term fertility outcome. However, normal radiologic findings show nothing about tubal function, since a disturbance can also be a cause for ectopic pregnancy. On the other hand, if the HSG demonstrates obstruction of the tubes, these results reduce the possibility of a spontaneous pregnancy and the patients should be offered *in vitro* fertilization.

3. Medical treatment

3.1 Systemic treatment

Systemic methotrexate for the treatment of gestational trophoblastic disease has been used since 1956 (Li et al., 1956). MTX is a folic acid antagonist. Folic acid normally is reduced to tetrahydrofolate by the enzyme dihydrofolate reductase (DHFR), a step in the synthesis of DNA and RNA precursors. MTX inhibits DHFR, causing depletion of cofactors required for DNA and RNA synthesis. When multiple doses of MTX are used, side effects may occur, such as gastric distress, nausea, vomiting, ulcerative stomatitis, dizziness and some rare situations like severe neutropenia, reversible alopecia and pneumonitis. Folinic acid is an antagonist to MTX that can help reduce side effects, particularly when multiple doses of MTX are used (Barnhart et al., 2001). Long-term follow-up of cases treated with MTX for gestational trophoblastic disease shows no increase in congenital malformation or spontaneous abortions. Therefore, none would be expected after treatment of ectopic pregnancy because a smaller dose is required and shorter treatment duration is used.

3.1.1 History

At first, methotrexate was used for the treatment of placenta left in situ after laparotomy for an abdominal pregnancy. Tanaka et al. (1982) during a laparotomy identified an advanced but unruptured interstitial pregnancy in a young patient. The authors to avoid the surgery that could compromise the reproductive future opted for a medical treatment with multiple

doses of intramuscular MTX. Since the beginning of the medical treatment of ectopic pregnancy, starting in 1982 with Tanaka et al., it has represented an important alternative for the treatment of ectopic pregnancy. Several authors have been studying this therapeutic treatment (Stovall et al., 1989; Elito et al., 1999a; Lipscomb et al., 2000). One important study to consider is that performed by Stovall et al. In 1989, it individualized the methotrexate dosage to improve patient compliance, to minimize side effects, and to reduce overall costs, which ultimately led to a single-dose regimen of 50 mg/m² body surface area intramuscular without folinic acid.

3.1.2 Selection criteria

Selection criteria for the systemic treatment with MTX are: hemodynamic stability, extraovarian adnexal mass \leq 3.5cm, beta-hCG \leq 5000 mUI/ml, no severe or persistent abdominal pain, commitment to follow-up until the ectopic pregnancy has resolved, and desire of future pregnancy (Table 3). The exclusion criteria are: intrauterine pregnancy, presence of free fluid in peritoneal cavity, adnexal mass with embryonic cardiac activity detected by transvaginal ultrasonography, decline of more than 15% in the levels of beta-hCG in an interval of 24 h prior to the treatment, hepatic dysfunction, blood dyscrasia, renal disease, evidence of immunodeficiency, sensitivity to MTX, active pulmonary or peptic ulcer disease and refusal to accept blood transfusion (Elito et al., 2008) (Table 4 and 5). Prior to the treatment, women should be screened with a complete blood count, liver function tests, serum creatinine and blood type and Rh (prescribe Rhogam if patient is Rh negative). Patients having a history of pulmonary disease should also have a chest x-ray (ASRM Practice Committee, 2008).

- Hemodynamic stability
- Extraovarian adnexal mass < 3.5cm
- No severe or persistent abdominal pain
- Desire of future pregnancy
- Commitment to follow-up until the ectopic pregnancy has resolved
- Informed consent obtained

Table 3. Inclusion Criteria for Systemic Methotrexate (Elito et al, 2008; ASRM Practice Committee, 2008)

- Intrauterine pregnancy
- Evidence of immunodeficiency
- Moderate to severe anemia
- Leukopenia (Leukocytes < 2000 Cel/Mm3)
- Thrombocytopenia (Platelets < 100000)
- Sensitivity to Methotrexate
- Active pulmonary disease
- Active peptic ulcer disease
- Clinically important hepatic or renal dysfunction
- Breast feeding

Table 4. Absolute Contraindications for Systemic Methotrexate (Elito et al, 2008; ASRM Practice Committee, 2008)

- Embryonic cardiac activity detected by transvaginal ultrasonography
- High initial hCG concentration (>5,000mIU/mL)
- Decline of the titers of beta-hCG > 15% in an interval of 24/48h
- Refusal to accept blood transfusion
- Inability to participate in follow-up

Table 5. Relative Contraindications for Systemic Methotrexate (Elito et al, 2008; ASRM Practice Committee, 2008)

3.1.3 Methotrexate protocols (single and multiple doses)

There are two commonly used MTX treatment protocols: single dose and multiple doses (Barnhart, 2009). The single dose MTX treatment uses a 50mg/m² intramuscular dose (Stovall et al., 1993; Elito et al., 1999a). Body surface area is calculated based in height and weight conformed Table 6. As a follow-up beta-hCG levels are tested on days 1, 4 and 7 after MTX injection. The protocol stipulated that any patient who did not have a 15% decline in the beta-hCG levels between days 4 and 7, should be given a second intramuscular dose of MTX (50mg/m²) one week after the first dose. Patients with declining beta-hCG levels > 15% between days 4 and 7 were monitored weekly until the beta-hCG levels decreased below 5 mIU/ml. The term “single dose” is actually misleading. Whereas it describes the number of MTX injections planned, the treatment may include additional doses of MTX (maximum 3 doses) when the response is inadequate (Stovall et al., 1993; Barnhart, 2009).

Height cm Weight kg	150	155	160	165	170	175	180
40	1,30	1.33	1.37	1.40	1.43	1.46	1.49
45	1.37	1.40	1.44	1.47	1.50	1.53	1.56
50	1.43	1.47	1.50	1.54	1.57	1.60	1.64
55	1.49	1.53	1.56	1.60	1.63	1.67	1.70
60	1.55	1.59	1.62	1.66	1.70	1.73	1.77
65	1.60	1,64	1.68	1.72	1.75	1.79	1.83
70	1.65	1.69	1.73	1.77	1.81	1.85	1.89
75	1.70	1.74	1.78	1.82	1.86	1.90	1.94
80	1.75	1.79	1.83	1.87	1.92	1.96	2.00
85	1.80	1.84	1.88	1.92	1.97	2.01	2.05
90	1.84	1.88	1.93	1.97	2.01	2.06	2.10

Table 6. Calculation Body Surface Area (log BSA = 0.425 log W + 0.725 log H - 2.1436) (Du Bois, Du Bois, 1916).

The multiple-dose protocol alternates 4 intramuscular doses of MTX (1mg/kg) with 4 intramuscular doses of leucovorin (0,1 mg/kg). The patients are followed up with beta-hCG levels in the day of MTX injection. MTX is continued until beta-hCG falls by 15% from its peak concentration. Approximately 50% of patients will not require the full 8-day regimen (Pisarka et al., 1998). A meta-analysis of nonrandomized studies showed success rates of 93% for multiple-dose treatment and 88% for single-dose therapy (Barnhart et al., 2003). The odds ratio for failure of single-dose therapy as compared with multiple-dose therapy was

2.0 after adjustment for the beta-hCG value and 4.8 after adjustment for the presence of fetal cardiac activity. As compared with the multiple-dose treatment, the single-dose protocol is more simple, commonly used, requires fewer visits and has fewer side effects. For all these reasons it should be the first option in cases of tubal pregnancy with levels of beta-hCG less than 5000 mIU/mL (Elito et al, 1999a). On the other hand, in cases of non-tubal pregnancy with high levels of beta-hCG more than 5000 mIU/mL, the best choice is the protocol of multiple-dose of MTX.

Recently, an alternative protocol of MTX was described. In this protocol women received 2 doses of methotrexate 50mg/m² IM (Barnhart et al., 2007). The initial day of treatment was designated day 0. Patient returned on day 4 and received the second dose of MTX, and the beta-hCG level was measured. On day 7, the beta-hCG level was measured and compared with the level on day 4. If there was a decline of at least 15%, the treatment was considered successful. These patients were monitored weekly until the beta-hCG levels decreased below 5 mIU/ml. The protocol stipulated that any case who did not have a 15% decline in the beta-hCG levels between days 4 and 7, should be given a third intramuscular dose of MTX (50mg/m²) on day 7. Patients then returned on day 11 for another beta-hCG measurement. If the beta-hCG level declined by at least 15% between day 7 and 11, the treatment was deemed successful and weekly beta-hCG levels were verified until the results were negative. If not, a fourth dose of MTX was administered, and a beta-hCG level was checked on day 14. If the beta-hCG titers declined at least 15% between days 11 and 14, the treatment was considered successful. Otherwise, the patient was referred for surgical treatment. The two-dose regimen was designed to increase the likelihood of successful therapy without more visits than are required with a single-dose regimen, but it has not been directly compared with the other regimens. One important consideration is that two-dose protocol should be indicated in cases with increase beta-hCG levels on day 4 after MTX.

When the criteria for MTX treatment are fulfilled, treatment success rates are comparable to those achieved with conservative surgery (Hajenius et al., 1997). Numerous open-label studies have been published demonstrating the efficacy of MTX protocols. One review concluded that MTX treatment was successful in 78%–96% of selected patients (Lipscomb et al., 2000).

3.1.4 Follow-up

Patients with declining beta-hCG levels after MTX protocols (single or multiple-dose) are monitored weekly until the beta-hCG levels are negative. Elito et al. (1998) evaluated the interval of time for beta-hCG levels to become negative. It took 15 days in 50% of the cases, 15 to 30 days in 38.8% and more than 30 days in 11.2% of the cases. Complete resolution of an ectopic pregnancy usually takes between 2 and 3 weeks but can take as long as 6 to 8 weeks when pre-treatment beta-hCG levels are in higher ranges (Elito et al, 1999a; Pisarka et al, 1998; Barnhart et al, 2003). When declining beta-hCG levels rise again, the diagnosis of a persistent trophoblastic tissue is made. Another important consideration is that the period for the regression of the tubal mass at ultrasound range from 3 to 6 months (Brown et al., 1991). Elito et al. (1996) evaluated the period necessary for the complete resolution of the tubal mass at ultrasound and observed that it took more than 30 days in 62.5% of the cases. Therefore, serial ultrasonographic examinations after MTX treatment are unnecessary because ultrasonographic findings cannot demonstrate or predict treatment failure, unless evidence of recent tubal rupture is observed (Atri et al., 1992).

Although several treatment protocols have been developed, it is prudent to inform the patient some instructions for the follow-up after the systemic treatment with MTX. Patients should avoid: sexual intercourse until beta-hCG levels is negative, sun exposition to minimize the risk of dermatitis after MTX, alcohol use, nonsteroidal antiinflammatory drugs (in cases of pain prescribe acetaminophen), foods and multivitamins containing folic acid, become pregnant for at least 3 months (risk of teratogenicity).

MTX is a safe treatment for an unruptured ectopic pregnancy. Life-threatening complications rarely have been reported with MTX (Isaacs et al., 1996). Approximately 40% of the patients feel pain between 3 and 7 days after MTX injection, but such pain normally resolves within 4 to 12 hours (Lipscomb et al., 1999). In cases of acute pain, it is important to rule out tubal rupture. Therefore, it is prudent to evaluate the patient's vital signs and hematocrit, and if rupture is suspected, surgery should be performed.

Signs of treatment failure or suspected rupture are indications to abandon medical treatment and to proceed with surgical treatment. Signs suggesting treatment failure or possible rupture include hemodynamic instability; increasing abdominal pain, regardless of trends in beta-hCG levels; and rapidly increasing beta-hCG concentrations after methotrexate treatment (ASRM Practice Committee, 2008).

More commonly encountered treatment effects of MTX are increase in abdominal girth, increase in beta-hCG during initial therapy, vaginal bleeding or spotting and abdominal pain. The commonly side effects encountered are gastric distress, nausea and vomiting, stomatitis, dizziness, and other rare conditions such as severe neutropenia, reversible alopecia and pneumonitis (ASRM Practice Committee, 2008).

Sexual intercourse is allowed when the beta-hCG titer is negative. At this moment, patients are instructed to begin contraceptive methods until the regression of the adnexal mass at ultrasound. Patients are asked not to become pregnant for at least 3 months following the completion of treatment so that a hysterosalpingography can be performed.

3.1.5 Predictive factors of success

Although the failure of the treatment is not very high, when the tubal rupture occurs after a few days, a doubt arises: Would it not been better to perform a conservative surgery at the moment of the early diagnosis? To reduce the failure of the treatment several authors studied the predictive factors for the success of MTX treatment. Initial level of beta-hCG is one of the most important variables in the prediction of therapeutic response to MTX in patients with an ectopic pregnancy. The evolution of ectopic pregnancy depends on the degree of trophoblast invasion. Intense trophoblastic activity is more frequently associated with tubal rupture, while lesser activity is associated with a lower capacity of invasion and a greater likelihood of success with MTX treatment. The invasion of the trophoblastic tissue in patients with an ectopic pregnancy may be calculated from their serum beta-hCG level. In studies carried out in fallopian tubes affected by ectopic pregnancy, Natale et al. (2003) used histopathology to demonstrate that the concentration of beta-hCG was proportional to the degree of invasion of the tubal wall. Therefore, the higher is the beta-hCG level, the greater is the invasion of the trophoblast and the lesser the likelihood of therapeutic success with MTX (Menon et al., 2007). If the beta-hCG level is low, then the likelihood of therapeutic success is high; however, if beta-hCG is high, surgery would be preferable. Lipscomb et al. (1999) noted that the failure rate of single-dose treatment was 13% (6/45) for initial beta-hCG values between 5,000 IU/L and 9,999 IU/L, 18% (4/22) for concentrations between

10,000 IU/L and 14,999 IU/L, and 32% (7/22) when beta-hCG values exceeded 15,000 IU/L. Elito et al. (1999) have reported failure rates of 62% when the initial beta-hCG concentration is over 5,000 IU/L. Systematic review combining all published data yields an odds ratio for failure of 5.45 (95% CI, 3.04–9.78) when the initial beta-hCG value above 5,000 IU/L compared with that observed when beta-hCG concentrations are below that threshold (Menon et al., 2007). Because the failure rate rises with the pre-treatment beta-hCG concentration, the single-dose MTX treatment regimen may be better reserved for patients with a relatively low initial beta-hCG level (Elito et al., 1999a; Barnhart et al., 2003; Potter et al., 2003).

Attempting to improve the selection of patients for the medical treatment with MTX and reduce the likelihood of therapeutic failure, some authors evaluated an additional predictive variable: the increment in beta-hCG levels in the 48-h interval prior to administration of MTX (Dudley et al., 2004; da Costa Soares et al., 2008). The hypothesis is that the increase in beta-hCG levels in the 48-h period prior to treatment would represent a dynamic assessment of the degree of evolution of the ectopic trophoblastic tissue and, consequently, of its invasion and its probable response to treatment. Moreover, this variable is easily obtainable. Da Costa Soares et al. (2008) demonstrated that the average increment in beta-hCG levels in the 48-h period prior to treatment was greater in the patients with therapy failure when compared to the cases of therapeutic success (36.28 vs. 13.15%, respectively). One important point to consider is that when initial beta-hCG level is low but its increment in the 48-h period is high, this is indicative of an ectopic trophoblastic tissue with a high degree of invasion, and the risk of tubal rupture is high so surgical treatment is preferable. Furthermore, when beta-hCG is elevated, this parameter alone is sufficient to serve as a guideline for treatment, with good sensitivity and specificity. Nevertheless, in cases of early diagnosis (the ideal situation for non-surgical treatment), baseline beta-hCG is generally low and in this situation the increment in beta-hCG values in the 48-h period prior to treatment is of great importance, since depending on the evolution of beta-hCG, the predicted response to nonsurgical treatment may be better assessed, leading to increased specificity and sensibility with respect to the success of treatment. Dudley et al. (2004) reported that the increase in beta-hCG prior to diagnosis and the increase in beta-hCG following MTX therapy were more accurate predictors of tubal rupture than beta-hCG on the day of MTX therapy. These results suggest that the changes in beta-hCG prior to and following MTX administration represent independent risk factors for subsequent tubal rupture.

Another important consideration is the aspect of the image at ultrasound (hematosalpinx, tubal ring and live embryo) (Figure 1 and 2). Elito et al. (1999a) observed better results with hematosalpinx image and worse results with live embryo. Several authors considered relative contraindications for systemic treatment with MTX the presence of embryonic cardiac activity detected by transvaginal ultrasonography (Lipscomb et al., 1999; Tawfiq et al., 2000).

Other variables that may be predictive of therapeutic response to MTX in cases of ectopic pregnancy are: size and volume of the gestational mass (≤ 3.5 cm), absence of free peritoneal blood and endometrial thickness (<7 mm) (Elito et al., 1999a; Soares et al., 2004; da Costa Soares et al., 2008).

Therefore, factors that are associated with failure of medical management include initial beta-hCG values greater than 5000 mIU/mL, ultrasonographic detection of a moderate or large amount of free peritoneal fluid, the presence of embryonic cardiac activity, and a pretreatment increase in the serum hCG level of more than 50% over a 48-hour period (ASRM Practice Committee, 2008).

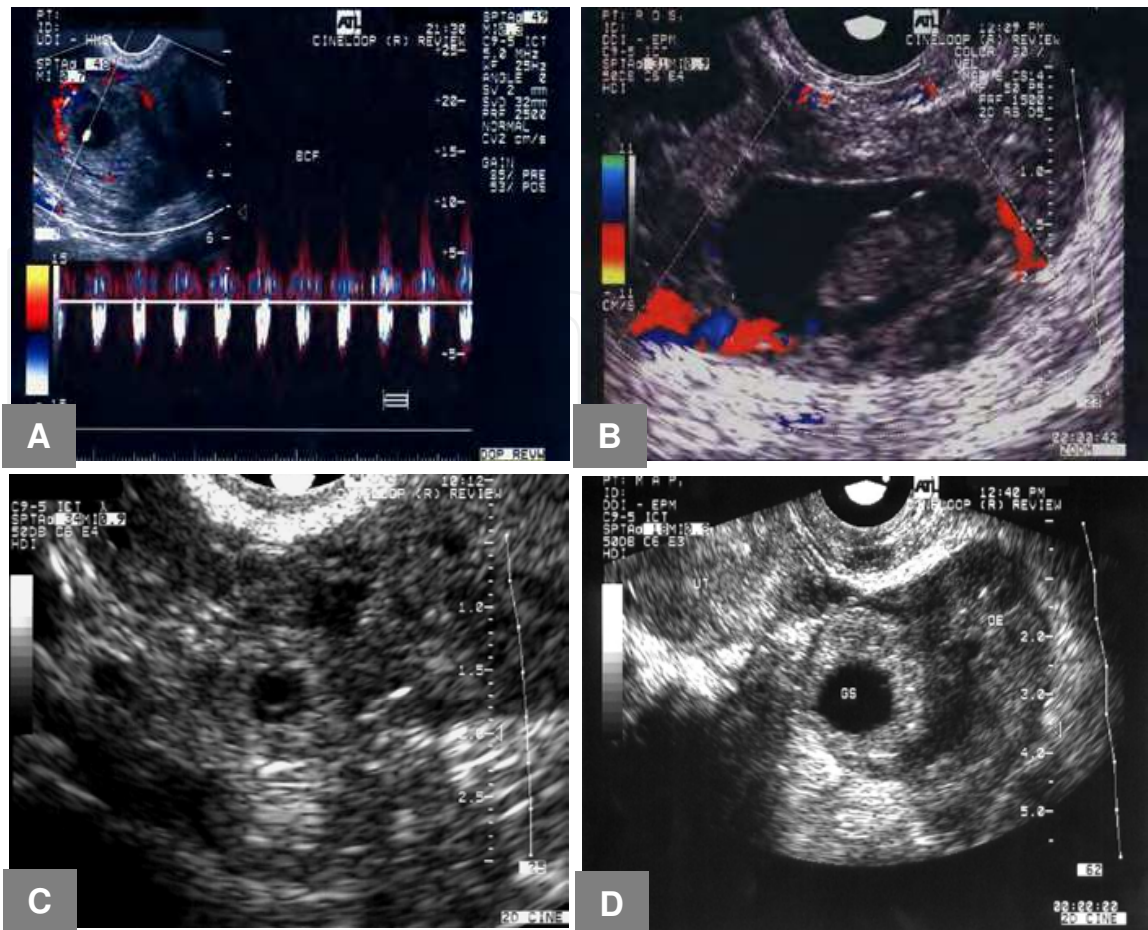


Fig. 1. Ultrasound of ectopic pregnancy with tubal ring: A) extra-uterine gestational sac with live embryo. B) gestational sac with absence of embryonic cardiac activity. C) gestational sac with yolk sac. D) gestational sac without yolk sac or fetal pole (Elito, Camano, 2010a).

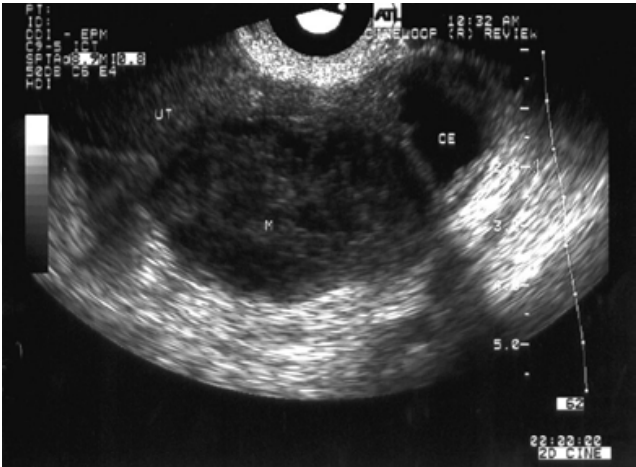

Fig. 2. Ultrasound of tubal pregnancy with hematosalpinx (Elito, Camano, 2010a).

3.1.6 Reproductive future

The fertility outcome of patients treated conservatively with MTX for unruptured EP can be evaluated by means of hysterosalpingography (HSG) or future pregnancy (Debby et al.,

2000). Elito et al. (2005b) showed that 84% of the diseased tubes were pervious after MTX treatment for ectopic pregnancy by HSG, similar to the rates in other reports that demonstrated post-treatment hysterosalpingography documented tubal patency in 78% of cases (Lipscomb et al., 2000; Stovall et al., 1991). This high rate of radiologically normal tubes after clinical treatment proves that the spontaneous regression of EP does not result in an increased harm or damage to the tube – i.e. the risk of repeating EP is rather low. However, the radiologically normal findings show nothing about the tubal function, when a disturbance can also be a cause of EP. On the other hand, if the results of HSG demonstrate obstruction of the tubes, the possibility of a spontaneous pregnancy will be reduced and should be treated with *in vitro* fertilization. Elito et al. (2005b) showed that beta-hCG levels were directly related to the obstruction of the tube. The increase in beta-hCG levels was followed by an enhancement in tubal obstruction risk. The explanation for these events is probably that in patients with high level of beta-hCG there is more invasion of the trophoblast tissue at the serosa of the tube, which increases damage to the tube.

The parameter considered most important for MTX treatment of unruptured EP is beta-hCG. Several authors have demonstrated its importance (Elito et al., 1999a; Lipscomb et al., 1999) and shown that the higher the level of beta-hCG, the lower the chances of successful treatment. Patients with indication for clinical treatment of EP usually have an important desire for future pregnancy. It is important to have a parameter, such as the levels of beta-hCG, in order to predict the tube sequel.

Lipscomb et al. (2000) demonstrated that 65% of patients who attempted subsequent pregnancies succeeded, and the incidence of recurrent ectopic pregnancy was a relatively low 13% (Stovall et al., 1989; Lipscomb et al., 2000).

3.2 Local treatment

Methotrexate can be administered locally in the tube. Efforts to attain maximal efficacy and minimize adverse effects of systemic MTX resulted in various protocols for local medical treatment administered into the gestational sac transvaginally under sonographic or under laparoscopic guidance. Drugs that have been used for local treatment are methotrexate 1mg/kg (Feichtinger, Kemeter, 1987; Pansky, Bubowski, 1989; Fernandez et al., 1993), KCL, prostaglandins, and hyperosmolar glucose.

3.2.1 History

Feichtinger and Kemeter (1987) described the first case where local treatment with MTX was administered into the gestational sac transvaginally under sonographic. The authors used the same technique used for retrieval of the oocytes from the ovary using a transvaginal technique involving an ultrasound-guided needle utilized for *in vitro* fertilization. The gestational sac of the tubal pregnancy was puncture and injected 10 mg of MTX. The case was treated successful and without side effects.

In 1989, Panski et al. presented another via to puncture the tubal pregnancy by laparoscopy. The gestational sac of 27 patients was punctured and injected 12,5 mg of MTX. The success rate was 88,9%, there are no side effects and tubal patency was 90.5%.

3.2.2 Selection criteria

Local treatment is indicated in ectopic pregnancies with embryonic heart activity, especially in cases of non-tubal ectopic pregnancies (Elito et al., 2008). One important point to consider

is that in cases of ectopic pregnancy with absence of embryonic cardiac activity, there is no reason to submit the patient to ultrasound-guided injection. In these cases the systemic treatment with MTX is considered to be the best choice. Although local injection appears to be relatively safe and as effective as systemic methotrexate, this approach requires an additional procedure and a certain degree of expertise and added cost. A further consideration is that the appropriate dose of local MTX is yet to be determined. Several doses of MTX have been described (Benifla et al., 1996; Sagiv et al., 2001; Lin et al., 2007). The most used is a dose of 1 mg/kg body weight and this is the dose selected for the study (Fernandez et al., 1993)). However, other doses including 100 mg single dose (Lin et al., 2007), 50mg/m² body surface (Lim et al., 2007) and an unadjusted dose of 12.5 mg have been used (Sagiv et al., 2001). Transvaginal ultrasound is the preferred mode for guidance and laparoscopic guidance has a limited role. The procedures were carried out under general anesthesia. The patient was placed in the lithotomy position. Methotrexate was injected under transvaginal ultrasound guidance, a 22-gauge, 15 cm Wallace needle was inserted via vaginal route into the embryonic heart and 1 ml (2 mEq/ml) KCL solution was injected. Following the cessation of embryonic cardiac activity, the tip of the needle was directed into the gestational sac and some amniotic fluid was aspirated. Then, a 1 mg/kg dose of MTX was injected into the gestational sac. The transvaginal administration of methotrexate under sonographic guidance requires visualization of an ectopic gestational sac and specific skills and expertise of the physician. Compared to the local treatment, systemic methotrexate is practical, easier to be administered, and less dependent from clinical skills. In combination with non-invasive diagnosis, systemic methotrexate offers the option of a totally non-invasive outpatient management. Therefore, the local treatment is restricted to the cases of non-tubal ectopic pregnancy with live embryo (Chetty et al., 2009).

3.2.3 Follow-up

Patients are followed up with beta-hCG levels on days 4 and 7 after MTX injection. The protocol stipulates that any patient, who did not have a 15% decline in the beta-hCG levels between days 4 and 7, would be given an intramuscular dose of MTX (50 mg/m²). In cases of ectopic pregnancy with high levels of beta-hCG the use of only ultrasound-guided injection seems to be less effective and the combination of systemic treatment of MTX could improve the results. On the other hand, patients who present a decline of more than 15% in the beta-hCG levels in this period are monitored weekly until the beta-hCG levels are below 5 mUI/ml. Follow up also includes clinics visits and repetition of transvaginal ultrasound if necessary. After approximately 3 months of treatment when the ectopic pregnancy disappeared at transvaginal ultrasound, a hysterosalpingography is performed.

4. Atypical ectopic pregnancies

The main localizations of atypical ectopic pregnancies are: cervical, caesarean scar, ovarian, interstitial, cornual and abdominal. This group represents less than 10% of all ectopic pregnancies but is associated with greater morbidity (Jourdain et al., 2003). Traditionally these pregnancies have been lately diagnosed and managed by open surgery. Advances in ultrasound technology have led to an increase in the early diagnosis of non-tubal ectopic pregnancies. This means that management of these rare cases of ectopic pregnancy has now progressed from open surgical management to the use of minimally invasive access

techniques and the exploration of medical and conservative treatments either alone or as adjuvant therapies.

4.1 Interstitial pregnancy

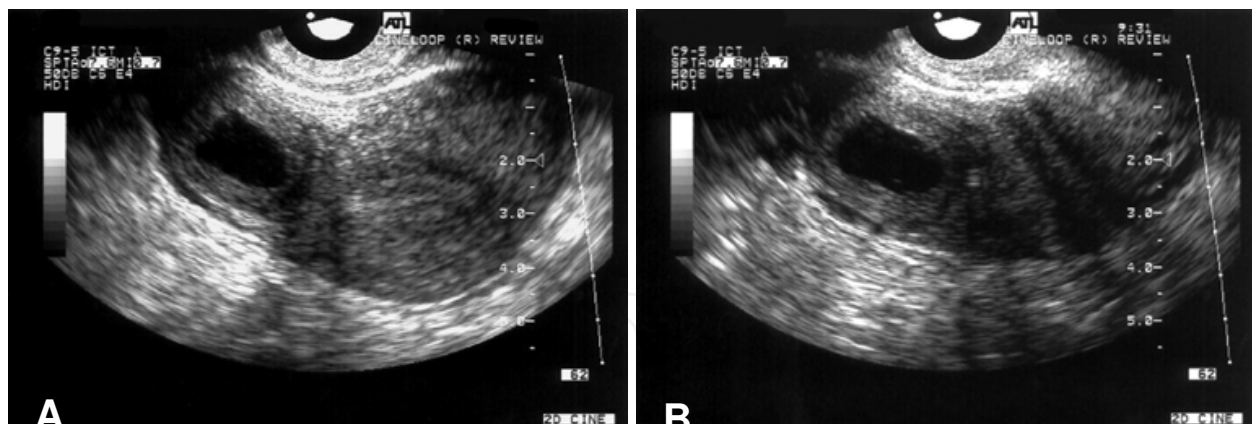
Interstitial pregnancy is an ectopic pregnancy that implanted in the interstitial portion of the fallopian tube. The interstitial portion is constricted, with its lumen being as narrow as 0.1mm to 0.7 mm in diameter and 1-2 cm in length, this relatively thick section of the tube has a significantly greater capacity to expand before rupture than do the distal tubal segments (Eddy, Pauerstein, 1980). For this reason, in some cases the interstitial pregnancy may remain asymptomatic until 7-16 weeks of gestation, at which time rupture can result in important hemorrhage (Lau, Tulandi, 1999). Because of the rich vascular anastomosis of the uterine and the ovarian arteries in this region there can be accentuated hemorrhage. Therefore, early diagnosis is essential to reduce morbidity and mortality.

Interstitial pregnancies are an uncommon form of ectopic pregnancy, account for only 2-4% of tubal pregnancies or approximately 1 in 2500-5000 live births (Damario et al., 2003). Despite their rarity, the mortality rate is as high as 2.5%, a rate that is 7 times greater than that of ectopic pregnancies in general (Walker, 2007). This is because the difficult diagnose that often presents late with rupture and hemorrhage.

Interstitial pregnancy sometimes is incorrectly confused with cornual and angular pregnancies. It is important to make a distinction among these conditions because their behavior, management, and outcomes are different. In contrast to interstitial pregnancy, an angular pregnancy refers to a viable intra-uterine pregnancy that is implanted in one of the lateral angles of the uterine cavity, medial to the uterotubal junction. During laparoscopy, angular pregnancy appears as an asymmetric protuberance in one of the uterine angles, medial to the round ligament. On the other hand, interstitial pregnancy appears lateral to the round ligament.

Cornual pregnancy refers to a pregnancy in a horn of a bicornuate uterus. The clinical outcome of cornual pregnancy varies greatly, depending on the size and expansile nature of the affected horn.

Traditional treatments for interstitial ectopic pregnancy have ranged from exploratory laparotomy with cornual wedge resection to total abdominal hysterectomy. However, the development of high-resolution ultrasound evaluation and rapid quantitative beta-hCG exams has advanced the detection of interstitial gestations before rupture, which, in turn, has made possible more conservative treatment options for the patient whose condition is hemodynamically stable. Risk factors for interstitial pregnancy are tubal damage from previous ectopic pregnancy, previous ipsilateral or bilateral salpingectomy, conception after *in vitro* fertilization, and history of sexually transmitted disease (Tulandi, Al-Jaroudi, 2004). The most common symptoms of interstitial pregnancy are abdominal pain and vaginal bleeding in the first trimester of pregnancy. On physical examination, an asymmetric uterine enlargement may be palpable. Signs of acute abdomen may be elicited in cases of cornual rupture and hemoperitoneum; in severe cases, tachycardia and subsequent hypotension may be evident. Early diagnoses of interstitial pregnancies are often discovered in asymptomatic patients during transvaginal ultrasound that is performed in the first trimester. Ultrasonographic criteria for diagnosis is an empty uterine cavity, an eccentricity of the gestational sac, a chorionic sac separate and at least 1 cm from the lateral edge of the uterine cavity, and a presence of a myometrial tissue that surrounds the gestational sac with a thickness of ≥ 5 mm (Timor-Tritsch et al., 1992; Ackerman et al., 1993) (figure 3).



A) Transversely oriented transvaginal ultrasound. B) Longitudinally oriented transvaginal ultrasound.

Fig. 3. Interstitial ectopic pregnancy: presence of an eccentric gestational sac with myometrial tissue that surrounds the gestational sac with a thickness of 2 mm (Elito, Camano, 2010).

Despite the advent of conservative strategies, the most appropriate technique for treatment of interstitial pregnancy and treatment of these patients during subsequent pregnancies remains controversial. Treatment options depend on the extent of uterine wall trauma, whether rupture has occurred and the patient's desire for future pregnancy. If the diagnosis is made before rupture, minimally invasive surgery and nonsurgical treatment options can be used. Conservative options include methotrexate administration (local and systemic), expectant management and minimally invasive surgical techniques that include resection of the involved tube and pregnancy alone with preservation of the uterine architecture. The potential advantage of clinical treatment is to avoid a surgical scar on the uterus and the risks that are associated with surgery.

Expectant management that has been practiced based on the natural course of many early EPs is a self-limiting process (Zalel et al., 1994). The inclusion criteria for this management are hemodynamically stable patients, beta-hCG ≤ 1500 mUI/ml, decline of the titers of beta-hCG in an interval of 24/48h, small interstitial pregnancy mass without fetal cardiac activity. The most important disadvantage of expectant management is the risk of rupture and associated maternal morbidity and death.

Systemic methotrexate treatment was used for the first time in an interstitial pregnancy. In 1982, Tanaka et al. treated successfully an interstitial pregnancy with multiple dose of methotrexate. Ectopic interstitial pregnancies without embryonic cardiac activity and beta-hCG ≤ 5000 mUI/ml should be treated with single dose of MTX 50 mg/m² IM. Cases with beta-hCG > 5000 mUI/ml should be treated with multiple doses of MTX. On the other hand, cases with embryonic heart activity should be treated with transvaginal administration of MTX and KCL under sonographic guidance. The major risk for patients after treatment of interstitial pregnancy is uterine rupture during subsequent pregnancy and the risk of recurrent interstitial pregnancy. Careful prenatal with a planned cesarean delivery at term appears to be the safest approach (Moawad et al., 2010).

4.2 Cervical pregnancy

Cervical pregnancy is an atypical localization and represents less than 1% of all ectopic pregnancies (Pisarka, Carson, 1999). It is a high-risk condition because of the possibility of

severe hemorrhage. Baptiste (1953) said: “The great majority of certified obstetricians will never see a cervical pregnancy. The minority who do happen to encounter this complication will probably wish they had not”.

The endocervix is eroded by the trophoblast that invade the fibrous cervical wall. If the trophoblast invasion is severe, the greater is the risk of hemorrhage.

Some pre-disposing factors for cervical implantation described in the literature are previous abortion, uterine curettage, previous cesarean section, uterine fibroids, use of intrauterine devices and assisted reproduction with embryo transfer (Pisarka, Carson, 1999; Hsieh et al., 2004).

The diagnosis is based on the history of vaginal bleeding after a period of amenorrhea and physical exam demonstrating a cervical enlargement with vascular congestion and a thin-walled cervix with a partially dilated external os (Figure 4).

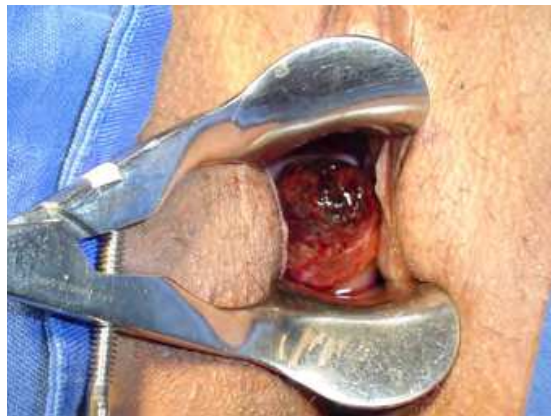

Fig. 4. Physical exam demonstrating a cervical enlargement with vascular congestion (Elito, Camano, 2010a).

The confirmation is made by ultrasound showing an empty uterine cavity and a gestational sac below the level of a closed internal os within the cervix (Dialani, Levine, 2004). The main ultrasonographic criteria for cervical pregnancy are: empty uterine cavity or the presence of a pseudo gestational sac, decidual transformation of the endometrium with dense echo structure, diffuse uterine wall structure, hourglass uterine shape, ballooned cervical canal, gestational sac in the endocervix, placental tissue in the cervical canal and closed internal os (Hofmann et al., 1987) (figure 5).

The classical treatment for cervical pregnancy is the hysterectomy. This modality of treatment compromises the reproductive future of the patient and is associated with significant morbidity. This procedure has a high risk of hemorrhage and trauma of the urinary tract because the enlargement of the cervix. The vaginal bleeding can be also treated with conservative surgical management such as curettage, local haemostatic sutures, intracervical balloon tamponade and arterial embolization (De La Veja et al., 2007; Xu et al., 2007). However, the majority of conservative surgical treatments are ineffective and lead to a hysterectomy.

The early diagnosis in asymptomatic cases has made a more conservative management of cervical pregnancy feasible. Medical treatment especially with methotrexate (MTX) can be administered systemically or locally with ultrasound guidance (Monteagudo et al., 2005; Mesogitis et al., 2005). The presence of embryonic heart activity is a relative contraindication for the systemic treatment with MTX. The predictive factors for failure in the systemic MTX

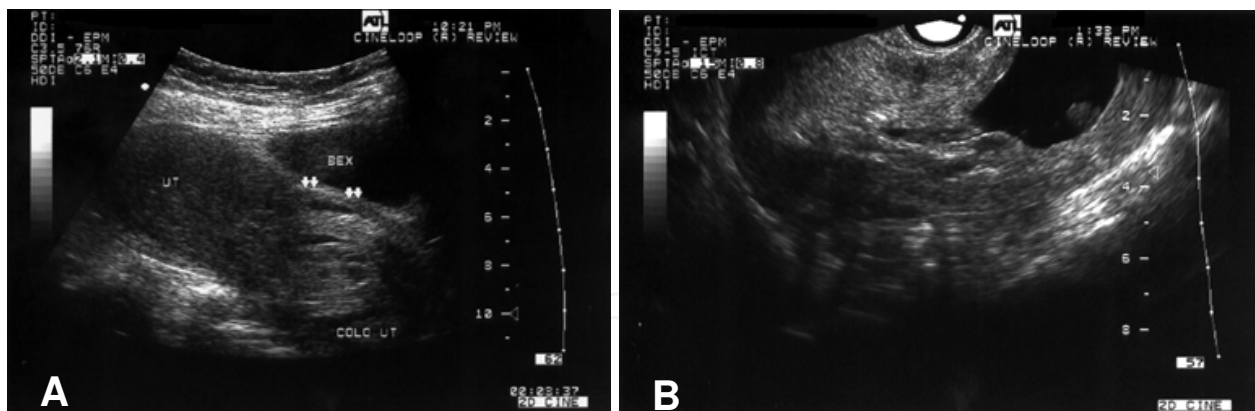


Fig. 5. A) Longitudinally oriented transabdominal ultrasound of cervical pregnancy showing an empty uterine cavity, hourglass uterine shape, placental tissue in the cervical canal and closed internal os. B) Longitudinally oriented transvaginal ultrasound showing an empty uterine cavity, hourglass uterine shape, gestational sac in the endocervix and closed internal os (Elito et al., 1999b).

treatment of cervical pregnancy were described as being gestational age > 9 weeks, beta-hCG levels > 10,000 mIU/ml, crown-rump length >10 mm, and embryonic cardiac activity (Bai et al., 2002). These situations have been shown to be associated with a higher risk of primary failure of treatment of cervical ectopic pregnancy with systemic methotrexate and combination therapy with intra-amniotic injection seemed to increase the chance of successful treatment.

For this reason in cases with live embryo the preferable therapeutic is the ultrasound-guided local injection of MTX and potassium chloride (Jeng et al., 2007). KCl is injected under transvaginal ultrasound guidance into the embryonic heart. Following the cessation of fetal cardiac activity, the tip of the needle is directed into the gestational sac and gestational tissues and some amniotic fluid was aspirated. Then, a 1 mg/kg dose of MTX is injected into the gestational sac. Patients are followed up with beta-hCG levels on days 4 and 7 after MTX injection. The protocol stipulated that any patient who does not have a 15% decline in the beta-hCG levels between days 4 and 7, would be given an intramuscular dose of MTX (50 mg/m²). On the other hand, patients who present a decline of more than 15% in the beta-hCG levels in this period are monitored weekly until the beta-hCG levels are below 5 mIU/ml. Follow up also include clinics visits and repeated transvaginal ultrasound if necessary. After approximately 3 months of treatment when the cervical pregnancy at transvaginal ultrasound disappears, a hysterosalpingography is performed.

A total of 15 patients with cervical pregnancy were referred to our institution. Embryonic heart activity was detectable in 7 cases (46,7%), which were treated with ultrasound-guided injection. The assessment of the demographic characteristics of these patients demonstrated that 4 patients had a history of previous abortion with uterine curettage and the other 3 cases had a previous cesarean section. The gestational age ranged from 8 to 11 weeks and the initial beta-hCG levels ranged from 3013 to 71199 mIU/ml. In 3 cases the titers of beta-hCG had not declined 15% between days 4 and 7 after MTX and the patient received a single intramuscular dose of MTX (50 mg/m²). All patients evolved with clinical success and in none of the cases hysterectomy or any further intervention were required. None of cases needed blood transfusion. In our series in only one case there was a complication. The patient evolved after 7 days of the treatment with fever and the cervical examination

demonstrated purulent secretion. The patient was hospitalized and received intravenous antibiotics. She recovered without the necessity of any further intervention. Another case submitted to local and systemic MTX presented with stomatitis, a minor side effect of MTX. The interval of time for the levels of beta-hCG to become negative ranged from 2 to 12 weeks. The period for the regression of the cervical pregnancy at ultrasound ranged from 3 to 14 weeks. Two patients of our series had an intrauterine pregnancy after the treatment. One patient had placenta previa and was submitted to a cesarean section at 37 weeks. The other case evaluated to a vaginal delivery at 39 weeks (Elito et al., 1999b).

4.3 Cesarean scar pregnancy

Implantation of a pregnancy within a cesarean scar is an uncommon form of ectopic pregnancy and constitutes a life-threatening condition (Fylstra et al., 2002). A cesarean scar pregnancy is considered to be more aggressive than placenta accreta because of its early invasion of the myometrium in the first trimester and the risk for uterine rupture (Seow et al., 2000). Rotas et al. (2006) and Ash et al. (2007) describe an increasing incidence of cesarean scar pregnancies of about 1:2000 pregnancies. This is likely to increase, as does the cesarean delivery rate. Its true incidence, however, has not been determined because so few cases have been reported in the literature: only 18 cases appeared in the literature between 1978 and 2001 (Fylstra, 2002; Seow et al., 2004).

One of the theories to explain the occurrence of cesarean scar pregnancy is that the blastocyst enters into the wall through a microscopic dehiscence tract consequence of a cesarean or uterine surgery.

Clinical diagnosis of an early cesarean scar pregnancy is challenge, it may occasionally be delayed until the uterus ruptures and the patient experiences life-threatening bleeding (Seow et al., 2000, 2004; Weimin and Wenqing, 2002; Maymon et al., 2004). Thus, a prompt and accurate diagnosis is crucial. Diagnosis should be based on history and clinical manifestations, such as abdominal pain and vaginal bleeding, but up to 40% of women are asymptomatic, and the diagnosis is made during routine ultrasound exam (Rotas et al., 2006).

Ultrasonography can detect an enlargement of the cesarean scar in the lower segment and a gestational sac that is attached to it. The most common sonographic criteria for a pregnancy in scar diagnosis are: an empty uterus, an empty cervical canal, the gestational sac being located in the anterior part of the isthmic portion of the uterus with a diminished myometrial layer between the bladder and the sac and a discontinuity in the anterior wall of the uterus being demonstrated on a sagittal view of the uterus when the direction of the ultrasound beam runs through the amniotic sac (Vial et al., 2000) (Figure 6). These criteria assist in distinguishing this type of pregnancy from other diagnostic options, such as cervicoisthmic implantation, cervical pregnancy and spontaneous abortion in progress (Godin et al., 1997; Fylstra, 2002). Magnetic resonance imaging may also provide a more reliable way to identify this condition (Figure 7).

With the limited experience on cesarean section scar pregnancies in the first trimester, it is difficult to conclude on the optimal management for individual cases. Management depends on the gestation and includes expectant management, medical and surgical treatment. The mode of treatment in some cases is dictated by the clinical presentation, with laparotomy and hysterectomy being the most appropriate treatment for the patients who present with haemoperitoneum and hypovolaemic shock. In a haemodynamically stable patient, two

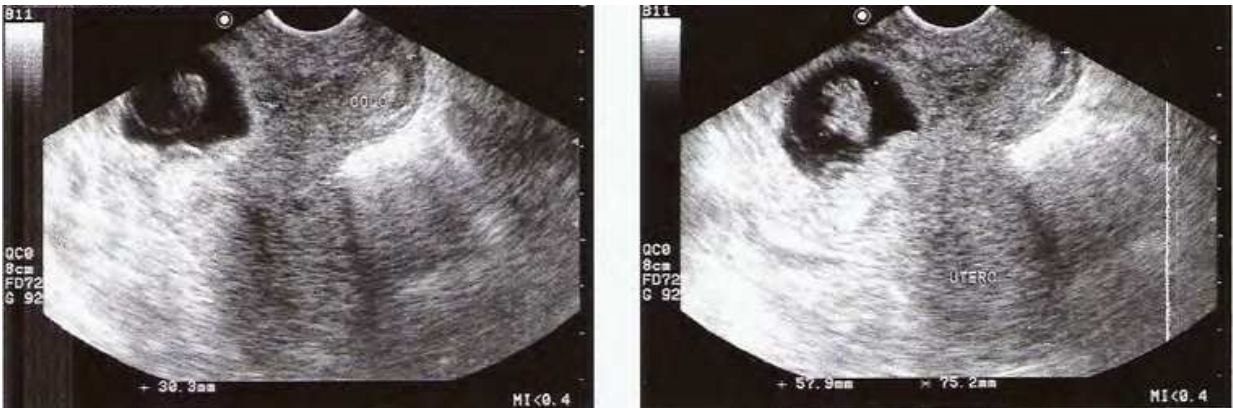


Fig. 6. Longitudinally oriented transvaginal ultrasound of the uterus demonstrating an empty uterus, an empty cervical canal, the gestational sac being located in the anterior part of the isthmic portion of the uterus with a diminished myometrial layer and a discontinuity in the anterior wall of the uterus (Elito, Camano, 2010a).

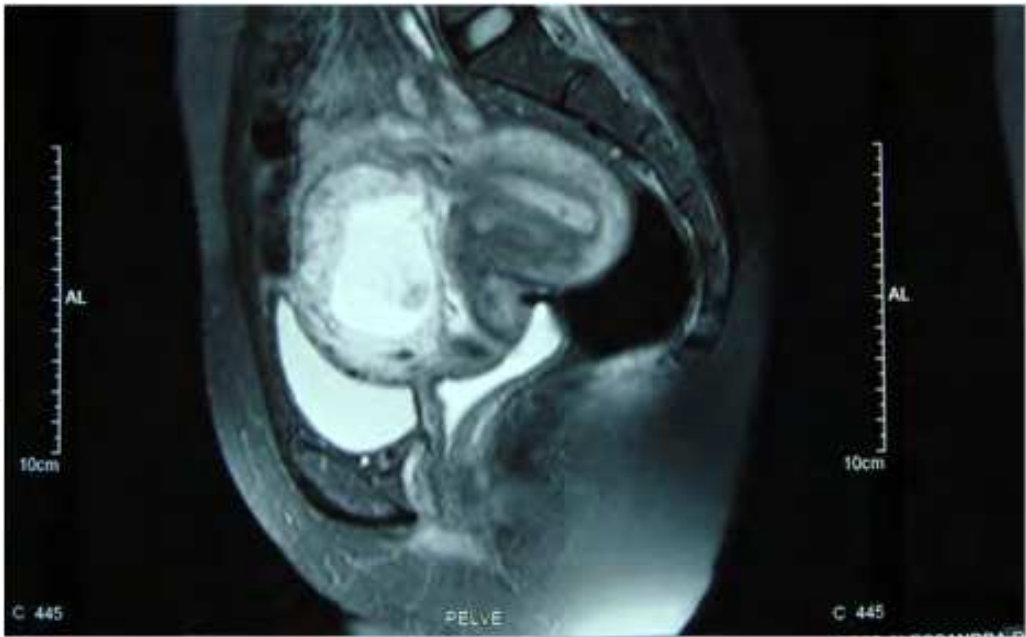


Fig. 7. Magnetic resonance imaging of the same case (Elito, Camano, 2010a).

principle management options may be considered, clinical or surgical, both aimed to eliminate the gestational sac and retain the patient's fertility. In cases where the diagnosis is made early and the patient is haemodynamically stable, assessment of the thickness of the anterior uterine wall is essential because a non-surgical procedure is the most appropriate option when the trophoblast reaches the vesico-uterine space on the bladder wall, thereby obviating an extended operation. There are few reported cases of cesarean section scar pregnancies managed expectantly in the literature. Two of these required additional treatment with methotrexate (Godin et al., 1997; Jurkovic et al., 2003) and two had emergency hysterectomies (Herman et al., 1995; Jurkovic et al., 2003). Expectant management does not therefore seem to be an appropriate choice, with the majority of cases reported requiring medical or surgical intervention.

Medical treatment consists of methotrexate administered systemically, locally or combined. Medical management with local injection of methotrexate has been more successful, with success rates of 70–80% when used as the initial treatment option (Jurkovic et al., 2003). This involves the direct injection of methotrexate into the pregnancy, performed transvaginally under ultrasound guidance. Local injections of potassium chloride have also been reported and were used prior to local methotrexate where embryonic cardiac activity was detected. Methotrexate has also been used systemically. The risk of cesarean scar rupture and heavy bleeding may occur following medical treatment. This has led some authors to propose that the medical approach should be combined with either bilateral uterine artery embolization or vasopressin intracervical injection combined with 18 Foley catheter balloon tamponade (Chuang et al., 2003), thus avoiding such complications (Ghezzi et al., 2002).

4.4 Ovarian pregnancy

Ovarian pregnancy represents the most common type of atypical localization of ectopic pregnancy.

In primary ovarian pregnancy the ovum is not guided into the tube but is fertilized in the peritoneal cavity and then implants onto the ovary. It causes the same symptoms as a tubal pregnancy and severe internal bleeding will eventually occur. In the secondary type, there is a tubal abortion with secondary implantation of the embryo on the tubal surface. Ovarian pregnancy is a rare form of ectopic gestation with estimates of frequency ranging from 1 in 2100 to 1 in 7000 pregnancies (Hage et al., 1994). It represents 0.5–3% of all ectopic pregnancies (Bouyer, Coste, 2002). Risk factors include previous pelvic inflammatory disease, IUD use, endometriosis, and assisted reproductive technologies (Marret et al., 1997). Spiegelberg (1878) suggested four criteria to diagnose an ovarian pregnancy: the fallopian tube with its fimbria should be intact and separate from the ovary, the gestational sac should occupy the normal position of the ovary, the gestational sac should be connected to the uterus by the ovarian ligament and ovarian tissue must be present in the specimen attached to the gestational sac.

The diagnosis is difficult and a continuous challenge to the gynecologist. The presentation of ovarian pregnancy is commonly indistinguishable from tubal pregnancy, except for the predisposition to early rupture. The diagnosis of an ovarian ectopic pregnancy is seldom made before surgery. Transvaginal ultrasound is an important tool in the diagnosis of this condition. At ultrasound ovarian pregnancies show as a cyst with a wide echogenic outside ring. A yolk sac or embryo is less commonly seen and the appearance of the sac contents tends to lag in comparison to gestational age. However, it can be mistaken for a

hemorrhagic corpus luteum or ovarian cyst. Misdiagnoses range from 35% (Hallat, 1982) to 75% (Herbertsson et al., 1987). Thick-walled ovarian cysts in the patient with an empty uterus and a serum beta-hCG level above the discriminatory zone should be investigated with particular care (Bontis et al., 1997). Most commonly symptoms are abdominal pain and light vaginal bleeding and diagnostic laparoscopy is often required to make the diagnosis of an ovarian pregnancy which is later confirmed by histological examination of the specimen (De Seta et al., 2001). Intraoperatively, ovarian ectopic pregnancies often resemble haemorrhagic cysts.

With early diagnosis laparoscopic surgery is the main method of treatment for ovarian ectopic pregnancies. Early detection of an ovarian pregnancy prior to rupture of the gestational sac and to onset of active bleeding permits laparoscopic surgery and removal of the ectopic pregnancy without excessive removal of healthy ovarian tissue (figure 8).

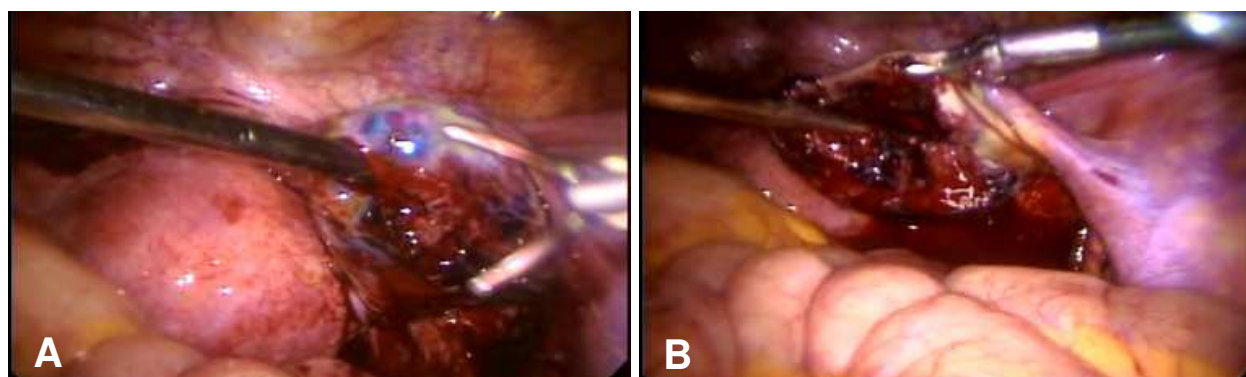


Fig. 8. Laparoscopic conservative surgery with removal of trophoblast tissue of the ovarian pregnancy (Elito, Camano, 2010b).

The medical treatment with methotrexate could be used in selected patients. It avoids surgical complications such as intraoperative hemorrhage, oophorectomy and pelvic adhesions.

Systemic methotrexate has been successfully used to treat ovarian ectopic pregnancy. There may be a place for medical management of carefully selected cases of ovarian ectopic pregnancy but selection criteria are not defined. Methotrexate may also be useful in the treatment of persistent trophoblastic tissue after laparoscopy (Einenkel et al., 2000). Though, if the initial diagnosis of an ectopic pregnancy is made during laparoscopy, it is preferable to remove it at the procedure. Nowadays, with early diagnosis and improvement of surgical techniques the ovarian tissue is preserved with minimal pelvic adhesions.

In the majority of cases ovarian pregnancies are diagnosed definitively at the time of surgical exploration. Therefore, MTX is not a first-line treatment for this condition.

4.5 Abdominal pregnancy

Abdominal pregnancy is one of the rarest form of ectopic pregnancy at 1.3% (Bouyer, Coste, 2002). It is described as primary or secondary where a tubal pregnancy aborts through the fimbrial end and implants in the peritoneal cavity. The vast majority of abdominal pregnancies are secondary. Most abdominal pregnancies are confined to the lower abdomen limited to the adnexa or the broad ligament (Holzhacker et al., 2008). However, abdominal pregnancies have been reported on the spleen, liver and diafragm. Early diagnosis is very

important in this situation. Treatment is easier in the first trimester of pregnancy. Clinical signs of early abdominal pregnancy are similar to those of other ectopic pregnancies. However, in advanced abdominal pregnancy frequent symptoms are abdominal pain, nausea, vomiting, diarrhea, painful fetal movement and fetal movements high in the abdomen. Ultrasound is the diagnostic procedure of choice. The following ultrasound criteria have been suggested as being diagnostic: an empty uterus, absence of both an evident dilated tube and a complex adnexal mass, a gestational cavity surrounded by loops of bowel and separated by peritoneum, a wide mobility similar to fluctuation of the sac particularly evident with pressure of the transvaginal probe toward the posterior cul-de-sac. MRI may also provide a more reliable way to identify this condition (figure 9). Early diagnosis allows for optimization of surgical conditions, including pre-operative arterial embolization, availability of blood products, bowel prepare and multidisciplinary surgery team. The traditional management involves a laparotomy with removal of the fetus with or without placental tissue (Ayinde et al., 2005). Recently, there have been several reports of laparoscopic management (Shaw et al., 2007). One of the problems associated with the removal of abdominal pregnancies after the first trimester is the risk of massive blood loss from the placental bed. Adjuvant treatment with methotrexate alongside selective arterial embolization has been suggested to control this (Oki et al., 2008). There are also case reports of early abdominal pregnancies being treated successfully with systemic methotrexate and ultrasound guided injection of potassium chloride, leading to reabsorption of the products of conception without the need for further surgery (Mitra, Le Quire, 2003).

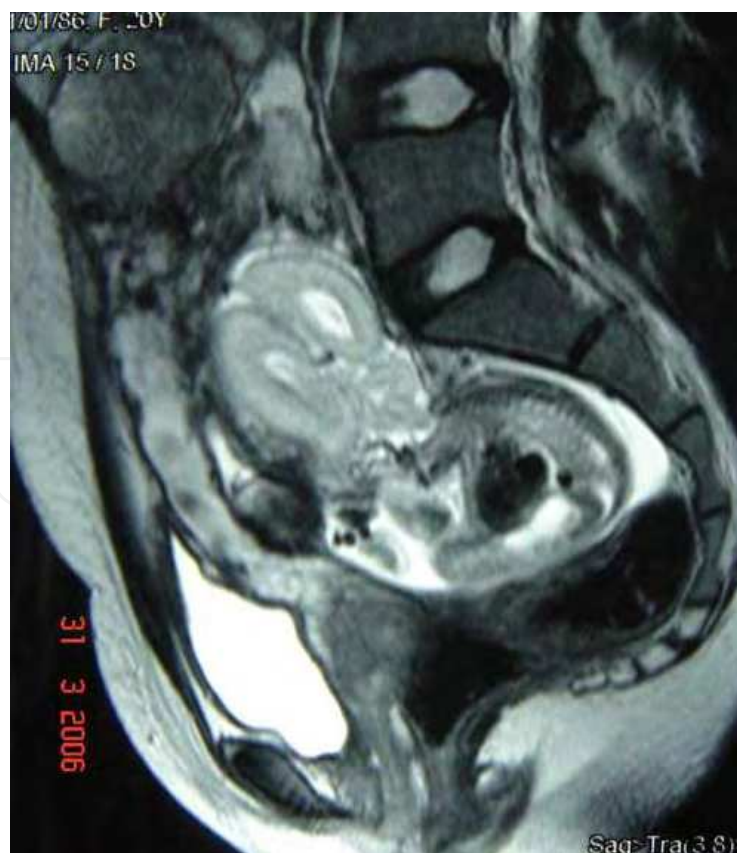

Fig. 9. MRI of advanced intraligamentar abdominal pregnancy (Holzhacker et al., 2008)..

4.6 Heterotopic pregnancy

Heterotopic pregnancy is defined by coexisting intrauterine and extrauterine pregnancies (figure 10). The increase of assisted reproduction resulted in a rise of heterotopic pregnancy. Nowadays approximately 1% of pregnancies resulting from assisted reproduction are heterotopic pregnancies. Unfortunately, approximately 50% of heterotopic pregnancies present symptoms of tubal rupture. Surgery is usually required and MTX is contraindicated (Chin et al., 2004; Fernandez et al., 2004). In cases of heterotopic pregnancy with an association of intra-uterine pregnancy and non-tubal pregnancy with embryonic cardiac activity, an alternative treatment could be local injection of KCL under ultrasound guidance. One important drawback for medical treatment in heterotopic pregnancy is the follow-up. Usually, the follow-up after medical treatment is made by the evaluation of the levels of beta-hCG. In heterotopic pregnancies this parameter cannot be used and ultrasound is a poor method to follow the patient. Therefore, medical treatment of heterotopic pregnancy should be restricted to cases with an association of atypical localization and intrauterine pregnancy, because in this situation the surgical treatment of choice is the hysterectomy. Other uncommon presentation of heterotopic pregnancy is the association of two extra-uterine pregnancies, such as tubal pregnancy and interstitial pregnancy or both tubal pregnancies. In these cases of heterotopic pregnancies without a viable intrauterine pregnancy medical treatment can be performed following the same rules of other ectopic pregnancies.

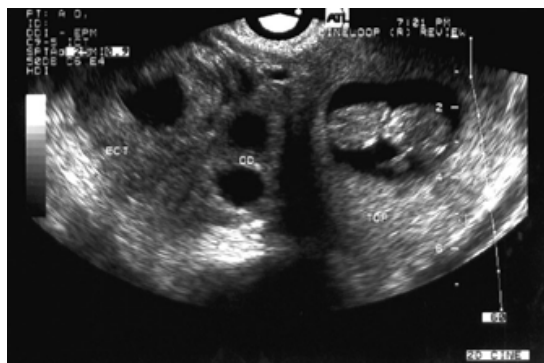

Fig. 10. Transvaginal ultrasound of heterotopic pregnancy showing at left side the tubal ring pregnancy and at right side the intrauterine pregnancy, between both the ovarian with two corpus luteum (Elito, Camano, 2010a).

4.7 Management in atypical ectopic pregnancies

There are many different approaches to the management of unusual ectopic pregnancies. Cases with embryonic cardiac activity should be treated with transvaginal administration of MTX and KCL under sonographic guidance. Ectopic pregnancies without embryonic cardiac activity and beta-hCG ≤ 5000 mUI/ml should be treated with single dose of MTX 50 mg/m² IM. Cases with beta-hCG > 5000 mUI/ml should be treated with multiple doses of MTX (Elito et al., 2008). It seems reasonable to treat some of these pregnancies with a combination of local and systemic MTX, in particular cases with high levels of beta-hCG. Adjunctive techniques for controlling hemorrhage (cervical cerclage, uterine artery embolization) should also be considered and a plan made for urgent assistance.

Surgery remains the main way for treatment of ovarian and abdominal ectopic pregnancies (Holzhacker et al., 2008).

5. Reproductive future

5.1 Hysterosalpingography

The fertility outcome of patients with unruptured EP treated conservatively with either MTX or expectant management can be evaluated indirectly through the hysterosalpingography (HSG) and directly by means of future pregnancy (Debby et al., 2000; Elito et al., 2006). The HSG represents important diagnosis methods after the treatment of EP, in spite of the inconveniences and doubts about the interpretation of this examination. The tubal patency after MTX is 84% and after expectant management is 78% (Elito et al., 2005a). This high rate of radiologically normal tubes after clinical treatment proves that the spontaneous regression of EP does not result in an increased harm or damage to the tube. However, the radiologically normal findings show nothing about the tubal function, when a disturbance can also be the cause of EP. On the other hand, if the results of HSG demonstrate obstruction of the tubes, the possibility of a spontaneous pregnancy will be reduced and should be treated with *in vitro* fertilization. The tubal obstruction is increased in cases with high beta-hCG levels (Elito et al., 2005b). The explanation for higher incidence of tubal obstruction is that in patients with higher levels of beta-hCG there is more invasion of the trophoblast tissue at the tube's serosa, what increases the damage to the tube.

5.2 Future pregnancy

After medical treatment 65% of patients who attempted subsequent pregnancies succeeded, and the incidence of recurrent ectopic pregnancy was relatively low at 13% (Stovall et al., 1989; Lipscomb et al., 2000). Systemic MTX in a single-dose regimen compared with laparoscopic salpingostomy of four trials (Fernandez et al., 1998; Saraj et al., 1998; Sowter et al., 2001; El-Sherbiny et al., 2003), involving 265 haemodynamically stable women with a small unruptured tubal EP, showed no significant differences in the number of IUPs (RR 1.01, 95% CI 0.66–1.54), whereas there was a non-significant trend towards a lower incidence of repeat EPs (RR 0.63, 95% CI 0.14–2.77) (Mol et al., 2008). Systemic MTX in a fixed multiple dose regimen compared with laparoscopic salpingostomy observed that fertility outcome was no significant different for IUP (RR 0.88, 95% CI 0.49–1.60) as well as for repeat EP (RR 0.88, 95% CI 0.21–3.67) (Dias Pereira et al., 1999).

6. Cost analysis

Serial serum beta-hCG measurements and transvaginal ultrasound examination can provide early diagnosis of most ectopic pregnancies allowing medical treatment with methotrexate. Approximately 40% of women diagnosed with ectopic pregnancy are candidates for medical management (Barnhart et al., 2003), and 90% of those can be treated successfully without surgery (Lipscomb et al., 2000). Whereas the costs of surgery and outpatient medical management vary widely, many cost-effectiveness analyses have favored MTX therapy. Systemic MTX in a single-dose regimen resulted in significant savings in direct costs compared with laparoscopic surgery: mean direct costs per patient were € 756 and € 1585, respectively, with a mean difference of € 829 (95% CI 599–1060). Furthermore, systemic MTX resulted in significant savings in indirect costs: mean indirect costs per patient were € 587 and € 977, respectively, with a mean difference of € 390 (95% CI 142–638). However, in women with initial serum hCG concentrations >1500 IU/l the difference in indirect costs was lost due to the prolonged follow-up and a higher rate of surgical re-interventions

(Sowter et al., 2001). Therefore, medical treatment is less expensive than surgery, except in cases with higher levels of beta-hCG (Sowter et al., 2001).

7. Conclusion

The early non-invasive diagnosis of ectopic pregnancy, before there is tubal rupture, can be made through transvaginal ultrasonography and with the dosage of the beta-fraction of the chorionic gonadotrophin. After the diagnosis, range of treatments may be used. Either a surgical intervention or a clinical treatment (expectant management or methotrexate therapy) may be taken into consideration. Expectant management should be indicated in cases of decline in the beta-hCG titers within 48 hours before the treatment, and when the initial titers are under 1,500 mUI/mL. The use of methotrexate (MTX) is a safe clinical procedure and in some cases could be indicated as the first option for treatment. The main criteria for MTX indication are hemodynamic stability, beta-hCG <5,000 mUI/mL, adnexal mass ≤3,5 cm, and no embryonic cardiac activity. It is preferable to administer a single intramuscular dose MTX (50 mg/m²) because it is easier, more practical and with less side effects (diagram 1). Protocol with multiple doses should be restricted for the cases with atypical localization (interstitial, cervical, caesarean section scar and ovarian) with values of beta-hCG >5,000 mUI/mL and no fetal heart activity. Indication for local treatment with an injection of MTX (1 mg/kg) and KCl guided by transvaginal ultrasonography should occur in cases of embryonic cardiac activity but with an atypical localization (Elito et al., 2008).

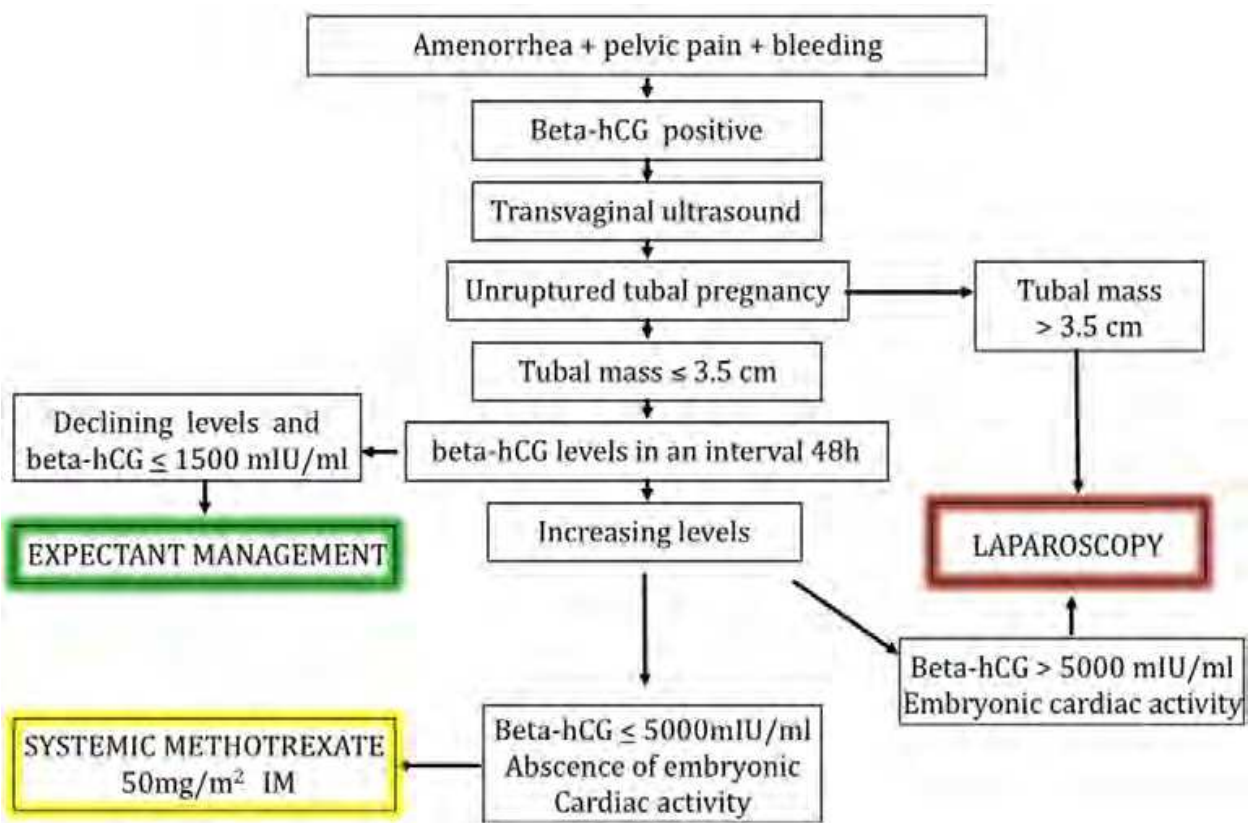


Diagram 1. Recommendation for Treatment of Unruptured Tubal Pregnancy (Elito et al., 2008)

8. References

- Ackerman TE, Levi CS, Dashefsky SM, Holt SC, Lindsay DJ. Interstitial line: sonographic finding in interstitial (cornual) ectopic pregnancy. *Radiology* 1993;189:83-7.
- Ash A, Smith A, Maxwell D. Caesarean scar pregnancy. *BJOG*. 2007 Mar;114(3):253-63.
- Atri M, Bret PM, Tulandi T, Senterman MK. Ectopic pregnancy: evolution after treatment with transvaginal methotrexate. *Radiology* 1992;185:749-53.
- Ayinde OA, Aimakhu CO, Adeyanju OA et al. Abdominal pregnancy at the University College Hospital, Ibadan: a ten-year review. *Afr J Reprod Health* 2005; 9: 123-127.
- Bai SW, Lee JS, Park JH, Kim JY, Jung KA, Kim SK, Park KH. Failed methotrexate treatment of cervical pregnancy. Predictive factors. *J Reprod Med*. 2002; 47:483-8.
- Baptiste A. Cervical pregnancy. *Obstet Gynecol* 1953; 1:353.
- Barnhart K, Coutifaris C, Esposito M. The pharmacology of methotrexate. *Expert Opin Pharmacother* 2001;2:409-17.
- Barnhart KT, Gosman G, Ashby R, Sammel M. The medical management of ectopic pregnancy: a meta-analysis comparing “single dose and multidose” regimens. *Obstet Gynecol* 2003;101:778-84.
- Barnhart K, Hummel AC, Sammel MD, Menon S, Jain JK, Chakhtoura NA. Use of “2-dose” regimen of methotrexate to treat ectopic pregnancy. *Fertil Steril* 2007;87:250-6.
- Barnhart KT. Clinical practice. Ectopic pregnancy. *N Engl J Med*. 2009 Jul 23;361(4):379-87.
- Benifla JL, Fernandez H, Sebban E, Darai E, Frydman R, Madelenat P. Alternative to surgery of treatment of unruptured interstitial pregnancy: 15 cases of medical treatment. *Eur J Obstet Gynecol Reprod Biol* 1996;70:151-6.
- Berg CJ, Chang J, Callaghan WM, Whitehead SJ. Pregnancy-related mortality in the United States, 1991-1997. *Obstet Gynecol* 2003;101: 289-96.
- Bontis J, Grimbizis G, Tarlatzis BC et al. Intrafollicular ovarian pregnancy after ovulation induction/intrauterine insemination: pathophysiological aspects and diagnostic problems. *Hum Reprod* 1997; 12(2): 376-378.
- Bouyer J, Coste J, Fernandez H et al. Sites of ectopic pregnancy; a 10 year population-based study of 1800 cases. *Hum Reprod* 2002; 17: 3224-3230.
- Brown DL, Felker RE, Stovall TG, Emerson DS, Ling FW. Serial endovaginal sonography of ectopic pregnancies treated with methotrexate. *Obstet. Gynecol.*, 77: 406-9, 1991.
- Cacciatore B, Korhonen J, Stenman UH, Ylostalo P. Transvaginal sonography and serum hCG in monitoring of presumed ectopic pregnancies selected for expectant management. *Ultrasound Obstet Gynecol* 1995; 5: 297-300.
- Centers for Disease Control and Prevention (CDC). Ectopic pregnancy – United States, 1990-1992. *MMWR Morb Mortal Wkly Rep*. 1995;44(3):46-8.
- Chetty M, Elson J. Treating non-tubal ectopic pregnancy. *Best Pract Res Clin Obstet Gynaecol*. 2009 Aug;23(4):529-38.
- Chin HY, Chen FP, Wang CJ, Shui LT, Liu YH, Soong YK. Heterotopic pregnancy after in vitro fertilization-embryo transfer. *Int J Gynaecol Obstet* 2004;86:411-6.
- Chuang J, Seow KM, Cheng WC, Tsai YL, Hwang JL. Conservative treatment of ectopic pregnancy in a caesarean section scar. *BJOG*. 2003 Sep;110(9):869-70.
- da Costa Soares R, Elito J Jr, Camano L. Increment in beta-hCG in the 48-h period prior to treatment: a new variable predictive of therapeutic success in the treatment of ectopic pregnancy with methotrexate. *Arch Gynecol Obstet*. 2008 Oct;278(4):319-24.

- Damario MA, Rock JA. Ectopic pregnancy. In: Rock JA, Jones HW III, eds. *Te Linde's operative gynecology*. Philadelphia: Lippincott, Williams & Wilkins; 2003:507-36.
- Debby A, Golan A, Sadan O, Zakut H, Glezerman M. Fertility outcome following combined methotrexate treatment of unruptured extrauterine pregnancy. *BJOG* 2000; 107: 626-30. 3.
- De La Veja GA, Avery C, Nemiroff R, Marchiano D. Treatment of early cervical pregnancy with cerclage, carboprost, curettage and balloon tamponade. *Obstet Gynecol*. 2007; 109:505-7.
- De Seta F, Baraggino E, Strazzanti C et al. Ovarian pregnancy: a case report. *Acta Obstet Gynecol Scand* 2001; 80: 661-662.
- Dialani V, Levine D. Ectopic pregnancy: a review. *Ultrasound* 2004; 20:105-117.
- Dias Pereira G, Hajenius PJ, Mol BW, Ankum WM, Hemrika DJ, Bossuyt PM, van der Veen F. Fertility outcome after systemic methotrexate and laparoscopic salpingostomy for tubal pregnancy. *Lancet*. 1999 Feb 27;353(9154):724-5.
- DuBois D, DuBois EF. A formula to estimate the approximate surface area if height and weight be known. *Arch Intern Med* 1916; 17: 863-871
- Eddy CA, Pauerstein CJ. Anatomy and physiology of the fallopian tube. *Clin Obstet Gynecol*. 1980, 23:1177.
- Egarter C, Kiss H & Husslein P. Prostaglandin versus expectant management in early tubal pregnancy. *Prostaglandins Leukot Essent Fatty Acids* 1991; 42: 177-179.
- Einenkel J, Baier D, Horn L-C et al. Laparoscopic therapy of an intact primary ovarian pregnancy with ovarian hyper-stimulation syndrome. *Hum Reprod* 2000; 15(9): 2037-2040.
- Elito Jr J, Uchiyama M, Camano L. O metotrexato no tratamento sistêmico da gravidez ectópica íntegra. *Rev Bras Ginecol Obstet*. 1996; 18(7):537-41.
- Elito Jr J, Uchiyama M, Camano L. Evolução dos níveis de beta-hCG após tratamento sistêmico da gravidez ectópica íntegra. *Rev Assoc Med Bras*. 1998; 44 (1):11-5.
- Elito J Jr, Reichmann AP, Uchiyama MN, Camano L. Predictive score for the systemic treatment of unruptured ectopic pregnancy with a single dose of methotrexate. *Int J Gynaecol Obstet* 1999a;67:75-9.
- Elito Jr J, Uchiyama M, Camano L. Gravidez ectópica cervical com embrião vivo: relato de quatro casos. *Rev Bras Ginecol Obstet*. 1999b; 21(6):347-50.
- Elito Jr J, Camano L. Unruptured tubal pregnancy: different treatments for early and late diagnosis. *São Paulo Med J*. 2006 Nov 7;124(6):321-4.
- Elito Jr J, Han KK, Camano L. Tubal patency after clinical treatment of unruptured ectopic pregnancy. *Int J Gynaecol Obstet*. 2005a; 88(3):309-13.
- Elito Jr J, Han KK, Camano L. Values of beta-human chorionic gonadotropin as a risk factor for tubal obstruction after tubal pregnancy. *Acta Obstet Gynecol Scand*. 2005b; 84(9):864-7.
- Elito Jr J, Han KK, Camano L. Tubal patency following surgical and clinical treatment of ectopic pregnancy. *Sao Paulo Med J*. 2006 Sep 7;124(5):264-6.
- Elito Jr J, Montenegro NA, Soares RC, Camano L. Unruptured ectopic pregnancy: diagnosis and treatment. State of art. *Rev Bras Ginecol Obstet*. 2008 Mar;30(3):149-59.
- Elito Jr J, Camano L. Hemorragias no primeiro trimestre de gestação: gravidez ectópica. In Pastore AR, Cerri GG. "Ultrassonografia em Ginecologia e Obstetrícia". 2a Edição. Livraria e Editora Revinter, 2010.pg:114-133.

- Elito Jr J; Camano L. Gestação ectópica. In: Moron AF; Camano L; Kulay Jr L. *Obstetrícia – UNIFESP/ EPM*. 1a Ed, Editora Manole, São Paulo, 2010; pg 151-168.
- El-Sherbiny MT, El G I, Mera IM. Methotrexate versus laparoscopic surgery for the management of unruptured tubal pregnancy. *Middle East Fertil Soc J* 2003;8:256-262.
- Elson J, Tailor A, Banerjee S, Salim R, Hillaby K, Jurkovic D. Expectant management of tubal ectopic pregnancy: prediction of successful outcome using decision tree analysis. *Ultrasound Obstet Gynecol* 2004; 23: 552-556.
- Feichtinger, W.; Kemeter, P.- Conservative treatment of ectopic pregnancy by transvaginal aspiration under sonographic control and MTX injection. *Lancet*. 1987; 1: 381-92.
- Fernandez, H.; Benifla, J. A.- Metotrexate treatment of ectopic pregnancy - 100 cases treated by primary transvaginal injection under sonographic control. *Fertil. Steril*. 1993; 59: 773-7.
- Fernandez H, Yves Vincent SC, Pauthier S, Audibert F, Frydman R. Randomized trial of conservative laparoscopic treatment and methotrexate administration in ectopic pregnancy and subsequent fertility. *Hum Reprod*. 1998 Nov;13(11):3239-43.
- Fernandez H, Gervaise A. Ectopic pregnancies after infertility treatment: modern diagnosis and therapeutic strategy. *Hum Reprod Update* 2004;10:503-13.
- Fylstra DL. Ectopic pregnancy within a cesarean scar: a review. *Obstet Gynecol Surv*. 2002 Aug;57(8):537-43.
- Glatstein IZ, Sleeper LA, Law Y, Simon A, Adoni A, Laufer N, et al. Observer variability in the diagnosis and management of the hysterosalpingogram. *Fertil Steril* 1997;67:233-7
- Godin PA, Bassil S, Donnez J. An ectopic pregnancy developing in a previous caesarian section scar. *Fertil Steril*. 1997 Feb;67(2):398-400.
- Ghezzi F, Lagana D, Franchi M, Fugazzola C, Bolis P. Conservative treatment by chemotherapy and uterine arteries embolization of a cesarean scar pregnancy. *Eur J Obstet Gynecol Reprod Biol*. 2002 Jun 10;103(1):88-91.
- Hage PS, Arnouk IF, Zarou DM et al. Laparoscopic management of ovarian pregnancy. *J Am Assoc Gynecol Laparosc* 1994; 1: 283-285.
- Hallat J. Primary ovarian pregnancy. A report of twenty-five cases. *Am J Obstet Gynecol*. 1982; 143: 50-60.
- Hajenius PJ, Mol BWJ, Ankum WM et al. Suspected ectopic pregnancy: expectant management in patients with negative sonographic findings and low serum hCG concentrations. *Early Pregnancy: Biol Med* 1995; 1: 258-262.
- Hajenius PJ, Engelsbel S, Mol BW, Van der Veen F, Ankum WM, Bossuyt PM, et al. Randomised trial of systemic methotrexate versus lap- aroscopic salpingostomy in tubal pregnancy. *Lancet* 1997;350:774-9.
- Hajenius PJ, Mol F, Mol BW, Bossuyt PM, Ankum WM, van der Veen F. Interventions for tubal ectopic pregnancy. *Cochrane Database Syst Rev*. 2007 Jan 24;(1):CD000324.
- Han KK; Elito Jr J, Camano L. Conduta expectante para gravidez tubária íntegra. *Rev Bras Ginecol Obstet*. 1999; 21(8):465-70.
- Herbertsson G, Magnusson SS, Benediktsdottir K. Ovarian pregnancy and IUCD use in a defined complete population. *Acta Obstet Gynecol Scand* 1987;66:607.


- Herman A, Weinraub Z, Avrech O et al. Follow up and outcome of isthmic pregnancy located in a previous caesarean section scar. *Br J Obstet Gynaecol* 1995; 102: 839–841.
- Hsieh BC, Lin YH, Huang JW, Chang JZ, Seo WKM, Pan HS, Hwang JL. Cervical pregnancy after in vitro fertilization and embryo transfer successfully treated with methotrexate and intracervical injection of vasopressin. *Acta Obstet Gynecol Scand* 2004; 83:112-4.
- Hofmann HMH, Urdl W, Hofler H. Cervical pregnancy: Case reports and current concepts in diagnosis and treatment. *Arch Gynecol Obstet*. 1987; 241:63.
- Holzhaecker S, Elito Jr J, Santana RM, Hisaba W. Advanced intraligamentary abdominal pregnancy – case report. *Rev Assoc Med Bras*. 2008 Sep-Oct;54(5):387-9.
- Isaacs JD, McGehee RP, Cowan BD. Life-threatening neutropenia following methotrexate treatment of ectopic pregnancy: a report of two cases. *Obstet Gynecol* 1996; 88:694–6.
- Jeng CJ, Ko ML, Shen J. Transvaginal ultrasound-guided treatment of cervical pregnancy. *Obstet Gynecol*. 2007; 109:1076-82.
- Jourdain O, Fontanges M, Schiano A, Rauch F, Gonnet JM. Management of other ectopic pregnancies (cornual, interstitial, angular, ovarian). *J Gynecol Obstet Biol Reprod (Paris)* 2003;32:S93–100.
- Jurkovic D, Hillaby K, Woelfer B et al. First-trimester diagnosis and management of pregnancies implanted into the lower uterine segment cesarean section scar. *Ultrasound Obstet Gynecol* 2003; 21: 220–227.
- Kamrava MM, Taymor ML, Berger MJ, Thompson IE, Seibel MM. Disappearance of human chorionic gonadotropin following removal of ectopic pregnancy. *Obstet Gynecol*. 1983 Oct;62(4):486-8.
- Korhonen J, Stenman U & Ylostalo P. Low dose oral methotrexate with expectant management of ectopic pregnancy. *Obstet Gynecol* 1996; 88: 775–778.
- Korhonen J, Stenman UH & Ylostalo P. Serum human chorionic gonadotropin dynamics during spontaneous resolution of ectopic pregnancy. *Fertil Steril* 1994; 61: 632–636.
- Lang PF, Makinen JI, Irjala KM et al. Laparoscopic instillation of hyperosmolar glucose vs. expectant management of tubal pregnancies with serum hCG < or 1/4 2500 mIU/mL. *Acta Obstet Gynecol Scand* 1997 Sep; 76(8): 797–800.
- Lau S, Tulandi T. Conservative medical and surgical management of interstitial ectopic pregnancy. *Fertil Steril* 1999;72:207-15.
- Li MC, Hertz R, Spencer, DB. Effect of methotrexate therapy upon choriocarcinoma and chorioadenoma. *Proc. Sci. Exp. Biol. Med.*, 93: 361-9, 1956.
- Lim JE, Kim T, Lee NW, et al. Ultrasonographic endometrial features in tubal pregnancy: are they predictive factors of successful medical treatment? *Ultrasound Med Biol* 2007; 33:714-9.
- Lin YS, Chen CL, Yuan CC, Wang PH. Successful rescue of an early interstitial pregnancy after failed systemic methotrexate treatment: a case report. *J Reprod Med* 2007;52:332-4.
- Lipscomb GH, Puckett KJ, Bran D, Ling FW. Management of separation pain after single-dose methotrexate therapy for ectopic pregnancy. *Obstet Gynecol* 1999;93:590–3.

- Lipscomb GH, McCord ML, Stovall TG, Huff G, Portera SG, Ling FW. Predictors of success of methotrexate treatment in women with tubal ectopic pregnancies. *N Engl J Med* 1999;341:1974-8.
- Lipscomb GH, Stovall TG, Ling FW. Nonsurgical treatment of ectopic pregnancy. *N Engl J Med* 2000;343:1325-9.
- Lui A, D'Ottavio G, Rustico MA, Conoscenti G, Fischer Tamaro F, Meir YJ, Maieron A, Mandruzzato GP. [Conservative management of ectopic pregnancy.] *Minerva Ginecol* 1997; 49: 67-72.
- Lund, JJ.- Early ectopic pregnancy treated nonsurgically. *J. Obstet. Br. Empire*, 62: 70-6, 1955.
- Marret H, Hamamah S, Alonso AM et al. Case report and review of the literature: primary twin ovarian pregnancy. *Hum Reprod* 1997; 12(8): 1813-1815.
- Mashiach S, Carp HJA & Serr DM. Non operative management of ectopic pregnancy: a preliminary report. *J Reprod Med* 1982; 27: 127.
- Lipscomb GH, Stovall TG, Ling FW. Nonsurgical treatment of ectopic pregnancy. *N Engl J Med* 2000;343:1325-9.
- Mass JW, Evers JL, Riet G, Kessels AG. Pregnancy rate following normal versus abnormal hysterosalpingography findings: a meta-analysis. *Gynecol Obstet Invest* 1997;43:79- 83.
- Maymon R, Halperin R, Mendlovic S, Schneider D, Vaknin Z, Herman A, et al. Ectopic pregnancies in Caesarean section scars: the 8 year experience of one medical centre. *Hum Reprod*. 2004 Feb;19(2):278-84.
- Mesogitis S, Pilalis A, Daskalakis G, Papantoniou N, Antsaklis A. Management of early viable cervical pregnancy. *BJOG* 2005; 112:409-11.
- Mitra AG & LeQuire MH. Minimally invasive management of 14.5 week abdominal pregnancy without laparotomy: a novel approach using percutaneous sonographically guided feticide and systemic methotrexate. *J Ultrasound Med* 2003; 22: 709-714.
- Moawad NS, Mahajan ST, Moniz MH, Taylor SE, Hurd WW. Current diagnosis and treatment of interstitial pregnancy (2010) *Am J Obstet and Gynecol*, 202 (1), pp. 15-29.
- Mol BW, Swart P, Bossut PM, Van Der Veen F. Hysterosalpingography an important tool in predicting fertility outcome? *Fertil Steril* 1997;67:663-9.
- Mol F, Mol BW, Ankum WM, van der Veen F, Hajenius PJ. Current evidence on surgery, systemic methotrexate and expectant management in the treatment of tubal ectopic pregnancy: a systematic review and meta-analysis. *Hum Reprod Update*. 2008 Jul-Aug;14(4):309-19.
- Monteagudo A, Minior VK, Stephenson C, Monda S, Timor-Tritsch E. Non-surgical management of live ectopic pregnancy with ultrasound-guided local injection: a case series. *Ultrasound Obstet Gynecol* 2005; 25:282-8.
- Natale, A., Candiani, M., Merlo, D., Izzo, S., Gruft, L., Busacca, M. Human chorionic gonadotropin level as a predictor of trophoblastic infiltration into the tubal wall in ectopic pregnancy: a blinded study. *Fertil. Steril*. 2003, 79, 981-986.
- Olofsson JL, Poromaa IS, Ottander U, Kjellberg L, Damber MG. Clinical and pregnancy outcome following ectopic pregnancy; a prospective study comparing expectancy, surgery and systemic methotrexate treatment. *Acta Obstet Gynecol Scand* 2001; 80: 744-749.

- Oki T, Baba Y, Yoshinaga M et al. Super-selective arterial embolization for uncontrolled bleeding in abdominal pregnancy. *Obstet Gynecol* 2008; 112: 427-429.
- Pansky, M.; Bubowsky, I.- Local methotrexate injection: a nonsurgical treatment of ectopic pregnancy. *Am. J. Obstet. Gynecol.* 1989; 161: 363-8.
- Pisarska MD, Carson SA, Buster JE. Ectopic pregnancy. *Lancet* 1998;351:1115-20.
- Pisarska M, Carson S. Incidence and risk factors for ectopic pregnancy. *Clin Obstet Gynecol* 1999; 42:2-8.
- Potter MB, Lepine LA, Jamieson DJ. Predictors of success with methotrexate treatment of tubal ectopic pregnancy at Grady Memorial Hospital. *Am J Obstet Gynecol* 2003;188:1192-4.
- Practice Committee of American Society for Reproductive Medicine. Medical treatment of ectopic pregnancy.(2008) *Fertility and Sterility*, 90 (5 SUPPL.), pp. S206-S212.
- Rantala M, Ma'kinen J. Tubal patency and fertility outcome after expectant management of ectopic pregnancy. *Fertil Steril* 1997;68:1043-6.
- Rotas MA, Haberman S, Levгур M. Cesarean scar ectopic pregnancies: etiology, diagnosis, and management. *Obstet Gynecol.* 2006 Jun;107(6):1373-81.
- Sagiv R, Golan A, Arbel-Alon S, Glezerman M. Three conservative approaches to treatment of interstitial pregnancy. *J Am Assoc Gynecol Laparosc* 2001;8:154-8.
- Saraj AJ, Wilcox JG, Najmabadi S, Stein SM, Johnson MB, Paulson RJ. Resolution of hormonal markers of ectopic gestation: a randomized trial comparing single-dose intramuscular methotrexate with salpingostomy. *Obstet Gynecol.* 1998 Dec;92(6):989-94.
- Seow KM, Cheng WC, Chuang J, Lee C, Tsai YL, Hwang JL. Methotrexate for cesarean scar pregnancy after in vitro fertilization and embryo transfer. A case report. *J Reprod Med.* 2000 Sep;45(9):754-7.
- Seow KM, Huang LW, Lin YH, Lin MY, Tsai YL, Hwang JL. Cesarean scar pregnancy: issues in management. *Ultrasound Obstet Gynecol.* 2004 Mar;23(3):247-53.
- Shalev E, Peleg D, Tsabari A, Romano S, Bustan M. Spontaneous resolution of ectopic tubal pregnancy: natural history. *Fertil Steril* 1995; 63: 15-19.
- Shaw SW, Hsu JJ, Chueh HY et al. Management of primary abdominal pregnancy: twelve years of experience in a medical centre. *Acta Obstet Gynecol Scand* 2007; 86(9): 1058-1062.
- Spiegelberg O-Zur. Cauistik der Ovarial schwangerschaft. *Arch E Gynak.* 1878; 13: 73
- Soares, RC; Elito Jr J, Han KK, Camano L. Endometrial thickness as an orienting factor for the medical treatment of unruptured tubal pregnancy. *Acta Obstet Gyn Scand,* 2004;83(3): 289-92.
- Sowter MC, Farquhar CM, Gudex G. An economic evaluation of single dose systemic methotrexate and laparoscopic surgery for the treatment of unruptured ectopic pregnancy. *BJOG* 2001;108:204-12.
- Stovall TG, Ling FW, Buster JE. Outpatient chemotherapy of unruptured ectopic pregnancy. *Fertil Steril* 1989;51:435-8.
- Stovall TG, Ling FW, Gray LA, Carson SA, Buster JE. Methotrexate treatment of unruptured ectopic pregnancy: a report of 100 cases. *Obstet Gynecol* 1991;77:749- 53.
- Stovall TG, Ling FW. Single-dose methotrexate: an expanded clinical trial. *Am J Obstet Gynecol* 1993;168:1759-65

- Tanaka T, Hayashi H, Kutsuzawa T, Fujimoto S, Ichinoe K. Treatment of interstitial ectopic pregnancy with methotrexate: report of a successful case. *Fertil Steril* 1982;37:851-5.
- Tawfiq A, Agameya AF, Claman P. Predictors of treatment failure for ectopic pregnancy treated with single-dose methotrexate. *Fertil Steril* 2000;74:877-80.
- Timor-Tritsch IE, Monteagudo A, Matera C, Veit CR. Sonographic evolution of cornual pregnancies treated without surgery. *Obstet Gynecol* 1992;79:1044-9.
- Trio D, Strobelt N, Picciolo C, Lapinski RH, Ghidini A. Prognostic factors for successful expectant management of ectopic pregnancy. *Fertil Steril* 1995; 63: 469-72.
- Tulandi T, Al-Jaroudi D. Interstitial pregnancy: results generated from the Society of Reproductive Surgeons Registry. *Obstet Gynecol* 2004;103:47-50.
- van Mello NM, Mol F, Mol BW, Hajenius PJ. Conservative management of tubal ectopic pregnancy. *Best Pract Res Clin Obstet Gynaecol*. 2009 Aug;23(4):509-18.
- Vial Y, Petignat P, Hohlfeld P. Pregnancy in a cesarean scar. *Ultrasound Obstet Gynecol*. 2000 Nov;16(6):592-3.
- Xu B, Wang YK, Zhang YH, Wang S, Yang L, Dai SZ. Angiographic uterine artery embolization followed immediate curettage: an efficient treatment for controlling heavy bleeding and avoiding recurrent bleeding in cervical pregnancy. *J Obstet Gynaecol Res* 2007; 33:190-4.
- Ylostalo P, Cacciatore B, Sjoberg J, Kaariainen M, Tenhunen A, Stenman UH. Expectant management of ectopic pregnancy. *Obstet Gynecol* 1992; 80: 345-348.
- Walker JJ. Ectopic pregnancy. *Clin Obstet Gynecol* 2007;50:89-99.
- Weimin W, Wenqing L. Effect of early pregnancy on a previous lower segment cesarean section scar. *Int J Gynaecol Obstet*. 2002 Jun;77(3):201-7.
- Zalel Y, Caspi B, Insler V. Expectant management of interstitial pregnancy. *Ultrasound Obstet Gynecol* 1994;4:238-40.
- Zohav E, Gerner O, Segal S. Reproductive outcome after expectant management of ectopic pregnancy. *Eur J Obstet Reprod Biol* 1996;66:1-2.

IntechOpen



Ectopic Pregnancy - Modern Diagnosis and Management

Edited by Dr. Michael Kamrava

ISBN 978-953-307-648-5

Hard cover, 248 pages

Publisher InTech

Published online 26, October, 2011

Published in print edition October, 2011

Ectopic pregnancy is the second major cause of maternal mortality in the United States and a leading cause of maternal morbidity and mortality in the world. This book contains the practical methods to early diagnosis of various forms of ectopic pregnancies and their modern management. Ectopic Pregnancy - Modern Diagnosis and Management is a comprehensive book which guides the reader through all features of ectopic pregnancy, both practical and academic, covering all aspects of diagnosis and management of ectopic pregnancy in a clear, concise, and practical fashion. The book is organized so that it can either be read cover to cover for a comprehensive tutorial or be kept desk side as a reference to the ectopic pregnancies. Each chapter introduces a number of related ectopic pregnancy and its diagnosis, treatment and co-morbidities supported by examples. Included chapters bring together valuable materials in the form of extended clinical knowledge from practice to clinic features.

How to reference

In order to correctly reference this scholarly work, feel free to copy and paste the following:

Julio Elito Junior (2011). Clinical Treatment of Unruptured Ectopic Pregnancy, Ectopic Pregnancy - Modern Diagnosis and Management, Dr. Michael Kamrava (Ed.), ISBN: 978-953-307-648-5, InTech, Available from: <http://www.intechopen.com/books/ectopic-pregnancy-modern-diagnosis-and-management/clinical-treatment-of-unruptured-ectopic-pregnancy>

INTech
open science | open minds

InTech Europe

University Campus STeP Ri
Slavka Krautzeka 83/A
51000 Rijeka, Croatia
Phone: +385 (51) 770 447
Fax: +385 (51) 686 166
www.intechopen.com

InTech China

Unit 405, Office Block, Hotel Equatorial Shanghai
No.65, Yan An Road (West), Shanghai, 200040, China
中国上海市延安西路65号上海国际贵都大饭店办公楼405单元
Phone: +86-21-62489820
Fax: +86-21-62489821

© 2011 The Author(s). Licensee IntechOpen. This is an open access article distributed under the terms of the [Creative Commons Attribution 3.0 License](https://creativecommons.org/licenses/by/3.0/), which permits unrestricted use, distribution, and reproduction in any medium, provided the original work is properly cited.

IntechOpen

IntechOpen