

# We are IntechOpen, the world's leading publisher of Open Access books Built by scientists, for scientists

6,900

Open access books available

186,000

International authors and editors

200M

Downloads

Our authors are among the

154

Countries delivered to

TOP 1%

most cited scientists

12.2%

Contributors from top 500 universities



WEB OF SCIENCE™

Selection of our books indexed in the Book Citation Index  
in Web of Science™ Core Collection (BKCI)

Interested in publishing with us?  
Contact [book.department@intechopen.com](mailto:book.department@intechopen.com)

Numbers displayed above are based on latest data collected.  
For more information visit [www.intechopen.com](http://www.intechopen.com)



## Sarcoid-Like Reactions

Shweta Nag  
Meenakshi University,  
India

### 1. Introduction

#### 1.1 History and prevalence

According to a revised definition introduced by the International Conference on Sarcoidosis in 1975, sarcoidosis is a multisystem granulomatous disorder of unknown etiology, most often affecting young adults, in which patients present with hilar lymphadenopathy, pulmonary infiltration, and skin or eye lesions. This definition has been the most accepted till date, although many advancements have been made to understand the pathogenesis of this disease.

Sarcoidosis is a chronic granulomatous disease, which is characterized by the formation of non-caseating granulomas at multiple sites. It is a systemic disorder of unknown etiology, although multiple factors like mycobacterium, viruses like mumps and influenza, beryllium, zirconium, genetic predisposition, autoimmune diseases and also carcinomas, are considered to be responsible for its etiology.

In the first described case of sarcoidosis 120 years ago, it was called "livid papillary psoriasis" by Jonathan Hutchinson. Hutchinson suspected that this was a variant of mumps. The patient presented with purplish skin lesions and gout and later died of renal failure.

Sarcoidosis has been reported to occur in association with malignant tumours, either preceeding or following malignancy. In 1977, a study was conducted on 580 cases of sarcoidosis. Out of these, 7 cases were found to be associated with malignancy. But these authors considered that the association of sarcoidosis to malignant tumour, would be just a co-incidence. (Battesti JP et al., 1977)

By 1987, 23 cases of malignancy following sarcoidosis were reported. It was observed that lung and breast cancer may occur more often than other tumours after sarcoidosis. It was considered that the immunologic abnormalities associated with sarcoidosis may promote the development of certain malignant tumors. (Brincker H, 1987). Patients may rarely present with typical sarcoidosis occurring before, during or after the diagnosis of cancer. Recent studies have documented this type of cases, particularly with lymphomas, testicular and lung cancers, melanomas and hepatocarcinomas. As far as lung cancer is considered, coexistence of sarcoidosis and lung cancer in the same patient is not common, and only 29 such cases have been reported. If bilateral mediastinal lymphadenopathy is found in a case of lung cancer associated with sarcoidosis, surgical tumor resection should be considered.

It has been reported that in patients with malignant diseases, non-caseating epithelioid cell granulomas are occasionally found in lymph nodes draining a region containing the malignant tumor. These non-caseating granulomas are present at single or multiple organ

sites without any clinical evidence to establish the diagnosis of sarcoidosis. For such tumour associated sarcoid granulomas, Nickerson in 1937, gave the term 'sarcoid reaction' and first pointed out the difference between sarcoid reaction and sarcoidosis. (Pavic M, 2008) This was accepted later as tumor-associated histologic changes, termed 'sarcoid reactions' (Takaki et al., 2010)

Granulomas may be found as a sarcoid reaction either within the vicinity of the tumour itself or within the regional lymph nodes draining that particular tumour. In some cases, such reactions can be seen in the non-regional lymph nodes. It was reported in 1986, that overall, sarcoid reactions occur in 4.4% of carcinomas, in 13.8% of patients with Hodgkin's disease, and in 7.3% of cases of non-Hodgkin lymphomas.

In 1997, 5 cases of Sarcoid reaction associated with papiollary carcinoma were reported. Brincker reviewed data on 4020 patients with malignant tumors in a broad spectrum. He found that 4.4% patients with carcinomas and one 0.4% of patients with sarcomas had sarcoid reactions. Sarcoid reaction may be slightly more common in patients with squamous cell carcinomas than in those with adenocarcinomas.

Sarcoid reaction has been observed in association with many kinds of primary tumors and particularly in regional lymph nodes, even in the absence of any metastases. But it is observed in studies that sarcoid reaction occurred about four times more often in regional lymph nodes without metastases than in lymph nodes with metastases. Therefore true sarcoidosis may be confused with local sarcoid reactions in cancer patients. This may lead to misdiagnosis and insufficient treatment. In some cases sarcoidosis may also develop by a preceeding treatment of malignancy. Although observed that, sarcoid reaction reported in Hodgkin's disease and gastric adenocarcinomas, may be associated with a better prognosis.

In a case report, association of sarcoid reactions and hepatocellular carcinoma combining early gastric carcinoma was reported was seen which is the first case of its kind (Kojima M et al., 1993). Granulomas may be found as a sarcoid reaction in the vicinity of regional lymph nodes more frequently than within the tumour itself. Sarcoid like reaction has been observed to be 13% in lymph nodes and 5% in spleen in patients with gastric carcinoma. In addition, none of them showed any symptoms or signs indicative of systemic sarcoidosis. (Abdel-Galiil K, 2006). Clinicians need to adapt specific diagnostic techniques to differentiate neoplasia from benign sarcoid reactions. However, biopsies are necessary in most of cases.

With regard to lung cancer patients, Laurberg et al reported that 20 out of 630 patients (3.2%) had sarcoid reactions in the mediastinal lymph nodes. In addition, they can be found not only in the lymph nodes draining a region containing the malignant tumor, but also in the tumor itself or in non-regional tissues. Some studies have shown that sarcoid reactions are observed within the primary tumor in patients with lung cancer. In 2008 there were three reported cases of sarcoid like reactions in head and neck cancer. In 2010, first case of sarcoid like reaction during chemotherapy for recurrent seminoma was reported. A sarcoid-like reaction was suspected in 1.1% of cancer patients, but the diagnosis was confirmed in 0.6%. (Tanizawa K)

In testicular cancer and lymphomas, association of sarcoidosis and sarcoid-like reactions have been reported. They occur either synchronously or metachronously, and may also occur after chemotherapy. In one such case report the importance of considering the diagnosis of sarcoidosis in patients with metastatic disease emphasised the association of sarcoidosis with head and neck cancer.

## 2. Symptoms

There are no early signs and symptoms of Sarcoidosis. Generalised symptoms are weight loss, fatigue, tiredness, weakness, sluggishness, night sweats, fever, malaise and enlarged lymph nodes. In about 90% of cases, Lungs are involved. Symptoms include, dyspnea, persistent cough and chest pain. Radiographic findings are lung tissue thickening, enlarged chest lymph nodes and small nodules throughout lungs. Eyes are involved in about 20-30% cases, and skin in 20% cases. Skin rashes, red lumps (erythema nodosum), red lumps on the legs (erythema nodosum), purple skin patches.

On the other hand, Sarcoid-like reaction is a localised reaction within tissues in the absence of any respiratory symptoms. A sarcoid-like reaction is often indistinguishable from metastases on radiological studies. Swollen lymph nodes caused by a sarcoid reaction often mimic metastatic lymph nodes. Thus, it is difficult to differentiate sarcoid reaction from lymph node metastases. Except histopathological examination, there is no useful examination for distinguishing them.

Laurberg reported that the frequency of associated sarcoid reactions is 3.2% in patients with pulmonary neoplasms, predominantly in squamous cell carcinomas. Histologically, squamous cell carcinomas show a statistically significant predominance. Sarcoid granulomas are found scattered within the lung parenchyma as well as around the carcinoid tumor. The distribution of this kind of sarcoid reaction is the first description.

## 3. Diagnosis

1. **ROLE OF IMAGING-** It is required that the clinicians adopt non- invasive diagnostic methods to differentiate neoplasia from benign sarcoid reactions. The 18-fluorodeoxyglucose (18-FDG) PET-scan has not been so successful but the adjunction of a [3-(18) F]-alpha-methyltyrosine ((18) F-FMT) PET-scan could be more useful. FDG-PET has been widely used in the assessment of malignancy. It has been observed that the sarcoid lesions could have increased FDG activity(Daniel RP et al.,1980). Differentiation of sarcoidosis from the sarcoid-like reactions is not an easy step in the final diagnosis. Thus, FDG-PET can be used as a diagnostic tool for the final diagnosis.
2. **ROLE OF CD4 + T LYMPHOCYTES-** The T- and B-lymphocyte disturbances in sarcoid patients may be attributed to the effects of a bacterial or viral infection depressing T-cell function. Mycobacteria or some of its components might be capable of inducing the B-cell immune response and the subsequent pathologic changes.
  - 1.1 **Phytohemagglutinin-** It has been observed that, the cultured lymphocytes from patients with depression of delayed-type hypersensitivity, react poorly to phytohemagglutinin. Thus, it has been used in the diagnosis of sarcoidosis as impaired cellular immunity is observed in these patients.
  - 1.2 **Circulating factors-** Other techniques used to expose immunologic defects in peripheral lymphocytes of patients with sarcoidosis include tests of T and B cell function, rosette formation and migration inhibition. There are increased circulating immunoglobulin levels, increased circulating antibody levels to Epstein-Barr, herpes simplex, rubella, measles and parainfluenza viruses, increase antibody response to mismatched blood and occasional false-positive Wassermann reactions, but there is no increase in circulating autoantibodies. (Kazuaki Morohashi ,2003)

- 1.3 Patients with active sarcoidosis, have a depression in systemic cell-mediated immunity manifested by a reduction in the number of circulating T cells and impaired responses of these cells to antigens. When B cell activity is increased, there is elevated serum immunoglobulins and the presence of autoantibodies and circulating immune complexes.
- 1.4 Bronchoalveolar lavage has shown that the sarcoid lung is characterized by increased numbers of "activated" T-lymphocytes within the alveolar structures. In contrast to normal control cells, the lung T-lymphocytes of patients with sarcoid release the mediator, monocyte chemotactic factor, which probably contributes to the pathogenesis of sarcoidosis. The recruitment of blood monocytes to the lung provides cellular building blocks for granuloma formation.
- 1.5 Sarcoidosis is recognized to be a multisystem granulomatous disease characterized by activated, cytokine-producing T cells and macrophages at sites of inflammation. Recent work on the molecular structure of T cell receptor genes in sarcoidosis provide evidence that sarcoidosis is characterized by proliferation of T cell population at sites of inflammation. This is consistent with local antigen-mediated immune responses. In addition, cytokine production in sarcoidosis indicates that tissue inflammation is dominated by expression of cytokines such as interferon-gamma and interleukin-12 that regulate the granulomatous response. These studies offer new insight into the molecular mechanisms of granuloma formation in sarcoidosis and provide a framework for developing new therapeutic strategies for the treatment of this disease.
- 1.6 VEGF has also been reported to enhance the activation and migration of monocytes through the Flt-1 receptor in vitro,<sup>6,7</sup> which are key events in granuloma formation. Genetic studies have demonstrated a significant difference in the allele frequency at locus  $\alpha$  813 between healthy control subjects and patients with sarcoidosis. In sarcoidosis patients, the less common T allele was underrepresented in the sarcoidosis patient population as compared to the C allele which is more common in normal patients. (Kazuaki Morohashi, 2003)
3. **KVEIM'S TEST** -Worldwide figures for the Kveim-Siltzbach skin test are presented. They provide evidence of its specificity in various international series. Kveim-Siltzbach reaction is a response to an unknown Ag(s) and there can be causes of non-specific reactions. In an analysis, Kveim-Siltzbach reaction sites was performed using a PCR technique and primers specific for 20 V beta gene families. Results of this analysis demonstrated a pattern of V beta expression dominated by expression of V beta 2, V beta 3, V beta 6, or V beta 8 to levels > 20% of total V beta gene expression in nine of 15 individuals. (Proenca NG, 1982) Kveim test performed with G-77 antigen obtained from sarcoid lymph nodes. The antigen was tested in 46 patients with proved or suspected sarcoidosis and in 50 controls. Results were; positive in 85,1%. in patients undergoing treatment for more than two years, only 1 out of three was positive. In suspected patients with only on the skin the test was positive in 58,1%. Control group was however negative. (Romer FK, 1985)
4. **ROLE OF ACE**-Elevated levels of angiotensin-converting enzyme (ACE) are observed in the sera of patients with clinically active, biopsy-proved sarcoidosis. The specificity of this test lies in the fact that patients with dormant sarcoidosis and those with various other disorders have normal levels. Elevated levels can also be seen in some cases representing sarcoid variants and some cases each of leprosy, carcinoma, tuberculosis,



lymphomatoid granulomatosis, and immunoblastic sarcoma. Although ACE is sensitive to active sarcoidosis, the presence of false-positive findings limits its diagnostic usefulness to an adjunctive role; the assay should be combined with medical evaluation and tissue biopsy in selected cases. (Romer FK,1980)

A review is given on S-angiotensin-converting enzyme (SACE) and its clinical value, based upon 327 sarcoidosis patients and 1,274 patients with various disorders. SACE was elevated in 55% of the sarcoidosis patients, although with a higher frequency in those with active disease. In non-sarcoid patients, elevated SACE was observed in only 10 cases. The sensitivity and specificity were 0.55 and 0.99, respectively, and the positive and negative predictive values were 0.95 and 0.90, respectively. Elevated SACE pointed strongly towards the presence of sarcoidosis, although reservations must be made in patients with liver disorders, diabetes mellitus, hyperthyroidism, asbestosis or silicosis which are rather common disorders also associated with elevated SACE. Normal SACE does not exclude sarcoidosis. (Shultz T, 1979)

Enzyme activity is higher SACE in patients with pulmonary involvement and changes in SACE are correlated to the roentgenological changes. It has been observed that among healthy controls, significantly higher SACE levels were found in children up to 17 years of age (21.2-42.2 U/ml) than in adults aged 18-65 years (12.0-36.8 U/ml). (Kiminobu Tanizawa,2010). In another study, the correlation between S-angiotensin-converting enzyme and disease activity was examined in 185 observation periods in 85 untreated sarcoidosis patients. An agreement between SACE and chest roentgenographic changes was found in 42% of the observations. The most convenient interval between enzyme measurements seems to be 3 months in patients with active disease. Therefore, it can be interpreted that the pattern of enzyme variation may be a prognostic indicator in sarcoidosis. (Yamauchi M et al., 1997)

5. **IMAGING-** Gallium-67 imaging has been widely used in the diagnosis of sarcoidosis. Gallium-67 is usually taken up in lesions with increased blood flow, typically in lesions of inflammatory origin. In sarcoidosis, a characteristic pattern of uptake in the chest has been described as the "lambda sign:" (paratracheal and bilateral hilar uptake) and the "panda sign," caused by uptake in the lacrimal and parotid glands. (J.T.Annema et al., 2005) Conventional monitors of the activity of pulmonary sarcoidosis, such as blood studies, pulmonary function testing, and chest roentgenograms, do not show as much as assessed by bronchoalveolar lavage or by histopathologic studies.
6. **ROLE OF ENDOSCOPY-** In March 2009, a large international randomized clinical study "Trial for the Diagnosis of Sarcoidosis (GRANULOMA)" was started. This phase III study investigates two different diagnostic strategies for patients with suspected stage I/II pulmonary sarcoidosis. Bronchoscopy was done for 121 patients with establishing the definite diagnosis of sarcoidosis in 57 cases (42%). EUS-FNA was used for diagnosis of sarcoidosis and had a yield of 82% and sensitivity of 89-94% by assessing noncaseating granulomas in mediastinal nodes. In 72 cases, EUS-FNA/EBUS-TBNA was performed, yielding a definite diagnosis in 47 (59%). Endoscopic ultrasound prevented a surgical procedure in more than half of these patients. (Julita Stępień,2010)

Thus, Endoscopic ultrasound-guided fine-needle aspiration has a high yield in diagnosing sarcoidosis. Endoscopic ultrasound-guided fine-needle aspiration will also reduce the number of mediastinoscopies.

The only abnormal finding in laboratory studies was a slightly elevated ESR (to 14 mm/h, normal range: 0–10 mm/h) In a study by Steinfort et al., which analysed lymph node lesions in patients suffering from non-small cell lung cancer, a sarcoid-like reaction was observed in 8 out of 187 patients who had previously undergone thoracoscopy, lobectomy, or pneumonectomy and in 1 out of 50 patients who had undergone endobronchial ultrasound as part of the diagnostic evaluation for cancer. The authors emphasised that the lymph nodes in which sarcoid tissue was found revealed no tumour cells.

7. **ROLE OF AMYLOID-** A role of serum amyloid A (SAA) in pathogenesis of granulomatous inflammation of sarcoidosis has recently been reported. Serum concentrations of SAA are significantly higher in sarcoidosis patients. The results of some studies have suggested suggest that serum amyloid A could be a suitable marker of sarcoidosis; the protein is only expressed in gels of sarcoidosis patients and not in healthy subjects, and the SAA1 isoforms could match the biomarker of sarcoidosis reported previously. Further studies on a larger scale are required to understand the effectiveness of SAA as a clinical biomarker of sarcoidosis. (Bässler R, 1988) During the past decade, advances have been made in the study of sarcoidosis. The multicenter ACCESS (A Case Control Etiologic Study of Sarcoidosis) trial recruited > 700 subjects with newly diagnosed sarcoidosis and matched control subjects. They were unable to identify a single cause of sarcoidosis, but the Mycobacterium tuberculosis catalase-peroxidase protein has been identified as a potential sarcoidosis antigen. Sarcoidosis remains a diagnosis of exclusion most reliably by a tissue biopsy specimen demonstrating non-caseating granulomas in a patient with additional clinical and radiologic features of the disease. The tumor necrosis factor inhibitors, a relatively new class of agents, have been used in some patients. The diagnosis of sarcoid like reactions may be problematic because other known causes of granulomatous inflammation need to be excluded.

#### 4. Histopathology

Histopathological examination of the involved organ is considered to be the most reliable method of diagnosis of Sarcoid like reaction. Sarcoid granulomas characteristically comprise of collections of numerous epithelioid cells along with many multinucleated giant cells. These giant cells can be of two types; either Langhans giant cells or foreign body type of giant cells. Another pathognomic feature of a sarcoid granuloma is the presence of inclusion bodies within the multinucleated giant cells; lamellated calcified masses named: the Schaumann bodies and the star shaped asteroid bodies.

Tumor-related sarcoid reactions have generally been reported to be in the lymph nodes draining regions with a malignancy disease, or in the parenchyma around the tumor. (Klein M, 1994) The induction and evolution of granuloma formation results from a complex interplay between different cell populations, cytokines, and chemokines. Genetic polymorphisms may also influence the clinical expression of the granuloma formation and the prognosis of the disease. Sarcoid reactions in lymph nodes with or without metastasis from a primary malignant neoplasm are well-known. However, it is extremely rare to find these reactions associated with cutaneous solid tumors; only one such case has appeared in the literature. In a patient with cutaneous squamous cell carcinoma sarcoid reactions and metastatic foci in the regional lymph nodes were also associated. The possibilities of systemic sarcoidosis and tuberculosis were excluded after extensive examinations specific

for these diseases. Some authors regard the sarcoid reaction to be a sign of a good prognosis on the basis of studies of a few patients with solid tumors. However, systematic analysis of a sufficient number of cases should be carried out to evaluate the clinical significance of this type of reaction. (Okabe T, 2002) In some cases of invasive ductal and lobular carcinoma of the breast multiple epithelioid and giant cell containing granulomas were detected. These granulomas occurred as sarcoid-like lesions in uni- and bilateral primaries, in a recurrent tumour, and also in axillary lymph nodes. Histopathologically, these granulomas are not quite uniform, some of them show classic features of sarcoidosis, while others show marked proliferations of epithelioid or giant cells. The granulomas contain fibrinoid exudate or areas of necrosis and are surrounded by dense infiltrates of mononuclear cells. Pathogenetically, these are reactions in the tumour stroma of varying intensity, and are caused by T-cell mediated immune response to an carcinoma antigen. (Brincker H, Pedersen NT, 1991). In sarcoidosis, unknown antigen(s) causes Th1-mediated granulomatous inflammation with cytokines such as IFN gamma and IL-12, initially. Furthermore IL-16, IL-8, IP-10 and RANTES also play a role in the accumulation of CD4+ T cell population. For the chemotaxis of macrophages and monocytes, factors like MCP-1, MIP1-alpha and RANTES are considered responsible. Local proliferation of T cell is induced by IL-2 and IL-15 and that of macrophage/monocyte lineage is done by M-CSF, GM-CSF and G-CSF as in cases of other inflammatory reactions. Removal of the antigen downregulates the immune response via TGF $\beta$  and suppresses granuloma formation. Failure of removal of antigen can induce persistence of granuloma and irreversible fibrosis. (Spiteri MA et al., 1989)

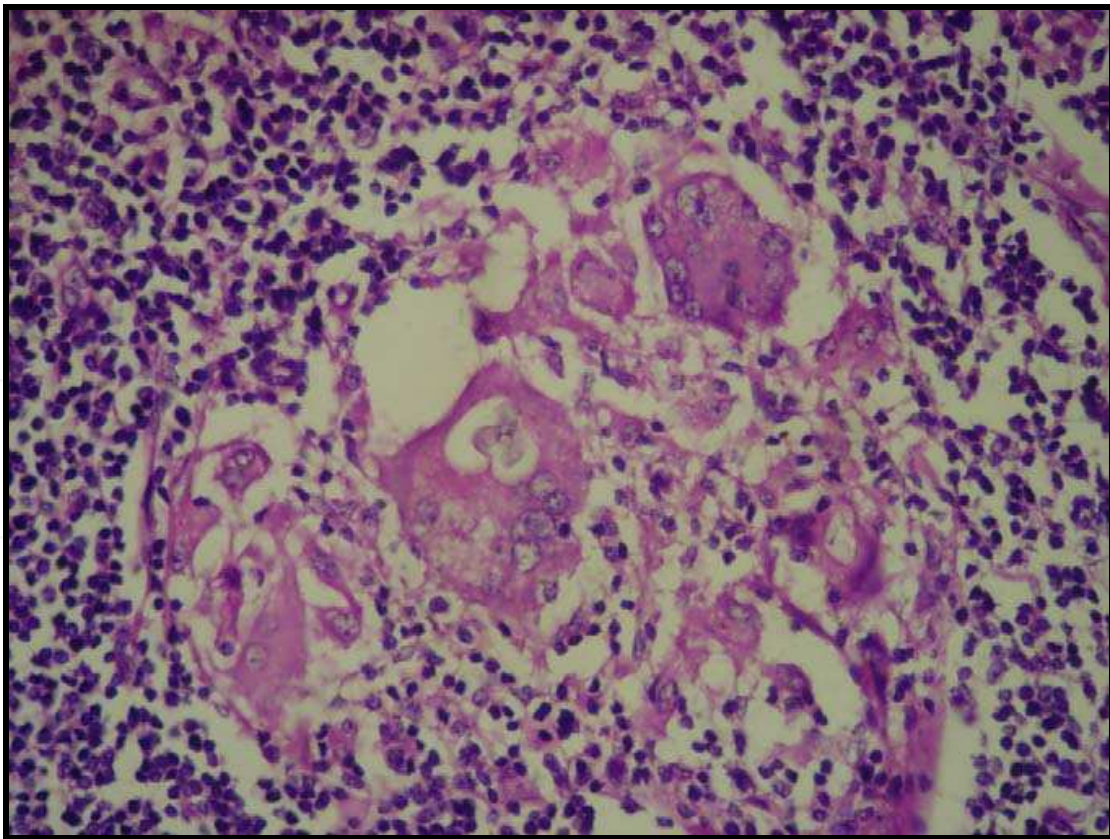


Fig. 1. A Sarcoid granuloma with Schaumann bodies within the multinucleated giant cells.



The pulmonary production of IFN-inducible protein (IP-10), a CXC chemokine that stimulates the directional migration of activated T cells. When compared to control subjects, excessively high levels of IP-10 are demonstrated in the bronchoalveolar lavage (BAL) fluid of patients with pulmonary sarcoidosis. In a study a positive correlation was also demonstrated between IP-10 levels and the number of sarcoid cells in the BAL. Immunohistochemistry was performed with an anti-human IP-10 polyclonal Ab in lymph nodes showing sarcoid granulomas. It was observed that cells bearing IP-10 were mainly epithelioid cells and CD68+ macrophages located inside granulomatous areas. In addition, alveolar lymphocytes recovered from patients with active sarcoidosis were CD4+ T cells expressing Th1 cytokines (IL-2 and IFN- $\gamma$ ) and high levels of CXCR3. All these facts suggest the potential role of IP-10 in regulating the migration and activation of T cells toward sites of sarcoid inflammatory process and the subsequent granuloma formation. (Kin T, 1999)

According to a study, granulomas can be divided into two main "families" according to the presence or absence of B cells within the granulomas: one is a B-cell-negative family comprising of sarcoidosis and mycobacterial infection; the other is a B-cell-positive family comprising of tumor-related sarcoid reactions, toxoplasmosis and other granulomatous lesions of unknown significance.

Sometimes in patients with squamous cell carcinoma of lung, histopathological examination of hilar and mediastinal drainage lymph nodes show many non-caseating epithelioid cell granuloma even in absence of metastasis. Co-existence of sarcoidosis and lung cancer in the same patient is not common, and only 29 cases, have been reported. even if bilateral mediastinal lymphadenopathy is found in a case of lung cancer complicated with sarcoidosis, surgical tumor resection should be considered

One such case of lower esophageal cancer was reported where a lower esophagectomy with a total gastrectomy was performed. A sarcoid-like reaction within lymph nodes can occur even after few year of resection of the tumour.

In some cases, the histological examination may show non-caseous epithelioid granulomas without necrosis in association with moderately differentiated carcinoma without any metastases to the regional lymph nodes; These changes should be considered to be sarcoid reactions, if no other physiological and laboratory findings compatible with systemic sarcoidosis are observed. Such histological findings suggest the possibility that the regional lymph nodes are not involved with the tumor cells at the time of diagnosis of cancer.

The granulomas are present in a lymphatic pattern around bronchovascular structures and, because of this, may show angioinvasion. The bronchial involvement produces a high diagnostic yield for transbronchial and endobronchial biopsies in this disease. Finally, small amounts of fibrinoid necrosis may occur within granulomas of sarcoidosis and do not exclude the diagnosis. A number of cytoplasmic structures/inclusions can be identified within the granulomas of sarcoidosis, including asteroid bodies, Schaumann's bodies, calcium oxalate crystals, and Hamazaki-Wesenberg bodies; the last two of these can cause difficulties in differential diagnosis. Extra-pulmonary sarcoid can be an important factor in prognosis. Involved sites include (in decreasing frequency) skin, endocrine organs, extra-thoracic lymph nodes, neurologic sites, eyes, liver, spleen, bone marrow, cardiac, ear/nose/throat, parotid/ salivary, muscles, bones/joint, and kidney.

The association of soft tissue sarcomas with a granulomatous reaction is very rare, although a case of Kaposi sarcoma containing sarcoid-like granulomas has also been reported. In addition to vascular proliferation, and extravasated erythrocytes numerous spindle cells

were observed. These areas were surrounded by non-caseating granulomas. The patient had no clinical or laboratory findings of sarcoidosis. As mentioned earlier the granulomatous reaction is reported to be a good prognostic indicator in several carcinoma types but its importance in sarcomas is not clear. Another unusual type of condition is coexistence of sarcoid-like reaction with synovial sarcoma. There have been no such reported cases in literature. Therefore, understanding this kind of cases and their pathogenesis may help to improve the understanding of the relationship between malignancy and sarcoid-like reactions.

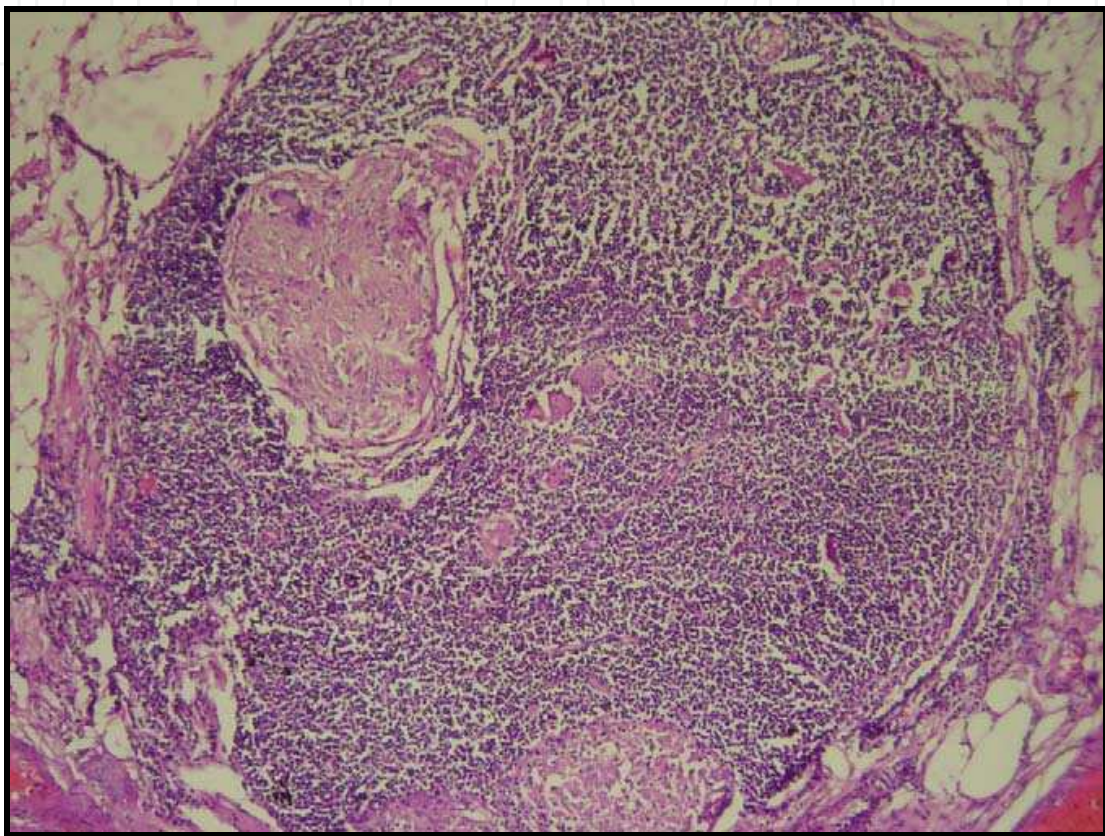


Fig. 2. A cervical lymph node showing non-caseating granulomas comprising of collections epithelioid cells and multinucleated giant cells in the background of Lymphocytes.

The authors report a case of Hodgkin's disease associated with pulmonary and mediastinal sarcoidosis, and the frequency of sarcoid reactions in lymphoma, notably in Hodgkin's disease. The Hodgkin's disease-sarcoidosis association is much less common and sometimes raises difficult diagnostic problems. (Agostini Cet al.,1998)

Electron microscopic examination of epithelioid-cell granulomas of has revealed a morphologic polarization of epithelioid cells, manifesting as 4 zones: crimped [correction of chimp] edge zone, zone of vesicles and vacuoles, basal zone and osmiophilic granules zone. The structure of epithelioid cells in sarcoidosis and in sarcoid reactions are found to be similar. Sarcoid epithelioid cells are believed to be a variant of tissue macrophages, which are derived from circulating monocytes in blood. It is a known fact that formation of monocytes and macrophages is controlled by hematopoietic growth factors, i.e.; colony-stimulating factors in the bone marrow. In the presence of colony-stimulating factors and

vitamin D3, blood monocytes can proliferate and differentiate into epithelioid cells and multinucleated giant cells. Recent observations have shown that sarcoid granulomas themselves produce colony-stimulating factors and vitamin D3 which stimulate the proliferation and differentiation of circulating monocytes into macrophage-epithelioid cells. This also leads to formation of new sarcoid granulomas.

Regarding the association of malignancy with sarcoidosis, various possibilities have been proposed to explain the occurrence of malignancy in sarcoidosis, namely, the occurrence of these two disorders together being a coincidence; sarcoidosis initiating the carcinogenesis or promoting the growth of malignancy via suppression of cellular immunity; and sarcoidosis occurring as a result of host immunological response against malignancy. However, in the absence of systemic involvement, the diagnosis is suggestive of a sarcoid reaction associated with a malignancy, rather than sarcoidosis.

In addition to the pathognomic, asteroid and Schaumann bodies, reactive hyperplasia within the Lymph nodes can also be observed. This could be explained on the basis of specific cell mediated immune response against the soluble antigenic factors derived from the tumor cells by both activated macrophages and T lymphocytes. Thus the granulomatous reaction and subsequent release of cytokines such as TNF- $\alpha$ , IL-2 and IL-8 might be a marker of an immunologically mediated anti-tumor response.

Three possible mechanisms are offered for the mode of formation of asteroid bodies, namely phagocytosis and partly fused cell membranes; trapping and polymerization of collagen within incompletely fused epithelioid cells; and transformation of epithelioid cells into fibroblasts during the healing of granulomas. The latter possibility of epithelioid cells being transformed into fibroblasts, is favored but requires more evidence in support of fibroblastic potentiality of epithelioid cells and macrophages.

The mechanism of the formation of Schaumann bodies can be explained on the basis of different concepts. Most of the authors who have previously examined these structures have considered them to be products of degeneration of elastic fibrils impregnated with calcium and iron salts. Schaumann advanced the opinion that tubercle bacilli can be transformed into such bodies. It is also believed that these bodies may result from deposition around elastic fibrils, connective tissue fibrils, or hair resulting from disintegrated tubercle bacilli and proposed that they are products of intracellular globulin precipitate.

Sarcoid granulomata result from aberrant immunological reactions initiated by antigen-presenting macrophage-like cells, and maintained by other effector macrophages. These macrophages can be distinguished phenotypically by monoclonal antibodies RFD1 and RFD7 (which recognize dendritic cells and mature macrophages respectively). A study has shown that active sarcoid BAL contains a high proportion of RFD1 + cells (mean 44.7% compared to 12% in normals). Furthermore it has been demonstrated that gamma-interferon, produced in high concentration by activated T-lymphocytes induces not only HLA-DR molecules on cells, but has also been shown in vitro to increase the proportion of RFD1+ cells but suppressing RFD7 expression. Therefore, It seems that the increased proportion of RFD1+ D7+ macrophages seen in active sarcoidosis could arise as a result of an increased induction of RFD1 expression on macrophages which express RFD7. (Sugio K, 1993)

## 5. Differential diagnosis

The first step in getting correct treatment is to get a correct diagnosis. Granulomas have also been observed within the lymph nodes associated with other granulomatous diseases.



Differential diagnosis list for Sarcoidosis may include: berylliosis, tuberculosis, hypersensitivity pneumonitis (farmer's lung disease), Fungal infections, Rheumatoid arthritis, Rheumatic fever, Lymphoma, Histoplasmosis, Coccidioidomycosis, Idiopathic pulmonary fibrosis, Pneumoconiosis, Syphilis. In 1994, Leibow first described a condition termed; Necrotizing sarcoid granulomatosis (NSG). Based on radiological and clinical features, it was concluded that NSG is the histopathological variant of sarcoidosis, also termed "nodular sarcoidosis. Necrotizing sarcoid granulomatosis has been reported in 1.6% to 4% of patients with sarcoidosis. Although it comprises of sarcoid-like granulomas, they are associated with granulomatous pneumonitis, variable amounts of necrosis and granulomatous vasculitis. Radiographic nodules made up of multiple granulomas are also found.

Common variable immunodeficiency (CVID) is a disorder characterized by hypogammaglobulinemia, poor antibody responses and recurrent bacterial infections. CVID patients have a higher prevalence of autoimmune disease and some of them develop noncaseating granulomas of the lungs, spleen, liver, skin, lymph nodes and eye. In patients with CVID, different types of autoimmune disease could be seen. Therefore, these patients should be carefully evaluated for diseases other than sarcoidosis.

An anti-Kveim monoclonal antibody, IHY-1, was developed which reacts with sarcoid granulomas as well as with epithelioid cells of various granulomatous diseases including tuberculosis. Thus differentiation of Sarcoid granulomas with granulomas of other conditions was difficult. Recently, 2 new anti-Kveim monoclonal antibodies, IHY-2 and IHY-3 were developed which reacted with epithelioid cells in sarcoidosis but not in tuberculosis. Immunoperoxidase technique was used and it was observed that these antibodies reacted with most epithelioid cells in sarcoid granulomas, confirming the fact that these cells expressed the antigen present in the Kveim reagent. (Balamurugan S, 2009)

Granulomatous reactions have been reported in association with lymphomas, more often with Hodgkins disease than with Non-Hodgkins Lymphoma. Not many reports are available on the association of anaplastic large-cell lymphoma with sarcoid-type granuloma. It is suggested that a detailed clinical history, careful histological examination and immunohistochemistry helped in attaining the correct diagnosis.

Problems may also arise of distinguishing between tumour-related sarcoid reactions and true systemic sarcoidosis. As mentioned earlier, the diagnosis of sarcoidosis is based more on exclusion criteria and thorough clinical and radiological investigations are required to differentiate it from sarcoid like reactions. This differentiation is essential for further treatment planning and prevention of recurrence of disease. Most probably, sarcoid reactions are caused by antigenic factors derived from the tumour cells, eliciting an immunological hypersensitivity reaction leading to the formation of epithelioid-cell granulomas. Sarcoid reactions may be a marker of an immunologically mediated anti-tumour response of macrophages activated by T-lymphocytes, and in Hodgkin's disease there is evidence that patients with sarcoid reactions have a better prognosis. Sometimes, sarcoid reactions may be so extensive that they complicate the diagnosis of an underlying malignant disease.

Previous reports indicate that enlarged hilar and mediastinal lymph nodes caused by sarcoid-like reactions may develop after curative resection of cancer. This presence does not indicate recurrence. Reports further suggest that coexisting pulmonary infiltrates in this setting may be related to sarcoidosis. In a study, two patients who had resected lung and gastric cancer and who later developed pulmonary interstitial infiltrate, concurrent with



progressive mediastinal lymphadenopathy initially thought to be caused by intrathoracic dissemination of their cancer. These changes were shown by open lung biopsy to be a benign, granulomatous reaction interpreted as sarcoidosis. Thus, it is important to recognize this clinical pattern when pulmonary infiltrates develop after complete treatment of cancer in an otherwise relapse-free patient and to encourage lung or lymph node biopsy in these particular settings in order to confirm a sarcoid-like reaction, thereby avoiding unnecessary chemotherapy for presumed tumor recurrence.

During microscopic examination of sections of lymph nodes, it may give an appearance of a metastatic node with numerous collections of tumour cells. But careful observation may reveal that they are actually epithelioid cells with presence of other pathognomonic features of sarcoid granulomas like, presence of Schaumann bodies and asteroid bodies. Further confirmation of sarcoid like reaction requires ruling out of any systemic involvement by radiographs, ACE level assessment and other investigation procedures which are specific for sarcoidosis.

## 6. Treatment

A standard treatment with immune suppressants such as glucocorticoids should be started. In some of the patients recover spontaneously without any treatment. In other patients, a treatment is necessary during the follow-up course. Immunosuppressive drugs like hydroxychloroquine and infliximab may be useful in some patients. Treatment should be continued at least for about one year. Initially, patients should receive prednisone or prednisolone at 0.5 to 1 mg/kg daily for 6 to 12 weeks to obtain a complete remission, and then later followed by a gradual dose reduction every 6 to 12 weeks. The follow up should be carried out for about three years. When corticosteroids are contraindicated, methotrexate and azathioprine in low doses are the most useful immunosuppressive drugs. Hydroxychloroquine and chloroquine are indicated in extensive skin lesions or as corticosteroids sparing agents. Recent advancements in the field of Biotechnology has resulted in new treatment strategies like use of monoclonal antibodies. In patients with sarcoidosis, only the use of monoclonal antibodies that block tumour necrosis factor (TNF) has been studied scientifically and at present, TNF-blockers are used in patients with therapy refractory sarcoidosis

In a Literature review, accessed through MEDLINE (1966-August 2002), OVID (2001-January 2003), and bibliographic searches, the use of infliximab in the treatment of sarcoidosis was evaluated. It was observed that, tumor-necrosis factor-alpha blockade appeared to be a suitable strategy for treating sarcoidosis. Since the evidence for above concept is not sufficient, further data are required to establish the role of infliximab. (Serio PN, 2003)

## 7. Prognosis

of sarcoidosis is often good. About 60-70% cases heal spontaneously within 24-36 months and fatal complications are observed only in 5-10% of patients which may be due to respiratory involvement. Estimated mortality rate for sarcoidosis from prevalence and deaths statistics is 20 per 100,000 overall; 5 in 100,000 white people; 40 out of 100,000 black people; Scandinavia 64 out of 100,000 people. The ratio of deaths to prevalence is 1.1%. As

far as sarcoid like reactions are considered, the resection of the tumour to which it is associated and the related surgical treatment of the involved organ and, would be sufficient to restore patient's normal condition. It is considered that granulomatous sarcoid-like lesions are indicative of an immunologically mediated antitumor response of macrophages activated by T lymphocytes. Thus leading to a favorable prognosis.

## 8. Conclusion

The diagnosis of sarcoidosis, could be difficult; in fact typical laboratory findings of sarcoidosis such as ACE, lysozyme, calcium, sometimes may not be diagnostic. Ultrasonography and CT are important but the diagnosis is mainly established only with the histological examination of suspected lesions. As it is not possible to distinguish sarcoid-like reaction from sarcoidosis only histologically, a thorough investigation of the patient is mandatory to rule out systemic sarcoidosis or other granulomatous diseases. The concept of correlation between various types of malignancies and sarcoid-like reaction and sarcoidosis is still unclear. Further studies are required to explain this concept more accurately.

## 9. References

- Abdel-Galiil K, Anand R, Sharma S, Brennan PA, Ramchandani PL, Ilankovan V.(2006) Incidence of sarcoidosis in head and neck cancer. *Epub* ; 46(1):59-60.
- Agostini C, Facco M, Chilosi M, Semenzato G (2001) Alveolar macrophage-T cell interactions during Th1-type sarcoid inflammation. *Microsc Res Tech*;53(40):278-7.
- Agostini C, Cassatella M, Zambello R, Trentin L, Gasperini S, Perin A, Piazza F, Siviero M, Facco M, Dziejman M, Chilosi M, Qin S, Luster AD, Semenzato G.( 1998) Involvement of the IP-10 chemokine in sarcoid granulomatous reactions. *J Immunol*;161(11):6413-2.
- Artac H, Bozkurt B, Talim B, Reisli I (2009) Sarcoid-like granulomas in common variable immunodeficiency. *Rheumatol Int*.
- Balamurugan S, Rajasekar B, Rao RR (2009) Anaplastic large-cell lymphoma with florid granulomatous reaction: a case report and review of literature. *Indian J Pathol Microbiol.*; 52(1):69-70.
- Battesti JP, Turiaf J, Hincky JM, Dournovo P (1977) Sarcoidosis and malignant tumors. *Nouv Presse Med*; 6(14):1213-5.
- Bargagli E, Magi B, Olivieri C, Bianchi N, Landi C, Rottoli P (2011) Analysis of serum amyloid A in sarcoidosis patients. *Respir Med*.
- Bässler R, Birke F (1988) Histopathology of tumour associated sarcoid-like stromal reaction in breast cancer. An analysis of 5 cases with immunohistochemical investigations. *Virchows Arch A Pathol Anat Histopathol*;412(3):231-9.
- Brincker H, Pedersen NT (1991)Immunohistologic separation of B-cell-positive granulomas from B-cell-negative granulomas in paraffin-embedded tissues with special reference to tumor-related sarcoid reactions*APMIS*. ;99(3):282-90..
- Brincker H. (1986) Sarcoid reactions in malignant tumours. *Cancer Treat Rev*; 13(3):147-56.
- Brincker H (1987). Solid tumors preceding or following sarcoidosis. *Med Pediatr Oncol*;15(2):82-8.

- Daniele RP, Dauber JH, Rossman MD (1980) *Ann Intern Med*;92(3):406-16. Immunologic abnormalities in sarcoidosis.
- de Hemricourt E, De Boeck K, Hilte F, Abib A, Kockx M, Vandevivere J, De Bock R.(2008) Sarcoidosis and sarcoid-like reaction following Hodgkin's disease. Report of two cases. *Nihon Kokyuki Gakkai Zasshi*. 2008 Jun;46(6):505-9.
- Giovinale M, Fonnesu C, Soriano A, Cerquaglia C, Curigliano V, Verrecchia E, De Socio G, Gasbarrini G, Manna R (2009) Atypical sarcoidosis: case reports and review of the literature. *Eur Rev Med Pharmacol Sci*. ; 13 Suppl 1:37-44.
- Hashem, S A, Sultan, Al-Hussaini M, Hawari F and Yaser.(2010) S Pulmonary sarcoid-like reaction in metastatic synovial sarcoma. *Respiratory Medicine CME*. Article in Press.
- Ishioka S, Wiwien HW, Hiyama K, Maeda A, Yamakido M (1999). New monoclonal antibodies against the epithelioid cells in sarcoid granulomas. *Exp Lung Res*; 25(8):663-70.
- J.T.Annema, M.Veselic. (2005) Endoscopic ultrasound-guided fine-needle aspiration for the diagnosis of sarcoidosis. *Eur Respir J*; 25: 405–409
- Julita Stępień<sup>1</sup>, Joanna Domagała-Kulawik<sup>1</sup>, Radosław Chądryński<sup>1</sup>, Włodzimierz Kupis, Ryszarda Chazan (2010) Sarcoidal reaction in lung adrenocarcinoma in 50-year old man *Pneumonol Alergol. Pol*; 78(4):302–305.
- Kazuaki Morohashi, Toshinori Takada; Kentaro Omori, Eiichi Suzuki, and Fumitake Gejyo (2003) Vascular Endothelial Growth Factor Gene Polymorphisms in Japanese Patients With Sarcoidosis. *CHEST*;123:1520–6.
- Kaminsky P, Deibener J, Cocciale MP, DucM(1994) Sarcoid reactions in cystic duct carcinoma. *Chest* 106: 1304.
- Kiminobu Tanizawa, Eisaku Tanaka , Seishu Hashimoto, Satoshi Noma, Yoichiro Kobashi, Kazuhiro Okumura,
- Toru Shindo and Yoshio Taguchi (2010)Paradoxical Development of a Sarcoid-Like Reaction during Successful Chemotherapy for Seminoma. *Inter Med*; 49: 1423-6.
- Kin T, Shimano Y, Shinomiya Y, Nakano H (1999) Double cancers of the lung and esophagus associated with a sarcoid-like reaction in their regional lymph nodes: report of a case. *Surg Today*;29(3):260-3.
- Klein JT, Horn TD, Forman JD, Silver RF, Teirstein AS, Moller DR (1995) Selection of oligoclonal V beta-specific T cells in the intradermal response to Kveim-Siltzbach reagent in individuals with sarcoidosis. *J Immunol* ; 154(3):1450-6.
- Kojima M, Nakamura S, Fujisaki M, Hirahata S, Hasegawa H, Maeda D, Suito T, Motoori T, Joshita T, Suzuki K, Suchi T.(1999) Sarcoid-like reaction in the regional lymph nodes and spleen in gastric carcinoma: a clinicopathologic study of five cases. *Surg Today*;29(6); 549-52.
- Komatsu M, Itoh N, Yazawa M, Kobayashi S, Inoue K, Kuroda T (1997) Sarcoid reaction in thyroid diseases: report of a case of thyroid carcinoma demonstrating sarcoid reaction in regional lymph nodes. *Endocr J*; 44(5):697-700.
- Lattaignant JC, Margent P, Arondelle C, Carvaillo D, Groussard O, Battesti JP. (1987) Solid tumours preceding or following sarcoidosis. *Medical and Pediatric Oncology*; 15:2:82-88.


- Laurberg P(1975) Sarcoid reactions in pulmonary neoplasms. *Scand J Respir Dis*; 56:20.
- Londner C, Zendah I, Freynet O, Carton Z, Dion G, Nunes H, Valeyre D. (2011) Treatment of sarcoidosis. *Rev Med Intern* Feb;32(2):109-113.
- Maeda J, Ohta M, Hirabayashi H, Matsuda H (2005)False positive accumulation in 18F fluorodeoxyglucose positron emission tomography scan due to sarcoid reaction following induction chemotherapy for lung cancer. *J Thorac Cardiovasc Surg*; 53(4):196-8.
- Morgenthau AS, Iannuzzi MC (2011) Recent advances in sarcoidosis. *Chest*; 139(1):174-82
- Okabe T. Origin of epithelioid cells in sarcoid granuloma. *Nippon Rinsho* (2002) Sep; 60(9):1714-9.
- Paparel P, Devonec M, Perrin P, et al. (2007) Association between sarcoidosis and testicular carcinoma: a diagnostic pitfall. *Vasc Diffuse Lung Dis*.24; 95-101.
- Parra ER, Canzian M, Saber AM, Coêlho RS, Rodrigues FG, Kairalla RA, de Carvalho CR, Capelozzi VL (2004) Pulmonary and mediastinal "sarcoidosis" following surgical resection of cancer. *Pathol Res Pract*.; 200(10):701-5.
- Pavic M, Debourdeau P, Vacelet V, Rousset H (2008). Sarcoidosis and sarcoid reactions in cancer. *Rev Med Interne*. 29(1):39-45.
- Proenca NG, Kliemann TA, Muller H (1982) Kveim test performed with antigen obtained from lymph nodes. *Med Cutan Ibero Lat Am*.10(4):255-60.
- Pulmonary sarcoidosis: a disease characterized and perpetuated by activated lung T-lymphocytes. *Ann Intern Med*; 94(1):73-94. No authors listed.
- Rajendran R, Sivapathasundharam B (2006) *Shafer's Textbook of Oral Pathology*; (5th edition): Reed Elsevier India Private Limited.
- Rømer FK (1980) Angiotensin-converting enzyme in newly detected sarcoidosis. With special reference to enzyme levels in patients with erythema nodosum. *Acta Med Scand*. ; 208(6):437-43.
- Rømer FK (1981) Correlation between disease activity, one-year prognosis, and angiotensin-converting enzyme in untreated sarcoidosis. *Acta Med Scand*.; 210(1-2):111-7.
- Romer FK (1985) Angiotensin-converting enzyme activity in sarcoidosis and other disorders. *Sarcoidosis*; 2(1):25-34.
- Serio RN (2003). Infliximab treatment of sarcoidosis. *Ann Pharmacother*.; 37(4):577-81.
- Shultz T, Miller WC, Bedrossian CW (1979) Clinical application of measurement of angiotensin-converting enzyme level. *AMA*; 242(5):439-41.
- Sugiyama Y, Oshikawa K (2002) Mechanism of sarcoid granuloma formation--participation of cytokines and chemokines. *Nippon Rinsho*; 60(9):1728-33.
- Spiteri MA, Poulter LW, Geraint-James D (1989) The macrophage in sarcoid granuloma formation. *Sarcoidosis*; 6 (1):12-4.
- Takaaki Fujii Yuichi Tabe Reina Yajima Soichi Tsutsumi Takayuki Asao Hiroyuki Kuwano. (2010). Adenocarcinoma of Ascending Colon Associated with Sarcoid Reaction in Regional Lymph Nodes. *Case Rep Gastroenterol*; 4:118-23.
- Tanizawa K, Tanaka E, Hashimoto S, Noma S, Kobashi Y, Okumura K, Shindo T, Taguchi Y.Paradoxical development of a sarcoid-like reaction during successful chemotherapy for seminoma. *Intern Med*; 49(14):1423-6.



Yamauchi M, Inoue D, Fukunaga Y, Kakudo K, Koshiyama H (1997) A case of sarcoid reaction associated with papillary thyroid carcinoma. *Thyroid* ; 7(6):901-3.

IntechOpen

IntechOpen



### **Sarcoidosis Diagnosis and Management**

Edited by Prof. Mohammad Hosein Kalantar Motamed

ISBN 978-953-307-414-6

Hard cover, 280 pages

**Publisher** InTech

**Published online** 17, October, 2011

**Published in print edition** October, 2011

Sarcoidosis is a type of inflammation that occurs in various locations of the body for no known reason. Normally, when foreign substances or organisms enter the body, the immune system will fight back by activating an immune response. Inflammation is a normal part of this immune response, but it should subside once the foreign antigen is gone. In sarcoidosis, the inflammation persists, and some of the immune cells form abnormal clumps of tissue called granulomas. The disease can affect any organ in the body, but it is most likely to occur in the lungs. It can also affect the skin, eyes, liver, or lymph nodes. Although the cause of sarcoidosis is not known, research suggests that it may be due to an extreme immune response or extreme sensitivity to certain substances. It also seems to have a genetic component as well, and tends to run in families. Sarcoidosis most commonly develops in people between 20 and 50 years of age. African Americans are somewhat more likely to develop sarcoidosis than Caucasians, and females are somewhat more likely to develop sarcoidosis than males. The symptoms of sarcoidosis depend on the organ involved. This book deals with the diagnosis and treatment of this mysterious disease of unknown etiology.

### **How to reference**

In order to correctly reference this scholarly work, feel free to copy and paste the following:

Shweta Nag (2011). Sarcoid-Like Reactions, Sarcoidosis Diagnosis and Management, Prof. Mohammad Hosein Kalantar Motamed (Ed.), ISBN: 978-953-307-414-6, InTech, Available from:  
<http://www.intechopen.com/books/sarcoidosis-diagnosis-and-management/sarcoid-like-reactions>

**INTECH**  
open science | open minds

### **InTech Europe**

University Campus STeP Ri  
Slavka Krautzeka 83/A  
51000 Rijeka, Croatia  
Phone: +385 (51) 770 447  
Fax: +385 (51) 686 166  
[www.intechopen.com](http://www.intechopen.com)

### **InTech China**

Unit 405, Office Block, Hotel Equatorial Shanghai  
No.65, Yan An Road (West), Shanghai, 200040, China  
中国上海市延安西路65号上海国际贵都大饭店办公楼405单元  
Phone: +86-21-62489820  
Fax: +86-21-62489821

© 2011 The Author(s). Licensee IntechOpen. This is an open access article distributed under the terms of the [Creative Commons Attribution 3.0 License](https://creativecommons.org/licenses/by/3.0/), which permits unrestricted use, distribution, and reproduction in any medium, provided the original work is properly cited.

IntechOpen

IntechOpen