

We are IntechOpen, the world's leading publisher of Open Access books Built by scientists, for scientists

6,900

Open access books available

186,000

International authors and editors

200M

Downloads

Our authors are among the

154

Countries delivered to

TOP 1%

most cited scientists

12.2%

Contributors from top 500 universities



WEB OF SCIENCE™

Selection of our books indexed in the Book Citation Index
in Web of Science™ Core Collection (BKCI)

Interested in publishing with us?
Contact book.department@intechopen.com

Numbers displayed above are based on latest data collected.
For more information visit www.intechopen.com



Acquired Ichthyosiform Erythrodermia Sarcoidosis

Hui-Jun Ma

*Department of Dermatology,
The 309 Hospital of Chinese People's liberation army,
China*

1. Introduction

Sarcoidosis is a systemic disease that can involve almost any organ system. Infiltration with noncaseating granulomas is the hallmark of the disease, and it may result in various clinical manifestations ¹. Cutaneous involvement occurs in 25% of patients with systemic sarcoidosis and may occur without systemic involvement. Because lesions assume a vast array of morphologies, cutaneous sarcoidosis is known as one of the “great imitators” in dermatology ². The important specific lesions are lupus pernio, plaques and maculopapular eruptions. The most frequent nonspecific lesion is erythema nodosum. Other specific skin changes include subcutaneous nodules, erythema multiforme-like erythemas, alopecia, scars, verrucous outgrowths, psoriasiform lesions, ulcerative lesions, hypopigmentation, lichenoid lesions, ichthyosiform lesions and a sporadic type of erythroderma ^{1,2}. Ichthyosiform and erythrodermic form of cutaneous sarcoidosis are all rare presentation of cutaneous sarcoidosis. The association of them in one case is extremely rare. To date, there are only three cases reported in English literature ³⁻⁵.

2. Methods to use for diagnosis

Correctly diagnosing sarcoidosis may be a challenge. Unfortunately, no single test can prove the diagnosis. Patients are diagnosed with sarcoidosis when a compatible clinical or radiologic picture is present, along with histologic evidence of noncaseating granulomas, and when other potential causes, such as infections, are excluded. The following tests are needed.

Laboratory tests: Urine and blood routine examination; 24h amount of urine protein; Serum calcium and glucose, liver function and kidney function tests; Erythrocyte sedimentation rate; C-reaction protein, tuberculin test, antinuclear antibody.

Cardiologic examination: Electrocardiography; 24h Holter monitoring electrocardiogram

Ultrasonography: ultrasonography for liver, bladder, spleen, kidney, pancreas.

X-ray: computer tomography scan of chest and abdomen

Histopathologic examination: Biopsy for an eruption, a periodic acid-Schiff stain for fungi, a Ziehl-Nielsen stain for acid fast bacilli, and a Steiner stain are also needed to exclude infections.

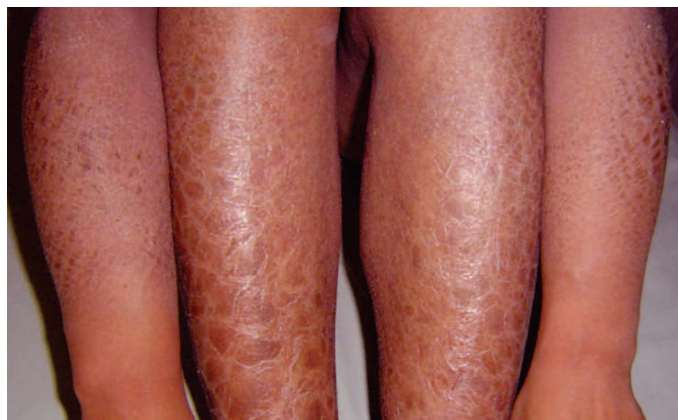
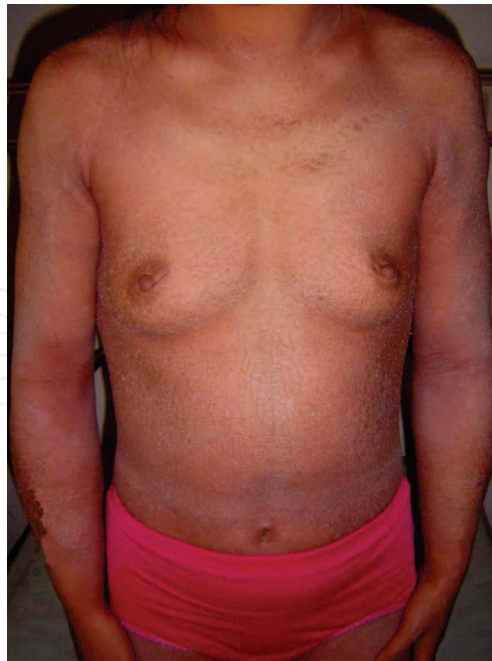
Fig. 1. The flushing, swelling and dry scaling of skin were seen throughout the whole body in a 27-year-old Chinese female patient with ichthyosiform erythrodermia Sarcoidosis. The Ichthyosiform skin lesions especially seen in upper and lower extremities.

3. Treatment protocol

The treatment of cutaneous sarcoidosis is often frustrating, because lesions may be refractory to treatment or may recur following successful treatment. Systemic glucocorticoids are the most effective agents. They are commonly used at slow, tapering dosages, starting at 20 to 40 mg of oral prednisone daily for four to six weeks. Many other medications such as hydroxychloroquine (Plaquenil), methotrexate (Rheumatrex) and thalidomide (Thalomid) may be used in refractory cases ^{3,6,7}

4. Different diagnoses

Acquired ichthyosis and erythrodermia in adult frequently signifies internal diseases, such as sarcoidosis, malignancy et al ^{8,9}. The malignant condition included lymphomas, especially

Hodgkin's disease and mycosis fungoides, multiple myeloma; carcinomas of the lung, breast, and cervix; Kaposi's sarcoma; and leiomyosarcoma ^{2,8,9}. Other systemic diseases that may be characterized by acquired ichthyosis include Hansen's disease, hypothyroidism, phrynoderma, and chronic malnutrition ^{1,10}.

5. Prognosis

Sarcoidosis can affect any organ of the body but most commonly involves the lungs, lymph nodes, skin, and eyes. Less common but usually severe manifestations also occur in the central nervous system, heart, and skeletal system ^{2,4,8}. Cutaneous manifestations are present in approximately 25 percent of patients and are classified as specific or nonspecific based upon the presence or absence of noncaseating granulomas on histopathologic examination ¹⁰. The relationship between cutaneous and systemic sarcoidosis is being studied. Cutaneous involvement in systemic sarcoidosis may occur at any stage of the disease. However, it is most often present at the onset and may even be the presenting complaint ¹¹. Certain types of cutaneous lesions may have a bearing on prognosis of systemic sarcoidosis. Lesions of lupus pernio, erythrodermia, seem likely to associate with more severe systemic involvement, while erythema nodosum often indicates acute benign disease ^{3,4,8}. Every patient with cutaneous sarcoidosis requires an initial work-up for systemic involvement, followed by periodic screening.

6. Conclusion


Sarcoidosis is a multisystem disease that may involve almost any organ system. Therefore, it results in various clinical manifestations. Cutaneous sarcoidosis is known as one of the "great imitators" in dermatology. Ichthyosiform and erythrodermic form of cutaneous sarcoidosis is extremely rare. To date, there are only three cases reported in English literature. Sarcoidosis can affect any organ of the body but most commonly involves the lungs, lymph nodes, skin, and eyes. The Correctly diagnosing sarcoidosis may be a challenge. Unfortunately, no single test can prove the diagnosis. The treatment of cutaneous sarcoidosis is often frustrating. Systemic glucocorticoids are the most effective agents.

7. References

1. Sawhney M, Sharma YK, Gera V, Jetley S. Ichthyosiform sarcoidosis following chemotherapy of Hodgkin's disease. *Indian J Dermatol Venereol Leprol*. 2003; 69(3):220-222.
2. Tchernev G. Cutaneous sarcoidosis: the "great imitator": etiopathogenesis, morphology, differential diagnosis, and clinical management. *Am J Clin Dermatol*. 2006; 7(6):375-382.
3. Feind-Koopmans AG, Lucker GP, van de Kerkhof PC. Acquired ichthyosiform erythroderma and sarcoidosis. *J Am Acad Dermatol*. 1996 ;35(5 Pt 2):826-828.
4. Amal S, Khadir K, Agzour K, Nejiam F, Badre L, Sqalli S, Lakhdar H. Ichthyosiform erythroderma: atypical manifestation of sarcoidosis *Ann Dermatol Venereol*. 2000; 127(1):64-66.

5. Zhang H, Ma HJ, Liu W, Yuan XY. Sarcoidosis characterized as acquired ichthyosiform erythroderma. *Eur J Dermatol*. 2009; 19(5):516-517.
6. Cather JC, Cohen PR . Ichthyosiform sarcoidosis. *J Am Acad Dermatol* 1999; 40(5 pt2):862-865.
7. Matarasso SL, Bruce S. Ichthyosiform sarcoidosis: report of a case. *Cutis*. 1991; 47(6):405-408.
8. Mañá J, Marcoval J, Graells J, Salazar A, Peyrí J, Pujol R. Cutaneous involvement in sarcoidosis: relationship to systemic disease. *Arch Dermatol* 1997; 133(7):882- 888.
9. Yoon CH, Lee CW .Case 6. Erythrodermic form of cutaneous sarcoidosis. *Clin Exp Dermatol*. 2003; 28(5):575-576.
10. Rosenberg B. Ichthyosiform sarcoisis. *Dermatol Online J*. 2005 Dec 30; 11(4):15.
11. Katta R. Cutaneous sarcoidosis: a dermatologic masquerader. *Am Fam Physician*. 2002; 65(8):1581-1584.

IntechOpen



Sarcoidosis Diagnosis and Management

Edited by Prof. Mohammad Hosein Kalantar Motamedi

ISBN 978-953-307-414-6

Hard cover, 280 pages

Publisher InTech

Published online 17, October, 2011

Published in print edition October, 2011

Sarcoidosis is a type of inflammation that occurs in various locations of the body for no known reason. Normally, when foreign substances or organisms enter the body, the immune system will fight back by activating an immune response. Inflammation is a normal part of this immune response, but it should subside once the foreign antigen is gone. In sarcoidosis, the inflammation persists, and some of the immune cells form abnormal clumps of tissue called granulomas. The disease can affect any organ in the body, but it is most likely to occur in the lungs. It can also affect the skin, eyes, liver, or lymph nodes. Although the cause of sarcoidosis is not known, research suggests that it may be due to an extreme immune response or extreme sensitivity to certain substances. It also seems to have a genetic component as well, and tends to run in families. Sarcoidosis most commonly develops in people between 20 and 50 years of age. African Americans are somewhat more likely to develop sarcoidosis than Caucasians, and females are somewhat more likely to develop sarcoidosis than males. The symptoms of sarcoidosis depend on the organ involved. This book deals with the diagnosis and treatment of this mysterious disease of unknown etiology.

How to reference

In order to correctly reference this scholarly work, feel free to copy and paste the following:

Hui-Jun Ma (2011). Acquired Ichthyosiform Erythrodermia Sarcoidosis, *Sarcoidosis Diagnosis and Management*, Prof. Mohammad Hosein Kalantar Motamedi (Ed.), ISBN: 978-953-307-414-6, InTech, Available from: <http://www.intechopen.com/books/sarcoidosis-diagnosis-and-management/acquired-ichthyosiform-erythrodermia-sarcoidosis>

INTECH
open science | open minds

InTech Europe

University Campus STeP Ri
Slavka Krautzeka 83/A
51000 Rijeka, Croatia
Phone: +385 (51) 770 447
Fax: +385 (51) 686 166
www.intechopen.com

InTech China

Unit 405, Office Block, Hotel Equatorial Shanghai
No.65, Yan An Road (West), Shanghai, 200040, China
中国上海市延安西路65号上海国际贵都大饭店办公楼405单元
Phone: +86-21-62489820
Fax: +86-21-62489821

© 2011 The Author(s). Licensee IntechOpen. This is an open access article distributed under the terms of the [Creative Commons Attribution 3.0 License](https://creativecommons.org/licenses/by/3.0/), which permits unrestricted use, distribution, and reproduction in any medium, provided the original work is properly cited.

IntechOpen

IntechOpen