

# We are IntechOpen, the world's leading publisher of Open Access books Built by scientists, for scientists

6,900

Open access books available

185,000

International authors and editors

200M

Downloads

Our authors are among the

154

Countries delivered to

TOP 1%

most cited scientists

12.2%

Contributors from top 500 universities



WEB OF SCIENCE™

Selection of our books indexed in the Book Citation Index  
in Web of Science™ Core Collection (BKCI)

Interested in publishing with us?  
Contact [book.department@intechopen.com](mailto:book.department@intechopen.com)

Numbers displayed above are based on latest data collected.  
For more information visit [www.intechopen.com](http://www.intechopen.com)



## Clinical Presentation

Rafid Fayadh Al-Aqeedi

*Hamad Medical Corporation, Cardiology and  
Cardiovascular Surgery Department  
Qatar*

### 1. Introduction

Myocarditis is a clinical syndrome characterized by inflammation of myocardium. It can be produced by a myriad of etiologies including infectious, autoimmune, myocardial toxins, hypersensitivity reactions and physical agents. Virtually any infectious agent can produce myocardial inflammation and injury. Human myocarditis is most frequently caused by viral infection. Ongoing viral infection, myocardial destruction, and adverse remodeling can lead to persistent ventricular dysfunction and dilated cardiomyopathy. The modern molecular techniques have facilitated new insights into inflammatory autoimmune processes that affect the myocardium and ultimately result in acute or chronic dilated cardiomyopathy.

The clinical manifestations are highly variable, ranging from asymptomatic electrocardiographic or echocardiographic abnormalities to acute myocardial infarction-like syndrome, overt congestive heart failure, fulminant condition with new atrial or ventricular arrhythmias or profound cardiogenic shock and death. Myocarditis is occasionally the unrecognized culprit in cases of sudden cardiac death. Autopsy series have reported much higher rates of myocarditis than expected with overt clinical manifestation from different etiological agents. The prospective postmortem data have implicated myocarditis in sudden cardiac death of young adults at rates of 8.6 percent to 12 percent (Doolan et al., 2004; Fabre & Sheppard, 2005). Furthermore, it has been identified as a cause of dilated cardiomyopathy in 9 percent of cases in a large prospective series (Felker et al., 1999).

The clinical history in patients presented with myocarditis remains essential to envelop a wide variety of etiologies in the clinical scenarios, many of which are infectious (Brodison & Swann, 1998). In the past 10 years, however, viruses, including adenovirus, parvovirus B19, hepatitis C, and herpes virus 6, have emerged as significant pathogens (Mahrholdt et al., 2006). The geographical distribution can be of relevance for some forms of myocarditis. In selected countries, Chagas disease, Lyme myocarditis, acute rheumatic fever and disorders associated with advanced human immune deficiency virus infection are significant causes. Other important infrequent clinicopathologic variants in the etiological spectrum are systemic disorders like giant cell myocarditis, cardiac sarcoidosis and eosinophilic myocarditis. Additionally, drugs, vaccinations, toxins, physical agents like radiation, heat stroke and hypothermia can be the key point for some rare clinical diagnoses. The physical examination in patients with myocarditis might be normal, but more severe cases frequently evident for significant physical findings. Although histological findings remains the gold standard for establishing the diagnosis of myocarditis, low risk patients are often given a

presumptive diagnosis if imaging studies and a compatible clinical scenario suggest new onset cardiomyopathy. The clinical manifestations of suspected patients with myocarditis will be discussed in details.

## 2. Clinicopathological classification

Over the past two decades, a great deal of confusion may be traced to the changing diagnostic criteria, multifaceted classifications, and varying patterns of infectious disease. The details of classifications will be discussed in other chapter in this book.

The morphologic criteria for the diagnosis of myocarditis by means of endomyocardial biopsy interpretation was proposed by the Dallas criteria authors in 1986 who defined myocarditis as a process characterized by the presence of an inflammatory cell infiltration of the myocardium with necrosis and/or degeneration of myocytes that is not typical of the myocardial damage of ischemic heart disease. The inflammatory cells are typically lymphocytic but may also include eosinophilic, neutrophilic, giant cells, granulomatous, or mixed cellularity infiltration. The amount of inflammation and its distribution may be mild, moderate, or severe and focal, confluent, or diffuse, respectively. A retrospective study of 112 consecutive patients with biopsy-confirmed myocarditis demonstrated, 55 percent lymphocytic; 22 percent borderline (inflammatory cellular infiltrate with no evidence of myocyte necrosis); 10 percent granulomatous; 6 percent giant cell and 6 percent eosinophilic form of myocarditis (Magnani et al., 2006). The viral etiology of myocarditis is thought to be the primary causative agents in most cases. However, a direct causative relationship still less well established in many clinical occasions. The majority of these cases are classified as lymphocytic myocarditis.

The Dallas criteria considered to be the first attempt to develop standardized histopathological description of biopsy samples from patients presented with myocarditis (Aretz et al., 1987). However, the histopathology alone can be inadequate to identify the presence of active myocarditis. Some clinicians feel that the definition is too narrow owing to the limitation by variable interpretation, lack of clinical prognostic values, and low sensitivity (Baughman, 2006). A combination of histopathologic characteristics and clinical criteria has been proposed in 1991 (Lieberman et al., 1991) as an alternative scheme to be utilized in the diagnosis of myocarditis. Histologic evidence of myocarditis was demonstrated in 35 of 348 patients submitted to endomyocardial biopsy over 5 years. Analysis of the histologic findings and clinical course of these patients resulted in a clinicopathologic classification of myocarditis in which four clinical subgroups are identified.

### 2.1 Fulminant myocarditis

The fulminant myocarditis is less frequent form of presentation. Patients presents with acute heart failure and cardiogenic shock up to two weeks after a distinct viral prodrome. They have severe cardiovascular compromise and may require mechanical circulatory support. Multiple foci of active myocarditis are typical. The histopathologic finding does not match the clinical phenotypic severity. The ventricular dysfunction often normalizes if patients survive the acute illness or results in death (McCarthy et al., 2000). In one series, 14 of 147 patients (10.2 percent) with clinical myocarditis presented in a fulminant fashion, with the triad of hemodynamic compromise, rapid onset of symptoms (usually within 2 weeks), and fever (McCarthy et al., 2000). On follow up, 93 percent of the original cohorts were alive and

transplant free 11 years following initial biopsy, compared with only 45 percent in those with more classic forms of acute myocarditis.

## **2.2 Acute myocarditis**

Classically, patients with acute myocarditis presents with a less distinct onset of illness with nonspecific symptoms related to the heart. Viral prodrome occurs between 20 and 80 percent of the cases, can be readily missed by the patient, and thus cannot be relied upon for diagnosis. They present with an established ventricular dysfunction and may respond to immunosuppressive therapy or their condition may progress to dilated cardiomyopathy. In a series of 245 patients with clinically suspected myocarditis, the most common symptoms include fatigue (82 percent); dyspnea on exertion (81 percent); arrhythmias (55 percent, both supraventricular and ventricular); palpitations (49 percent); and chest pain at rest (26 percent), (Kuhl et al., 2005). The presentation can mimic acute coronary syndromes in view of troponin release, ST segment elevation on electrocardiogram, and segmental wall motion abnormalities on echocardiogram.

## **2.3 Chronic active myocarditis**

This group of patients with chronic active myocarditis represents the majority of older adult with myocarditis. They are also presents with a less distinct onset of illness and often insidious with symptoms compatible with moderate ventricular dysfunction such as fatigue and dyspnea. Affected patients may initially respond to immunosuppressive therapy but often have clinical and histologic relapses and develop ventricular dysfunction associated with chronic inflammatory changes, and mild to moderate fibrosis on histological study including giant cells.

## **2.4 Chronic persistent myocarditis**

This group of patients with chronic persistent myocarditis, whom also presents with a less distinct onset of illness, is characterized by a persistent histological infiltrate, often with foci of myocyte necrosis but without ventricular dysfunction, despite other cardiovascular symptoms such as chest pain or palpitation.

The previously depicted four forms are still used to describe the clinical presentation and progression of myocarditis, particularly in the absence of ongoing histological evaluation. These categories may also provide some prognostic information and may suggest which patients can or cannot benefit from immunosuppressive therapy.

A new diagnostic criteria derived from limited data was proposed in 2009. The Lake Louise Consensus Criteria utilizes the cardiac magnetic resonance imaging (CMR) for the diagnosis of myocarditis (Friedrich et al., 2009). The CMR enhances the ability to detect myocardial inflammation through noninvasive means, as well as to improve diagnostic accuracy. In these criteria, four major domains are considered when making the diagnosis including, clinical presentation compatible with myocarditis, evidence of new or recent onset myocardial damage, increased T2 signal or delayed enhancement on CMR (compatible with myocardial edema and inflammation), and endomyocardial biopsy evidence of myocardial inflammation. The use of CMR appears suitable to identify patients with significant ongoing inflammation, which may be especially important for patients with recurrent or persisting symptoms and in patients with new onset heart failure. The awareness came out that the

recommendations proposed by these criteria are based on limited data and that not all centers will be able to apply all components of the suggested protocol.

### 3. Clinical manifestation

Myocarditis is synonymous with inflammatory cardiomyopathy which has a wide range of clinical presentation, from subtle to devastating clinical scenario that contributes to the difficulties in diagnosis and classification of this disorder. There are few population-based, epidemiologic studies which have defined the presenting symptoms of acute myocarditis; this is due to the absence of a safe and sensitive noninvasive test that can confirm the diagnosis. Worldwide, the true frequency of disease in its less severe forms, whether clinical or subclinical, across various age segments of the population are more difficult to appreciate. Table 1 summarized the most significant clinical manifestations and physical findings in patients presented with myocarditis. Typically myocarditis has a bimodal age distribution in the general population, with the acute presentation more commonly seen in young children and teenagers. In contrast, the presenting symptoms are more subtle and insidious, often with dilated cardiomyopathy and heart failure in the older adult population. Most studies of acute myocarditis reported a slight preponderance in male patients (Caforio et al., 2007). The male-to-female ratio is 1.5 to 1, which may be related to a protective effect of natural hormone variations on immune responses in women (Schwartz et al., 2004). The variable clinical manifestation of myocarditis in part reflects the variability in histological disease severity. Myocardial inflammation may be focal or diffuse, involving any or all cardiac chambers. Severe, diffuse myocarditis can result in a clinical manifestation of acute dilated cardiomyopathy.

Many patients with myocarditis present with a nonspecific illness characterized by fatigue, mild dyspnea, and myalgias. Most cases of viral myocarditis are subclinical; therefore, the patient infrequently seeks medical attention during acute illness. These subclinical cases may have transient electrocardiographic abnormalities. The reported antecedent infectious viral syndrome is highly variable, ranging from 10 percent to 80 percent of patients with viral myocarditis (Baboonian & Treasure, 1997; Feldman & McNamara, 2000; Imazio et al., 2008; Mason et al., 1995). The appearance of cardiac specific symptoms occurs primarily in the subacute virus clearing phase; therefore, patients commonly present two weeks after the acute viremia.

A few patients present acutely with fulminant congestive heart failure secondary to widespread myocardial involvement. Animal models have lead to a much greater understanding of the fulminant clinical course of myocarditis in which a rapid progression, severe ventricular dysfunction and cardiovascular collapse occurs (Ellis & Di Salvo, 2007). Fulminant myocarditis, manifested by severe hemodynamic compromise requiring high dose vasopressor support or mechanical circulatory support, was identified in 15 of 147 patients (10.2 percent) in a large prospective study (McCarthy et al., 2000). Fulminant cases were additionally characterized by a distinct viral prodrome, fever, and abrupt onset (generally <3 days) of advanced heart failure symptoms. These patients typically have severe global left ventricular dysfunction and minimally increased left ventricular end-diastolic dimensions. Of note, either borderline or active lymphocytic myocarditis can produce this dramatic clinical presentation. The histological features of chronic myocarditis are usually produced a more subtle clinical course. Adults may present with heart failure years after initial index event of myocarditis.



<b>Clinical manifestations</b> <ol style="list-style-type: none"><li>1. Subclinical presentation (most cases of viral myocarditis)</li><li>2. Nonspecific symptoms (e.g fatigue, arthralgias and myalgias)</li><li>3. Clinical presentation, including :<div>Shortness of breath, orthopnea or paroxysmal nocturnal dyspnea Pedal edema Chest pain (concomitant pericarditis) Palpitation (arrhythmias) Presyncope or syncope (atrioventricular block) Sudden cardiac death (dysrhythmic death) Fever Flu-like syndrome (e.g pharyngitis or tonsillitis) Thromboembolic symptoms (systemic or pulmonary)</div></li></ol>
<b>Physical findings</b> <ol style="list-style-type: none"><li>1. Normal or unremarkable findings</li><li>2. Relevant physical signs, including :<div>Tachypnea Cyanosis Elevated jugular venous pressure Tachycardia Signs of cardiovascular collapse and shock Diffuse apex beat and laterally displaced (cardiomegaly) Diminished intensity of first heart sound Third and fourth heart sound summation gallops Murmurs of mitral or tricuspid valves regurgitation Pericardial friction rub and effusion (concomitant myopericarditis) Bibasilar crackles Hepatomegaly Ascites Peripheral edema</div></li></ol>

Table 1. The most significant clinical manifestations and physical findings in patient with myocarditis

The medical history may embrace a number of hints that merits an emphasis. Previous history of rheumatic heart disease or symptoms defined by Jones criteria e.g. fever or arthralgia can be a clue for the clinical diagnosis acute rheumatic fever. History of tick bite may correlate with suspected Lyme disease. Patients treated for neoplastic disorders with chemotherapeutic agents like doxorubicin may draw attention to anthracyclines-induced myocarditis. History of travel to Central or South America can be a clue for the diagnosis of Chagas disease. Additionally, giant-cell myocarditis should be considered in patients with acute dilated cardiomyopathy associated with thymoma, autoimmune disorders, ventricular tachycardia, or high-grade heart block. Furthermore, an unusual cause of myocarditis, such as cardiac sarcoidosis, should be suspected in patients who present with chronic heart

failure, dilated cardiomyopathy and new ventricular arrhythmias, or second-degree or third degree heart block or who do not have a response to standard care (Yazaki et al., 1998).

In the European Study of the Epidemiology and Treatment of Inflammatory Heart Disease, a 3055 patients with suspected acute or chronic myocarditis were screened, of them 72 percent had dyspnea, 32 percent had chest pain, and 18 percent had arrhythmias (Hufnagel et al., 2000). The most important clinical manifestations in patients with myocarditis are as followed:

### **3.1 Shortness of breath**

Dyspnea on exertion and fatigue are common. A history of shortness of breath at rest, orthopnea, pedal edema or paroxysmal nocturnal dyspnea is suggestive of congestive heart failure. Dyspnea is due to left ventricular dysfunction causes elevated left ventricular diastolic pressure and low cardiac output.

### **3.2 Chest pain**

Chest pain is usually associated with concomitant pericarditis. Chest discomfort is reported in one third of patients. The pain is most commonly described as a pleuritic, sharp, stabbing precordial pain. It may be substernal and squeezing and, therefore, difficult to distinguish from that typical of ischemic pain. However, myocarditis can be masquerading as an acute coronary syndrome both clinically and on the electrocardiogram, particularly in younger patients (Angelini et al., 2000). In one series of 34 patients with known normal coronary anatomy presenting with symptoms and electrocardiographic changes consistent with an acute coronary syndrome, 11 (32 percent) of the patients were found to have myocarditis on biopsy (Dec et al., 1992). Sarda et al., using myocardial indium111-labeled antimyosin antibody and rest thallium imaging, identified 35 of 45 patients (78 percent) who presented with acute chest pain, ischemic electrocardiographic abnormalities, and elevated cardiac biomarkers as having diffuse or focal myocarditis. However biopsy verification of actual myocarditis was not undertaken in this series. Complete recovery of left ventricular function occurred at six months in 81 percent of these patients (Sarda et al., 2001). Some presentations of myocarditis, especially those related to parvovirus B19, present like an acute lateral wall myocardial infarction. The ischemia associated with myocarditis may be due to localized inflammation or occasionally, due to coronary artery spasm (McCully et al., 2005). It is essential for clinicians to consider acute myocarditis in younger patients who present with acute coronary syndromes when coronary risk factors are absent, electrocardiographic abnormalities extend beyond a single coronary artery territory or global rather than segmental left ventricular dysfunction is evident on echocardiography.

### **3.3 Palpitation, presyncope or syncope**

Palpitation is a common presentation in patient with myocarditis. Presyncope or syncope in a patient with a presentation consistent with myocarditis may be a signal for high-grade atrioventricular block and risk for sudden death. Small focal inflammation in electrically sensitive areas may be the etiology of patients whose initial presentation is sudden death.

### **3.4 Fever**

Fever with or without sweats and chills occur in 20 percent of patients presenting with myocarditis. A history of fever or flu-like syndrome in form of pharyngitis, tonsillitis, or

upper respiratory tract infection before admission occurs in 50 percent of patients (Imazio et al., 2008).

### 3.5 Other symptoms

Apart from the nonspecific symptoms recognized like malaise, myalgias and arthralgias, other extracardiac symptoms may identify infectious, toxic agents or autoimmune diseases affecting the heart and resulting in a myocarditis. A viral prodrome of fever, myalgias, and muscle tenderness may precede viral myocarditis, while a delayed hypersensitivity reaction may be first apparent from a cutaneous rash. Rash, fever, peripheral eosinophilia, or a temporal relation with recently initiated medications or the use of multiple medications suggest a possibility of hypersensitivity myocarditis.

The clinical diagnosis of myocarditis is challenging due to its varying presentation, nonspecific symptoms and physical findings. Accordingly, a high level of clinical suspicion is warranted and a presumptive diagnosis usually made based on patient demographics and the clinical course.

## 4. Physical examination

The physical examination of patient presented with myocarditis is frequently normal. Mild cases of patients with myocarditis may appear to have a simple viral syndrome. More acutely ill patients with acute myocarditis have the classic signs of circulatory impairment due to congestive heart failure. Patients may show signs of fluid overload including elevated jugular venous pressure, bibasilar crackles, hepatomegaly, ascites and peripheral edema. More severe cases may show cardiovascular collapse and signs of shock. In addition to the signs of fluid overload, the physical examination may reveal direct evidence of cardiovascular signs in symptomatic patients. Tachypnea and tachycardia are common. Tachycardia is often out of proportion to fever. Cyanosis may occur as well. The apex beat may be diffuse and laterally displaced suggesting cardiomegaly. Heart auscultation may reveal diminished intensity of first heart sound. The third and occasionally fourth heart sound summation gallops may be noted with impaired ventricular function, particularly when biventricular acute myocardial involvement results in systemic and pulmonary congestion. If the right or left ventricular dilatation is severe, auscultation may reveal murmurs of mitral or tricuspid valves regurgitation. Table 1 summarized the most significant clinical manifestations and physical findings in patients presented with myocarditis.

A pericardial friction rub and effusion may become evident in some patients with diffuse inflammation as a result of myopericarditis. Pericardial tamponade was reported in very rare occasions. Pleural friction rub may develop as the inflammatory process involves surrounding structures. In cases where a dilated cardiomyopathy has developed, signs of peripheral or pulmonary thromboembolism may be encountered. Certain physical findings may imply a specific cause of myocarditis. Enlarged lymph nodes might suggest systemic sarcoidosis. A pruritic, maculopapular rash may suggest a hypersensitivity reaction, often to a drug or toxin. Acute rheumatic fever can present with the modified Jones criteria.

## 5. Electrocardiogram findings

Generally, the Electrocardiogram (ECG) is a sensitive means in myocarditis. However, its diagnostic value is limited by the low specificity and a wide diversity of changes which



observed during the course of disease. The ECG must be timely repeated, since minor abnormalities detected initially may become subsequently more apparent.

The ECG findings associated with myocarditis may include first, second or third degree atrioventricular block, intraventricular conduction delay (widened QRS complex), bundle branch or fascicle block, reduced R wave height, abnormal Q waves, ST-T segment changes or low voltage. In one report, either ST-segment elevation or T-wave inversion is present as the most sensitive ECG criterion in <50% of patients, even during the first weeks of the disease (Morgera et al., 1992). A gradual increase in the width of the QRS complex may be a sign of exacerbation of myocarditis. Frequent premature beats, supraventricular tachycardia and atrial fibrillation may arise as well. Arrhythmias such as sinus arrest, ventricular tachycardia, ventricular fibrillation or asystole may occur and threaten the life of patients with myocarditis. Hence, continuous ECG monitoring is crucial to detect potentially fatal arrhythmias.

## **6. Clinical manifestation of complications**

Despite the fact that a substantial number of myocarditis are never coming to medical attention, a less frequent form of myocarditis is fulminant and leads rapidly to cardiovascular collapse and shock that required mechanical ventilation support. In contradiction, if these patients survive the first 3-4 weeks of illness they have almost complete recovery and far fewer long term complications compared with those patients with more indolent courses (Chau et al., 2006; Khabbaz et al., 2007). Generally, there are a number of well recognized complications that may encounter in the variety of clinical scenarios of patients with myocarditis.

### **6.1 Congestive heart failure**

In many patients who develop heart failure, fatigue and decreased exercise capacity are the initial manifestations. However, diffuse, severe myocarditis, if rapid in evolution, can result in acute myocardial failure and cardiogenic shock. Signs of right ventricular failure include increased jugular venous pressure, hepatomegaly, and peripheral edema may supervene. The decline in right ventricular function "protects" the left side of the circulation so that signs of left ventricular failure may not be seen. If, however, there is predominant left ventricular involvement, the patient may present with the symptoms of pulmonary congestion including dyspnea, orthopnea, pulmonary crackles, and, in severe cases, acute pulmonary edema. Patients with persistent viral genome expression show limited recovery of left ventricular function, decreased stroke volume index and more stiffness of the ventricle with the resultant long-term morbidity of heart failure and a mortality of nearly 25 percent (Fuse et al., 2000).

### **6.2 Arrhythmias**

A number of arrhythmias may be seen during the clinical course of myocarditis. Sinus tachycardia is more frequent than serious atrial or ventricular arrhythmias, while palpitations secondary to premature atrial or, more often, ventricular premature complexes are common. Ventricular arrhythmias and variable heart blocks are uncommon, but well recognized clinical presentations (Hosenpud et al., 1986; Marboe & Fenoglio et al., 1988). Persistent complex ventricular arrhythmias after apparent resolution of myocarditis were reported in children and young adults as well (Friedman et al., 1994).

Several series have examined the frequency of myocarditis among patients evaluated for life threatening ventricular arrhythmias that occurred in the absence of structural heart disease (Strain et al., 1983; Sugrue et al., 1984; Vignola et al., 1984). These patients tended to be young (younger than 50 years) and to have normal or near-normal left ventricular systolic function. The frequency of syncope or cardiac arrest as reported has ranged from 8 percent to 61 percent (Strain et al., 1983; Sugrue et al., 1984). Biopsy evidence of myocarditis among patients without structural heart disease has ranged from 8 percent to 50 percent. On the other hand, patients with ventricular arrhythmias due to lymphocytic or granulomatous myocarditis stay at higher risk. Sustained ventricular tachycardia or new heart block in the setting of rapidly progressive congestive heart failure suggests giant cell myocarditis. Granulomatous myocarditis has been associated more frequently with life threatening ventricular arrhythmias, syncope, and high-grade atrioventricular block requiring temporary or permanent ventricular pacing than has lymphocytic myocarditis (Davidoff et al., 1991; Fleming & Bailey, 1981; Sekiguchi et al., 1996). Furthermore, granulomatous myocarditis might be suspected in patients who present with apparently chronic dilated cardiomyopathy yet with new ventricular arrhythmias or heart block or who do not have a response to optimal care (Yazaki et al., 1998).

### 6.3 Sudden cardiac death

The risk of sudden dysrhythmic death in patients with myocarditis is increasingly appreciated in the current morbidity and mortality data. The discovery of myocarditis in 1 to 9 percent of routine postmortem examinations suggests that myocarditis is a major cause of sudden, unexpected death (Feldman & McNamara, 2000).

Although heart failure and cardiomyopathy are more common clinical presentations, patients with myocarditis may present with syncope or unexpected sudden cardiac death, presumably due to ventricular tachycardia or fibrillation (Drory et al., 1991; Eckart et al., 2004; Maron et al., 2003; Theleman et al., 2001). Myocarditis is a significant cause of sudden, unexpected death in adults younger than age 40 years and elite young athletes. In these presumably healthy individuals, autopsy findings have revealed myocarditis in up to 20 percent of cases (Wesslen et al., 1996). In an autopsy series of patients under age 40 who presented with sudden death in the absence of known heart disease, myocarditis was responsible for 22 percent of cases under age 30 and 11 percent in older subjects (Drory et al., 1991). In another autopsy study of sudden death occurring in 1866 competitive athletes, myocarditis was present in 6 percent of the cardiovascular deaths (Maron et al., 2009). In one more series of autopsies in military recruits, myocarditis accounted for 20 percent of deaths due to identifiable structural cardiac abnormalities (Eckart et al., 2004).

### 6.4 Dilated cardiomyopathy

A substantial subset of symptomatic cases of postviral or lymphocytic myocarditis present with a syndrome of heart failure and dilated cardiomyopathy. A clinical and pathologic syndrome that is similar to dilated cardiomyopathy (DCM) may develop after resolution of viral myocarditis in animal models and biopsy proven myocarditis in human subjects (Gilbert & Mason, 1987). This has led to speculation that DCM may develop in some individuals as a result of subclinical viral myocarditis. Theoretically, an episode of myocarditis could initiate a variety of autoimmune reactions that injure the myocardium and ultimately result in the development of DCM. These abnormalities in immune

regulation and the variety of antimyocardial antibodies present in DCM are consistent with this hypothesis. Enteroviral RNA sequences may be found in heart biopsy samples in DCM but with a very variable frequency (0–30 percent), (Bowles et al., 1986; Giacca et al., 1994). Furthermore, analysis of human viruses other than enteroviruses suggests that adenoviruses, herpes, and cytomegalovirus can also cause myocarditis and potentially DCM, particularly in children and young subjects (Martin et al., 1994; Pauschinger et al., 1999).

In most acute cases of lymphocytic myocarditis, left ventricular function improves over one to six months with standard heart failure care. However a substantial minority will develop a persistent inflammation that leads to chronic cardiomyopathy. In the patients who develop chronic cardiomyopathy, the risk of heart transplantation and death is high. In a large review of 1230 cases of initially unexplained cardiomyopathy, 9 percent were thought to be due to myocarditis (Felker et al., 2000). A similar prevalence of 10 percent was noted in the Myocarditis Treatment Trial in which endomyocardial biopsy was performed in over 2200 patients with unexplained heart failure of less than two years duration (Mason et al., 1995).

### 6.5 Thromboembolism

Thromboembolism, arterial and venous, is more evident in patients with left ventricular dysfunction, and appears to be quite frequent complication in certain forms of myocarditis and cardiomyopathies. Additionally, the risk of thromboembolism from either tissue or thrombus from the biopsy site is higher in left ventricular biopsy. Right-sided thromboembolism can be due to thrombus from the venous access sheath especially with the internal jugular approach. The possibility of some small added diagnostic yield by taking biopsy samples of the left ventricle in addition to the right is outweighed by the small attendant risk of systemic embolism.

Thromboembolism is frequent in advanced Chagas disease, and its occurrence is probably underestimated (Bestetti, 2000; Samuel et al., 1983). At autopsy, 73 percent of patients have left or right ventricular mural thrombi, with evidence of pulmonary or systemic embolization in 60 percent (Arteaga-Fernandez et al., 1989). The apical aneurysm typical of Chagas disease is particularly prone to the formation of thrombi and is associated with a high incidence of thromboembolic events (Fernandes et al., 1987). Furthermore, there is a high incidence of thromboembolism in population with peripartum cardiomyopathy. Thrombi are the result of the hypercoagulable state of pregnancy and of stasis and turbulent flow in the dilated heart. Thrombi often form in patients with lower left ventricular ejection fraction (<35 percent), (Amos et al., 2006; Sliwa et al., 2006). Higher mortality rates have been reported to be due to thromboembolism as well (Ford et al., 2000).

### 6.6 Recurrent myocarditis

The clinical course of myocarditis in the majority of patients is self-limited and there is complete resolution of myocardial inflammation without further relapse or sequelae. However, the disease has been observed to recur in a similar scenario to initial presentation, which then may resolve spontaneously or be associated with heart failure, arrhythmias, or death. Chronic myocarditis may be considered to be one of the mechanisms of the process of recurrence. Recurrence was reported to in 10 to 25 percent of patients after apparent resolution of the initial illness (Daly et al., 1984; Dec et al., 1985). Recurrence of myocarditis

is well recognized in patients with acute rheumatic fever. It is also demonstrated in subsequent pregnancies after peripartum cardiomyopathy and recurrence should be suspected if ventricular function subsequently deteriorates (Dec et al., 1985). Women should be counseled to avoid pregnancy after a diagnosis of peripartum cardiomyopathy. Recurrence was also described in giant cell myocarditis in transplanted heart which responded to intensive immunosuppression. History of third time recurrences of active myocarditis proven by endomyocardial biopsy associated with complete atrioventricular block was described as well and viral studies showed no evidence of recent infection (Kanazawa et al., 2004). Another report present recurrent viral myocarditis and vaccine-associated myocarditis in a single patient with complete reversal of the cardiomyopathy and return to normal cardiac function (Makaryus et al., 2006). Moreover, some cases were observed to have recurrent myocarditis after tapering of immunosuppressive therapy and previous biopsy specimens showing healed myocarditis.

One report indicated that pericarditis on initial presentation may be associated with a higher rate of recurrence of myocarditis (Fowler et al., 1973). However, in reality, there are no reliable predictors that identify patients likely to have recurrence.

## 7. Manifestations of specific forms of myocarditis

Specific clinical forms of myocarditis of variable etiologies will be described below. Table 2 summarized some key clinical hints among specific forms of myocarditis that help with the clinical diagnosis

### 7.1 Viral myocarditis

Amongst the multiple infectious etiologies which have been implicated as the cause of clinically significant acute myocarditis, viral myocarditis being the most common and the enterovirus coxsackie B being the most significant. Numerous seroepidemiologic and molecular studies were linked coxsackievirus B to outbreaks of myocarditis occurred before the 1990s. The spectrum of viruses that were detected in endomyocardial biopsy samples shifted from coxsackievirus B to adenovirus in the late 1990s. In the last decade a number of reports implicate new viruses in the etiology of myocarditis and dilated cardiomyopathy. The parvovirus B19 was identified in patients with myocarditis in Germany (Kühl et al., 2005; Mahrholdt et al., 2006) and hepatitis C virus was reported in Japan (Matsumori 2005, 2006) as well.

Early studies suggested that cardiac involvement occurred in 3.5 to 5 percent of patients during outbreaks of coxsackievirus infection (Gerzen et al., 1972; Grist & Bell, 1969). Most cases of enteroviral myocarditis or pericarditis occur in children and young adults in whom more than two-thirds are male. In the majority of patients, active myocarditis remains unsuspected because the subclinical and self-limited pattern of presentation or the presence of myocarditis may infer only by the finding of transient electrocardiographic ST-T-wave abnormalities. In addition, subtle cardiac symptoms and signs may be overshadowed by the systemic manifestations of the underlying infection or disease process. Clinically, the patients give a history of a preceding upper respiratory febrile illness or a flu-like syndrome, and viral nasopharyngitis or tonsillitis may be evident. In the United States Myocarditis Treatment Trial, 89 percent of subjects reported a syndrome consistent with a viral prodrome (Mason et al., 1995). The patient may also have fever, myalgias, and muscle tenderness that is followed by chest pain, dyspnea or arrhythmias, and occasionally heart

failure. A pericardial friction rub is documented in half of cases, and the electrocardiogram shows ST segment elevations or ST- and T-wave abnormalities. Most adults recover completely and only a minority of cases progress to chronic dilated cardiomyopathy.

Clinical clues	Clinical diagnosis	Comments
Preceding upper respiratory febrile or flu-like illness (viral nasopharyngitis or tonsillitis)	Viral myocarditis	Often self-limited
Patients present with chronic heart failure, dilated cardiomyopathy and new arrhythmias or heart block with no response to standard care	Sarcoid myocarditis	Enlarged lymph nodes suggest systemic sarcoidosis
Cutaneous rash (pruritic, maculopapular), fever, peripheral eosinophilia or a temporal relation with recently initiated medications or the use of multiple medications	Hypersensitive/ eosinophilic myocarditis	
Patients treated anti-neoplastic chemotherapeutic agents	Anthracyclines-induced myocarditis	
History of travel to Central or South America, Systemic or pulmonary thromboembolism	Chagas disease	The apical aneurysm is typical in advanced disease
History of residence or travel through the endemic area; previous tick bites; prior or current erythema migrans lesions and coexistence of neurologic dysfunction	Lyme disease	Varying degrees of atrioventricular conduction block is common
Previous history of rheumatic heart disease or symptoms defined by Jones criteria e.g. erythema marginatum, polyarthralgia, chorea, subcutaneous nodules fever or arthralgia	Acute rheumatic fever	
Heart failure developing in the last month of pregnancy or within 5 months following delivery	Peripartum cardiomyopathy	Higher incidence of thromboembolism (hypercoagulable state of pregnancy). More often when left ventricular ejection fraction <35 %
Sustained ventricular tachycardia in rapidly progressive heart failure associated with thymoma, autoimmune disorders, or high-grade heart block	Giant-cell myocarditis	Syncope or sudden death develop due to ventricular arrhythmias or heart block

Table 2. Some key clinical hints among specific forms of myocarditis that help with the clinical diagnosis.



In addition to the coxsackievirus B, other members of the genus Enterovirus (coxsackievirus A, echovirus, and poliovirus) and many other viruses have also been associated less frequently with myocarditis; these viruses include influenza virus, Epstein-Barr virus, cytomegalovirus, human herpesvirus (Kindermann et al., 2008) and varicella-zoster virus. Myocarditis and pericarditis were reported in association with influenza virus infection during the 1918-1919 pandemic. Unusually, myocarditis has also been described as a complication of mumps in a severe but usually self-limited form. Molecular diagnostic assays have implicated mumps virus in some cases of endocardial fibroelastosis following myocarditis as well. In more recent study of 172 patients with a biopsy sample showing myocarditis, the most common viruses were parvovirus B19, 36.6 percent; enterovirus, 32.6 percent; co-infection with HHV-6 and parvovirus B19, 12.6 percent human herpesvirus 6 (HHV-6), 10.5 percent; adenovirus, 8.1 percent (Kuhl et al., 2005).

The novel influenza virus A (H1N1) pandemic began in Mexico in 2009 and rapidly spread worldwide. The cardiac complications of H1N1 infection were uncommonly reported. Sudden death as a result of myocarditis was a rare recognized complication in otherwise immunocompetent individuals, despite the absence of significant respiratory tract infection. A report from Japan described 10 patients presented with fulminant myocarditis which was confirmed by endomyocardial biopsy in 6 patients, 8 of the cases were rescued (Ukimura et al., 2009). Also, a documented influenza myocarditis was reported due to 2009 pandemic H1N1 virus occurred in a previously healthy adult (Haessler et al., 2010). Another reported fatal case of acute myocarditis in an immunocompetent young woman, the autopsy revealed a predominantly lymphocytic myocarditis (Gdynia et al., 2011). On the other hand, cases diagnosed with fulminant myocarditis were described in pediatric population with fatal outcomes within a 30-day of presentation (Bratincsák et al., 2010).

Though viral myocarditis is most often self-limited and without sequelae, fulminant condition with arrhythmias, heart failure occurs. Arrhythmias are common and are occasionally difficult to manage. Patients with fulminant myocarditis may require mechanical cardiopulmonary support or cardiac transplantation, but the majority survived and many demonstrate substantial recovery of ventricular function. Patients with myocarditis and pulmonary hypertension are at a particularly high risk of death. Deaths attributed to heart failure, tachyarrhythmias, and heart block has been reported and it seems prudent to monitor the electrocardiogram of patients with arrhythmias, especially during the acute illness. In some patients, myocarditis simulates acute myocardial infarction, with chest pain, electrocardiographic changes, and elevated serum levels of myocardial enzymes. Additionally, viral myocarditis are assumed to be the major causes of chronic dilated cardiomyopathy, some cases of myocarditis may recur as well, however the number of cases with acute myocarditis that progresses to chronic dilated cardiomyopathy remains anonymous.

## **7.2 Human immunodeficiency virus (HIV) myocarditis**

The human immunodeficiency virus type I (HIV-1) infection that causes the acquired immunodeficiency syndrome (AIDS) has become a worldwide pandemic. It has been identified for more than 3 decades, during which time a number of factors may altered the nature of cardiac manifestation. Notably, the survival in adult with HIV infection and AIDS is prolonged as a result of earlier detection and the use of highly active antiretroviral therapy (HAART), (Hoover et al., 1993; Palella et al., 1998). On the other hand, disorders

such as hypertension, hyperglycemia, hyperlipidemia, lipodystrophy and coronary artery disease appeared to add further comorbidity to HIV infection (Fisher & Lipshultz, 2001; Friis-Møller et al., 2007; Tershakovec et al., 2004).

Human immunodeficiency virus is the most common cardiac pathologic finding at autopsy in HIV infected patients with prevalence as high as 70 percent (Anderson et al., 1988; Baroldi et al., 1988, Lewis, 1989). Myocarditis identified at autopsy or on endomyocardial biopsy in HIV-infected patients is most often nonspecific and manifested as focal, inflammatory lymphocytic infiltrates without myocyte necrosis. However, it is uncertain whether the myocarditis so frequently observed at autopsy is clinically relevant.

Myocarditis should be considered in any HIV-infected patient with dyspnea or cardiomegaly. It is most often present with signs and symptoms of congestive heart failure or asymptomatic left ventricular (LV) dysfunction established by echocardiography. Of note, the clinical features of concomitant noncardiac disorders may mask cardiac involvement and steer to inaccurate approach, since myocardial manifestations due of HIV infection may respond at least transiently to standard therapy.

A prospective long-term clinical and echocardiographic follow-up study of asymptomatic HIV-positive patients showed a mean annual incidence of progression to dilated cardiomyopathy of 15.9 cases per 1,000 patients. The exact pathogenesis of myocarditis in the AIDS is unclear. Possible direct action of HIV on the myocardial tissue or an autoimmune process induced by HIV, possibly in association with other cardiotropic viruses. It is difficult to assess the clinical significance of viral infection of the myocardium in HIV infected patients. A histologic diagnosis of myocarditis was reported in 83 percent of patients with dilated cardiomyopathy. This significant proportion had focal, nonspecific lymphocytic myocarditis (Barbaro et al., 1998).

Dilated cardiomyopathy can be subclinical or may present with overt clinical findings. Cardiac involvement is often subclinical as echocardiographic studies have demonstrated LV dysfunction in 41 percent of asymptomatic HIV-positive individuals (Corallo et al., 1988). However, in the primary care setting, AIDS cardiac complications are unusual. One autopsy series demonstrated no cardiac disease in 115 consecutive autopsies of patients who died of AIDS-related complications (Lewis, 1989). In one series of 416 HIV-positive patients from Rwanda without a previous history of cardiovascular disease and not receiving HAART reported an echocardiographically evident dilated cardiomyopathy in 17.7 percent (Twagirimukiza et al., 2007). The overt clinical involvement is seen in 10 percent of HIV patients, and the most common clinically significant finding is a dilated cardiomyopathy associated with typical findings of congestive heart failure, namely edema and shortness of breath.

Apart from the clinical manifestation which may be seen as a direct consequence of HIV infection, a more likely, as a consequence of possible etiologies related to non-HIV cardiotropic viral infection, postviral autoimmune mechanism, drug toxicity or neoplastic infiltration by Kaposi sarcoma or lymphoma.

Since the introduction of HAART regimens there has been a marked reduction in the incidence of myocarditis and opportunistic infections, which has led to a nearly 30 percent reduction in HIV-associated cardiomyopathy (Barbaro, 2005). Opportunistic infections include bacteria, fungi, protozoa, and viruses are the most frequent cause of morbidity and mortality in AIDS which is identified in 10 to 15 percent of cases (Hofman et al., 1993). However, symptomatic disease appears to be rare. *Toxoplasma gondii* is the most frequently documented infectious cause of myocarditis associated with AIDS. Myocardial

toxoplasmosis described in 1 to 16 percent autopsy series of patients dying of AIDS (Anderson et al., 1988; Baroldi et al., 1988; Matturri et al., 1990). Cytomegalovirus is another common opportunistic infection in patients with late stage AIDS that can cause myocarditis in selected patients (Barbaro et al., 1998; Niedt & Schinella, 1985). Other virus identified within the myocardium of HIV-infected or AIDS patients, either at antemortem endomyocardial biopsy or from autopsy material, have included Epstein-Barr and coxsackie B virus in adults (Barbaro et al., 1998; Dittrich et al., 1988). These viruses may be present as either primary infection or as coinfection and can occur with or without associated myocarditis and with or without associated LV dysfunction. Other infections like, myocardial tuberculosis appears to be rare (Miller-Catchpole et al., 1989). Fungal myocarditis is another unusual complication of disseminated infection that is identified most often at autopsy. Various fungal organisms identified in the myocardium at autopsy with associated myocarditis. Cardiac cryptococcus has been diagnosed in association with congestive heart failure and resolved after therapy (Kinney et al., 1989; Lafont et al., 1987; Lewis et al., 1985).

Other possible etiologies of LV dysfunction are drug toxicity from either abuse of illicit substances or iatrogenic disease from agents used in the therapy for AIDS. Alcohol, cocaine, or heroin may contribute to LV dysfunction in many cases (Brown et al., 1991; Peng et al., 1989; Soodini & Morgan, 2001). Therapeutic agents implicated as potential cardiac toxins include zidovudine (d'Amati et al., 1992; Herskowitz et al., 1992), interleukin-2 (Samlowski et al., 1989) and interferon alfa-2 (Deyton et al., 1989; Zimmerman et al., 1994). Neoplastic infiltration of the heart by Kaposi sarcoma is frequently seen at autopsy and usually associated with widespread disease in the terminal phases of AIDS (Silver et al., 1984). Non-Hodgkin lymphoma is also observed in this setting and also associated with widespread disease (Holladay et al., 1992).

### 7.3 Bacterial myocarditis

Nowadays, myocarditis of infectious etiology caused by non-viral agents is less frequent worldwide. Bacterial involvement of the heart is uncommon, but when it does occur, it is usually as a complication of endocarditis. Various bacteria include (*Corynebacterium diphtheriae*, *Streptococcus pyogenes*, *Staphylococcus aureus*, *Haemophilus pneumoniae*, *Salmonella* spp., *Neisseria gonorrhoeae*, *Leptospira*, *Borrelia burgdorferi*, *Treponema pallidum*, *Brucella*, *Mycobacterium tuberculosis*, *Actinomyces*, *Chlamydia* spp., *Coxiella brunetti*, *Mycoplasma pneumoniae* and *Rickettsia* spp). Bacteria like streptococcal and staphylococcal species and *Bartonella*, *Brucella*, *Leptospira*, and *Salmonella* species can spread to the myocardium as a consequence of severe cases of endocarditis. Some forms of bacterial myocarditis will be discussed below.

#### 7.3.1 Diphtheritic myocarditis

Worldwide, the most common bacterial cause of myocarditis is diphtheria. As early as 1806, a relationship between infection (diphtheria) and chronic heart disease was postulated, but it was not until the 1970s, with the advent of endomyocardial biopsy, that the diagnosis of myocarditis could be established during life.

The risk of developing cardiac toxicity is proportional to the severity of local infection. *Corynebacterium diphtheriae* produce toxins that inhibit protein synthesis that can cause myocarditis and leads to a dilated, flabby, hypocontractile heart. The manifestations of

diphtheritic myocarditis include various dysrhythmias, conduction disturbances, and dilated cardiomyopathy. Cardiomegaly and severe congestive heart failure typically appear after the first week of illness. However, clinically evident cardiac manifestation like dyspnea, decreased heart sounds, gallop rhythm or cardiac dilatation is much less common, occurring in 10 to 25 percent of all patients with diphtheria (Morgan et al., 1963).

Myocarditis occurred in 22 percent of 656 hospitalized patients with diphtheria in the Kyrgyz Republic in 1995; 7 percent of patients with myocarditis and 2 percent of patients without myocarditis died (Kadirova et al., 2000). Myocarditis as evidenced by electrocardiographic changes such as ST-T wave changes, QTc prolongation, and/or first-degree heart block can be detected in as many as two-thirds of cases, often occurring when local respiratory symptoms are improving (Boyer & Weinstein, 1963; Lumio et al., 1948). The conduction system is frequently involved. The complete heart block result from diphtheritic myocarditis was almost always fatal before temporary cardiac pacemakers were developed. Diphtheritic myocarditis considered the most serious complication and remains the major cause of mortality (Kneen et al., 2004). The death rate is highest during the first week of illness particularly among patients with bull-neck diphtheria and among patients with myocarditis who develop ventricular tachycardia, atrial fibrillation, or complete heart block.

### 7.3.2 Lyme myocarditis

Lyme disease is an inflammatory disease caused by infection with the spirochete *Borrelia burgdorferi*. In United States, carditis occurs in approximately 5 percent, while, it is less frequent in Europe, affecting approximately 0.3 to 4.0 percent of untreated adults (Cox et al., 1991). This difference may be related to infection by different organisms.

A careful history should address risk factors or possible evidence of *B. burgdorferi* infection particularly in the presence of atrioventricular conduction abnormalities (McAlister et al., 1989). These include history of residence or travel through an endemic area; previous tick bites; prior or current erythema migrans lesions and coexistence of objective or subjective neurologic dysfunction compatible with neurologic Lyme disease. Cardiac Lyme disease occurs during the early disseminated phase of the disease, usually within weeks to a few months after infection (Fish, 2008). In a patient with suspected Lyme disease after a tick bite, the possibility of coinfection with Ehrlichia (ehrlichiosis) and Babesia (babesiosis) should be considered as both can also cause myocarditis.

There is a male predominance of approximately 3:1 in cardiac Lyme disease (Vlay, 1993). Patients with cardiac involvement may be asymptomatic and clinically inapparent. However, some patients develop symptomatic myocarditis with cardiac muscle dysfunction and/or associated pericarditis (Vlay et al., 1991) (Lorcerie et al., 1987). Symptoms mainly include palpitations, shortness of breath, chest pain, presyncope or syncope. In a review of 84 patients with Lyme carditis, the United States Centers for Disease Control and Prevention reported palpitations in 69 percent, conduction abnormalities in 19 percent, myocarditis in 10 percent and left ventricular failure 5 percent (Ciesielski et al., 1989). Endomyocardial biopsy samples resemble idiopathic lymphocytic myocarditis, and rarely the spirochetal organisms are identified (Cox et al., 1991; McAlister et al., 1989; Stanek et al., 1990).

Atrioventricular conduction block of varying degrees are the most common manifestation of Lyme carditis. In some patients, heart block is the first and only manifestation of Lyme disease (Kimball et al., 1989). Patients may present with first degree heart block but can progress to second degree or complete heart block over a short period of time (Peeters et al., 1990). One review of 52 patients with Lyme carditis found that 87 percent had



atrioventricular block, which was usually symptomatic (McAlister et al., 1989). Wenckebach periodicity occurred in 40 percent and complete atrioventricular block in 50 percent; other findings include bundle branch and fascicular blocks, which are rare. In another report, 38 percent of patients with Lyme carditis required a temporary pacemaker (Goldings & Jericho, 1986). Patients with a PR interval greater than 300 milliseconds carry a highest risk for progression to complete heart block, which may develop rapidly (Steere et al., 1980). Complete heart block caused by Lyme disease typically resolves within one week, and more minor conduction disturbances within six weeks (Fish, 2008; McAlister et al., 1989). More reports showed heart block usually persists for 3 to 42 days and often resolves spontaneously (Costello et al., 2009; Cox et al., 1991; Steere et al., 1980; van der Linde et al., 1989). In Europe, scattered case reports have suggested that *B. burgdorferi* may, in isolated cases, be a cause of chronic cardiomyopathy (Bartunek et al., 2006; Palecek et al., 2010). This has not been shown in the United States. A small Dutch series evaluated 42 patients with dilated cardiomyopathy (Vlay et al., 1991). Nine were seropositive for anti-*B. burgdorferi*; six recovered fully, two had a partial response, and one showed no improvement.

### 7.3.3 Salmonella myocarditis

Typhoid fever is a life-threatening illness rarely complicated by myocarditis. *Salmonella* myocarditis may produce variable clinical manifestations from latent to severe clinical forms, such as acute congestive heart failure or sudden cardiac death (Al-Aqeedi et al., 2009; Burt et al., 1990). Postmortem studies suggest that myocarditis is a major cause of sudden unexpected death in young adults and may account for 20 percent of cases (Feldman & McNamara, 2000).

### 7.3.4 Yersinia myocarditis

Myocarditis sometimes occurs as a complication of *Yersinia*. Clinical evidence of *Campylobacter*-associated myocarditis described in association with *Campylobacter* spp. enteritis (Kotilainen et al., 2006). Mild, self-limited myocarditis accompanies 10 percent of cases of *Yersinia* induced arthritis and can occur independently. Typical manifestations include cardiac murmurs and transient electrocardiographic abnormalities, such as prolongation of the PR interval and nonspecific ST-segment and T wave changes. The syndrome of *Yersinia*-induced arthritis and carditis can be confused with acute rheumatic fever.

### 7.3.5 Legionella myocarditis

Myocardial involvement is a rare manifestation of *Legionella* infection, though, the most common extrapulmonary site of Legionnaires' disease is the heart. Numerous reports have described myocarditis, pericarditis, postcardiotomy syndrome, and prosthetic valve endocarditis (Antonarakis et al., 2006; Lowry & Tompkins, 1993; Tompkins et al., 1988). Most cases have been hospital acquired. *Legionella* carditis in the adult population is invariably seen in association of pneumonia, however, isolated *Legionella* myocardial involvement without associated pneumonia have been reported (Burke et al., 2009).

### 7.3.6 Mycoplasma myocarditis

Cardiac abnormalities rarely reported in conjunction with *Mycoplasma pneumoniae* infection including myocarditis and pericarditis (Martin & Bates, 1991; Paz & Potasman, 2002).



Myocarditis has been described in rare autopsy reports as well. Cardiac manifestations include rhythm disturbances, congestive heart failure, chest pain, and conduction abnormalities on the electrocardiogram.

#### **7.3.7 Q fever myocarditis**

Myocarditis, though uncommon, may be a particularly severe manifestation of Q fever. A study of 1070 patients with acute Q fever from southern France, 1 percent had pericarditis, and 1 percent had myocarditis. In other series of 1276 patients with Q fever over a 15-year period, only eight developed myocarditis but two were among only 12 total patients with Q fever who died (Fournier et al., 2001). Q fever may also cause endocarditis which usually occurs in patients with previous valvular damage or immunocompromise particularly a bicuspid aortic valve or a prosthetic valve.

#### **7.3.8 Chlamydial myocarditis**

Chlamydial infection also has been reported in association with clinical manifestations of myocarditis (Mavrogeni et al., 2008).

#### **7.3.9 Relapsing fever myocarditis**

Relapsing fever is an arthropod-borne infection characterized by recurrent episodes of fever, caused by spirochetes of the genus *Borrelia*. The first episode of illness tends to be the most severe. Myocarditis appears to be common in both louse-borne and tick-borne relapsing fever. Clinical and electrocardiographic evidence of myocarditis and myocardial dysfunction includes a prolonged QTc interval, commonly a galloping third heart sound, elevated central venous pressure, arterial hypotension, and rare pulmonary congestion. Heart involvement has been prominent in fatal cases (Wengrower et al., 1984).

#### **7.4 Acute rheumatic fever**

Acute rheumatic fever (ARF) is a nonsuppurative complication of group A streptococcus pharyngitis that occurs two to four weeks following infection and arises as an autoimmune response to extracellular or somatic bacterial antigens that share similar epitopes in human tissue. Rheumatic fever remains one of the most important cardiovascular diseases that cause significant cardiac morbidity and mortality in developing countries (Hutchison, 1998). In developed countries, ARF is generally preceded by pharyngitis but not skin infection (Guidelines for the diagnosis of rheumatic fever, JAMA 1992). However, data from endemic regions with ARF and rheumatic heart disease suggest a less clear association (McDonald et al., 2004, 2006; Noel et al., 2005).

Acute rheumatic fever occurs most frequently in children from 5 to 15 years of age. The incidence of rheumatic heart disease in patients with a history of ARF is variable; in general, valvular damage manifesting as a murmur later in life is likely to occur in about 50 percent of patients with evidence of carditis at initial presentation (Albert et al., 1995; Meira et al., 2005). The myocardial lesions consist of nonspecific lymphocytic myocarditis and Aschoff nodules. The latter are pathognomonic of ARF. Myocarditis is often indicated by cardiomegaly and/or congestive heart failure (CHF) particularly in the absence of a significant pericardial effusion. The presence of valvulitis is established clinically by auscultatory findings. Although CHF in rheumatic fever patients traditionally has been ascribed to severe myocardial inflammation, endomyocardial biopsy in patients with

rheumatic carditis does not show significant evidence of myocyte damage (Narula et al., 1993). In addition, echocardiographic left ventricular ejection fraction and indices of myocardial contractility remain normal in patients with rheumatic carditis even in the presence of CHF (Essop et al., 1993). Further, CHF occurs only in the presence of hemodynamically significant valvular lesions.

The diagnosis of ARF is established largely on clinical grounds. The clinical manifestations initially described by Jones (Jones, 1944). Subsequently revised and lastly the established guidelines for the diagnosis of rheumatic fever reviewed by the American Heart Association Working Group in 2002 (Ferrieri, 2002). The five major manifestations include migratory arthritis, carditis and valvulitis, central nervous system involvement (eg, Sydenham chorea), erythema marginatum and subcutaneous nodules. Whereas, the four minor manifestations include, arthralgia, fever, elevated acute phase reactants (erythrocyte sedimentation rate, C-reactive protein) and prolonged PR interval. The probability of ARF is high in the setting of group A streptococcal infection followed by two major manifestations or one major and two minor manifestations. Strict adherence to the Jones criteria in areas of high prevalence may result in under detection of the disease. This was illustrated in a report of 555 cases of confirmed ARF among Australian aboriginals in whom monoarthritis and low-grade fever were important manifestations (Carapetis & Currie, 2001).

## 7.5 Chagas myocarditis

Chagas disease is a protozoan infection due to *Trypanosoma cruzi*; transmitted by an insect vector, produces an extensive myocarditis that typically becomes evident years after the initial infection. It is a major public health problem in endemic areas and in immigrants from rural Central or South America. Chagas myocarditis is by far the most common form of cardiomyopathy in Latin American countries (Schofield & Dias, 1991). Chagas disease consists of acute and chronic phases. During the chronic phase, many patients present the indeterminate form. The latter describes patients who have positive serology, but no symptoms, physical signs, or laboratory evidence of organ involvement (Dias, 1989).

### 7.5.1 Acute phase

The first signs of acute Chagas' disease develop at least 1 week after contact with the infected vector. Local skin indurated erythema and swelling produces the typical portal of entry lesions at the skin known as chagomas accompanied by local lymphadenopathy. The conjunctiva portal of entry may result in a unilateral painless periorbital edema and swelling of the palpebrae (Romana's sign). Infection can also occur through blood transfusion, congenital transmission, and, much less often, organ transplantation, laboratory accident, breast feeding, and oral contamination (Benchimol Barbosa, 2006). Although heart transplantation for Chagas cardiomyopathy has been successfully performed, reactivation of *Trypanosoma cruzi* is common. These initial local signs may be followed by malaise, fever sweating, myalgias anorexia, and a morbilliform rash may also appear. Generalized lymphadenopathy and hepatosplenomegaly may develop. Cardiac failure occur secondary to myocarditis; cardiac involvement is present in over 90 percent of those in whom the diagnosis is made (Pinto et al., 2004). The frequency and severity of myocarditis are inversely proportional to age (Dias & Kloetzel, 1968). The acute symptoms resolve spontaneously in virtually all patients, who then enter the asymptomatic or indeterminate phase of chronic *T. cruzi* infection. The electrocardiogram normalized in over 90 percent of patients after one year.

The indeterminate form usually lasts 10 to 30 years and only approximately 30 percent of the patients develop overt cardiac disease. Most patients remain asymptomatic throughout life. The natural history of this phase of disease is characterized by subtle degree of cardiac involvement and gradual appearance of clinical or electrocardiographic markers of cardiac involvement, which signals the onset of the chronic phase. In one review, progression from indeterminate to the full-blown clinical form in the chronic phase occurred at approximately 2 percent per year (Dias, 1989). In another report, 38.3 percent of patients with positive serology but without symptoms developed chagasic cardiomyopathy over a 10-year period (Coura et al., 1985). About 50 percent of patients remain with the indeterminate form indefinitely (Marin-Neto et al., 2003).

### 7.5.2 Chronic phase

The chronic form is characterized by dilatation of several cardiac chambers, fibrosis and thinning of the ventricular wall, aneurysm formation (especially at the left ventricular apex), and mural thrombi.

Chronic progressive heart failure is the rule and is associated with poor survival. Mortality associated with the chronic phase almost exclusively due to cardiovascular involvement. The cause of death is sudden cardiac death in 55 to 65 percent, progressive heart failure in 25 to 30 percent, and stroke in 10 to 15 percent (Rassi et al., 2001). Symptoms and physical signs at this stage of the disease arise from three basic syndromes that often coexist in the same patient, heart failure, cardiac dysrhythmia, and thromboembolism (systemic and pulmonary). Heart failure in Chagas heart disease is usually biventricular and commonly presented with fatigue. However, right-sided failure manifested with increased jugular venous pressure, peripheral edema, ascites, and hepatomegaly is characteristically more pronounced than those of left-sided failure manifested with dyspnea and pulmonary rales. Both systolic and diastolic dysfunction can occur (Sousa et al., 1988). Cardiac examination typically reveals the findings of murmurs of mitral and tricuspid regurgitation, wide splitting of the second heart sound due to right bundle branch block and prominent diffuse apical thrust.

Cardiac arrhythmias may cause palpitation, lightheadedness, dizziness, or syncope. Autonomic dysfunction results in marked abnormalities in the heart rate changes. Chest pain is common symptom and usually atypical in Chagas heart disease. It may mimic angina due to abnormal coronary vasomotion postulated as underlying mechanism (Marin-Neto et al., 1992). Sudden cardiac death accounts for 55 to 65 percent of deaths in CD; the real frequency of this complication is probably underestimated, particularly in rural areas (Rassi et al., 2001). Sudden cardiac arrest can occur even in previously asymptomatic patients (Rassi Júnior et al., 1995). However, most patients have severe underlying heart disease, including ventricular aneurysms at multiple sites (posterior-lateral, inferior basal, or apical), which is a characteristic finding in Chagas heart disease (Rassi Júnior et al., 1995). Sudden death is usually precipitated by exercise, and can be caused by VT or fibrillation, asystole, or complete AV block (Mendoza et al., 1986). The electrocardiogram is abnormal in most patients with cardiac involvement and typically shows right bundle branch block, left anterior hemiblock and diffuse ST-T changes, which may progress to complete atrioventricular block. Ventricular arrhythmia may also be seen in form of premature beats that may be multifocal and runs of nonsustained ventricular tachycardia. The severity of ventricular arrhythmias tends to correlate with the degree of LV dysfunction. Other changes like, abnormal Q waves, various degrees of atrioventricular block, QT interval prolongation

and variation in the QT interval (QT dispersion) are frequent findings (Salles et al., 2003). Virtually all types of atrial and ventricular arrhythmias occur frequently, atrial fibrillation and low QRS voltage may be observed in advanced disease.

A potentially serious complication of chronic Chagas heart disease is thromboembolism. In a review of 1345 autopsies, cardiac thrombus or thromboemboli reported in 44 percent; both right and left cardiac chambers equally affected (Samuel et al., 1983). Although thromboembolic phenomena were more common in the systemic circulation, pulmonary embolism accounted for 14 percent of deaths. Cardioembolism appears to be an important cause of acute ischemic stroke. One series of 94 patients with Chagas disease in Brazil reported higher rate of cardioembolism (56 versus 9 percent) as compared to control group (Carod-Artal et al., 2005). Stroke was also reported significantly more frequent in patients who had Chagas disease related cardiomyopathy compared with patients who had other cardiomyopathies (15.0 versus 6.3 percent), (Oliveira-Filho et al., 2005). Echocardiography or contrast ventriculography may reveal a left ventricular apical aneurysm, regional wall motion abnormalities, or diffuse cardiomyopathy. The cause of death is either intractable CHF or an arrhythmia, with a minority of patients dying from embolic phenomena.

### 7.6 Fungal myocarditis

The incidence of invasive fungal disease has dramatically increased over the past few decades corresponding to the rising number of immunocompromised patients. Cardiac fungal infection, especially myocarditis, may be difficult to recognize clinically and may in itself produce a fatal outcome. Myocardial involvement frequently occurs in disseminated fungal infection in which multiple organs often affected. Conditions that appear predisposing to fungal infection are human immunodeficiency virus infection, medication like, corticosteroids, antineoplastic agents or broad-spectrum antibiotics, alone or in combination with invasive medical procedures (Nosanchuk, 2002). *Candida* was the most frequently observed organism, while *Aspergillus* was the second most frequent fungus to involve the heart. Rarely *Cryptococcus* identified as a cause of myocarditis as well.

### 7.7 Eosinophilic and hypersensitivity myocarditis

The association between eosinophilia (eosinophil count  $>500/\text{mm}^3$ ) and heart disease was first identified by Loeffler (Loeffler, 1936). A specific eosinophilic form of myocarditis identified following drug-induced hypersensitivity reactions and systemic hypereosinophilic syndromes (Taliencio et al., 1985).

Eosinophilic myocarditis is characterized by a predominantly mature eosinophils infiltration of the myocardium and other organ systems. It occurs in association with systemic diseases such as hypereosinophilic syndrome, Churg-Strauss syndrome and Löffler's endomyocardial fibrosis. Also it may occur in association with cancer, parasitic, helminthic or protozoal infections such as Chagas disease, toxoplasmosis, schistosomiasis, trichinosis, hyatid cysts and visceral larval migrans (Corradi et al., 2004; Corssmit et al., 1999; Spodick, 1997). Eosinophilic myocarditis has been reported after vaccination for several diseases, including smallpox (Arness et al., 2004; Barton et al., 2008). Acute eosinophilic necrotizing myocarditis is a rare aggressive form of eosinophilic myocarditis and may represent an extreme form of hypersensitivity myocarditis which characterized by acute onset and rapidly results in cardiovascular deterioration and circulatory collapse carried high mortality rates (Cooper & Zehr, 2005). The clinical manifestations of eosinophilic myocarditis may include right and left congestive heart failure, endocardial and valvular



fibrosis leading to regurgitation, and formation of endocardial thrombi. Clinical awareness warranted when presentation may mimics acute myocardial infarction, with ischemic chest pain and ST-segment elevation on electrocardiography (Galiuto et al., 1997).

Hypersensitivity myocarditis is a form of eosinophilic myocarditis due to autoimmune reaction affecting the heart muscle, often induced by drug. It is often first discovered at postmortem examination. In one series, the prevalence of clinically undetected hypersensitivity myocarditis in explanted hearts ranged from 2.4 to 7 percent (Wu et al., 2002).

Numerous drugs have been implicated in hypersensitivity myocarditis including, antibiotics (Burke et al., 1991) like penicillins, cephalosporins and sulfonamides; antipsychotics (Killian et al., 1999) like clozapine and tricyclic antidepressants (Ansari et al., 2003; Burke et al., 1991; Kounis et al., 1989); others like methyldopa, hydrochlorothiazide, furosemide, tetracycline, azithromycin, aminophylline, phenytoin and benzodiazepines (Ben m'rad et al., 2009; Pursnani et al., 2009; Taliercio et al., 1985). Hypersensitivity myocarditis not constantly develop early in the course of medication. Patients taking the antipsychotic agent clozapine have been reported to develop myocarditis more than two years after the drug was started (Haas et al., 2007). Prolonged continuous infusion of dobutamine has also been associated with hypersensitivity myocarditis which has been reported in 2.4 to 23 percent (Spear, 1995; Takkenberg et al., 2004). Cocaine also rarely produce a hypersensitivity myocarditis, unlike the hypereosinophilic syndrome, peripheral eosinophilia is typically absent (Isner & Chokshi, 1991).

Clinically, the presentation often heralded by fever, peripheral eosinophilia and a drug rash that occurs days to weeks after administration of a previously well-tolerated agent. Electrocardiographic abnormalities show nonspecific ST segment changes or infarct patterns (Fenoglio et al., 1981). Myocardial involvement varies but usually does not result in fulminant heart failure or hemodynamic collapse. However, some patients present with sudden death or rapidly progressive heart failure (Burke et al., 1991; Galiuto et al., 1997). Eosinophilic myocarditis can be a manifestation of eosinophilia-myalgia syndrome, which is a multisystem disease caused by ingestion of contaminants in L-tryptophan containing products (Belongia et al., 1990), characterized by peripheral eosinophilia and generalized disabling myalgias (Martin et al., 1990). Eosinophils, lymphocytes, macrophages, and fibroblasts accumulate in the affected tissues, but their role in pathogenesis is unclear. The disease is frequently evolves into a chronic course but can be fatal in up to 5% of patients.

### **7.8 Giant cell myocarditis**

Idiopathic giant cell myocarditis is a rare inflammatory disease that often affects previously healthy young adults and frequently fatal type of myocarditis (Cooper et al., 2008). The pathogenesis of this disorder is not known. It is identified by the presence of multinucleated giant cells associated with eosinophils and myocyte destruction in the absence of granulomas on endomyocardial biopsy. It is thought to be primarily autoimmune in nature because of the reported comorbidity with a variety of autoimmune disorders (Cooper et al., 1997), thymoma, (Kilgallen et al., 1998) and drug hypersensitivity (Daniels et al., 2000).

Idiopathic giant cell myocarditis is usually a fulminant form of myocarditis and characterised by a history of rapid progression of severe heart failure associated with refractory sustained ventricular arrhythmias. Giant-cell myocarditis is sometimes distinguished from the much more common postviral myocarditis by the presence of



ventricular tachycardia, heart block, and a downhill clinical course, despite optimal clinical care. In the series of 63 patients with giant cell myocarditis enrolled in the multicenter Giant Cell Myocarditis Treatment Trial, 75 percent identified with heart failure symptoms as the primary presentation, 14 percent with ventricular arrhythmia and heart block in 5 percent (Cooper et al., 1997). Most patients will require cardiac transplantation, the median survival from the onset of symptoms of less than 6 months and has an 89 percent rate of death or transplantation. This represents a significantly worse outcome compared to lymphocytic or viral myocarditis. Despite a 25 percent incidence of post-transplantation recurrence of giant cell myocarditis detected by biopsy, the 5-year survival after transplantation is about 71 percent which is comparable to survival after transplantation for cardiomyopathy.

### **7.9 Systemic lupus erythematosus myocarditis**

Acute myocarditis is an uncommon manifestation of systemic lupus erythematosus (SLE), with a prevalence of 8 to 25 percent in different studies (Apte et al., 2008; Mandell, 1987). Myocarditis frequently asymptomatic but less often may accompany other manifestations of acute SLE. In particular pericarditis, commonly occur in about two-thirds of patients, and generally follows a benign course, however tamponade or constriction may occur infrequently.

Myocarditis generally parallels the activity of the disease and, although common histologically, rarely results in clinical heart failure unless associated with hypertension. African American ethnicity is associated with a higher risk of myocarditis compared with Hispanic and Caucasian ethnicity (Apte et al., 2008). Myocarditis should be suspected if there is resting tachycardia disproportionate to body temperature, ST and T wave electrocardiographic abnormalities and unexplained cardiomegaly. The cardiomegaly may be associated with symptoms and signs of heart failure, conduction abnormalities or arrhythmias (Moder et al., 1999). Patients with SLE are at increased risk for myocardial ischemia due to accelerated atherosclerosis or coronary arteritis. Endocardial involvement with fibrinous endocarditis (Libman & Sachs, 1924) is another serious manifestation can lead to valvular insufficiencies or embolic events. Likewise patients with the antiphospholipid syndrome have a higher incidence of valvular disease, a variety of thrombotic disorders, myocardial infarction, pulmonary hypertension, and cardiomyopathy. Myocardial biopsy reveal mononuclear cells infiltration distinguish active myocarditis from fibrosis and other causes of cardiomyopathy (Schattner & Liang, 2003) or rarely cardiotoxicity induced by hydroxychloroquine (Keating et al., 2005). Inflammation may lead to fibrosis that may be manifested clinically as dilated cardiomyopathy.

### **7.10 Sarcoid myocarditis**

It is a granulomatous form of myocarditis. The clinical evidence of myocardial involvement is present in approximately 5 percent of patients with sarcoidosis. However, an autopsy series have reported higher rates of about 25 percent of subclinical cardiac involvement (Chapelon-Abric et al., 2004; Kim et al., 2009; Thomsen & Eriksson et al., 1999). The clinical manifestations of cardiac sarcoidosis are largely nonspecific and may precede, follow, or occur concurrently with involvement of other organs. Sarcoid heart disease should be considered in the evaluation of an otherwise healthy young or middle aged person with cardiac symptoms or in a patient with known sarcoidosis who develops arrhythmias, conduction disease, or heart failure. Patients who present with apparently chronic dilated

cardiomyopathy yet with new ventricular arrhythmias or second-degree or third degree heart block or who do not have a response to optimal care are more likely to have cardiac sarcoidosis (Yazaki et al., 1998). Cardiac symptoms were reported in 101 patients, when cardiac sarcoidosis was diagnosed in 84 percent compared to 4 percent in asymptomatic patients (Smedema et al., 2005). Endomyocardial biopsy shows characteristic noncaseating granulomas. However, the diagnosis can also be inferred if there is a tissue diagnosis of sarcoidosis from an extracardiac source in the presence of a cardiomyopathy of unknown origin.

The electrocardiographic abnormalities found in nearly 70 percent of patients with sarcoidosis (Chapelon-Abric et al., 2004). Cardiac involvement with sarcoidosis may produce clinical symptoms and electrocardiographic findings simulating myocardial infarction. Conduction abnormalities in form of first-degree heart block due to disease of the atrioventricular node or bundle of His, and various types of intraventricular conduction defects, are common among patients with cardiac sarcoidosis (Chapelon-Abric et al., 2004). These lesions may initially be silent, but can progress to complete heart block and cause syncope (Yoshida et al., 1997). Sustained or nonsustained ventricular tachycardia and ventricular premature beats are the second most common presentation of cardiac sarcoidosis; electrocardiography reveals ventricular arrhythmias in as many as 22 percent of patients with sarcoidosis (Sekiguchi et al., 1980). Supraventricular arrhythmias are infrequent. Sudden death due to ventricular tachyarrhythmias or conduction block accounts for 25 to 65 percent of deaths due to cardiac sarcoidosis, however, sudden death can occur in the absence of a previous cardiac event (Reuhl et al., 1997; Soejima & Yada, 2009; Yazaki et al., 2001). Both systolic and diastolic heart failure can occur. Left ventricular aneurysms develop in patients with extensive involvement of the myocardium. Mitral incompetence may occur with cardiac sarcoidosis due to associated systolic dysfunction and left ventricular dilation or due to papillary muscle involvement by sarcoid granulomas (Sato et al., 2008). Tricuspid regurgitation with atrioventricular block secondary to infiltration of tricuspid valves and conduction system by sarcoid granulomas has been reported as well (Goyal & Aragam, 2006). A left atrial granulomatous mass resembling myxoma has been reported too (Abrishami et al., 2004).

### **7.11 Peripartum cardiomyopathy**

The syndrome is a rare disorder of pregnancy. It was recognized in 1937, as a distinct clinical entity (Gouley et al., 1937). Currently, the etiology of peripartum cardiomyopathy (PPCM) remains unclear. However, there is compelling data from animal and human studies suggesting that PPCM is actually a type of myocarditis arising from an infectious, autoimmune, or idiopathic etiology. The relationship between pregnancy and viral myocarditis was first published in 1968 (Farber & Glasgow, 1970). Endomyocardial biopsies in women with PPCM have demonstrated myocarditis in many patients. The highest incidence of myocarditis reported in PPCM was 76 percent (Midei et al., 1990), however much lower incidence was reported (8.8 percent), which found to be comparable to an age and sex matched control population undergoing transplantation for idiopathic dilated cardiomyopathy (9.1 percent), (Rizeq et al., 1994). Viral genomes of parvovirus B19, human herpes virus 6, Epstein-Barr virus, and human cytomegalovirus revealed in endomyocardial biopsy specimens from patients with PPCM (Bultmann et al., 2005). Other reported data linked with Chlamydia infection (Cenac et al., 2003).

Women present with heart failure during the peripartum period and become manifested in the last month of pregnancy or within 5 months of the delivery without apparent etiology for the heart failure can be found. The clinical scenario is challenging because many normal women in the last month of a normal pregnancy experience dyspnea, fatigue and pedal edema, symptoms can mimic early congestive cardiac failure. Physical examination can be significant for signs of right and left heart failure. Symptoms and signs that should raise the suspicion of heart failure include paroxysmal nocturnal dyspnea, chest pain, nocturnal cough, new regurgitant murmurs, pulmonary crackles, elevated jugular venous pressure and hepatomegaly. The electrocardiogram usually demonstrates a normal sinus or sinus tachycardia rhythm, but frequent ectopy and other atrial arrhythmias may also be present. Left ventricular hypertrophy, inverted T waves, Q waves, and nonspecific ST-T changes have also been reported (Brown & Bertolet, 1998). Recurrence in a subsequent pregnancy has been reported. However, significant improvement occurs in up to 50 percent of affected women; others are left with a progressive dilated cardiomyopathy.

## 8. Conclusion

The clinical signs and symptoms of myocarditis are highly variable. A thorough medical history with emphasis on possible causes is essential. A scrupulous awareness to ample clinical scenarios is essential for clinicians, particularly when the cases are lacking apparent etiologies or the presentations being similar to acute myocardial infarction, asymptomatic left ventricular systolic dysfunction, unexplained ventricular tachyarrhythmias or cardiogenic shock. Clinician need to be attentive when evidence of myocardial damage not attributable to epicardial coronary artery disease, primary valvular disease or noninflammatory causes. Usually, most cases of myocarditis are self limited and a spontaneous improvement occurs in a substantial number of patients with lymphocytic disease but is rarely, if ever, observed with granulomatous myocarditis. While routine diagnostic endomyocardial biopsy is not required in most cases of suspected acute myocarditis, the need for biopsy will depend upon the time course and severity of the clinical presentation.

Better understanding of the clinicopathologic aberration that characterize the diverse clinical scenarios and more comprehensive understanding of the natural history of the various subtypes of myocarditis should assist clinicians for better approach and subsequently plan more effective therapy in the future.

## 9. Acknowledgment

The authors would like to acknowledge Sahera Khalil Al-Nnadaf (H.D.) who actively contributed in preparation and assembly of this chapter.

## 10. References

- Abrishami, B., O'Connel, C., Sharma, O. (2004). Cardiac sarcoidosis with presentation of large left atrial mass. *Curr Opin Pulm Med*, Vol.10, p. 397.
- Akhras, F., Dubrey, S., Gazzard, B. (1994). Emerging patterns of heart disease in HIV infected homosexual subjects with and without opportunistic infections; a prospective colour flow Doppler echocardiographic study. *Eur Heart J*, Vol.15, pp. 68-75.

- Al-aqeedi, RF., Kamha, A., Al-aani, FK. (2009). Salmonella myocarditis in a young adult patient presenting with acute pulmonary edema, rhabdomyolysis, and multi-organ failure *Journal of Cardiology*, Vol.54, pp. 475-479.
- Albert, DA., Harel, L., Karrison, T. (1995). The treatment of rheumatic carditis: a review and meta-analysis. *Medicine (Baltimore)*, Vol.74, p. 1.
- Arness, MK., Eckart, RE., Love, SS. (2004). Myopericarditis following smallpox vaccination. *Am J Epidemiol*, Vol.160, pp. 642-651.
- Amos, AM., Jaber, WA., Russell, SD. (2006). Improved outcomes in peripartum cardiomyopathy with contemporary. *Am Heart J*, Vol.152, pp. 509-513.
- Anderson, DW., Virmani, R., Reilly, JM. (1988). Prevalent myocarditis at necropsy in the acquired immunodeficiency syndrome. *J Am Coll Cardiol*, Vol.11, pp. 792-799.
- Angelini, A., Calzolari, V., Calabrese, F. (2000). Myocarditis mimicking acute myocardial infarction: role of endomyocardial biopsy in the differential diagnosis. *Heart*, Vol.84, p. 245.
- Ansari, A., Maron, BJ., Berntson, DG. (2003). Drug-induced toxic myocarditis. *Tex Heart Inst J*, Vol.30, pp. 76 -79.
- Antonarakis, ES., Wung, PK., Durand, DJ. (2006). An atypical complication of atypical pneumonia. *Am J Med*, Vol.119, p. 824.
- Apte, M., McGwin, G, Jr., Vilá, LM. (2008). Associated factors and impact of myocarditis in patients with SLE from LUMINA, a multiethnic US cohort (LV). *Rheumatology (Oxford)*, Vol.47, p. 362.
- Aretz, HT., Billingham, ME., Edwards, WD. (1987). Myocarditis: a histopathologic definition and classification. *Am J Cardiovasc Pathol*, Vol.1, pp. 3-14.
- Arteaga-Fernandez, E., Barretto, AC., Ianni, BM. (1989). Cardiac thrombosis and embolism in patients having died of chronic Chagas cardiopathy. *Arq Bras Cardiol*, Vol.52, pp. 189-192.
- Baboonian, C. & Treasure, T. (1997). Meta-analysis of the association of enteroviruses with human heart disease. *Heart*, Vol.78, pp. 539 -543.
- Barbaro, G., Di Lorenzo, G., Grisorio, B. (1998). Cardiac involvement in the acquired immunodeficiency syndrome: a multicenter clinical-pathological study. Gruppo Italiano per lo Studio Cardiologico dei pazienti affetti da AIDS Investigators. *AIDS Res Hum Retroviruses*, Vol.14, p. 1071.
- Barbaro, G., Di Lorenzo, G., Grisorio, B. (1998). Gruppo Italiano per lo Studio Cardiologico dei Pazienti Affetti da AIDS. Incidence of dilated cardiomyopathy and detection of HIV in myocardial cells of HIV-positive patients. *N Engl J Med*, Vol.339, pp. 1093-1099.
- Barbaro, G. (2005). Reviewing the cardiovascular complications of HIV infection after the introduction of highly active antiretroviral therapy. *Curr Drug Targets Cardiovasc Haematol Disord*, Vol.5, p. 337.
- Baroldi, G., Corallo, S., Moroni, M. (1988). Focal lymphocytic myocarditis in acquired immunodeficiency syndrome (AIDS): a correlative morphologic and clinical study in 26 consecutive fatal cases. *J Am Coll Cardiol*, Vol.12, pp. 463-469.
- Barton, M., Finkelstein, Y., Opavsky, M. (2008). Eosinophilic myocarditis temporally with conjugate meningococcal C and hepatitis B vaccines in children. *Pediatr Infect Dis J*, Vol.27, pp. 831-835.
- Bartůnek, P., Gorican, K., Mrázek, V. (2006). Lyme borreliosis infection as a cause of dilated cardiomyopathy. *Prague Med Rep*, Vol.107(2), pp. 213-226.



- Baughman, KL. (2006). Diagnosis of myocarditis: death of Dallas criteria. *Circulation*, Vol.113, pp. 593-595.
- Belongia, EA., Hedberg, CW., Gleich, GJ. (1990). An investigation of the cause of the eosinophilia-myalgia syndrome associated with tryptophan use. *N Engl J Med*, Vol.323, p. 357.
- Benchimol Barbosa, PR. (2006). The oral transmission of Chagas' disease: an acute form of infection responsible for regional outbreaks. *Int J Cardiol*, Vol.112, p. 132.
- Ben m'rad, M., Leclerc-Mercier, S., Blanche, P. (2009). Drug-induced hypersensitivity syndrome: clinical and biologic disease patterns in 24 patients. *Medicine (Baltimore)*, Vol.88, p. 131.
- Bestetti, R. (2000). Stroke in a hospital-derived cohort of patients with chronic Chagas' disease. *Acta Cardiol*, Vol.55, pp. 33-38.
- Bowles, NE., Richardson, PJ., Olsen, ECJ. (1986). Detection of Coxsackie-B virus specific RNA sequences in myocardial biopsy samples from patients with myocarditis and dilated cardiomyopathy. *Lancet*, Vol.1, pp. 1120-1128.
- Boyer, NH. & Weinstein, L. (1948). Diphtheritic myocarditis. *N Engl J Med*, Vol.239, p. 913.
- Bratincsák, A., El-Said, HG., Bradley, JS. (2010). Fulminant myocarditis associated with pandemic H1N1 influenza A virus in children. *J Am Coll Cardiol*, Vol.9, pp. 928-929.
- Brodison, A. & Swann, JW. (1998). Myocarditis: a Review. *J Infection*, Vol.37, pp. 99-103.
- Brown, CS. & Bertolet, BD. (1998). Peripartum cardiomyopathy: a comprehensive review. *Am J Obstet Gynecol*, Vol.178, pp. 409-414.
- Brown, J., King, A., Francis, CK. (1991). Cardiovascular effects of alcohol, cocaine, and acquired immune deficiency. *Cardiovasc Clin*, Vol.21, pp. 341-376.
- Bultmann, BD., Klingel, K., Nabauer, M. (2005). High prevalence of viral genomes and inflammation in peripartum cardiomyopathy. *Am J Obstet Gynecol*, Vol.193, pp. 363-365.
- Burke, AP., Saenger, J., Mullick, F. (1991). Hypersensitivity myocarditis. *Arch Pathol Lab Med*, Vol.115, pp. 764-769.
- Burke, PT., Shah, R., Thabolingam, R. (2009). Suspected Legionella-induced perimyocarditis in an adult in the absence of pneumonia: a rare clinical entity. *Tex Heart Inst J*, Vol.36(6), pp. 601-613.
- Burt, CR., Proudfoot, JC., Roberts, M. (1990). Fatal myocarditis secondary to Salmonella septicemia in a young adult. *J Emerg Med*, Vol.8, pp. 295-297.
- Caforio, A., Calabrese, F., Angelini, A. (2007). A prospective study of biopsy-proven myocarditis: prognostic relevance of clinical and aetiopathogenetic features at diagnosis. *Eur Heart J*, Vol.28, pp. 1326-1333.
- Carapetis, JR. & Currie, BJ. (2001). Rheumatic fever in a high incidence population: the importance of monoarthritis and low grade fever. *Arch Dis Child*, Vol.85, p. 223.
- Carod-Artal, FJ., Vargas, AP., Horan, TA. (2005). Chagasic cardiomyopathy is independently associated with ischemic stroke in Chagas disease. *Stroke*, Vol.36, p. 965.
- Cenac, A., Djibo A., Chaigneau, C. (2003). Are anti-Chlamydia pneumoniae antibodies prognosis indicators for peripartum cardiomyopathy? *J Cardiovasc Risk*, Vol.10, pp. 195-199.
- Chapelon-Abrie, C., de Zuttere, D., Duhaut, P. (2004). Cardiac sarcoidosis: a retrospective study of 41 cases. *Medicine (Baltimore)*, Vol.83, p. 315.
- Chau, EM., Chow, WH., Chiu, C. (2006). Treatment and outcome in biopsy proven fulminant myocarditis in adults. *Int J Cardiol*, (June 2006) Vol.110 (3), pp. 405-406.



- Ciesielski, CA., Markowitz, LE., Horsley, R. (1989). Lyme disease surveillance in the United States, 1983-1986. *Rev Infect Dis*, 11 Suppl, Vol.6, pp. S1435.
- Cooper, LT., Jr, Berry, GJ., Shabetai, R. (1997). Idiopathic giant-cell myocarditis--natural history and treatment. Multicenter Giant Cell Myocarditis Study Group Investigators. *N Engl J Med*, Vol.336, pp. 1860-1866.
- Cooper, LT. & Zehr, KJ. (2005). Biventricular assist device placement and immunosuppression as therapy for necrotizing eosinophilic myocarditis. *Nat Clin Pract Cardiovasc Med*, Vol.2, pp. 544-548.
- Cooper, LT., Jr, Hare, JM., Tazelaar, HD. (2008). Usefulness of immunosuppression for giant cell myocarditis. *Am J Cardiol*, Vol.102, pp. 1535.
- Corallo, S., Mutinelli, MR., Moroni, M. (1988). Echocardiography detects myocardial damage in AIDS: prospective study in 102 patients. *Eur Heart J*, Vol.9, pp. 887-892.
- Corradi, D., Vaglio, A., Maestri, R. (2004). Eosinophilic myocarditis in a patient with idiopathic hypereosinophilic syndrome: insights into mechanisms of myocardial cell death. *Hum Pathol*, Vol.35, pp. 1160-1163.
- Corssmit, EP., Trip, MD., Durrer, JD. (1999). Löffler's endomyocarditis in the idiopathic hypereosinophilic syndrome. *Cardiology*, Vol.91, p. 272-276.
- Costello, JM., Alexander, ME., Greco, KM. (2009). Lyme carditis in children: presentation, predictive factors, and clinical course. *Pediatrics*, Vol.123, pp. e835.
- Coura, JR., de Abreu, LL., Pereira, JB. (1985). Morbidity in Chagas' disease. IV. Longitudinal study of 10 years in Pains and Iguatama, Minas Gerais, Brazil. *Mem Inst Oswaldo Cruz*, Vol.80, p. 73.
- Cox, J. & Krajden, M. (1991). Cardiovascular manifestations of Lyme disease. *Am Heart J*, Vol.122, pp. 1449-1455.
- d'Amati, G., Kwan, W., Lewis, W. (1992). Dilated cardiomyopathy in a zidovudine-treated AIDS patient. *Cardiovasc Pathol*, Vol.1, pp. 317-320.
- Daly, K., Richardson, PJ., Olsen, EG. (1984). Acute myocarditis. Role of histological and virological examination in the diagnosis and assessment of immunosuppressive treatment. *Br Heart J*, Vol.51, pp. 30-35.
- Daniels, P., Tazelaar, H., Edwards, W. (2000). Giant cell myocarditis as a manifestation of drug hypersensitivity. *Cardiovasc Pathol*, Vol.9, pp. 287-291.
- Davidoff, R., Palacios, I., Southern, J. (1991). Giant cell versus lymphocytic myocarditis. A comparison of their clinical features and long-term outcomes. *Circulation*, Vol.83, pp. 953-961.
- Dec, GW Jr., Palacios, IF., Fallon, JT. (1985). Active myocarditis in the spectrum of acute dilated cardiomyopathies. Clinical features, histologic correlates, and clinical outcome. *N Engl J Med*, Vol.312, pp. 885-890.
- Dec, GW Jr., Waldman, H., Southern, J. (1992). Viral myocarditis mimicking acute myocardial infarction. *J Am Coll Cardiol*, Vol.20, p. 85.
- Deyton, LR., Walker, RE., Kovacs, JA. (1989). Reversible cardiac dysfunction associated with interferon alfa therapy in AIDS patients with Kaposi's sarcoma. *N Engl J Med*, Vol.321, pp. 1246-1249.
- Dias, JC. & Kloetzel, K. (1968). The prognostic value of the electrocardiographic features of chronic Chagas' disease. *Rev Inst Med Trop Sao Paulo*, Vol.10, p. 158.
- Dias, JC. (1989). The indeterminate form of human chronic Chagas' disease A clinical epidemiological review. *Rev Soc Bras Med Trop*, Vol.22, p. 147.
- Dittrich, H., Chow, L., Denaro, F. (1988). Human immunodeficiency virus, coxsackievirus, and cardiomyopathy. *Ann Intern Med*, Vol.108, p. 308.

- Doolan, A., Langlois, N., Semsarian, C. (2004). Causes of sudden cardiac death in young Australians. *Med J Aust*, Vol.180, pp. 110 –112.
- Drory, Y., Turetz, Y., Hiss, Y. (1991). Sudden unexpected death in persons less than 40 years of age. *Am J Cardiol*, Vol.68, pp. 1388-1392.
- Eckart, RE., Scoville, SL., Campbell, CL. (2004). Sudden death in young adults: a 25-year review of autopsies in military recruits. *Ann Intern Med*, Vol.141, p. 829.
- Ellis, CR. & Di Salvo, T. (2007). Myocarditis: basic and clinical aspects. *Cardiol Rev*, Jul-Aug. Vol.15(4), pp. 170-177.
- Essop, MR., Wisenbaugh, T., Sareli, P. (1993). Evidence against a myocardial factor as the cause of left ventricular dilation in active rheumatic carditis. *J Am Coll Cardiol*, Vol.22, pp. 826-829.
- Fabre, A. & Sheppard, MN. (2005). Sudden adult death syndrome and other non ischaemic causes of sudden cardiac death: a UK experience. *Heart*, Vol.92(3), pp. 316-320.
- Farber, PA., Glasgow, LA., (1970). Viral myocarditis during pregnancy: encephalomyocarditis virus infection in mice. *Am Heart J*, Vol.80, pp. 96-102.
- Feldman, AM. & McNamara, D. (2000). Myocarditis. *N Engl J Med*, Vol.343, pp. 1388-1398.
- Felker, GM., Hu, W., Hare, JM. (1999). The spectrum of dilated cardiomyopathy: the Johns Hopkins experience with 1,278 patients. *Medicine (Baltimore)*, Vol.78, pp. 270 –283.
- Felker, GM., Thompson, RE., Hare, JM. (2000). Underlying causes and long-term survival in patients with initially unexplained cardiomyopathy. *N Engl J Med*, Vol.342, p. 1077.
- Fenoglio, JJ, Jr., McAllister, HA, Jr., Mullick, FG. (1981). Drug related myocarditis. I. Hypersensitivity myocarditis. *Hum Pathol*, Vol.12, p. 900.
- Fernandes, SO., de Oliveira, MS., Teixeira, Vd. (1987). Endocardial thrombosis and type of left ventricular lesion in chronic Chagasic patients. *Arq Bras Cardiol*, Vol.48, pp. 17-19.
- Ferrieri, P. Jones Criteria Working Group. (2002). Proceedings of the Jones Criteria workshop. *Circulation*, Vol.106, p. 2521.
- Fish, AE., Pride, YB., Pinto, DS. (2008). Lyme carditis. *Infect Dis Clin North Am*, Vol.22, p. 275.
- Fisher, SD. & Lipshultz, SE. (2001). Epidemiology of cardiovascular involvement in HIV disease and AIDS. *Ann N Y Acad Sci*, Vol.946, p. 13.
- Fleming, HA. & Bailey, SM. (1981). Sarcoid heart disease. *J R Coll Physicians Lond*, Vol.15, pp. 245-253.
- Ford, RF., Barton, JR., O'brien, JM. (2000). Demographics, management, and outcome of peripartum cardiomyopathy in a community hospital. *Am J Obstet Gynecol*, Vol.182, pp. 1036-8.
- Fournier, PE., Etienne, J., Harle, JR. (2001). Myocarditis, a rare but severe manifestation of Q fever: report of 8 cases and review of the literature. *Clin Infect Dis*, Vol.32, pp. 1440.
- Fowler, NO. & Manitsas, GT. (1973). Infectious pericarditis. *Prog Cardiovasc Dis*, Vol.16, pp. 323-336.
- Friedman, RA., Kearney, DL., Moak, JP. (1994). Persistence of ventricular arrhythmia after resolution of occult myocarditis in children and young adults. *J Am Coll Cardiol*, Vol.24, pp. 780-783.
- Friedrich, MG., Sechtem, U., Schulz-Menger, J. (2009). Cardiovascular magnetic resonance in myocarditis: A JACC White Paper. *J Am Coll Cardiol*, Vol.53, pp. 1475-1487.
- Friis-Møller, N. & Reiss, P. (2007). DAD Study Group. Class of antiretroviral drugs and the risk of myocardial infarction. *N Engl J Med*, Vol.356, p. 1723.
- Fuse, K., Kodama, M., Okura, Y. (2000). Predictors of disease course in patients with acute myocarditis. *Circulation*, Dec 5, Vol.102(23), pp. 2829-2835.

- Galiuto, L., Enriquez-Sarano, M., Reeder, GS. (1997). Eosinophilic myocarditis manifesting as myocardial infarction: early diagnosis and successful treatment. *Mayo Clin Proc*, Vol.72, pp. 603-610.
- Gdynia, G., Schnitzler, P., Brunner, E. (2011). Sudden death of an immunocompetent young adult caused by novel (swine origin) influenza A/H1N1-associated myocarditis. *Virchows Arch*, Mar, Vol.458(3), pp. 371-376.
- Gerzen, P., Granath, A., Holmgren, B. (1972). Acute myocarditis. A follow-up study. *Br Heart J*, Vol.34, p. 575.
- Giacca, M., Severini, GM., Mestroni, L. (1994). Low frequency of detection by nested polymerase chain reaction of enterovirus ribonucleic acid in endomyocardial tissue of patients with idiopathic dilated cardiomyopathy. *J Am Coll Cardiol*, Vol.24, pp. 1033-1040.
- Gilbert, EM. & Mason, JW. (1987). Immunosuppressive therapy of myocarditis. In: Engelmeier RS, JB O'Connell, eds. *Drug Therapy in Dilated Cardiomyopathy and Myocarditis*. New York: Marcel Dekker, pp. 233-263.
- Goldings, EA. & Jericho, J. (1986). Lyme disease. *Clin Rheum Dis*, Vol.12, p. 343.
- Gouley, BA., McMillan, TM., bellet, S. (1937). Idiopathic myocardial degeneration associated with pregnancy and especially the puerperium. *Am J Med Sci*, Vol.19, pp. 185-199.
- Goyal, SB. & Aragam, JR. (2006). Cardiac sarcoidosis with primary involvement of the tricuspid valve. *Cardiol Rev*, Vol.14, p. e12.
- Grist, NR. & Bell, EJ. (1969). Coxsackie viruses and the heart. *Am Heart J*, Vol.77, p. 295.
- Guidelines for the diagnosis of rheumatic fever. Jones Criteria, 1992 update. (1992). Special Writing Group of the Committee on Rheumatic Fever, Endocarditis, and Kawasaki Disease of the Council on Cardiovascular Disease in the Young of the American Heart Association. *JAMA*, Vol.268, p. 2069.
- Haas, SJ., Hill, R., Krum, H. (2007). Clozapine-associated myocarditis: a review of 116 cases of suspected myocarditis associated with the use of clozapine in Australia during 1993-2003. *Drug Saf*, Vol.30, p. 47.
- Haessler, S., Paez A., Rothberg M. (2010). 2009 Pandemic H1N1-associated Myocarditis in a Previously Healthy Adult. *Clin Microbiol Infect*, Jul 15. Vol.17(4), pp. 572-574.
- Heidenreich, PA., Eisenberg, MJ., Kee, LL. (1995). Pericardial effusion in AIDS. Incidence and survival. *Circulation*, Vol.92, pp. 3229-3234.
- Herskowitz, A., Willoughby, SB., Baughman, KL. (1992). Cardiomyopathy associated with antiretroviral therapy in patients with HIV infection: a report of six cases. *Ann Intern Med*, Vol.116, pp. 311-313.
- Hofman, P., Drisci, MD., Gibelin, P. (1993). Prevalence of toxoplasma myocarditis in patients with the acquired immunodeficiency syndrome. *Br Heart J* Vol.70, p. 376.
- Holladay, AO., Siegel, RJ., Schwartz, DA. (1992). Cardiac malignant lymphoma in acquired immune deficiency syndrome. *Cancer*, Vol.70, pp. 2203-2207.
- Hoover, DR., Saah, AJ., Bacellar, H. (1993). Clinical manifestations of AIDS in the era of pneumocystis prophylaxis. Multicenter AIDS Cohort Study. *N Engl J Med*, Vol.329, pp. 1922-1926.
- Hosenpud, JD., McAnulty, JH., Niles, NR. (1986). Unexpected myocardial disease in patients with life threatening arrhythmias. *Br Heart J*, Vol.56, pp. 55-61.
- Hufnagel, G., Pankuweit, S., Richter, A. (2000). The European Study of Epidemiology and Treatment of Cardiac Inflammatory Diseases (ESETCID): first epidemiological results. *Herz*, Vol.25, pp. 279-285.
- Hutchison, SJ. (1998). Acute rheumatic fever. *J Infect*, Vol.36, pp. 249-253.

- Imazio, M., Cecchi, E., Demichelis, B. (2008). Myopericarditis versus viral or idiopathic acute pericarditis. *Heart*, Vol.94, pp. 498-501.
- Isner, JM. & Chokshi, SK. (1991). Cardiovascular complications of cocaine. *Curr Probl Cardiol*, Vol.16, pp. 89-123.
- Jones, TD. (1944). The diagnosis of rheumatic fever. *JAMA*, Vol.126, p. 481.
- Kadirova, R., Kartoglu, HU., Strebel, PM. (2000). Clinical characteristics and management of 676 hospitalized diphtheria cases, Kyrgyz Republic,. *J Infect Dis*, 181 Suppl 1, pp. S110-115.
- Kanazawa, H., Hata, N., Yamamoto, E. (2004). Recurrent myocarditis of unknown etiology. *J Nippon Med Sch*, Aug. Vol.71(4), pp. 292-296.
- Keating, RJ., Bhatia, S., Amin, S. (2005). Hydroxychloroquine-induced cardiotoxicity in a 39-year-old woman with systemic lupus erythematosus and systolic dysfunction. *J Am Soc Echocardiogr*, Vol.18, p. 981.
- Khabbaz, Z., Grinda, JM., Fabiani, JN. (2007). Extracorporeal life support: an effective and noninvasive way to treat acute necrotizing eosinophilic myocarditis. *J Thorac Cardiovasc Surg*, Apr, Vol.133(4), pp. 1122-3, author reply pp. 1123-1124.
- Kilgallen, CM., Jackson, E., Bankoff, M. (1998). A case of giant cell myocarditis and malignant thymoma: a postmortem diagnosis by needle biopsy. *Clin Cardiol*, Vol.21, pp. 48-51.
- Killian, JG., Kerr, K., Lawrence, C. (1999). Myocarditis and cardiomyopathy associated with clozapine. *Lancet*, Vol.354, pp. 1841-1845.
- Kim, JS., Judson, MA., Donnino, R. (2009). Cardiac sarcoidosis. *Am Heart J*, Vol.157, p. 9.
- Kimball, SA., Janson, PA., LaRaia, PJ. (1989). Complete heart block as the sole presentation of Lyme disease. *Arch Intern Med*, Vol.149, p. 1897.
- Kindermann, I., Kindermann, M., Kandolf, R. (2008). Predictors of outcome in patients with suspected myocarditis. *Circulation*, Vol.118, pp. 639-648. [Erratum, *Circulation*, (2008). Vol.118(12), p. e493.]
- Kinney, EL., Monsuez, JJ., Kitzis, M. (1989). Treatment of AIDS-associated heart disease. *Angiology*, Vol.40, pp. 970-976.
- Kneen, R., Nguyen, MD., Solomon, T. (2004). Clinical features and predictors of diphtheritic cardiomyopathy in Vietnamese children. *Clin Infect Dis*, Vol.39, pp. 1591.
- Kotilainen, P., Lehtopolku, M., Hakanen, AJ. (2006). Myopericarditis in a patient with *Campylobacter* enteritis: a case report and literature review. *Scand J Infect Dis*, Vol.38(6-7), pp. 549-552.
- Kounis, NG., Zavras, GM., Soufras, GD. (1989). Hypersensitivity myocarditis. *Ann Allergy*, Vol.62, pp. 71-74.
- Kühl, U., Pauschinger, M., Noutsias, M. (2005). High prevalence of viral genomes and multiple viral infections in the myocardium of adults with "idiopathic" left ventricular dysfunction. *Circulation*, Vol.111, pp. 887-893.
- Kuhl, U., Pauschinger, M., Seeberg, B. (2005). Viral persistence in the myocardium is associated with progressive cardiac dysfunction. *Circulation*, Sep 27, Vol.112(13), pp. 1965-1970.
- Lafont, A., Wolff, M., Marche, C. (1987). Overwhelming myocarditis due to *Cryptococcus neoformans* in an AIDS patient. *Lancet*, Vol.2, pp. 1145-1146.
- Lewis, W. (1989). AIDS: cardiac findings from 115 autopsies. *Prog Cardiovasc Dis*. 32, pp. 207-215.
- Lewis, W., Lipsick, J., Cammarosano, C. (1985). Cryptococcal myocarditis in acquired immune deficiency syndrome. *Am J Cardiol*, Vol.55, p. 1240.



- Libman, E. & Sacks, B. (1924). A hitherto undescribed form of valvular and mural endocarditis. *Arch Intern Med*, Vol.33, pp. 701-737.
- Lieberman, EB., Hutchins, GM., Herskowitz, A. (1991). Clinicopathologic description of myocarditis. *J Am Coll Cardiol*, Vol.18, pp. 1617-1626.
- Loeffler, W. (1936). Endocarditis parietalis fibroplastica mit. Bluteosinophilie. *Schweiz Med Wochenschr*, Vol.17, pp. 817-820.
- Lorcerie, B., Boutron, MC., Portier, H. (1987). Pericardial manifestations of Lyme disease. *Ann Med Interne (Paris)*, Vol.138, p. 601.
- Lowry, PW. & Tompkins, LS. (1993). Nosocomial legionellosis: a review of pulmonary and extrapulmonary syndromes. *Am J Infect Control*, Vol.21, p. 21.
- Lumio, JT., Groundstroem, KW., Melnick, OB. Electrocardiographic abnormalities in patients with diphtheria: a prospective study. *Am J Med*, Vol.116, p. 78.
- Magnani, JW., Suk-Danik, HJ., Dec, GW. (2006). Survival in biopsy proven myocarditis: a long-term retrospective analysis of the histopathologic, clinical, and hemodynamic predictors. *Am Heart J*, Vol.151(2), pp. 463-470.
- Mahrholdt, H., Wagner, A., Deluigi, CC. (2006). Presentation, Patterns of Myocardial Damage, and Clinical Course of Viral Myocarditis. *Circulation*, Vol.114, pp. 1581-1590.
- Makaryus, AN., Revere, DJ., Steinberg, B. (2006). Recurrent reversible dilated cardiomyopathy secondary to viral and streptococcal pneumonia vaccine-associated myocarditis. *Cardiol Rev*, Jul-Aug, Vol.14(4), pp. e1-4.
- Mandell, BF. (1987). Cardiovascular involvement in systemic lupus erythematosus. *Semin Arthritis Rheum*, Vol.17, p. 126.
- Marboe, CC. & Fenoglio, JJ Jr. (1988). Pathology and natural history of human myocarditis. *Pathol Immunopathol Res*, Vol.7, pp. 226-239.
- Marin-Neto, JA., Marzullo, P., Marcassa, C. (1992). Myocardial perfusion abnormalities in chronic Chagas' disease as detected by thallium-201 scintigraphy. *Am J Cardiol*, Vol.69, p. 780.
- Marin-Neto, JA., Simões, MV., Maciel, BC. (2003). *Specific diseases: cardiomyopathies and pericardial diseases. Other cardiomyopathies. In: Evidence-Based Cardiology*, 2nd ed, Yusuf, S., Cairns, JA., Camm, AJ. (Eds), BMJ Books, London, p.718.
- Maron, BJ., Carney, KP., Lever, HM. (2003). Relationship of race to sudden cardiac death in competitive athletes with hypertrophic cardiomyopathy. *J Am Coll Cardiol*, Vol.41, p. 974.
- Maron, BJ., Doerer, JJ., Haas, TS. (2009). Sudden deaths in young competitive athletes: analysis of 1866 deaths in the United States, 1980-2006. *Circulation*, Vol.119, pp. 1085-1092.
- Martin, AB., Webber, S., Fricker, FJ. (1994). Acute myocarditis: rapid diagnosis by PCR in children. *Circulation*, Vol.90, pp. 330-339.
- Martin, RE. & Bates, JH. (2004). Atypical pneumonia. *Infect Dis Clin North Am*, Vol.5, p. 585.
- Martin, RW., Duffy, J., Engel, AG. (1990). The clinical spectrum of the eosinophilia-myalgia syndrome associated with L-tryptophan ingestion. Clinical features in 20 patients and aspects of pathophysiology. *Ann Intern Med*, Jul 15, Vol.113(2), pp. 124-134.
- Mason, JW., O'Connell, JB., Herskowitz, A. (1995). A clinical trial of immunosuppressive therapy for myocarditis. The Myocarditis Treatment Trial Investigators. *N Engl J Med*, Vol.333, pp. 269-275.
- Matsumori, A. (2005). Hepatitis C virus infection and cardiomyopathies. *Circ Res*, Vol.96, pp. 144-147.



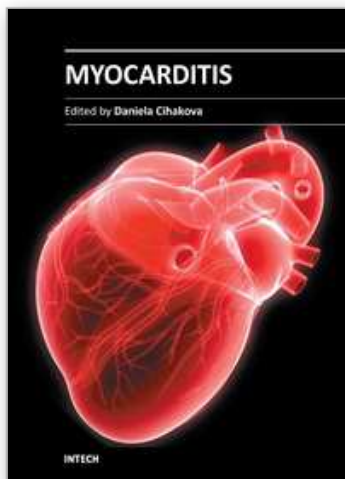
- Matsumori, A., Shimada, T., Chapman, NM. (2006). Myocarditis and heart failure associated with hepatitis C virus infection. *J Card Fail*, Vol.12, pp. 293-298.
- Matturri, L., Quattrone, P., Varesi, C. (1990). Cardiac toxoplasmosis in pathology of acquired immunodeficiency syndrome. *Panminerva Med*, Vol.32, pp. 194-196.
- Mavrogeni, S., Manoussakis, M., Spargias, K. (2008). Myocardial involvement in a patient with chlamydia trachomatis infection. *J Card Fail*, Vol.14(4), pp. 351-353.
- McAlister, HF., Klementowicz, PT., Andrews, C. (1989). Lyme carditis: an important cause of reversible heart block. *Ann Intern Med*, Vol.110, pp. 339-345.
- McCarthy, RE., Boehmer, JP., Hruban, RH. (2000). Long-term outcome of fulminant myocarditis as compared with acute (non-fulminant) myocarditis. *N Engl J Med*, Vol.342, pp. 690-695.
- McCully, RB., Cooper, LT., Schreiter, S. (2005). Coronary artery spasm in lymphocytic myocarditis: a rare cause of acute myocardial infarction. *Heart*, Vol.91, p. 202.
- McDonald, M., Currie, BJ., Carapetis, JR. (2004). Acute rheumatic fever: a chink in the chain that links the heart to the throat? *Lancet Infect Dis*, Vol.4, p. 240.
- McDonald, MI., Towers, RJ., Andrews, RM. (2006). Low rates of streptococcal pharyngitis and high rates of pyoderma in Australian aboriginal communities where acute rheumatic fever is hyperendemic. *Clin Infect Dis*, Vol.43, p. 683.
- Meira, ZM., Goulart, EM., Colosimo, EA. (2005). Long term follow up of rheumatic fever and predictors of severe rheumatic valvar disease in Brazilian children and adolescents. *Heart*, Vol.91, p. 1019.
- Mendoza, I., Camardo, J., Moleiro, F. (1986). Sustained ventricular tachycardia in chronic chagasic myocarditis: electrophysiologic and pharmacologic characteristics. *Am J Cardiol*, Vol.57, p. 423.
- Midei, MG., DeMent, SH., Feldman, AM. (1990). Peripartum myocarditis and cardiomyopathy. *Circulation*, Vol.81, pp. 922-928.
- Miller-Catchpole, R., Variakojis, D., Anastasi, J. (1989). The Chicago AIDS autopsy study: opportunistic infections, neoplasms, and findings from selected organ systems with a comparison to national data. Chicago Associated Pathologists. *Mod Pathol*, Vol.2, pp. 277-294.
- Moder, KG., Miller, TD., Tazelaar, HD. (1999). Cardiac involvement in systemic lupus erythematosus. *Mayo Clin Proc*, Vol.74, p. 275.
- Morgan, BC. (1963). Cardiac complications of diphtheria. *Pediatrics*, Vol.32, p. 549.
- Morgera, T., Di Lenarda, A., Dreas, L. (1992). Electrocardiography of myocarditis revisited: clinical and prognostic significance of electrocardiographic changes. *Am Heart J*, Vol.124, pp. 455- 467.
- Narula, J., Chopra, P., Talwar, KK. (1993). Does endomyocardial biopsy aid in the diagnosis of active rheumatic carditis? *Circulation*, Vol.88, pp. 2198-2205.
- Niedt, GW. & Schinella, RA. (1985). Acquired immunodeficiency syndrome. Clinicopathologic study of 56 autopsies. *Arch Pathol Lab Med*, Vol.109, p. 727.
- Noel, TP., Zabriskie, J., Macpherson, CN. (2005). Beta-haemolytic streptococci in school children 5-15 years of age with an emphasis on rheumatic fever, in the tri-island state of Grenada. *West Indian Med J*, Vol.54, p. 22.
- Nosanchuk, JD. (2002). Fungal myocarditis. *Front Biosci*, Jun 1, Vol.7, pp. 1423-1438.
- Oliveira-Filho, J., Viana, LC., Vieira-de-Melo, RM. (2005). Chagas disease is an independent risk factor for stroke: baseline characteristics of a Chagas Disease cohort. *Stroke*, Vol.36, p. 2015.

- Palecek, T., Kuchynka, P., Hulinska, D. (2010). Presence of *Borrelia burgdorferi* in endomyocardial biopsies in patients with new-onset unexplained dilated cardiomyopathy. *Med Microbiol Immunol*, May, Vol.199(2), pp. 139-143.
- Palella, FJ Jr., Delaney, KM., Moorman, AC. (1998). Declining morbidity and mortality among patients with advanced human immunodeficiency virus infection. HIV Outpatient Study Investigators. *N Engl J Med*, Vol.338, pp. 853-860.
- Pauschinger, M., Doerner, A., Kuehl, U. (1999). Enteroviral RNA replication in the myocardium of patients with left ventricular dysfunction and clinically suspected myocarditis. *Circulation*, Vol.99, pp. 889-895.
- Paz, A. & Potasman, I. (2002). Mycoplasma-associated carditis. Case reports and review. *Cardiology*, Vol.97(2), pp. 83-88.
- Peeters, AJ., Dijkmans, BAC., Sedney, MI. (1990). Lyme borreliosis: A hidden cause of heart block in pacemaker treated males. *IV International Conference on Lyme Borreliosis*, Stockholm, Sweden.
- Peng, SK., French, WJ., Pelikan, PC. (1989). Direct cocaine cardiotoxicity demonstrated by endomyocardial biopsy. *Arch Pathol Lab Med*, Vol.113, pp. 842-845.
- Pinto, AY., Valente, SA., Valente Vda, C. (2004). Emerging acute Chagas disease in Amazonian Brazil: case reports with serious cardiac involvement. *Braz J Infect Dis*, Vol.8, p. 454.
- Pursnani, A., Yee, H., Slater, W. (2009). Hypersensitivity myocarditis associated with azithromycin exposure. *Ann Intern Med*, Vol.150, p. 225.
- Rassi, A Jr., Rassi, SG., Rassi, A. (2001). Sudden death in Chagas' disease. *Arq Bras Cardiol*, Vol.76, p. 75.
- Rassi Júnior, A., Gabriel Rassi, A., Gabriel Rassi, S. (1995). Ventricular arrhythmia in Chagas disease. Diagnostic, prognostic, and therapeutic features. *Arq Bras Cardiol*, Vol.65, p. 377.
- Reuhl, J., Schneider, M., Sievert, H. (1997). Myocardial sarcoidosis as a rare cause of sudden cardiac death. *Forensic Sci Int*, Vol.89, p. 145.
- Rizeq, MN., Rickenbacher, PR., Fowler, MB. (1994). Incidence of myocarditis in peripartumcardiomyopathy. *Am J Cardiol*, Vol.74, pp. 474-477.
- Salles, G., Xavier, S., Sousa, A. (2003). Prognostic value of QT interval parameters for mortality risk stratification in Chagas' disease: results of a long-term follow-up study. *Circulation*, Vol.108, p. 305.
- Samlowski, WE., Ward, JH., Craven, CM. (1989). Severe myocarditis following high-dose interleukin-2 administration. *Arch Pathol Lab Med*, Vol.113, pp. 838-841.
- Samuel, J., Oliveira, M., Correa De Araujo, RR. (1983). Cardiac thrombosis and thromboembolism in chronic Chagas' heart disease. *Am J Cardiol*, Vol.52, pp. 147-151.
- Sarda, L., Colin, P., Boccara, F. (2001). Myocarditis in patients with clinical presentation of myocardial infarction and normal coronary angiograms. *J Am Coll Cardiol*, Vol.37, p. 786.
- Sato, Y., Matsumoto, N., Kunimasa, T. (2008). Multiple involvements of cardiac sarcoidosis in both left and right ventricles and papillary muscles detected by delayed-enhanced magnetic resonance imaging. *Int J Cardiol*, Vol.130, p. 288.
- Schattner, A. & Liang, MH. (2003). The cardiovascular burden of lupus: a complex challenge. *Arch Intern Med*, Vol.163, p. 1507.
- Schofield, CJ. & Dias, JC. (1991). A cost-benefit analysis of Chagas disease control. *Mem Inst Oswaldo Cruz*, Vol.86, p. 285.

- Schwartz, J., Sartini, D., Huber, S. (2004). Myocarditis susceptibility in female mice depends upon ovarian cycle phase at infection. *Virology*, Vol.330, pp. 16-23.
- Sekiguchi, M., Numao, Y., Imai, M. (1980). Clinical and histopathological profile of sarcoidosis of the heart and acute idiopathic myocarditis. Concepts through a study employing endomyocardial biopsy. I. Sarcoidosis. *Jpn Circ J*, Vol.44, p. 249.
- Sekiguchi, M., Yazaki, Y., Isobe, M. (1996). Cardiac sarcoidosis: diagnostic, prognostic, and therapeutic considerations. *Cardiovasc Drugs Ther*, Vol.10, pp. 495-510.
- Silver, MA., Macher, AM., Reichert, CM. (1984). Cardiac involvement by Kaposi's sarcoma in acquired immune deficiency syndrome (AIDS). *Am J Cardiol*, Vol.53, pp. 983-985.
- Sliwa, K., Fett, J., Elkayam, U. (2006). Peripartum cardiomyopathy. *Lancet*, Vol.368, pp. 687-693.
- Smedema, JP., Snoep, G., van Kroonenburgh, MP. (2005). Cardiac involvement in patients with pulmonary sarcoidosis assessed at two university medical centers in the Netherlands. *Chest*, Vol.128, p. 30.
- Soejima, K. & Yada, H. (2009). The work-up and management of patients with apparent or subclinical cardiac sarcoidosis: with emphasis on the associated heart rhythm abnormalities. *J Cardiovasc Electrophysiol*, Vol.20, p. 578.
- Soodini, G. & Morgan, JP. (2001). Can cocaine abuse exacerbate the cardiac toxicity of human immunodeficiency virus? *Clin Cardiol*, Vol.24, pp. 177-181.
- Sousa, AC., Marin-Neto, JA., Maciel, BC. (1988). Systolic and diastolic dysfunction in the indeterminate, digestive and chronic cardiac forms of Chagas' disease. *Arq Bras Cardiol*, Vol.50, p. 293.
- Spear, GS. (1995). Eosinophilic explant carditis with eosinophilia: ? hypersensitivity to dobutamine infusion. *J Heart Lung Transplant*, Vol.14, pp. 755-760.
- Spodick, DH. (1995). Eosinophilic myocarditis. *Mayo Clin Proc*, Vol.72, p. 996.
- Stanek, G., Klein, J., Bittner, R. (1990). Isolation of *Borrelia burgdorferi* from the myocardium of a patient with longstanding cardiomyopathy. *N Engl J Med*, Vol.322, pp. 249-252.
- Steere, AC., Batsford, WP., Weinberg, M. (1980). Lyme carditis: cardiac abnormalities of Lyme disease. *Ann Intern Med*, Vol.93, p. 8.
- Strain, JE., Grose, RM., Factor, SM. (1983). Results of endomyocardial biopsy in patients with spontaneous ventricular tachycardia but without apparent structural heart disease. *Circulation*, Vol.68, pp. 1171-1181.
- Sugrue, DD., Holmes, DR Jr., Gersh, BJ. (1984). Cardiac histologic findings in patients with life-threatening ventricular arrhythmias of unknown origin. *J Am Coll Cardiol*, Vol.4, pp. 952-957.
- Takkenberg, JJ., Czer, LS., Fishbein, MC. (2004). Eosinophilic myocarditis in patients awaiting heart transplantation. *Crit Care Med*, Vol.32, p. 714.
- Taliercio, CP., Olney, BA., Lie, JT. (1985). Myocarditis related to drug hypersensitivity. *Mayo Clin Proc*, Vol.60, pp. 463-468.
- Tershakovec, AM., Frank, I., Rader, D. (2004). HIV-related lipodystrophy and related factors. *Atherosclerosis*, Vol.174, p. 1.
- Theleman, KP., Kuiper, JJ., Roberts, WC. (2001). Acute myocarditis (predominately lymphocytic) causing sudden death without heart failure. *Am J Cardiol*, Vol.88, p. 1078.
- Thomsen, TK. & Eriksson, T. (1999). Myocardial sarcoidosis in forensic medicine. *Am J Forensic Med Pathol*, Vol.20, p. 52.
- Tompkins, LS., Roessler, BJ., Redd, SC. (1988). *Legionella* prosthetic-valve endocarditis. *N Engl J Med*, Vol.318, p. 530.

- Twagirumukiza, M., Nkeramihigo, E., Seminega, B. (2007). Prevalence of dilated cardiomyopathy in HIV-infected African patients not receiving HAART: a multicenter, observational, prospective, cohort study in Rwanda. *Curr HIV Res*, Vol.5, p. 129.
- Ukimura, A., Izumi, T., Matsumori, A. (2010). Clinical Research Committee on Myocarditis Associated with 2009 Influenza A (H1N1) Pandemic in Japan organized by Japanese Circulation Society. Collaborators (16). A national survey on myocarditis associated with the 2009 influenza A (H1N1) pandemic in Japan. *Circ J*, Oct, Vol.74(10), pp. 2193-9.
- van der Linde, MR., Crijns, HJ., Lie, KI. (1989). Transient complete AV block in Lyme disease. Electrophysiologic observations. *Chest*, Vol.96, pp. 219.
- Vasan, RS., Shrivastava, S., Vijayakumar, M. (1996). Echocardiographic evaluation of patients with acute rheumatic fever and rheumatic carditis. *Circulation*, Vol.94, pp. 73-82.
- Vignola, PA., Aonuma, K., Swaye, PS. (1984). Lymphocytic myocarditis presenting as unexplained ventricular arrhythmias: diagnosis with endomyocardial biopsy and response to immunosuppression. *J Am Coll Cardiol*, Vol.4, pp. 812-819.
- Vlay, SC. (1993). *Cardiac manifestations in Lyme disease*, Coyle, P (Ed), Mosby-Yearbook, St Louis.
- Vlay, SC., Dervan, JP., Elias, J. (1991). Ventricular tachycardia associated with Lyme carditis. *Am Heart J*, Vol.121, p. 1558.
- Wengrower, D., Knobler, H., Gillis, S. (1984). Myocarditis in tick-borne relapsing fever. *J Infect Dis*, Vol.149, p. 1033.
- Wesslen, L., Pahlson, C., Lindquist, O. (1996). An increase in sudden unexpected cardiac deaths among young Swedish orienteers during 1979-1992. *Eur Heart J*, Vol.17, pp. 902-910
- Wu, L., Cooper, LT., Kephart, G. (2002). The Eosinophil in Cardiac Disease. In: Cooper L, ed. *Myocarditis: From Bench to Bedside*, Humana Press, Totowa, NJ, p. 437.
- Yazaki, Y., Isobe, M., Hiramitsu, S. (1998). Comparison of clinical features and prognosis of cardiac sarcoidosis and idiopathic dilated cardiomyopathy. *Am J Cardiol*, Vol.82, pp. 537-40.
- Yazaki, Y., Isobe, M., Hiroe, M. (2001). Prognostic determinants of long-term survival in Japanese patients with cardiac sarcoidosis treated with prednisone. *Am J Cardiol*, Vol.88, p. 1006.
- Yoshida, Y., Morimoto, S., Hiramitsu, S. (1997). Incidence of cardiac sarcoidosis in Japanese patients with high-degree atrioventricular block. *Am Heart J*, Vol.134, p. 382.
- Zimmerman, S., Adkins, D., Graham, M. (1994). Irreversible, severe congestive cardiomyopathy occurring in association with interferon alpha therapy. *Cancer Biother*, Vol.9, pp. 291-299.





## **Myocarditis**

Edited by Dr. Daniela Cihakova

ISBN 978-953-307-289-0

Hard cover, 428 pages

**Publisher** InTech

**Published online** 19, October, 2011

**Published in print edition** October, 2011

Myocarditis, the inflammation of the heart muscle, could be in some cases serious and potentially fatal disease. This book is a comprehensive compilation of studies from leading international experts on various aspects of myocarditis. The first section of the book provides a clinical perspective on the disease. It contains comprehensive reviews of the causes of myocarditis, its classification, diagnosis, and treatment. It also includes reviews of Perimyocarditis; Chagas's™ chronic myocarditis, and myocarditis in HIV-positive patients. The second section of the book focuses on the pathogenesis of myocarditis, discussing pathways and mechanisms activated during viral infection and host immune response during myocarditis. The third, and final, section discusses new findings in the pathogenesis that may lead to new directions for clinical diagnosis, including use of new biomarkers, and new treatments of myocarditis.

### **How to reference**

In order to correctly reference this scholarly work, feel free to copy and paste the following:

Rafid Fayadh Al-Aqeedi (2011). Clinical Presentation, Myocarditis, Dr. Daniela Cihakova (Ed.), ISBN: 978-953-307-289-0, InTech, Available from: <http://www.intechopen.com/books/myocarditis/clinical-presentation>

**INTECH**  
open science | open minds

### **InTech Europe**

University Campus STeP Ri  
Slavka Krautzeka 83/A  
51000 Rijeka, Croatia  
Phone: +385 (51) 770 447  
Fax: +385 (51) 686 166  
[www.intechopen.com](http://www.intechopen.com)

### **InTech China**

Unit 405, Office Block, Hotel Equatorial Shanghai  
No.65, Yan An Road (West), Shanghai, 200040, China  
中国上海市延安西路65号上海国际贵都大饭店办公楼405单元  
Phone: +86-21-62489820  
Fax: +86-21-62489821



© 2011 The Author(s). Licensee IntechOpen. This is an open access article distributed under the terms of the [Creative Commons Attribution 3.0 License](https://creativecommons.org/licenses/by/3.0/), which permits unrestricted use, distribution, and reproduction in any medium, provided the original work is properly cited.

IntechOpen

IntechOpen