

# We are IntechOpen, the world's leading publisher of Open Access books Built by scientists, for scientists

6,900

Open access books available

185,000

International authors and editors

200M

Downloads

Our authors are among the

154

Countries delivered to

TOP 1%

most cited scientists

12.2%

Contributors from top 500 universities



WEB OF SCIENCE™

Selection of our books indexed in the Book Citation Index  
in Web of Science™ Core Collection (BKCI)

Interested in publishing with us?  
Contact [book.department@intechopen.com](mailto:book.department@intechopen.com)

Numbers displayed above are based on latest data collected.  
For more information visit [www.intechopen.com](http://www.intechopen.com)



## Drug Induced Small Vessel Vasculitis

Jorge Daza Barriga<sup>1</sup>, Mónica Manga Conte<sup>2</sup>  
and Arturo Valera Agámez<sup>3</sup>

<sup>1</sup>*Universidad Libre – Barranquilla, Professor; Neurologist; Neurology Unit  
Chief, Hospital Universitario CARI ESE; Neuroscience Group Member  
Caribbean, Universidad Simón Bolívar,*

<sup>2</sup>*Internal Medicine, Visalia Medical Clinic and Kaweah  
Delta District Hospital, California,*

<sup>3</sup>*Universidad Libre - Barranquilla, Hospital Universitario  
CARI ESE, Internal Medicine,  
<sup>1,3</sup>Colombia,  
<sup>2</sup>USA*

### 1. Introduction

Vasculitis is the inflammation of a blood or lymph vessel (Merriam – Webster Online Dictionary, 2011). Vasculitis is a broad term used to include a group of syndromes characterized by inflammation, fibrinoid necrosis or formation of granulomas in the blood vessel walls. These can be localized or multifocal, and have different causes and manifestations, depending on the location, size, presence or absence of necrosis. The latter can affect different organs. The vasculitides can be classified as primary or secondary, and are usually a diagnostic challenge for the physician. An open mind and great deal of suspicion is required. Once vasculitis is suspected, a thorough and systematic approach is mandatory. Laboratory tests, imaging studies, and, on occasion, tissue biopsies will help achieve an accurate diagnosis. Its etiology is also diverse (González-Gay et al., 2005) and hence provides the patient with an efficient and appropriate treatment.

Recent advances in technology, with more complete serologic, histochemical, and detailed images, have helped in understanding and differentiating vasculitis from each other. This has resulted in a classification based on etiology, as well as the identification of possible prevention techniques, and strategic treatments.

Medications can induce different side effects, including vasculitis. There are two recognized presentations: Drug Induced Lupus (DIL), and Drug Induced Vasculitis (DIV). These are difficult to separate, and are usually superimposed. Among the latter, one of the most well recognized is Antineutrophil cytoplasmic antibody (ANCA) associated autoimmune disease induced by antithyroid drugs (Aloush V et al., 2006; Bonaci-Nikolic B et al, 2005; Wiik, 2005; Pillinger & Staud, 2006). It has been proposed that neutrophil myeloperoxidase (MPO) reacts with propylthiouracil (PTU), transforming this in a sulfa form, which initiates a chain reaction with activation of T lymphocytes, and B lymphocytes that induces vascular inflammation (Aloush V et al., 2006, Pillinger & Staud, 2006). It is interesting to note that, despite the elimination of PTU, the patient may continue having ANCA, and relapses of the

disease (Bonaci-Nikolic B et al., 2005, Aloush V et al., 2006, Bonaci-Nikolic B et al., 2005, Pillinger & Staud, 2006, Choi HK et al., 2000).

This article will focus on the historic evolution of the recognition of vasculitides as an autoimmune entity. We will also describe its pathophysiology, clinical presentation and treatment; paying special attention to drug induced vasculitides. Medications can induce different reactions, from local to systemic ones, including vasculitis. The skin and subcutaneous tissue are common targets, producing rashes and skin discolorations, usually associated with pruritus, edema, and, on occasion, ulceration and necrosis. There might be concomitant arthralgias and myalgias. In these cases, the discontinuation of the medication is recommended, and immunosuppressive therapies are usually required.

## 2. Epidemiology of small vessel vasculitis

Vasculitides are rare entities, and trustable epidemiologic data is limited. An annual incidence of cutaneous forms in 38.6 cases per million people has been estimated. It is usually most common in women (50.4 cases per million), than in men (26 cases per million). In any case, these are approximations, and likely underestimated, because some of the presentations like leucopenia are considered separately (Watts RA et al., 1998, Watts RA et al., 2000, Tidman, M et al., 1998).

The first publications regarding drug induced vasculitis described reactions by sulfadiazine and hydralazine, and referred to a DIL (Hofman BJ, 1945; Alarcon D, 1967; Scott DGI, 2000). In 1953 it was demonstrated that 7% of patients that took hydralazine for the treatment of hypertension develop DIL. These patients present fever, arthralgias, arthritis, myalgias, and serositis involving the pleura and pericardium. It is more common after prolonged use and in patients with advanced age. Antinuclear antibodies (ANA) are usually positive with a homogenous pattern, and autoantibodies to the nucleosome subunit (H2AH2B)-DNA. These patients rarely develop double stranded DNA antibodies (anti-DNA), which usually happen in DIL by sulphasalazine. The latter patients are usually carriers of HLA DR 0301, which is a recognized predisposing factor for DIL (Bonaci-Nikolic B et al., 2005, Morrow JD et al., 1953, Yung & Richardson 1994).

There are different ANA that are responsible for DIL (Yung & Richardson, 1994; Burlingame & Rubin, 1996; Ayer LM, 1994). These can be directed against MPO, human leukocyte elastase (HLE), cathepsin G, lactoferrin and azurocidine, but they all have in common that they affect the neutrophils and monocytes in the perinuclear area (Jennette JC, 2000).

Medications that cause DIL, may also induce DIV, and in both cases there might be compromise of small vessels, the skin, synovial tissues, kidneys and lungs. These further complicates the differentiation between the two (Aloush V et al., 2006, Bonaci-Nikolic B et al., 2005, Pillinger & Staud, 2006, Choi HK et al, 2000).

There are two major antigens for the ANCA: MPO and proteinase (PR3) (Zhao MH, 1995). The combination of PR3-ANCA with normal neutrophils fixed with acetone produces a typical cytoplasmic discoloration, and hence the term C-ANCA. The MPO-ANCA induces a perinuclear change known as P-ANCA (Westman K, et al, 2003).

Other drugs that cause DIL and DIV include, but are not limited to: carbamazepine, chlorpromazine, isoniazide, methimazole, alpha methyldopa, minocycline, phenytoin, procainamide and quinidine (Ullman S. et al, 2004). Similar findings have been described with Etanercept.

ANCA are found also in other conditions, where its role it is not well understood (DeBant et al, 2005), for example: Ulcerative Colitis, Crohn's disease and HIV (Doyle & Cuellar, 2003; Mekel PA, 2001).

### 3. Historical evolution

The first descriptions were made by Claudio Galeno, when he concluded that some of the peripheral arterial aneurysms that he found were of iatrogenic nature (Litton & Resurh, 1978). These are well written in his book "De tumoribus pariter naturam". Later, in the XVI century Montpellier described vasculitis of infectious origin, specifically related to syphilis (Saporta A, 1624, Cited by Garrison & Morton, 1970). But it was only until the XIX century that vasculitis was recognized as a separate entity (Iglesias et al, 2002). In 1801, William Heberden started describing a vascular purpura (Heberden, 1931). His studies were confirmed and completed in 1837 by Schönlein (Schönlein JL, 1837) and in 1874 by Eduard Henoch (Henoch E, 1868). In 1862, Karl Von Rokitansky proposed that the origin of atherosclerosis is the result of the deposit of material that came from the blood, which subsequently induces arteritis or inflammation (Rokitansky K, 1852). He established that this inflammation started in the external layer or adventitia (Rokitansky K, 1852). The concept of vasculitis was consolidated after the pathological analysis by Rudolf Maier and Adolf Kussmaul (Kussmaul A, 1866). This was the first description and recognition of the polyarteritis nodosa. Around 1827, an association between purpura and abdominal pain was determined. The term Henoch-Schönlein purpura was given (Henoch E, 1868).

It was in the XX century that Osler described a form of vasculitis that included purpura and visceral involvement (Glanzman E, 1920). This was later named Systemic Lupus Erythematosus (SLE). Wegener's granulomatosis was described in 1931. But it was only until 1948 that Douglas Gaaidner proposed that Henoch-Schönlein purpura (Klinge F, 1933), acute nephritis, rheumatic fever and polyarteritis nodosa had a common etiology and were associated to an antibody-antigen reaction that occurred at the blood vessel level. Subsequent descriptions of different cases of Wegener's granulomatosis, Churg Strauss syndrome, Kawasaki, Henoch Schönlein, Behcet's, RA, Takayasu's, temporal arteritis and SLE were done (Wegener F, 1990; Hunder GG et al, 1990).

The first descriptions of DIL were recorded in 1945 with the use of sulfadiazine (Hoffman BJ, 1945); and in 1953 with hydralazine (Alarcon Segovia D, 1967; Ullman S et al, 1974; Yung & Richardson, 1994). The presentation was similar to the one of Systemic Lupus Erythematosus: fever, arthritis, myalgias, and serositis with involvement of the pericardium and pleura (Yung & Richardson, 1994).

In 1970, it was determined that DIV and DIL were usually observed in people with HLA DR0301 (Mielke et al, 1993; Gunnarsson I, 2000).

It was in 1973 when it was established that immunosuppressive therapy improved the prognosis of patients with Wegener's granulomatosis (Fauci & Wolff, 1993).

Around 1990, the classification criterion of different vasculitis was established, as well as its therapeutic and diagnostic approach (Churg J, 1991). However, it was in 1994 when simple nomenclature was made. This classified the vasculitis in big vessel vasculitis (giant cell arteritis and Takayasu's); median vessel vasculitis (Polyarteritis nodosa); and small vessel vasculitis (Wegener's granulomatosis, Churg Strauss syndrome, microscopic Polyangiitis, Henoch Schönlein purpura, Vasculitis induced by Cryoglobulins) (Jannette et al, 1994).

Vessel size	Presence of Granuloma.	No Granuloma
Large	Temporal arteritis.	Polyarteritis Nodosa.
	Takayasu’s arteritis.	
Medium		Kawasaki’s disease
Small	Wegener’s Granulomatosis	Microscopic Polyangitis
	Churg Strauss Syndrome	Henoch Schonlein purpura
		Cutaneous leukocytolastic

Table 1. Classification of vasculitis depending on the presence or not of granulomas, by Jennette et al 1994

4. Clinical presentation

Clinical manifestations vary as well as the organs affected. In general, it depends on the cause, localization, the size of the vessel affected, and the degree of ischemia. Symptoms commonly found are: purpura, erythema, urticaria, vesiculobullous lesions, superficial ulcers, splinter hemorrhages, scleritis, episcleritis, uveitis, neutrophilic granulomatous dermatitis, glomerulonephritis, gastric colic, pulmonary hemorrhage, constitutional symptoms. When the compromise is in the middle of medium-caliber vessels, we find subcutaneous nodules, deep ulcers, livedo reticularis, digital gangrene, mononeuritis, aneurysms, and ischemic lesions (Iglesias Gamarra A, et al, 2006).

As we have stated, the most common skin manifestations are: Urticaria, edema, petequias, exanthema, livedo reticularis, purpura, vesicles or ulcerations. The distribution varies, affecting the extremities, trunk or both (Iglesias Gamarra A, et al, 2006).

If there is damage of the muscular vessels, a myopathy may develop with myalgia, weakness and elevation of CK and LDH (Iglesias Gamarra A, et al, 2006).

It is common to see a prodromal presentation of non specific symptoms like general malaise, weight loss, fever and night sweats. Specific symptoms develop once a major organ is affected. For example, in Wegener’s granulomatosis, there is compromise of the upper and lower airways and the kidneys. Similarly, the kidneys are affected in microscopic polyangitis. This results in hematuria, proteinuria and kidney failure. The lower airways affection may result in pulmonary hemorrhage, which is fatal if not recognized and treated in a timely manner (Iglesias Gamarra A, et al, 2006).

In Churg Strauss the clinical presentation is often mistaken as asthma exacerbations. Chest x rays show transitory pulmonary infiltrates, and eosinophils are very elevated in blood. There might appear concomitant cutaneous vasculitis, as well as gastrointestinal abnormalities with abdominal pain and symptoms that can be confused with irritable bowel syndrome (Iglesias Gamarra A. et al, 2006).

Polyarteritis nodosa is less frequent, but more severe and devastating. It causes ischemic infarcts of various organs, which can induce to hemorrhage, specially the in bowel, pancreas and gallbladder. Urinary tract compromise is seen in 50% of the patients, but it is uncommon to have severe kidney insufficiency (Jennette JC, 1994).

In general, the gold standard diagnostic test for vasculitis is tissue biopsy that demonstrates fibrinoid necrosis with vascular inflammation. Common sources are the nose, lungs, skin or kidneys. Serological tests are also important in helping define the type of vasculitis (Iglesias Gamarra A, et al, 2006; Jennette JC, 1994).

In drug induced vasculitis, small vessels are usually affected. The histopathological findings are similar to other types of vasculitis. And this is usually considered a diagnosis of exclusion. Non specific symptoms are present as described above, including fever, weight loss, arthralgias and myalgias. Skin changes are frequently seen, like purpuric lesions, vesicles and bullae, urticaria and splinter hemorrhages. More severe cases may present with glomerulonephritis, alveolar hemorrhage, uveitis and scleritis. The syndrome might resolve in weeks after the drug has been discontinued. However in rare cases it might become persistent, especially in those with ANCA positive. There are no specific laboratory findings, eosinophilia is present in 79% of cases, ESR and CRP are commonly elevated. Hence, biopsy is mandatory (Jennette JC, 1994).

## 5. Laboratory findings

1. Complete blood counts and erythrocyte sedimentation rate: Anemia is a common finding, usually normocytic, normochromic. Platelets are usually elevated, as is ESR. White blood cell counts are of extreme importance, since leucopenia is usually the limiting factor with immunosuppression.
2. Chemistries: To assess renal (BUN, creatinine, eGFR), hepatic (Liver function tests) and muscular (CK, aldolase, LDH) compromise.
3. Creatinine is used to evaluate kidney function. A urinalysis is required to diagnose glomerular involvement, in which case proteinuria and hematuria are found. Kidney function is also a prognosis factor.
4. Chest X rays, to look for lung involvement or pulmonary nodules.
5. Electromyography (EMG) to assess neuropathy and neuritis.
6. ANCA: Anti PR3 and anti MPO are present in 90% of the Wegener's granulomatosis.
7. Cryoglobulins and complement levels (C3 and C4).
8. Hepatitis B, and C, which might be the underlying cause of cryoglobulins.
9. Angiograms to evaluate vascular compromise in Takayasu's arthritis.

## 6. Histopathology

There is an inflammatory response, manifested as a cellular infiltration with subsequent wall vessel damage. Inflammation results in leukocytosis, and may end in vascular necrosis. When the latter occurs and becomes chronic, granulomas are usually present.

Fibrinoid necrosis is characterized by replacement of the vascular wall by eosinophils, fibrinogen deposits, immunoglobulins. In general, there is leucocyte destruction, but lymphocytes might also be affected.

This results in immunoproliferative vasculitis. All the above findings make biopsy necessary. The skin, respiratory tract (either superior or inferior) and kidneys are the most frequently biopsied. Approximately 20% of cases of cutaneous vasculitis represent an adverse drug eruption and most will represent so-called hypersensitivity vasculitis (CLA) and exhibit a superficial dermal, small-vessel neutrophilic vasculitis or lymphocytic vasculitis (Carlson & Chen, 2006; Carlson & Chen, 2007). Identification of tissue eosinophilia in these biopsies is a clue to a drug etiology (Bahrami S, 2006). Pharmacological classes involved in drug-induced vasculitis are: 1. an ANCA-associated group, such as propylthiouracil, hydralazine, allopurinol, minocycline, penicillamine, and phenytoin; 2. an ANCA-negative group, such as colony-stimulating factors, isotretinoin, and methotrexate

(Holder SM et al, 2002). Identifying the offending drug is the most important aspect of treatment as its discontinuation is followed by a rapid improvement in the vasculitis in many cases.

## 7. Small vessel vasculitis

Small vessel vasculitis comprises a heterogeneous group of diseases and syndromes. To facilitate its understanding, they are classified as follows:

1. Immune complex mediated:
  - 1.1 GoodPasture's.
  - 1.2 Leucocytoclastic angitis.
  - 1.3 Henoch Schonlein Purpura.
  - 1.4 Urticarial Crioglobulinemia.
2. ANCA associated vasculitis:
  - 2.1 Wegener's granulomatosis.
  - 2.2 Microscopic polyangitis.
  - 2.3 Churg Strauss.
  - 2.4 Kidney vasculitis.
  - 2.5 Secondary vasculitis.
3. Miscellaneous:
  - 3.1. Connective tissue disorders (Rheumatoid vasculitis, SLE, Sjogren and inflammatory myopathies).
  - 3.2 Paraneoplastic syndromes.
  - 3.3 Infections.
  - 3.4 Drug induced.

## 8. Drug induced vasculitis mechanism

As stated above, the mechanism with which a medication can induce a vasculitis varies, and different ones have been established. The presentation of the disease also differs depending not only on the type, but also on genetic factors, geographic regions, age, sex, and race.

Clinically it is difficult to differentiate between drug induced and small vessel vasculitis. Skin manifestations are the most common in DIV, which ranges from a maculopapular rash to a palpable purpura. There might be concomitant arthralgias, arthritides, kidney and liver compromise, as well as central nervous system affection (Molina J et al, 2000).

The duration of the process is also variable. It may resolve in a few weeks after discontinuation of the culprit agent, or persist afterwards. This is especially true in ANCA positive cases.

Again, DIV is a diagnosis of exclusion, and can only be made once other types of vasculitis, infections and malignancy have been ruled out (Jennette & Falk, 1997). There is no diagnostic test available. Eosinophilia is present in 79% of the cases (Jennette & Falk, 1997; Calabrese LH et al, 1990). A biopsy is usually required, and the list of medications taken in the last 6 months reviewed.

Treatment includes the discontinuation of the medication and immunosuppressive agents.

Patients with idiopathic vasculitis, more commonly develop ANCA to one neutrophil antigen, whereas in DIV it is usual to find several (Calabrese LH et al, 1990, Savige J et al 2000).

When used, anti-TNF agents can induce DIV. Cases have been described of antibodies against double stranded DNA when infliximab is used (Buttman et al, 2005).

Procainamide and Hydralazine share a structure similar to the nucleosome, which can induce an immunogenic reaction. This results in the formation of antibodies similar to the ones found in SLE. These drugs can also cause a direct toxicity by its metabolics, which inhibit DNA methyltransferase and induces autoimmunity (Carlson et al, 2005).

Interferon is a naturally found protein in the human immune system. There are three known types: alpha, gamma and lambda. The production of interferon is induced by interleukins and TNF. Different types of cells produce interferon: T and B cells, macrophages, fibroblasts, endothelial cells and osteoblasts. They constitute an important mechanism of defense against viruses, stimulating macrophages and natural killer cells. In synthesis, interferon prevents the viral replication and induces the destruction of infected cells. It was in the 80's when using DNA recombinant technology that interferon was produced massively. This is commonly used in the treatment of certain cancers, hepatitis C and B, as well of multiple sclerosis among others. It is given as an intramuscular injection. Frequent adverse reactions include: flu like symptoms, fever, myalgia, general malaise, headaches, and rarely seizures. Depression is also observed (Wiik, A 2008; O'Sullivan et al 2006). Most of the side effects are reversible, once treatment is completed (O'Sullivan et al 2006, Coppola G, 2006). Autoimmune side effects are rare. The induction of antithyroglobulins, sarcoidosis, diabetes and arthritis has been described. Buttmann proposed three possible mechanisms (Coppola G, 2006, Buttmann et al, 2005):

1. Quimiotactic effect of the immune system cells.
2. Direct effect over immune cells.
3. Indirect effect over immune cells through induction of proinflammatory substances.

## 9. Therapeutic approach

The conventional treatment of systemic vasculitis was introduced by Wolfe and Fauci in the 1970's with the use of cyclophosphamide and steroids (Fauci & Wolff, 1973). This consists of a year of induction with cyclophosphamide and 4 weeks of pulse dose steroids. After the initial 4 weeks, the steroids are gradually tapered. However, the toxicity of oral cyclophosphamide is high, with a mortality rate ranging from 14 - 20%. Common side effects are Myelodysplastic syndromes (8%), Neoplasia (4.5%), severe infections (26%) (Hogan SL, 2005; Koldingsnes & Nossent H, 2002; Mukhtyar C, 2009).

Due to the above, new strategies have been proposed with the purpose of reducing the overall accumulation. Currently, the parenteral approach is more commonly used with a dose of 0.6 mg/m<sup>2</sup> (Reinhold-Keller et al, 2000).

Mycophenolate mofetil (MMF) is an alternative. It is an immunosuppressive agent; inosine monophosphate dehydrogenase (IMPDH) 23 inhibitor (Huang Y, 2005). MMF is rapidly absorbed following oral administration and hydrolyzed to form MPA, which is the active metabolite. MPA is a potent, selective, uncompetitive, and reversible inhibitor of inosine monophosphate dehydrogenase (IMPDH), and therefore inhibits the de novo pathway of guanosine nucleotide synthesis without incorporation into DNA. Because T- and B-lymphocytes are critically dependent for their proliferation on de novo synthesis of purines, whereas other cell types can utilize salvage pathways, MPA has potent cytostatic effects on

lymphocytes. MPA inhibits proliferative responses of T- and B-lymphocytes to both mitogenic and allospecific stimulation. The addition of guanosine or deoxyguanosine reverses the cytostatic effects of MPA on lymphocytes. MPA also suppresses antibody formation by B-lymphocytes. MPA prevents the glycosylation of lymphocyte and monocyte glycoproteins that are involved in intercellular adhesion to endothelial cells and may inhibit recruitment of leukocytes into sites of inflammation. Once remission is achieved, maintaining it is a challenge (Joy M et al, 2005; Stassen P, 2005). The ultimate goal is to minimize the toxicity.

In drug induced vasculitis, the first step is the discontinuation of the medication. If there is potentially fatal compromise, steroids and cyclophosphamide should be given. Different approaches have been described. In the first one, cyclophosphamide is administered in monthly boluses for 6 months, then every 3 months for 2 years. The alternative is to give the monthly boluses for 6 months, and then use azathioprine daily for 2 years (Klemmer PJ et al, 2003). Methorexate might be used for maintenance, too.

10. Case presentation

We had the case of a 42 year old woman with a history of multiple sclerosis (MS) diagnosed 9 years ago. Three years after the diagnosis was established, she was initiated on Beta Interferon 1a. Two years later, she developed non pruritic, palpable purpura in her lower extremities with subsequent ulceration and edema. Biopsy was consistent with vasculitis (Daza JS, 2008). She was then treated with high dose steroids, with poor response, and then started on cyclophosphamide. Beta interferon was discontinued. Resolution of the lesions was obtained.

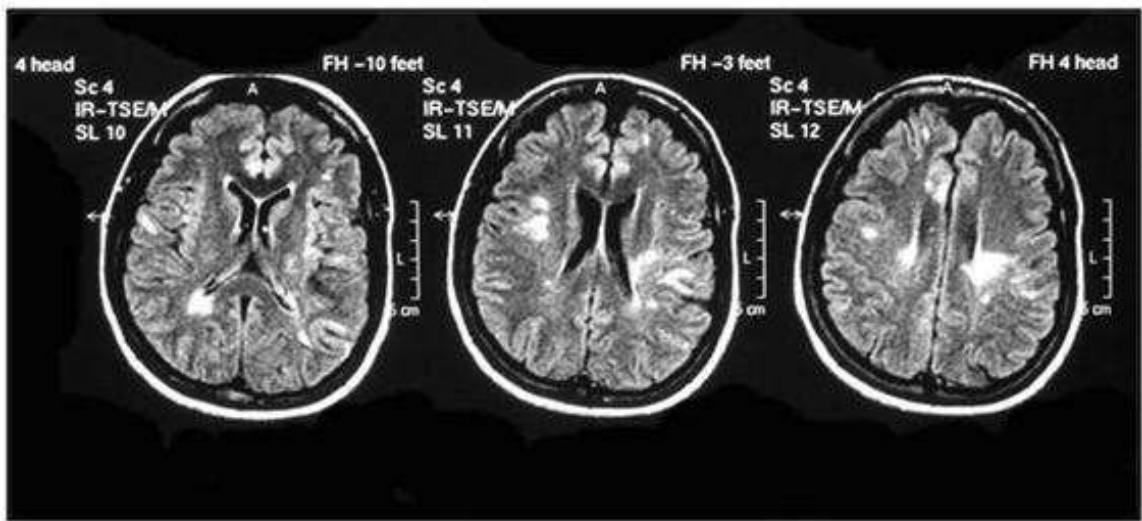


Fig. 1. MRI flash fair image: hyperdense lesions in the yuxtacortical area bilaterally, as well as in the semioval centre and periventricular matter.

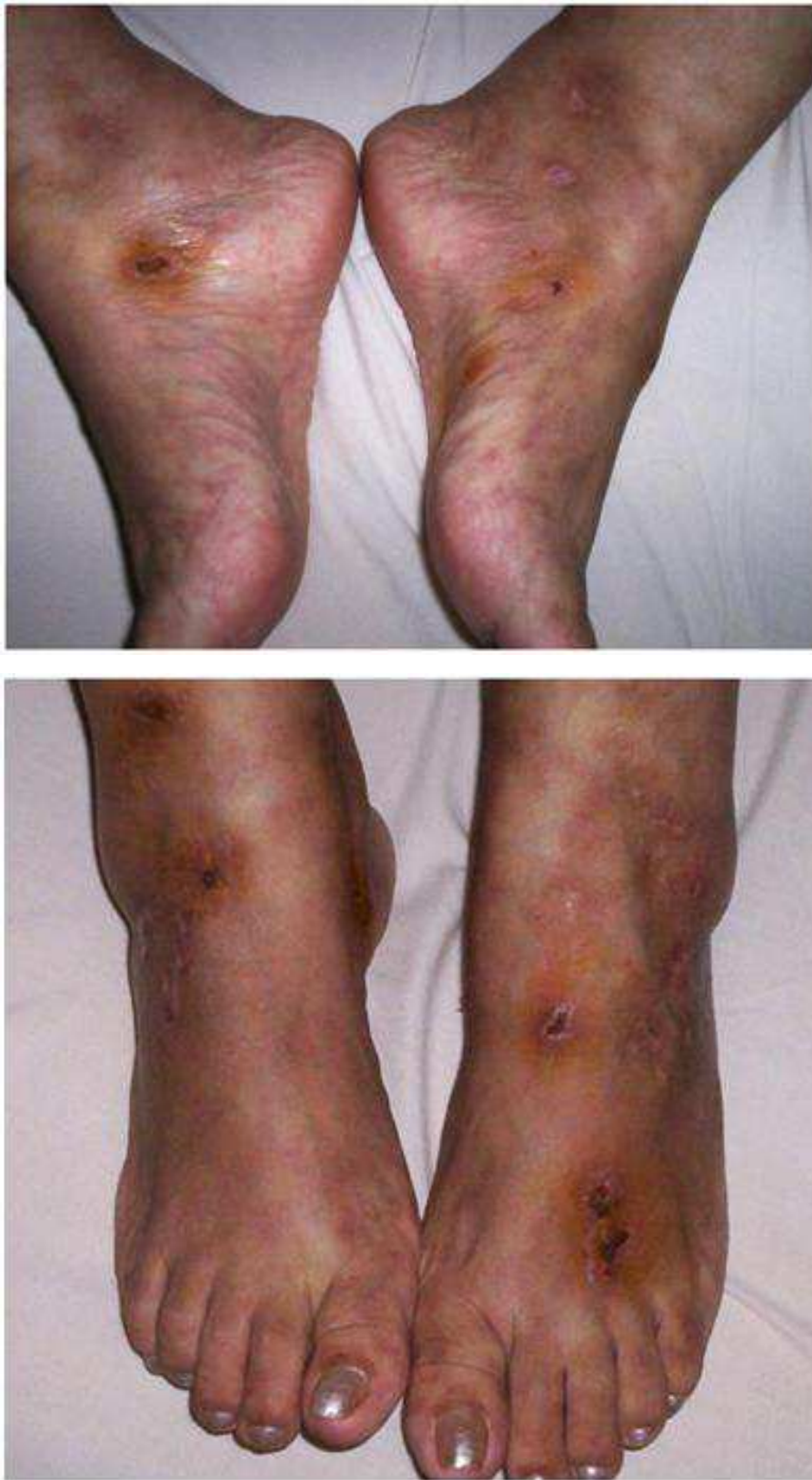

Fig. 2. and 3. In our clinical case lesions are seen in different stages of evolution, some necrotic and scarred other areas hyper pigmentation at the ankle and dorsum of the foot that correspond to areas of vasculitis

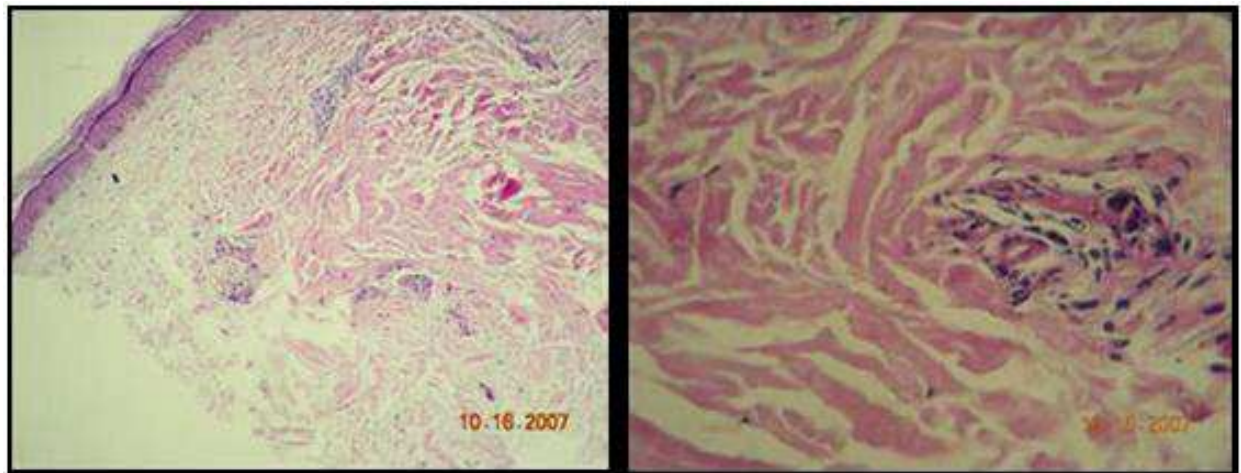


Fig. 4. Skin with preserved epidermis. Superficial and medial dermis with minimal edema. Small vessels with prominent endothelial cells; some of them obstructing the lumen. The wall vessels appears with fibrinoid exudates, neutrophils and debris. Above findings are compatible with small vessel vasculitis of the lower extremities.

The frequency of MS and vasculitis together is exceptional. This was first published in 1998. It has been hypothesized that these reactions are related to the presence of antibodies against interferon beta, which usually increase during the appearance of the lesions, and decrease with their resolution (Szilasiová J, 2003; Daza JS, 2008).

## 11. Conclusion

Vasculitis is a group of diseases characterized by vascular inflammation, which results in decrease of blood flow, and blood vessel wall damage. Any vessel may be affected, as well as one or several organs.

In drug induced vasculitis, small vessels are usually affected. Again this is a diagnosis of exclusion. The diagnosis is a clinical one, with the support of serologic and histological findings. The clinical manifestations are similar to the other vasculitis. The skin, subcutaneous tissue, kidneys and lungs are most commonly affected. C-ANCA antibodies are usually positive. Interferon is a protein naturally produced by the immune system as a response to viruses or malignant cells. Interferon beta is a biological product obtained by DNA recombination techniques, and is used for treatment of MS. Immune complications with this therapy are rare.

In the article, a patient treated for multiple sclerosis with interferon was presented. She developed vasculitis, which was later determined to be caused by Interferon, and was treated accordingly with the scheme depicted above.

The use of any medication opens the possibility to complications and reactions. It is the role of the physician to determine when the benefits outweigh the risks, and once the treatment has been established, close follow up is required.

Drug induced vasculitis, although rare, are not exceptional and should be included in the differential diagnosis of any vasculitis.

Research is needed, to learn which patients have higher possibilities to develop drug induced vasculitis, so screening methods can be designed to avoid such medications in susceptible individuals.

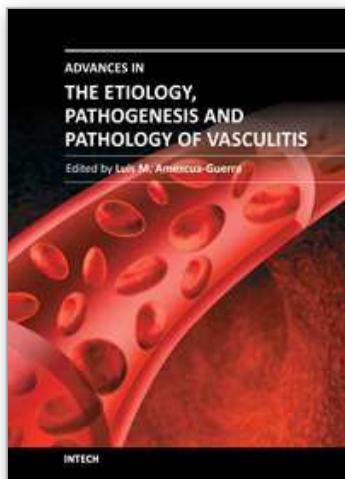
## 12. References

- Alarcon Segovia D, Wakim KG, Worthington JW, et al (1967). Clinical and experimental studies on the hydralazine syndrome and its relationship to systemic lupus erythematosus. *Medicine* Vol. 46, pp 1-6. ISSN on line 1536- 5964
- Aloush V, Litinsky I, Caspi D, Elkayam O (2006). Propylthiouracil-induced autoimmune syndromes: two distinct clinical presentations with different course and management. *Semin Arthritis Rheum* Vol.36, pp 4-9. ISSN 0049 0172
- Ayer LM, Rubin RL, Dixon GH, et al (1994). Antibodies to HMG proteins in patients with drug-induced autoimmunity. *Arthritis & Rheum* Vol.37, pp 98-103. ISSN 1529 0131
- Bonaci-Nikolic B, Nikolic MM, Andrejevic S, et al (2005). Antineutrophil cytoplasmic antibody (ANCA)- associated autoimmune diseases induced by antithyroid drugs: comparison with idiopathic ANCA vasculitides. *Arthritis Res Ther* Vol. 7:R1072-R1081. ISSN electronic 1478 6362
- Burlingame RW, Rubin RL (1996). Autoantibody to the nucleosome subunit (H2AH2B) - DNA is an early and ubiquitous feature of lupus-like conditions. *Mol Biol Rep* Vol. 23, pp 159-166. ISSN electronic 0301-4851
- Bahrami S, Malone JC, Webb KG, et al (2006). Tissue eosinophilia as an indicator of drug-induced cutaneous small-vessel vasculitis. *Arch Dermatology* Vol. 142 (2) pp 155-61. ISSN (electronic): 0096-5359
- Buttmann M, Goebeler M, Toksoy A, Schmid S, Graf W, Berberich-Siebelt F, et al (2005). Subcutaneous interferon-beta injections in patients with multiple sclerosis initiate inflammatory skin reactions by local chemokine induction. *J Neuroimmunol* Vol. 168 pp 175-82. ISSN 0165 5728
- Calabrese LH, Michel BA, Bloch DA, Arend WP, Edworthy SM, Fauci AS, et al (1990): The American College of Rheumatology 1990 criteria for the classification of hypersensitivity vasculitis. *Arthritis Rheum* Vol. 33 pp 1108 ISSN 1529 0131
- Carlson JA, Ng BT, Chen KR (2005) cutaneous vasculitis update: diagnostic criteria, classification, epidemiology, etiology, pathogenesis, evaluation and prognosis. *Am J Dermatopathol*. Vol.27 (6) pp 504-28 ISSN on line 1533 0311
- Carlson JA, Chen KR (2006). Cutaneous vasculitis update: small vessel neutrophilic vasculitis syndromes. *Am J Dermatopathol* Vol 28 (6) pp 486-506. ISSN on line 1533 0311
- Carlson JA, Chen KR (2007). Cutaneous vasculitis update: neutrophilic muscular vessel and eosinophilic, granulomatous, and lymphocytic vasculitis syndromes. *Am J Dermatopathol* Vol. 29 (1) pp 32-43. ISSN on line 1533 0311
- Churg J (1991). Nomenclature of vasculitic syndromes: a historical perspective. *Am J Kidney Dis* Vol. 18 pp 148-153 ISSN 0272 6386
- Choi HK, Merckel PA, Niles JL (2000). Drug-associated antineutrophil cytoplasmic autoantibody-positive vasculitis: prevalence among patients with high titers of antimyeloperoxidase antibodies. *Arthritis Rheum* Vol. 43 (2) pp.405-413 ISSN 1529-0131
- Coppola G, Lanzillo R, Florio C, Orefice G, Vivo P, Ascione S, et al (2006). Long-term clinical experience with weekly interferon beta-1a in relapsing multiple sclerosis. *Eur J Neurol* Vol. 13 pp 1014-1021 ISSN 1468-1331
- Daza-Barriga JS (2008). Vasculitis de vasos pequeños asociada al uso de interferón beta-1a en la esclerosis múltiple. *Rev Neurol* Vol. 46 (11) pp 702-703. ISSN 1576-6578

- DeBandt M, Sibilia J, Le Loe't X, et al (2005). Systemic lupus erythematosus induced by antitumour necrosis factor alpha therapy: a French national survey. *Arthritis Res Ther* Vol. 7:R545-R551 ISSN electronic 1478 6362
- Doyle MK, Cuellar ML (2003). Drug-induced vasculitis. *Expert Opin Drug Saf* Vol. 2 pp 401-409 ISSN 1474 0338
- Fauci AS, Wolff SM (1973). Wegener's granulomatosis: Studies in eighteen patients and a review of the literature. *Medicine (Baltimore)* Vol. 52 pp 535-61 ISSN 1536- 5964
- Glanzmann E (1920). Die Konzeption der anaphylaktoiden Purpura. *Jahrb Kinderh Berl* Vol. 91 pp 391-431.
- González-Gay, MA, Garcia-Porrúa C, Pujol RM (2005). Clinical approach to cutaneous vasculitis. *Curr Op Rheumatol*, vol. 17, pp 56. ISSN 1040 8711
- Gunnarsson I, Nordmark B, Bakri H, et al (2000). Development of lupus-related side effects in patients with early RA during sulphasalazine treatment. The role of IL-10 and HLA. *Rheumatology (Oxford)* Vol. 39 pp 886-893 ISSN on line 1462 0332
- Heberden W (1801). Commentarii de Marlbaun. *Historia et curatione*. London, T. Payne.
- Henoch E (1868). Zusammenhang von purpura and Intestinalstorungen. *Berl. Klin Wchnschr*, 5: 517
- Hoffman BJ (1945). Sensitivity to sulfadiazine resembling acute disseminated lupus erythematosus. *Arch Dermatol Syphilol*; 51:190-192 ISSN 0022 202X
- Hogan SL, Falk RJ, Chin H, Cai J, Jennette CE, Jennette JC, et al (2005). Predictors of relapse and treatment resistance in antineutrophil cytoplasmic antibody- associated small-vessel vasculitis. *Ann Intern Med*. Vol 143 pp 621-318. ISSN on line 1539 3704
- Holder SM, Joy MS, Falk RJ (2002). Cutaneous and systemic manifestations of drug-induced vasculitis. *Ann Pharmacother* Vol. 36 (1) pp 130-47. ISSN on line 1060 0280
- Huang Y, Liu Z, Huang H, Liu H, Li L (2005). Effects of mycophenolic acid on endothelial cells. *Int Immunopharmacol* Vol. 5 pp 1029-39. ISSN 1567 5769
- Hunder GG, Arend WP, Bloch DA, Calabrese LH, Fauci AS, Fries JF, et al (1990). The American College of Rheumatology 1990 criteria for the classification of vasculitis: introduction. *Arthritis Rheum* Vol. 33 pp 1065-1067. ISSN on line 1529 0131
- Iglesias Gamarra A, Restrepo Suarez JF, Valle R., Osorio E., et al (2002). Historia de las vasculitis. *Rev Col de Reumt*. Vol. 9 No. 2, pp. 87-121. ISSN 0121 5426
- Iglesias Gamarra A; Cantillo Turbay J.; Restrepo Suárez J (2006). Análisis crítico de las clasificaciones de las vasculitis. *Rev Col de Reum* Vol. 13 (1), pp. 48-64 ISSN 0121 5426
- Jennette JC, Falk RJ, Andrassy K, Bacon PA, Churg J, Gross WL, et al (1994). Nomenclature of systemic vasculitides: proposal of an international consensus conference. *Arthritis Rheum* Vol. 37 pp 187-192. ISSN on line 1529 0131
- Jennette JC (1994). Pathogenic potential of anti-neutrophil cytoplasmic autoantibodies. *Lab Invest* Vol. 70 pp 135-137. ISSN 1530 0307
- Jennette JC, Falk RJ (1997). Small-vessel vasculitis. *N Engl J Med* Vol. 337 pp 1512-23. ISSN 1533 4406
- Jennette JC, Wilkman AS, Falk RJ (1998). Diagnostic predictive value of ANCA serology. *Kidney Int*. Vol. 53 pp 796-8 ISSN 1523 1755
- Joy M, Hogan S, Jennette J, Falk R, Nachman P (2005). A pilot study using mycophenolate mofetil in relapsing or resistant ANCA small vessel vasculitis. *Nephrol Dial Transplant* Vol. 20(27), pp 25-32. 40. ISSN on line 1460 2385

- Klemmer PJ, Chalermkulrat W, Reif MS, Hogan SL, Henke DC, Falk RJ (2003). Plasmapheresis therapy for diffuse alveolar hemorrhage in patients with small-vessel vasculitis. *Am J Kidney Dis* Vol. 42 pp 1149-53. ISSN 0272 6386
- Klinge F (1933). Der Rheumatismus: pathologisch-anatomische und experimentell-pathologische Tatsachen und ihre Auswertung für das ärztliche Rheumaproblem. *Ergebn Allg Pathol Anat* Vol.27 pp 243-254.
- Koldingsnes W, Nossent H (2002). Predictors of survival and organ damage in Wegener's granulomatosis. *Rheumatology (Oxford)* Vol. 41 pp 572-81. 9. ISSN 1462-0332
- Kussmaul A, Maier R (1866). Ueber eine bisher nicht beschriebene eigenthümliche Arterienerkrankung (Periarteritis nodosa), die mit Morbus Brightii und rapid fortschreitender allgemeiner Muskellähmung einhergeht. *Deutsche Arch Klin Med* Vol. 1 pp. 484-518. ISSN 0003 4819
- Litton DG & Resurh LM (1978). Galen on Abnormal Swellings. *J Hist Med Allied Sci* Vol 34 (4) pp 531-549 Online ISSN 1468-4373
- Merkel PA (2001). Drug-induced vasculitis. *Rheum Dis Clin North Am*; 27:849-862. ISSN 0889-857X
- Merriam – Webster Online Dictionary, 2011. Definition of vasculitis.
- Mielke H, Wildhagen K, Mau W, et al (1993). Follow-up of patients with doublestranded DNA antibodies induced by sulfasalazine during treatment of inflammatory rheumatic diseases. *Scand J Rheumatol*; 22:299-301. ISSN electronic 1502 7732
- Molina J, Alarcon D, Molina R J, Anaya J, Cardiel M (2000). *Fundamentos de Medicina, Reumatología*. CIB, pp 274-289. ISBN 958-9400-82-5.
- Morrow JD, Schroeder HA, Perry HM Jr (1953). Studies on the control of hypertension by Hyphex. II. Toxic reactions and side effects. *Circulation*; 8:829-839
- Mukhtyar C, Guillevin L, Cid MC, Dasgupta B, de Groot K, Gross W, et al (2009). EULAR Recommendations for the management of primary small and medium vessel vasculitis. *Ann Rheum Dis*; 68:310-7. ISSN on line 1468 2060
- O'Sullivan SS, Cronin EM, Sweeney BJ, et al (2006). Panniculitis and lipoatrophy after subcutaneous injection of interferon beta-1b in a patient with multiple sclerosis. *J Neurol Neurosurg Psychiatry* Vol. 77 pp 1382-1383. ISSN electronic 1468 330X
- Pillinger MH, Staud R (2006). Propylthiouracil and antineutrophil cytoplasmic antibody associated vasculitis: the detective finds a clue. *Semin Arthritis Rheum* Vol. 36 pp 1-3. ISSN 0049 0172
- Reinhold-Keller E, Beuge N, Latza U, De Groot K, Rudert H, Noelle B, et al (2000). An interdisciplinary approach to the care of patients with Wegener's granulomatosis: Long-term outcome in 155 patients. *Arthritis Rheum*; 43 pp 1021-32. ISSN 1529 0131
- Rokitansky K (1852). Ueber einige der wichtigsten Krankheiten der Arterien. *Denkschr Akad der Wissensch. Wien, Hof Staatsdruckerei*. Vol.4(1)
- Savigne J, Davies D, Falk RJ, Jennette JC, Wiik A (2000). Antineutrophil cytoplasmic antibodies and associated diseases: a review of the clinical and laboratory features. *Kidney Int* Vol. 57 pp 846-62
- Saporta A. De tumoribus paeter naturam, (Ravaud, Lyons 1624). Cited by Garrison. F. H. and Morton, L.T.: *A medical bibliography*; 3rd ed. (Deutsch, London 1970). No. 2971, the manuscript is from 1554.
- Scott DGI, Watts RA (2000). Systemic vasculitis: Epidemiology, classification and environmental factors. *Ann Rheum Dis* Vol. 59 pp. 161-3. ISSN on line 1468 2060

- Schönlein JL. Allgemeine und specielle (1837). Pathologie and Therapie. *St. Gallen*, 1837; 2: 42
- Stassen P, Cohen Tervaert J, Stegeman C (2007). Induction of remission in active anti-neutrophil cytoplasmic antibody-associated vasculitis with mycophenolate mofetil in patients who cannot be treated with cyclophosphamide. *Ann Rheum Dis* Vol. 66 pp 798–802. ISSN 1468 2060
- Szilasiová J, Gdovinová Z, Jautová J, Baloghová J, Ficová M, Bohus P (2009). Cutaneous vasculitis associated with interferon beta-1b treatment for multiple sclerosis. *Clin Neuropharmacol*. Vol. 32(5) pp 301-3 ISSN on line 1537-162X
- Tidman M, Olander R, Slavender C, et al (1998). Patients hospitalized because of small vessel vasculitis renal involvement in the period 1975 - 1995: organ involvement, anti-neutrophil cytoplasmic antibodies patterns, seasonal attack rates and fluctuation of annual frequencies. *J Intern Med*, pp 133 – 41. ISSN on line 1365 2796
- Ullman S, Wiik A, Kobayasi T, et al (1974). Drug-induced lupus erythematosus syndrome. Immuno-pathological, electronmicroscopical and serological studies. *Acta Derm Venereol* Vol. 54 pp 387–390. ISSN 0001 5555
- Watts RA, Jolliffe VA, Grattan CE, et al (1998). Cutaneous vasculitis in a defined population-clinical and epidemiological associations. *J Rheumatol* Vol. 25 pp 920-4. ISSN on line 1499 2752
- Watts RA, Lane SE, Bentham G, et al (2000). Epidemiology of systemic vasculitis: A ten-year study in the United Kingdom. *Arthritis Rheum* Vol. 43 pp 422-7. ISSN on line 1529 0131
- Wegener F (1990). Wegener's granulomatosis: thoughts and observations of a pathologist. *Eur Arch Otorhinolaryngol* Vol. 247 pp 133-142. ISSN on line 1434 4726
- Westman K, et al (2003). High Proteinase 3-anti-neutrophil cytoplasmic antibody (ANCA) level measured by the capture enzyme-linked immunosorbent assay method is associated with decreased patient survival in ANCA-associated vasculitis with renal involvement. *J Am Soc Nephrol* Vol.14 pp 2926–2933. ISSN 1533 3450
- Wiik A (2005). Clinical and laboratory characteristics of drug-induced vasculitic syndromes. *Arthritis Res Ther* Vol. 7 pp 191–192. ISSN On line 1478 6362
- Wiik A (2008). Drug-induced vasculitis. *Current Opinion in Rheumatology* Vol. 20 pp 35–39 ISSN 1040 8711
- Yung RL & Richardson BC (1994). Drug-induced lupus. *Rheum Dis Clin N Am* Vol. 20 pp 61–85. ISSN 1558 3163
- Zhao MH, Jones SJ, Lockwood CM (1995). Bactericidal/permeability-increasing protein (BPI) is an important antigen for antigen-neutrophil cytoplasmic autoantibodies (ANCA) in vasculitis. *Clin Exp Immunol* Vol. 99 pp 49-56 ISSN 0749 0690



## **Advances in the Etiology, Pathogenesis and Pathology of Vasculitis**

Edited by Dr. Luis M Amezcua-Guerra

ISBN 978-953-307-651-5

Hard cover, 438 pages

**Publisher** InTech

**Published online** 17, October, 2011

**Published in print edition** October, 2011

This book represents the culmination of the efforts of a group of outstanding experts in vasculitis from all over the world, who have endeavored to devote their work to this book by keeping both the text and the accompanying figures and tables lucid and memorable. Here, you will find an amalgam between evidence-based medicine to one based on eminence, through an exciting combination of original contributions, structured reviews, overviews, state-of-the-art articles, and even the proposal of novel pathogenetic models of disease. The book contains contributions on the etiology and pathology of vasculitis, the potential role of endothelial cells and cytokines in vascular damage and repair as well as summaries of the latest information on several primary and secondary vasculitis syndromes. It also covers selected topics such as organ-specific vasculitic involvement and quality of life issues in vasculitis. The editor and each of the authors invite you to share this journey through one of the most exciting fields of the medicine, the world of Vasculitis.

### **How to reference**

In order to correctly reference this scholarly work, feel free to copy and paste the following:

Jorge Daza Barriga, Mónica Manga Conte and Arturo Valera Agámez (2011). Drug Induced Small Vessel Vasculitis, *Advances in the Etiology, Pathogenesis and Pathology of Vasculitis*, Dr. Luis M Amezcua-Guerra (Ed.), ISBN: 978-953-307-651-5, InTech, Available from: <http://www.intechopen.com/books/advances-in-the-etiology-pathogenesis-and-pathology-of-vasculitis/drug-induced-small-vessel-vasculitis>

**INTECH**  
open science | open minds

### **InTech Europe**

University Campus STeP Ri  
Slavka Krautzeka 83/A  
51000 Rijeka, Croatia  
Phone: +385 (51) 770 447  
Fax: +385 (51) 686 166  
[www.intechopen.com](http://www.intechopen.com)

### **InTech China**

Unit 405, Office Block, Hotel Equatorial Shanghai  
No.65, Yan An Road (West), Shanghai, 200040, China  
中国上海市延安西路65号上海国际贵都大饭店办公楼405单元  
Phone: +86-21-62489820  
Fax: +86-21-62489821

© 2011 The Author(s). Licensee IntechOpen. This is an open access article distributed under the terms of the [Creative Commons Attribution 3.0 License](https://creativecommons.org/licenses/by/3.0/), which permits unrestricted use, distribution, and reproduction in any medium, provided the original work is properly cited.

IntechOpen

IntechOpen