

We are IntechOpen, the world's leading publisher of Open Access books Built by scientists, for scientists

6,900

Open access books available

186,000

International authors and editors

200M

Downloads

Our authors are among the

154

Countries delivered to

TOP 1%

most cited scientists

12.2%

Contributors from top 500 universities



WEB OF SCIENCE™

Selection of our books indexed in the Book Citation Index
in Web of Science™ Core Collection (BKCI)

Interested in publishing with us?
Contact book.department@intechopen.com

Numbers displayed above are based on latest data collected.
For more information visit www.intechopen.com



New Bone Formation in the Maxillary Sinus With/Without Bone Graft

Dong-Seok Sohn
Catholic University of Daegu
Daegu
Republic of Korea

1. Introduction

Pneumatization of maxillary sinus causes insufficient vertical bone volume on posterior maxilla. So the restoration of edentulous posterior maxilla with dental implants is challenging due to a deficient posterior alveolar ridge, unfavorable bone quality and increased pneumatization of the maxillary sinus.¹ For maxillary sinus augmentation, the crestal approach and the lateral window approach have been used. In this chapter, sinus augmentation using crestal and lateral window approach with/without bone graft is described.

2. Indications and contraindications for sinus augmentation

Even sinus augmentation procedure is considered as highly predictable augmentation procedure, presurgical evaluation on maxillary sinus and patient's medical and dental history should carefully be evaluated.

The following are indications for sinus augmentation.

- No history of sinus pathosis
- Insufficient residual bone height (less than 10mm of bone height)
- Severely atrophic maxilla
- Poor bone quality and quantity in the posterior maxilla

Sinus augmentation is not indicated when patient has history as below

- Recent radiation therapy in maxilla
- Uncontrolled systemic diseases such as Diabetes Mellitus
- Acute / chronic maxillary sinusitis (Fig. 1)
- Heavy smoker
- Alcohol abuse
- Psychosis
- Severe allergic rhinitis
- Tumor or large cyst in the maxillary sinus (Fig. 2)
- Oroantral fistula (Fig. 3)

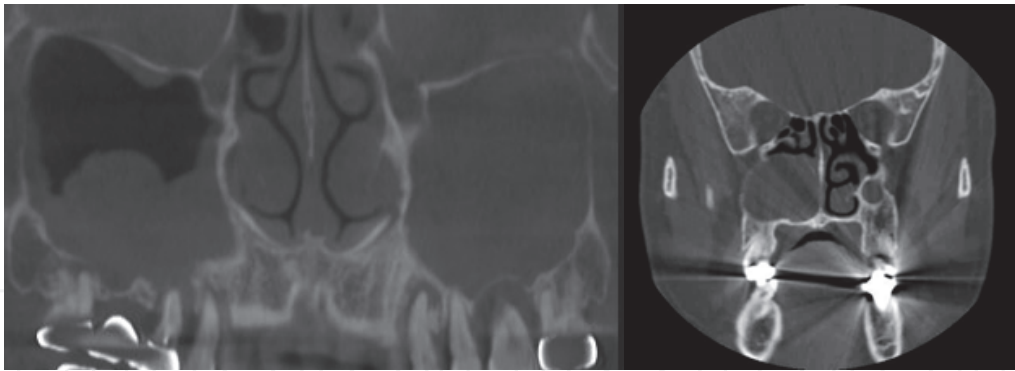


Fig. 1. (Left) demonstrates odontogenic sinusitis in the both sinus. Fig. 2. (right) shows mucocoele in the right sinus. Sinus pathosis should be eliminated before sinus augmentation.

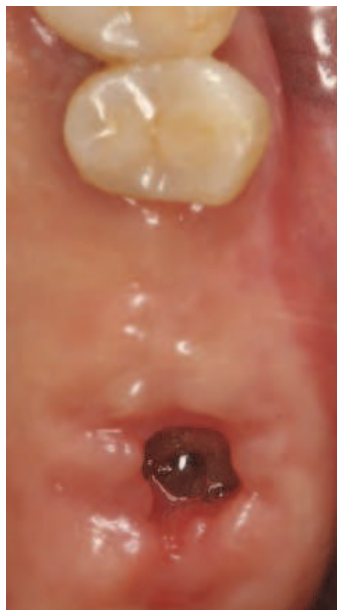

Fig. 3. Oroantral fistula should be corrected before sinus augmentation.

3. Sinus augmentation using crestal approach

Sinus augmentation using the lateral window procedure has been predictable for several decades. However, this procedure has some complications such as postoperative swelling, pain, and a long edentulous healing period. To reduce the complications from the lateral window approach in maxillary sinus augmentation, various crestal approaches such as osteotome mediated sinus floor elevation (OMSFE)², piezoelectric internal sinus elevation (PISE)³⁻⁵, hydraulic sinus condensing (HSC) technique⁶, internal sinus manipulation (ISM) procedure method⁷, and crestal window technique (CWT)⁸ and hydrodynamic piezoelectric internal sinus elevation (HPISE)⁹⁻¹⁰ have been introduced as alternative to lateral window approach for sinus augmentation.

3.1 Osteotome Mediated Sinus Floor Elevation (OMSFE)

OMSFE technique utilizes osteotome and a surgical mallet to break sinus floor and to compact bone graft into the sinus cavity.

Surgical procedure of OMSFE (Fig. 4-16)

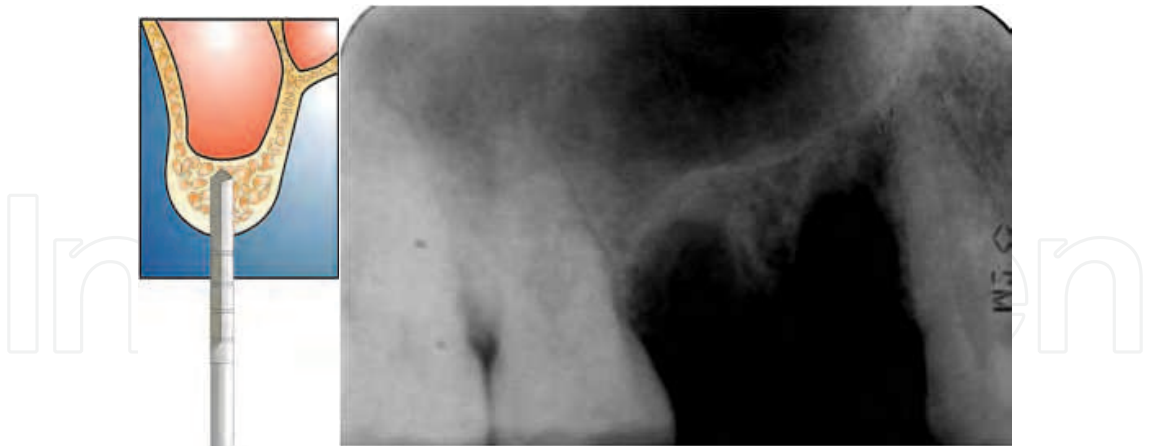

Fig. 4. and 5. A pilot drill is usually used to the depth 1-2mm short to the sinus floor to accommodate osteotome to sinus floor. However as shown on fig 5 , pilot drill is omitted when bone height is less than 2mm from sinus floor at the implant sites

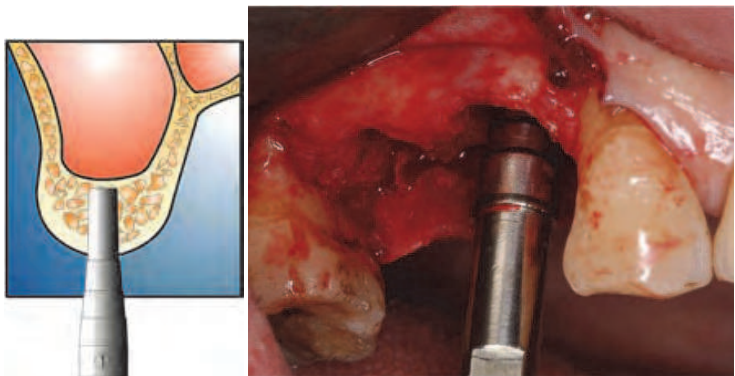


Fig. 6. and 7.

Small diameter osteotome is inserted into the prepared bone to compress sinus floor using a surgical mallet. Wider osteotome is inserted continuously into the prepared bone to accommodate implants. The insertion of osteotome would impose a light pressure on the sinus floor.

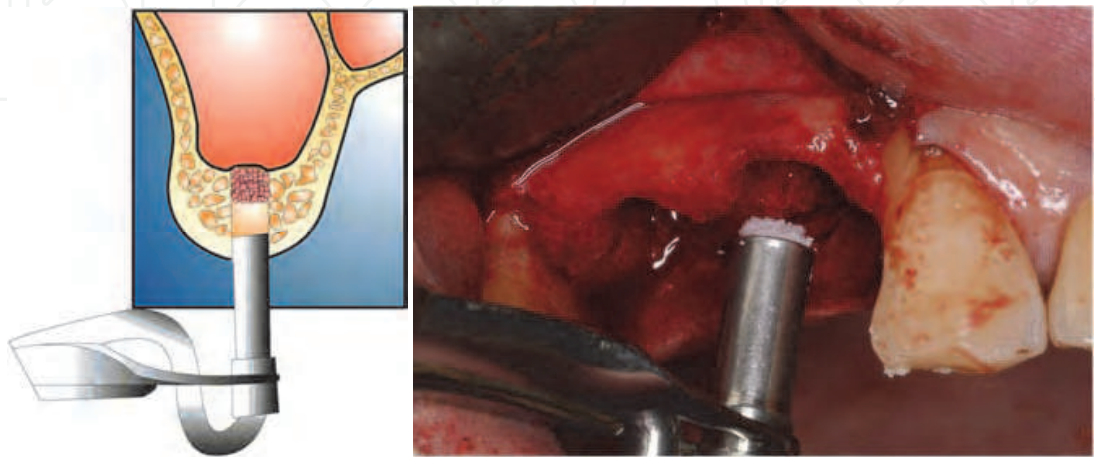


Fig. 8. and 9.

In order to elevate the sinus floor indirectly and provide buffering effect to sinus floor, bone graft material is added using an amalgam carrier. For the graft material, the radiopaque bone grafts, such as mineral allograft or xenograft, are preferred over radiolucent materials such as demineralized allograft.

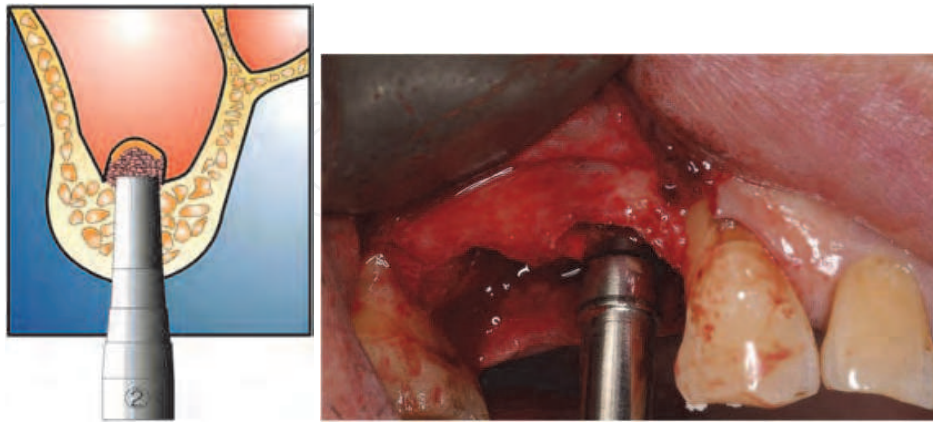


Fig. 10. and 11.

The sinus floor is elevated by repeated bone grafting and osteotome insertion. For sinus floor elevation of 3~4mm, 4~6 times of grafting and osteotome insertion and for the elevation of 5~7mm, 7~10 times of the repetition is required.

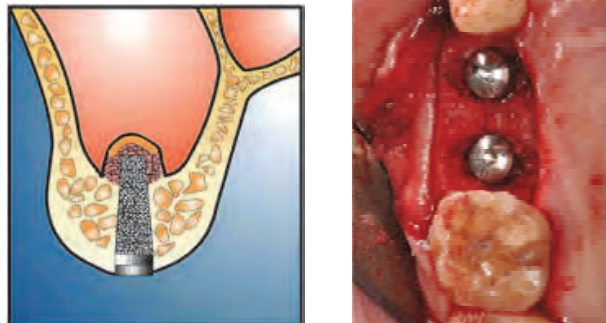


Fig. 12. and 13. The implants are placed.

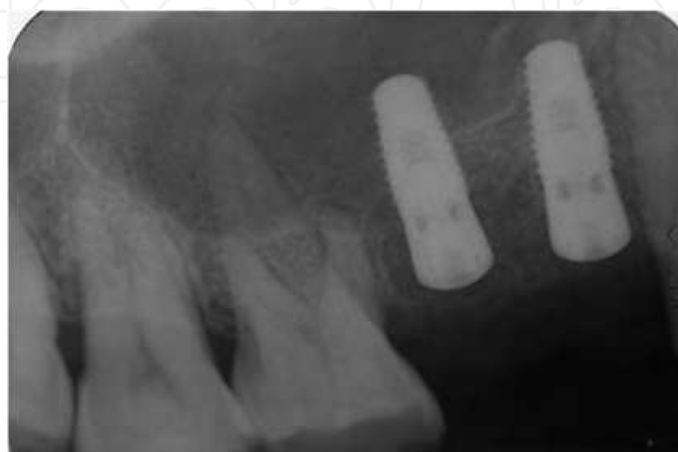

Fig. 14. Postoperative radiogram shows sinus elevation over the implant apex.

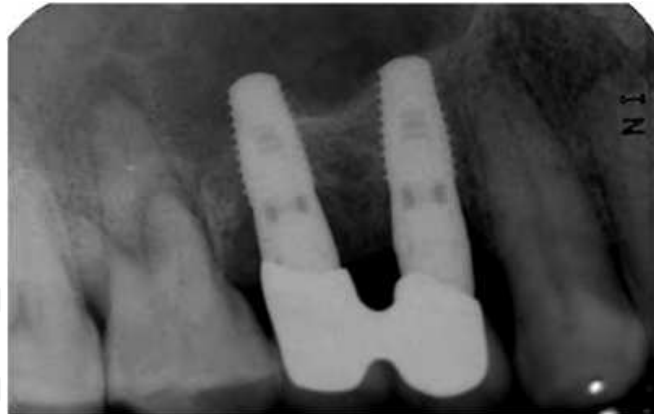

Fig. 15. Final prosthesis was cemented after 6 months healing. New sinus floor is seen in the radiogram.

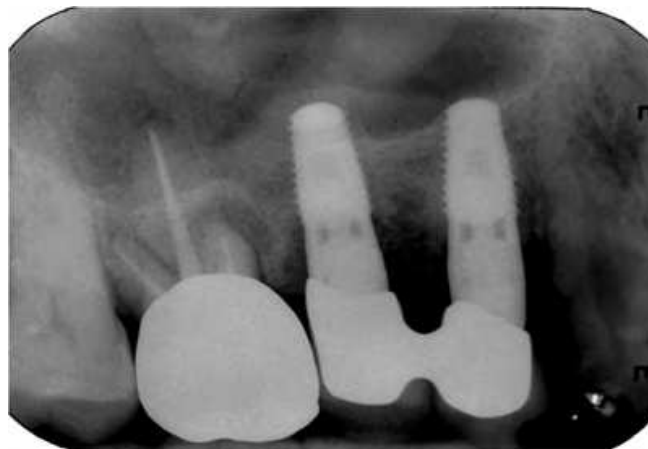

Fig. 16. 2 years after loading. Note newly formed sinus floor.

OMSFE has the advantage of surgical simplicity, resulting in minimal post-operative symptoms. But this technique also has the possibility of complications such as perforation of sinus membrane during bone drilling and bone compaction using osteotome. In addition, benign positional paroxysmal vertigo (BPPV) can be caused by the damage to the internal ear from striking osteotome and surgical mallet when sinus floor is broken.¹¹⁻¹³ It is difficult to break sinus floor in the area of slope of the sinus and in the site of septum with conventional crestal approach, and it could be time consuming and traumatic procedure to the internal ear (Fig 17 and Fig 18). Author experienced one case of BPPV caused from excessive striking of mallet in the anterior slope of sinus cavity in 2000. BPPV is not a common complication but surgeons should avoid excessive force to the surgical mallet when sinus floor is broken. In addition, OMSFE is a blind technique, so sinus augmentation is limited. The OMSFE technique has lower success rates when residual bone height is 4mm or less (when compared to cases with 5mm or more residual bone height).¹⁴

Sinus membrane integrity should be maintained when performing OMSFE because the membrane perforation causes cessation of sinus floor elevation. It is recommended that drilling should be stopped 1-2mm short to sinus floor in conventional OMSFE but this is not always easy because of magnification of plain radiogram.⁶ Accidental sinus membrane perforation can be developed from improper drilling due to magnification of radiogram,

improper use of osteotome and excessive compaction of bone graft. Membrane perforation can cause the failure of osseointegration and sinus pathosis. (Fig 19 and Fig 20)

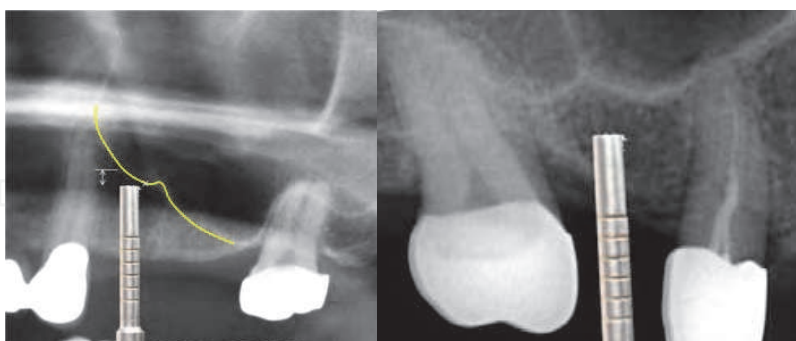


Fig. 17. and 18. Sinus elevation can be difficult at the anterior slope of sinus cavity due to too much remained bone height after initial osteotomy using pilot drill and at the sinus septum because it is very dense bone to break with OMSFE. Benign positional paroxysmal vertigo can be caused by the damage from the internal ear from striking osteotome and surgical mallet to sinus floor at these sites.

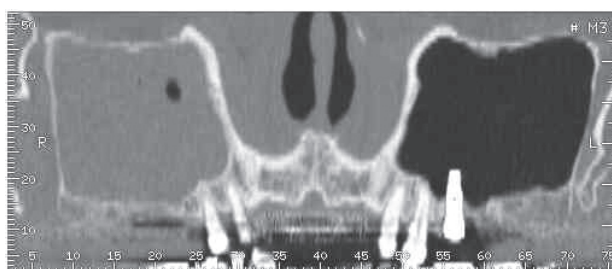

Fig. 19. OMSFE was performed at the site of # 26 and # 27 at private clinic. However membrane was perforated at the both sites. Two implants were placed at the same time. After 6 months healing, # 27 implant was removed because of mobility of implant during uncovering procedure and #26 implant showed the mobility too. The patient was referred to my department for the removal of implant and sinus graft. #26 implant was removed out, followed by sinus graft using lateral window approach. The integrity of sinus membrane should be maintained for successful sinus augmentation when performing OMSFE procedure. Note chronic sinusitis in the right sinus.

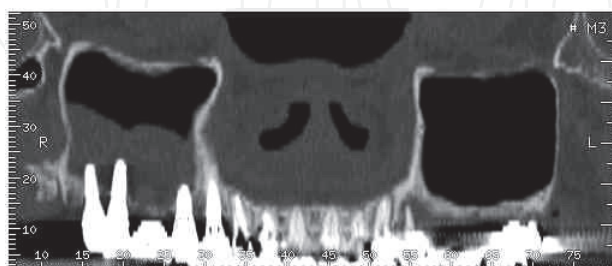

Fig. 20. OMSFE was performed at the both sinus by private clinician. Implants were placed at the same time. All implants placed in the left posterior maxilla were failed due to membrane perforation. She was referred to my department for sinus augmentation in the left sinus. Right sinus shows mucosal thickening due to intrusion of implant in to the sinus cavity. To maintain healthy sinus mucosa, the integrity of sinus membrane should be maintained.

3.2 Piezoelectric internal sinus elevation (PISE)

The PISE and HSC technique are innovative crestal methods which a surgical mallet is not required to break the sinus floor. PISE uses ultrasonic piezoelectric vibration and HSC technique uses high speed diamond bur to break sinus floor directly. These techniques are free from postoperative vertigo, but bone compaction is needed to elevate the sinus membrane. The CWT overcomes the blind nature of conventional OMSFE,⁸ but the indication of this technique is limited because this technique is indicated when wide diameter implants (>5mm) are available.

Surgical procedure of PISE (Fig. 21- Fig. 33)

In PISE technique, PISE tip, connected with an ultrasonic piezoelectric device (Surgybone®, Silfradent srl, Sofia, Italy) is used to break the sinus floor. The working head of PISE tip (S028E® tip, Bukbu Dental Co, Daegu, Korea) is 2.8mm wide and 4mm high. A piezoelectric carbide-type tip is more powerful and effective for osteotomy than diamond coated tip. Thanks to selective cut of ultrasonic piezoelectric vibration, the perforation of sinus membrane is very rare when sinus floor is eroded. After breaking sinus floor with piezoelectric tip directly, gel or putty conditioned bone graft was prepared to elevate sinus membrane with buffering function. To prepare gel or putty conditioned bone graft, author prefer to mix bovine bone powder (Bio-Cera™, Oscotec Co, Cheonan, Korea) and gel-onditioned allograft (OrthoBlast® II, Isotis Orthobiologics Inc, Irvine, USA). Bovine bone acts as radiopaque material and the gel conditioned allograft acts as buffer during membrane elevation.

The amalgam carrier is used when placing the graft into the narrow socket. A narrow diameter osteotome (usually 2mm in diameter) or PISE tip is inserted to compact the graft in the osteotomy site. After the membrane was elevated properly, the regular diameter implant is placed (3.7-4.0mm wide implant) without additional drilling procedure. To place wide body implant implant site should be widened with drill to accommodate the implant

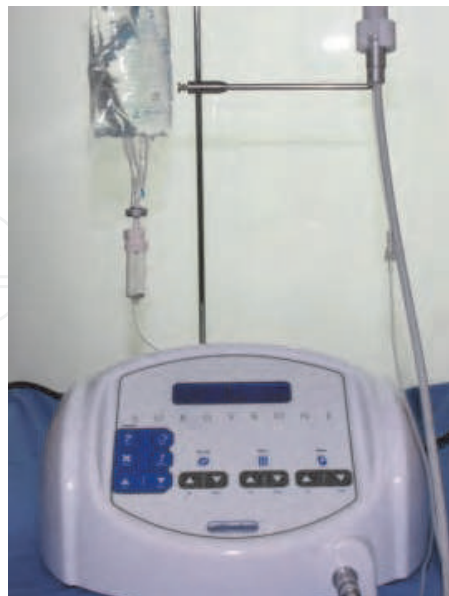

Fig. 21. Ultrasonic piezoelectrci device (Surgybone®, Silfradent srl, Sofia, Italy). This decice works in hard tissue, not in the soft tissue. Therefore membrane perforation is rare when breaking sinus floor.



Fig. 22. Carbide type PISE tip (S028E) with external irrigation.

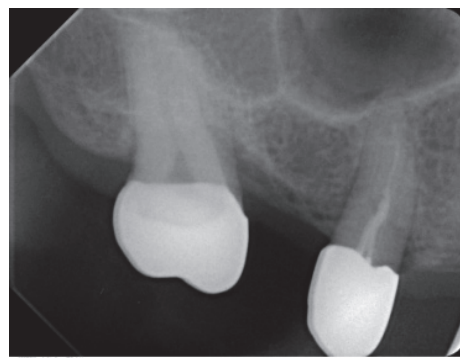


Fig. 23. A periapical radiogram shows high septum in the sinus. The bone around septum is dense, so the breaking of sinus floor using OMSFE technique is time consuming and could be traumatic to internal ear due to heavy striking of mallet. Therefore PISE is applied to break sinus floor directly.

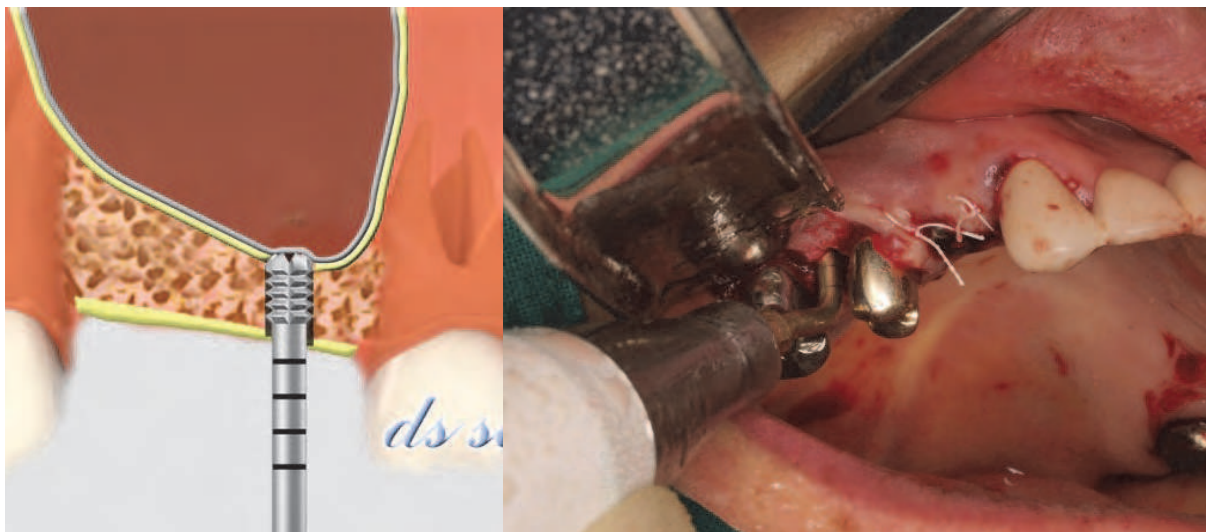


Fig. 24. (left) and Fig. 25. (right). Sinus floor is penetrated with PISE tip directly. At this stage, the exact bone height from alveolar crest to sinus floor is estimated.

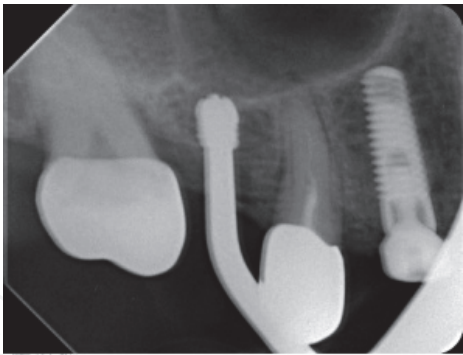


Fig. 26. The sinus floor is completely broken at the implant site by PISE tip. Note the broken sinus floor without membrane perforation.

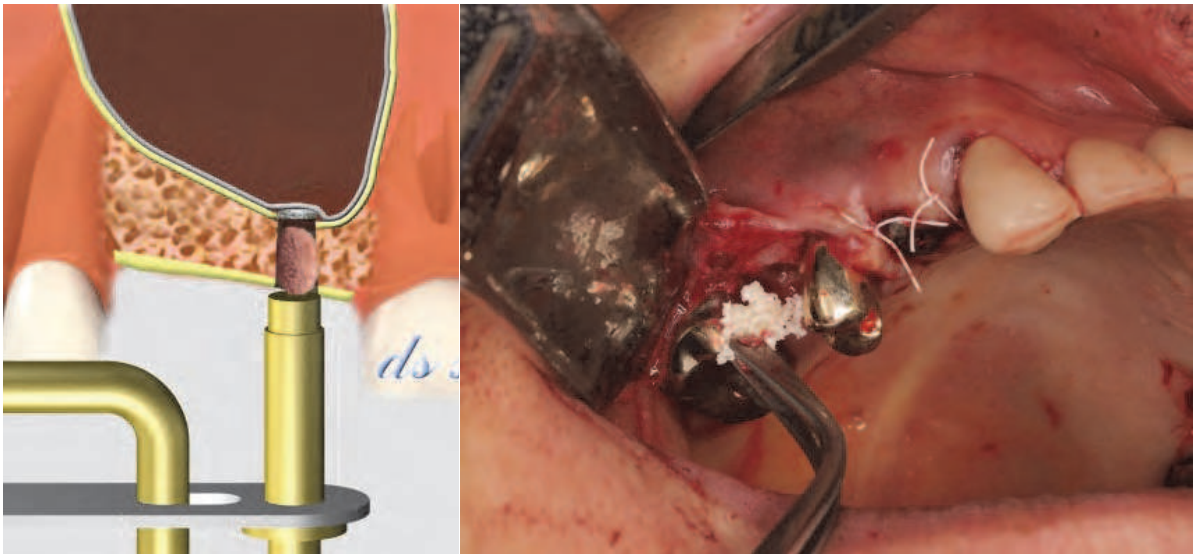


Fig. 27 (left) and Fig. 28. (right). Gel conditioned bone graft materials are carried into the osteotomy site.

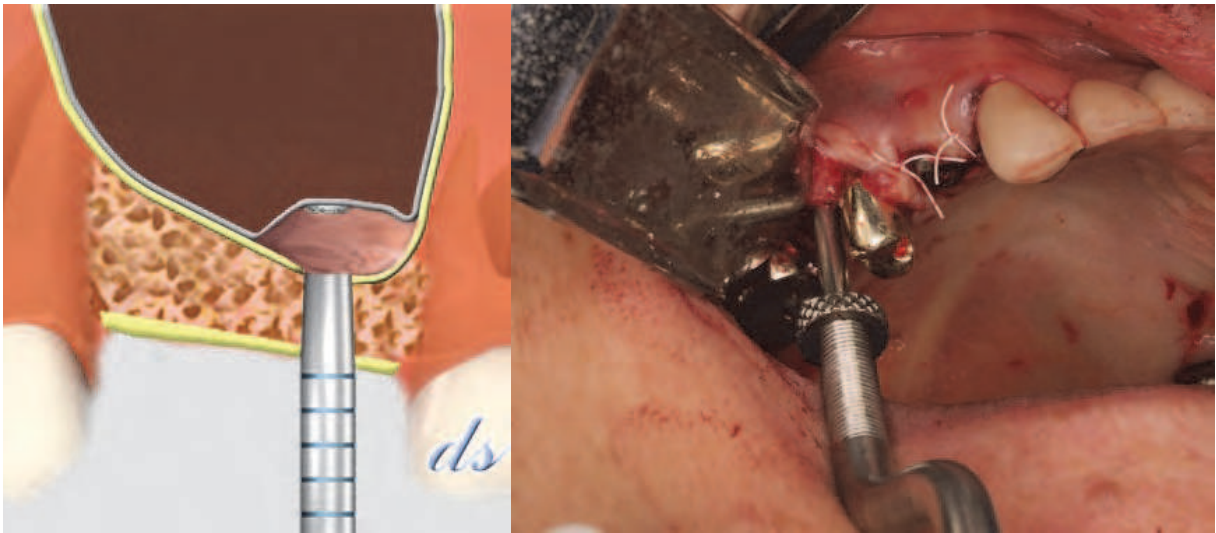


Fig. 26. (left) and Fig. 30. (right). Bone graft is compacted with the narrow osteotome or PISE tip using vibration to elevate sinus membrane.

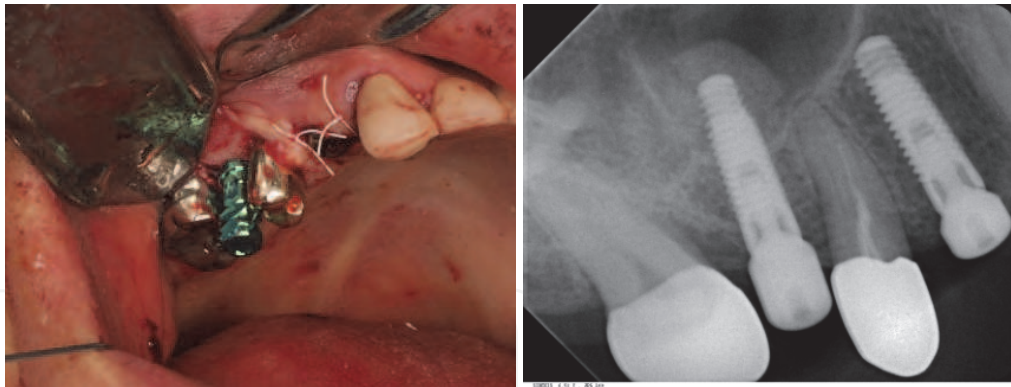


Fig. 31. (left) and Fig. 32. (right). A 3.7mm wide and 13mm high implant is placed without additional drilling procedure. Sinus elevation is seen at the radiogram.

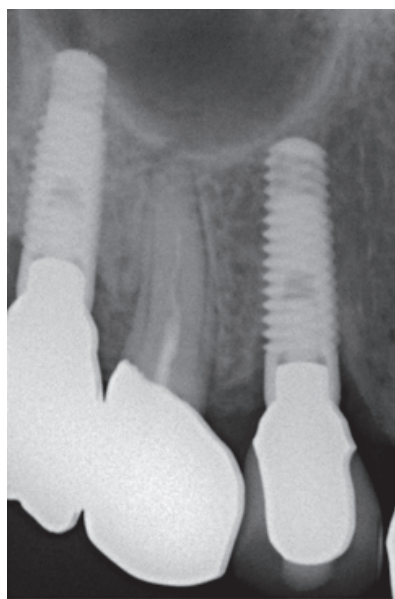


Fig. 33. Final prosthesis is cemented on after 6 months healing. A radiogram indicates sufficient augmentation of the sinus floor.

3.3 Hydrodynamic piezoelectric internal sinus elevation (HPISE)

HPISE is the updated crestal approach from PISE. This technique utilizes ultrasonic piezoelectric vibration to break sinus floor as same as PISE. However, unlike PISE and other conventional crestal approaches, HPISE usually doesn't rely on bone compaction to elevate sinus membrane. HPISE uses water pressure to elevate the sinus membrane. Hydraulic pressure from internal irrigation facilitates gentle and broad elevation of the sinus membrane before bone grafting. The HPISE uses a specially designed tip attached to a piezoelectric ultrasonic unit (Surgybhone®, Silfradent srl, Sofia, Italy or compatible device). HPISE tip (S028I®, BukBu Dental Co, Daegu, Korea) allows internal irrigation to apply water pressure to the sinus membrane (Fig 34). Bone graft is dependent on surgeon's personal preference. Bone graft is indicated when heavy cyst is located in the sinus, more than 6mm high sinus elevation is required, implant is not placed simultaneously and postoperative radiopaque image is required to verify sinus elevation.

If the required sinus elevation is minimal (less than 5mm) and implant is placed at the same time, bone graft is not a prerequisite for sinus augmentation. New bone formation is achieved in the new compartment under the elevated sinus membrane thanks to tenting effect. As an alternative to bone graft, collagen sponge or fibrin rich block with concentrated growth factors (CGF®, Medifuge, Silfradent srl, S.Sofia, Italy) can be used. Fibrin rich block with concentrated growth factors can be used to accelerate new bone formation in the sinus

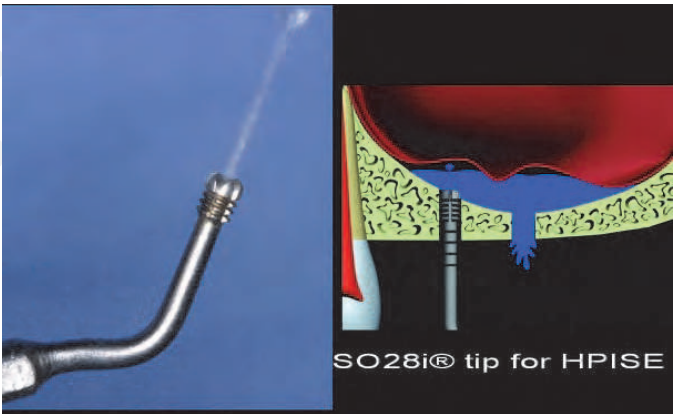


Fig. 34. HPISE (S028I®) tip with internal irrigation. Hydraulic pressure from internally irrigated saline elevates sinus membrane.

Surgical procedure of HPISE without bone graft (Fig. 35- Fig. 47)

As a first step, a 1.6mm wide carbide round insert (S016®, BukBu Dental Co, Daegu, Korea) with external irrigation is used to penetrate sinus floor directly. After breaking the sinus floor with the round tip, a 2.8mm wide HPISE tip is utilized to enlarge the osteotomy site and elevate the sinus membrane using hydraulic pressure. The HPISE tip has 4mm working tip height, and depth indicating lines are marked by 2mm intervals. Hydraulic pressure to the sinus membrane from internally irrigated sterile saline detaches sinus membrane from the sinus floor. Hydraulic pressure is applied for several ten seconds to detach sinus membrane from sinus floor. After the detachment of sinus membrane, surgeons can observe up and down movement of sinus membrane whenever patient takes a breath. When the diameter of implant is less than 4mm wide, the HPISE insert is the last instrument to make the osteotomy prior to implant placement. Undersizing the osteotomy ensures favorable initial stability of the implant in the posterior edentulous ridge with poor bone quantity and quality. When a wider implant is placed, intermittent drilling is often required to accommodate the wide body implant.

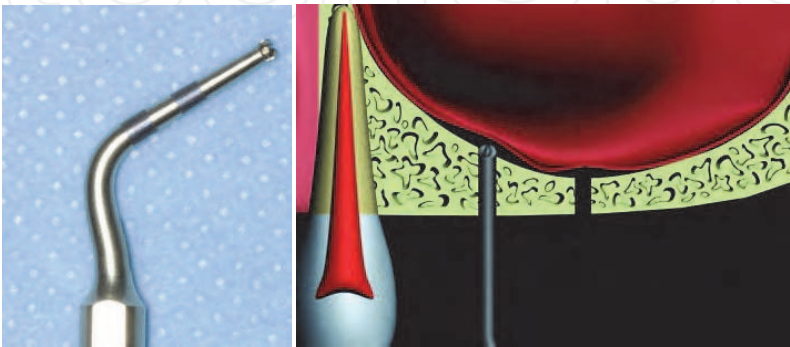


Fig. 35. (left) and Fig. 36. (right). Round carbide tip is used to break sinus floor directly. This tip provides surgeon tactile feeling of sinus membrane.

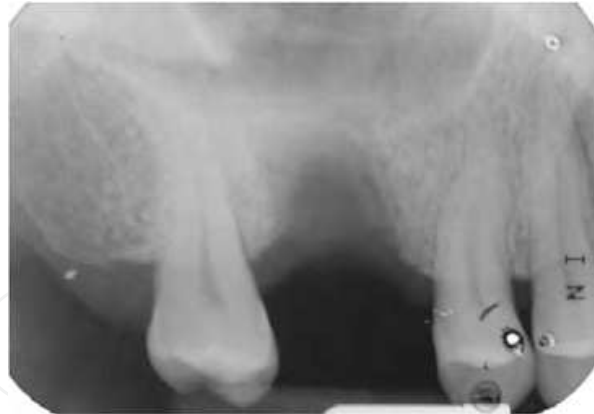

Fig. 37. When remaining bone height at the implant site is very low as shown on this radiogram, round tip can be omitted.

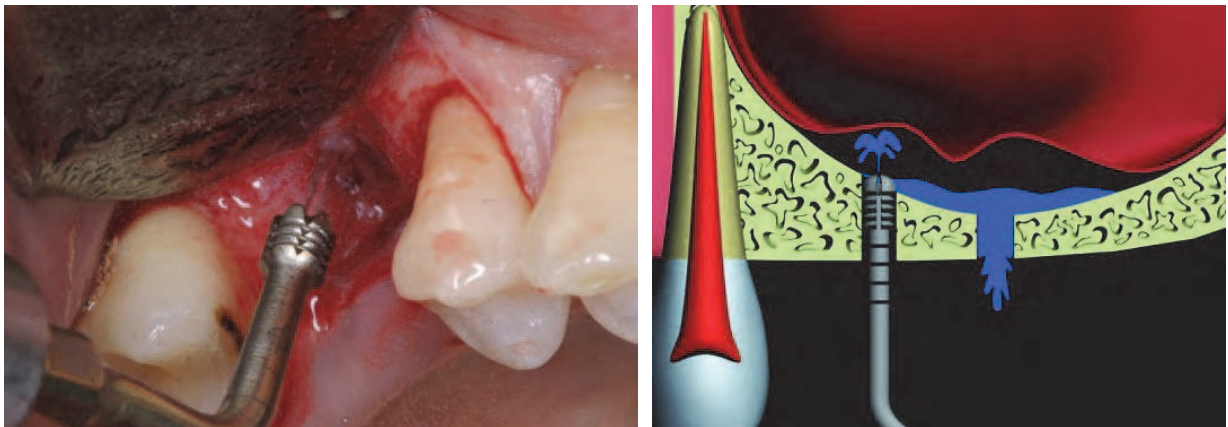


Fig. 38. (left) and Fig. 39. (right). HPISE is inserted to break sinus floor using ultrasonic vibration and elevate sinus membrane using water pressure.

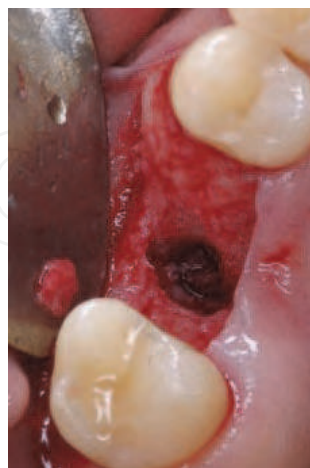

Fig. 40.

After applying water pressure, the detachment of membrane from sinus floor is seen. Surgeon can observe up and down movement of sinus membrane whenever patients take a breath.

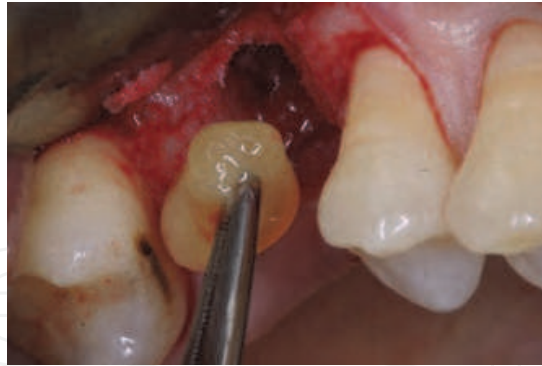

Fig. 41. As alternative to bone graft, CGF alone is inserted in order to accelerate bone reformation in the sinus,

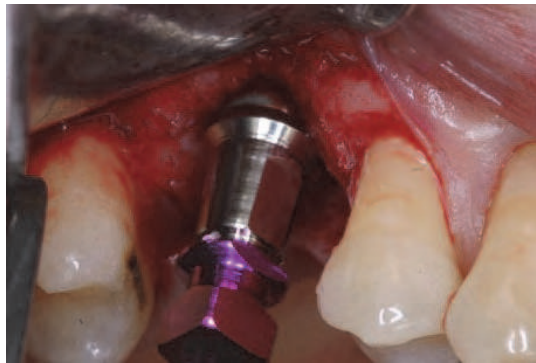

Fig. 42. 4.7mm wide and 11.5mm long HA coated implant is placed at the same time.

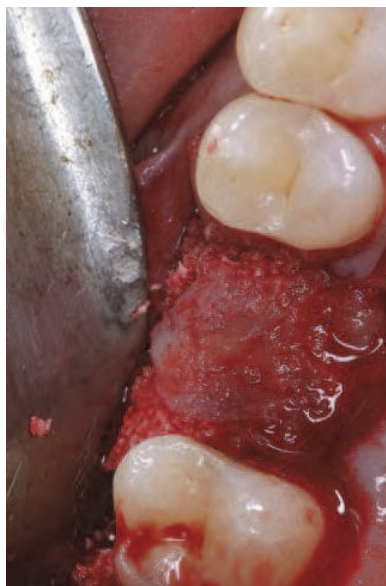

Fig. 43. Bovine bone is grafted in the defect around implant. CGF barrier is covered over the bone graft,

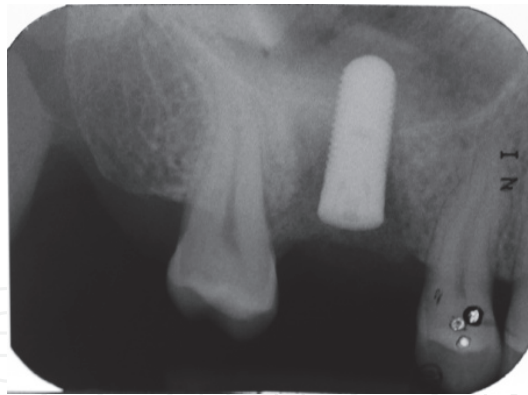


Fig. 44. A radiogram shows membrane elevation without bone graft.

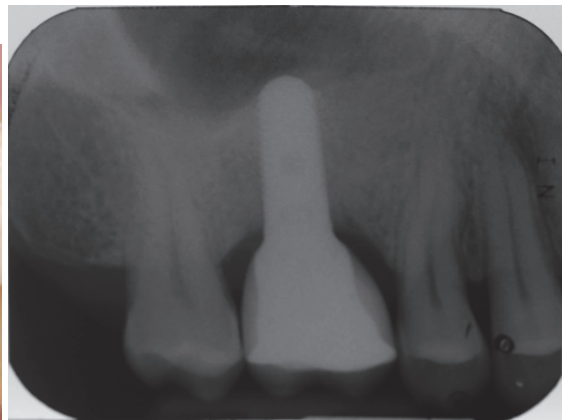
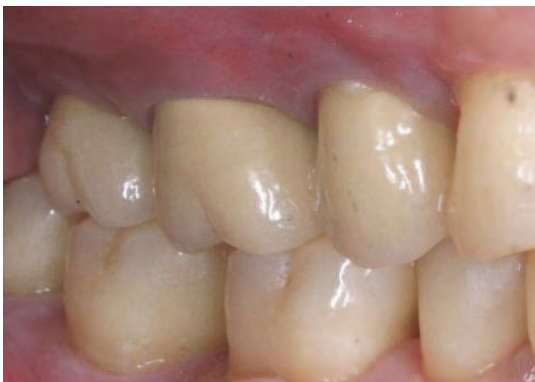
Fig. 45. (left) and Fig. 46. (right). Final prosthesis is cemented after 4 months healing. A radiogram shows sinus augmentation.

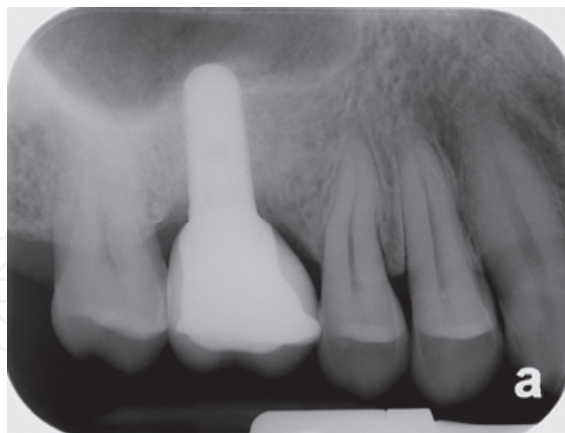


Fig. 47. A radiogram after 18 months loading. New bone formation is evident in the sinus without bone graft.

Surgical procedure of HPISE with bone graft (Fig. 48 – Fig. 60)

After elevating sinus membrane using water pressure, bone graft is optional. Bone graft in the new compartment under the elevated sinus membrane is indicated when heavy cyst is located in the sinus, more than 6mm high sinus elevation is required, implant is not placed simultaneously and postoperative radiopaque image is required to verify sinus elevation.

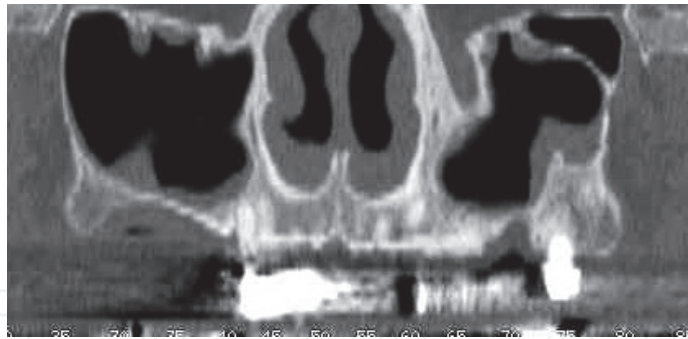


Fig. 48. 69 aged man was referred to my department for sinus and vertical ridge augmentation on the right posterior maxilla. He wants bone augmentation only. A radiogram shows very low bone height on the right posterior maxilla.

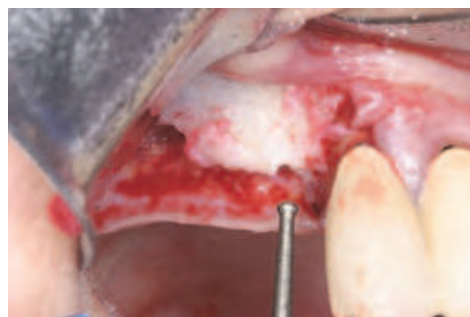

Fig. 49. Round carbide tip is used to break sinus floor at the implant sites.

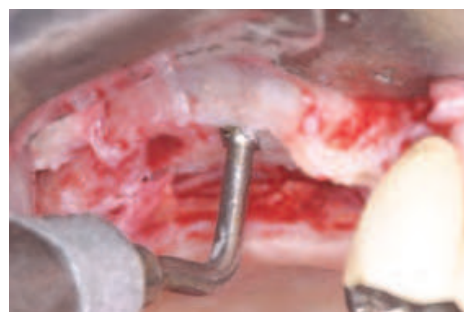

Fig. 50. HPSE tip is inserted into the sinus to elevate sinus membrane with water pressure.

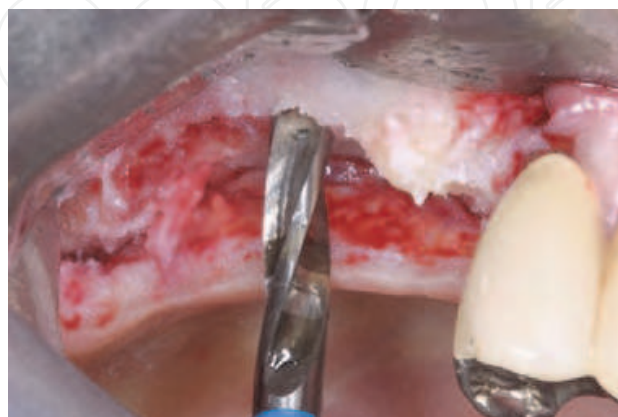


Fig. 51. In order to facilitate bone grafting, 4mm wide implant drill is used to expand the site of bone graft .

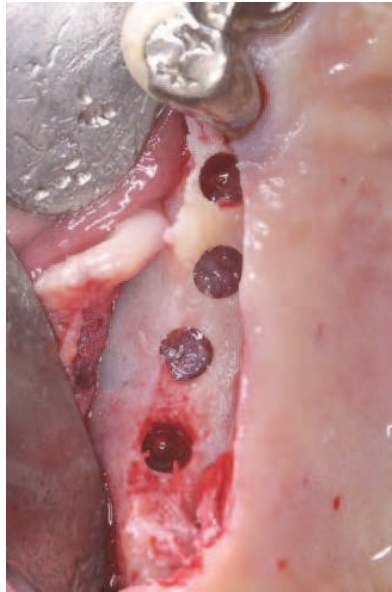


Fig. 52. Note detached sinus membrane from sinus floor. Whenever patient takes a breath, up and down movement of the membrane is seen.

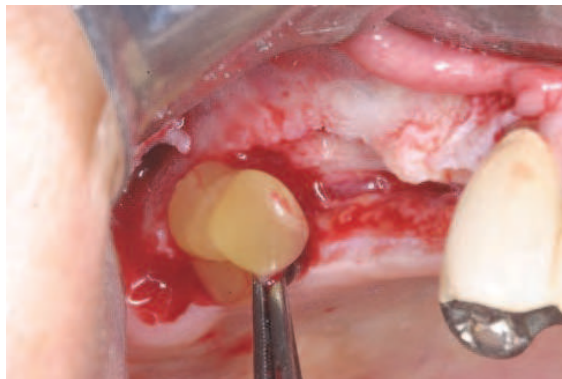


Fig. 53. CGF is inserted under the elevated sinus membrane. The CGF prevents membrane perforation as buffering effect during bone grafting and accelerates bone formation in the sinus.

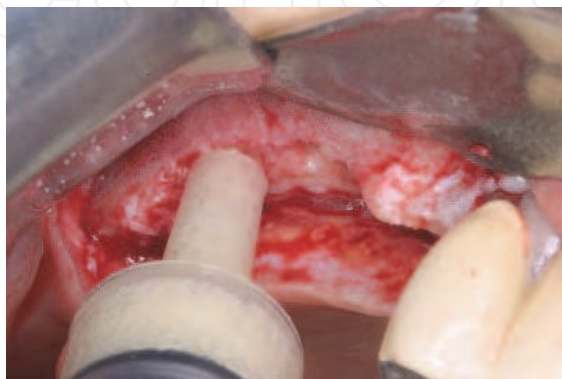

Fig. 54. Gel conditioned allograft is injected into the sinus cavity

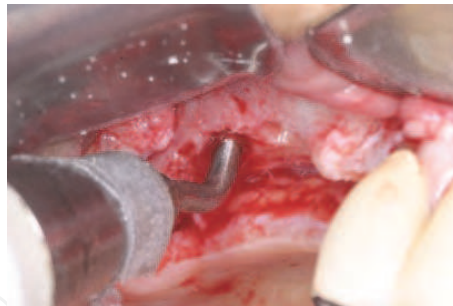


Fig. 55. Bone graft is compacted with HPISE tip

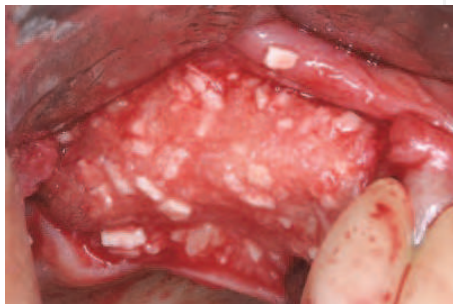

Fig. 56. Vertical bone defect is augmented with the mixture gel conditioned allograft and mineral allograft.

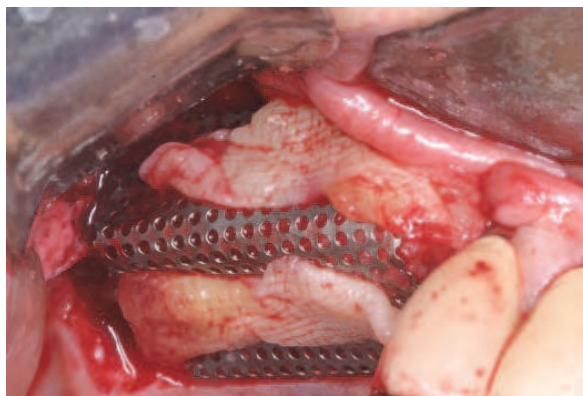


Fig. 57. Ti-mesh is stabilized with bone tack to stabilize bone graft. CGF is covered over the mesh to induce rapid soft tissue healing.

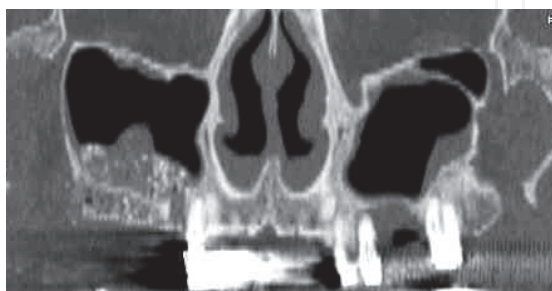


Fig. 58. Postoperative radiogram shows favorable sinus augmentation and ridge augmentation.

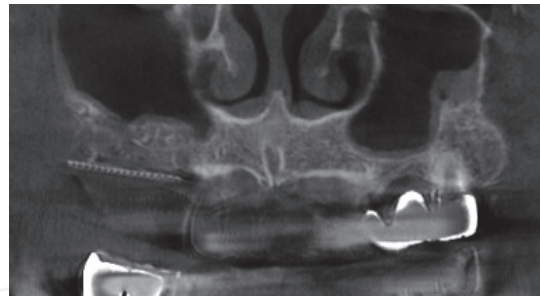


Fig. 59. A radiogram after 6 months healing. Sinus augmentation is evident.

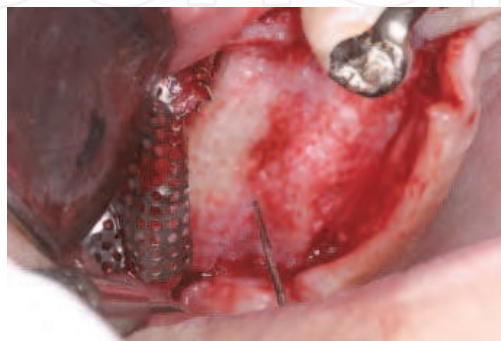


Fig. 60. Ti-mesh is removed after 6 months healing. Favorable edge augmentation is observed. The patient is referred to private clinic for implant placement.

231 implants were placed with HPISE technique at 3 centers from January 2008 to May 2010. 10 implants showed failure. Membrane perforation was developed in 14 implants (6.0% of perforation). CGF alone was inserted in the new compartment under the elevated sinus membrane in 127 implants (54.9%). Bone graft was used in 100 implants (43.2%). Collagen membrane was inserted in 3 implants (1.3%). Hyaloss matrix was used in 1 implant (0.4%). The success rate of implants was 96%. The success rate of HPISE is compatible to lateral window approach. However postoperative patient's discomfort is very minimal than lateral approached sinus augmentation.

4. Sinus augmentation using lateral window approach

Lateral window approach using various bone substitutes have been performed to overcome deficient bone volume on posterior maxillary ridge for decades.¹⁵⁻¹⁷ However some studies reported new bone formation in animal and human's sinus with membrane elevation alone, resorbable gelatin sponge alone, venous blood alone and autologous fibrin gel with concentrated growth factors alone as alternatives to bone materials.¹⁸⁻²⁵ According to these studies, bone substitutes may not be a prerequisite for sinus augmentation. The function of elevated sinus membrane is controversial, but some studies reported that sinus membrane acted as periosteum and showed osteoinductive potential.^{26, 27}

Sohn et al reported that significantly higher new bone formation was demonstrated in the sinus without bone graft than inorganic bovine bone grafted sinus.²³ According to this study, bone reformation in the new compartment under the elevated sinus membrane started from elevated sinus membrane and repositioned bony window. Osteoinductive function of sinus membrane seems to be similar to periosteum. Grafted bovine bone acted as

only space maker and scaffolding effect in this study. The key for bone reformation in the sinus is not grafting materials but space making under the elevated sinus membrane. Therefore simultaneous implant placement is required to maintain blood clot in the new compartment under the elevated sinus membrane when bone materials are not used.

4.1 New bone formation in the sinus with membrane elevation alone

Lundgren et al first reported radiographic finding of bone reformation in the sinus with membrane elevation alone in human. However the study didn't demonstrate histological evidence to verify new bone formation in the sinus.¹⁸ Palma et al demonstrated histologic evidence to verify new bone formation in the monkey's sinus. According to this study, no differences on new bone formation, implant stability and bone-implant contacts was demonstrated between two groups with and without adjunctive autogenous bone graft.¹⁹

Sohn et al. first demonstrated histological evidence of new bone formation in human maxillary sinuses with sinus membrane elevation alone and simultaneous implant placement.²²

Patient selection

Ten sinus surgeries were performed under local anesthesia. The subjects were divided into two groups according to the method of treating the lateral bony window of the sinus. Group A (five cases) used a non-resorbable membrane to seal the lateral window, but a replaceable bony window was used in Group B (five cases) to maintain blood clot in the sinus. The residual bone height of the edentulous site for implant placement varied from 1-9 mm (mean 5 mm). After average six months healing, implants were allowed to connect healing abutment and bone biopsy was performed through the site of previous bony window for histologic evaluation.

Surgical procedure of Group A (with barrier membrane)

A bony window was prepared with round carbide insert (S016®, BukBu Dental, Daegu, Korea) connected with ultrasonic piezoelectric device (Surgybone®, Silfradent srl, Sofia, Italy). After careful elevation of sinus membrane, two 4.2mm wide and 13mm high implants (Seven®, MIS implants Technologies Ltd, Shlomi, Israel) were inserted simultaneously (Fig. 61 - Fig. 62). The bony window was sealed with non-resorbable membrane (Gore-Tex®, W. L. Gore & Associates, INC. Flagstaff, Arizona, USA) and the membrane was stabilized with pin (TiTac™, IMTEC Co., Ardmore, USA) to retain the blood in the sinus (Fig. 63). The bony defect around dental implant was augmented with autogenous bone taken from bony portion of window and gel conditioned allograft (Orthoblast II®, IsoTis OrthoBiologics Inc, California, USA) and covered with a resorbable membrane (Tutoplast Pericardium®) over the bone graft (Fig. 64). Antibiotics (Levofloxacin, 100mg) and analgesics (Zaltoprofen, 80mg), three times a day for seven days, were give to all patients. Postoperative radiographic views were taken to confirm the implant position and to check coagulum formation after surgery (Fig. 65). After average six months healing, the CT scan was taken to evaluate new bone formation in the sinus (Fig. 66 and Fig. 67). Bone biopsy was performed through the site of previous bony window for histologic evaluation (Fig. 68). Follow up radiographic evaluation was continued after the placement of the final prosthetics and at follow-up after loading (Fig. 69 and Fig. 70).

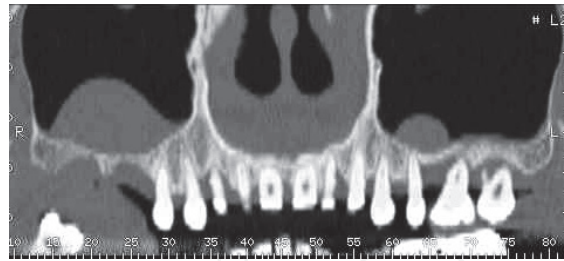


Fig. 61. Preoperative radiogram showing insufficient bone height in the right posterior maxilla.

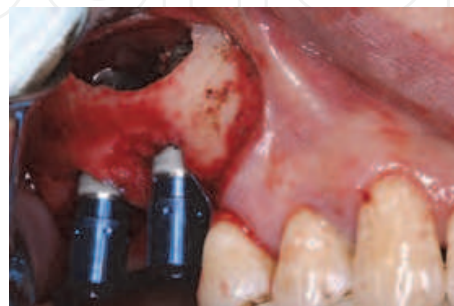

Fig. 62. The preparation of bony window is performed with round carbide tip, connected with ultrasonic piezoelectric device. After careful elevation of sinus membrane, two 13mm high implants is placed simultaneously to maintain space under the elevated sinus membrane.

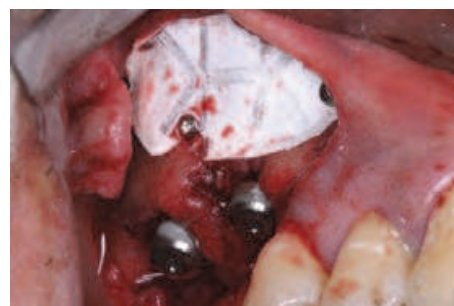

Fig. 63. The bony window is sealed with non-resorbable membrane to retain the blood in the sinus.

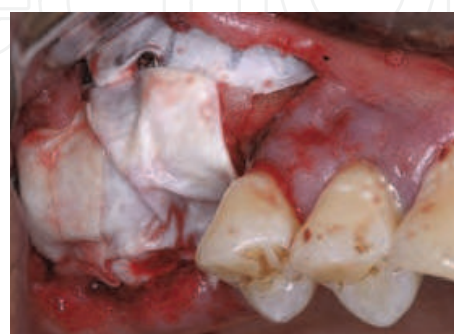


Fig. 64. The bony defect around dental implant is augmented with autogenous bone taken from bony portion of window and gel conditioned allograft, followed by covering with a resorbable membrane.

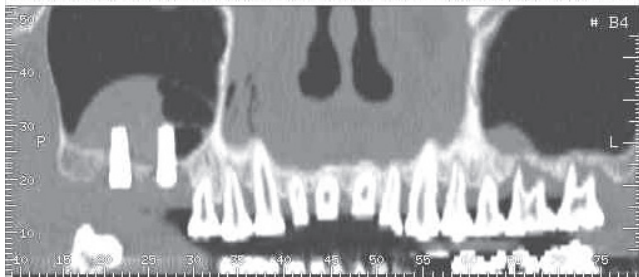

Fig. 65. Postoperative radiogram showing the elevation of sinus membrane.

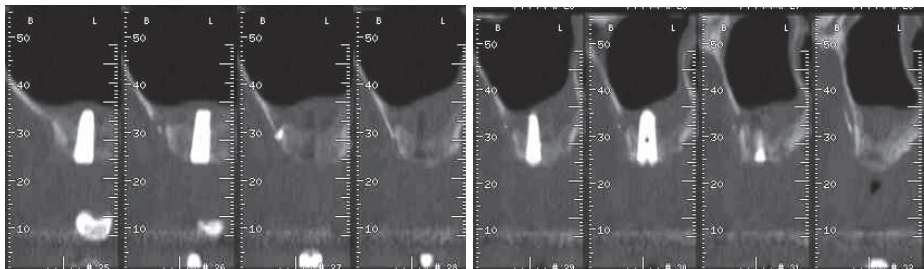


Fig. 66. (left) and 67. (right). CT scan shows bone reformation in the sinus after 6 months healing.

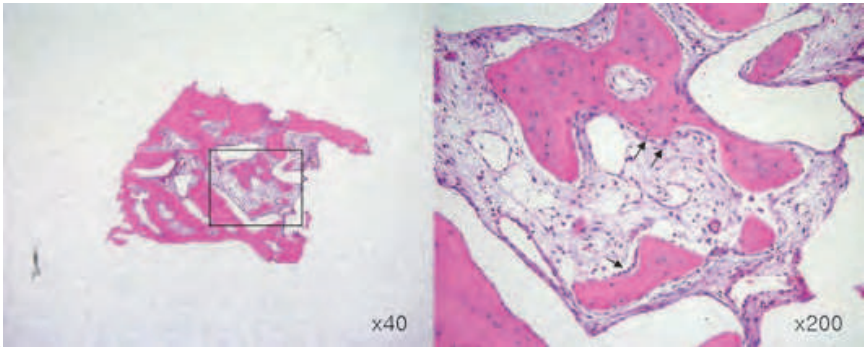


Fig. 68. Bone biopsy showing new bone formation in the sinus. Osteoblasts lines along newly formed bone (arrow). (H-E stain).

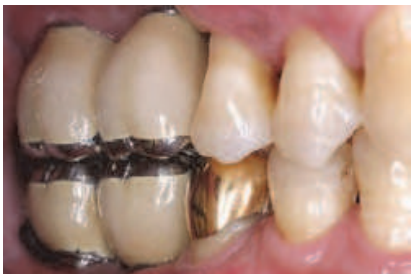

Fig. 69. Final prosthesis

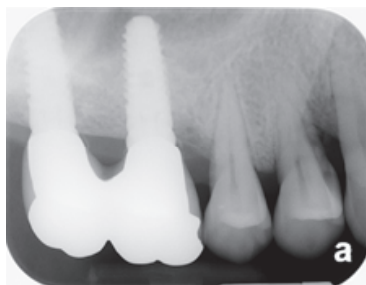


Fig. 70. Two years in function.

Surgical procedure of Group B (with replaceable bony window)

Full thickness mucoperiosteal flap was elevated to expose lateral wall of sinus cavity under local anesthesia. Saw insert with thin blade (S-saw®, BukBu Dental, Daegu, Korea) connected with ultrasonic piezoelectric device (Surgybone®) was tilted to lateral wall of sinus cavity to make replaceable bony window (Fig. 71 and Fig. 72). The bony window was carefully detached from the sinus membrane and the membrane was elevated superiorly very carefully to create new compartment to retain coagulum in the sinus. When membrane perforation was happened, resorbable collagen membrane (Tutoplast Pericardium®, Tutogen Medical GmbH, Neunkirchen am Brand, Germany) was covered over the perforation (Fig. 73 and Fig. 74). Three dental implants (Tapered Screw Vent implant, Zimmer Co) were placed at the same time (Fig. 75). The bony window was repositioned to hold blood in the sinus (Fig. 76). Postoperative care was as same as that of Group A. Postoperative radiograms and CT scans were taken immediately on surgery day and on the day of the uncovering (Fig. 77 – Fig 78). A bone biopsy was taken on the lateral access window area on the uncovering day after a six month healing period (Fig. 79). Follow up radiographic evaluation was continued after the placement of the final prosthetics (Fig. 80 – Fig. 81)

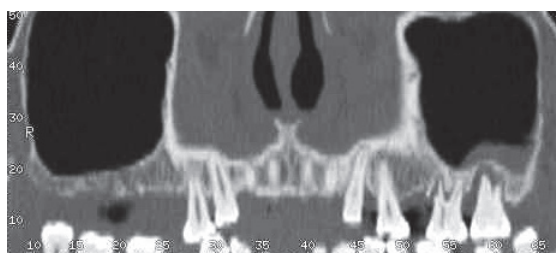


Fig. 71. Preoperative radiogram showing low bone height at right posterior maxilla.

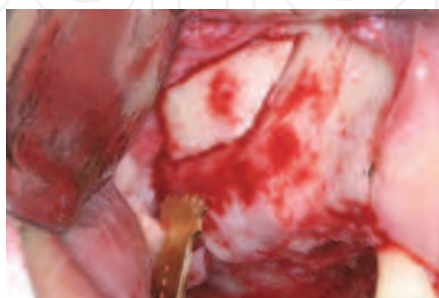

Fig. 72. Replaceable bony window is prepared with saw insert. Tilted osteotomy is made at anterior and inferior osteotomy line. The bony window is carefully detached from the sinus membrane.

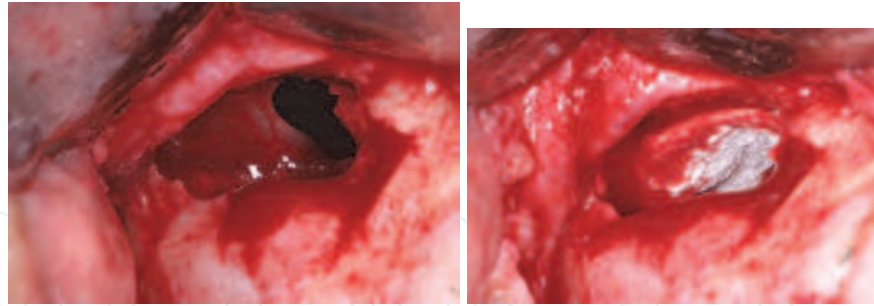


Fig. 73. (left) and Fig. 74. (right). Membrane perforation is happened during the elevation of membrane and resorbable collagen membrane is covered over the perforation.

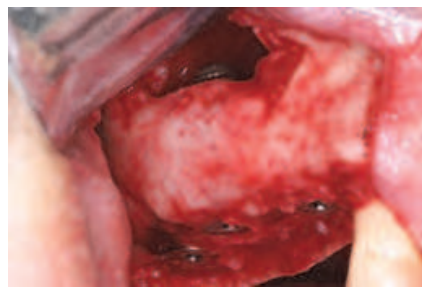


Fig. 75. Three dental implants are placed simultaneously with good stability.

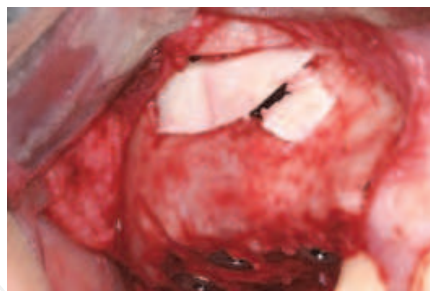

Fig. 76. The bony window is repositioned to seal the window.

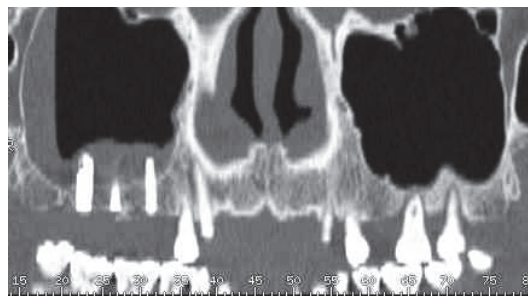

Fig. 77. Postoperative CT scan showing membrane elevation in the sinus.

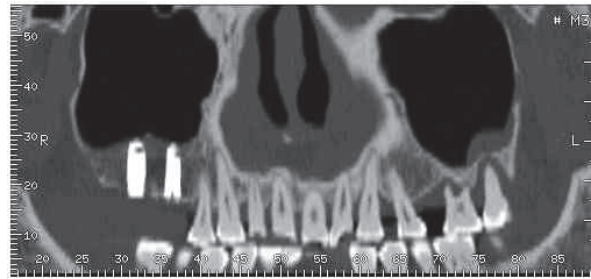


Fig. 78. CT scan shows newly formed bone in the sinus after 6 months healing.

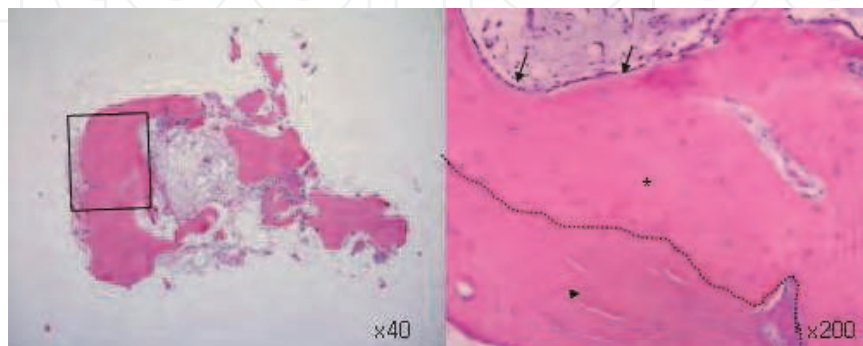


Fig. 79. Bone biopsy taken at the uncovering procedure reveals new bone formation (*) in the sinus. Arrow indicates osteoblasts and triangle indicates the bony portion of window.

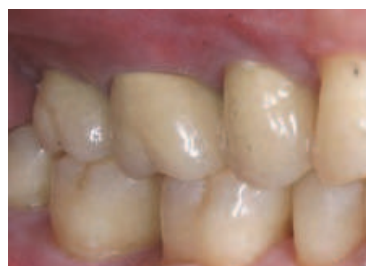

Fig. 80. Final prosthesis.

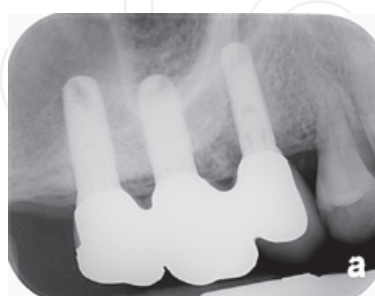

Fig. 81. Radiogram after 3 year and 8 months loading.

Results and discussion

A total of 21 implants were placed simultaneously and no implants showed osseointegration failure after the uncovering procedure. No postoperative infection was developed. All sinuses demonstrated new bone formation through clinical, radiographic

and histologic evaluations. All implant supported prosthesis was clinically stable after about 3 year follow-up. There are no differences on new bone formation between two groups. The most important factor is to induce new bone formation in the sinus is to maintain the space of new compartment under the elevated sinus membrane.

To prepare bony window, various cutting devices have been recommended. Rotary bur is a common instrument to make bony window, but high rate of membrane perforation is reported in some studies.²⁸⁻³⁰ Some studies reported lower rate of membrane perforation with piezoelectric round tip.³¹⁻³³ Current author compared the effect of two types of piezoelectric inserts – round and saw tip – on membrane perforation during creation of lateral bony window.³³ A total rate of membrane perforation using both kinds of piezoelectric insert at 5.51%. The rate of perforation created by the piezoelectric saw (7.14%) was relatively higher than that created by the round diamond insert (2.32%) in this study. But there was no significant difference between the rates for membrane perforation for the two types of piezoelectric inserts. According to this study, the piezoelectric saw insert has some advantages over the round inserts, such as precision, minimal bone loss, and facilitation of precise replacement of the bony window. In addition, replaceable bony window acts as osteoinductive barrier to accelerate new bone formation in the sinus.²³

4.2 New bone formation in the maxillary sinus using absorbable gelatin sponge alone

Maxillary sinus has a potential to induce new bone formation in the new compartment under the elevated sinus membrane. As demonstrated earlier, bone graft may not be prerequisite for sinus augmentation. So even though resorbable gelatin sponge is inserted in the compartment under the elevated sinus membrane for space making, bone reformation in the sinus is evident.^{24,34}

Patient selection

The study consisted of nine patients treated with sinus augmentation with resorbable gelatin sponge membrane and simultaneous implant placement. Seven patients (seven men and two woman), with age ranging from 40 to 75 (a mean age of 55.2 years), were included in this study. Preoperative examinations with panoramic views and dental cone-beam computed topographic scans (Combo®: Pointnix, Seoul, Korea or Implagraphy: Vatec, Kyungi, Korea) were performed. The bone height of remaining alveolar ridge was 1.5~7.2mm (average 4.7 mm). Bilateral sinus surgery was performed in three patients and unilateral sinus surgery was performed in six patients.

Surgical procedures

Prophylactic oral antibiotics, Cefditoren pivoxil (Meiact®; Boryung Parm., Seoul, Korea) 300mg t.i.d. were used routinely, beginning one day prior to the procedure and continuing for seven days. Surgery was performed under local anesthesia through maxillary block anesthesia by using 2% lidocaine that includes 1:100,000 epinephrine. After elevating of full thickness flap, the lateral wall of the maxillary sinus was exposed. Piezoelectric saw with thin blade (S-Saw, Bukbu Dental Co., Diego, Korea), connected to piezoelectric device (Surgybone®, Silfradent srl, Sofia, Italy), was used to create the lateral window of the maxillary sinus. The tilted osteotomy into sinus cavity was performed at anterior and inferior osteotomy line to facilitate the precise replacement of the bony window as a barrier

over inserted gelatin sponge in the maxillary sinus (Fig. 82- Fig. 83) . After careful elevation of the sinus membrane, the absorbable gelatin sponge (Cutanplast®, Mascia Brunelli Spa, Viale Monza, Italy) was inserted in the new compartment under the elevated sinus membrane. Twenty two Implants were placed at the same time. The bony portion of lateral window was repositioned to prevent soft tissue ingrowth into the sinus cavity and to promote new bone formation from the lateral wall of maxillary sinus (Fig. 84 - Fig. 87). Preoperative prophylactic antibiotic therapy was continued postoperatively for 7 days and the sutures were removed 14 days postoperatively. After sinus augmentation, postoperative panoramic radiographs and cone-beam CT scans were taken immediately after surgery. An average of 6 months was allowed for the implants to integrate. The implants were then uncovered and panoramic radiographs and dental cone-beam CT scans were obtained to assess the new bone formation around the implants. Follow up radiogram after loading was taken (Fig. 88-92).

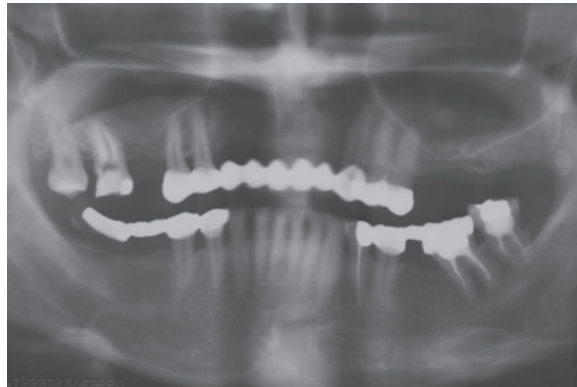


Fig. 82. Preoperative radiogram reveals pneumatization of bilateral maxillary sinus and insufficient bone height in both posterior maxilla.

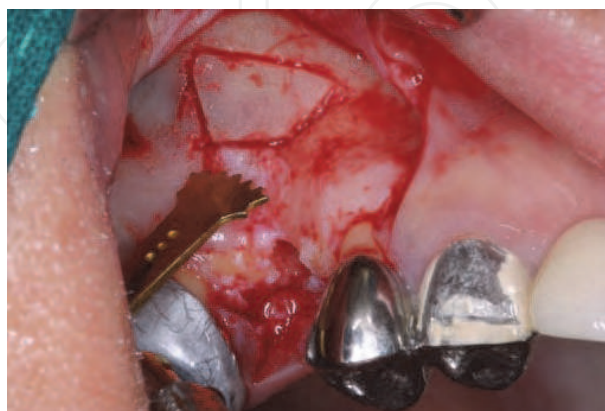

Fig. 83. Replaceable bony window is prepared with piezoelectric saw insert. The tilted osteotomy into the sinus cavity was made to facilitate the precise replacement of the bony window as a barrier over inserted gelatin sponge in the maxillary sinus.

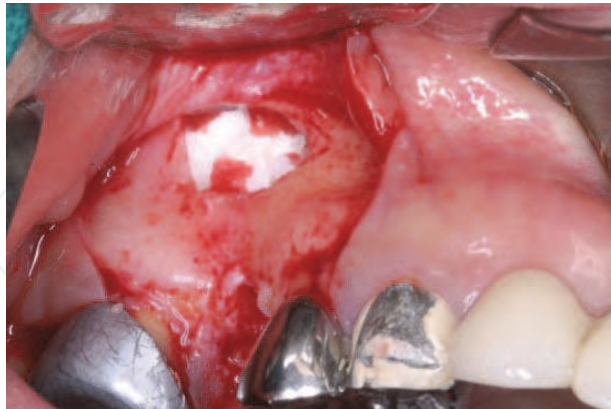


Fig. 84. After careful elevation of sinus membrane, gelatin sponge is inserted in the new compartment under the elevated membrane.

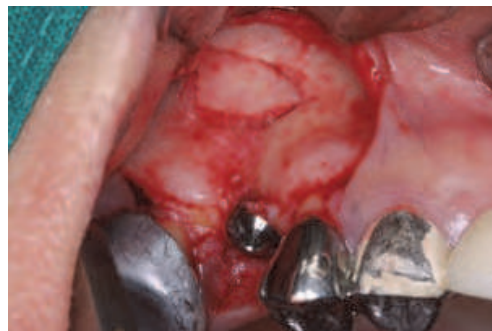

Fig. 85. Implant is placed at the same time and the bony window is repositioned. Ridge augmentation is performed at bony defect around implant.

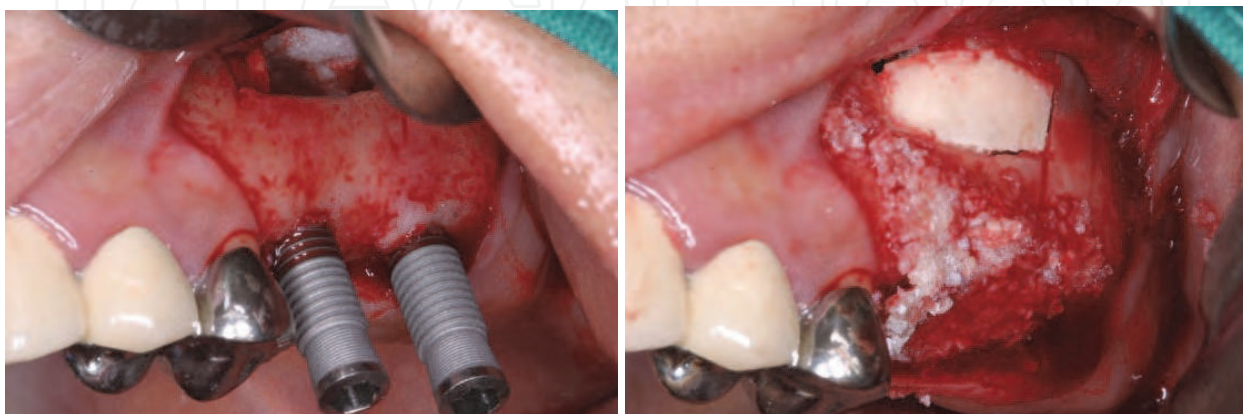


Fig. 86. and Fig. 87. Same procedure is performed in the left sinus.

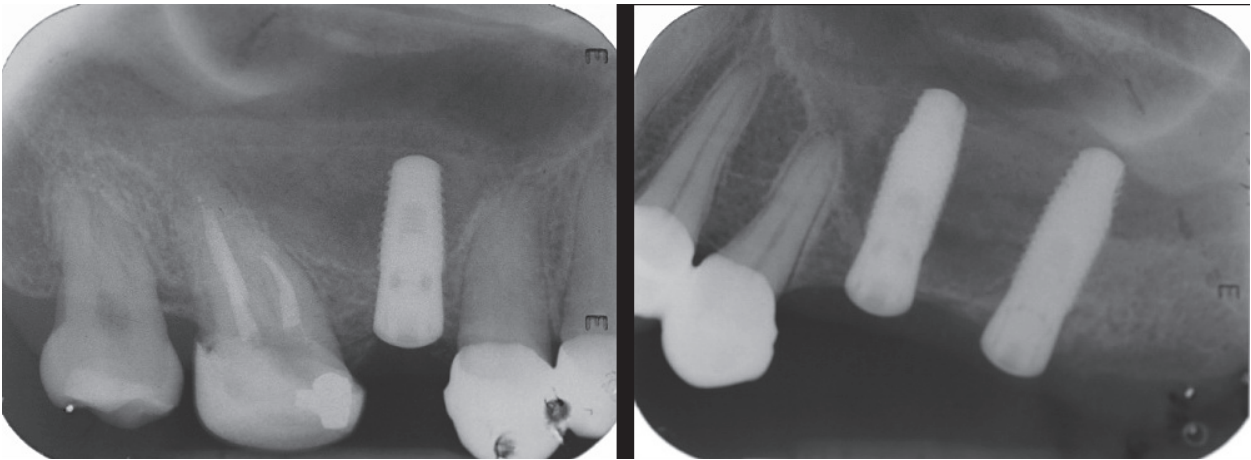


Fig. 88. Postoperative radiograms showing original sinus floor and no radiopaque image in the sinus

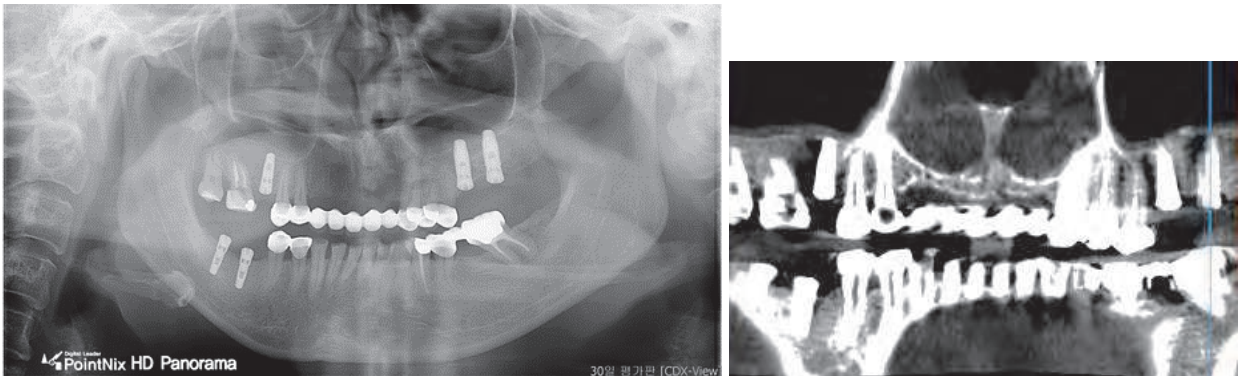


Fig. 89. (left) and Fig. 90. (right). Radiogram taken after 6 months healing reveals bone reformation in the both sinus.

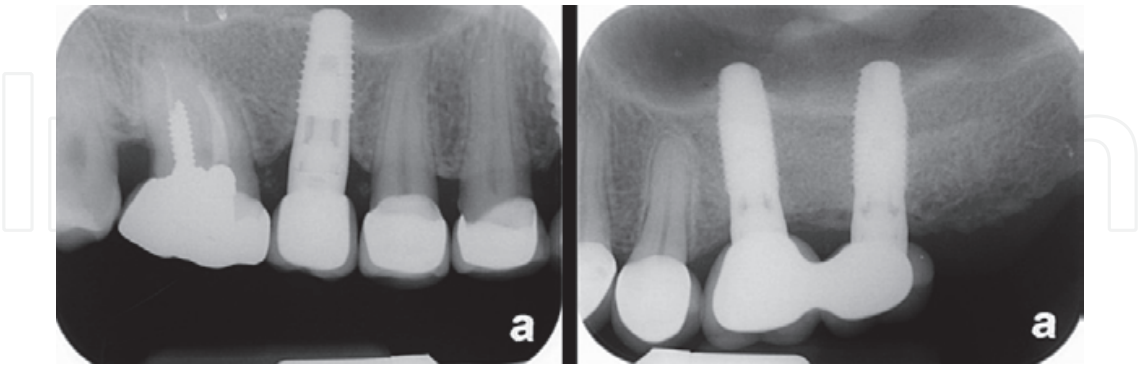


Fig. 91. A radiogram confirming bone reformation in the both sinus after 2 year loading.

Results and discussion

The membrane perforation was developed in two cases. Infection was not developed. New bone formation in the sinus was achieved in all cases using gelatin sponges alone after average six months healing period. Two RBM surfaced implants were failed after the uncovering procedure. The failures came from insufficient initial instability. This study

revealed that placement of dental implant with maxillary sinus with gelatin sponge appears to be predictable procedure for sinus augmentation and bone graft is not an essential factor for sinus augmentation.

4.3 Bone reformation in the maxillary sinus using peripheral venous blood alone

As described earlier in this chapter, bone graft is not a prerequisite for sinus augmentation when implant is placed simultaneously. According to Hatano et al and Moon et al's study,²¹ The insertion of peripheral venous blood as alternative to graft material can be safely used in maxillary sinus augmentation as demonstrated in this chapter.

Surgical procedure

The surgical procedure is as same as those demonstrated above except for the insertion of venous blood in the new compartment under the elevated sinus membrane (Fig. 92 – Fig. 98)

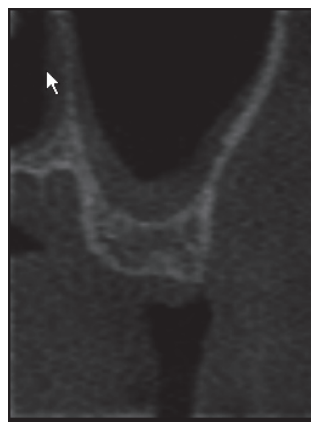

Fig. 92. Preoperative radiogram reveals approximately 6mm bone height at the site of left upper second molar.

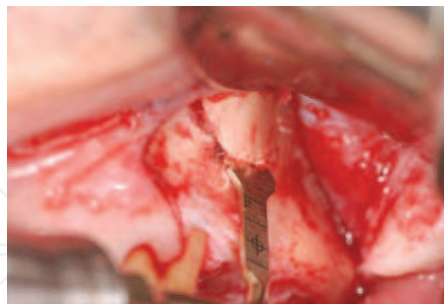


Fig. 93. After the elevation of a mucoperiosteal flap, lateral wall of sinus cavity is exposed. The piezoelectric saw with thin blade (S-Saw, Bukboo Dental Co., Daegu, Korea), connected to piezoelectric device (Surgystone®, Silfradent srl, Sofia, Italy), is used with copious saline irrigation to create the lateral window of the maxillary sinus. The anterior and inferior osteotomy line was created out of perpendicular to the sinus lateral wall, and then superior and posterior osteotomy were made perpendicular to the lateral wall. This design of osteotomy facilitates the precise replacement of the bony window as an osteoinductive barrier over injected venous blood in the maxillary sinus. The bony window was detached carefully to expose the sinus membrane. The sinus membrane is carefully elevated from the sinus floor walls with a manual elevator.

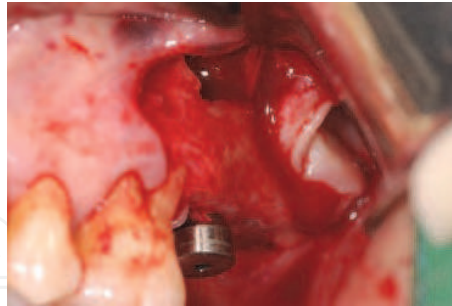


Fig. 94. A 4.1 mm wide and 13 mm high implant (SybronPRO™XRT implants, Sybron implant solution, California, USA) is placed after elevation of the sinus membrane. The collected peripheral venous blood taken from the brachial vein of patient's arm is injected to fill the new compartment of maxillary sinus.

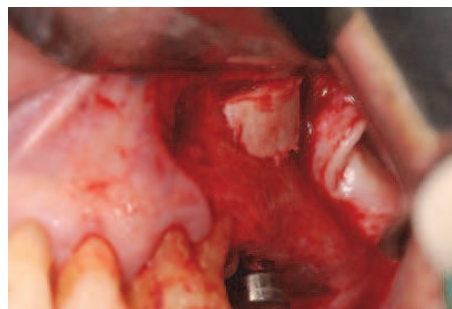

Fig. 95. The detached bony window is repositioned to prevent soft tissue ingrowth into the sinus cavity and to promote new bone formation from the lateral wall of maxillary sinus. This bony window acts as osteoinductive barrier.

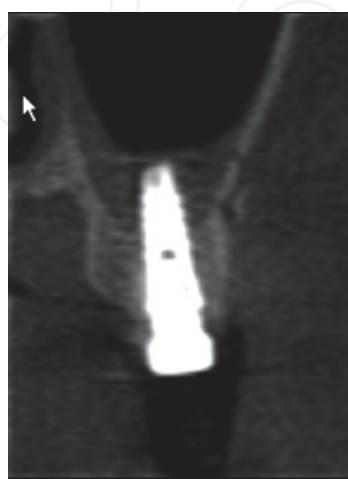


Fig. 96. A postoperative cone-beam CT scans shows venous blood filled sinus.

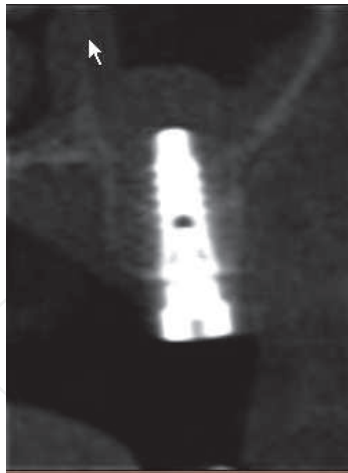


Fig. 97. 6 months healing is allowed for the osseointegration of implant. Cone beam CT shows newly formed bone in the sinus. During uncovering procedure, biopsy specimens is taken with 4 mm wide trephine bur at the site of repositioned bony window.

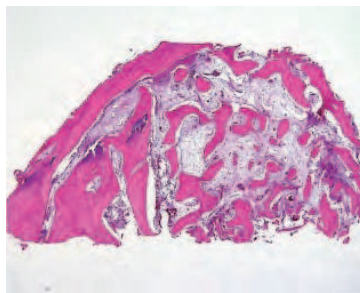


Fig. 98. Bone biopsy reveals active new bone formation. (H-E stain, x 40)

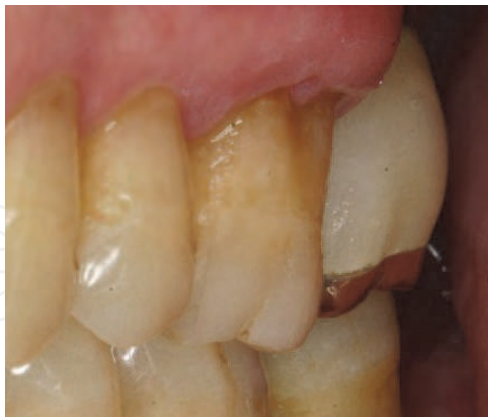

Fig. 99. Final prosthesis.

The peripheral venous blood under the elevated sinus membrane could to induce new bone formation in the maxillary sinus as shown on this case. The presence of a blood clot in healing of circumscribed bone defects was already reported ^{.36-37} Injection of collected venous blood could be a scaffold for new bone formation in the new compartment under the elevated membrane. The insertion of peripheral venous blood as a graft material can be a viable alternative to bone substitutes and safely used in maxillary sinus augmentation.

4.4 New bone formation in the maxillary sinus using fibrin rich gel with concentrated growth factors alone

Platelet aggregates, such as platelet rich plasma (PRP), platelet rich in growth factors (PRGF), platelet rich fibrin (PRF) and fibrin rich gel with concentrated growth factors alone (CGF) have been used to accelerate new bone formation associated with guided bone regeneration and sinus graft.³⁸⁻⁴⁰ Platelet aggregates are known to contain concentrated growth factors such as transforming growth factor (TGF- β 1), Platelet-derived growth factor and vascular endothelial growth factor and release slowly the growth factors. As alternative to bone filler in the sinus, the effect of fibrin rich block with concentrated growth factors (CGF) was already reported.⁴¹ Compared to platelet rich plasma or platelet rich in growth factors, fibrin rich gel with concentrated growth factors is simple to make and doesn't require any synthetic or biomaterials to make gel condition. So it is free from the risk of cross-contamination from bovine thrombin. (Fig 100)

According to current author and colleagues' unpublished study on 61 sinus augmentations using fibrin rich gel with concentrated growth factors alone, fast new bone formation in the sinus was apparent in the all sinus radiographically and histologically.⁴² Any significant postoperative complications were not developed. The success rate of implant was 98.2% after average 10 months loading. The study showed that the use of fibrin block with concentrated growth factor acts as alternative to a bone graft and can be a predictable procedure for sinus augmentation.




Fig. 100. (left). Fibrin rich block with concentrated growth factors (CGF) made by specific centrifuge (Medifuge®, Silfradent srl, Sofia, Italy). CGF is prepared with 20-60CC of patient's venous blood was taken from patients' vein in patient's forearm before sinus graft is performed. The blood in the test tubes is centrifuged at 2400-2700 rpm using specific centrifuge with a rotor turning at alternated and controlled speed for 12 minutes. The 2nd layer is fibrin buffy coat layer represented by a very large and dense polymerised fibrin block and the 3rd layer is a liquid phase containing the concentrated growth factors, white line cells and stem cells waiting for stimulation and to differentiate into specialized cell types. The second and third layer is known to have high concentration of growth factors. These two layers are inserted into the sinus cavity to accelerate new bone formation.

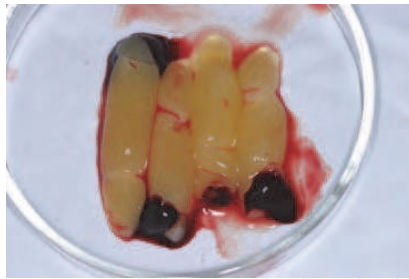

Fig. 101. This Fibrin rich block includes 2nd and 3rd layer of prepared CGF.

Surgical procedure

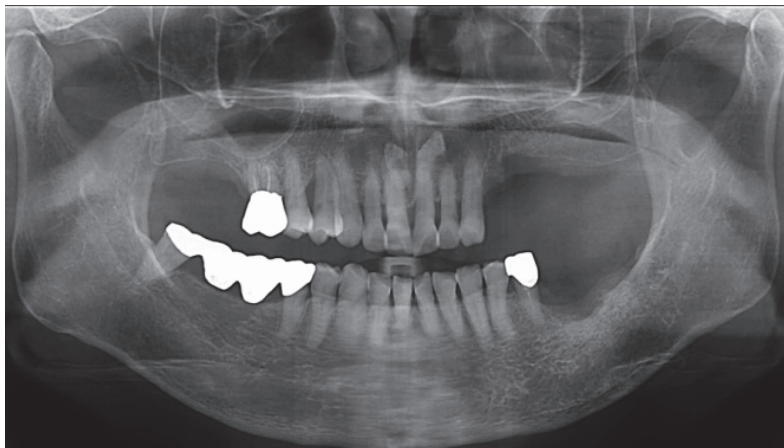


Fig. 102. Preoperative radiogram shows 5-6mm of bone height at left posterior maxilla.

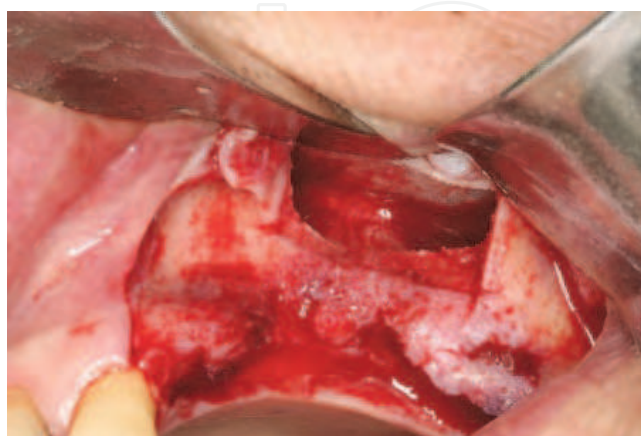

Fig. 103. The piezoelectric saw, connected to ultrasonic piezoelectric device (Surgybone), is used to create the replaceable lateral window of the maxillary sinus. Sinus membrane is carefully elevated to expose medial wall of sinus.

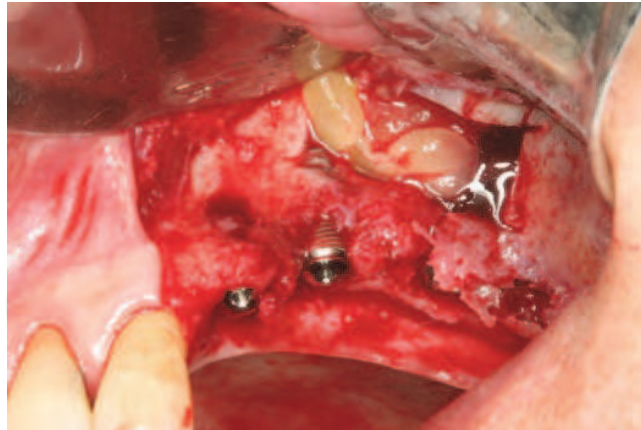


Fig. 104. Four pieces of fibrin rich gel are inserted in the new compartment between the elevated membrane and sinus floor. Three tapered design implants (Dentis implant, Dentis Inc, Daegu, Korea) is placed simultaneously

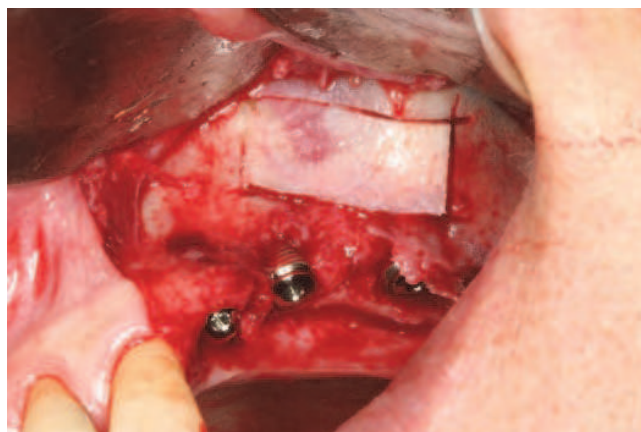

Fig. 105. The bony window was repositioned with stability to seal the window. Guided bone regeneration using mineral allograft and collagen membrane was performed to augment the bony defect around implants.

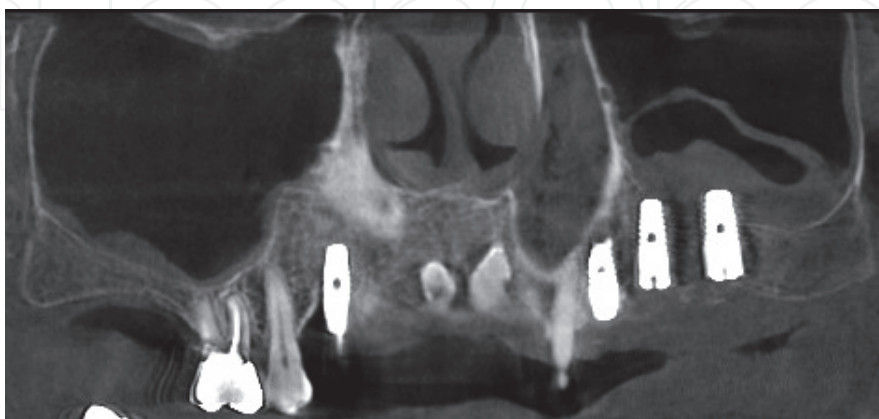

Fig. 106. Postoperative cone beam CT scans showing membrane elevation and implant placement in the left sinus.

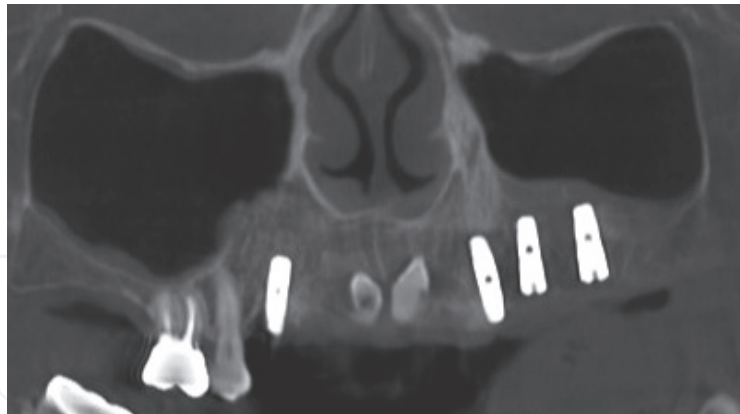


Fig. 107. Radiogram after 5 months healing. Bone reformation is evident in the left sinus

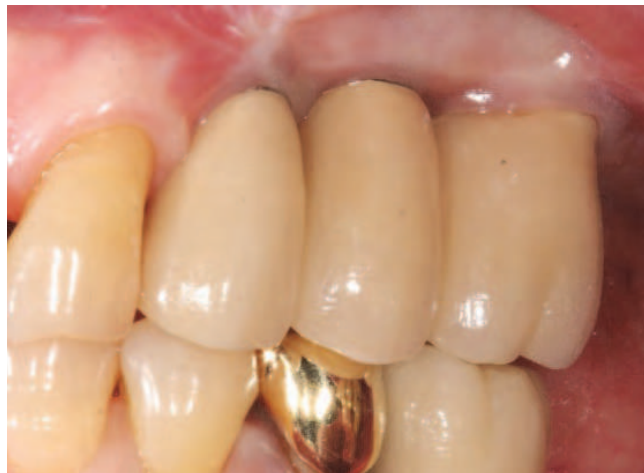

Fig. 108. Final prosthesis after 6 months loading

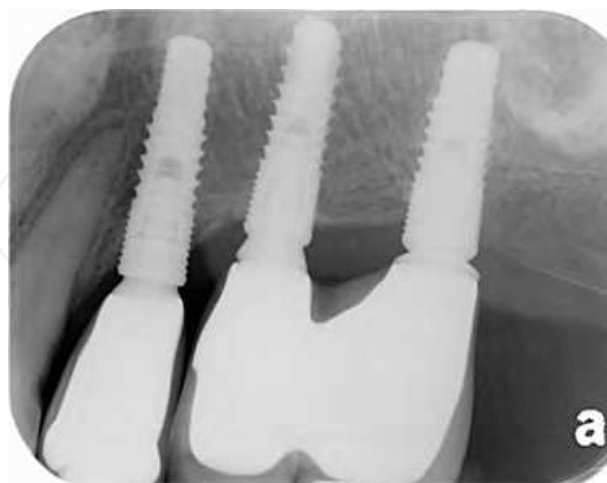

Fig 109. A periapical radiogram after 6 months loading.

As various studies on sinus augmentation without bone graft revealed earlier, bone graft may not be essential factor for sinus augmentation. The key is to maintain new space under the elevated sinus membrane.

No bone added sinus augmentation has many advantages such as

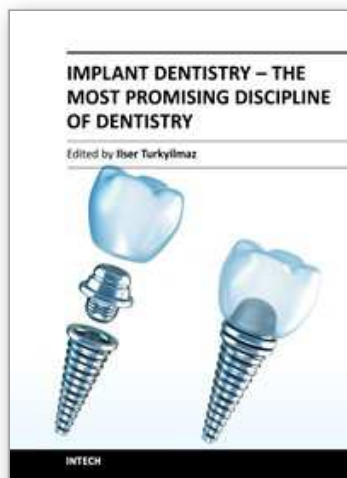
1. Infection is not reported.
2. Significant higher new bone formation is achieved than bone added sinus graft
3. Patient's morbidity is very low because the harvesting of autogenous bone is not required
4. The risk of cross contamination from bovine and human bone is eliminated.
5. Surgical cost can be reduced

5. References

- [1] Boyne PJ, James RA. Grafting of the maxillary sinus floor with autogenous marrow and bone. *J Oral Surg* 1980;38:613-616
- [2] Summers RB. The osteotome technique: Part 3-Less invasive methods of elevating the sinus floor. *Compendium*. 1994;15:698-708.
- [3] Sohn DS. Presented at hands on course on piezoelectric bone surgery. 2003;Oct 26.
- [4] Sohn DS, Lecture titled with clinical applications of piezoelectric bone surgery. 8th congress of international congress of oral implantologists. Singapore. 2004;Aug.28th.
- [5] Sohn DS, Lee JS, An KM, Choi BJ. Piezoelectric internal sinus elevation (PISE) technique: a new method for internal sinus elevation. *Implant Dent*. 2009;18(6):458-463
- [6] Chen L, Cha J. An 8-year retrospective study: 1100 patients receiving 1557 implants using the minimally invasive hydraulic sinus condensing technique. *J Periodontol*. 2005;76:482-491
- [7] Yamada JM, Park HJ. Internal sinus manipulation (ISM) procedure: a technical report. *Clin Implant Dent Relat Res*. 2007;9(3):128-135
- [8] Samuel Lee, Grace Kang, Kwang-Bum park, Thomas Han. Crestal sinus lift: A minimally invasive and systematic approach to sinus grafting. *J Implant Adv Clin Dent*. 2009;1(1):75-88.
- [9] Sohn DS, Moon JW, Ahn KM, et al. Minimally invasive sinus augmentation using hydrodynamic piezoelectric internal sinus elevation(HPISE). *Newspaper of Korean Dental Association*. 2008;1696:18-19.
- [10] Sohn DS, Maupin P, Fayos RP, et al, Minimally Invasive Sinus Augmentation using Ultrasonic Piezoelectric Vibration and Hydraulic Pressure. *J Implant Adv Clin Dent*. 2010;2:27-40 .
- [11] Girolamo MD, Napolitano B, Arullani CA, et al. Paroxysmal positional vertigo as a complication of osteotome sinus floor elevation. *Eur Arch Otorhinolarygol*. 2005; 262: 631-633.
- [12] Peñarrocha M, García A. Benign paroxysmal positional vertigo as a complication of interventions with osteotome and mallet. *J Oral Maxillofac Surg*. 2006; 64:1324.
- [13] Saker M, Ogle O. Benign paroxysmal positional vertigo subsequent to sinus lift via closed technique. *J Oral Maxillofac Surg*. 2005;63:1385-1387.
- [14] Rosen PS, Summers R, Mellado JR, Salkin LM, Shanaman RH, Marks MH, Fugazzotto PA. The bone-added osteotome sinus floor elevation technique: multicenter retrospective report of consecutively treated patients *Int J Oral Maxillofac Implants*. 1999 ;14(6):853-858
- [15] Misch CE. Maxillary sinus augmentation for endosteal implants: organized alternative treatment plans. *Int J Oral Implantol*. 1987;4:49-58.

- [16] Jemt T, Lekholm U. Implant treatment in edentulous maxillae: a 5-year follow-up report on patients with different degrees of jaw resorption. *Int J Oral Maxillofac Implants*. 1995;10:303-311.
- [17] Aghaloo TL, Moy PK. Which hard tissue augmentation techniques are the most successful in furnishing bony support for implant placement? *Int J Oral Maxillofac Implants*. 2007; 22:49-70.
- [18] Lundgren S, Andersson S, Gualini F, et al. Bone reformation with sinus membrane elevation: A new surgical technique for maxillary sinus floor augmentation. *Clinical Implant Dentistry and Related Research*. 2004; 6(3): 165-173.
- [19] Palma VC, Magro-Filho O, de Oliveira JA, et al. Bone reformation and implant integration following maxillary sinus membrane elevation: An experimental study in primates. *Clinical Implant Dentistry and Related Research*. 2006; 8(1): 11-24.
- [20] Nedir R, Bischof M, Vazquez L, et al. Osteotome sinus floor elevation without grafting material: a 1-year prospective pilot study with ITI implants. *Clin Oral Implants Res*. 2006; 17(6):679-86.
- [21] Hatano N, Sennerby L, Lundgren S. Maxillary sinus augmentation using sinus membrane elevation and peripheral venous blood for implant-supported rehabilitation of the atrophic posterior maxilla: case series. *Clin Implant Dent Relat Res*. 2007;9:150-155.
- [22] Sohn DS, Lee JS, Ahn MR, et al. New bone formation in the maxillary sinus without bone grafts. *Implant Dent* 2008;17:321-331.
- [23] Sohn DS, Kim WS, An KM, et al. Comparative histomorphometric analysis of maxillary sinus augmentation with and without bone grafting in rabbit. *Implant Dent*. 2010;19(3):259-270
- [24] Sohn DS, Moon JW, Moon KN, et al. New bone formation in the maxillary sinus using only absorbable gelatin sponge. *J Oral Maxillofac Surg*. 2010;68(6):1327-1333.
- [25] Sohn DS, Moon JW, Moon YS, et al. The use of concentrated growth factor(CGF) for sinus augmentation. *The Journal of Oral Implants*. 2009;38: 25-38.
- [26] Gruber R, Kandler B, Fuerst G, et al. Porcine sinus mucosa holds cells that respond to bone morphogenetic protein (BMP)-6 and BMP-7 with increased osteogenic differentiation in vitro. *Clin Oral Implants Res*. 2004;15:575-580.
- [27] Srouji S, Kizhner T, Ben David D, et al. The Schneiderian membrane contains osteoprogenitor cells: in vivo and in vitro study. *Calcif Tissue Int*. 2009;84:138-145.
- [28] Schwartz-Arad D, Herzberg R, Dolev E. The prevalence of surgical complications of the sinus graft procedure and their impact on implant survival. *J Periodontol* 2004;75:511-516.
- [29] Pikos MA. Maxillary sinus membrane repair: Report of a technique for large perforations. *Implant Dent* 1999;8:29-34.
- [30] Proussaefs P, Lozada J, Kim J, Rohrer MD. Repair of the perforated sinus membrane with a resorbable collagen membrane: A human study. *Int J Oral Maxillofac Implants* 2004;19:413-420.
- [31] Wallace SS, Mazor Z, Froum SJ, Cho SC, Tarnow DP. Schneiderian membrane perforation rate during sinus elevation using piezosurgery: Clinical results of 100 consecutive cases. *Int J Periodontics Restorative Dent* 2007;27:413-419.

- [32] Blus C, Szmukler-Moncler S, Salama M, Salama H, Garber D. Sinus bone grafting procedures using ultrasonic bone surgery: 5-year experience. *Int J Periodontics Restorative Dent* 2008;28: 221-229.
- [33] Sohn DS, Moon JW, Lee HW, et al. Comparison of two piezoelectric cutting inserts for lateral bony window osteotomy: a retrospective study of 127 consecutive sites. *Int J Oral Maxillofac Implants*. 2010 ;25(3):571-576.
- [34] Sohn DS, Moon JW, Moon KN, et al. New bone formation in the maxillary sinus with elevation of sinus membrane and graft of resorbable gelatin sponge : case series report. *Implantology* 2008; 12-2:26~34.
- [35] Moon JW, Son DS, Heo JU, et al. New Bone Formation in the Maxillary Sinus Using Peripheral Venous Blood Alone. Accepted for publication in *J Oral Maxillofac Surg*.
- [36] Melcher AH, Dreyer CJ. Protection of the blood clot in healing of circumscribed bone defects. *Journal of Bone Joint Surgery* 1962;22:424-429.
- [37] Thor A, Rasmusson L, Wennerberg A, Thomsen P, Hirsch JM, Nilsson B, Hong J. The role of whole blood in thrombin generation in contact with various titanium surfaces. *Biomaterials*. 2007;28:966-974.
- [38] Anitua E, Orive G, Pla R, Roman P, Serrano V, Andía I. The effects of PRGF on bone regeneration and on titanium implant osseointegration in goats: a histologic and histomorphometric study. *J Biomed Mater Res A*. 2009 ;91(1):158-165.
- [39] Choukroun J, Diss A, Simonpieri A, Girard MO, Schoeffler C, Dohan SL, Dohan AJ, Mouhyi J, Dohan DM. Platelet-rich fibrin (PRF): a second-generation platelet concentrate. Part V: histologic evaluations of PRF effects on bone allograft maturation in sinus lift. *Oral Surg Oral Med Oral Pathol Oral Radiol Endod*. 2006;101(3):299-303.
- [40] Corigliano M., Sacco L., Baldoni E. CGF- una proposta terapeutica per la medicina rigenerativa. *Odontoiatria n°1- anno XXIX- maggio 2010*, 69-81. Sohn DS, Moon JW, Moon YS, et al.
- [41] The use of concentrated growth factor(CGF) for sinus augmentation. *The Journal of Oral Implants*. 2009;38: 25-38
- [42] Sohn DS, He JU, Kwak DH, et al. Bone regeneration in the maxillary sinus using autologous fibrin rich block with concentrated growth factors alone. Submitted to *Implant Dent*



Implant Dentistry - The Most Promising Discipline of Dentistry

Edited by Prof. Ilser Turkyilmaz

ISBN 978-953-307-481-8

Hard cover, 476 pages

Publisher InTech

Published online 30, September, 2011

Published in print edition September, 2011

Since Dr. Branemark presented the osseointegration concept with dental implants, implant dentistry has changed and improved dramatically. The use of dental implants has skyrocketed in the past thirty years. As the benefits of therapy became apparent, implant treatment earned a widespread acceptance. The need for dental implants has resulted in a rapid expansion of the market worldwide. To date, general dentists and a variety of specialists offer implants as a solution to partial and complete edentulism. Implant dentistry continues to advance with the development of new surgical and prosthodontic techniques. The purpose of *Implant Dentistry - The Most Promising Discipline of Dentistry* is to present a contemporary resource for dentists who want to replace missing teeth with dental implants. It is a text that integrates common threads among basic science, clinical experience and future concepts. This book consists of twenty-one chapters divided into four sections.

How to reference

In order to correctly reference this scholarly work, feel free to copy and paste the following:

Dong-Seok Sohn (2011). New Bone Formation in the Maxillary Sinus With/Without Bone Graft, *Implant Dentistry - The Most Promising Discipline of Dentistry*, Prof. Ilser Turkyilmaz (Ed.), ISBN: 978-953-307-481-8, InTech, Available from: <http://www.intechopen.com/books/implant-dentistry-the-most-promising-discipline-of-dentistry/new-bone-formation-in-the-maxillary-sinus-with-without-bone-graft>

INTech
open science | open minds

InTech Europe

University Campus STeP Ri
Slavka Krautzeka 83/A
51000 Rijeka, Croatia
Phone: +385 (51) 770 447
Fax: +385 (51) 686 166
www.intechopen.com

InTech China

Unit 405, Office Block, Hotel Equatorial Shanghai
No.65, Yan An Road (West), Shanghai, 200040, China
中国上海市延安西路65号上海国际贵都大饭店办公楼405单元
Phone: +86-21-62489820
Fax: +86-21-62489821

© 2011 The Author(s). Licensee IntechOpen. This chapter is distributed under the terms of the [Creative Commons Attribution-NonCommercial-ShareAlike-3.0 License](https://creativecommons.org/licenses/by-nc-sa/3.0/), which permits use, distribution and reproduction for non-commercial purposes, provided the original is properly cited and derivative works building on this content are distributed under the same license.

IntechOpen

IntechOpen