

We are IntechOpen, the world's leading publisher of Open Access books Built by scientists, for scientists

6,900

Open access books available

186,000

International authors and editors

200M

Downloads

Our authors are among the

154

Countries delivered to

TOP 1%

most cited scientists

12.2%

Contributors from top 500 universities



WEB OF SCIENCE™

Selection of our books indexed in the Book Citation Index
in Web of Science™ Core Collection (BKCI)

Interested in publishing with us?
Contact book.department@intechopen.com

Numbers displayed above are based on latest data collected.
For more information visit www.intechopen.com



Epilepsy in Mitochondrial Disorders

Silvana Franceschetti¹, Graziella Uziel²,
Eleonora Lamantea³, Gianfranco Carrara³,
Carlo Antozzi⁴, Massimo Zeviani³ and Laura Canafoglia¹

¹*From the Department of Neurophysiopathology and Epilepsy Centre,*

²*Child Neurology,*

³*Biochemistry and Medical Genetics,*

⁴*Myopathology, IRCCS Foundation Neurological Institute Carlo Besta, Milan, Italy*

1. Introduction

Mitochondrial encephalopathies (MEs) are characterized by an extreme clinical heterogeneity since they can involve different systems and manifest at distinct ages with variable course. Many affected individuals display a cluster of clinical features that fall into discrete syndromes - among syndromic pictures, epilepsy is relevant in myoclonic epilepsy with ragged-red fibers (MERRF), mitochondrial encephalomyopathy with lactic acidosis and stroke-like episodes (MELAS), neurogenic weakness with ataxia and retinitis pigmentosa (NARP), Alpers' encephalopathy and Leigh syndrome (LS). However, many patients do not fit neatly into one particular syndrome, due to "overlapping" presentations (sharing symptoms of different syndromes) or atypical clusters of symptoms.

Epilepsy is a frequent symptom also in non-syndromic patients, sometimes dominating the clinical presentation.

2. Genetics

Mitochondrial disorders derive from mutations of mitochondrial (mtDNA) or nuclear DNA (nDNA), which lead to the impairment of the mitochondrial respiratory chain activity or mitochondrial ATP synthesis. Mitochondrial disorders typically involve tissues or organs with high energy demand including peripheral nervous system (PNS), central nervous system (CNS), eyes, ears, heart, endocrine system, kidney, guts, and liver. Fever, infection and stress may aggravate the neurological symptoms.

Generally, the genotype-phenotype correlation in mitochondrial disorders is poor, since the clinical phenotype is not only dependent on the type and pathogenicity of the DNA mutation, but it may also derive from other genetic and environmental factors.

A possible mechanism of inheritance is maternal transmission of the mutations located in the mtDNA. It is noteworthy that variable amounts of the mutated mtDNA (mutation load) usually coexist with wild-type molecules in the different tissues, resulting in a "heteroplasmic state". Moreover, the phenotypic expression of mtDNA mutations may be dependent on a threshold effect, which can be dissimilar in different tissues, in relation to

specific energy demand. Nuclear “modifier” genes, environmental factors, mtDNA haplotypes (polymorphisms) or clusters of mtDNA variants could also influence the expression of mtDNA.

The mtDNA contains 37 genes: 13 encoding for subunits of the respiratory chain complexes I (ND1–6, ND4L), III (cytochrome b), IV (COX I–III) and V (ATPase6, ATPase8) (oxidative phosphorylation system, OXPHOS); 22 encoding for transfer RNAs (tRNAs); 2 for ribosomal RNAs (rRNAs). The mitochondrial genetic code differs from the universal genetic code since mtDNA is not protected by any repair mechanism, thus resulting prone to mutations; indeed mutation rates of mtDNA are 10 times higher than those of nDNA.

MtDNA mutations are classified as either large-scale rearrangements (partial deletions or duplications) or point mutations. Rearrangements are frequently sporadic, while point mutations are commonly inherited.

The nuclear genome encodes more than 95% of all proteins located in the mitochondria. An increasing number of clinical conditions have been associated with nDNA mutations, which may involve different genes. These genes have been divided into four groups, according to their function. First group includes genes encoding for structural components of the respiratory chain; second group genes encoding for assembly factors of the respiratory chain complexes; third group genes responsible for factors of mtDNA stability; fourth group genes involved in biogenesis of mitochondria (Finsterer, 2006). Mutations of the nDNA are inherited by autosomal mechanism.

Nuclear-mitochondrial interactions play a fundamental role in cellular homeostasis. The optimal interaction between nuclear and mitochondrial encoded factors is essential for transcription and translation of mtDNA and also for the correct assembly and function of the OXPHOS system.

In both maternal and autosomal inherited MEs, single or multiple defects of the respiratory chain can be detected in the blood cells or muscular specimens. However, biochemical analysis can also identify defective activity of the respiratory chain complexes (in particular complex I and IV) in case of mitochondrial DNA depletion (see for example the mtDNA depletion syndrome 4A, due to mutation in the nuclear gene encoding for mitochondrial polymerase gamma) or multiple deletions.

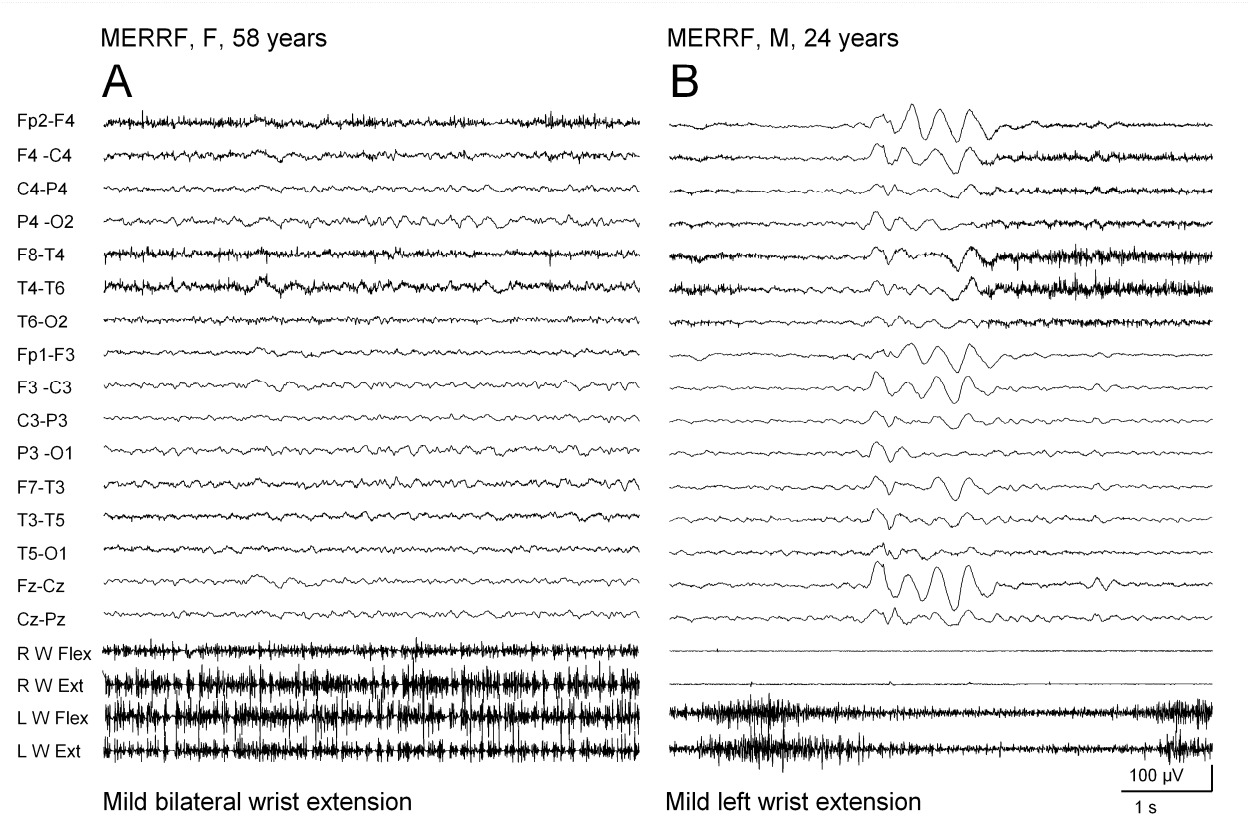
3. Maternally inherited syndromes with epilepsy, associated with mtDNA mutations

Among MEs characterized by maternal inheritance, generalized seizures and myoclonus are the main symptoms of *MERRF* (myoclonus epilepsy with ragged-red fibers) syndrome (MIM ID #545000). This syndrome, initially described by Fukuhara et al (1980), is characterized by myoclonus, seizures, progressive cerebellar syndrome, and ragged-red fibers in muscle biopsy. It can be due to mutations in more than one mitochondrial gene, e.g. *MTTK*, *MTTL1*, *MTTH*, *MTTS1*, *MTTS2*, *MTTF* and *MTND5*. However, a specific mtDNA mutation of the tRNA(Lys) gene (*MTTK*), implying an A-to-G transition at nucleotide 8344, accounts for 80 to 90% of *MERRF* cases (Shoffner and Wallace, 1992). Biochemically, this mutation produces multiple deficiencies in the enzyme complexes of the respiratory chain (typically complexes I and IV), consistent with a defect in translation of all mtDNA-encoded genes.

A typical *MERRF* picture was observed in a patient bearing a mutation of the *MTTF* gene which codes tRNA(Phe) (Mancuso et al, 2004).

Myoclonus epilepsy may manifest at variable age and can associate with other symptoms including general weakness, muscle wasting, deafness, dementia, short stature, optic atrophy, peripheral neuropathy, cardiomyopathy, myoglobinuria and renal tubular dysfunction (Wu et al, 2010).

As an example of the heterogeneity affecting also well defined ME with epilepsy, we report here some features of a MERRF family, bearing the common MTTK mutation, including four affected siblings with similar symptoms, but clinically different severity. The proband, previously described by Roger et al. (1982), had typical and severe progressive myoclonus epilepsy associated with optic atrophy. His brother showed occasional seizures and photoparoxysmal EEG response. His sister had late-onset action myoclonus and photoparoxysmal EEG response (figure 1).



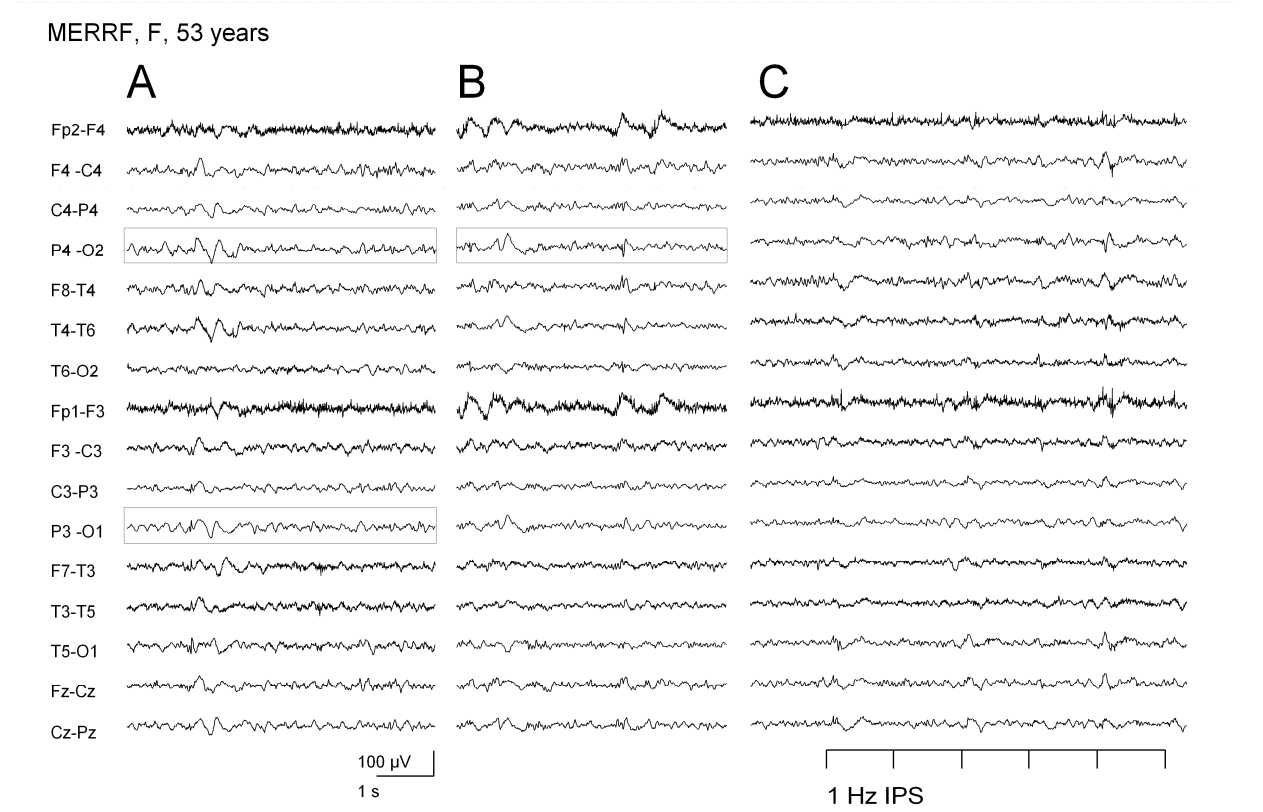
A: EEG recording of a 58 years-old female patient with MERRF syndrome showing slow background activity and diffuse slow waves; EMG recording includes positive and negative myoclonic jerks. B: EEG recording of the 24 years-old son of the previous patient showing a sequence of diffuse slow waves; in this case, EMG shows regular muscular contraction.

Fig. 1. Heterogeneous EEG-EMG features in the same family with MERRF syndrome

His nephew showed decreased visual acuity, associated with photosensitive (but not action-induced) myoclonus (figure 2).

MELAS (MIM ID #540000) syndrome is characterized by mitochondrial myopathy, encephalopathy, lactic acidosis, and stroke-like episodes. The disorder is characterized by symptoms and signs of central nervous system involvement, including seizures, migraine, hemiparesis, hemianopsia, cortical blindness, and episodic vomiting. Other common symptoms are: hearing loss, reduced statural growth, diabetes (Ciafaloni et al, 1992).

MELAS syndrome can be caused by mutation in several genes of the mtDNA coding for tRNA or polypeptides, including MTTL1, MTTQ, MTTH, MTTK, MTTs1, MTND1, MTND5, MTND6, and MTTs2. The 3243A-G transition in the MTTL1 gene can be found in about 80% of the patients (Goto et al, 1992).



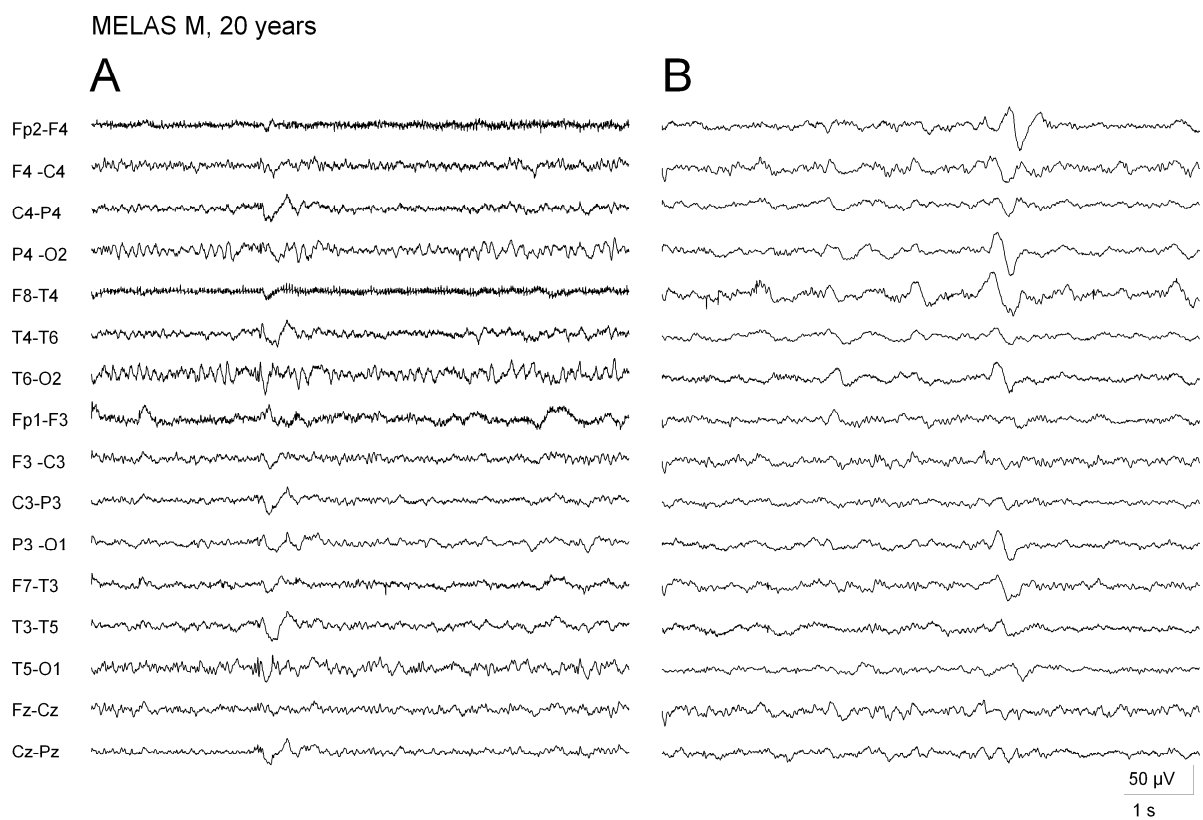
A and B: EEG recording of a female patient with MERRF syndrome showing diffuse spike and slow waves prevalent on posterior derivations (boxes) with occasional spontaneous occurrence. C: Intermittent photic stimulation (IPS) induces an increase of the epileptic discharges.

Fig. 2. Spontaneous and photically-induced epileptiform abnormalities in MERRF syndrome

In MELAS syndrome, epilepsy is a frequent symptom; seizures are often of motor type and can be grouped in clusters (until the extreme picture of *epilepsia partialis continua*) even without the evidence of concomitant new acute brain insult (Canafoglia et al, 2004). However, a relationship between clusters of seizures and stroke-like episodes is common: focal neuronal hyperexcitability or epileptic activity may cause an increase of ATP demand which can be followed by depletion of ATP and consecutive vasogenic edema (Iizuka et al, 2002 ; 2003). Finally, the vasogenic edema turns into laminar necrosis indicated by T1 hyperintensity at cerebral MRI. Another explanation suggests that stroke like episodes are due to metabolic derangement, spreading beyond an ischemic focus. Figure 3 shows the dramatic change of EEG activity after repeated seizures, indicated by the appearance of subcontinuous focal slow waves, in a patient with MELAS syndrome.

A syndrome characterized by features of both MERRF and MELAS (*overlap MERRF-MELAS*) has been described by Zeviani et al. (1993) in association with a point mutation at nucleotide 8356 (T-to-C transition) in the MTTK gene. The phenotype was characterized by myoclonic epilepsy, neural deafness, ataxia, stroke-like episodes in the majority of the affected siblings

or rarely by the association of seizures with other symptoms. In other families with an overlap MERFF-MELAS, Nakamura et al. (1995) identified a heteroplasmic mutation in the MTTT1 gene, while Melone et al. (2004) reported a heteroplasmic mutation in the MTTH gene.



A: EEG recording of a patient with MELAS syndrome showing asymmetric background activity and occasional diffuse spike and waves with posterior prevalence.

B: After repeated seizures, the EEG recording of the same patient shows diffuse attenuation of the background activity and the appearance of subcontinuous slow waves on posterior derivations.

Fig. 3. EEG changes in a patient with MELAS syndrome after repeated seizure occurrence

Neurogenic muscle weakness, ataxia, and retinitis pigmentosa (NARP) syndrome typically presents with proximal motor neuropathy, sensory disturbances, cerebellar ataxia, and retinitis pigmentosa. More rare features include developmental delay, mental retardation, dementia, epilepsy, or cardiomyopathy.

In some patients, NARP may clinically overlap with Leigh syndrome (NARP/MILS overlap) due to point mutations in the mitochondrial ATPase6 gene, presumably resulting in impaired ATP synthesis. In this syndrome usually associated with T8993G mutation, have been described infantile spasms with hypsarrhythmia (Desguerre et al, 2003)

4. Autosomal inherited syndromes with epilepsy, associated with nDNA mutations

Other mitochondrial syndromes causing epilepsy are associated with multiple mtDNA deletions or tissue-specific depletions. These conditions are due to nuclear gene defects

involved in controlling the nuclear-mitochondrial intergenomic signaling (Spinazzola and Zeviani, 2005).

These conditions include the following syndromes:

Developmental delay or dementia, lactic acidosis, cyclic vomiting, seizures, failure to thrive, hearing loss, myopathy, liver failure, renal tubular acidosis, pancreatitis, manifesting at 1-3 months, characterize childhood myo-cerebro-hepatopathy spectrum (MCHS).

Myoclonic epilepsy, myopathy, sensory ataxia (MEMSA) is characterized by epilepsy, myopathy, ataxia without ophthalmoplegia (previously defined as spinocerebellar ataxia with epilepsy: SCAE).

Ataxia neuropathy spectrum (ANS) is characterized by ataxia and neuropathy, seizures (reported in two-thirds of the patients), ophthalmoplegia (one-half), clinical myopathy (rare). This disorder was previously defined as recessive ataxia syndrome: MIRAS and sensory ataxia neuropathy dysarthria and ophthalmoplegia: SANDO.

Autosomal Recessive progressive external ophthalmoplegia (arPEO) and Autosomal Dominant progressive external ophthalmoplegia (adPEO) are characterized by myopathy, variable sensorineural hearing loss, axonal neuropathy, ataxia, depression, parkinsonism, hypogonadism, and cataracts (previously defined as CPEO plus). Seizures are uncommon; however, few patients may have signs reminding those observed in MELAS syndrome, including stroke-like episodes and seizures (Deschauer et al, 2007). These syndromes are typically associated with mutations in the nuclear-encoded DNA polymerase-gamma gene (gene map locus: 15q25).

The syndrome variably defined as Alpers' disease, Alpers' syndrome, Alpers-Huttenlocher's disease, progressive neuronal degeneration of childhood, progressive sclerosing poliodystrophy or progressive infantile poliodystrophy is characterized by neuronal degeneration of the cerebral cortex and elsewhere, caused by recessive mutations in nDNA, coding for the mitochondrial DNA polymerase-gamma. In this syndrome, the onset is usually before age four years and up to age 25-35; often there is pre-existing developmental delays of variable severity. The syndrome is characterized by seizures, episodic psychomotor regression, liver dysfunction or failure, which may follow exposure to certain antiepileptic medication. The electro-clinical pattern is typically characterized by periodic EEG and epilepsia partialis continua.

5. Leigh syndrome

Leigh syndrome also defined as "subacute necrotizing encephalomyelopathy" is characterized by focal, bilateral, and symmetric necrotic lesions associated with demyelination, vascular proliferation, and gliosis in the brain stem, diencephalon, basal ganglia, cerebellum, and (occasionally) cerebral white matter.

The syndrome has early onset with hypotonia, failure to thrive, psychomotor regression, and brain stem and basal ganglia dysfunction with ataxia, ocular movement abnormalities, dystonia, and swallowing and respiratory disturbances. It can be inherited as autosomal recessive trait or as autosomal dominant or X-linked mechanism, while other patients show maternal inheritance (MILS). It can be associated with functional or molecular defects in several enzyme systems (pyruvate dehydrogenase complex: PDHC), respiratory chain complexes I-IV (cytochrome c oxidase: COX), and mitochondria-encoded ATPase 6 subunit of complex V.

Molecular exams could identify heterogeneous mutations in various mitochondrial and nuclear genes coding for complex I, complex III and complex IV and complex V gene. Mutations have been found also in genes encoding mitochondrial tRNA proteins (MTTV, MTTK, MTTW, and MTTL1) and in components of the pyruvate dehydrogenase complex (e.g. PDHA1: X-linked Leigh syndrome). The French-Canadian (or Saguenay-Lac Saint Jean) type of Leigh syndrome with COX deficiency (LSFC) is caused by mutation in the LRPPRC gene. Deficiency of coenzyme Q10 can present as Leigh syndrome.

In the Leigh syndrome, both generalized and focal seizures have been described, according to genetic and biochemical heterogeneity.

6. Non-syndromic pictures

Seizures can manifest in many patients with infantile MEs, who were diagnosed on the bases of their biochemical defects but still not classified genetically. Epilepsy may manifest as catastrophic neonatal forms, neonatal myoclonic encephalopathies, infantile spasms, refractory status epilepticus, epilepsia partialis continua, myoclonic epilepsy (El Sabbagh et al, 2010), Landau Kleffner, Lennox-Gastaut syndromes, unclassified generalized epilepsy or partial epilepsy (Canafoglia et al, 2001; Lee et al, 2008). Thus, epilepsy may be either focal or generalized and its severity varies in different case series, though the appearance of drug-resistant seizures possibly marks a severe turn in the disease with high risk of neurological deterioration and fatal outcome (El Sabbagh et al, 2010).

Among various biochemical defects, it's worth noting complex I deficiency. Complex I deficiency, due to mutations in mtDNA genes coding for ND subunits, has been described in patients with heterogeneous syndromic (MELAS, Leigh) and non-syndromic MEs, frequently associated with severe epilepsy (Antozzi et al, 1995; Malfatti et al, 2007).

Mitochondrial dysfunctions may be implicated also in sporadic forms of partial epilepsy such is temporal lobe epilepsy, since severe impairment of the respiratory chain activity has been detected *in vitro* on hippocampus samples from patients with drug resistant epilepsy. This observation was also supported by various evidences obtained *in vivo* using neuroimaging techniques (Zsurka and Kunz, 2010).

7. Pyruvate dehydrogenase (PDH) Deficiency (MIM ID #312170)

Pyruvate dehydrogenase complex (PDHC) is a mitochondrial matrix enzyme complex that catalyzes the oxidative decarboxylation of pyruvate to acetyl CoA, nicotinamide adenine dinucleotide (the reduced form, NADH), and CO₂. This reaction constitutes the bridge between anaerobic and aerobic cerebral energy metabolism. The great majority of PDH complex deficiencies results from mutations in the X-linked pyruvate dehydrogenase (E1) alpha subunit gene (PDHA1). Gene map locus: *Xp22.2-p22.1*.

The clinical severity can vary from early neonatal presentation with severe lactic acidosis to a progressive disease with mental retardation and neurological complications. Some females are only mildly affected or asymptomatic in relation to the pattern of X-inactivation.

Epilepsy has been reported with a high frequency in children with PDH deficiency (Canafoglia et al, 2001; Kang et al, 2007). Epilepsy is frequently severe and may have variable characteristics including some forms of epileptic encephalopathy.

8. Guidelines for the recognition of patients with mitochondrial DNA disease

Guidelines for recognition of patients with mitochondrial DNA disease should include the detection of the classic syndromes; however, in non-syndromic cases, may be useful the recognition of characteristic clinical features (for example, myoclonus) or specific combinations of symptoms (for example, strokes and migraine and seizures and ataxia). Typically, in the mitochondrial encephalopathies, the observed symptoms may be referred to the involvement of many organ systems, for example, diabetes and deafness.

Besides the clinical observation, characteristic MRI findings may orientate the diagnostic work-up.

Laboratory exams should include the determination of the lactic acidemia, which is frequently elevated in children in case of mitochondrial encephalopathy. Finally, the muscle biopsy may reveal ragged-red fibres or cytochrome c oxidase-deficient fibres. (Falk, 2010)

Among other symptoms, epileptic presentation may include isolated seizure or isolated status, intermittent seizures or status, severe epilepsies, focal or multifocal epilepsies, generalized seizures and myoclonus (mainly progressive myoclonus epilepsies).


Though not always associated with MEs, myoclonus, epilepsy partialis continua, status epilepticus and intractable epilepsy should be considered common symptoms of these disorders.

9. References

- Antozzi C, Franceschetti S, Filippini G, Barbiroli B, Savoardo M, Fiacchino F, Rimoldi M, Lodi R, Zaniol P, Zeviani M. Epilepsia partialis continua associated with NADH-coenzyme Q reductase deficiency. *J Neurol Sci.* 1995;129:152-61.
- Canafoglia L, Franceschetti S, Antozzi C, Carrara F, Farina L, Granata T, Lamantea E, Savoardo M, Uziel G, Villani F, Zeviani M, Avanzini G. Epileptic phenotypes associated with mitochondrial disorders. *Neurology.* 2001;56:1340-6.
- Ciafaloni E, Ricci E, Shanske S, Moraes CT, Silvestri G, Hirano M, Simonetti S, Angelini C, Donati MA, Garcia C, Martinuzzi A, Mosewich R, Servidei S, Zammarchi E, Bonilla E, DeVivo DC, Rowland LP, Schon EA, DiMauro S. MELAS: clinical features, biochemistry, and molecular genetics. *Ann Neurol* 1992;31: 391-398.
- Deschauer M, Tennant S, Rokicka A, He L, Kraya T, Turnbull DM, Zierz S, Taylor RW. MELAS associated with mutations in the POLG1 gene. *Neurology* 2007;68: 1741-1742.
- Desguerre I, Pinton F, Nabbout R, Moutard ML, N'Guyen S, Marsac C, Ponsot G, Dulac O. Infantile spasms with basal ganglia MRI hypersignal may reveal mitochondrial disorder due to T8993G MT DNA mutation. *Neuropediatrics.* 2003;34:265-9.
- Falk MJ. Neurodevelopmental manifestations of mitochondrial disease. *J Dev Behav Pediatr.* 2010;31:610-21. Review.
- Finsterer J. Central nervous system imaging in mitochondrial disorders. *Can J Neurol Sci* 2009;36:143-53. Review.
- Fukuhara N, Tokiguchi S, Shirakawa K, Tsubaki T. Myoclonus epilepsy associated with ragged-red fibres (mitochondrial abnormalities): disease entity or a syndrome?

- Light-and electron-microscopic studies of two cases and review of literature. *J Neurol Sci* 1980;47:117-33.
- Goto Y, Horai S, Matsuoka T, Koga Y, Nihei K, Kobayashi M, Nonaka I. Mitochondrial myopathy, encephalopathy, lactic acidosis, and stroke-like episodes (MELAS): a correlative study of the clinical features and mitochondrial DNA mutation. *Neurology* 1992;42: 545-550.
- Iizuka T, Sakai F, Suzuki N, Hata T, Tsukahara S, Fukuda M, Takiyama Y. Neuronal hyperexcitability in stroke-like episodes of MELAS syndrome. *Neurology* 2002;59:816-24.
- Iizuka T, Sakai F, Kan S, Suzuki N. Slowly progressive spread of the stroke-like lesions in MELAS. *Neurology* 2003;61:1238-44.
- Kang HC, Kwon JW, Lee YM, Kim HD, Lee HJ, Hahn SH. Nonspecific mitochondrial disease with epilepsy in children: diagnostic approaches and epileptic phenotypes. *Childs Nerv Syst.* 2007;23:1301-7.
- Lee YM, Kang HC, Lee JS, Kim SH, Kim EY, Lee SK, Slama A, Kim HD. Mitochondrial respiratory chain defects: underlying etiology in various epileptic conditions. *Epilepsia.* 2008;49(4):685-90.
- Malfatti E, Bugiani M, Invernizzi F, de Souza CF, Farina L, Carrara F, Lamantea E, Antozzi C, Confalonieri P, Sanseverino MT, Giugliani R, Uziel G, Zeviani M. Novel mutations of ND genes in complex I deficiency associated with mitochondrial encephalopathy. *Brain.* 2007;130:1894-904.
- Mancuso M, Filosto M, Mootha VK, Rocchi A, Pistolesi S, Murri L, DiMauro S, Siciliano GA. novel mitochondrial tRNA-phe mutation causes MERRF syndrome. *Neurology* 2004;62:2119-2121.
- Melone MAB, Tessa A, Petrini S, Lus G, Sampaolo S, di Fede G, Santorelli FM, Cotrufo R. Revelation of a new mitochondrial DNA mutation (G12147A) in a MELAS/MERFF phenotype. *Arch Neurol* 2004;61: 269-272.
- Nakamura M, Nakano S, Gato Y-i, Ozawa M, Nagahama Y, Fukuyama H, Akiguchi I, Kaji R, Kimura, J. A novel point mutation in the mitochondrial tRNA (ser(UCN)) gene detected in a family with MERRF/MELAS overlap syndrome. *Biochem Biophys Res Commun* 1995;214: 86-93.
- Roger J, Pellissier JF, Dravet C, Bureau-Paillas M, Arnoux M, Larrieu JL. Spinocerebellar degeneration, optic atrophy, epilepsy, myoclonus and mitochondrial myopathy: a case report. *Rev Neurol (Paris)* 1982;138:187-200.
- Shoffner JM, Wallace DC. Mitochondrial genetics: principles and practice. *Am J Hum Genet* 1992;51:1179-1186.
- Spinazzola A, Zeviani M. Disorders of nuclear-mitochondrial intergenomic signaling. *Gene.* 2005 Jul 18;354:162-8. Review.
- Tiranti V, Hoertnagel K, Carrozzo R, Galimberti C, Munaro M, Granatiero M, Zelante L, Gasparini P, Marzella R, Rocchi M, Bayona-Bafaluy MP, Enriquez JA, Uziel G, Bertini E, Dionisi-Vici C, Franco B, Meitinger T, Zeviani M. Mutations of SURF-1 in Leigh disease associated with cytochrome c oxidase deficiency. *Am J Hum Genet.* 1998;63:1609-21.

- Wu S-B Ma YS, Wu YT, Chen YC, Wei YH. Mitochondrial DNA mutation-elicited oxidative stress, oxidative damage, and altered gene expression in cultured cells of patients with MERRF syndrome. *Mol Neurobiol.* 2010;41(2-3):256-66. Review.
- Zsurka G, Kunz WS. Mitochondrial dysfunction in neurological disorders with epileptic phenotypes. *J Bioenerg Biomembr* 2010;42(6):443-8. Review.



Novel Aspects on Epilepsy

Edited by Prof. Humberto Foyaca-Sibat

ISBN 978-953-307-678-2

Hard cover, 338 pages

Publisher InTech

Published online 12, October, 2011

Published in print edition October, 2011

This book covers novel aspects of epilepsy without ignoring its foundation and therefore, apart from the classic issues that cannot be missing in any book about epilepsy, we introduced novel aspects related with epilepsy and neurocysticercosis as a leading cause of epilepsy in developing countries. We are looking forward with confidence and pride in the vital role that this book has to play for a new vision and mission. Therefore, we introduce novel aspects of epilepsy related to its impact on reproductive functions, oral health and epilepsy secondary to tuberous sclerosis, mitochondrial disorders and lisosomal storage disorders.

How to reference

In order to correctly reference this scholarly work, feel free to copy and paste the following:

Silvana Franceschetti, Graziella Uziel, Eleonora Lamantea, Gianfranco Carrara, Carlo Antozzi, Massimo Zeviani and Laura Canafoglia (2011). Epilepsy in Mitochondrial Disorders, Novel Aspects on Epilepsy, Prof. Humberto Foyaca-Sibat (Ed.), ISBN: 978-953-307-678-2, InTech, Available from:
<http://www.intechopen.com/books/novel-aspects-on-epilepsy/epilepsy-in-mitochondrial-disorders>

INTECH
open science | open minds

InTech Europe

University Campus STeP Ri
Slavka Krautzeka 83/A
51000 Rijeka, Croatia
Phone: +385 (51) 770 447
Fax: +385 (51) 686 166
www.intechopen.com

InTech China

Unit 405, Office Block, Hotel Equatorial Shanghai
No.65, Yan An Road (West), Shanghai, 200040, China
中国上海市延安西路65号上海国际贵都大饭店办公楼405单元
Phone: +86-21-62489820
Fax: +86-21-62489821

© 2011 The Author(s). Licensee IntechOpen. This is an open access article distributed under the terms of the [Creative Commons Attribution 3.0 License](https://creativecommons.org/licenses/by/3.0/), which permits unrestricted use, distribution, and reproduction in any medium, provided the original work is properly cited.

IntechOpen

IntechOpen