

We are IntechOpen, the world's leading publisher of Open Access books Built by scientists, for scientists

6,900

Open access books available

186,000

International authors and editors

200M

Downloads

Our authors are among the

154

Countries delivered to

TOP 1%

most cited scientists

12.2%

Contributors from top 500 universities



WEB OF SCIENCE™

Selection of our books indexed in the Book Citation Index
in Web of Science™ Core Collection (BKCI)

Interested in publishing with us?
Contact book.department@intechopen.com

Numbers displayed above are based on latest data collected.
For more information visit www.intechopen.com



New Aspects of Natural History and Pathogenicity of Hepadnaviral Infection and Hepatocyte Function Revealed by the Woodchuck Model of Hepatitis B

Patricia M. Mulrooney-Cousins and Tomasz I. Michalak

*Molecular Virology and Hepatology Research Group, Faculty of Medicine,
Health Sciences Center, Memorial University of Newfoundland,
St. John's, Newfoundland and Labrador,
Canada*

1. Introduction

The application of modern molecular biology and immunological techniques exponentially increased the utilization of liver biopsy material collected from either patients or animal models for diagnostic and research purposes. In the areas of our direct research interest, which is focused on delineation of the molecular immunopathogenesis of hepatocellular injury in hepatitis B virus (HBV) infection and hepadnaviral persistence, the mechanisms of hepadnaviral infection of the immune system and elucidation of the hepatocyte immune effector function, we routinely investigate liver biopsy specimens obtained from woodchucks infected with woodchuck hepatitis virus (WHV). The woodchuck-WHV infection system is not only the closest natural animal model of hepatitis B and HBV-induced hepatocellular carcinoma (HCC), but also is unparalleled for the evaluation of novel therapeutic and preventive strategies against HBV and its long-term pathological outcomes, such as chronic hepatitis (CH) and HCC.

The aim of this chapter is to review the findings from investigations of liver biopsy material acquired from the woodchuck model of hepatitis B, as well as primary or cultured hepatocytes derived from WHV-infected and healthy animals. Since some research areas in which the woodchuck model is applied are almost exclusive domains of this laboratory, we will describe these areas in more detail.

1.1 HBV and its pathological significance

Despite the availability of effective prophylactic vaccines, HBV occurs in an estimated 400 million people worldwide as a serologically evident chronic infection (Lia & Liaw, 2010; Liaw *et al.*, 2010; Romano *et al.*, 2011). Many of these individuals succumb after years of CH to liver failure due to cirrhosis and development of HCC. Recent statistics indicate that up to one-third of the global population has evidence of exposure to HBV (WHO, 2008). This may indicate that over 90% of those exposed carry HBV asymptomatically, at levels which are not readily detectable by the current clinical laboratory tests, but which can be often

identified by analysis of appropriately prepared samples using research assays of greater sensitivity. This has potential implications for blood transfusion, transplantation, as well as therapy with immunosuppressive and anti-cancerous toxic agents which reactivate silently persisting infection (Feraý *et al.*, 1990; Chazouilleres *et al.*, 1994; Dickson *et al.*, 1997; Yotsuyanagi *et al.*, 1998; Grob *et al.*, 2000; Carpenter *et al.*, 2002; Hu, 2002; Yuki *et al.*, 2003; Pollicino *et al.*, 2004; Mulrooney-Cousins & Michalak, 2007; Kao, 2008; De Mitri *et al.*, 2010; Coffin *et al.*, 2011a, 2011b; Morisco *et al.*, 2011; Villadolid *et al.*, 2011).

HBV is a circular 3.2 kilobase-long, partially double-stranded DNA virus whose genome contains four overlapping open reading frames (ORF) named surface (S), core (C), polymerase (P) and X. There are three envelope proteins encoded by the S ORF, designated as large (preS1), middle (preS2), and major or small (S). They have a common carboxy-terminus, but they differ at their amino-termini. The C ORF encodes the virus nucleocapsid protein carrying HBV core antigen (HBcAg) reactivity and a protein which, due to post-translational modifications of HBcAg, displays e antigen (HBeAg) specificity. Transcription of the P ORF results in formation of a multidomain polypeptide with viral reverse transcriptase, RNase, and DNA polymerase activities which are essential for virus replication (Nassal, 2008; Wei *et al.*, 2010). The X protein is derived from the smallest X ORF. It has transcriptional trans-activating properties and plays a role in virus oncogenicity. In terms of the replication strategy, the virus nucleocapsid migrates to the nucleus following entry and removal of envelope. There, HBV relaxed circular DNA (rcDNA) is converted to covalently closed circular DNA (cccDNA) by host DNA polymerases and ligases. This event is the first step in the viral replication cycle and detection of cccDNA serves as the marker of hepadnaviral replication. Four HBV mRNA transcripts, *i.e.*, 3.5, 2.4, 2.1, and 0.7 kb, are transcribed from the cccDNA. The mature nucleocapsid particles containing rcDNA are either packaged into virions, which are exported from the cell, or recycled to the nucleus. HBV and related viruses, known as the hepadnaviral family, are the only DNA viruses that use reverse transcription in their replication cycle.

In regard to pathogenicity, hepadnaviruses are considered to be essentially noncytopathic. Symptoms of hepatitis are a consequence of hepatocyte damage induced primarily by the host's immune responses directed against viral peptides presented on infected cells in the context of major histocompatibility complex (MHC) molecules, particularly class I (Chisari & Ferrari, 1996; Michalak, 2004; Bertoletti *et al.*, 2010; Chisari *et al.*, 2010). The subsequent release of proinflammatory cytokines, such as interferon gamma (IFN γ) and tumor necrosis factor alpha (TNF α), by activated cytotoxic T cells (CTL) are the main mediators of liver injury (reviewed in Michalak, 2004; Bertoletti *et al.*, 2010; Chisari *et al.*, 2010). One of the unique characteristics of hepadnaviruses is their stealth nature during the incubation period with no evidence of T cell recognition for approximately two months after exposure. However, the data from the woodchuck model of hepatitis B indicate that immediately after invasion, WHV induces virus-nonspecific lymphocyte activation (Gujar *et al.*, 2008), as well the cells of the innate immune system recognize virus shortly after its invasion, although they are not able to control virus replication or promptly induce virus-specific T cell responses (Guy *et al.*, 2008a).

One of the mechanisms of viral immune evasion, frequently utilized by viruses capable of long-term persistence, is their ability to infect immune cells (Alacami & Koszinowski, 2000). The lymphotropic nature of HBV has been shown in both *in vivo* and *in vitro* conditions (Korba *et al.*, 1987; Blum *et al.*, 1991; Chemin *et al.*, 1992; Calmus *et al.*, 1994; Michalak *et al.*,

1994; Bläckberg & Kigg-Ljunggren, 2001; reviewed in Michalak 2000; Michalak *et al.*, 2007; Pontisso *et al.*, 2008; Coffin *et al.*, 2011a, 2011b). On the other hand, the ability of WHV, which is a close relative of HBV, to infect and propagate in cells of the immune system has been well documented (Korba *et al.*, 1988; Michalak *et al.*, 1999; Michalak *et al.*, 2004, 2007; reviewed in Michalak 2000, 2004; Mulrooney-Cousins & Michalak, 2007). Overall, hepadnaviruses have developed multiple mechanisms to avoid immune elimination allowing them to persist within an infected host independent of whether infection is symptomatic or clinically and serologically silent (occult).

2. The woodchuck model of hepatitis B

2.1 Woodchuck hepatitis virus (WHV)

WHV was discovered in a colony of eastern North American woodchucks in the Philadelphia Zoological Garden, where a high rate of CH and HCC was observed (Summers *et al.*, 1978). The WHV infection in this subspecies of woodchucks (*Marmota monax*) is acknowledged as the most accurate natural model for the study of the natural course of HBV infection, the pathogenesis of hepatitis B and HCC, as well as for preclinical evaluations of new antiviral agents and preventive methods against HBV. WHV and HBV share the same genome organization, significant antigenic cross-reactivity, the same range of targeted organs, and comparable sequelae of liver disease. Thus, both viruses cause hepatitis that progresses from acute hepatitis (AH) to CH and finally HCC (Summers & Mason, 1982; reviewed in Michalak, 1998, 2004; Menne & Tennant, 1999; Menne & Cote, 2007; Roggendorf *et al.*, 2010). Nonetheless, the outbred nature of woodchucks and the relative shortage of WHV- and species-specific reagents and assays limit a wider utilization of the model. On the other hand, the woodchuck-WHV infection system is significantly more accessible and substantially less expensive than a chimpanzee model of hepatitis B, and liver disease and immunological processes in woodchucks are more closely compatible to a human disease situation than those in the avian models of HBV infection or in bioengineered mice. Considering the main differences between WHV and HBV-induced disease, HCC develops in almost all animals which have serum WHV surface antigen (WHsAg)-reactive CH (Popper *et al.*, 1981; Korba *et al.*, 1989). It is believed that the activation of cellular oncogenes, particularly *c-myc* and *N-myc*, through the integration of viral promoter sequences near these genes or through rearrangements of the genes, is responsible for the higher rates of HCC in woodchucks than in humans. However, WHV DNA can also integrate randomly into the hepatocyte genome, similarly to HBV DNA in human and chimpanzee hepatocytes (Feitelson & Lee, 2007; Mason *et al.*, 2009). Another difference is that CH type B in humans frequently advances to cirrhosis, while this is not the case during CH in woodchucks.

2.2 Serological and molecular markers of WHV infection

The profile of serological markers of WHV infection closely mirrors that in HBV infection (Mulrooney-Cousins & Michalak, 2009). The detection of serum WHsAg is indicative of a high virus replication rate and persistence of WHsAg in the circulation for longer than 6 months is indicative of CH, similarly to serum HBsAg in humans. In woodchucks that resolve AH, serum WHsAg falls to undetectable levels. However, concentration of plasma by ultracentrifugation may allow detection of WHsAg long after resolution of AH (Coffin *et al.*, 2004). Further, antibodies to WHV antigens detectable in woodchucks also are similar to

their counterparts in HBV infection in terms of the time of their emergence, duration and diagnostic significance. Thus, antibodies to WHV core antigen (anti-WHc) are indicative of exposure to virus and, if they occur alone, they reflect the existence of occult WHV infection in which low levels of circulating WHV DNA can be also detected (Michalak *et al.*, 1999; Coffin *et al.*, 2004). In the case of HBV infection, the detection of IgM or IgG classes of anti-HBc is indicative of a recent or a past exposure to the virus, respectively. However, identification of anti-WHc of IgM class is not yet routinely feasible in woodchucks. Antibodies to WHsAg (anti-WHs) are detectable after resolution of AH or seemingly asymptomatic infection and they confer protection from re-infection. However, as it will be explained later (Section 6.2), this is by no means an indication of total eradication of virus or normal liver histology. In recent years, the development of highly sensitive nucleic acid amplification assays detecting hepadnavirus DNA and its genome replicative intermediates, such as cccDNA and mRNA, have led to the delineation of new forms of hepadnaviral infection. These findings will be summarized below (Sections 6.2 and 6.3). The detection of WHV genome and serological (immunovirological) markers in different stages and forms of infection is summarized in Table 1.

Status	WHsAg	Anti-WHc	Anti-WHs	WHV DNA Serum	WHV DNA Immune cells*	WHV DNA Liver
Pre-acute infection	-	+	-	+	+	+ or -
Acute serologically apparent infection	+	+	-	+	+	+
Chronic serologically apparent infection	+	+	-	+	+	+
Secondary occult infection (SOI)	-	+	+ or -	+	+	+
Primary occult infection (POI)	-	-	-	+	+	- **

* Based on WHV DNA detection in peripheral blood mononuclear cells (PBMC).
** Low levels of WHV DNA and its replication intermediates can be detected after 3 or more years of follow-up of POI (Mulrooney-Cousins *et al.*, manuscript in preparation).

Table 1. Serological markers of WHV infection and WHV DNA detection in serum, cells of the immune system and liver as detected by research assays in various stages and forms of WHV infection

3. Liver biopsy acquisition and histological grading of WHV hepatitis

The significant advantage of the woodchuck model is access to serial liver biopsies from virologically and immunologically well-defined stages of infection, including samples prior to initiation of infection experiments which are essential for base line measurements. In addition, due to the size of the woodchuck liver, a sufficient amount of tissue can be secured via laparotomy for both diagnostic and experimental purposes, including isolation of hepatocytes and intrahepatic immune cells. In this laboratory, the protocols for collection of

liver biopsies and preservation of liver tissue samples from woodchucks are highly standardized. Briefly, animals are immobilized under general inhalant anaesthesia in a surgical suite under aseptic conditions. Liver tissue fragments (2-3 if required) are obtained by surgical laparotomy using a 7-mm wide-edge Schmeden No. 2 triangular punch (Churchill & Michalak, 2004). The liver bleeding is stopped with sterile absorbant hemostat cellulose (Surgicel; Ethicon Inc., USA). The tissue sample is divided into at least 3 portions. One is snap frozen in liquid nitrogen for nucleic acid isolations, another fixed in 10% buffered formaldehyde for histological examination, and a third cryopreserved for immunohistochemical investigations (Michalak, 1978). Depending on the nature of the experiment, small tissue fragments are also preserved for ultrastructural and other investigations.

Histological examination of hepatic tissue remains the gold standard for determining the dynamic of progression of liver damage in viral hepatitis. Woodchuck liver specimens are processed exactly as those from patients. Thus, formalin-fixed tissue is embedded in paraffin and thin serial sections (4 μ m) are stained with hematoxylin-eosin (H&E), Masson trichrome, periodic acid-Schiff and impregnated with silver. Upon double-blinded microscopic analysis, morphological alterations encountered in hepatocellular, extrahepatocellular intralobular and portal compartments of hepatic parenchyma are graded on a numerical scale from 0 to 3. The overall grade of disease severity from 0 to 3 with 0.5-score intervals, defined as histological degree of hepatitis, is assigned taking into consideration the grades given for each category of liver lesions and the global impression on the pathological picture as a whole (Michalak *et al.*, 1990, 1999, 2000). The pivotal significance of histological examination in uncovering new aspects of natural history of hepadnaviral infection has been illustrated when serial liver biopsies obtained over the lifespan of woodchucks convalescent from AH were analyzed. It was found that although the animals cleared serum WHsAg, mounted anti-WHs and normalized liver enzymes, they persistently carried low levels of replicating virus and their livers showed an intermittent minimal to moderate liver inflammation up to the end of their lives. This documented that liver lesions did not subside completely despite apparent complete serological and biochemical resolution of hepatitis. Importantly, approximately 20% of the animals ultimately developed HCC (Michalak *et al.*, 1999). This finding was consistent with a similar observation made by others (Korba *et al.*, 1989). Accumulating clinical evidence indicates that the same may happen in humans convalescent from an episode of self-limited AH (Pollicino *et al.*, 2004; Simonetti *et al.*, 2010).

4. Isolation of hepatocytes from liver biopsy

Hepatocytes are the site of the most robust virus replication in serologically evident, symptomatic hepadnaviral infection. However, during the pre-acute phase and in the course of persistent low level WHV infection continuing after recovery from AH, termed as secondary occult infection (SOI) (see Section 6.3), the levels of WHV replication are comparable in hepatocytes and in infected immune cells (Michalak *et al.*, 1999, 2004). Up to this point, it has been virtually impossible to mimic the vigorous HBV or WHV replication seen in vivo in cell culture systems. It is for this reason that the derivation of primary hepatocytes from liver biopsies or during autopsy and establishment of cell lines from them are valuable tools in the attempts to understand hepatocyte engagement in different forms of hepadnaviral infection, to uncover mechanisms of hepadnaviral cell-to-cell spread and to assess hepadnavirus influence on hepatocyte function on the single cell level.

In most instances, primary hepatocytes can be isolated by microperfusion with a collagenase buffer under aseptic conditions from as little as 100-150 mg of liver tissue (Churchill & Michalak, 2004). After gentle teasing of the cells through a sieve, the cells are collected by low-speed centrifugation and are extensively washed until a high purity preparation of hepatocytes (>97%) is obtained. Cells are allowed to attach in culture flasks for 4 hours and after culture for 24 hours, hepatocytes from virus-naïve animals can be exposed to WHV for infection experiments, whereas those from WHV-infected woodchucks examined for viral genome and protein expression and/or used for assessing antiviral potential of test agents (Churchill & Michalak, 2004). Using this approach, a hepatocyte cell line, designated as WCM-260, was established from liver biopsy of a healthy woodchuck (Churchill & Michalak, 2004). The hepatocyte origin of the line was confirmed by gene expression analysis and identification of proteins specifically produced by hepatocytes. The studies carried out using this cell line significantly contributed to recognition of different aspects of WHV and hepatocyte biology, including studies on WHV cell tropism (Lew & Michalak, 2001; Mulrooney-Cousins & Michalak, 2008), hepadnavirus effect on the class I MHC expression (Wang *et al.*, 2006), mechanisms of hepatocyte cytotoxicity and their modulation by hepadnaviral infection (Guy *et al.*, 2010, 2011).

5. WHV-cell interactions in vitro

The WCM-260 hepatocyte line was found to be susceptible to WHV infection, regardless of whether the WHV inoculum was derived from serum of WHV-infected woodchucks or from in vitro infected hepatocytes or lymphocytes (Lew & Michalak, 2001; Mulrooney-Cousins & Michalak, 2008). WHV obtained after serial passage in WCM-260 cells caused classical AH in virus-naïve woodchucks (Lew & Michalak, 2001) and the virus genome sequence remained unchanged after multiple passages (Mulrooney-Cousins & Michalak, 2008), indicating that the cells supported replication of the biologically competent virus under conditions favorable to virus growth.

Although hepatocytes and lymphoid cells are known targets of WHV and HBV, there is still very little knowledge in regard to the receptor/s mediating the highly restricted cell tropism characterizing these viruses. However, it has been shown that there is a protease-activated cell recognition site in the preS1 (large) protein of WHV that mediates strictly host-specific binding to woodchuck hepatocytes and lymphoid cells (Jin *et al.*, 1996). The crucial determinant of this site was mapped to amino acids 10-13 at the amino-terminus of the large envelope protein. Synthetic peptides comprising the site sequence bound woodchuck hepatocytes and lymphoid cells with characteristics of a specific ligand-receptor interaction, although their ability to interact with lymphocytes was significantly greater (approximately 1000-fold) than that for hepatocytes. Interestingly, this binding site was protected within the tertiary structure of the virus preS1 envelope protein and was not identifiable unless the protein was treated with proteases. When animals experimentally infected with WHV were examined for the presence of antibodies directed against the site, the antibodies were found to appear as the first immunological indicator of virus infection, suggesting that proteolytic cleavage of the preS1 protein also occurs in vivo (Jin *et al.*, 1996).

6. Findings regarding natural history

Much of our understanding regarding the natural history and pathogenesis of HBV infection has come from investigations of the woodchuck-WHV model. The subsequent

sections will be focused on new aspects of the natural history of hepadnaviral infection that have come to light by analyzing the liver and other natural compartments of WHV replication in woodchucks experimentally infected with various virus doses.

6.1 Symptomatic serologically evident hepadnaviral infection

The transmission of WHV through blood and body fluids, as well as vertically from mother to offspring, parallels that of HBV. Most neonates infected with WHV before 3 days after birth or those born to mothers with serum WHsAg-positive infection develop serologically evident CH that almost invariably progresses to HCC. This suggests that the maturity of the immune system at the time of infection is an important element determining establishment of CH. The role of virus dose and a possible influence of virus strain in the rate of CH development have been considered (Cote *et al.*, 2000a, 2000b; Michalak *et al.*, 2004). In adult animals, serum WHsAg-positivity accompanied by AH is usually self-limiting and is followed by the apparent complete antigen clearance; however molecular indicators of residual WHV infection remain (Michalak, 1998; Michalak *et al.*, 1999, 2004; reviewed in Michalak, 2000, 2004; Guy *et al.*, 2008a). The same happens in patients with self-limited AH (Michalak *et al.*, 1994; Grob *et al.*, 2000; Marusawa *et al.*, 2000; Chemin *et al.*, 2001; Murakami *et al.*, 2004; De Mitri *et al.*, 2010; Raimondo *et al.*, 2010). Similarly, approximately 10% of serum WHsAg-positive adult woodchucks and 5-10% of serum HBsAg-positive humans develop CH. However, suppression of the immune responses by administration of cyclosporin A dramatically increases the rate of progression to CH in experimentally infected woodchucks (Cote *et al.*, 1992). This supports the concept that the competence of the immune system plays a pivotal role in CH development.

Lymphotropism is an inherent property of many viruses capable of establishing persistent infection (Alcami & Koszinowski, 2000). There is a long history of findings indicating that both HBV and WHV can persist and actively replicate at extrahepatic locations, specifically in the cells of the lymphatic (immune) system, in the course of serologically evident chronic infection (Pontisso *et al.*, 1984, 2008; Yoffe *et al.*, 1986; Korba *et al.*, 1987, 1988; Ogston *et al.*, 1989). Studies in the woodchuck model significantly contributed to identification of hepadnaviral lymphotropism and characterization of virus replication in cells of the immune system. Overall, although WHV replicates at approximately 50 to 100-fold lower levels (per cell) in immune cells than in hepatocytes in chronic symptomatic infection, the size of the reservoir is very large considering the total number of cells which constitute the immune system.

Hepadnavirus clearance without massive immune-mediated destruction of infected hepatocytes occurs in both HBV and WHV infections (Guidotti *et al.*, 1999; Guidotti & Chisari, 2001). In one study, hepatocytes were labeled during the peak of AH, when nearly all liver cells are infected (Kajino *et al.*, 1994). After immunohistochemically evident elimination of WHV antigens from the liver, many labeled hepatocytes were still present, suggesting that non-cytopathic viral clearance occurs in infected woodchucks. Other studies investigating the role of anti-viral cytokines, such as IFN γ and TNF α , as determinants of progression of AH to CH or recovery, demonstrated that the hepatic cytokine milieu during the acute phase of infection is important in determining the outcome of hepatitis in both neonatally acquired and adult WHV infections (Cote *et al.*, 2000b; Hodgson and Michalak, 2001). Thus, elevated intrahepatic levels of IFN γ , TNF α , and CD3 expression, together with a lower hepatic viral load and augmented liver inflammation, preceded recovery from AH,

while the opposite coincided with progression of AH to CH (Hodgson & Michalak, 2001). Although cells of the innate immune system sense WHV within the liver as early as an hour after intravenous injection of virus and cause a significant decrease in virus hepatic load within 3 hours post-inoculation, this response is impaired and unable to eliminate virus or promptly induce effective anti-virus T cell response (see Section 9) (Guy *et al.*, 2008a).

Symptomatic hepatitis B is commonly accompanied by autoimmune phenomena clinically appearing as circulating organ non-specific and organ-specific autoantibodies. Although the pathogenic relevance of these responses to liver injury remains unclear in humans, it is generally accepted that their presence coincides with a more severe course of hepatitis (Poralla *et al.*, 1991; Cacoub & Terrier, 2009). In the woodchuck model, WHV infection usually induces organ non-specific autoantibodies, such anti-smooth muscle antibodies (SMA) and anti-nuclear antibodies (ANA) (Dzwonkowski & Michalak, 1990), as well as liver-specific antibodies directed against hepatocyte asialoglycoprotein receptor (ASGPR) (Diao & Michalak, 1996, 1997). It has been found that circulating autoantibodies to ASGPR (anti-ASGPR) induced by WHV infection are capable of causing complement-mediated lysis of hepatocytes and inhibit binding of desialylated glycoproteins to hepatocyte ASGPR, which mediates their clearance (Diao *et al.*, 1998). It has been also shown that the induction of anti-ASGPR prior to infection with a liver pathogenic dose of WHV tended to modulate infection toward CH outcome, and that the occurrence of anti-ASGPR in woodchucks with ongoing CH was associated with exacerbated histological severity of hepatitis. These findings raised the possibility that the liver compromised by CH might be prone to anti-ASGPR directed complement-mediated hepatocellular injury due to formation of the ASGPR-anti-ASGPR immune complexes at hepatocyte plasma membranes (HPM) (Diao *et al.*, 2003). Based on these findings, it is expected that the host's immune response mounted against ASGPR may contribute to both the outcome and the severity of hepadnaviral hepatitis (Diao *et al.*, 1998, 2003).

6.2 Primary occult WHV infection

Primary occult infection (POI) was originally identified in offspring born to woodchuck dams convalescent from AH, including those which developed anti-WHs antibodies after an episode of serum WHsAg-positive infection (Coffin & Michalak, 1999). All offspring from these dams demonstrated low levels of WHV genomes and WHV cccDNA and mRNA in the lymphatic system, while the liver was infected only in some of them. Importantly, no serological markers of infection, such as WHsAg, anti-WHc or anti-WHs, could be detected. In addition, WHV DNA-reactive particles displaying biophysical characteristics of complete virions were found in the circulation of the offspring. Thus, they migrated with comparable velocity in sucrose and had the buoyant density of intact WHV virions. Histological examination of serial liver biopsies showed normal liver morphology in all animals. Furthermore, the inocula prepared from serum or supernatants of cultured lymphoid cells acquired from these offspring induced serologically evident WHV infection and hepatitis in virus-naive adult animals, confirming the pathogenic competence of the virus. Interestingly, the offspring were not protected from challenge with a liver pathogenic dose of WHV (*i.e.*, 1.1×10^{10} vge), indicating that this low level infection did not induce virus-specific protective immunity (Coffin & Michalak, 1999). This study was the first to identify that hepadnaviral infection can be restricted to the lymphatic system and does not engage the liver, indicating that at low infectious doses hepadnavirus could be primarily lymphotropic.

This finding was followed by another study in which the amount of WHV required to establish serologically silent, lymphatic system-restricted infection was determined using intravenous inoculations of woodchucks with serial 10-fold dilutions of a well characterized WHV inoculum (Michalak *et al.*, 2004). The WHV genome was detected in the circulation and its replicative intermediates in cells of the immune system but not in the liver, while anti-viral antibodies were consistently absent. The liver biopsies collected from these animals over 3 years of follow-up showed normal morphology. The study not only confirmed the existence of POI and uncovered that this form of infection is induced by virus doses lower than 10^3 virions, but also established a reproducible model of POI. In the same study, it was uncovered that the inoculum that induced POI at doses greater than 10^3 virions caused classical serum WHsAg-positive AH. Taken together, the results from this study revealed that the amount of invading virus determines whether infection is serologically apparent or silent, that only virus doses greater than 10^3 virions are liver pathogenic, and that the cells of the lymphatic system are primary targets when virus invade a susceptible host at small doses ($<10^3$ virions) (Michalak *et al.*, 2004).

Currently, the long-term pathological consequences of POI are under investigation. In this regard, liver biopsies collected at approximately yearly intervals from animals followed for over 5 years are examined for virus presence and morphological alterations. During this observation period, all animals showed molecular evidence of WHV infection in the absence of the infection serological markers. As expected, the infection was restricted to the lymphatic system. However, after approximately 3 years post-infection, WHV DNA and WHV mRNA became detectable in the liver, even though viral load in serum of these animals rarely exceeded 100 vge/mL. The pathogenic competence of the persisting virus was documented by demonstrating its ability to induce classical AH in virus-naïve animals. This ability was observed regardless of whether serum was collected at the time of lymphatic system-restricted infection or when infection also involved the liver (Mulrooney-Cousins *et al.*, manuscript in preparation). Liver histology remained normal up to 4 years post-infection. However, minimal necroinflammatory alterations were found after 5 years post-infection. The most important finding was that HCC had developed in some of the animals, indicating that the persisting virus retained its oncogenic potency and, therefore, that this form of infection is of a direct pathological relevance (Mulrooney-Cousins *et al.*, manuscript in preparation). In another study, intrahepatic injection of small amounts of recombinant complete WHV DNA has also induced POI, whereas high doses of the same WHV DNA similarly administered can induce typical AH (Will *et al.*, 1982; Chen *et al.*, 1998; Mulrooney-Cousins & Michalak, manuscript in preparation).

The characteristics of WHV-specific T cell immune responses and cytokine expression profiles in circulating lymphoid cells were also examined in the course of experimental POI and subsequent challenge with liver pathogenic dose ($>10^3$ virions) or liver non-pathogenic dose (50 virions) of the same inoculum (Gujar & Michalak, 2009). The data revealed that POI was accompanied by the appearance of a strong WHV-specific T cell proliferative response directed against multiple viral epitopes which intermittently persisted at low levels for up to 10 months of follow-up. Moreover, immediately after exposure to a liver-nonpathogenic dose of WHV, lymphocytes acquired a heightened capacity to proliferate in response to mitogenic stimuli and displayed augmented expression of IFN α , interleukin-12 (IL-12) and IL-2, but not TNF α and the profile of that response was closely comparable to that seen in infection induced with liver-pathogenic viral doses (Gujar *et al.*, 2008; Gujar & Michalak, 2009). The data also showed that virus-specific T cell proliferative reactivity is a very

sensitive indicator of exposure to hepadnavirus, even to very small amounts that induce serologically silent infection. They demonstrated that POI is not only identifiable molecularly but it is also a distinctive immunological entity.

The existence of POI in humans has not yet been clearly established, however existence of HBV-specific CD8⁺ T cell response in the absence of HBV-specific antibodies and the presence of detectable HBV DNA (Zerbini *et al.*, 2008), strongly suggest that this form of infection may occur. On the other hand, the consequences of HBV infection in infants born to mothers with resolved hepatitis B have never been investigated. One of the constraints in this type of study is the difficulty in acquisition of serial samples from different compartments of virus occurrence, i.e., serum or plasma, lymphoid cells (PBMC) and liver, and their proper standardized preparation to secure recovery of small amounts of viral material. Another important limitation is the sensitivity of the clinical assays currently applied for detection of HBV genome, which are at least 100-times less sensitive than the research assays applied for this purpose. The strong similarities between WHV and HBV suggest that the persistence of small amounts of the virus could have a significant impact in terms of transmission of infection and pathogenesis of disorders which are not yet considered to be a consequence of persistent hepadnavirus infection. POI initiated by minute amounts of the virus transmitted from mothers may induce occult infection in neonates, similar to the chronic infection induced in newborns to mothers with symptomatic CH (Beasley, 2009). Also, transmission of virus from unknowingly HBV infected individuals via blood transfusion and organ donation remains a relative risk until clinical laboratory assays reach a sensitivity that is now only obtained by research assays (Lok *et al.*, 1991; Uemoto *et al.*, 1998; Conjeevaram & Lok, 2001; Mulrooney-Cousins & Michalak, 2007, 2009; De Mitri *et al.*, 2010; Schmeltzer & Sherman, 2010).

6.3 Secondary occult hepadnaviral infection

Residual hepadnaviral infection continuing after resolution of HBV and WHV hepatitis, i.e., secondary occult infection or SOI, have been documented in both humans and woodchucks (Liang *et al.*, 1990; Blum *et al.*, 1991; Mason *et al.*, 1992, 1998; Michalak *et al.*, 1994; Michalak *et al.*, 1999; Michalak, 2000; Bläckberg & Kidd-Ljunggren, 2001; Mulrooney-Cousins & Michalak, 2007; Tong *et al.*, 2009; Gerlich *et al.*, 2010; Hollinger & Sood, 2010; Raimondo *et al.*, 2010; Lledo *et al.*, 2011; Said, 2011). It is now evident that the anti-viral immunity established after an encounter with WHV or HBV at doses that cause hepatitis is not able to completely eradicate the virus and replication of virus persists in both hepatocytes and cells of the lymphatic system (Chemin *et al.*, 1992, 1993; Michalak *et al.*, 1994, 1999; Cabrerizo *et al.*, 2000; Mulrooney & Michalak, 2003; Murakami *et al.*, 2004). In this form of infection, the virus can persist for many years without apparent variations in its sequence or emergence of cell type-specific mutants (Laskus *et al.*, 1999; Bläckberg & Kidd-Ljunggren, 2001; Mulrooney-Cousins & Michalak, 2008).

In the woodchuck model, persistence of WHV replication and production of small amounts of infectious virions after resolution of self-limiting AH is life-long when highly sensitive PCR-based assays coupled with detection of amplicons via nucleic acid hybridization (PCR/NAH) are used (Michalak *et al.*, 1999). This life-long carriage involves the liver and is not restricted to the lymphatic organs and PBMC like in POI. As already mentioned (Section 3), animals that have serologically resolved AH show transient minimal to moderate liver inflammatory alterations through their lifespan (Michalak *et al.*, 1999), as has also been reported for individuals with self-limited AH type B (Yuki *et al.*, 2003). Moreover, up to one

fifth of the recovered animals develop HCC (Michalak *et al.*, 1999). Taken together, virus persisting at very low levels as SOI retains its liver pathogenic and oncogenic potentials.

SOI is always accompanied by anti-WHc and frequently by anti-WHs (Michalak *et al.*, 1999; Michalak *et al.*, 2007). It has also been shown that the persistence of isolated anti-WHc is indicative of SOI, even in the absence of prior evidence of serologically evident, i.e., serum WHsAg reactive infection (Coffin *et al.*, 2004). In such animals, low levels of WHV DNA are detectable in the serum, PBMC and liver by PCR/NAH (Coffin *et al.*, 2004). This form of infection is also accompanied by the persisting ability of T cells to respond to virus-specific stimuli (Gujar *et al.* 2008), which also characterize T cell proliferative and cytotoxic responses in patients with a past history of self-limiting AH (Rehermann *et al.*, 1995, 1996a, 1996b; Penna *et al.*, 1996).

The importance of SOI has also been highlighted in the study in which woodchucks were immunized with a bicistronic DNA vaccine carrying WHV core and woodchuck IFN γ in an attempt to enhance induction of protective immunity against virus. It has been postulated that the immunity elicited against nucleocapsid of HBV or WHV could be important in treatment of CH and protection from infection (Murray *et al.*, 1987; Garcia-Navarro *et al.*, 2001). It was found that the animals receiving high doses of the vaccine successfully produced anti-WHc (Wang *et al.*, 2007). However, molecular analysis of liver biopsies revealed that although the animals were protected from hepatitis, as confirmed by histological examination, they were not entirely sheltered from WHV infection since WHV DNA and RNA remained detectable in the livers at levels comparable to those seen in SOI. The results implied that vaccination with DNA encoding hepadnaviral core protein may not be sufficient to mount sterilizing immunity against the virus or prevent establishment of occult infection, although it can protect against development of symptomatic hepatitis.

7. WHV-hepatocyte plasma membrane interactions in the course of hepatitis

As already indicated, the development of hepadnaviral hepatitis is a direct consequence of the cytopathic immune responses directed against infected hepatocytes. However, minimal inflammatory alterations or their absence and essentially normal liver function tests are observed in patients with very high hepatic loads of HBV envelope material where essentially all hepatocytes carry the antigen, as is observed in a healthy chronic HBV carrier state. This and other observations raised questions as to whether there is a relationship between the status of hepadnaviral protein incorporation into HPM structure and immunomorphological forms of hepatitis. This was based on the postulate that hepadnaviral proteins exposed on hepatocytes can modulate immunopathogenic reactions causing liver damage. In a series of studies, highly purified HPM isolated from woodchucks with different stages of WHV hepatitis or HCC were analyzed for the amounts of the HPM-associated WHV proteins, the protein molecular profiles and the nature of their association with the HPM bilayer. Comparative analysis revealed that the HPM levels and molecular profiles of WHV nucleocapsid (core) protein were not related to the duration or histological severity of liver damage. In contrast, quantities of the virus envelope material (WHsAg) were significantly greater in HPM derived from CH than from AH or HCC. Interestingly, although the envelope preS1, preS2 and S polypeptides were detected in all infected HPM, expression of WHV pre-S2 polypeptides was always dominant (Michalak & Lin, 1994) (also see Section 8). Furthermore, in CH, WHV envelope proteins was found to be very tightly bound to HPM and behaved as integral membrane proteins, implying its irreversible

incorporation into the plasma membrane structure and suggesting that they could be eliminated only by lysis of infected hepatocytes (Michalak & Churchill, 1988). In addition, HPM from woodchucks with CH or from nontumor parenchyma of animals with HCC, but not HPM from AH or healthy animals, showed an inability to bind an exogenous WHsAg (Michalak & Lin, 1994). The same was also observed for plasma membranes purified from livers of chronic carriers of WHV with minimal hepatitis (Michalak, 1988). Taken together, the extent and the characteristics of WHV envelope interaction with HPM undergo significant variations in the natural course of hepatitis and distinct forms of WHV-induced liver disease display specific properties of that association. The accumulation of WHV envelope proteins in HPM is a prominent characteristic of CH, but is not connected with histological activity of liver inflammation (Michalak *et al.*, 1990). This event may contribute to the maintenance of chronic disease by creating an immune resistant barrier preserving infected hepatocytes. In this regard, the augmented display of WHV envelope proteins, particularly pre-S2 peptides, in CH coincides with a significant inhibition of class I MHC display on hepatocyte surface. This may profoundly impact the effectiveness of the elimination of infected hepatocytes by virus-specific CTL (Michalak *et al.*, 2000).

It should also be noted that anti-WHc and antibodies recognizing WHV e antigen (anti-WHe) reactivity were also detected in association with HPM (Michalak *et al.*, 1990). However, while anti-WHc antibodies were readily identifiable, anti-WHe could only be detected in eluates from HPM of animals that had recovered from AH (Michalak *et al.*, 1990). This suggested that a humoral response against e antigen may contribute to the resolution of acute infection, presumably by the elimination of infected hepatocytes through antibody-mediated cytolysis, as was suggested for chimpanzees vaccinated with HBeAg (Schlicht *et al.*, 1991).

8. WHV inhibition of hepatocyte class I MHC in chronic hepatitis

As previously mentioned, the utilization of such a unique animal model as the WHV-infected woodchucks has certain disadvantages; they are, among others, related to the lack of commercially available reagents and assays. This laboratory has made a significant effort over the years in developing tools essential for research on different aspects of hepadnaviral infection, and the liver and the immune system biology in this model. One of the important antibodies generated was a monoclonal antibody (mAb) against the heavy chain of woodchuck class I MHC (Michalak *et al.*, 1995). Employment of this woodchuck-specific mAb, as well as flow cytometry and immunoblotting analyses, revealed that normal woodchuck hepatocytes express class I MHC, although at a low level, in contrast to the previous assumptions based on immunohistochemical staining. With this new tool in hand, class I MHC expression was examined on hepatocytes and HPM isolated from different stages of experimentally induced WHV hepatitis (Michalak *et al.*, 2000). It was found that AH is characterized by a significantly enhanced hepatocyte surface display of class I MHC. This coincided with the augmented hepatocyte gene expression for class I MHC heavy chain, IFN γ and class I MHC-associated genes, such as β_2 -microglobulin and transporters associated with antigen processing (TAP1 and TAP2). However, despite the similarly augmented transcription of class I MHC heavy chain and the associated genes in hepatocytes from woodchucks with CH, there was no evidence of class I MHC protein presence on the hepatocyte surface. This indicated a profound posttranscriptional inhibition in the class I MHC display in hepatocytes chronically infected with WHV (Michalak *et al.*,

2000). Since, the cell surface class I MHC is paramount to the efficient presentation of viral peptides to virus-specific CTLs, this finding was of high importance to our understanding of mechanisms underlying development and perpetuation of CH in hepadnaviral infection. Further investigations have focused on the elucidation of which of the WHV proteins are specifically responsible for the inhibition of class I MHC display on hepatocytes (Wang & Michalak, 2006). In this study, WCM-260 hepatocytes (see Section 4) transfected with WHV genes encoding individual viral proteins as well as the entire WHV genome were employed. It was found that hepatocyte presentation of class I MHC was significantly inhibited following transfection with the complete WHV genome or with viral subgenomic fragments encoding envelope preS2 (middle) or preS1 (large) protein, which also encompasses the preS2 amino acid sequence. In contrast, hepatocytes transfected with the WHV X gene demonstrated a significant augmentation in the class I MHC protein display. Further, treatment of hepatocytes with recombinant woodchuck IFN- γ (Wang & Michalak, 2005) restored the inhibited presentation of the class I antigen induced by total WHV and preS2 and preS1 sequences. It is of note that the class I antigen suppression was not associated with down-regulation of hepatocyte genes for class I MHC heavy chain, β_2 -microglobulin, TAP1, TAP2 and proteasome subunits. Taken together, these findings indicated that the defective presentation of class I MHC on hepatocytes transcribing WHV is a consequence of posttranscriptional suppression exerted by the virus pre-S2 envelope protein and that this defect can be fully reversed by treatment with IFN γ (Wang & Michalak, 2006).

9. Intrahepatic immune response in pre-acute WHV infection

One of the impediments to understanding the pathogenesis of HBV infection is the lack of the delineation of virological and immunological events occurring in the liver immediately after hepadnavirus invasion and during the pre-acute phase of infection, since identification of patients in during this asymptomatic phase of infection is extremely difficult and acquisition of liver biopsy material is practically impossible due to the lack of clinically sound indications. For these types of investigations, the woodchuck model of hepatitis B is particularly well suited. Using woodchucks with experimentally induced AH, the hepatic kinetics of hepadnavirus replication and the profiles of activated genes encoding cytokines, cytotoxic effector molecules and immune cell markers were quantified in sequential liver biopsies from one hour post-inoculation outward using real-time amplification assays (Guy *et al.*, 2008a). To achieve the most complete recognition of the events investigated, over 110 liver biopsies were collected starting from the time when animals were healthy to up to 36 months after virus infection when SOI was established. The study showed that WHV replication is detectable in the liver within one hour after infection. In 3 to 6 hours, significantly augmented hepatic transcription of IFN γ and IL-12 were evident, implying activation of antigen presenting cells. In 48 to 72 hours, natural killer (NK) cells and NK T cells were activated and WHV replication was transiently but significantly inhibited, indicating that this early innate immune response is at least partially successful in limiting virus propagation in the liver. Despite this, T cells were activated 4 to 5 weeks later when hepatitis became histologically apparent. Overall, these data demonstrated that hepadnaviral replication is initiated and the innate response is activated in the liver soon after exposure to a liver pathogenic dose of virus. Nonetheless, this response is unable to prompt a timely virus-specific T cell reactivity which is a characteristic of infections with other viral pathogens (Guy *et al.*, 2008a).

10. New insights into hepatocyte function

It is now acknowledged that the liver plays an important role in immunity, particularly in maintenance of peripheral tolerance and pathogen surveillance. Although the involvement of liver cells, such as Kupffer cells and sinusoidal endothelial cells, is relatively well recognized (Bertolino *et al.*, 2002; Warren *et al.*, 2006; Crispe, 2009), a contribution of hepatocytes to the intrahepatic immunological process was entirely unknown. By using woodchuck and human primary hepatocytes, as well as woodchuck WCM-260 hepatocyte line, novel and unexpected properties of hepatocytes were uncovered (Guy & Michalak, 2008).

10.1 Hepatocyte as cytotoxic effector cells

Initially, in contrast to the previous opinion, it was found that normal primary and cultured hepatocytes constitutively express CD95 ligand (CD95L, formerly called Fas ligand) and are capable of inducing death of CD95-bearing cells (Guy *et al.*, 2006). Cytokines, such as IFN γ and TNF α , can upregulate hepatocyte expression and usage of CD95L. Then, we also documented that hepatocytes express perforin and can kill cells brought into contact with their surface via an exocytic pathway. However, this cytotoxic potency of hepatocytes is not modified by the cytokine milieu (Guy *et al.*, 2008b). We concluded that hepatocytes, similar to lymphocytes, are endowed in two distinct cytotoxic effector mechanisms. The relevance of these findings may pertain not only to fratricidal cell death during the development and progression of liver disease, but implicate an active cytotoxic role for hepatocytes as they may interact with other cells either trafficking through or residing in the liver. In this regard, our recent study showed that hepatocytes are capable of eliminating activated autologous T lymphocytes utilizing both CD95-CD95L and perforin-granzyme B dependent pathways (Guy *et al.*, 2011). Despite that the ability of hepatocytes to eliminate contacted cells was documented and the underlying cytopathic mechanisms were delineated, it remained unknown whether hepatocyte-mediated cell killing is indiscriminant or if hepatocytes are capable of discerning which cells are to be eliminated. Furthermore, the cell surface molecules involved in hepatocyte recognition of cells targeted for killing were recently investigated. In the course of this study, it was identified that the hepatocyte specific protein, ASGPR (as mentioned already in Section 6.1), which plays a central role in the clearance of circulating desialylated glycoproteins, is involved in the recognition and removal of cells by hepatocytes (Guy *et al.*, 2011).

10.2 WHV infection augments hepatocyte cytotoxicity

To recognize if hepadnaviral infection modifies the cytotoxic potency of hepatocytes, we investigated primary hepatocytes isolated from woodchucks with progressing CH and those which resolved AH (Guy *et al.*, 2010). It was found that the hepatocyte potential to kill contacted cells is significantly augmented both during CH and after resolution of AH when compared to hepatocytes from healthy animals. Furthermore, hepatocytes exposed to exogenous IFN γ , but not those transfected with the complete WHV genome or individual virus genes, except the WHV X gene, demonstrated enhanced CD95L and perforin-mediated cytotoxicity. This argued that augmented intrahepatic production of IFN γ rather than virus replication itself increased the killing. In this regard, an increased intrahepatic expression of IFN γ was reported not only in CH but also during SOI continuing after resolution of AH (Hodgson & Michalak, 2001). It was also observed that hepatocytes transfected with the

WHV X gene alone transcribed significantly more CD95L and perforin and killed cell targets more efficiently, suggesting that under certain circumstances, albeit probably very rare, the virus may directly augment hepatocyte cytotoxicity (Guy *et al.*, 2010). This was the first study that demonstrated that the cytotoxic phenotype of hepatocytes can be modified by virus infection and that this occurred irrespective whether liver inflammation is active or progresses quiescently. Although hepatocyte cell killing may not be apparent in the normal liver, it is reasonable to expect that inflammation and other forms of liver damage may heighten the ability of hepatocytes to cause death of other cells residing or passing through the liver and, in consequence, influence progression and outcomes of diseases engaging this organ (Guy *et al.*, 2008).

11. Conclusions

Liver biopsy material is invaluable for determination of the progression of viral hepatitis and assessment of the outcome of antiviral therapy, as well as for investigations into the pathogenesis of hepatocellular injury and perpetuation of hepatitis. Many of the mechanisms of liver disease, the elements of the natural course of hepadnaviral infection, the basic biological properties of hepadnaviruses as well as hepatocyte biology were delineated by utilizing liver biopsy material from the woodchuck model of hepatitis B. This overcame impediments imposed by difficulties in obtaining hepatic tissue specimens from patients with different stages of hepatitis B and from seemingly healthy individuals with silently progressing infection. The ability to obtain sequential liver biopsies prior to and over the course of experimentally induced WHV infection has led to the discovery of previously unknown characteristics and consequences of hepadnaviral infection which are only recently being recognized in the clinical setting. The woodchuck-WHV infection model retains a significant potential to generate new knowledge which should be even more vigorously explored in years to come.

12. Acknowledgements

The authors thank current and former graduate students, post-doctoral fellows and staff of the Molecular Virology and Hepatology Research Group and the Woodchuck Hepatitis Research Facility at the Faculty of Medicine, Memorial University of Newfoundland for their contributions to the research summarized in this review. The studies were supported by operating grants MOP-14818, MT-11262 and RO-15174 awarded to T.I.M. by the Canadian Institutes of Health Research (formerly Medical Research Council of Canada). P.M.M.-C. is the Manager of the Woodchuck Hepatitis Research Facility at Memorial University. T.I.M. is the Senior Canada Research Chair in Viral Hepatitis/Immunology supported by the Canadian Institutes of Health Research and Canada Foundation for Innovation.

13. References

- Alcami A. & Koszinowski U.H. (2000). Viral mechanisms of immune evasion. *Immunol. Today* 21:447-455
- Beasley R.P. (2009). Roadblocks along the road to the control of HBV and HCC. *Ann. Epidemiol.* 19:231-234

- Bertoletti A., Maini M.K. & Ferrari C. (2010). The host-pathogen interaction during HBV infection: immunological controversies. *Antivir. Ther.* 15:15-24
- Bertolino P, McCaughan G.W. & Bowen DG. (2002). Role of primary intrahepatic T-cell activation in the 'liver tolerance effect'. *Immunol. Cell. Biol.* 80:84-92
- Bläckberg J. & Kidd-Ljunggren K. (2001). Occult hepatitis B virus after acute self-limited infection persisting for 30 years without sequence variation. *J. Hepatol.* 33:992-997
- Blum H.E., Liang E., Galun E. & Wands J.R. (1991). Persistence of hepatitis B virus DNA after serological recovery from hepatitis B virus infection. *Hepatology* 14: 56-63
- Cabrerizo M., Bartolomé J., Caramelo C., Barril G. & Carreño V. (2000). Molecular analysis of hepatitis B virus DNA in serum and peripheral blood mononuclear cells from hepatitis B surface antigen-negative cases. *Hepatology* 32:116-123
- Cacoub P. & Terrier B. (2009). Hepatitis B-related autoimmune manifestations. *Rheum. Dis. Clin. North Am.* 35:125-137
- Calmus Y., Marcellin P., Beaurain G. & Brechot C. (1994). Distribution of hepatitis B virus DNA sequences in different peripheral blood mononuclear cell subsets in HBs antigen-positive and -negative patients. *Eur. J. Clin. Invest.* 24:548-552
- Carpenter P.A., Huang M.L. & McDonald G.B. (2002). Activation of occult hepatitis B from a seronegative patient after hematopoietic cell transplant: a cautionary tale. *Blood* 99:4245-4246
- Chazouilleres O., Mamish D., Kim M., Carey K., Ferrell L., Roberts J.P., Ascher N.L. & Wright T.L. (1994). "Occult" hepatitis B virus as a source of infection in liver transplant recipients. *Lancet* 343:142-146
- Chemin I., Vermot-Desroches C., Baginski I., Saurin J.C., Laurent F., Zoulim F., Bernard J., Lamelin J.P., Hantz O., Rigal D., & Trepo C. (1992). Selective detection of human hepatitis B surface and core antigen in peripheral blood mononuclear cells subsets by flow cytometry. *J. Clin. Lab. Immunol.* 38:63-71
- Chemin I., Vermot-Desroches C., Baginski I., Lamelin J.P., Hantz O., Jacquet C., Rigal D. & Trepo C. (1993). Monitoring of early events of experimental woodchuck hepatitis infection: studies of peripheral blood mononuclear cells by cytofluorometry and PCR. *FEMS Immunol. Med. Microbiol.* 7:241-249
- Chemin I., Zoulim F., Merle P., Arkhis A., Chevallier M., Kay A., Cova L., Chevallier P., Mandrand B. & Trepo C. (2001). High incidence of hepatitis B infection among chronic hepatitis cases of unknown aetiology. *J. Hepatol.* 34:447-454
- Chen H.S., Miller R.H., Hornbuckle W.E., Tennant B.C., Cote P.J., Gerin J.L. & Purcell R.H. (1998). Titration of recombinant woodchuck hepatitis virus DNA in adult woodchucks. *J. Med. Virol.* 54:92-94
- Chisari F.V. & Ferrari C. (1995). Hepatitis B virus immunopathogenesis. *Ann. Rev. Immunol.* 13:29-60
- Chisari F.V. & Ferrari C. (1996). Viral hepatitis. In: *Viral Pathogenesis*, R. Ahmed, K.V. Holmes, F. Gonzalez-Scarano, F.A. Murphy, D.E. Griffin, H.L. Robinson, (eds.), pp. 745-778, Lippincott-Raven Publishers, Philadelphia, Pennsylvania, USA
- Chisari F.V., Isogawa M. & Wieland S.F. (2010). Pathogenesis of hepatitis B infection. *Pathologie Biologie* 58:258-286
- Churchill N.D. & Michalak T.I. (2004). Woodchuck hepatitis virus hepatocyte culture models. In: *Methods in Molecular Medicine: Hepatitis B and D Protocols*, R.K.,

- Hamatake and J.Y.N. Lau (eds.), vol. 2. pp. 175-187, Humana Press Inc., Totowa, New Jersey, USA
- Coffin C.S. & Michalak T.I. (1999). Persistence of infectious hepadnavirus in the offspring of woodchuck mothers recovered from viral hepatitis. *J. Clin. Invest.* 104:203-212
- Coffin C.S., Pham T.N.Q., Mulrooney P.M., Churchill N.D. & Michalak T.I. (2004). Persistence of isolated antibodies to woodchuck hepatitis virus core antigen is indicative of occult virus infection. *Hepatology* 40:1053-1061
- Coffin C.S., Mulrooney-Cousins P.M., Peters M.G., van Marle G., Roberts J.P., Michalak T.I. & Terrault N.A. (2011a). Molecular characterization of intrahepatic and extrahepatic hepatitis B virus (HBV) reservoirs in patients on suppressive antiviral therapy. *J. Viral Hepat.* 18:415-423
- Coffin C.S., Mulrooney-Cousins P.M., van Marle G., Roberts J.P., Michalak T.I. & Terrault N.A. (2011b). Hepatitis B virus (HBV) quasispecies in hepatic and extrahepatic viral reservoirs in liver transplant recipients on prophylactic therapy. *Liver Transpl* 17:955-962.
- Conjeevaram H. & Lok A. S. (2001). Occult hepatitis B virus infection: a hidden menace? *Hepatology* 34:204-206
- Cote P.J., Korba B.E., Baldwin B., Hornbuckle W.E., Tennant B.C. & Gerin J L. (1992). Immunosuppression with cyclosporin during the incubation period of experimental woodchuck hepatitis virus infection increases the frequency of chronic infection in adult woodchucks. *J. Infect. Dis.* 166:628-631
- Cote P.J., Korba B.E., Miller R.H., Jacob J.R., Baldwin B.H., Tennant B.C. & Gerin J.L. (2000a). Effects of age and viral determinants on chronicity as an outcome of experimental woodchuck hepatitis virus infection. *Hepatology* 31:190-200
- Cote P.J., Toshkov I., Bellezza C., Ascenzi M., Roneker C., Ann Graham L., Baldwin B.H., Gaye K., Nakamura I., Korba B.E., Tennant B.C. & Gerin J.L. (2000b). Temporal pathogenesis of experimental neonatal woodchuck hepatitis virus infection: increases initial viral load and decreased severity of acute hepatitis during the development of chronic viral infection. *Hepatology* 32:807-817
- Crispe I.N. (2009). The liver as a lymphoid organ. *Annu. Rev. Immunol.* 27:147-163
- De Mitri M.S., Cassini R. & Bernardi M. (2010). Hepatitis B virus-related hepatocarcinogenesis: molecular oncogenic potential of clear or occult infections. *Eur. J. Cancer* 46:2178-2186
- Diao J. & Michalak T.I. (1996). Composition, antigenic properties and hepatocyte surface expression of the woodchuck asialoglycoprotein receptor. *J. Recept. Signal Transduct. Res.* 16:243-271
- Diao J. & Michalak T.I. (1997). Virus-induced anti-asialoglycoprotein receptor autoimmunity in experimental hepadnaviral hepatitis. *Hepatology* 25:689-696
- Diao J., Churchill N.D. & Michalak T.I. (1998). Complement-mediated cytotoxicity and inhibition of ligand binding to hepatocytes by woodchuck virus-induced autoantibodies to asialoglycoprotein receptor. *Hepatology* 27:1623-1631
- Diao J., Slaney D.M. & Michalak T.I. (2003). Modulation of the outcome and severity of hepadnaviral hepatitis in woodchucks by antibodies to hepatic asialoglycoprotein receptor. *Hepatology* 38:629-638

- Dickson R.C., Everhart J.E., Lake J.R., Wei Y., Seaberg E.C., Wiesner R.H., Zetterman R.K., Pruett T.L., Ishitani M.B. & Hoofnagle J.H. (1997). Transmission of hepatitis B by transplantation of livers from donors positive for antibody to hepatitis B core antigen. The National Institute of Diabetes and Digestive and Kidney Diseases Liver Transplantation Database. *Gastroenterology* 113:1668-1674
- Dzwonkowski P. & Michalak T.I. (1990). Autoantibody pattern in a woodchuck model of hepatitis B. *Clin. Invest. Med.* 13: 322-328
- Feitelson M.A. & Lee J. (2007). Hepatitis B virus integration, fragile sites and hepatocarcinogenesis. *Cancer Letters* 252:157-70
- Feray C., Zignego A.L., Samuel D., Bismuth A., Reynes M., Tiollais P., Bismuth H. & Brechot C. (1990). Persistent hepatitis B virus infection of mononuclear blood cells without concomitant liver infection: the liver transplantation model. *Transplantation* 49: 1155-1158
- Garcia-Navarro R., Blanco-Urgoito B., Berraondo P., Sanchez de la Rosa R., Vales A., Hervas-Stubbs S., Lasarte J.J., Borrás F., Ruiz J. & Prieto J. (2001). Protection against woodchuck hepatitis virus (WHV) infection by gene gun coimmunization with WHV core and interleukin-12. *J. Virol.* 75:9068-9076
- Gerlich W.H., Bremer C., Saniewski M., Schuttler C.G., Wend U.C., Willems W.R. & Glebe D. (2010). Occult hepatitis B virus infection: detection and significance. *Dig. Dis.* 28:116-125
- Grob P., Jilg W., Bornhak H., Gerken G., Gerlich W., Gunther S., Hess G., Hudig H., Kitchen A., Margolis H., Michel G., Trepo C., Will H., Zanetti A. & Mushahwar I. (2000). Serological pattern "anti-HBc alone": report on a workshop. *J. Med. Virol.* 62: 450-455
- Guidotti L.G., Rochford R., Chung J., Shapiro M., Purcell R. & Chisari F.V. (1999). Viral clearance without destruction of infected cells during acute HBV infection. *Science* 284:825-829
- Guidotti L.G. & Chisari F.V. (2001). Non-cytolytic control of viral infections by the innate and adaptive immune response. *Annu. Rev. Immunol.* 19:65-91
- Gujar S.A., Jenkins A.K., Guy C.S., Wang J. & Michalak T.I. (2008). Aberrant lymphocyte activation preceded delayed virus-specific T cell response after both primary infection and secondary exposure to hepadnavirus in the woodchuck model of hepatitis B infection. *J. Virol.* 82:6992-7008
- Gujar S. A. & Michalak T.I. (2009). Primary occult hepadnavirus infection induces virus-specific T-cell and aberrant cytokine responses in the absence of antiviral antibody reactivity in the woodchuck model of hepatitis B virus infection. *J. Virol.* 83:3861-3876
- Guy C.S., Wang J. & Michalak T.I. (2006). Hepatocytes as cytotoxic effector cells can induce cell death by CD95 ligand-mediated pathway. *Hepatology* 43:1231-1240
- Guy C.S. & Michalak T.I. (2008). Hepatocytes as cytotoxic effector cells. *Curr. Immunol. Rev.* 4:215-220
- Guy C.S., Mulrooney-Cousins P.M., Churchill N.D. & Michalak, T.I. (2008a). Intrahepatic expression of genes affiliated with innate and adaptive immune responses immediately after invasion and during acute infection with woodchuck hepadnavirus. *J. Virol.* 82:8579-8591

- Guy C.S., Rankin S.L., Wang J. & Michalak T.I. (2008b). Hepatocytes can induce death of contacted cells via perforin-dependent mechanism. *Hepatology* 47:1691-1701
- Guy C.S. & Michalak T.I. (2010). Hepadnaviral infection augments hepatocyte cytotoxicity mediated by both CD95 ligand and perforin pathways. *Liver Int* 30:396-405
- Guy C.S., Rankin S.L. & Michalak T.I. (2011). Hepatocyte cytotoxicity is facilitated by asialoglycoprotein receptor. *Hepatology* (in press; e-pub ahead of print Jun 7; doi: 10.1002/hep.24477)
- Hodgson P.D. & Michalak T.I. (2001). Augmented hepatic interferon gamma expression and T-cell influx characterize acute hepatitis progressing to recovery and residual lifelong virus persistence in experimental adult woodchuck hepatitis virus infection. *Hepatology* 34:1049-1059
- Hollinger F.B. & Sood G. (2010). Occult hepatitis B virus infection: a covert operation. *J. Viral Hepat.* 17:1-15
- Hu K.Q. (2002). Occult hepatitis B virus infection and its clinical implications. *J. Viral Hepatitis* 9:243-257
- Jin Y.-M., Churchill N.D. & Michalak T.I. (1996). Protease-activated lymphoid cell and hepatocyte recognition site in the preS1 domain of the large woodchuck hepatitis virus envelope protein. *J. Gen. Virol.* 77:1837-1846
- Kajino K., Jilbert A.R., Saputelli J., Aldrich C.E., Cullen J. & Mason W.S. (1994). Woodchuck hepatitis virus infections: very rapid recovery after a prolonged viremia and infection of virtually every hepatocyte. *J. Virol.* 68: 5792-5803
- Kao J.H. (2008). Diagnosis of hepatitis B virus infection through serological and virological markers. *Expert. Rev. Gastroenterol. Hepatol.* 2:553-562
- Korba B.E., Wells F., Tennant B.C., Cote P.J. & Gerin J. L. (1987). Lymphoid cells in the spleens of woodchuck hepatitis virus-infected woodchucks are a site of active viral replication. *J. Virol.* 61:1318-1324
- Korba B.E., Cote P.J. & Gerin J.L. (1988). Mitogen-induced replication of woodchuck hepatitis virus in cultured peripheral blood lymphocytes. *Science* 241:1213-1216
- Korba B.E., Wells F.V., Baldwin B., Cote P.J., Tennant B.C., Popper H. & Gerin J.L. (1989). Hepatocellular carcinoma in woodchuck hepatitis virus infected woodchucks. Presence of viral DNA in tumor tissue from chronic carriers of animals serologically recovered from acute infections. *Hepatology* 9:461-470
- Laskus T., Radkowski M., Wang L.F., Nowicki M. & Rakela J. (1999). Detection and sequence analysis of hepatitis B virus integration in peripheral blood mononuclear cells. *J. Virol.* 73: 1235-1238
- Lew Y.-Y. & Michalak T.I. (2001). *In vitro* and *in vivo* infectivity and pathogenicity of the lymphoid cell-derived woodchuck hepatitis virus. *J. Virol.* 75:1770-1782
- Lia M. & Liaw Y.F. (2010). Chronic hepatitis B: past, present, and future. *Clin. Liver Dis.* 14:531-546
- Liang T.J., Blum H. E. & Wands J. R. (1990). Characterization and biological properties of a hepatitis B virus isolated from a patient without hepatitis B virus serologic markers. *Hepatology* 12:204-212
- Liaw Y.F., Brunetto M. R. & Hadziyannis S. (2010). The natural history of chronic HBV infection and geographical differences. *Antiviral Therapy* 15:25-33

- Lledo J.L., Fernandez C., Gutierrez M.L. & Ocana S. (2011). Management of occult hepatitis B virus infection: An update for the clinician. *World J. Gastro.* 17:1563-1568
- Lok A.S., Liang R.H., Chiu E. K., Wong K. L., Chan T. K. & Todd D. (1991). Reactivation of hepatitis B virus replication in patients receiving cytotoxic therapy: report of a prospective study. *Gastroenterology* 100:1432-1434
- Marusawa H., Uemoto S., Hijikata M., Ueda Y., Tanaka K., Shimotohno K. & Chiba T. (2000). Latent hepatitis virus infection in healthy individuals with antibodies to hepatitis B core antigen. *Hepatology* 31:488-495
- Mason A., Yoffe B., Noonan C., Mearns M., Campbell C., Kelley A. & Perrillo R. P. (1992). Hepatitis B virus DNA in peripheral-blood mononuclear cells in chronic hepatitis B after HBsAg clearance. *Hepatology* 16:26-41
- Mason A.L., Xu L., Guo L., Kuhns M. & Perrillo R.P. (1998). Molecular basis for persistent hepatitis B virus infection in the liver after clearance of serum hepatitis B surface antigen. *Hepatology* 27:1736-1742
- Mason W.S., Jilbert A.R. & Summers J. (2005). Clonal expansion of hepatocytes during chronic woodchuck hepatitis virus infection. *Proc. Natl. Acad. Sci. USA* 102:1139-1144
- Mason W.S., Low H.C., Xu C., Aldrich C.E., Scougall C.A., Grosse A., Clouston A., Chavez D., Litwin S., Peri S., Jilbert A.R. & Lanford R.E. (2009). Detection of clonally expanded hepatocytes in chimpanzees with chronic hepatitis B virus infection. *J. Virol.* 83:8396-8408
- Menne S. & Tennant B.C. (1999). Unravelling hepatitis B virus infection of mice and men (and woodchucks and ducks). *Nature Med.* 5:1125-1126
- Menne S. & Cote P.J. (2007). The woodchuck as an animal model for pathogenesis and therapy of chronic hepatitis B virus infection. *World J. Gastro.* 13:104-124
- Michalak T. (1978). Immune complexes of hepatitis B surface antigen in the pathogenesis of periarteritis nodosa. A study of seven necropsy cases. *Am. J. Pathol.* 90:619-632
- Michalak T.I. (1988). Woodchuck hepatitis virus surface antigen association with purified liver plasma membranes from chronic carriers of woodchuck hepatitis virus. In: *Viral Hepatitis and Liver Disease*, A. Zuckerman (ed), pp. 476-480, Alan R. Liss, Inc., New York, USA
- Michalak T.I. & Churchill N.D. (1988). Interaction of woodchuck hepatitis virus surface antigen with hepatocyte plasma membrane in woodchuck chronic hepatitis. *Hepatology* 8:499-506
- Michalak T.I., Lin B., Churchill N.D., Dzwonkowski P. & Desousa J.R. (1990). Hepadnavirus nucleocapsid and surface antigens and the antigen-specific antibodies associated with hepatocyte plasma membranes in experimental woodchuck acute hepatitis. *Lab Invest.* 6:680-689
- Michalak T.I. & Lin B. (1994). Molecular species of hepadnavirus core and envelope polypeptides in hepatocyte plasma membrane of woodchucks with acute and chronic viral hepatitis. *Hepatology* 20:275-286
- Michalak T.I., Pasquinelli C., Guilhot S. & Chisari F.V. (1994). Hepatitis B virus persistence after recovery from acute viral hepatitis. *J. Clin. Invest.* 93:230-239

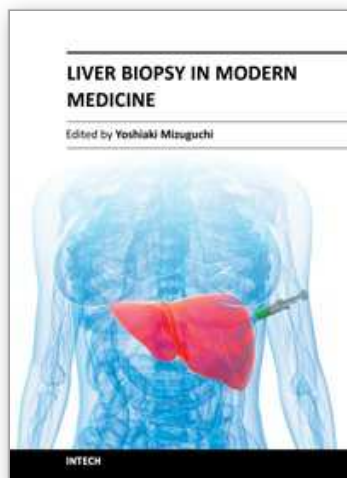
- Michalak T.I., Churchill N.D., Codner D., Drover S. & Marshall W.H. (1995). Identification of woodchuck class I MHC antigens using monoclonal antibodies. *Tissue Antigens*. 45:333-342
- Michalak T. I. (1998). The woodchuck animal model of hepatitis B. *Viral Hepatitis Rev.* 4:139-165
- Michalak T.I., Pardoe I.U., Coffin C.S., Churchill N.D., Freake D.S., Smith P. & Trelegan C.L. (1999). Occult life-long persistence of infectious hepadnavirus and residual liver inflammation in woodchucks convalescent from acute viral hepatitis. *Hepatology* 29:928-938
- Michalak T.I. (2000). Occult persistence and lymphotropism of hepadnaviral infection: insights from the woodchuck viral hepatitis model. *Immunol. Rev.* 174:98-111
- Michalak T.I., Hodgson P.D. & Churchill N.D. (2000). Posttranscriptional inhibition of class I major histocompatibility complex presentation on hepatocytes and lymphoid cells in chronic woodchuck hepatitis virus infection. *J. Virol.* 74:4483-4494
- Michalak T.I. (2004). Immunology of hepatitis B virus. In: *Hepatitis Prevention and Treatment*, J.M. Colacino and B.A. Heinz (eds.), pp.87-105, Birkhauser Verlag Publishers, Basel, Switzerland
- Michalak T.I., Mulrooney P.M. & Coffin C.S. (2004). Low doses of hepadnavirus induce infection of the lymphatic system that does not engage the liver. *J. Virol.* 78:1730-1738
- Michalak T.I. (2007). Characteristics and consequences of experimental occult hepadnavirus infection in the woodchuck model of hepatitis B. *Curr. Topics Virol.* 6:1-13
- Michalak T.I., Pham T.N.Q. & Mulrooney-Cousins P.M. (2007). Molecular diagnosis of occult HCV and HBV infections. *Future Medicine* 2:451-465
- Morisco F., Castiglione F., Rispo A., Stroffolini T., Vitale R., Sansone S., Granata R., Orlando A., Marmo R., Reigler G., Vecchi M., Biancone L. & Caporaso N. (2011). Hepatitis B virus infection and immunosuppressive therapy in patients with inflammatory bowel disease. *Dig. Liver Dis.* 43:40-48
- Mulrooney P.M. & Michalak T.I. (2003). Quantitative detection of hepadnavirus-infected lymphoid cells by *in situ* PCR combined with flow cytometry: implications for the study of occult virus persistence. *J. Virol.* 77:970-979
- Mulrooney-Cousins P.M. & Michalak T.I. (2007). Persistent occult hepatitis B virus infection: experimental findings and clinical implications. *World J. Gastro.* 13:5682-5686
- Mulrooney-Cousins P.M. & Michalak T.I. (2008). Repeated passage of wild-type woodchuck hepatitis virus in lymphoid cells does not generate cell type-specific variants or alter virus infectivity. *J. Virol.* 82:7540-7550
- Mulrooney-Cousins P.M. & Michalak T.I. (2009). Diagnostic assays for hepatitis B virus. *Hot Topics in Viral Hepatitis* 15:7-13
- Murakami Y., Minami M., Daimon Y. & Okanoue T. (2004). Hepatitis B virus DNA in liver, serum, and peripheral blood mononuclear cells after the clearance of serum hepatitis B surface antigen. *J. Med. Virol.* 72:203-214
- Murray K., Bruce S.A., Wingfield P., van Eerd P., de Reus A, & Schellekens H. (1987). Protective immunisation against hepatitis B with an internal antigen of the virus. *J. Med. Virol.* 23:101-107

- Nassal M. (2008). Hepatitis B viruses: reverse transcription in a different way. *Virus Res.* 134:235-49
- Ogston C.W., Schechter E.M., Humes C.A. & Pranikoff M.B. (1989). Extrahepatic replication of woodchuck hepatitis virus in chronic infection. *Virology* 169:9-14
- Penna A., Artini M., Cavalli A., Levero M., Bertoletti A., Pilli M., Chisari F.V., Rehermann B., Del Prete G., Fiaccadori F. & Ferrari C. (1996). Long-lasting memory T cell responses following self-limited acute hepatitis B. *J. Clin. Invest.* 98:1185-1194
- Pollicino T., Squandrito G., Cerenzia G., Cacciola I., Raffa G., Crax A., Farinati F., Missale G., Smedile A., Tiribelli C., Villa E. & Raimondo G. (2004). Hepatitis B virus maintains its pro-oncogenic properties in the case of occult HBV infection. *Gastroenterology* 126:102-110
- Pontisso P., Poon M.V., Tiollais P. & Brechot C. (1984). Detection of hepatitis B virus DNA in mononuclear cells. *Br. Med. J.* 288:1563-1566
- Pontisso P., Vidalino L., Quarta S. & Gatta A. (2008). Biological and clinical implications of HBV infection in peripheral blood mononuclear cells. *Autoimm. Rev.* 8:13-17
- Popper H., Shih W. W-K., Gerin D.C., Wong D.C., Hoyer B.H., London W.T., Sly D.L. & Purcell R.H. (1981). Woodchuck hepatitis and hepatocellular carcinoma: correlation of histologic with virologic observations. *Hepatology* 1:91-98
- Poralla T., Treichel U., Lohr H. & Fleischer B. (1991). The asialoglycoprotein receptor as target structure in autoimmune liver diseases. *Semin Liver Dis* 11:215-222
- Raimondo G., Allain, J.P., Brunetto, M.R., Buendia M.A., Chen D.-S., Colombo M., Craxi A., Donato F., Ferrari C., Gaeta G.B., Gerlich W.H., Levrero M., Locarnini S., Michalak, T.I., Mondeli M.U., Pawlowsky J.-M., Pollicino T., Prati D., Puoti M., Samuel D., Shouval S., Smedile A., Squadrito G., Trepo C., Villa E., Will H., Zanetti A.R. & Zoulim F. (2008). Statements from the Taormina expert meeting on occult hepatitis B virus infection. *J. Hepatol.* 49:652-657
- Rehermann B., Fowler P., Sidney J., Person J., Redeker A., Brown M., Moss B., Sette A. & Chisari F.V. (1995). The cytotoxic T lymphocyte response to multiple hepatitis B virus polymerase epitopes during and after acute viral hepatitis. *J. Exp. Med.* 181:1047-1058
- Rehermann B., Lau D., Hoofnagle J.H. & Chisari F.V. (1996a). Cytotoxic T lymphocyte responsiveness after resolution of chronic hepatitis B virus infection. *J. Clin. Invest.* 97:1655-1665
- Rehermann B., Ferrari C., Pasquinelli C. & Chisari F.V. (1996b). The hepatitis B virus persists for decades after patients' recovery from acute viral hepatitis despite active maintenance of a cytotoxic T-lymphocyte response. *Nature Med.* 2:1104-1108
- Roggendorf M., Yang D. & Lu M (2010). The woodchuck: a model for therapeutic vaccination against hepadnaviral infection. *Pathologie Biologie* 58:308-314
- Romano L., Paladini S., Van Damme P. & Zanetti A.R. (2011). The worldwide impact of global vaccination on the control and protection of viral hepatitis B. *Dig. Liver Dis.* 43:S2-7
- Said Z.N. (2011). An overview of occult hepatitis B virus infection. *World J. Gastro.* 17: 1927-1938

- Schlicht H.J., von Brunn A. & Theilmann L. (1991). Antibodies in anti-HBe-positive patient sera bind to an HBe protein expressed on the cell surface of human hepatoma cells: implications for virus clearance. *Hepatology* 13:57-61
- Schmeltzer P. & Sherman K.E. (2010). Occult hepatitis B: clinical implications and treatment decisions. *Dig. Dis. Sci.* 55:3328-3335
- Simonetti J., Bulkow L., McMahon B.J., Homan C., Snowball M., Negus S., Williams J. & Livingstone S. E. (2010). Clearance of hepatitis B surface antigen and risk of hepatocellular carcinoma in a cohort chronically infected with hepatitis B virus. *Hepatology* 51:1531-1537
- Summers J., Smolec J.M., & Snyder R. (1978). A virus similar to human hepatitis B virus associated with hepatitis and hepatoma in woodchucks. *Proc. Natl. Acad. Sci. USA* 75:4533-4537
- Summers J. & Mason W.S. (1982). Replication of the genome of a hepatitis B-like virus by reverse transcription of an RNA intermediate. *Cell* 29:403-415
- Tong M. J., Nguyen M.O., Tong L.T. & Blatt L.M. (2009). Development of hepatocellular carcinoma after seroclearance of hepatitis B surface antigen. *Clin. Gastroenterol. Hepatol.* 7:889-893
- Uemoto S., Sugiyama K., Marusawa H., Inomata Y., Asonuma K., Egawa H., Kiuchi T., Miyake Y., Tanaka K. & Chiba T. (1998). Transmission of hepatitis B virus from hepatitis B core antibody-positive donors in living related liver transplantation. *Transplantation* 65:494-499
- Villadolid J., Laplant K.D., Markham M. J., Nelson D.R. & George T.J. Jr. (2011). Hepatitis B reactivation and rituximab in the oncology practice. *Oncologist* 15: 1113-1121
- Wang J. & Michalak T.I. (2005). Comparison of biological activity of recombinant woodchuck interferon gamma and tumor necrosis factor alpha produced in baculovirus and *Escherichia coli* expression systems. *Cytokine* 30:22-34
- Wang J. & Michalak T.I. (2006). Inhibition by woodchuck hepatitis virus of class I major histocompatibility complex presentation on hepatocytes is mediated by virus envelope pre-S2 protein and can be reversed by treatment with gamma interferon. *J. Virol.* 80:8541-8553
- Wang J., Gujar S.A., Cova L. & Michalak T.I. (2007). Biscistronic woodchuck hepatitis virus core and gamma interferon DNA vaccine can protect from hepatitis but does not elicit sterilizing antiviral immunity. *J. Virol.* 81:903-916
- Warren A., Le Couteur D.G., Fraser R., Bowen D.G., McCaughan G.W. & Bertolino P. (2006). T lymphocytes interact with hepatocytes through fenestrations in murine liver sinusoidal endothelial cells. *Hepatology* 44:1182-1190
- Wei Y., Neuveut C., Tiollais P. & Buendia M.A. (2010). Molecular biology of hepatitis B virus and role of the X gene. *Pathologie Biologie* 58:267-272
- Will H., Cattaneo R., Koch H.G., Darai G. & Schaller H. (1982). Cloned HBV DNA causes hepatitis in chimpanzees. *Nature* 299:740-742
- World Health Organization. (August, 2008). Hepatitis B fact sheet No. 204, In: World Health Organization/HepatitisB/ Media Centre, April 2011, Available from: <http://www.who.int/mediacentre/factsheets/fs204/en/index.html>

- Yoffe B., Noonan C.A., Melnick J.L. & Hollinger F.B. (1986). Hepatitis virus DNA in mononuclear cells and analysis of cell subsets for the presence of replicative intermediates of viral DNA. *J. Infect. Dis.* 153:471-477
- Yotsuyanagi H., Yasuda K., Iino S., Moriya K., Shintani Y., Fujie H., Tsutsumi T., Kimura S. & Koike K. (1998). Persistent viremia after recovery from self-limited acute hepatitis B. *Hepatology* 27:1377-1382
- Yuki N., Nagaoka T., Yamashiro M., Mochizuki K., Kaneko A., Yamamoto K., Omura M., Hikiji K. & Kato M. (2003). Long-term histologic and virologic outcomes of acute self-limited hepatitis B. *Hepatology* 37:1172-1179
- Zerbini A., Pilli M., Boni C., Fisicaro P., Penna A., Di Vincenzo P., Giuberti T., Orlandini A., Raffa G., Pollicino T., Raimondo G., Ferrari C. & Missale G. (2008). The characteristics of the cell-mediated immune response identify different profiles of occult hepatitis B virus infection. *Gastroenterology* 134:1470-1481

IntechOpen



Liver Biopsy in Modern Medicine

Edited by Dr. Yoshiaki Mizuguchi

ISBN 978-953-307-883-0

Hard cover, 378 pages

Publisher InTech

Published online 10, October, 2011

Published in print edition October, 2011

Liver biopsy, first performed by Paul Ehrlich in 1883, remains an important diagnostic procedure for the management of hepatobiliary disorders and the candidate/donated organ for transplantation. The book "Liver biopsy in Modern Medicine" comprises 21 chapters covering the various aspects of the biopsy procedure in detail and provides an up-to-date insightful coverage to the recent advances in the management of the various disorders with liver biopsy. This book will keep up with cutting edge understanding of liver biopsy to many clinicians, physicians, scientists, pharmaceuticals, engineers and other experts in a wide variety of different disciplines.

How to reference

In order to correctly reference this scholarly work, feel free to copy and paste the following:

Patricia M. Mulrooney-Cousins and Tomasz I. Michalak (2011). New Aspects of Natural History and Pathogenicity of Hepadnaviral Infection and Hepatocyte Function Revealed by the Woodchuck Model of Hepatitis B, Liver Biopsy in Modern Medicine, Dr. Yoshiaki Mizuguchi (Ed.), ISBN: 978-953-307-883-0, InTech, Available from: <http://www.intechopen.com/books/liver-biopsy-in-modern-medicine/new-aspects-of-natural-history-and-pathogenicity-of-hepadnaviral-infection-and-hepatocyte-function-r>

INTECH
open science | open minds

InTech Europe

University Campus STeP Ri
Slavka Krautzeka 83/A
51000 Rijeka, Croatia
Phone: +385 (51) 770 447
Fax: +385 (51) 686 166
www.intechopen.com

InTech China

Unit 405, Office Block, Hotel Equatorial Shanghai
No.65, Yan An Road (West), Shanghai, 200040, China
中国上海市延安西路65号上海国际贵都大饭店办公楼405单元
Phone: +86-21-62489820
Fax: +86-21-62489821

© 2011 The Author(s). Licensee IntechOpen. This is an open access article distributed under the terms of the [Creative Commons Attribution 3.0 License](https://creativecommons.org/licenses/by/3.0/), which permits unrestricted use, distribution, and reproduction in any medium, provided the original work is properly cited.

IntechOpen

IntechOpen