

# We are IntechOpen, the world's leading publisher of Open Access books Built by scientists, for scientists

6,900

Open access books available

186,000

International authors and editors

200M

Downloads

Our authors are among the

154

Countries delivered to

TOP 1%

most cited scientists

12.2%

Contributors from top 500 universities



WEB OF SCIENCE™

Selection of our books indexed in the Book Citation Index  
in Web of Science™ Core Collection (BKCI)

Interested in publishing with us?  
Contact [book.department@intechopen.com](mailto:book.department@intechopen.com)

Numbers displayed above are based on latest data collected.  
For more information visit [www.intechopen.com](http://www.intechopen.com)



# Endoscopic Management of Biliary Complications After Liver Transplantation

Firas Zahr ElDeen, Ching-Song Lee and Wei-Chen Lee  
*Chang-Gung Transplantation Institute, Chang-Gung Memorial Hospital,  
 Chang-Gung University College of Medicine, Taoyuan,  
 Taiwan*

## 1. Introduction

Biliary reconstruction has been described 35 years ago by Sir Roy Calne as the technical 'Achilles heel' of orthotopic liver transplantation (OLT). The name "Achilles' heel" comes from Greek mythology, which is a metaphor of a single vulnerable spot. This is because the potential detrimental effects of biliary complications on graft and patient survival. Biliary complications, which "plagued" the early experience of liver transplantation occurring in nearly one of every three transplant recipients (Moser & Wall, 2001), have been reduced dramatically due to the improvements in organ selection, retrieval, preservation, and implantation techniques. However, biliary complications still remain a common source of morbidity and mortality (Greif et al., 1994). Additionally, they significantly affect the recipients' quality of life because they entail frequent readmissions, repeated imaging, invasive procedures, and even reoperation. All of them added to the financial and emotional toll suffer the patients (Sharma et al., 2008). Biliary leaks and strictures, either anastomotic or non-anastomotic, are the most frequent complications. Cystic duct obstruction due to mucocele, stones, sludge or casts, hemobilia and sphincter of Oddi dysfunction have also been recorded (Colonna et al., 1992; Greif et al., 1994). The surgical management used to be the standard of care for these conditions in earlier practice. However, the revolutionary progress in minimally invasive armamentarium, namely endoscopy and percutaneous radiologic interventional modalities, made it the current alternative first line of management displacing surgical intervention to be a second backup option (Sharma et al., 2008; Williams & Draganov, 2009). A living donor liver transplantation (LDLT) was first reported in 1988 by Raia in Brazil, followed by Nagasue in Japan in 1989. After the leading successful experience of right lobe living related liver transplantation (RL-LDLT) that has been reported by Hong Kong team in 1996, it rapidly evolved as a well-established practice in Asian countries. World wide organ shortage and promising results were alluring to other centers to consider (RL-LDLT) as a practical option. In this review we will shed more light on biliary complications related to right lobe living donor liver transplantation and their endoscopic management.

### 1.1 Incidence of biliary complications

Apparently, patients who were transplanted more recently are at increased risk of biliary complications. This could be explained by the awareness of this major problem, evolution of

both invasive and non invasive diagnostic modalities, and more importantly, the marked increase in graft survival in the last decade since biliary problems such as strictures need some time to develop and become evident (Verdonk et al., 2006). The incidence of biliary complications is greatest in the first few months after transplantation. The frequency becomes very low after the first post transplantation year; however, occasionally appear after several years (Moser & Wall, 2001). The reported incidence of such complications differs considerably among centers which can be attributed to the wide variety of research methodologies as well as the different surgical techniques adopted. In a review article which included six studies over several years from various countries, the overall biliary complication rate in deceased donor liver transplantation (DDLT) averaged 17.3% (range, 9%–30%) with 6.8% (range, 0.3%–17%) bile leaks and 7.5% (range, 3%–13%) strictures (Dualilibi et al., 2010). While, overall biliary complication incidence in living donor liver transplantation (LDLT) was found to be 28.7% (range, 16.1%–33.3%) with 17.1% (range, 9.3%–23%) bile leaks and 15.2% (range, 9.3%–27%) strictures. These results were higher compared to those in other reviews. For instance, in a review article (Pascher & Neuhaus, 2005), 18.3% (8%–26.6%) was the reported incidence of biliary complications after right hepatic lobe grafting with 10.5% (range, 0%–26.6%) leakages and 9.1% (range, 3.3%–20%) strictures. Finally our results in right lobe LDLT show that rate of leakage and stricture were 14.4% and 18.9%, respectively (Lee et al., 2008). From the above figures, overall rate of biliary complications was lower in DDLT compared with LDLT; however, variables were poorly linked. Perhaps standardization of methodologies and large scale research could help us to discover correlations between complications and modalities of transplantation. Taken together, higher rates of biliary complications may suggest that the inherently sensitive nature of the biliary epithelium is more vulnerable to ischemic damage in comparison with hepatocytes and vascular endothelium (Sharma et al., 2008).

## **1.2 Etiology and classification of biliary complications after liver transplantation**

The etiology of biliary complications is multifactorial. Risk factors implicated include elderly donor (Shah et al., 2007), gender mismatch with a female donor/male recipient (Verdonk et al., 2006), female recipient, age of recipient, severity of original disease, variations in the biliary tract anatomy, number and size of reconstructed bile duct(s), techniques in graft procurement and diseased liver removal, ischemic damage to bile duct (hepatic artery complication, warm and cold ischemia time, bile duct blood supply), method of biliary reconstruction (type, suture methods, suture material, stent, or T-tube use), immunological issues (ABO incompatibility, preformed antibody), infection (biliary sepsis, cytomegalovirus) (Todo et al., 2005). Moreover, Bile leakage after transplantation has been considered as a significant risk factor for the development of strictures (Lee et al., 2008; Shah et al., 2007; Verdonk et al., 2006). Other uncommon etiological factors that may present with biliary obstruction are post-transplantation lymphoproliferative disease and recurrent or de novo cancer (Wojcicki et al., 2008). In a review article published in 2005 (Todo et al., 2005), authors broadly classified the factors that must be considered while contemplating biliary complications, namely, biliary strictures after LDLT into two categories: anatomical and technical.

## **2. Anatomical factors**

### **2.1 Bile duct anatomy**

Clear understanding of biliary anatomy is crucial in living donor liver transplantation to ensure donor safety and to minimize complications in recipients. According to Couinaud's

classification, patterns of the hepatic duct confluence fall into six groups: (A) typical anatomy (57%), (B) triple confluence (12%), (C) ectopic drainage of a right duct (anterior or posterior) into the common hepatic duct (20%), (D) ectopic drainage of a right duct (anterior or posterior) into the left hepatic duct (6%), (E) absence of the hepatic duct confluence (3%), and (F) absence of the right hepatic duct and ectopic drainage of the right posterior duct into the cystic duct (2%). These findings are comparable to those observed during hepatic resection and LDLT donor surgeries. Thanks to recent imaging modalities, particularly multiphase three-dimensional studies, that allowed us to identify invaluable preoperative information on the graft volume and the vascular structures. However, imaging studies of the biliary tree are still significantly less reliable. Therefore, it has been suggested to perform intraoperative cholangiography at every donor hepatectomy in LDLT to confirm bile duct anatomy and the point of bile duct transection (Todo et al., 2005).

## **2.2 Blood supply of bile duct**

Bile duct receives 60% its blood supply from axial branches arising from the posterior superior pancreaticoduodenal artery and the gastro-duodenal artery at 3 O'clock and 9 O'clock positions; while right and left hepatic arteries provides 38% of blood supply via a fine arterial plexus at the inferior aspect of the hilar plate nourishing the confluence and bilateral hepatic ducts. The remaining 2% of blood supply comes from the proper hepatic artery via transversal branches. Therefore, injury of the hilar plexus during donor or recipient hepatectomy may lead to leakage, stricture, or even necrosis due to bile duct ischemia (Todo et al., 2005).

## **3. Technical considerations**

### **3.1 Donor hepatectomy (Graft harvesting)**

Standard techniques and refinements in graft preparation have been described thoroughly in literature. Technical safeguards have been stressed upon based on biliary and arterial anatomical considerations including intraoperative cholangiography which has been advocated for safer intrahepatic bile duct division, leaving at least 2 mm stump from the confluence to secure safe closure, avoidance of dissection between hepatic duct and the hepatic artery beyond level of transection to maintain uninterrupted blood supply to bile ducts, avoidance of ischemic damage to the graft bile duct by excessive use of diathermy, and using fine suture ligation alternatively to control minor bleeding (Todo et al., 2005).

### **3.2 Recipient hepatectomy (Liver explantation)**

By the same token, we should bear in mind biliary and arterial anatomical considerations in recipient hepatectomy. Preservation of uninterrupted blood supply to the biliary tract as high as possible in the hilum and leaving enough length for a tension-free biliary anastomosis are paramount. This has been fulfilled by a high hilar dissection method or intrahepatic Glissonian approach that proposed by Lee et al. and they showed good results in their series of adult duct to duct liver transplantation patients (Todo et al., 2005).

### **3.3 Graft implantation (Biliary reconstruction)**

#### **3.3.1 Type of biliary anastomosis**

Early practice of utilizing gallbladder as a pedicle graft biliary conduit had been abandoned due to associated bile stasis with stone formation, frequent episodes of cholangitis and

inferior outcomes. Roux-en-Y hepaticojejunostomy was the standard biliary reconstruction in living-donor liver transplantation and split liver transplantation. The growing evidence and experience in transplantation urged the surgeons to restore bilioenteric continuity through a duct-to-duct anastomosis which becomes the preferred choice of biliary reconstruction whenever possible and this for the following reasons: (i) technically faster, less number of anastomoses, (ii) preserved function of sphincter of Oddi as a defense against enteric reflux and ascending cholangitis, (iii) no need for intestinal manipulation, thus preventing possible intraoperative contamination and earlier oral feeding, (iv) the physiological bilio-enteric continuity enabling endoscopic access after right lobe-LDLT and (v) more treatment options for biliary complications including percutaneous approach, endoscopic approach, surgical revision, and surgical conversion to Roux-en-Y bilioenteric anastomosis (Yazumi & Chiba, 2005). Duct-to-duct anastomosis has been increasingly reported in right lobe living-donor transplants (Shah et al., 2007), in right lobe split transplants and also has been shown to be feasible in left lobe living-donor liver transplants. In earlier experience of living donor liver transplantation, duct-to-duct anastomosis has been only performed in presence of single biliary anastomosis. The use of the recipient right and left hepatic ducts as well as the cystic duct has been successfully utilized in later practice (Gondolesi et al., 2004). Having said that, Roux-en-Y reconstruction is still indispensable in pediatric LDLT, patients with bile duct diseases or prior biliary surgery, retransplantation (Todo et al., 2005), left lateral segment split liver grafts, left lateral segment and left lobe living donor grafts in presence of separate segmental II and III ducts, segment IV duct draining into the confluence, and the presence of multiple small bile ducts in grafts harvested with caudate lobe; and still an option in right lobe graft with multiple small bile ducts (Cuinaud's classification, types C-F). It is worth to mention that both duct-to-duct anastomosis and jejunal loop could be used in the same patient having a graft with multiple small ducts (Wojcicki et al., 2008). In an article published in 2005 (Yazumi & Chiba, 2005), the incidence of biliary complications has been reviewed and it had been shown the incidence of anastomotic leakage in right lobe living donor liver transplantation (RL-LDLT) with Roux-en-Y hepatico-jejunostomy (RYHJ) was higher than that with duct-to-duct anastomosis (12.4%–18.2% and 4.7%–7.3%, respectively), while on the other side, the incidence of anastomotic stricture in RL-LDLT with RYHJ was found to be less than that with duct-to-duct anastomosis (8.3%–16.3% and 24.3%–31.7%, respectively) (Yazumi & Chiba, 2005). Although the superiority of either hepaticojejunostomy or duct-to-duct for biliary reconstruction in adult LDLT was debatable issue, it has been concluded that surgeons should follow the principle of tension-free, viable anastomosis, and be accustomed to both procedures at the forum of European Association for the Study of the Liver in 2005 annual meeting (Todo et al., 2005).

### 3.3.2 Stent or no stent

There is an ongoing hot debate regarding the use of a T tube for duct-to-duct anastomosis. Traditionally, proponents of using biliary stents argue that T tube aids to access biliary tree, monitor the quality and quantity of bile output, decrease the incidence of late anastomotic strictures, and lower the pressure in the biliary system which may be elevated as a result of anastomotic stricture or to sphincter of Oddi dysfunction (Rabkin et al., 1998). On the other hand, biliary drains were considered by opponents to increase complication rates as shown by frequent reports of biliary leak following bile drain removal, dislodgement, cholangitis and/or biliary obstruction (Greif et al., 1994; Scatton et al., 2001). The incidence of biliary



drain related complications was found to range between 10 and 22% (Wojcicki et al., 2008), with bile leak after bile drain removal occurring in 5–15% of patients (Scatton et al., 2001; Vougas et al., 1996). The use of T tube in deceased-donor liver transplantation has been widely abandoned. This practice has been adopted after two prospective randomized trials (Scatton et al., 2001) showing that not using T tubes seems to be safe, efficacious, and cost-effective. Some have suggested that using 6 F double J ureteric as internal stents theoretically could eliminate possible complications associated with T tubes and offers the potential benefits of a splint. Yet, this has not shown uniformly reproducible results (Sharma et al., 2008). Stenting or no stenting of biliary reconstruction in living donor liver transplantation is still a debate that is far from being settled (Wojcicki et al., 2008).

### **3.3.3 Suturing technique and suture material**

Using continuous or interrupted sutures, conventional or microscopic biliary reconstruction, absorbable or non absorbable sutures material in biliary anastomosis, is also a technical issue that has not been standardized. However, some authors recently advocated the use of microsurgical technique and synthetic non-absorbable sutures (Lin et al., 2009) for their feasibility, easier handling, supposedly less induction of the tissue reaction (Sharma et al., 2008) and theoretical durability in the early postoperative period especially with steroid based immunosuppressive regimen.

### **3.3.4 Implantation (vascular reconstruction)**

Ischemic biliary problems are among the most troublesome complications both in early and late post transplantation periods. Two main broad categories are identified: hepatic artery thrombosis (HAT) and ischemic type biliary lesions (ITBL).

#### **3.3.4.1 Hepatic artery thrombosis (HAT) or macroangiopathy**

Hepatic artery thrombosis is generally divided into two categories: early and late hepatic artery thrombosis (eHAT and late HAT). Reports on eHAT are heterogeneous due to a lack of a commonly accepted definition. A systematic review by Bekker et al. from Netherlands that included all published work from 1990 to 2007 has provided us with valuable definitions. Early HAT is defined as a thromboembolic occlusion of the hepatic artery that occurs within 2 months after liver transplantation (Bekker et al., 2009). The incidence of eHAT was found to be significantly higher in children (8.3%) than in adults (2.9%). eHAT presents with liver failure, hepatic necrosis, or bile duct necrosis in up to 58% of affected patients (Tzakis et al., 1985). Uncontrollable sepsis in the immunocompromised recipients and ultimately death are common scenarios after eHAT. Collaterals probably prevent similar ominous outcome in case of late HAT. Cholangiographic findings are characterized by confluent intraductal filling defects within irregular dilated or strictured bile ducts. These findings were reported in more than 80% of patients with hepatic artery thrombosis and were frequently associated with intrahepatic bile leak and biloma formation (Tzakis et al., 1985). In comparison, hepatic artery stenosis has a wide spectrum of presentations. Many patients only present with nonspecific elevation in liver enzyme levels, however abnormal cholangiograms can be present in up to 67% of patients with hepatic artery stenosis even in absence of any evident abnormality by Ultrasonography (Orons et al., 1995a). Early diagnosis is critical to avoid permanent allograft damage. Orons and coworkers found that the treatment of hepatic artery stenosis with balloon angioplasty was of limited benefit once significant allograft dysfunction had occurred (Orons et al., 1995b). The reported risk factors

for eHAT are cytomegalovirus mismatch (seropositive donor liver in seronegative recipient), retransplantation, arterial conduits, prolonged operation time, low recipient weight, variant arterial anatomy, and low volume transplantation centers. However, the exact cause of eHAT remains debatable. Incidence of eHAT was found to be higher in low volume centers, while no difference in incidence of eHAT was found between studies reporting only on living donor liver transplantation versus studies reporting only on deceased donor liver transplantation; also no difference in incidence of eHAT in the living donor liver transplantation (LDLT) subgroup was found in centers using the operation microscope for the arterial anastomosis versus centers using loupe magnification. It has been found that revascularization attempt was performed in approximately half of the cases with a reported success rate of about 50%, therefore, early detection and urgent revascularization are paramount especially in centers that lack a back up system for urgent retransplantation (Bekker et al., 2009).

#### **3.3.4.2 Ischemic type biliary lesions (ITBL) or microangiopathy**

The incidence of ITLB varies between 5% and 15%. The exact pathophysiological mechanism of ITBL is still unclear, however, several risk factors have been identified and strongly suggested a multifactorial origin. Ischemia-reperfusion and preservation injury related variables are well-described risk factors for non-anastomotic strictures including prolonged cold ischemia time (>12 hours) or warm ischemia time (>60 minutes) and variables related to the efficacy of preservation of the peribiliary plexus, such as viscosity and perfusion pressure of the preservation fluid (Guichelaar et al., 2003; Verdonk et al., 2007). Generally speaking, as suggested by Buis et al., risk factors for ITBL can be divided into three categories: ischemia-related injury to the biliary epithelium, immunologically mediated injury, and cytotoxic injury induced by bile salts (Buis et al., 2006).

##### **3.3.4.2.1 Cold ischemic and reperfusion injury**

It has been shown by many studies that prolonged cold ischemia time (CIT) predisposes to ITBL. In an experimental study using cell cultures, it has been shown that biliary epithelial cells are more susceptible to reperfusion/re-oxygenation injury than hepatocytes. Moreover, clinical evidence was provided in a clinical study as reflected by postoperative peaks in serum aspartate aminotransferase and alanine aminotransferase (Buis et al., 2006).

##### **3.3.4.2.2 Preservation injury**

Preservation injury was found to increase the arterial resistance, leading to circulatory disturbances in the small capillaries of the biliary plexus (Buis et al., 2006).

##### **3.3.4.2.3 Warm ischemic injury**

Bile ducts, that are solely dependent on arterial blood supply for their nourishment, are exposed to warm ischemia during initial reperfusion via the portal vein alone. However, favorable effect of simultaneous arterial and portal reperfusion on the incidence of ITBL could not be clearly demonstrated. Moreover, the higher incidence of non-anastomotic strictures in liver transplantation from donors after cardiac death also strongly suggests an ischemia-related factor in its pathogenesis. Several studies have provided evidence for an immunological injury in the pathogenesis of ITBL such as ABO-incompatible liver transplantation and pre-existing diseases with a presumed autoimmune component, such as primary sclerosing cholangitis (PSC), autoimmune hepatitis (AIH), cytomegalovirus (CMV) infection, chronic rejection, and genetic polymorphism of chemokines (Buis et al., 2006).

## 4. Biliary complications in recipient

### 4.1 Biliary leak

Bile leaks are the second most common biliary tract complication in many series (Greif et al., 1994; Rerknimitr et al., 2002a). As we mentioned before, the incidence of anastomotic biliary leakage in right lobe live donor living transplants with bilioenteric anastomosis and that with duct-to-duct reconstruction were 12.4%–18.2% and 4.7%–7.3%, respectively. Remarkably, refractory biliary leakage was found to be associated with significant mortality in bilioenteric reconstruction patients and 12%–19.1% of the patients died from sepsis (Yazumi & Chiba, 2005). However, the incidence of early bile leak appears to be equal in patients with duct-to-duct anastomosis with or without a T-tube (Rabkin et al., 1998; Scatton et al., 2001). Generally, bile leakage could be divided into anastomotic and non-anastomotic in site. Non-anastomotic leaks could occur from the T tube exit site or tract, cystic duct stump, duct of Lushka or damaged accessory bile ducts or from the cut surface of the graft in LDLT (Greif et al., 1994; Rabkin et al., 1998; Thuluvath et al., 2005; Wojcicki et al., 2008). The diagnosis of bile leak was primarily evidenced by extravasation of contrast medium in retrograde endoscopic cholangiogram or bile-stained fluid in percutaneous drainage. Leaks could be categorized as early and late postoperative leaks (Thuluvath et al., 2005). As a general rule, the majority of bile leaks occurs early in the postoperative period and mandates intervention to avoid sepsis (Greif et al., 1994). However, bile leakage could be successfully managed either by endoscopic therapy as a first option, percutaneous transhepatic cholangiography-guided drainage, or surgical reconstruction. Bile leakage remains as a risk factor for subsequent development of anastomotic stricture. Endoscopic management seems to be the treatment of choice in biliary leakage as it offers excellent diagnostic and therapeutic results. It can treat over 90% of biliary tract leaks with minimal morbidity (Greif et al., 1994; Ostroff et al., 1990; Pfau et al., 2000; Thuluvath et al., 2005). By the same notion followed in management of biliary complications, percutaneous transhepatic approach or surgery should be reserved for patients in whom the endoscopic approach failed (Thuluvath et al., 2005).

#### 4.1.1 Early postoperative leaks (within 4 weeks)

Early leaks usually occur from the anastomotic site, and most probably due to technical problems and/or local ischemia (Thuluvath et al., 2005; Wojcicki et al., 2008). These risk factors may include insufficient arterial supply to the biliary anastomosis, active bleeding from cut ends of bile ducts, denuding the bile ducts during harvesting, excessive tension on ductal anastomosis or excessive use of diathermy to control bleeding on the bile ducts (Thuluvath et al., 2005). Therefore, high index of suspicion should be maintained to exclude any hepatic artery thrombosis or any vascular compromise. In one report, cut surface biliary leakage developed in 8.3% patients (Gondolesi et al., 2004), and this may be explained by increased pressure of the intrahepatic bile duct (Pascher & Neuhaus, 2005). Double or triple hepaticojejunostomies were found to be significant risk factor for biliary leakage in patients with bilioenteric anastomosis (Kasahara et al., 2006). Welling et al. showed that warm ischemia was the only independent risk factor for a leakage, however, direct correlation of warm ischemia to biliary strictures did not reach statistical significance in their study (Welling et al., 2008). In presence of T tube, leaks are easily diagnosed with a T tube cholangiogram and can be managed conservatively as leaks frequently is resolved on their own after a short course of unclamping of the T tube (Thuluvath et al., 2005; Wojcicki et al.,



2008). In the absence of a T tube, HIDA scanning or MRCP may be needed to diagnose bile leaks. However, if there is strong clinical suspicion or evidence like bile in drains, retrograde endoscopic stenting of the bile duct is preferable option, since endoscopy is both diagnostic and therapeutic and could identify the site of leaks in over 90% of patients (Pfau et al., 2000; Thuluvath et al., 2005). When leakage is suspected with a T-tube in situ and conservative management failed to control the leak, a 10 Fr biliary stent could be placed and then T tube should be removed. Although some reported success in sealing leaks within 6 weeks of stenting (Pfau et al., 2000), others recommended to leave the tube in place for approximately 2-3 months as healing is delayed probably due to immunosuppressive drug treatment and this approach is supported by the occurrence of bile leaks through the T tube exit site even with 3-4 months of T tube placement (Thuluvath et al., 2005).

Larger leaks, particularly those associated with bilioenteric anastomosis, tend to be less amenable to non-operative treatment. Immediate or early operative revision should be strongly considered as intestinal loop of the anastomosis increase the chance of intraabdominal abscess formation and sepsis. In case of bilioenteric anastomosis without a transanastomotic catheter in place, a bile leak could be diagnosed with ultrasound, computed tomography, magnetic resonance imaging, hepatobiliary scintigraphy and in selected cases with PTC, which was followed by non-surgical management of infection and leakage by systemic antibiotics. Percutaneous transhepatic biliary drainage and/or percutaneous transabdominal biloma and abscess drainage must be fully resolved before surgical reconstruction because regional sepsis and poor infection control can result in recurrent biliary leaks (Thuluvath et al., 2005). Non-surgical conservative treatment involves carrying out a PTC with placement of an internal-external drain that can be sequentially upsized for a total period of 3-6 months of stenting. However, surgical intervention may be required when conservative management fails or as a first line of treatment if there is evidence of HAT, or if the duct-to-duct anastomotic defect is too large. Traditionally, the duct-to-duct anastomosis is converted to a Roux-en-Y choledochojejunostomy which allows wide debridement of necrotic and infected tissue (Thuluvath et al., 2005).

#### **4.1.2 Late postoperative bile leaks**

Late postoperative bile duct leaks are nearly always related to elective or inadvertent removal of the T tube (Thuluvath et al., 2005). The incidence of late bile duct leakage is 7% (Scatton et al., 2001) with a mean time to presentation of 118 days after transplantation despite prolonged T tube placement (Thuluvath et al., 2005). Scatton et al. reported in their large randomized trial that the incidence of biliary fistula in DDLT was found to be 10% in the T-tube group and 2.2% in the group without a T tube (Scatton et al., 2001). Although the classical clinical picture of persistent abdominal discomfort or pain after T tube removal prompts the diagnosis of biliary leakage in most cases, the diagnosis is also suggested in a small subset of patients based on fluctuating cyclosporine levels, pneumoperitoneum or increased leakage through the T tube tract. Leaks resulting from T tubes are managed successfully by endoscopic placement of internal stents with resolution rate near to 100% (Pfau et al., 2000). In management of biliary leakage, several endoscopic strategies have also been described, such as biliary stents, nasobiliary drainage, sphincterotomy, or combination of the techniques. In the two large series, nasobiliary catheters were used successfully to treat post-transplant leaks (Ostroff et al., 1990). Other investigators have noted high closure rates with decompression by endoscopic sphincterotomy alone. It appears that any endoscopic technique significantly reduces or eliminates the pressure gradient between bile

duct and duodenum will seal a biliary fistula (Rerknimitr et al., 2002a). Some reported that majority of patients could be discharged within 48 hours after endoscopic stenting (Thuluvath et al., 2005). Nasobiliary tube has some advantages that it allows cholangiographic follow-up every 3-5 days and is easily removed without the need for another endoscopic intervention. Sherman et al. reported symptomatic relief of patients within 12 hours of nasobiliary stenting, and closure of fistula at a mean of 6.3 days (Sherman et al., 1993). However, inconvenience due to nasal tube, prolonged hospital stay, in addition to alteration of cyclosporine bioavailability due to biliary diversion is considered among the disadvantages of this approach (Thuluvath et al., 2005).

## **4.2 Biliary strictures**

Generally, biliary strictures could be classified into anastomotic strictures (AS) and non-anastomotic strictures (NAS). The former type is more frequent in living donor OLT as compared to recipients of deceased donor OLT (Tsujino et al., 2006; Yazumi et al., 2006). Strictures can present at any time after transplantation. The incidence is greatest in the first 5 to 8 months (range, 1 to 36 months) (Gondolesi et al., 2004; Yazumi & Chiba, 2005; Kasahara et al., 2006). Recently, it has been suggested that prevalence continues to increase with time after transplantation (Verdonk et al., 2006), and that NAS presents earlier than AS, with mean time 3.3-5.9 months (Graziadei et al., 2006; Guichelaar et al., 2003). Moreover, NAS secondary to ischemic causes was shown to present within 1 year of the transplant, whereas the occurrence after 1 year was more often secondary to immunological causes (Verdonk et al., 2007).

### **4.2.1 Diagnosis**

Timely management of biliary complications is paramount to avoid unnecessary diagnostic procedures, improves graft survival, reduces morbidity, mortality and decreases the financial and psychological toll that patients suffer. High index of suspicion must be maintained for early diagnosis, and therefore, it would be desirable to have an easy and non-invasive diagnostic tool for differentiation between different causes of cholestasis. However, the exact diagnosis and localization of post transplant biliary strictures prior to endoscopic cholangiography are unfortunately difficult for the following reasons (Shastri et al., 2007; Zoepf et al., 2005): (1) Pain, a feature of Charcot's triad, may be absent in the transplant setting because of immunosuppression and hepatic denervation; (2) Derangements in biochemical profile may be misleading as it could be due to recurrence of the underlying pretransplant liver illnesses or graft rejection; (3) Clinical symptoms like fever, anorexia are non-specific; (4) Epithelial casts may fill the biliary system rendering it difficult to be visualized by indirect radiological imaging; and (5) Dilatation of the biliary system in allografts may develop slower (Thuluvath et al., 2005; Verdonk et al., 2006; Williams & Draganov, 2009).

#### **4.2.1.1 Value of biochemical and laboratory parameters**

There are diverse results about the value of biochemical parameters either in prediction or follow up of biliary complications. Some reported that they are not reliable enough (Thuluvath et al., 2005) or just could provide a hint to detect biliary complications post transplantation (Zoepf et al., 2005). While others concluded that Gamma glutamyl transferase (GGT) and serum alkaline phosphatase (AP) (Shastri et al., 2007), but not serum bilirubin, to be early, non-invasive and inexpensive diagnostic markers. Moreover, they

could be of great help during follow up and to correlate with adequacy of endoscopic therapy in patients presenting with early onset biliary complications after transplantation. However, others found that elevated serum bilirubin level  $>1.5$  mg/dL is highly sensitive tool with negative predictive value of 100% and its decline is well correlated with clinical and radiographic improvement (Venu et al., 2007).

#### **4.2.1.2 Value of radiological modalities in diagnosis of biliary strictures**

Ultrasonography (US) with Doppler examination of hepatic vessels is usually the first imaging modality of choice when a biliary complication is suspected, followed by biliary imaging and may be biopsy depending on the pattern of liver test abnormalities. However, in post-transplant patients, the interpretation of histological findings due to ischemia, recurrence of liver disease or rejection can sometimes be misleading. Retrograde endoscopic cholangiography (ERC) can directly show the patency of biliary tree or the stenosis of biliary tree and show the site of stenosis/stricture. Definitely, ERC is the better diagnostic option than other modalities. Hepatic angiography may be indicated if hepatic vascular abnormality was suspected (Thuluvath et al., 2005). US may have low sensitivity (close to 50%) to detect biliary dilatation in patients who received transplantation (Graziadei et al., 2006; Zoepf et al., 2005) and not accurate enough to diagnose or localize biliary strictures either because the true diameter of cast filled bile ducts could not be properly determined, acute obstruction may not result in a prompt dilatation of the prestenotic bile ducts (Zoepf et al., 2005) or because dilatation of the biliary system in allografts may develop slower (Shastri et al., 2007). Different studies reported variable results for helical computed tomography and magnetic resonance imaging. However, exact data were not available, questionable or not applicable due to low accuracy in localizing stricture site (Zoepf et al., 2005). While Scintigraphy of the hepatobiliary tract is rarely performed when biliary stricture is suspected but still remains an excellent test to detect biliary leaks. Magnetic resonance cholangiography (MRC) was shown to have a sensitivity of 95%, a positive predictive value of 98% and an overall accuracy of 95% compared to ERCP as the reference standard (Valls et al., 2005). Due to the progressive advancement in its computation modes, it is suggested that MRC becomes the most promising future diagnostic tool before referral to endoscopic intervention. Recently, a hepatocyte-specific contrast agent gadolinium ethoxybenzyl diethylenetriamine pentaacetic acid (Gd-EOB-DTPA)-enhanced MR cholangiography has been utilized in evaluation of biliary anatomy, differentiation of biliary from extrabiliary lesions, assessment of bile duct obstruction, detection of bile duct injury including leakage and stricture, evaluation of biliary-enteric anastomoses, post-procedure evaluation, differentiation of biloma from other pathologic conditions, and evaluation of sphincter of Oddi dysfunction, and was found to be effective. However, the clinical applications of this imaging technique have not yet been fully explored. Moreover, the chief disadvantage of MRC in general, beyond lack of availability, is the lack of its therapeutic ability (Williams & Draganov, 2009). Currently, cumulative results confirm that none of the indirect imaging modalities could replace direct cholangiography for diagnosis of post transplantation biliary strictures (Pascher & Neuhaus, 2006; Pfau et al., 2000; Rerknimitr et al., 2002; Thuluvath et al., 2005; Zoepf et al., 2005).

#### **4.2.2 Anastomotic strictures (AS)**

Incidence of anastomotic strictures reported is around 5%-10% of transplanted patients. AS is usually isolated, short in length, and resulted from fibrotic changes within the first year

after transplantation (Greif et al., 1994; Verdonk et al., 2006). Surgical technical issues seem to be the most important etiological factors in the early post transplant period, and may include improper techniques, small diameter of the bile ducts, size mismatch between the donor and recipient bile ducts, tension at the anastomosis, excessive use of electrocauterization for control of bile duct bleeding, infection and bile leakage which has been found to be an independent risk factor for AS (Lee et al., 2008; Welling et al. 2008). Later onset anastomotic stricture is most likely to indicate fibrotic changes due to ischemia either of donor or recipient bile duct (Verdonk et al., 2007; Pascher & Neuhaus, 2006).

#### **4.2.2.1 Management of AS**

The trend in management of AS has changed over the past 20 years from predominantly surgical to primarily endoscopic, namely endoscopic regtrograde cholangiography (ERC). ERC is considered as the gold standard, most physiological, least invasive diagnostic and therapeutic interventional option that carries good long term results in terms of graft and patient survival. ERC has an overall success rate in the range of 70%-100% in deceased donor liver transplantation (DDLT) (Graziadei et al., 2006; Morelli et al., 2003; Thuluvath et al., 2005; Williams & Draganov, 2009) and 60-75% in living donor liver transplantation (LDLT) (Hisatsune et al., 2003; Tsujino et al., 2006; Yazumi & Chiba, 2006). Percutaneous transhepatic cholangiography (PTC), although it has high success rate (50%-75%), is most often spared as a second line option for patients with Roux-en-Y bilioenteric reconstruction or failed ERC; and this is because the possible associated morbidities of PTC like hemorrhage and bile leak ((Sharma et al., 2008; Williams & Draganov, 2009). In high volume centers with experienced endoscopists, newer approaches of ERC have been described using the variable stiffness pediatric colonoscope, double balloon enteroscope, single balloon enteroscope, and spiral overtube. Moreover, both techniques could be combined by “rendezvous” endoscopy when endoscopic access to the anastomotic stricture can not be obtained. It is worth to mention that using ERCP or PTC is not only dependent on the type of biliary reconstruction, but also on the possibility of therapeutic intervention and the available expertise (Williams & Draganov, 2009). Therapeutic ERCP whether is successful or ultimately unsuccessful and necessitating surgical intervention does not negatively affect survival. Therefore, in the majority of patients with biliary complications, a trial of endoscopic therapy should be performed to delay or defer a post-OLT surgical procedure (Pfau et al., 2000). Surgical revision is now only reserved for patients who have failed the endoscopic and transhepatic percutaneous measures. Surgical revision in the form of Roux-en-Y bilio-enteric reconstruction is usually the operation of choice in patients with duct-to-duct anastomosis. In those who already have a Roux-en-Y bilioenteric anastomosis, repositioning the graft bile duct to a better vascularized area may be required (Verdonk et al., 2007), while retransplantation could be the last resort when all else fail (Graziadei et al., 2006; Williams & Draganov, 2009).

#### **4.2.2.2 Deceased donor liver transplantation (DDLT)**

Factors found to be associated with poor outcome and/or higher recurrence following endoscopic treatment or stent removal include delayed initial presentation (more than 6 months after transplantation), presence of tight strictures (Alazmi et al., 2006; Verdonk et al., 2007), presence of bile leaks, and use of T tubes (Sharma et al., 2008; Alazmi et al., 2006). The conventional method of endoscopic treatment comprises of stricture localization followed by guidewire cannulation, balloon dilatation, and subsequent placement of plastic stents. It has been reported that success rate of balloon dilation is approximately 40% (Shwartz et al.,



2000); however, additional stent placement seems to have more successful and durable outcomes in 75% of patients (Shwartz et al., 2000; Zoepf et al., 2005). Dual or multiple stents placed side by side further improves outcomes in up to 80-90% of patients (Morelli et al., 2003; Graziadei et al., 2006). The stents are generally replaced by larger stents every 3 months (Shwartz et al., 2000; Morelli et al., 2003) to prevent the complication of clogging, cholangitis, or stone formation (Sharma et al., 2008). The majority of patients with anastomotic strictures will require several endoscopic interventions every 3 months with a mean of 3 to 5 sessions, using balloon dilation of 6-10 mm and multiple stents of 7 Fr to 10 Fr repeated for 12-24 months (Morelli et al., 2003; Thuluvath et al., 2005). The long-term success rates were in the range of 70%-100% (Alazmi et al., 2006; Morelli et al., 2003; Rerknimitr et al., 2002; Verdonk et al., 2006). A small group of patients, with transient anastomotic narrowing during the first 1-2 month post transplant, presumably due to postoperative edema, may respond with a single session of endoscopic balloon dilatation and plastic stent placement with no need for further intervention (Verdonk et al., 2006). An "aggressive approach" has been advocated by Pasha et al., which they defined as combination of maximal dilation and placement of maximum number of stents. Temporary placement of covered self-expanding metal stents has been tried to reduce the need for repeated stent exchanges, however, the data are limited (Williams & Draganov, 2009). Another protocol proposed an accelerated dilation every 2 weeks and a shortened stenting period of an average of 3.6 months. The results were encouraging with a high success rate 87%. Generally, it seems that shorter intervals in between treatments may ultimately reduce the time needed for successful long term outcomes (Williams & Draganov, 2009).

Significantly, more recurrences were seen in the patients who developed AS after more than 6 months after orthotopic liver transplantation compared to those with AS in the first 6 months (Verdonk et al., 2006). Recurrence rate of post-anastomotic biliary strictures was reported by Alzami et al. to be relatively small (18%) over a follow-up period of almost 3 years (Alazmi et al., 2006), while others reported to be around 10%-13% (Morelli et al., 2003). They concluded that recurrence could be effectively diagnosed and treated by endoscopic approach requiring between one and four additional sessions. However, they did not identify any clinical or endoscopic parameters that predicted recurrence of anastomotic biliary strictures in post-OLT patients.

#### **4.2.2.3 Living donor liver transplantation**

However, the results of endoscopic intervention for biliary strictures in DDLT is excellent, but cannot be extrapolated to right-lobe LDLT. Inability to cannulate the stricture (Yazumi & Chiba, 2006; Tashiro et al., 2007) and difficulty to place a stent (Tsujino et al., 2006) were found to be the most common reasons for the failure of endoscopic treatment in this group of patients. The difference in outcome might be explained by the presence of multiple ductal anastomosis, smaller size, peripheral location, and increased risk of devascularization (Sharma et al., 2008). However, as in DDLT, the combination of balloon dilatation and stenting was superior to either modality alone (Tashiro et al., 2007). Kyoto group classified the strictures in living donor liver transplants into four types: unbranched, fork-shaped, trident-shaped, and multibranched (Hisatsune et al., 2003). Moreover, they were the first to describe the "crane neck deformity", in which the biliary anastomosis was located at a point that was far below the highest portion of the recipient duct. This event was probably related to compensatory hypertrophy of the graft that resulted in sharp angulation of the bile duct rendering it extremely difficult to be managed endoscopically (Yazumi & Chiba, 2006). Generally, it is



recommended to start with endoscopic therapy as the first approach while percutaneous therapy should be spared for rescue therapy for following reasons (Chang et al., 2010). First, although the rates of successful interventions and patency do not differ for percutaneous or endoscopic therapy, the numbers of necessary interventions are higher for percutaneous therapy; second, the inconvenience of the percutaneous drain catheter cannot be ignored which significantly affects quality of life of those patients. Lastly but not the least, percutaneous drain related complications, such as leakage, pain, infection, and accidental removal of the drain are not uncommon. Other reported complications of percutaneous approach include portal vein injury, hepatic artery injury, and death (Yazumi & Chiba, 2005). In other studies, PTBD resulted in hemobilia, cholangitis, and a hemothorax (Schwartz et al., 2000). The patients in whom the endoscopic treatment is unsuccessful are rescued with a percutaneous transhepatic biliary drainage. The procedure could be summarized as follows: under fluoroscopic guidance, the right intrahepatic duct is punctured with a 21G Chiba needle and then few ml of bile is aspirated. After insertion of 0.018-inch hairwire, a yellow sheath followed by a 0.035-inch guide wire is introduced. After confirmation of anastomotic stricture, dilatation of biliary stricture with balloon catheters is performed. An 8 F pigtail catheter is inserted over the wire with its tip placed within the common bile duct or duodenum, and tubogram is then obtained. The catheter is anchored to the skin with anchoring device (Chang et al., 2010). If primary or rescue percutaneous approach is successfully performed, subsequent insertion of endoscopic retrograde biliary stents is recommended. Consequently, percutaneous drain catheter could be removed earlier and its related complications can be reduced. If the insertion of stents is expected to be difficult because of sharp or twisted angle of the anastomosis or for other reasons, endoscopic approach can be successfully performed with the "rendezvous" method, which could be generally described as, insertion of 0.035-inch or (0.025-inch) guidewire through the catheter into the intrahepatic bile duct proximal to the site of biliary stricture; then dilatation using a bougienation catheter (7 F-11.5 F), a stent retriever (7 F-11.5 F) or a balloon catheter (6 or 8 mm in diameter) according to the indications. After stricture dilatation and minor sphincterotomy, stents as many and as big as possible, are endoscopically placed. The proximal side of the stent is located sufficiently over the stricture and the distal side of the stent is passed 1-2 cm outside the major papilla (Chang et al., 2010). Sphincterotomy is usually required during endoscopic stenting to avoid acute pancreatitis as a result of compression of pancreatic duct orifice by the duodenal end of stents. However, this procedure could be associated with cholangitis. Other theoretically possible long term complications in patients who underwent endoscopic sphincterotomy for choledocholithiasis unrelated to transplantation might be reported in transplant patients. When longer term results are more available in the future, these complications include recurrent stones (12.3%), biliary carcinoma (2.0%), and liver abscess (1.2%) (Tanaka et al., 1998). There was a successful trial by Koyoto group (Hisatsune et al., 2003; Yazumi et al., 2006) with endoscopic stenting of biliary strictures without sphincterotomy. Placing the inside stent above the papilla of Vater apparently has two clinical benefits. First, the inside stents are not directly exposed to digested food and this may reduce the possibility of being occluded. The average patency of the inside stent was found to be 450 days, exceeding the median patency of the conventional endoscopic biliary stent (about 3 months); Secondly, more stents could be placed because the orifice of the pancreatic duct is not compressed by the distal ends of these stents. Magnetic compression anastomosis (MCA) is revolutionary method of performing choledochocholedochostomy in patients with biliary obstruction after LDLT (Itoi et al., 2010). Endoscopically, a samarium-cobalt (Sm-Co) rare-earth magnet is placed at the superior site of obstruction via the

percutaneous transhepatic biliary drainage route, and another Sm-Co magnet is also placed at the inferior site of obstruction with the aid of an endoscope.

#### **4.2.3 Non anastomotic strictures (NAS)**

NAS after liver transplantation is not just single disease but rather an array of biliary abnormalities with different pathogenesis and variations in anatomical localization and severity, ranging from slight, localized mucosal irregularity to extensive and diffuse biliary strictures (Verdonk et al., 2007). Non-anastomotic strictures account for 10%-25% of all stricture complications after OLT with an incidence of 1%-19%. These strictures are often multiple, longer, proximal to the anastomosis in the extra- or intra-hepatic bile ducts and occur earlier than anastomotic strictures with a mean time to stricture development of 3-6 months (Graziadei et al., 2006; Guichelaar et al., 2003; Williams & Draganov, 2009). Verdonk et al. reported that more than 50% of the cases presented within the first year post transplantation. However, long-term follow-up revealed gradual increase in incidence up to 12 years after transplantation, resulting in steep initial rise of the cumulative incidence curve of NAS during the first year after OLT and followed by a smaller increment beyond the first year. The cumulative incidence was 14%, 15%, and 16% at 3, 5, and 10 years after OLT, respectively (Verdonk et al., 2007). As we discussed before, the risk factors could be broadly classified as macroangiopathic due to hepatic artery thrombosis (HAT) or microangiopathic which also known as ischemic type biliary lesions (ITBL). ITBL could be divided into three categories: ischemia-related injury to the biliary epithelium; immunologically mediated injury; and cytotoxic injury induced by bile salts. Groningen team reported that ischemia-related injury represented around 80% of NAS cases. Non-anastomotic strictures secondary to ischemic causes presented within 1 year of transplant and found around the bifurcation and the common bile duct had severer course and higher risk of progression. Whereas, the occurrence of NAS after 1 year was more often related to immunological causes as the risk factors identified more frequently in the periphery of the liver and represented around 20% of NAS cases. Groningen team also showed that cold and warm ischemia times were significantly longer for the group with early NAS compared to the group with late NAS. Anastomotic bile leak which is generally associated with local bile duct ischemia is observed in the group with early NAS. Moreover, higher incidence of NAS in liver transplantation from donors after cardiac death (non-heart-beating donors) also strongly suggests an ischemia-related factor in the pathogenesis of NAS. The critical relevance of arterial blood supply for the viability of the larger and extrahepatic bile ducts is well described. This part of the biliary tree in the graft becomes entirely dependent on arterial blood from the hepatic artery, making them more prone to hypoperfusion and ischemia. This may explain the central localization of NAS presenting early after transplantation (Buis et al., 2007; Verdonk et al., 2007). They also analyzed the risk factors in relation to the outcome and concluded that patients with following criteria: hepaticojejunostomy as biliary reconstruction and early diagnosis of NAS, NAS presenting at the level of the peripheral branches of the biliary tree were at risk for the development of recurrent cholangitis, radiological progression, development of cirrhosis, and eventually retransplantation (Verdonk et al., 2007).

##### **4.2.3.1 Management of NAS**

NAS secondary to early HAT usually requires urgent revascularization or retransplantation, whereas NAS due to late HAT or any other etiological risk factor could be salvaged by endoscopic means (Sharma et al., 2008). Compared to AS, non-anastomotic

strictures are more difficult to treat with more complications and less favorable overall outcomes including increased graft loss and death (Williams & Draganov, 2009). It is reported that only 50%-75% of DDLT patients had a long term response to endoscopic therapy and the median time of response was 185 days; on the other hand, long term response in patients with anastomotic strictures was 70%-100% and the median time of response was 67 days (Graziadei et al., 2006; Pfau et al., 2000; Rerknimitr et al., 2002; Thuluvath et al., 2005). The results of endoscopic approaches in the context of NAS in LDLT are even more disappointing, as the average success rate varies from 25% to 33% (Todo et al., 2005; Tsujino et al., 2006; Yazumi et al., 2006), which is way below the success rate seen with NAS in DDLT. Non-anastomotic strictures required an increased number of interventions, and also did not result in significant long term improvement (Graziadei et al., 2006) as it is complicated by the development of repeated episodes of cholangitis, biliary cirrhosis, atrophy of the involved lobe and graft failure (Sharma et al., 2008). It did not appear that the poor response of non-anastomotic treatment varied with etiology (Guichelaar et al., 2003). In patients with changes located primarily in the extrahepatic bile duct and the duct bifurcation, complex surgical reconstruction with resection of the bifurcation and Roux-en-Y hepaticojejunostomy could be an option. Ultimately, up to 30-50% of the patients with NAS either required retransplantation or died as a consequence of these complications despite endoscopic or percutaneous therapy (Graziadei et al., 2006; Guichelaar et al., 2003; Pascher & Neuhaus, 2006; Shah et al., 2007; Thuluvath et al., 2005). Generally, endoscopic therapy of NAS is challenging and comprises of extraction of the biliary sludge and casts, balloon dilation of all accessible strictures and placement of plastic stents which are replaced every 3 months. However, dilatation of all strictures is not possible due to their multifocal distribution, involvement of the smaller and peripheral intrahepatic ducts, and rapid stent occlusion by biliary sludge and casts (Williams & Draganov, 2009). Although endoscopic therapy is considered as first line in management of non-anastomotic strictures and may occasionally be a definite solution in selected patients, it requires lifelong surveillance since strictures are likely to recur, and more importantly, it seems to play a prominent role as a bridge to liver retransplantation. A stricture that is too tight precluding successful cannulation of biliary system by the guidewire is the commonest cause of endoscopic failure in management of biliary strictures after LDLT (Tashiro et al., 2007; Verdonk et al., 2007). However, once a stricture is cannulated, the reported success for this procedure is about 80%-90%, which highlights the importance of cannulation of the stricture as a critical event in predicting the success or failure of the endoscopic treatment. Sharma et al. used the Spyglass direct visualization system as the guidance system for the passage of the guidewire through very tight strictures in this subset of patients where conventional ERCP failed. However, definitive answers on the best treatment modality for NAS should come from multicenter, prospective, randomized studies (Sharma et al., 2008).

#### **4.3 Other indications of endoscopy in recipients**

##### **4.3.1 Sphincter of Oddi Dysfunction (SOD)**

Also termed ampullary dysfunction occurs in from 0-7% of liver transplant recipients with duct to duct anastomosis. Its pathophysiology in the post-transplant setting is poorly understood (Thuluvath et al., 2005), but it is probably related to denervation of the ampullary region of the native duct, resulting in abnormal ampullary relaxation and

increased intraductal biliary pressure (Clavien et al., 1995). However, distal bile duct obstruction in the post transplant setting might be due to a combination of SOD, edema, or inflammatory stricturing due to long term stenting with a T tube or internal stent when the distal end protrudes into the sphincter. CMV and other opportunistic infections may also play a pathological role in post-transplant sphincter of Oddi dysfunction (Thuluvath et al., 2005). It is usually suspected clinically by persistently elevated liver enzymes in an obstructive/cholestatic pattern, dilation of the native duct to a diameter greater than 10 mm (Pfau et al., 2000), improvements in liver tests with T tube unclamping, delayed drainage of contrast (> 15 min) in a cholangiography that fails to show any evident cause of obstruction (Greif et al., 1994). Hepatobiliary scintigraphy and sphincter or T tube manometry could also be diagnostic (Thuluvath et al., 2005). Endoscopic sphincterotomy and/or biliary stenting is usually a successful treatment. Some reported 100% response to sphincterotomy without stenting (Pfau et al., 2000; Thuluvath et al., 2005; Wojcicki et al., 2008). Therefore, manometric studies, although diagnostic, are not performed in most cases because evidence to support this approach has been largely anecdotal and remains controversial (Pfau et al., 2000). A study reported that conversion to a hepaticojejunostomy may occasionally be required to resolve the dysfunction (Greif et al., 1994).

#### 4.3.2 Biliary stones

The incidence of biliary stones after liver transplantation is quite variable in different reports. For instance, Riknimitir et al. reported the occurrence of biliary stones in 38% of their patients (Riknimitir et al., 2002), while others reported an incidence of 4-18% of post liver transplant patients (de la Mora-Levy & Baron, 2005). The exact etiology is unclear, however, this could be explained theoretically by increased lithogenicity of the bile or as a result of cyclosporine inhibitory effect on bile acid production and bile flow. However, post transplant calculi formation is most likely the result of mechanical obstruction mainly strictures (de la Mora-Levy & Baron, 2005; Thuluvath et al., 2005), biliary tract infection, biliary reflux and biliary mucosal inflammation. The stones or debris can be removed successfully after sphincterotomy in almost all cases, and patients with strictures require dilation of the strictures before stone removal (de la Mora-Levy & Baron, 2005; Pfau et al., 2000; Thuluvath et al., 2005).

#### 4.3.3 Biliary cast syndrome

Biliary cast syndrome is an ill-defined entity that includes a number of pathophysiologies that share similar cholangiographic findings. Biliary casts, rare in nontransplant patients, are associated with morbidity, graft failure, need for retransplantation, and mortality. Biliary cast syndrome describes the cholangiographic findings of multiple fixed filling defects in the intrahepatic or extrahepatic biliary tree that conform to the luminal dimensions of the segment of bile duct. Cast material may be hard or soft, may adhere to the bile duct wall, and may have a "staghorn" configuration. Theories as to the etiology include sloughed biliary epithelium due to prolonged cold storage time or transient or ongoing ischemia, chronic rejection, infection, bile stasis, and alteration of the bile milieu (Pfau et al., 2000); and are often accompanied by strictures including diffuse stricturing of the hilum. Evidence suggests that endoscopic therapy will fail to treat multiple biliary casts and many patients may be better managed with the percutaneous approach. Ursodeoxycholic acid might delay new formation of sludge and stones. Although enough data are not available, most patients may require retransplantation (Pfau et al., 2000; Thuluvath et al., 2005).



#### 4.3.4 Mucocoele

It is a very rare complication after liver transplantation. It can develop when the outflow end of the blind donor cystic duct remnant is incorporated into the suture line of a biliary anastomosis (Koneru et al., 1989). This creates the blind mucosa-lined sac which can later on become distended by accumulated mucus and leads to bile duct obstruction by extrinsic compression (Osroff et al., 1990; Wojcicki et al., 2008). Computed tomography and ultrasonography will reveal the mucocoele as a fluid collection in the porta hepatis and should be differentiated from other conditions, including hepatic artery pseudoaneurysm, biloma, loculated ascites, abscess, liquefied hematoma, tumor, adenopathy, and a fluid filled Roux-en-Y loop of jejunum. Surgical excision or drainage of the cystic duct remnant by enteric anastomosis is curative (Koneru et al., 1989; Thuluvath et al., 2005).

#### 4.3.5 Posttransplant lymphoproliferative disease and opportunistic infection

Posttransplant lymphoproliferative disease is generally associated with over-immunosuppression in the setting of Epstein-Barr virus infection and may respond to lowering of immunosuppression and antiviral therapy. Bile duct obstruction may occur at the hilum and can be relieved with temporary endoscopic biliary stent placement. However, if the disease progresses to lymphoma, long-term biliary stent placement may be necessary (de la Mora-Levy & Baron, 2005). Chronic CMV infection can cause chronic cholangitis and lead to multiple strictures mimicking PSC.

#### 4.3.6 Recurrence of the primary sclerosing cholangitis

Primary sclerosing cholangitis recurs after OLT in 5–20% of patients, and the risk seems to be increased in males and in recipients who have not undergone colectomy before transplantation. The recurrence may be difficult to distinguish from ischemic-type biliary lesions (Wojcicki et al., 2008). The diagnosis is usually based on preoperative diagnosis of primary sclerosing cholangitis. Cholangiographic findings include non-anastomotic biliary strictures of the intrahepatic and/or extrahepatic biliary tree with beading and irregularity occurring more than 90 days after transplantation (Graziadei et al., 2006; Wojcicki et al., 2008). Differential diagnosis includes wide spectrum of factors such as hepatic artery thrombosis or stenosis and ischemic-type biliary lesions of other etiology. However, it seems that patient and graft survival are not negatively affected in the intermediate term of follow-up. An increased incidence of biliary strictures and reduced graft and patient survival are observed in patients with duct-to-duct anastomosis, as compared to those undergoing hepaticojejunostomy reconstructions. Therefore, Roux loop has been preferentially performed aiming at reducing the risk of disease recurrence. However, some authors reported that duct-to-duct anastomosis in these patients could be performed if the disease was not involving the distal duct, and the results in terms of the rates of biliary complications and patient and graft survival were comparable (Wojcicki et al., 2008).

### 5. Biliary complications in donor

The incidence of biliary complications in donors tends to be about 5% based on recent publications. Bile leakage and biliary strictures are the most common biliary complications. Most bile leakages occurred from cut surfaces, and others may originate from biliary radicles draining the caudate lobe (Yuan & Gotoh, 2010). When strictures develop, they tend to occur at the hilum. The same endoscopic treatments previously described are used.



Specifically for the cut surface of the liver, endoscopic biliary drainage could be successfully used as demonstrated in patients undergoing liver resection for other causes (Hasegawa et al., 2003).

## 6. Conclusion

ERCP has become an established procedure in the management of post-transplantation biliary complications both in recipients and donors with a comprehensive body of literature published for more than 20 years to support its use. In addition to the formentioned indications, it also has diagnostic and/ therapeutic role in management of hemobilia, necrosis of the bile duct, bile duct redundancy/kinking, and retained surgical stents. In general, therapeutic ERC, whether successful or ultimately unsuccessful and necessitating surgical intervention, does not negatively affect survival. Therefore, in the majority of patients with biliary complications, a trial of endoscopic therapy should be performed to delay or defer a post-OLT surgical procedure.

## 7. References

- Alazmi, W. M., E. L. Fogel, Watkins, J.L, McHenry, L., Tector, J.A., Fridell, J., Mosler, P., Sherman, S. & Lehman, G.A. (2006). "Recurrence rate of anastomotic biliary strictures in patients who have had previous successful endoscopic therapy for anastomotic narrowing after orthotopic liver transplantation." *Endoscopy* 38(6): 571-574, ISSN 0013-726X.
- Bekker, J., Ploem, S. & de Jong, K.P. (2009). "Early hepatic artery thrombosis after liver transplantation: a systematic review of the incidence, outcome and risk factors." *Am J Transplant* 9(4): 746-757, ISSN 1600-6143.
- Buis, C. I., Hoekstra, H., Verdonk, R.C., & Porte, R.J. (2006). "Causes and consequences of ischemic-type biliary lesions after liver transplantation." *J Hepatobiliary Pancreat Surg* 13(6): 517-524, ISSN 0944-1166 .
- Buis, C. I., Verdonk, R.C., Van der Jagt, E.J, Van der Hilst, C.S., Sloof, M.J., Haagsma, E.B. & Porte, R.J. (2007). "Nonanastomotic biliary strictures after liver transplantation, part 1: Radiological features and risk factors for early vs. late presentation." *Liver Transpl* 13(5): 708-718.
- Chang, J. H., Lee, I.S., Choi, J.Y., Yoon, S.K., Kim, D.G., You, Y.K., Chun, H.J., Lee, D.K., Choi, M.G & Chung, I.S. (2010). "Biliary Stricture after Adult Right-Lobe Living-Donor Liver Transplantation with Duct-to-Duct Anastomosis: Long-Term Outcome and Its Related Factors after Endoscopic Treatment." *Gut Liver* 4(2): 226-233, ISSN 1976-2283 .
- Clavien, P. A., Camargo, C.A., Jr., Baillie, J. & Fitz, J.G. (1995). "Sphincter of Oddi dysfunction after liver transplantation." *Dig Dis Sci* 40(1): 73-74, ISSN 0163-2116.
- Colonna, J. O., 2nd, Shaked, A., Gomes, A.S., Coloquhoun, S.D., Jurim, O., McDiarmid, S.V., Millis, J.M., Goldstein, L.I., & Busuttil, R.W. (1992). "Biliary strictures complicating liver transplantation. Incidence, pathogenesis, management, and outcome." *Ann Surg* 216(3): 344-350; discussion 350-342, ISSN 0003-4932 .
- de la Mora-Levy, J. G. & Baron, T.H. (2005). "Endoscopic management of the liver transplant patient." *Liver Transpl* 11(9): 1007-1021, ISSN 1527-6465 .

- Duailibi, D. F. & Ribeiro, M.A., Jr. (2010). "Biliary complications following deceased and living donor liver transplantation: a review." *Transplant Proc* 42(2): 517-520, ISSN 0041-1345.
- Gondolesi, G. E., Varotti, G., Florman, S.S., Munoz, L., Fishbein, T.M., Erme, S.H., Schwartz, M.E. & Miller, C. (2004). "Biliary complications in 96 consecutive right lobe living donor transplant recipients." *Transplantation* 77(12): 1842-1848, ISSN 0041-1337.
- Graziadei, I. W., Schwaighofer, H., Kock, R., Nachbaur, K., Koenigsrainer, A., Margreiter, R. & Vogel, W. (2006). "Long-term outcome of endoscopic treatment of biliary strictures after liver transplantation." *Liver Transpl* 12(5): 718-725 ISSN 1527-6465.
- Graziadei, I. W., Wiesner, R. H., Batts, K.P., Marotta, P.J., LaRusso, N.F., Parayko, M.K., Hay, J. E., Gores, G. J., Charlton, M. R., Ludwig, J., Poterucha, J. J., Steers, J. L., & Krom, R. A. (1999). "Recurrence of primary sclerosing cholangitis following liver transplantation." *Hepatology* 29(4): 1050-1056, ISSN 0270-9139.
- Greif, F., O. L. Bronsther, et al. (1994). "The incidence, timing, and management of biliary tract complications after orthotopic liver transplantation." *Ann Surg* 219(1): 40-45.
- Guichelaar, M. M., Benson, J. T., Malinchoc, M., Krom, R. A., Wiesner, R. H. & Charlton, M. R. (2003). "Risk factors for and clinical course of non-anastomotic biliary strictures after liver transplantation." *Am J Transplant* 3(7): 885-890, ISSN 1600-6135.
- Hasegawa, K., Yazumi, S., Egawa, H., Tamaki, H., Asada, M., Kodama, Y., Hisatsune, H., Okazaki, K., Tanaka, K. & Chiba, T. (2003). "Endoscopic management of postoperative biliary complications in donors for living donor liver transplantation." *Clin Gastroenterol Hepatol* 1(3): 183-188, ISSN 1542-3565.
- Hisatsune, H., Yazumi, S., Egawa, H., Asada, M., Hasegawa, K., Kodama, Y., Okazaki, K., Itoh, K., Takakuwa, H., Tanaka, K. & Chiba, T. (2003). "Endoscopic management of biliary strictures after duct-to-duct biliary reconstruction in right-lobe living-donor liver transplantation." *Transplantation* 76(5): 810-815 ISSN 0041-1337.
- Itoi, T., Yamanouchi, E., Ikeuchi, N., Kasuya, K., Iwamoto, H. & Tsuchida, A. (2010). "Magnetic Compression Duct-to-duct Anastomosis for Biliary Obstruction in a Patient with Living Donor Liver Transplantation." *Gut Liver* 4 Suppl 1: S96-98, ISSN 1976-2283.
- Kasahara, M., Egawa, H., Takada, Y., Oike, F., Sakamoto, S., Kiuchi, T., Yazumi, S., Shibata, T. & Tanaka, K. (2006). "Biliary reconstruction in right lobe living-donor liver transplantation: Comparison of different techniques in 321 recipients." *Ann Surg* 243(4): 559-566, ISSN 0003-4932.
- Koneru, B., Zajko, A. B., Sher, L., Marsh, J. W., Tzakis, A. G., Iwatsuki, S. & Starzl, T. E. (1989). "Obstructing mucocele of the cystic duct after transplantation of the liver." *Surg Gynecol Obstet* 168(5): 394-396, ISSN 0039-6087.
- Lee, C. S., Liu, N. J., Lee, C. F., Chou, H. S., Wu, T. J., Pan, K. T., Chu, S. Y. & Lee, W. C. (2008). "Endoscopic management of biliary complications after adult right-lobe living donor liver transplantation without initial biliary decompression." *Transplant Proc* 40(8): 2542-2545, ISSN 0041-1345.
- Lin, T. S., Concejero, A. M., Chen, C. L., Chiang, Y. C., Wang, C. C., Wang, S. H., Liu, Y. W., Yang, C. H., Yong, C. C., Jawan, B. & Cheng, Y. F. (2009). "Routine microsurgical biliary reconstruction decreases early anastomotic complications in living donor liver transplantation." *Liver Transpl* 15(12): 1766-1775, ISSN 1527-6465.

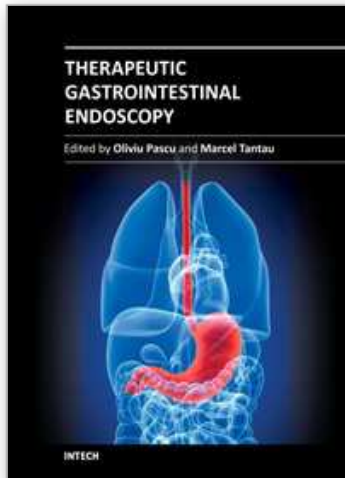
- Morelli, J., Mulcahy, H. E., Willner, I. R., Cunningham, J. T. & Draganov, P. (2003). "Long-term outcomes for patients with post-liver transplant anastomotic biliary strictures treated by endoscopic stent placement." *Gastrointest Endosc* 58(3): 374-379, ISSN 0016-5107.
- Moser, M. A. & Wall, W. J. (2001). "Management of biliary problems after liver transplantation." *Liver Transpl* 7(11 Suppl 1): S46-52, ISSN 1527-6465.
- Orons, P. D., Sheng, R. & Zajko, A. B. (1995a). "Hepatic artery stenosis in liver transplant recipients: prevalence and cholangiographic appearance of associated biliary complications." *AJR Am J Roentgenol* 165(5): 1145-1149, ISSN 0361-803X.
- Orons, P. D., Zajko, A. B., Bron, K. M., Trecha, G. T., Selby, R. R. & Fung, J. J. (1995b). "Hepatic artery angioplasty after liver transplantation: experience in 21 allografts." *J Vasc Interv Radiol* 6(4): 523-529, ISSN 1051-0443 .
- Ostroff, J. W., Roberts, J. P., Gordon, R. L., Ring, E. J. & Ascher, N. L. (1990). "The management of T tube leaks in orthotopic liver transplant recipients with endoscopically placed nasobiliary catheters." *Transplantation* 49(5): 922-924, ISSN 0041-1337.
- Pascher, A. & Neuhaus, P. (2005). "Bile duct complications after liver transplantation." *Transpl Int* 18(6): 627-642, ISSN 0934-0874 .
- Pascher, A. & Neuhaus, P. (2006). "Biliary complications after deceased-donor orthotopic liver transplantation." *J Hepatobiliary Pancreat Surg* 13(6): 487-496, ISSN 0944-1166.
- Pasha, S. F., Harrison, M. E., Das, A., Nguyen, C. C., Vargas, H. E., Balan, V., Byrne, T. J., Douglas, D. D. & Mulligan, D. C. (2007). "Endoscopic treatment of anastomotic biliary strictures after deceased donor liver transplantation: outcomes after maximal stent therapy." *Gastrointest Endosc* 66(1): 44-51, ISSN 0016-5107 .
- Pfau, P. R., Kochman, M. L., Lewis, J. D., Long, W. B., Lucey, M. R., Olthoff, K., Shaked, A. & Ginsberg, G. G. (2000). "Endoscopic management of postoperative biliary complications in orthotopic liver transplantation." *Gastrointest Endosc* 52(1): 55-63, ISSN 0016-5107.
- Rabkin, J. M., Orloff, S. L., Reed, M. H., Wheeler, L. J., Corless, C. L., Benner, K. G., Flora, K. D., Rosen, H. R. & Olyaei, A. J. (1998). "Biliary tract complications of side-to-side without T tube versus end-to-end with or without T tube choledochocholedochostomy in liver transplant recipients." *Transplantation* 65(2): 193-199, ISSN 0041-1337 .
- Rerknimitr, R., Sherman, S., Fogel, E. L., Kalayci, C., Lumeng, L., Chalasani, N. Kwo, P. & Lehman, G. A. (2002). "Biliary tract complications after orthotopic liver transplantation with choledochocholedochostomy anastomosis: endoscopic findings and results of therapy." *Gastrointest Endosc* 55(2): 224-231, ISSN 0016-5107.
- Scatton, O., Meunier, B., Cherqui, D., Boillot, O., Sauvanet, A., Boudjema, K., Launois, B., Fagniez, P. L., Belghiti, J., Wolff, P., Houssin, D. & Soubrane, O. (2001). "Randomized trial of choledochocholedochostomy with or without a T tube in orthotopic liver transplantation." *Ann Surg* 233(3): 432-437, ISSN 0003-4932.
- Schwartz, D. A., Petersen, B. T., Poterucha, J. J. & Gostout, C. J. (2000). "Endoscopic therapy of anastomotic bile duct strictures occurring after liver transplantation." *Gastrointest Endosc* 51(2): 169-174, ISSN 0016-5107 .
- Shah, S. A., Grant, D. R., McGilvray, I. D., Greig, P. D., Selzner, M., Lilly, L. B., Girgrah, N., Levy, G. A. & Cattral, M. S. (2007). "Biliary strictures in 130 consecutive right lobe

- living donor liver transplant recipients: results of a Western center." *Am J Transplant* 7(1): 161-167, ISSN 1600-6135.
- Sharma, S., Gurakar, A. & Jabbour, N. (2008). "Biliary strictures following liver transplantation: past, present and preventive strategies." *Liver Transpl* 14(6): 759-769, ISSN 1527-6465 .
- Shastri, Y. M., Hoepffner, N. M., Akoglu, B., Zapletal, C., Bechstein, W. O., Caspary, W. F. & Faust, D. (2007). "Liver biochemistry profile, significance and endoscopic management of biliary tract complications post orthotopic liver transplantation." *World J Gastroenterol* 13(20): 2819-2825, ISSN 1007-9327.
- Sherman, S., Shaked, A., Cryer, H. M., Goldstein, L.I. & Busuttil, R.w. (1993). "Endoscopic management of biliary fistulas complicating liver transplantation and other hepatobiliary operations." *Ann Surg* 218(2): 167-175, ISSN 0003-4932.
- Tanaka, M., Takahata, S., Konomi, H., Matsunaga, H., Yokohata, K., Takeda, T., Utsunomiya, N. & Ikeda, S. (1998). "Long-term consequence of endoscopic sphincterotomy for bile duct stones." *Gastrointest Endosc* 48(5): 465-469, ISSN 0016-5107.
- Tashiro, H., Itamoto, T., Sasaki, T., Ohdan, H., Fudaba, Y., Amano, H., Fukuda, S., Nakahara, H., Ishiyama, K., Ohshita, A., Kohashi, T., Mitsuta, H., Chayama, K. & Asahara, T. (2007). "Biliary complications after duct-to-duct biliary reconstruction in living-donor liver transplantation: causes and treatment." *World J Surg* 31(11): 2222-2229, ISSN 0364-2313.
- Thuluvath, P. J., Pfau, P. R., Kimmey, M. B. & Ginsberg, G. G. (2005). "Biliary complications after liver transplantation: the role of endoscopy." *Endoscopy* 37(9): 857-863, ISSN 0013-726X.
- Todo, S., Furukawa, H. & Kamiyama, T. (2005). "How to prevent and manage biliary complications in living donor liver transplantation?" *J Hepatol* 43(1): 22-27, ISSN 0168-8278 .
- Tsujino, T., Isayama, H., Sugawara, Y. Sasaki, T. Kogure, H. Nakai, Y., Yamamoto, N., Sasahira, N., Tada, M., Yoshida, H., Kokudo, N., Kawabe, T., Makuuchi, M. & Omata, M. (2006). "Endoscopic management of biliary complications after adult living donor liver transplantation." *Am J Gastroenterol* 101(10): 2230-2236, ISSN 0002-9270.
- Tzakis, A. G., Gordon, R. D., Shaw, B. W., Jr., Iwatsuki, S. & Starzl, T. E. (1985). "Clinical presentation of hepatic artery thrombosis after liver transplantation in the cyclosporine era." *Transplantation* 40(6): 667-671, ISSN 0041-1337 .
- Valls, C., Alba, E., Cruz, M., Figueras, J., Andia, E., Sanchez, A., Llado, L. & Serrano, T. (2005). "Biliary complications after liver transplantation: diagnosis with MR cholangiopancreatography." *AJR Am J Roentgenol* 184(3): 812-820, ISSN 0361-803X.
- Venu, M., Brown, R. D., Lepe, R., Berkes, J., Cotler, S. J., Benedetti, E., Testa, G. & Venu, R. P. (2007). "Laboratory diagnosis and nonoperative management of biliary complications in living donor liver transplant patients." *J Clin Gastroenterol* 41(5): 501-506, ISSN 0192-0790.
- Vera, A., Moledina, S., Gunson, B., Hubscher, S., Mirza, D., Olliff, S. & Neuberger, J. (2002). "Risk factors for recurrence of primary sclerosing cholangitis of liver allograft." *Lancet* 360(9349): 1943-1944, ISSN 0140-6736.



- Verdonk, R. C., Buis, C. I., Porte, R. J., van der Jagt, E. J., Limburg, A. J., van den Berg, A. P., Slooff, M. J., Peeters, P. M., de Jong, K. P., Kleibeuker, J. H. & Haagsma, E. B. (2006). "Anastomotic biliary strictures after liver transplantation: causes and consequences." *Liver Transpl* 12(5): 726-735, ISSN 1527-6465 .
- Verdonk, R. C., Buis, C. I., van der Jagt, E. J., Gouw, A. S., Limburg, A. J., Slooff, M. J., Kleibeuker, J. H., Porte, R. J. & Haagsma, E. B. (2007). "Nonanastomotic biliary strictures after liver transplantation, part 2: Management, outcome, and risk factors for disease progression." *Liver Transpl* 13(5): 725-732, ISSN 1527-6465.
- Vougas, V., Rela, M., Gane, E., Muiesan, P., Melendez, H. V., Williams, R. & Heaton, N. D. (1996). "A prospective randomised trial of bile duct reconstruction at liver transplantation: T tube or no T tube?" *Transpl Int* 9(4): 392-395, ISSN 0934-0874 .
- Welling, T. H., Heidt, D. G., Englesbe, M. J., Magee, J. C., Sung, R. S., Campbell, D. A., Punch, J. D. & Pelletier, S. J. (2008). "Biliary complications following liver transplantation in the model for end-stage liver disease era: effect of donor, recipient, and technical factors." *Liver Transpl* 14(1): 73-80, ISSN 1527-6465.
- Williams, E. D. and Draganov P. V. (2009). "Endoscopic management of biliary strictures after liver transplantation." *World J Gastroenterol* 15(30): 3725-3733, ISSN 1007-9327 .
- Wojcicki, M., Milkiewicz, P. & Silva, M. (2008). "Biliary tract complications after liver transplantation: a review." *Dig Surg* 25(4): 245-257, ISSN 0253-4886.
- Yazumi, S. & Chiba, T. (2005). "Biliary complications after a right-lobe living donor liver transplantation." *J Gastroenterol* 40(9): 861-865, ISSN 0944-1174.
- Yazumi, S. & Chiba, T. (2006). "Endoscopic management of biliary stricture after right-lobe living-donor liver transplantation with biliary anastomosis." *Clin Gastroenterol Hepatol* 4(10): 1296; author reply 1296, ISSN 1542-3565 .
- Yazumi, S., Yoshimoto, T., Hisatsune, H., Hasegawa, K., Kida, M., Tada, S., Uenoyama, Y., Yamauchi, J., Shio, S., Kasahara, M., Ogawa, K., Egawa, H., Tanaka, K. & Chiba, T. (2006). "Endoscopic treatment of biliary complications after right-lobe living-donor liver transplantation with duct-to-duct biliary anastomosis." *J Hepatobiliary Pancreat Surg* 13(6): 502-510, ISSN 0944-1166 .
- Yuan, Y. & Gotoh M. (2010). "Biliary complications in living liver donors." *Surg Today* 40(5): 411-417, ISSN 0941-1291 .
- Zoepf, T., Maldonado-Lopez, E. J., Hilgard, P., Dechene, A., Malago, M., Broelsch, C. E., Schlaak, J. & Gerken, G. (2005). "Diagnosis of biliary strictures after liver transplantation: which is the best tool?" *World J Gastroenterol* 11(19): 2945-2948, ISSN 1007-9327.





## **Therapeutic Gastrointestinal Endoscopy**

Edited by Prof. Oliviu Pascu

ISBN 978-953-307-743-7

Hard cover, 216 pages

**Publisher** InTech

**Published online** 22, September, 2011

**Published in print edition** September, 2011

Endoscopy has had a big role in the development of modern gastroenterology. Modern endoscopy will certainly be more therapeutic. It started with endoscopic hemostasis and polypectomy, than beginning of the 1970's with the advent of endoscopic sphincterotomy extended to biliopancreatic pathology and has a huge impact in this difficult pathology. Plastic stents made the first steps in endoscopic palliation of neoplastic jaundice, metallic stents, covered or uncovered are better for biliary palliation and can be used also for palliation neoplastic obstruction at different levels of the digestive tube. Resection of digestive tumors has evolved now to sub-mucosal resection, looking to have one-piece complete resection. Interventional endoscopy is now very complex and takes a lot of time for endoscopists to learn properly these techniques. This book is a very good up-to-date overview of new techniques of interventional endoscopy for those who want to learn or develop their knowledges in this field.

### **How to reference**

In order to correctly reference this scholarly work, feel free to copy and paste the following:

Firas Zahr ElDeen, Ching-Song Lee and Wei-Chen Lee (2011). Endoscopic Management of Biliary Complications After Liver Transplantation, Therapeutic Gastrointestinal Endoscopy, Prof. Oliviu Pascu (Ed.), ISBN: 978-953-307-743-7, InTech, Available from: <http://www.intechopen.com/books/therapeutic-gastrointestinal-endoscopy/endoscopic-management-of-biliary-complications-after-liver-transplantation>

**INTECH**  
open science | open minds

### **InTech Europe**

University Campus STeP Ri  
Slavka Krautzeka 83/A  
51000 Rijeka, Croatia  
Phone: +385 (51) 770 447  
Fax: +385 (51) 686 166  
[www.intechopen.com](http://www.intechopen.com)

### **InTech China**

Unit 405, Office Block, Hotel Equatorial Shanghai  
No.65, Yan An Road (West), Shanghai, 200040, China  
中国上海市延安西路65号上海国际贵都大饭店办公楼405单元  
Phone: +86-21-62489820  
Fax: +86-21-62489821

© 2011 The Author(s). Licensee IntechOpen. This chapter is distributed under the terms of the [Creative Commons Attribution-NonCommercial-ShareAlike-3.0 License](https://creativecommons.org/licenses/by-nc-sa/3.0/), which permits use, distribution and reproduction for non-commercial purposes, provided the original is properly cited and derivative works building on this content are distributed under the same license.

IntechOpen

IntechOpen