

# We are IntechOpen, the world's leading publisher of Open Access books Built by scientists, for scientists

6,900

Open access books available

186,000

International authors and editors

200M

Downloads

Our authors are among the

154

Countries delivered to

TOP 1%

most cited scientists

12.2%

Contributors from top 500 universities



WEB OF SCIENCE™

Selection of our books indexed in the Book Citation Index  
in Web of Science™ Core Collection (BKCI)

Interested in publishing with us?  
Contact [book.department@intechopen.com](mailto:book.department@intechopen.com)

Numbers displayed above are based on latest data collected.  
For more information visit [www.intechopen.com](http://www.intechopen.com)



# Wireless Capsule Endoscopy in Pediatric Gastrointestinal Diseases

Daisuke Tokuhara

*Dept of Pediatrics, Osaka City University Graduate School of Medicine,  
Japan*

## 1. Introduction

Capsule endoscopy (CE), which was invented to visualize the entire small intestine in a noninvasive manner was first described in 2000 (Iddan, 2000), was approved for adult patients in 2001 by Food and Drug Administration (FDA). More than 600,000 PillCam SB capsules, which is the first model for CE in the world, have been used worldwide since 2001 (Nakamura, 2009). In pediatric patients, Seidman et al has first described the diagnostic value of CE (Seidman, 2002), and in 2003, FDA approved CE for pediatric patients ages 10 years and older. Emerging number of CE studies in children indicate the great demand for this population ( Tokuhara, 2010; de'Angelis, 2007; Atay, 2009; Fritscher-Ravens, 2009; Moy, 2009; Guilhaon de Araujo Sant'Anna, 2005; Thomson, 2010; Ge, 2007; Postgate, 2009; Pinho, 2008; Shamir, 2007; Stiffler, 2003; Argüelles-Arias, 2004; Cohen, 2008 ), but performed number is relatively small (approximately 600, at the time of 2010) compared to adult cases (> 600,000), therefore, informations about indications, obtained results and risk of complications are not fully understood in pediatric patients. In pediatric patients, as well as in adults, CE is a first-line of examination to evaluate the entire small intestine and provides evidence for the diagnosis to the suspected small bowel disease especially in obscure gastrointestinal bleeding (OGIB) and suspected inflammatory bowel disease (IBD), on the other hand, accumulated studies are extending the indication of CE to protein loss, growth failure, abdominal pain, suspected polyp or graft-versus-host disease (GVHD) and regular follow-up for the known small bowel diseases. In this review, we summarize and discuss the capsule endoscopy system, indication, limitation, and future perspective of CE in pediatric patients.

## 2. General features of CE

### 2.1 Capsule endoscopy system

Capsule endoscopy system in children is almost same as that of adults. It is available to use a pediatric accessory kit with a recorder belt and sensor array, which are more appropriately sized for children (Fritscher-Ravens, 2009), on the other hand, CE, a PillCam SB capsule itself is the same type used by adults. The PillCam SB system has three components: a capsule endoscopy body, an external receiving antenna (consisting of eight sensor arrays) with attached portable hard disc drive (data recorder), and a customized PC workstation (RAPID: reading and processing images and data) with dedicated software for review and interpretation of images (Cave, 2004). CE is 26-mm long, 11-mm wide, weighs 3.4 g, records

images at a rate of 2 frames per second (fps), and has a battery life of about 8 hours. Image features include a 140°C field of view, 1:8 magnification, 1- to 30-mm depth of view, and a minimum size of detection of about 0.1mm. There is no capability of biopsy. After the patients ingest capsule, they can resume normal activities immediately, and are permitted to consume clear liquids and food at 2 h and 4 h thereafter (Tokuhara, 2010).

2.2 Abnormalities assessed by CE

CE visualizes various mucosal abnormalities such as ulcer, erosion, stricture, vascular anomaly, and mucosal protuberance such as polyp and tumor in pediatric patients as well as in adults (Table 1, Fig.1). In addition, Abnormal intestinal contents such as bleeding and

Findings	
Ulcer	Vascular anomalies
Redness	Polyp
Erosion	Stricture
Atrophy	Bleeding
White villi	Intestinal contents (ex. parasitic worm)
Mass	
Diagnosed or suggested diseases	
Crohn’s disease	Celiac disease
Angiodysplasia	Hemangioma
Lymphangiectasia	
Meckel’s diverticula	Lymphonodular hyperplasia
Peutz-Jeghers syndrome	GVHD
Blue rubber bleb	Parasitic worm

Table 1. Findings and diagnosed or suggested diseases by CE

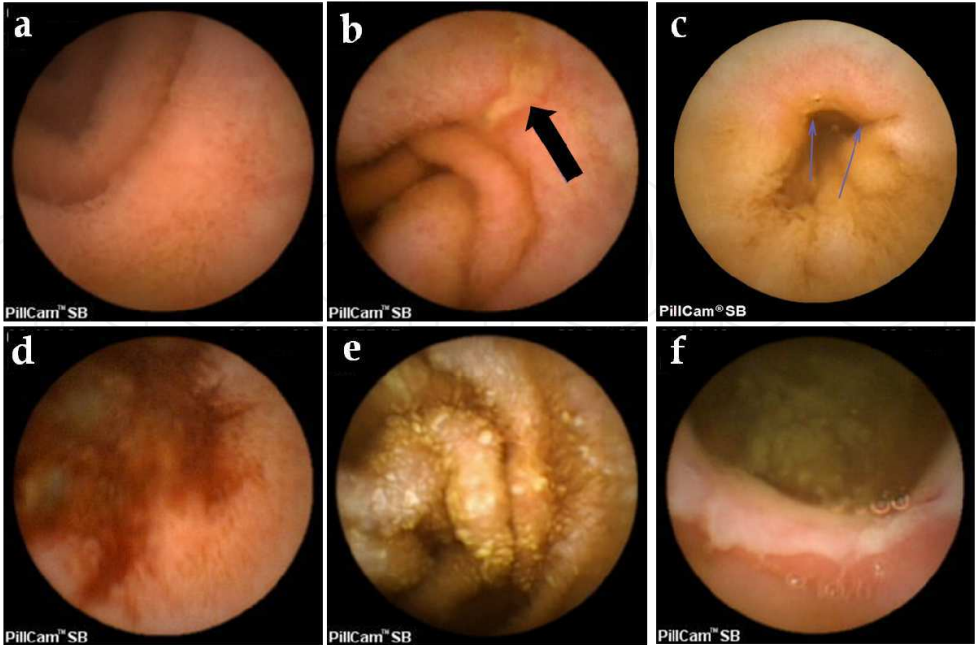


Fig. 1. CE findings. (a) Normal jejunum. (b) Longitudinal ulcer (black arrow). (c) Stricture with redness and ulcer (arrows). (d) Active bleeding. (e) White villi. (f) Stenosis with ulcer.

parasitic worm can be seen (Table 1). Those abnormalities are highly detectable in the entire small intestine, to some extent, CE provide supportive information for the presence of abnormalities in the esophagus, stomach and colon. Transit time of CE and analyzed pathway by the software will help to assess the localization of detected abnormality in the small intestine. In pediatric patients with suspected small intestinal disease, CE detect abnormal findings in 55% (286/523) of cases (Tokuhara, 2010; de'Angelis, 2007; Atay, 2009; Fritscher-Ravens, 2009; Moy, 2009; Guilhon de Araujo Sant'Anna, 2005; Thomson, 2010; Ge, 2007; Argüelles-Arias, 2004; Pinho, 2008; Stiffler, 2003). Based on the detected abnormalities by CE in addition to the clinical and/or other laboratory informations, various small intestinal diseases are diagnosed or suggested, or further elucidated of their involvements of small intestinal lesions in known diseases (Table 1).

### 2.3 Comparison with other modalities

A previous study demonstrated that CE is superior to small-bowel radiography, computed tomography enterography (CTE), and colonoscopy with ileoscopy in the evaluation of adult patients with suspected CD (Dionisio, 2010). As well as adult patients, CE is more sensitive than radiological and standard endoscopic modalities in the detection of small bowel CD distribution, OGIB source, and presence of polyps in children (Thomson, 2007; Guilhon de Araujo Sant'Anna, 2005). In addition, because of its non-invasive approach, even if initial study is non-diagnostic, repeat CE may increase diagnostic yield (Tokuhara, 2010). Further, even if initial CE study is technically inadequate (poor visualization and/or not reaching colon), it is possible to repeat examination compared to the invasive conventional examination. Almost at the same time with CE, double balloon enteroscopy (DBE), which is relatively a novel technique compared to the conventional examination, was developed to investigate the entire small intestine (Yamamoto, 2001). DBE can evaluate the small intestine as well as CE, but can gather biopsy specimens, and can carry out therapeutic procedures which are impossible by CE. In order to evaluate the entire small intestine, it is necessary to perform DBE 2 times with anterograde and retrograde routes. On the other hand, DBE often cannot visualize the entire small intestine. In regard to the application of DBE in children, previous studies reported the feasibility and usefulness of DBE in pediatric patients (Nishimura, 2010; Thomson, 2010; Leung, 2007). Another study described the successful use of DBE in 3 years old children with OGIB (Kramer, 2009). In regard to the differences in diagnostic accuracy and other advantages between CE and DBE, most of studies have concluded that CE was superior to the initial diagnosis but DBE was superior to treatment or histopathological diagnosis in adult patients with OGIB (Hadithi, 2006; Nakamura, 2006). In addition, lack of experience and expertise for smaller children are to be solved for the future extensive use of DBE in children (Leung, 2007). Thus it is expected that DBE is used in pediatric patient, but it is prefer that DBE is performed based on the screening by CE.

### 2.4 Preparations for CE

Generally, overnight fasting is used as a standard preparation for CE in pediatric patients (Tokuhara, 2010; Guilhon de Araujo Sant'Anna, 2005; Atay, 2009). Diagnostic yield of capsule endoscopy depends on the quality of visualization of the small bowel wall and complete passage through the small bowel. Some abnormalities such as angiodysplasias are sometimes hampered by residual intestinal contents. Thus, a bowel preparation is studied previously, and sodium phosphate (Niv, 2005) or polyethylene glycol (PEG) (Viazis, 2004; Dai, 2005) has been described to offer improved visualization of the small intestine in adults.

In pediatric patients, colonoscopic bowel preparation was reported to offer the most favorable preparation. On the other hand, evaluation of entire small intestine is sometimes not completed because of prolonged gastric emptying and limited battery life (< 8h). In pediatric patients, completion rate of CE in the entire small intestine varies from 69 – 89 % (Tokuhara, 2010; Guilhon de Araujo Sant'Anna, 2005; Atay, 2009; de'Angelis, 2007; Ge, 2007; Moy, 2009; Postgate, 2009). In order to improve the completion rate, mosapride citrate or laxatives are one of candidate to increase the ability to observe the entire small intestine, but there is no systematic study in regard to the use of mosapride or laxatives as a preparation drug for CE study in pediatric patients. In adults, a previous study (Wei, 2007) reported oral 10mg mosapride citrate 1h before CE examination could accelerate the gastric emptying (13.5 min vs 34 min) and completion rate of small bowel examination ( 93.3 % vs 66.7 % ). In regard to the laxatives, a previous study (Franke, 2008) reported that a combination of bisacodyl and sodium phosphate significantly accelerated small bowel transit time (262 min  $\pm$  55min vs 287 min  $\pm$  97min) but had no effect on the visibility of CE. Taken together, in order to increase the completion rate of small intestine and carefully examine the mucosal abnormality such as angiodysplasias, mosapride or laxatives might be effective preparation drug for CE in addition to the overnight fasting as the standard method.

### 3. Ages and indications for CE

#### 3.1 Age

Accumulated studies confirmed that CE is safe and useful to children over 10 years of age (Tokuhara, 2010; Guilhon de Araujo Sant'Anna, 2005; Argüelles-Arias, 2004), and application to this age group is considered as appropriate as well as adult. On the other hand, it is still controversial to use CE for the children under 10 years of age. Several studies described that CE has high diagnostic yield to those patients under 10 years of age (de'Angelis, 2007; Atay, 2009; Fritscher-Ravens, 2009; Ge, 2007), and their small body size don't relate to the risk of capsule retention, which is the most serious complication in this modality as described in the latter paragraph. In addition, there was no difference in the gastric and small intestinal passage time between adult and pediatric patients (Ge, 2007). In young children (1.5-8 yr), a previous study reported CE detected small intestinal pathology in 45% (37 of 83 patients) in whom their indications are gastrointestinal bleeding, suspected Crohn's disease, abnormal pain, protein loss and malabsorption (Fritscher-Ravens, 2009). Because of no incidence of retention among those aged patients (1.5-7.9yr), CE is considered as feasible and safe down to the age of 1.5 yr. As another important aspect, swallowing of CE is unavoidable problem in small children. Based on the previous studies, most of pediatric patients (>10yr) can ingest CE (Tokuhara, 2010; Guilhon de Araujo Sant'Anna, 2005). In regard to children > 4yr, 32% of children could ingest CE (Fritscher-Ravens, 2009). In case those young children cannot ingest capsule, endoscopic placement of the capsule into the duodenum is used (Bizzarri, 2005; Barth, 2004; Fritscher-Ravens, 2009). In the endoscopic placement, CE is released at the third part of the duodenum in order to prevent migration of CE back to the stomach (Bizzarri, 2005; Barth, 2004; Fritscher-Ravens, 2009). Some of devices are developed and reported (Orendain, 2010), on the other hand, mucosal injury by passage of device should be taken into consideration as a complication (Barth, 2004; Fritscher-Ravens, 2009). As another potential risk regarding the age, complication associated with deep intravenous sedation and general anesthesia for the endoscopic placement should be taken into consideration.



3.2 Indications

The indications for CE in pediatric patients are similar to that of adult patients; OGIB and suspected IBD are the major indications and suspected or known polyps such as Peutz-Jeghers syndrome are the following well-studied indication (Table 2). Known CD is also well-studied indication, but needs attention before the use of CE because of a relative high risk of capsule retention as described later. Malabsorption, protein loss, recurrent abdominal pain, and growth failure are the other minor indications, but sometimes important rather than adult population because of importance of mental and physical growth in children. Celiac disease is one of major indication in adult of Western countries such as USA and Europe, but it is rarely included as indication in children. On the other hand, because of non-invasive method, CE can be used repeatedly thus has been applied to get information to evaluate the treatment of known small bowel disease. Further, CE can provide supportive information about further examination, for example, when a physician determine the route of double balloon enteroscopy (via anal or oral) to resect polyps or take biopsies.

	Total Rate	Atay, 2009	Fritscher- Ravens, 2009	de' Angelis, 2007	Moy, 2009	Guilhon de Araujo Sant'Anna, 2005	Thomson, 2010	Ge, 2007	Tokuhara, 2000
Age		8~21	1.5~7.9	1.5~18	ND	10~18	9.4~15.9	3~18	10~18
n	509	207	83	87	46	30	28	16	12
Indications									
IBD	285 (56)	172 (83)	20 (24)	32 (37)	19 (41)	20 (67)	16 (57)	0 (0)	6 (50)
(Suspected IBD)	138 (27)	73 (35)	20 (24)	10 (11)	0 (0)	20 (67)	10 (36)	0 (0)	5 (42)
(Known IBD)	147 (29)	99 (48)	0 (0)	22 (25)	19 (41)	0 (0)	6 (21)	0 (0)	1 (8)
OGIB	94 (18)	15 (7)	30 (36)	21 (24)	7 (15)	4 (13)	6 (21)	9 (56)	2 (17)
Polyps	55 (11)	2 (1)	0 (0)	33 (38)	11 (24)	6 (20)	3 (11)	0 (0)	0 (0)
Abdominal pain	22 (4)	0 (0)	12 (14)	0 (0)	1 (2)	0 (0)	1 (4)	3 (19)	4 (33)
Protein loss	13 (3)	1 (1)	9 (11)	0 (0)	1(2)	0 (0)	2 (7)	0 (0)	0 (0)
Malabsorption	13 (3)	0	12 (14)	1 (1)	0	0	0	0	0
Growth failure	5 (1)	0	0	0	5(10)	0	0	0	0
Diarrhea	4 (1)	4 (2)	0	0	0	0	0	0	0

Table 2. Indications for CE in pediatric patients.

Indications were summarized based on the previous CE studies for pediatric patients, which included at least 10 CE examinations for suspected small intestinal diseases (Tokuhara, 2010; de'Angelis, 2007; Atay, 2009; Fritscher-Ravens, 2009; Moy, 2009; Guilhon de Araujo Sant'Anna, 2005; Thomson, 2010; Ge, 2007). We excluded the studies with limited indications (ex. abdominal pain alone). ( ), percentage. ND, not described.

3.2.1 Chron's disease or inflammatory bowel disease

CE provides supportive evidence to diagnose or exclude small bowel CD. Thus, CE can be used in order to evaluate suspected CD or IBD, small bowel involvement of known CD, or follow-up of known small bowel CD. In adults, OGIB is the major indication rather than suspected IBD, however in children, suspected CD or IBD became the major indication (Table 2). Although indication rate of suspected CD or IBD depends on the physicians' protocol and criteria, in regard to the papers in which all of small intestinal disease are included as indication, indication rate for suspected IBD varies from 0%-67% and total indication rate is 27%(138/509). If known CD or IBD are included, indication rate increase up to 56% (285/509) (Table 2). On the other hand, a previous study showed the indication rate of suspected CD as 7.8% in adult patients (Rondonotti, 2010). Because a known CD increases a risk of capsule retention possibly caused by an intestinal stricture (Cheifetz, 2006; Moy, 2009; Atay, 2009), it is

recommended to avoid the use of CE for the evaluation of known CD in both adult and children. In regard to the diagnostic accuracy, the previous pediatric study elucidated that CE was a more effective diagnostic tool in established CD patients compared with small-bowel radiography, CTE, and push enteroscopy (Thomson, 2007). Further, CE provides evidence not only to diagnose a patient having CD but also exclude CD and discriminate CD from indeterminate colitis. The rate of diagnosis of CD in patients with suspected CD depends on the study, which was 12.5-70.6% in adult (Cheifetz, 2006; De Bona, 2006; Fireman, 2003), and 50-55% in children (de'Angelis, 2007; Fritscher-Ravens, 2009; Guilhon de Araujo Sant'Anna, 2005), thus criteria of suspected CD will be an important issue of concern.

3.2.2 OGIB and chronic anemia

Obscure gastrointestinal bleeding (OGIB) including chronic anemia is one of the major indication of CE in children as well as in adults (Table 2). In adults, a previous study showed the indication rate of OGIB as 43.4% (Rondonotti, 2010). Another study identified those patients of having significant findings; small bowel CD, angiodysplasia, Meckel's diverticulum, and rarely parasitic infection such as hookworm (Sriram, 2004). In regard to the previous studies in which all of small intestinal disease are included as indication, indication rate of OGIB in pediatric CE varies from 7.2%-56.2%, and a total indication rate is 18.4% (94/509) (Table 2). In regard to the outcome of CE for the evaluation of source of OGIB, CD, polyp or polyposis and angiodysplasia are the most frequently detected source of OGIB in children (Table 3). Hemangioma, ulcerative jejunitis and Meckel's diverticulum are also sometimes found in pediatric patients with OGIB. In regard to the source of venous malformations, Turner syndrome, which caused by loss of part or all of an X chromosome, is important in the field of pediatrics. In Turner syndrome, an intestinal telangiectasia is described as an association with an estimated incidence of 7% (Eroglu, 2002) and cause obscure GI bleeding. A previous report described that CE well detected multiple angiectasias and 2 large telangiectasia in the small intestine of a Turner syndrome with OGIB (Nudell, 2006). CE can determine the size, the location, and the number of telangiectasias, therefore contribute to select medical, surgical, or endoscopic therapy.

Findings	Rate (%)
Total abnormal findings	69.3
CD	9.3
Polyp or polyposis	9.3
Angiodysplasia	9.3
Hemangioma*	6.7
Ulcerative jejunitis	5.3
Meckel's diverticulum	4
Non-specific bleeding lesions	4
Multiple venous malformations	2.6
Giant ileal lymphoid nodular hyperplasia	2.6
Hemorrhagic gastroduodenopathy	2.6
Asmotic ulcer, Cobble stone appearance, Reduplication of the intestine, NSAID-induced mucosal lesions, Erosive gastroenteropathy, Ileal bleeding ulcer,	1.3
Multiple small intestinal varices, Ileal stenosis, TAM	

\* includes Blue rubber bleb syndrome

Table 3. Outcome of CE in 75 patients with OGIB.

As another option, CE provides helpful information in the diagnosis of OGIB in patients who suffered from malignant diseases such as leukemia and received chemotherapy and cord-blood transplantation or bone marrow transplantation. Our recent study described that CE provided a real-time imaging without patient's stress and played a significant role in the management of OGIB in the malignant disease (Tokuhara, 2010). Chronic malignant diseases, such as leukemia, sometimes require repeated evaluation of gastrointestinal bleeding, but repeated conventional endoscopy is stressful and invasive, especially for seriously ill patients. Thus, repeated CE evaluation was acceptable to these patients and did not cause undue physical or mental stress. CE increases patient compliance and can therefore provide real-time informations about changes in gastrointestinal mucosal lesions without invasive bowel preparation.

### 3.2.3 Polyp or tumor

Although polyps and tumors are commonly detected in adult patients, it is rare to detect malignant tumor in pediatric patients thus polyp is a main indication in children. Following the 2 major indications (suspected IBD and OGIB), polyp or polyposis are well-performed indication (Table 2). In regard to the papers in which all of small intestinal disease are included as indication, indication rate of polyps in pediatric CE was 11% (55/509) (0-38%) (Table 2). The purpose of CE for the patients with suspected polyposis is diagnosis, follow-up, selection of route of endoscopy to resect polyp, or determine the necessity of laparotomy. Polyp is sometimes found in a patient with OGIB as an indication (Ge, 2007). As a known polyposis, Peutz-Jeghers syndrome (PJS), familial adenomatous polyposis (FAP), juvenile polyp, and Bannayan-Riley-Ruvalcaba syndrome have been reported. CE provided high diagnostic yield (100%, 5/5) to those pediatric patients with suspected polyposis (deAngelis, 2007). Another study examined 6 pediatric patients with known polyposis (3 PJS, 2 multiple juvenile polyposis, and 1 familial polyposis) and demonstrated that CE had 100% concordance with previously performed imaging modalities, but CE had a higher sensitivity revealing 50% more polyps than observed with the traditional imaging studies (Guilhon de Araujo Sant'Anna, 2005). Among polyposis, hereditary polyposis syndromes including PJS and FAP are known to develop benign small bowel pathology and cancer, thus the follow-up for PJS and FAP is especially important.

In regard to PJS, which is a rare autosomal dominant disorder characterized by mucocutaneous pigmentation and the hamartous polyps throughout the gastrointestinal tract, diagnosis is made by genetic analysis of STK11 gene mutation or 2 of the 3 clinical criteria: family history of PJS, hamartomatous polyps, and mucocutaneous pigmentation (Giardillelo, 2006). Intestinal polyps sometimes cause bleeding, anemia, and intussusceptions. Further, the patients with PJS have risk of malignancy including intestinal, breast, lung cancer in which average age of development of malignancy is the fourth decade of life (van Lier, 2010). Their first episode of manifestation also tend to occur during the first decade of life. Previous study revealed that 68% of children had undergone a laparotomy for bowel obstruction by the age of 18 years and many of these proceeded to a second laparotomy within 5 years (Hinds, 2004). Further, PJS sometimes need endoscopic removal of polyps or surgical treatment for bowel obstruction. Based on the accumulated studies, it has been recommended that endoscopic evaluation of the upper and lower gastrointestinal tract and imaging of the small bowel should be performed from the age of 8 years of earlier if symptoms are present (Hinds, 2004; Hyer, 2000). Therefore it is important to detect malignancies in an early phase and to remove polyps that may be premalignant and may



cause complications. In this regard, it is necessary to understand the size and localization of polyps in PJS. CE can evaluate the entire small intestine and contribute to select whether polyps should be observed or removed by upper endoscopy, colonoscopy, or double balloon enteroscopy. In comparison to conventional technique, a previous study demonstrated that CE detected significantly higher numbers of small-bowel polyps (at least 1cm in diameter) than barium follow-through in adult PJS patients (Brown, 2006). In pediatric patients with PJS, CE significantly detected small polyps (<10mm), and was assessed as a feasible, safe, and sensitive tool for small bowel screening in patients with PJS (Postgate, 2009). Therefore, CE can be used as a first-line surveillance approach in PJS.

In regard to FAP, which is an autosomal dominant condition with a defect in the APC gene on chromosome 5q21, if the patient was left untreated, there is a nearly 100% progression to colorectal cancer by the age of 35–40 yr (Hyer, 2000). The diagnosis is confirmed by finding adenomas during flexible sigmoidoscopy, or more than four pigmented ocular fundus lesions based on indirect ophthalmoscopy carries a 100% positive predictive value. In FAP-affected families with a known gene mutation, direct DNA genotypic analysis can determine whether a family member has the condition. In children with FAP, hepatoblastoma is important as complication rather than intestinal polyps (Aretz, 2006). Typical FAP is characterized by the occurrence of hundreds to thousands of colorectal adenomas. Adenomas usually appear within the second decade, and become symptomatic during the third decade of life. In the patients with FAP, they have high risk to develop duodenal adenoma and cancer, thus the duodenum and particularly the periampullary region is recognized as a major cause of morbidity and mortality. A previous CE study in adult patients with FAP reported that 76% of the patients with FAP with duodenal adenomas had additional adenomas in the proximal jejunum in addition to polyps in the distal jejunum or ileum, in contrast, in FAP patients without duodenal polyps, jejunal or ileal polyps occurred rarely (12%) (Schulmann, 2005). Thus, CE may be useful in selected patients with FAP. In children, the feasibility and usefulness of CE is not remarkable in FAP compared to PJS. It is necessary to accumulate further studies for FAP in children to evaluate the feasibility and usefulness of CE.

### 3.2.4 Abdominal pain

Several CE studies evaluated pediatric patients with abdominal pain. Based on the previous studies in which all of small intestinal diseases are included as indication, indication rate of abdominal pain in pediatric CE was 4% (20/509), varies from 0.0 % to 33.0% depends on the studies (Table 2). As for usefulness of CE, it is controversial that abdominal pain can be an appropriate indication for CE. In adult patients, a previous study described 20 patients with chronic abdominal pain who were negative for extensive diagnostic workup, but no patients had clinically significant CE findings (Bardan, 2003). On the other hand, another study for adult patients demonstrated that abdominal pain with additional symptoms such as weight loss (>10% of body weight), inflammation shown by laboratory tests, chronic anemia, and suspected OGIB was associated with high diagnostic yield (May, 2007). In addition, another study applied to 16 patients with chronic abdominal pain without criteria for other gastrointestinal disorders and detected abnormal findings in 3 patients but in which only 1 patient, with additional symptom of weight loss, had relevant findings to abdominal pain in which ileal erosions and inflammation with a stricture which undetected by radiology (Spada, 2006). Based on previous studies in adult population, CE doesn't provide diagnostic value against

abdominal pain itself, and strict patient selection on the basis of additional symptoms or signs is the key to increasing the field to capsule endoscopy in patients with chronic abdominal pain. In regard to children, a previous study reported that CE detected small bowel involvement in 1/10 patients with functional abdominal pain and most of patients don't have the related organic etiology (Shamir, 2007). Another pediatric study described that 6/12 patients with abdominal pain had abnormal findings in which 3 with small bowel CD, 2 lymph nodular hyperplasia, and 1 blue rubber bleb syndrome, however it is undescribed whether those patients had additional symptoms or signs (Fritscher-Ravens, 2009). CE evaluation for a patient with recurrent abdominal pain reported a self-resolving ileojejunum intussusceptions in the mid-small bowel (Thomson, 2007). Taken together, as well as adult patients, it is indicated that CE doesn't provide diagnostic value against abdominal pain in children, but additional symptoms or signs may increase the demand of CE. On the other hand, in treating children with FAP, it is important to give the family the reassurance that no serious disease is present according to physical examination and laboratory examination. In this regard, CE provides supportive information to exclude the significant small bowel involvement. In adults, celiac disease might be suggested by CE in patients with abdominal pain (Culliford, 2005), but there is no report in pediatric population.

### 3.2.5 Protein loss

Protein loss might be included as indication for CE. A previous study evaluated 9 patients as having protein loss as a main indication, and revealed, in spite of normal duodenal biopsies, 6/9 had abnormal findings in which 4 had lymphangiectasia and 2 had lymph nodular hyperplasia (Fritscher-Ravens, 2009). Protein loss originated from the gut is often found in children with protein-losing gastropathy such as Menetrier disease (Tokuhara, 2007). In case of protein loss as an indication, lymphangiectasia is one of the most suspected and obtained result by CE. Several reports (Alkhoury, 2009; Tokuhara, 2010; Thomson, 2007) described 4 cases of protein loss were identified of having intestinal lymphangiectasia in pediatric patients.

### 3.2.6 Others

Malabsorption and growth failure are not main indication for CE, but CE sometimes contribute to evaluate those patients. A previous study (Moyl, 2009) reported that CE identified 4/7 pediatric patients with unexplained growth failure and normal small bowel series as having small bowel CD. In their study, 5/7 patients had positive anti-*Saccharomyces cerevisiae* antibodies (ASCA), a diagnostic serological marker for CD. In addition, 3 patients had growth failure with abdominal pain, 2 patients had growth failure with diarrhea and aphthous ulcers, and 1 patient had a family history of CD. Thus, Growth failure with additional symptom might be included as an indication for CE.

As an optional application, CE can be applied to evaluate the management of gastrointestinal diseases such as Henoch-Schönlein purpura (HSP) (Preud'Homme DL, 2006) and GVHD (Silbermintz, 2006; Yakoub-Agha I, 2004). In HSP, gastrointestinal bleeding occurs in ~50% of children, and massive bleeding may occur (Katz, 1991). A previous report demonstrated that CE contributed to identify the extent of the small intestinal involvement of HSP and confirmed the efficacy of cyclophosphamide therapy in improving the gastrointestinal lesions (Preud'Homme DL, 2006). In regard to GVHD, a previous study reported that in an 8-yr old child following allogeneic hematopoietic cell transplantation

who developed large volume bloody diarrhea requiring multiple blood transfusions that was resistant to aggressive therapy for GVHD, CE provided significant information not provided by upper endoscopy and colonoscopy that allowed for successful treatment changes (Silbermintz, 2006). Another study (Yakoub-Agha I, 2004) in adults demonstrated that CE provided more significant findings than upper endoscopy in the diagnosis of intestinal GVHD. The diagnosis of intestinal GVHD is based upon histological findings in endoscopic mucosal biopsy specimens. Therefore, it is sometimes required to use colonoscopy and upper endoscopy in order to diagnose and evaluate the extent of GVHD, but these tools cannot provide the entire small bowel information. In this regard, CE can provide supportive information about small bowel involvement of GVHD and the unknown source of OGIB and the effect of treatment. While DBE might be superior approach to CE in certain cases, it is an inappropriate option for exhausted children undergoing chemotherapy. In this regard, CE evaluation is acceptable to these patients and does not cause undue physical or mental stress, thus repeated CE examination is available.

## 4. Complications and contraindications

### 4.1 Complications

The most significant complication in the CE examination is capsule retention (Fig.2). Capsule retention is defined as having a capsule endoscope remain in the digestive tract for a minimum of 2 weeks (Cave, 2005). A preceding normal small-bowel series does not preclude subsequent CE retention. The reported capsule retention rate in a study of 900 adult patients was approximately 0.7% (Barkin, 2002). It should be noted that there are potential risks of retention in CD, especially known CD. A previous study in adults (Cheifetz, 2006) revealed that CD is an potential risk of having the retention which is caused by unsuspected strictures, and retention was occurred in 13% (5 of 38) of patients with known CD , whereas in 1.6% (1 of 64) with suspected CD. When we reviewed previous CE studies of pediatric patients, which included at least 10 CE examinations for each patient, and found that 13 capsules had been retained in a total of 345 CE examinations giving an average frequency of capsule retention of 3.7% (range, 0–20%) (Table 4).

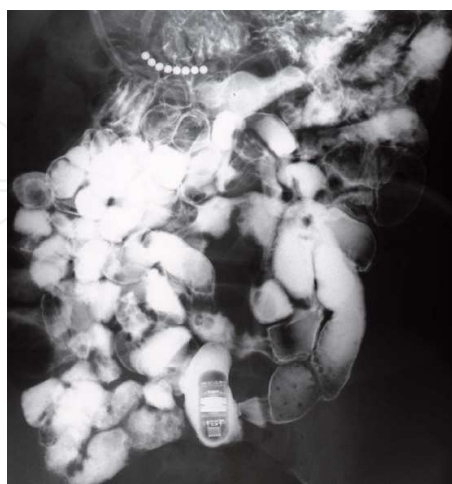

Fig. 2. Capsule retention.

Small bowel series showing a capsule retention at ileal stenoses in a 10-year-old girl with OGIB. After 2 months of retention, stenoses were surgically resected and a capsule was

removed. The patient was finally diagnosed as having non-specific multiple ulcers of small intestine (Tokuhara, 2010).

As well as adult cases, in also pediatric patients, a previous study retrospectively demonstrated that the risk of retention was significantly high (37.5% ; 3/8) in known CD, whereas none of patients with other indications showed the retention(Atay, 2009) . When capsule retention happened, a risk of endoscopic or surgical removal might arise, although some reports described successful excretion of capsule after the corticosteroid therapy against gastrointestinal disease such as eosinophillic gastroenteropathy(Guilhon de Araujo Sant'Anna, 2005). As another severe insults related to capsule retention, a previous study described that adult patient with Crohn’s disease had a perforation after capsule endoscopy (Parikh, 2009). To decrease the risk of capsule retention and the following perforation, care should be taken in obtaining a history of problems with delayed gastric emptying, small bowel obstruction secondary to previous surgical changes, pyloric stenosis, Crohn disease, or Meckel diverticulum.

	Age/sex	Indication	Duration*	Symptoms	Outcome	Diagnosis (Source)
<b>(Retention)</b>						
Tokuhara, 2010	10y, F	OGIB	2 months	None	Surgical ileal resection	(stricture) **
de' Angelis , 2007	F	CD	3 months	None	Spontaneous excretion	CD
	7y, F	OGIB	2 months	None	Surgical removal	Blinding ending loop
Atay, 2009	22y, M	Known CD	2 y	Unknown	Passed after medication	(ND)
	13y, M	Known CD	3 weeks	Nausea, emesis	Passed after steroid use	(ND)
Thomson, 2010	<16y	CD	4 weeks	ND	Passed after steroid use	CD (ND)
<b>(Transit abnormality)</b>						
Atay, 2009	16y, M	Known CD	5 days	Abdominal pain	Surgery	(stricture)
Guilhon de Araujo Sant'Anna, 2005	ND	Suspected IBD	10 days	None	Passed after steroid use	Eosinophilic enteropathy (stricture)
Moy, 2009	5-15y	ND	ND	Abdominal pain	Surgical removal	4 CD
		1 suspected CD	ND	Abdominal pain	Surgical removal	
		3 known CD	ND	Abdominal pain	Passed after steroid use	
		ND	5 days	Abdominal pain	passed	
Cohen, 2008	ND	Known CD	ND	Ileal pouch	endoscopic removal	

ND, not described; \*Duration of retention or transit abnormalities. \*\* The patient was finally diagnosed as non-specific multiple ulcers of small intestine.

Table 4. Capsule retention or regional transit abnormalities with symptoms or abnormal findings.



A novel dissolvable patency capsule will soon be available as a potential screening tool for patients deemed to be a high risk for retention. A patency capsule, which similar in size to PillCam SB and dissolves spontaneously because it is composed of lactose, has been developed by Given Imaging to assess bowel patency and degree of stenosis (Nakamura, 2008). If passage of the patency capsule is blocked, the capsule dissolves in 40-100h. The safety and efficacy of the initial model has been questioned (Gay, 2005), but recently, a new patency capsule model with a biodegradable body has been developed. The new patency capsule is a reliable indicator of functional patency in suspected or even known cases of intestinal stricture, and it can be used prior to conventional CE to predict and minimize the risk of retention and impaction (Banerjee, 2007).

As another rare condition, a previous study reported that a patient having a nervous temperament showed the discomfort, headache, and low blood pressure 2 h after capsule ingestion (Tokuhara, 2010). Patient temperament might affect outcome, especially among children, thus when pediatric patients have a nervous temperament, patient preparation, and explanation of the possibility of adverse effects to their legal guardians might be necessary.

#### **4.2 Contraindications**

It is not recommended to use CE in patients with known or suspected gastrointestinal obstruction, strictures, or fistulas based on the clinical picture or pre-procedure testing and profile, patients with cardiac pacemakers or other implanted electromedical devices. It is not generally recommended to use CE in patients with difficulty of swallowing, but based on the development of capsule replacement, it is considerable if the pediatric patient is considered to take a benefit by capsule endoscopy even by endoscopic replacement under general anesthesia. There is no detailed limitation to use CE in small children but it is not recommended to use CE under 1.5yr or 10kg of body weight.

#### **5. Perspective**

Development of capsule endoscopy provides another 2 types of capsule endoscopies (PillCam ESO and PillCam COLON) which is for the esophagus and the colon, respectively (Eliakim, 2004; Saurin, 2007). The Pillcam ESO capsule differs from the small-bowel capsule in that it has a camera at both ends of the capsule and captures a total of 14 images per second (7 per second for each camera). The battery life of the Pillcam ESO is approximately 20 minutes and is approved for esophageal imaging only. The FDA approved the Pillcam ESO in November 2004. PillCam ESO and PillCam COLON have been demonstrated of their feasibility and usefulness in adult patients with GERD and esophageal varices, and colonic neoplasia, respectively. Future application of PillCam ESO and PillCam COLON is expected also in pediatric patients. As another interest of issue, therapeutic interventions using a capsule endoscope, such as delivery of medication to specific disease sites, smaller size of CE, higher quality image, biopsy with remote control are expected in future CE.

#### **6. Conclusion**

Capsule endoscopy is a non-invasive and effective approach to investigate the entire small bowel intestine in the suspected small intestinal diseases of children compared to the conventional examination methods (Barium series, computed tomography, push



enteroscopy), and provide the evidence in the diagnosis and give the supportive informations to evaluate the effect of the treatment and the clinical course. On the other hand, a physician and a patient must be aware of that CE is a first-line of surveillance but not necessarily a perfect tool to diagnose or exclude a disease thus other examination such as double-balloon endoscopy might be needed for histological examination or resection of lesions. In addition, especially in known CE, there is a risk of capsule retention which might need endoscopic or surgical removal. In those patients who are unable to swallow the capsule, endoscopic replacement of capsule is available. Major diagnostic yield is expected in patients having indications of suspected IBD, OGIB, and suspected polyps. Abdominal pain, malabsorption, protein loss, and growth failure might be included as indication especially when they accompanied additional clinical or laboratory signs suggesting inflammation. Relatively small number of CE studies in children compared to adult, it needs further consideration to use CE in small children at least under 10 years of age as well as children over 10 years of age and adults, it is clear that clinical application of CE in pediatric population is extending and there is small children who had benefit by the use of CE. For the future, together with accumulation of clinical studies, further development of CE such as smaller size of CE which is appropriate to small children, increased quality of images, option of biopsy, remote control are expected.

## 7. References

- Alkhoury, N.; Carter-Ken, C.; Mayacy, S.; Hupertz, V.; Eghtesad, B.; Quintini, C.; Fung, J. & Radhakrishnan, K. (2009). Reversal of protein-losing enteropathy after liver transplantation in a child with idiopathic familial neonatal hepatitis. *Liver Transplantation*. Vol.15, No.12, (Dec, 2009), pp.1894-1896, ISSN 1527-6465
- Aretz, S.; Koch, A.; Uhlhaas, S.; Friedl, W.; Propping, P.; von Schweinitz, D. & Pietsch, T. (2006). Should children at risk for familial adenomatous polyposis be screened for hepatoblastoma and children with apparently sporadic hepatoblastoma be screened for APC germline mutations? *Pediatric Blood Cancer*. Vol.47, No.6, (Nov, 2006), pp.811-818, ISSN 1545-5009
- Argüelles-Arias, F.; Caunedo, A.; Romero, J.; Sánchez, A.; Rodríguez-Téllez, M.; Pellicer, F.J.; Argüelles -Martín, F. & Herrerías, J.M. (2004). The value of capsule endoscopy in pediatric patients with a suspicion of Crohn's disease. *Endoscopy*. Vol.36, No.10, (Oct, 2004), pp.869-873, ISSN 0013-726X
- Atay, O.; Mahajan, L.; Kay, M.; Mohr, F.; Kaplan, B. & Wyllie, R. (2009). Risk of capsule endoscope retention in pediatric patients: a large single-center experience and review of the literature. *Journal of Pediatric Gastroenterology and Nutrition*. Vol.49, No. 2, (Aug 2009), pp.196-201, ISSN 0277-2166
- Banerjee, R.; Bhargav, P.; Reddy, P.; Gupta, R.; Lakhtakia, S.; Tandan, M.; Rao, V.G. & Reddy, N.D. (2007). Safety and efficacy of the M2A patency capsule for diagnosis of critical intestinal patency: results of a prospective clinical trial. *Journal of Gastroenterology and Hepatology*. Vol.22, No.12, (Dec, 2007), pp.2060-2063, ISSN 0815-9319
- Bardan, E.; Nadler, M.; Chowers, Y.; Fidler, H. & Bar-Meir, S. (2003). Capsule endoscopy for the evaluation of patients with chronic abdominal pain. *Endoscopy*. Vol.35, No.8, (Aug, 2003), pp.688-689, ISSN 0013-726X

- Barkin, J.S. & Friedman, S. (2002). Wireless capsule endoscopy requiring surgical intervention. The world's experience. *American Journal of Gastroenterology*. Vol.97, No.Supple 1, (2002), pp. S298, ISSN 0002-9270
- Barth, B.A.; Donovan, K. & Fox, V.L. (2004). Endoscopic placement of the capsule endoscope in children. *Gastrointestinal Endoscopy*. Vol.60, No. 5, (Nov, 2004), pp.818-821, ISSN 0016-5107
- Bizzarri, B.; Fornaroli, F.; Cannizzaro, R.; de' Angelis, N.; Vincenzi, F.; Maffini, V. & de' Angelis GL. (2005). Endoscopic placement of video capsule in a pediatric population. *Gastrointestinal Endoscopy*. Vol.62, No.6, (Dec, 2005), pp.991, ISSN 0016-5107
- Brown, G.; Fraser, C.; Schofield, G.; Taylor, S.; Bartram, C.; Phillips, R. & Saunders, B. (2006). Video capsule endoscopy in peutz-jeghers syndrome: a blinded comparison with barium follow-through for detection of small-bowel polyps. *Endoscopy*. Vol.38, No.4, (Apr, 2006), pp.385-90, ISSN 0013-726X
- Cave, D.; Legnami, P.; de Franchis, R. & Lewis, B.S. (2005). ICCE consensus for capsule retention. *Endoscopy*. Vol.37, No.10, (Oct, 2005), pp. 1065-1067, ISSN 0013-726X
- Cave, D.R. (2004). Reading wireless video capsule endoscopy. *Gastrointestinal Endoscopy Clinics of North America*. Vol.14, No.1, (Jan 2004), pp. 17-24, ISSN 1052-5157
- Cheifetz, A.S.; Kornbluth, A.A.; Legnani, P.; Schmelkin, I.; Brown, A.; Lichtiger, S. & Lewis, B.S. (2006). The risk of retention of the capsule endoscope in patients with known or suspected Crohn's disease. *The American Journal of Gastroenterology*. Vol.101, No.10, (Oct, 2006), pp.2218-2222, ISSN 0002-9270
- Cohen, S.A.; Gralnek, I.M.; Ephrath, H.; Saripkin, L.; Meyers, W.; Sherrod, O.; Napier, A. & Gobin, T. (2008). Capsule endoscopy may reclassify pediatric inflammatory bowel disease: a historical analysis. *Journal of Pediatric Gastroenterology and Nutrition*. Vol.47, No.1, (Jul, 2008), pp. 31-36, ISSN 0277-2166
- Culliford, A.; Daly, J.; Diamond, B.; Rubin, M. & Green, P.H. (2005). The value of wireless capsule endoscopy in patients with complicated celiac disease. *Gastrointestinal Endoscopy*. Vol.62, No.1, (Jul, 2005), pp.55-61, ISSN 0016-5107
- Dai, N.; Gubler, C.; Hengstler, P.; Meyenberger, C. & Bauerfeind, P. (2005). Improved capsule endoscopy after bowel preparation. *Gastrointestinal Endoscopy*. Vol.61, No. 1, (Jan 2005), pp.28-31, ISSN 0016-5107
- de' Angelis, G.L.; Fornaroli, F.; de' Angelis, N.; Magiteri, B. & Bizzarri, B. (2007). Wireless capsule endoscopy for pediatric small-bowel diseases. *The American Journal of Gastroenterology*. Vol.102, No.8, (Aug 2007) pp.1749-1757, ISSN 0002-9270
- De Bona, M.; Bellumat, A.; Cian, E.; Valiante, F.; Moschini, A. & De Boni, M. (2006). Capsule endoscopy findings in patients with suspected Crohn's disease and biochemical markers of inflammation. *Digestive and Liver Disease*. Vol.38, No.5, (May, 2006), pp.331-335, ISSN 1590-8658
- Dionisio, P.M.; Gurudu, S.R.; Leighton, J.A.; Leontiadis, G.I.; Fleischer, D.E.; Hara, A.K.; Heigh, R.I.; Shiff, A.D. & Sharma, V.K. (2010). Capsule Endoscopy Has a Significantly Higher Diagnostic Yield in Patients With Suspected and Established Small-Bowel Crohn's Disease: A Meta-Analysis. *The American Journal of Gastroenterology*. Vol.106, No.6, (Jun 2010), pp.1240-1248, ISSN 0002-9270
- Eliakim, R.; Yassin, K.; Shlomi, I.; Suissa, A. & Eisen, G.M. (2004). A novel diagnostic tool for detecting oesophageal pathology: the PillCam oesophageal video capsule.

- Alimentary pharmacology & therapeutics*. Vol.20, No.10, (Nov, 2004), pp.1083-1089, ISSN 0269-2813
- Eroglu, Y.; Emerick, K.M.; Chou, P.M. & Reynolds, M. (2002). Gastrointestinal bleeding in Turner's syndrome: a case report and literature review. *Journal of Pediatric Gastroenterology and Nutrition*. Vol.35, No.1, (Jul, 2002), pp. 84-87, ISSN 0277-2166
- Fireman, Z.; Mahajna, E.; Broide, E.; Shapiro, M.; Fich, L.; Sternberg, A.; Kopelman, Y. & Scapa, E. (2003). Diagnosing small bowel Crohn's disease with wireless capsule endoscopy. *Gut*. Vol.52, No.3, (Mar, 2003), pp.390-392, ISSN 0017-5749
- Franke, A.; Hummel, F.; Knebel, P.; Antoni, C.; Bocker, U.; Singer, M.V. & Lohr, M. (2008). Prospective evaluation of small bowel preparation with bisacodyl and sodium phosphate for capsule endoscopy. *World Journal of Gastroenterology*. Vol.14, No.13, (Apr 2008), pp.2061-2064, ISSN 1007-9327
- Fritscher-Ravens, A.; Scherbakov, P.; Bufler, P.; Torroni, F.; Ruuska, T.; Nuutinen, H.; Thomson, M.; Tabbers, M. & Milla, P. (2009). The feasibility of wireless capsule endoscopy in detecting small intestinal pathology in children under the age of 8 years: a multicentre European study. *Gut*. Vol.58, No.11, (Jul 2009), pp.1467-172, ISSN 0017-5749
- Gay, G.; Delvaux, M.; Laurent, V.; Reibel, N.; Regent, D.; Grosdidier, G. & Roche, J.F. (2005). Temporary intestinal occlusion induced by a "patency capsule" in a patient with Crohn's disease. *Endoscopy*. Vol.37, No.2, (Feb, 2005), pp.174-177, ISSN 0013-726X
- Ge, Z.Z.; Chen, H.Y.; Gao, Y.J.; Gu, J.L.; Hu, Y.B. & Xiao, S.D. (2007a). Clinical application of wireless capsule endoscopy in pediatric patients for suspected small bowel diseases. *European Journal of Pediatrics*. Vol.166, No. 8, (Aug, 2007), pp. 825-829, ISSN 0340-6199
- Giardiello, F.M. & Trimbath, J.D. (2006). Peutz-Jeghers syndrome and management recommendations. *Clinical Gastroenterology and Hepatology*. Vol.4, No.4, (Apr, 2006), pp.408-415, ISSN 1542-3565
- Guilhon de Araujo Sant'Anna, A.M.; Dubois, J.; Miron, M.C. & Seidman, E.G. (2005). Wireless capsule endoscopy for obscure small-bowel disorders: final results of the first pediatric controlled trial. *Clinical Gastroenterology and Hepatology*. Vol.3, No.3, (Mar 2005), pp.264-270. ISSN 1542-3565
- Hadithi, M.; Heine, G.D.; Jacobs, M.A.; van Bodegraven, A.A. & Mulder, C.J. (2006). A prospective study comparing video capsule endoscopy with double-balloon enteroscopy in patients with obscure gastrointestinal bleeding. *The American Journal of Gastroenterology*. Vol.101, No.1, (Jan 2006), pp.52-57, ISSN 0002-9270
- Hinds, R.; Philp, C.; Hyer, W. & Fell, J.M. (2004). Complications of childhood Peutz-Jeghers syndrome: implications for pediatric screening. *Journal of Pediatric Gastroenterology and Nutrition*. Vol.39, No.2, (Aug, 2004), pp. 219-220, ISSN 0277-2166
- Hyer W, Beveridge I, Domizio P, Phillips R. (2000) Clinical management and genetics of gastrointestinal polyps in children. *Journal of Pediatric Gastroenterology and Nutrition*. Vol.31, No.5, (Nov, 2000), pp.469-479, ISSN 0277-2166
- Iddan, G.; Meron, G.; Glukhovsky, A. & Swain, P. (2000). Wireless capsule endoscopy. *Nature*. Vol.405, No.6785, (May 2000), pp. 417, ISSN 0028-0836
- Katz, S.; Borst, M.; Seekri, I. & Grosfeld, J. (1991). Surgical evaluation of Henoch-Schonlein purpura: experience with 110 children. *Arch Surg*. Vol.126, No. 7, (Jul, 1991), pp. 849-854, ISSN 0272-5533

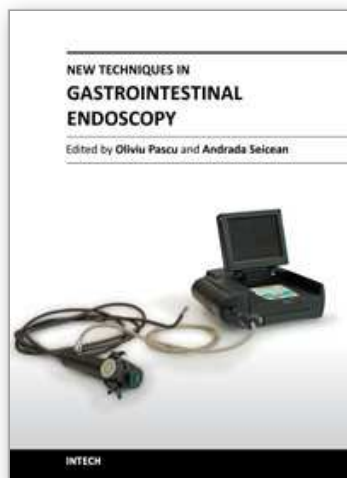
- Kramer, R.E.; Brumbaugh, D.E.; Soden, J.S.; Capocelli, K.E. & Hoffenberg, E.J. (2009). First successful antegrade single-balloon enteroscopy in a 3-year-old with occult GI bleeding. *Gastrointestinal Endoscopy*. Vol.70, No.3, (Sep 2009), pp.546-549, ISSN 0016-5107
- Leung, Y.K. (2007). Double balloon endoscopy in pediatric patients. *Gastrointestinal Endoscopy*. Vol.66, No.3 suppl, (Sep 2007), pp.S54-S56, ISSN 0016-5107
- Lewis, B. (2005). How to prevent endoscopic capsule retention. *Endoscopy*. Vol.37, No.9, (Sep, 2005), pp. 852-856., ISSN 0013-726X
- May, A.; Manner, H.; Schneider, M.; Ipsen, A. & Ell, C. (2007). Prospective multicenter trial of capsule endoscopy in patients with chronic abdominal pain, diarrhea and other signs and symptoms (CEDAP-Plus Study). *Endoscopy*. Vol.397, No.7, (Jul, 2007), pp. 606-612, ISSN 0013-726X
- Moy, L. & Levine, J. (2009). Capsule endoscopy in the evaluation of patients with unexplained growth failure. *Journal of Pediatric Gastroenterology and Nutrition*. Vol.48, No.5, (May 2009), pp.647-650, ISSN 0277-2166
- Nakamura, M.; Niwa, Y.; Ohmiya, N.; Miyahara, R.; Ohashi, A.; Itoh, A.; Hirooka, Y. & Goto, H. (2006). Preliminary comparison of capsule endoscopy and double-balloon enteroscopy in patients with suspected small-bowel bleeding. *Endoscopy*. Vol.38, No.1, (Jan 2006), pp.59-66, ISSN 0013-726X
- Nakamura, T. & Terano, A. (2008). Capsule endoscopy: past, present, and future. *Journal of Gastroenterology*. Vol.43, No.2, (Feb 2008), pp. 93-99, ISSN 0944-1174
- Nishimura, N.; Yamamoto, H.; Yano, T.; Hayashi, Y.; Arashiro, M.; Miyata, T.; Sunada, K. & Sugano, K. (2010). Safety and efficacy of double-balloon enteroscopy in pediatric patients. *Gastrointestinal Endoscopy*. Vol.71, No.2, (Feb, 2010), pp.287-294, ISSN 0016-5107
- Niv, Y.; Niv, G.; Wiser, K. & Demarco, D.C. (2005). Capsule endoscopy - comparison of two strategies of bowel preparation. *Alimentary Pharmacology and Therapeutics*. Vol.20, No.10, (Nov 2005), pp.957-962, ISSN 1365-2036
- Nudell, J. & Brady, P. (2006). A case of GI hemorrhage in a patient with Turner's syndrome: diagnosis by capsule endoscopy. *Gastrointestinal Endoscopy*. Vol.63, No.3, (Mar, 2006), pp.514-516, ISSN 0016-5107
- Orendain, L.; Rhee, C.; Fiore, N.; Kogut, K. & Baron, H. (2005). Diagnostic use of video capsule endoscopy in a toddler with occult gastrointestinal bleeding. *Journal of Pediatric Gastroenterology and Nutrition*. Vol.50, No.2 (Feb, 2005), pp.227-229, ISSN 0277-2166
- Parikh, D.A.; Parikh, J.A.; Albers, G.C. & Chandler, C.F. (2009). Acute small bowel perforation after wireless capsule endoscopy in a patient with Crohn's disease: a case report. *Cases Journal*. Vol.31, No.2, (Jul, 2009), pp.7607, ISSN 1757-1626
- Pinho, R.; Rodrigues, A.; Proença, L.; Silva, A.P.; Fernandes, S.; Leite, S.; Amaral, I.; de Sousa, P. & Fraga, J. (2008). Solitary hemangioma of the small bowel disclosed by wireless capsule endoscopy. *Gastroentérologie clinique et biologique*. Vol.31, No.1, (Jan, 2008), pp. 15-18, ISSN 0399-8320
- Postgate, A.; Hyer, W.; Phillips, R.; Gupta, A.; Burling, D.; Bartram, C.; Marshall, M.; Taylor, S.; Brown, G.; Schofield, G.; Bassett, P.; Spray, C.; Fitzpatrick, A.; Fraser, C. & Latchford, A. (2009). Feasibility of video capsule endoscopy in the management of children with peutz-jeghers syndrome: a blinded comparison with barium



- enterography for the detection of small bowel polyps. *Journal of Pediatric Gastroenterology and Nutrition*. Vol.49, No.4, (Oct 2009), pp.417-423, ISSN 0277-2166
- Preud'Homme, D.L.; Michail, S.; Hodges, C.; Milliken, T. & Mezoff, A.G. (2006). Use of wireless capsule endoscopy in the management of severe Henoch-Schonlein purpura. *Pediatrics*. Vol.118, No.3, (Sep, 2006), pp.e904-906, ISSN 1098-4275
- Rondonotti, E.; Soncini, M.; Girelli, C.; Ballardini, G.; Bianchi, G.; Brunati, S.; Centenara, L.; Cesari, P.; Cortelezzi, C.; Curioni, S.; Gozzini, C.; Gullotta, R.; Lazzaroni, M.; Maino, M.; Mandelli, G.; Mantovani, N.; Morandi, E.; Pansoni, C.; Piubello, W.; Putignano, R.; Schalling, R.; Tatarella, M.; Villa, F.; Vitagliano, P.; Russo, A.; Conte, D.; Masci, E.; de, Franchis, R.; on behalf of AIGO, SIED and SIGE Lombardia. (2010). Small bowel capsule endoscopy in clinical practice: a multicenter 7-year survey. *European Journal of Gastroenterology and Hepatology*. Vol.22, No.11, (Nov, 2010), pp.1380-1386, ISSN 0954-691X
- Saurin, J.C. (2007). Capsule endoscopy. *Endoscopy*. Vol.39, No.11, (Nov, 2007), pp.986-991, ISSN 0013-726X
- Schulmann, K.; Hollerbach, S.; Kraus, K.; Willert, J.; Vogel, T.; Möslin, G.; Pox, C.; Reiser, M.; Reinacher-Schick, A. & Schmiegel, W. (2005) Feasibility and diagnostic utility of video capsule endoscopy for the detection of small bowel polyps in patients with hereditary polyposis syndromes. *American Journal of Gastroenterology*. Vol.100, No.1, (Jan, 2005), pp.27-37, ISSN 0002-9270
- Sears, D.M.; Avots-Avotins, A.; Culp, K. & Gavin, M.W. (2004). Frequency and clinical outcome of capsule retention during capsule endoscopy for GI bleeding of obscure origin. *Gastrointest inal Endoscopy*. Vol.60, No.5, (Nov, 2004), pp.822-827, ISSN 0016-5107
- Seidman, EG. (2002). Wireless capsule video-endoscopy: an odyssey beyond the end of the scope. *Journal of Pediatric Gastroenterology and Nutrition*. Vol.34, No.4, (Apr 2002), pp.333-334, ISSN 0277-2166
- Shamir, R.; Hino, B.; Hartman, C.; Berkowitz, D.; Eshach-Adiv, O. & Eliakim, R. (2007) Wireless video capsule in pediatric patients with functional abdominal pain. *Journal of Pediatric Gastroenterology and Nutrition*. Vol.44, No.1, (Jan, 2007), pp.45-50, ISSN 0277-2166
- Silbermintz, A.; Sahdev, I.; Moy, L.; Vlachos, A.; Lipton, J. & Levine, J. (2006). Capsule endoscopy as a diagnostic tool in the evaluation of graft-vs.-host disease. *Pediatric Transplantation*. Vol.10, No.2, (Mar, 2006), pp. 252-254, ISSN 1397-3142
- Sriram, P.V.; Rao, G.V. & Reddy, D.N. (2004). Wireless capsule endoscopy: experience in a tropical country. *Journal of Gastroenterology and Hepatology*. Vol.19, No.1, (Jan, 2004), pp. 63-67, ISSN 1440-1746
- Spada, C.; Pirozzi, G.A.; Riccioni, M.E.; Iacopini, F.; Marchese, M. & Costamagna, G. (2006). Capsule endoscopy in patients with chronic abdominal pain. *Digestive and Liver Disease*. Vol.38, No.9, (Sep, 2006), pp.696-698, ISSN 1590-8658
- Stiffler, H.L. (2003). Capsule endoscopy: a case study of an 11-year-old girl. *Gastroenterology Nursing*. Vol.26, No.1, (Jan, 2003), pp. 38-40, ISSN 1042-895X
- Thomson, M.; Fritscher-Ravens, A.; Mylonaki, M.; Swain, P.; Eltumi, M.; Heuschkel, R.; Murch, S.; McAlindon, M. & Furman, M. (2007). Wireless capsule endoscopy in children: a study to assess diagnostic yield in small bowel disease in paediatric



- patients. *Journal of Pediatric Gastroenterology and Nutrition*. Vol.44, No.2, (Feb 2007), pp.192-197, ISSN 0277-2166
- Thomson, M.; Venkatesh, K.; Elmalik, K.; van der Veer, W. & Jacobs, M. (2010). Double balloon enteroscopy in children: diagnosis, treatment, and safety. *World Journal of Gastroenterology*. Vol.16, No.1, (Jan 2010), pp.56-62, ISSN 1007-9327
- Tokuhara, D.; Okano, Y.; Asou, K.; Tamamori, A. & Yamano, T. (2007). Cytomegalovirus and *Helicobacter pylori* co-infection in a child with Ménétrier disease. *European Journal of Pediatrics*. Vol.166, No.1, (Jan, 2007), pp.63-65, ISSN 0340-6199
- Tokuhara, D.; Watanabe, K.; Okano, Y.; Tada, A.; Yamato, K.; Mochizuki, T.; Takaya, J.; Yamano, T. & Arakawa, T. (2010). Wireless capsule endoscopy in pediatric patients: the first series from Japan. *Journal of Gastroenterology*. Vol.45, No.7, (Feb 2010), pp.683-691, ISSN 0944-1174
- van Lier, M.G.; Wagner, A.; Mathus-Vliegen, E.M.; Kuipers, E.J.; Steyerberg, E.W. & van Leerdam, M.E. (2010). High Cancer Risk in Peutz-Jeghers Syndrome: A Systematic Review and Surveillance Recommendations. *American Journal of Gastroenterology*. Vol.105, No.6, (Jun, 2010), pp.1258-1264, ISSN 0002-9270
- Viazis, N.; Sgouros, S.; Papaxoinis, K.; Vlachogiannakos, J.; Bergele, C.; Sklavos, P.; Panani, A. & Avgerinos, A. (2004). Bowel preparation increases the diagnostic yield of capsule endoscopy: a prospective, randomized, controlled study. *Gastrointestinal Endoscopy*. Vol.60, No.4, (Oct 2004), pp.534-538, ISSN 0016-5107
- Wei, W.; Ge, Z.Z.; Lu, H.; Gao, Y.J.; Hu, Y.B. & Xiao, S.D. (2007). Effect of mosapride on gastrointestinal transit time and diagnostic yield of capsule endoscopy. *Journal of Gastroenterology and Hepatology*. Vol.22, No.10, (Oct 2007), pp.1605-1608, ISSN 1440-1746
- Yamamoto, H.; Sekine, Y.; Sato, Y.; Higashizawa, T.; Miyata, T.; Iino, S.; Ido, K. & Sugano, K. (2001). Total enteroscopy with a nonsurgical steerable double-balloon method. *Gastrointestinal Endoscopy*. Vol.53, No.2, (Feb 2001), pp.216-220, ISSN 0016-5107
- Yakoub-Agha, I.; Maunoury, V.; Wacrenier, A.; Couignoux, S.; Depil, S.; Desreumaux, P.; Bauters, F.; Colombel, J.F. & Jouet, J.P. (2004). Impact of Small Bowel Exploration Using Video-Capsule Endoscopy in the Management of Acute Gastrointestinal Graft-versus-Host Disease. *Transplantation*. Vol.78, No.11, (Dec, 2004), pp.1697-1701, ISSN 0041-1337



## **New Techniques in Gastrointestinal Endoscopy**

Edited by Prof. Oliviu Pascu

ISBN 978-953-307-777-2

Hard cover, 310 pages

**Publisher** InTech

**Published online** 30, September, 2011

**Published in print edition** September, 2011

As result of progress, endoscopy has became more complex, using more sophisticated devices and has claimed a special form. In this moment, the gastroenterologist performing endoscopy has to be an expert in macroscopic view of the lesions in the gut, with good skills for using standard endoscopes, with good experience in ultrasound (for performing endoscopic ultrasound), with pathology experience for confocal examination. It is compulsory to get experience and to have patience and attention for the follow-up of thousands of images transmitted during capsule endoscopy or to have knowledge in physics necessary for autofluorescence imaging endoscopy. Therefore, the idea of an endoscopist has changed. Examinations mentioned need a special formation, a superior level of instruction, accessible to those who have already gained enough experience in basic diagnostic endoscopy. This is the reason for what these new issues of endoscopy are presented in this book of New techniques in Gastrointestinal Endoscopy.

### **How to reference**

In order to correctly reference this scholarly work, feel free to copy and paste the following:

Daisuke Tokuhara (2011). Wireless Capsule Endoscopy in Pediatric Gastrointestinal Diseases, New Techniques in Gastrointestinal Endoscopy, Prof. Oliviu Pascu (Ed.), ISBN: 978-953-307-777-2, InTech, Available from: <http://www.intechopen.com/books/new-techniques-in-gastrointestinal-endoscopy/wireless-capsule-endoscopy-in-pediatric-gastrointestinal-diseases>

**INTECH**  
open science | open minds

### **InTech Europe**

University Campus STeP Ri  
Slavka Krautzeka 83/A  
51000 Rijeka, Croatia  
Phone: +385 (51) 770 447  
Fax: +385 (51) 686 166  
[www.intechopen.com](http://www.intechopen.com)

### **InTech China**

Unit 405, Office Block, Hotel Equatorial Shanghai  
No.65, Yan An Road (West), Shanghai, 200040, China  
中国上海市延安西路65号上海国际贵都大饭店办公楼405单元  
Phone: +86-21-62489820  
Fax: +86-21-62489821

© 2011 The Author(s). Licensee IntechOpen. This chapter is distributed under the terms of the [Creative Commons Attribution-NonCommercial-ShareAlike-3.0 License](https://creativecommons.org/licenses/by-nc-sa/3.0/), which permits use, distribution and reproduction for non-commercial purposes, provided the original is properly cited and derivative works building on this content are distributed under the same license.

IntechOpen

IntechOpen