

We are IntechOpen, the world's leading publisher of Open Access books Built by scientists, for scientists

6,900

Open access books available

186,000

International authors and editors

200M

Downloads

Our authors are among the

154

Countries delivered to

TOP 1%

most cited scientists

12.2%

Contributors from top 500 universities



WEB OF SCIENCE™

Selection of our books indexed in the Book Citation Index
in Web of Science™ Core Collection (BKCI)

Interested in publishing with us?
Contact book.department@intechopen.com

Numbers displayed above are based on latest data collected.
For more information visit www.intechopen.com



EMR and ESD for Gastrointestinal Neoplasms

Keiichiro Kume

*K's device; Laboratory for Endoscopy, Third Department of Internal Medicine,
School of Medicine, University of Occupational and Environmental Health,
Japan*

1. Introduction

Surgery is the accepted standard treatment of early gastrointestinal cancer, defined as cancer with involvement confined to the mucosa or submucosa, regardless of the size or the presence of regional lymph-node metastases. However, recent progress in endoscopic technique has made it possible to treat gastrointestinal neoplasm. For example, early gastric cancer confined to the mucosa can be treated successfully with endoscopic resection alone. Endoscopic resection of early gastric cancer originated with the development of a polypectomy technique using high-frequency current for gastric polyps in 1968 (Niwa 1968), and has become popular as endoscopic mucosal resection (EMR) since the birth of the strip biopsy method in 1984 (Tada et al. 1984). Endoscopic submucosal dissection (ESD) is a new endoscopic technique using cutting devices that developed from one of the EMR techniques, namely endoscopic resection after local injection of a solution of hypertonic saline-epinephrine (Hirano et al. 1988). EMR has recently been replaced by endoscopic submucosal dissection (ESD), because en bloc resection of specimens >20 mm in diameter is difficult to achieve with EMR, and piecemeal resection is associated with increased rates of local recurrence to about 15% (Muto et al. 2005, Oka et al. 2006). The technique of ESD was introduced to resect large specimens of early gastric cancer in a single piece. But, the question remains as to whether ESD is superior to EMR in all regards. This chapter provides an overview of EMR and ESD.

2. Indication for EMR and ESD

2.1 Esophagus

Epithelial cancer (m1) and proper mucosal cancer (m2) are not associated with lymph-node metastasis. Cancer invading into the muscularis mucosae (m3) and to the upper third of the submucosal layer (sm1) are associated with lymph-node metastases in 10-15% of cases. However, when the cancer invades more deeply into the submucosal layer (sm2-sm3), lymph-node metastasis is present in 40-50% of cases. Cases of m1-m2 cancer are therefore absolute indications for EMR and ESD and cases of m3-sm1 cancer are relative indications (Makuuchi. 1996, Oyama et al. 2005).

2.2 Stomach

The indication for EMR is considered as intestinal well differentiated mucosal cancer without ulcer and less than 20 mm in diameter, because en bloc resection of specimens >20

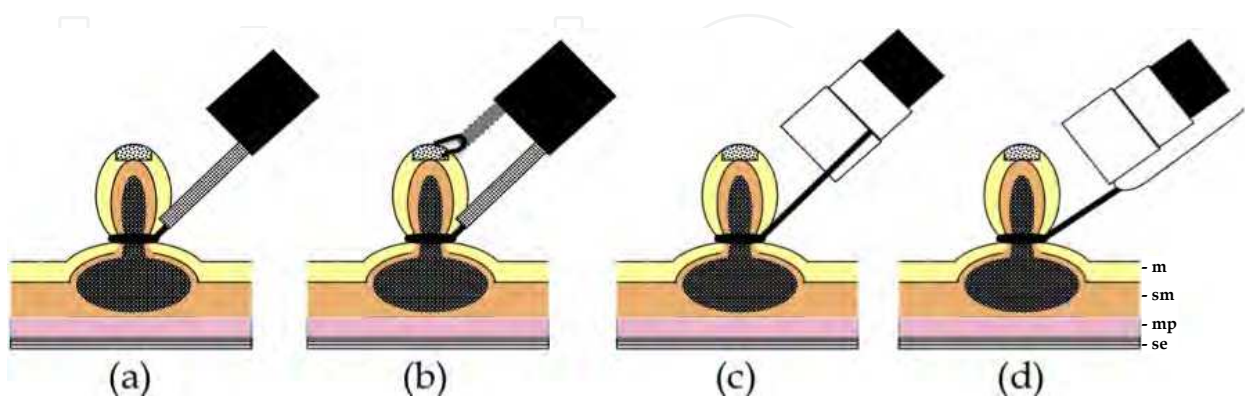
mm in diameter is difficult to achieve with EMR. On the other hands, in the stomach no lymph-node metastasis were seen in large series of patients with intestinal well differentiated mucosal cancer without ulcer and no size limit, with ulcer with size less than 30 mm, and in patients with submucosal cancer limited to sm1 infiltration (<500 μ m deep in the submucosa starting from the muscularis mucosae) and less than 30 mm in diameter (Gotoda. 2007). Therefore, the indication for ESD is considered as above.

2.3 Colon

From the large numbers of surgically resected colorectal cases, intramucosal carcinomas and those with sm1 infiltration (< 1000 μ m deep in the submucosa starting from the muscularis mucosae) without lymphovascular infiltration have little risk of nodal metastasis (Kitajima et al. 2004). Tumor morphology and surface pit pattern are good endoscopic indicators for submucosal invasion. From this aspect, depressed lesions, laterally spreading tumors of non-granular type (LST-NG) and large protruding tumors are considered as good candidates for ESD because these lesions have a high risk of submucosal invasion, which may be difficult to diagnose preoperatively, and a thorough histopathological assessment of the resected specimen is essential. It is controversial whether one should perform ESD or piecemeal EMR for laterally spreading tumors of granular type (LST-G), because most lesions are intramucosal and the endoscopic prediction of invasiveness is highly feasible (Uraoka et al. 2006).

3. EMR

Various devices and techniques of EMR have been described. EMR is classified into techniques without an aspiration cap and techniques with an aspiration cap (Soetikno et al. 2003). Strip biopsy methods using a single-channel scope or double-channel scope are included as techniques without an aspiration cap. Cap-assisted endoscopic mucosal resection (EMRC), endoscopic aspiration mucosectomy (EAM), endoscopic mucosal resection with ligation (EMRL), and others are included as techniques with an aspiration cap.



m:mucosa, sm: submucosa, mp: muscularis propria, se:serosa.

Fig. 1. Four types of commonly used EMR techniques: (a) Strip biopsy method using a single-channel scope, (b) Strip biopsy method using a double-channel scope, (c) Cap-assisted endoscopic mucosal resection (EMRC), (d) endoscopic aspiration mucosectomy (EAM).

3.1 Standard EMR: Strip biopsy method using a single-channel scope

The lesion is raised off the muscularis propia by the creation of a submucosal bleb, strangulated by a snare, and resected using an electrosurgical snare (Tada et al. 1984, 1993).

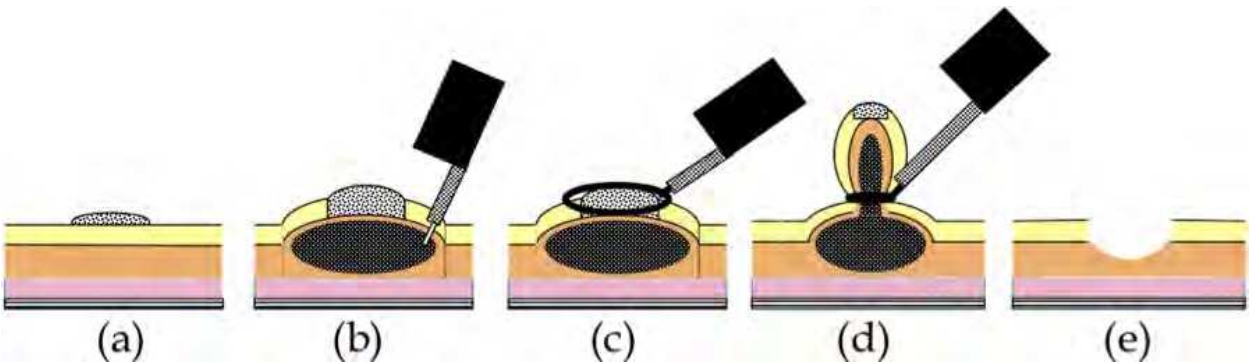


Fig. 2. Technique of strip biopsy method: (a) The lesion is examined carefully and the border is defined. Electrocoagulation is used to mark the border of the lesion. (b) The submucosa is injected with saline solution with a sclerotherapy needle. The lesion must lift during and after injection before attempting resection. (c) The snare loop is placed at the base of the lesion. (d) The snare is closed. If the snare appears to entrap the muscularis propria, maneuvers to release the muscle are performed before the lesion is cut with blended current. (e) The specimen is removed.

3.2 Strip biopsy method using a double-channel scope

Submucosal injection is performed in standard fashion. Both the snare and grasping forceps are advanced through the channels. In preparation for EMR, the snare is opened to capture the forceps, then closed snugly. The lesion is grasped by the forceps and pulled gently into the now-opened snare. The snare is then closed and the lesion is resected (Tada et al. 1993, Takekoshi et al. 1994, Karita et al. 1992).



Fig. 3. A double-channel scope

3.3 EMRC

EMRC has methods using a standard cap and my original devices.

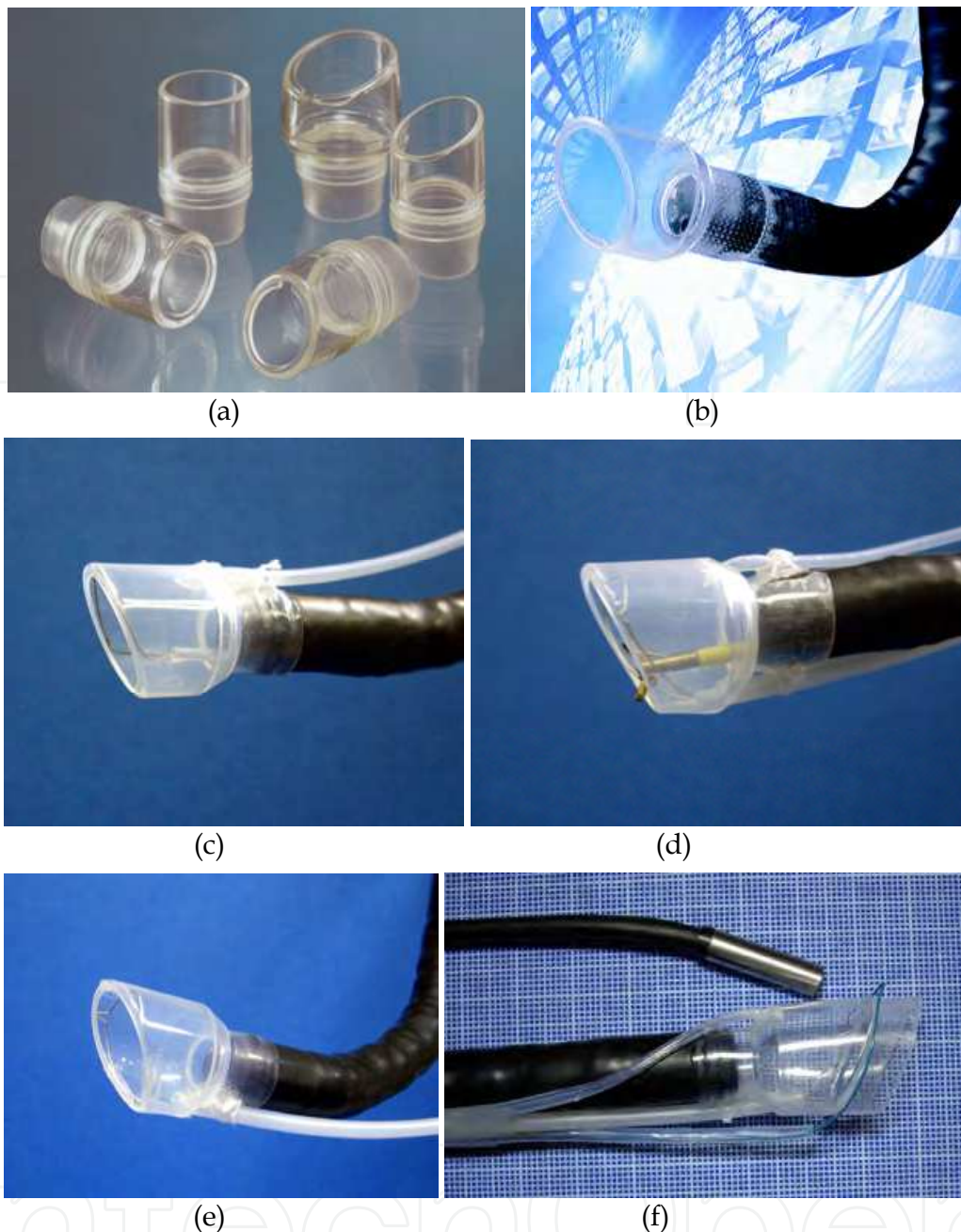


Fig. 4. EMRC device: (a) Transparent plastic cap, (b) Soft 18-mm diameter cap, (c) EMRC-UI cap, (d) 2-channel prelooped cap, (e) IRS cap, (f) EMRC-C device; (c)-(f):Each devices placed at the top of the scope.

3.3.1 EMRC (standard)

EMRC is a simpler and easier refinement of EMR methods (Takeshita et al. 1993). The technique requires a specialized transparent plastic cap that is fitted to the tip of the endoscope. Different-sized caps are available, according to the diameter of the endoscope (MH-594 MAJ-290 etc. Olympus, Japan). In addition, a soft 18-mm diameter cap designed for en bloc resection of larger lesions is available (D-206, Olympus, Japan). Matsuzaki et al. (2003) used this soft cap for resection of gastric lesions 1.4-times larger than specimens that could be removed by the conventional cap.

After marking the periphery of the lesion, submucosal solution (saline, glucose, Glyceol®, etc.) is injected into the submucosa. The crescent-shaped snare (SD-221L-25 or SD-7P-1; Olympus, Japan) is then prelooped into the groove of the rim of the cap. The endoscopist performs this prelooping by lightly pressing against and suctioning normal mucosa to seal the cap outlet. The snare is opened and forced to rest along the inside groove of the rim of the cap to form the loop. Suction is released and the cap is then used to suck the lesion with medium to high vacuum into the cap. After the endoscopist strangulates the lesion by closing the snare, the suction is again released. After the lesion looks similar to a snared polypoid lesion, blend electrosurgical current is typically used to resect the lesion.

3.3.2 EMRC-UI (EMRC under irrigation)

One problem with the EMRC method is that the lesion cannot always be kept in the center of the cap, because the procedure is performed in a blind manner after aspiration. The usefulness of a novel end-hood that facilitates endoscopic hemostatic procedures while simultaneously allowing irrigation of the bleeding site was improved by the author (Kume et al. 2003, 2004, 2005), resulting in a soft, prelooped cap with attached irrigation tube (Kume et al. 2004).

The aspiration method of EMRC-UI method is similar to EMRC. Aspiration is applied repeatedly until the lesion is stabilized in the center of the hood. If the field of view is compromised because of the presence of mucus and/or blood, the site is irrigated. After strangulating the lesion by closing the snare, the negative aspiration pressure is released.

EMR-UI was performed in 15 patients. Mean diameter of specimens was 24.5 mm (interquartile range, 15-35 mm). The proportion of en bloc-resected lesions was 86.7% (13/15). The median time required for EMR-UI was 19 min.

3.3.3 Grasping forceps-assisted EMRC using a 2-channel prelooped cap

Next, the author improved the EMRC-UI cap. Two side holes were fabricated by drilling in the hood portion of a conventional soft prelooped cap, and then the irrigation tube and the accessory channel tube were glued to the exterior surface of the holes. The author developed a 2-channel prelooped cap that facilitates EMRC while simultaneously allowing both grip of the central position of the lesion and irrigation of the aspiration site (Kume et al. 2006).

The aspiration method of grasping forceps-assisted EMRC using a 2-channel prelooped cap method is similar to EMRC. The endoscopist releases the negative aspiration pressure while slowly pulling the regular biopsy forceps gripping the center of the lesion. Until the lesion is stabilized in the center of the hood, the endoscopist repeatedly performs grasp and aspiration of the lesion. If the field of view at the aspiration site is poor as a result of contamination by mucus and blood, the endoscopist repeatedly performs irrigation of the site. After strangulating the lesion by closing the snare, the endoscopist again releases the aspiration.

Grasping forceps-assisted EMRC using a 2-channel prelooped cap was performed in 12 patients. Mean diameter of specimens was 22.3 mm (interquartile range, 15-31 mm). The rate of en bloc resection was 91.7% (11/12). Median time required for the procedure was 19 min.

3.3.4 EMRC using IRS (internally retained snare) cap

In EMRC, the crescent-shaped snare needs to be prelooped into the groove of the rim of the cap during the procedure itself. As this prelooping can be initially difficult, the author has

avoided this step by developing a new type of prelooped cap, the “internally retained snare” (IRS) cap that makes prelooping unnecessary (Kume et al. 2008). After adapting the IRS cap to the tip of the endoscope, EMRC using the IRS cap method is similar to EMRC. The endoscopist releases the negative aspiration pressure and the cap is then placed to aspirate the lesion with medium to high vacuum into the hood. The endoscopist again releases the aspiration, after strangulating the lesion by closing the snare. EMRC using an IRS cap was performed in 27 patients. Mean diameter of specimens was 27.6 mm (interquartile range, 15-38 mm). The rate of en bloc resection was 88.9% (24/27). Median time required for EMRC using IRS cap was 16 min.

3.3.5 EMRC-C (EMRC and closure)

This device has not yet been used in human patients. Delayed bleeding may occur from a gastric ulcer after EMRC. Solving this problem may allow surgery on an outpatient basis. The author therefore developed a novel EMRC and closure (EMRC-C) cap that facilitates the EAM procedure, simultaneously allowing endoscopic closure (Kume et al. 2007). The EMRC-C hood was produced by attaching an additional hood of short length and another accessory channel to the top of the 2-channel prelooped cap. Two types of snares are then set. The crescent-shaped snare (SD-221L-25; Olympus) is inserted through the accessory channel tube of the first part of the hood, and prelooped into the groove of the rim of the hood. The detained snare (HX-20L-1; Olympus) is passed through and tightened around the outer circumference of the second part of the hood. The endoscopist places the EMRC-C hood at the tip of the endoscope. Aspiration is released and the hood is then used to aspirate the lesion by high-power vacuum into the hood. The endoscopist confirms aspiration of the lesion with the outside CCD camera, then snares the lesion using the detained and crescent-shaped snares. The endoscopist uses the former to tightly strangle the lesion, and resects the lesion using blend electrosurgical current closing the latter snare.

3.4 EAM

EAM has methods using a standard device and my original device.

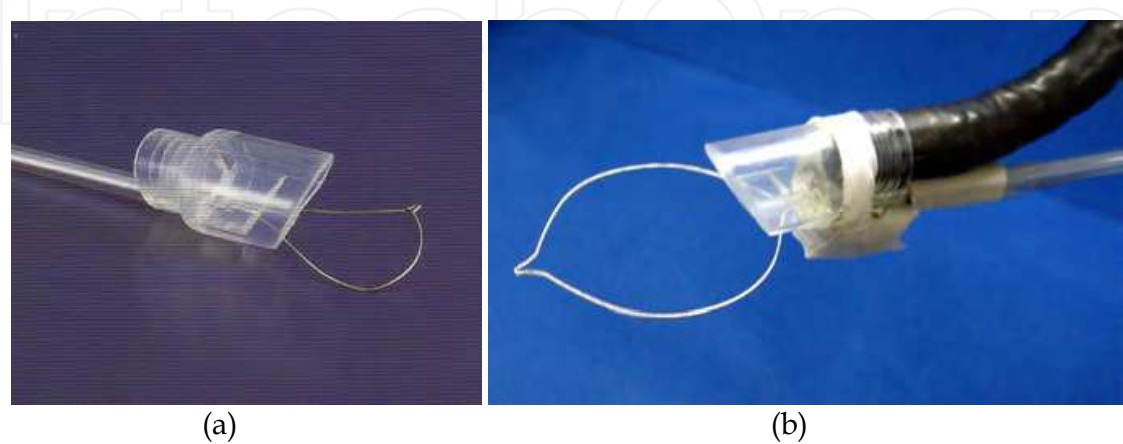


Fig. 5. EAM device: (a) Conventional EAM hood, (b) EAM-V device placed at the top of the scope.

3.4.1 EAM (standard)

The EAM hood uses a conventional hood (Create Medic, Yokohama, Japan, and TOP, Tokyo, Japan). In this device, a snare is passed through an outside channel and tightened around the outer circumference of the hood (Katayama et al. 2006, Torii et al. 1995). Prelooping during the EAM procedure is thus unnecessary.

As a method to adapt EAM with a snare on the tip of the endoscope, the EAM hood method is similar to EMRC. The endoscopist releases the negative aspiration pressure and the hood is then placed to aspirate the lesion with medium to high vacuum into the hood. The snare is pushed over the tumor while the lesion is aspirated. In addition, the loop is pushed tightly around the specimen. The endoscopist again releases the aspiration, after strangulating the lesion by closing the snare.

3.4.2 EAM-V (EAM with vibration)

This device has not yet been used in patients.

EAM carries a risk of aspirating and perforating the full thickness of the gastric wall. A novel vibration hood to reduce such risks was thus developed (Kume et al. 2009). A novel vibration hood enables strangulation and resection of only the mucosal and submucosal layers by vibrating the snare during strangulation to shake off the muscle layer and serous membrane.

Investigations were conducted separately with and without vibration at 10,000 rpm applied at the time of strangulation and resection. Perforation rates were lower in the vibration group (0/9: 0%) than in the group without vibration (2/9: 22.2%).

3.5 EEMR (Endoscopic esophageal mucosal resection)

With EEMR tube (Create Medic, Yokohama, Japan) method, the largest enbloc resection that can be carried out is when the esophageal lesion is less than 3 cm in diameter (Makuuchi et al. 2004). EEMR tube method is similar to EAM.



Fig. 6. EEMR tube

3.6 EMR-L (EMR with ligation)

The technique of EMR with ligation (EMR-L) uses a standard endoscopic variceal ligation device fitted to a single-channel endoscope (Suzuki et al. 1999). The maximum lesion size for

en bloc resection is 1.5 cm. Larger lesions may require piecemeal resection. This technique has been reported with or without prior submucosal injection. The lesion is snared by standard snare polypectomy after it has been ligated at its base with an endoscopic variceal ligation device.

3.7 Multi-camera system using a novel 1-channel camera-hood

This device has not yet been used in patients.

Precise snaring during EMR is important to achieve en bloc resection. However, this can be difficult to achieve in practice, because snaring cannot be performed under complete observation. Although we can easily observe the proximal side of the lifting lesion, the distal side is hard to see after injection of saline solution into the submucosa. The author therefore developed a novel 1-channel camera-hood that allows observation of the distal side of the lesion during snaring in the EMR procedure (Kume et al. 2007). The 1-channel camera-hood was fabricated by cutting the partial hood in a “U-shape” in the cap portion of the hood and then attaching a machined camera for dental use that consisted of a charge-coupled device (CCD) camera and 4 light-emitting diodes (LEDs) (“Miharu-kun”; RF System Lab, Japan) through two tubes. The length of the two tubes is variable and one is an accessory channel.

EMR using the 1-channel camera-hood was performed as follows. After injection of saline solution into the submucosa, the endoscope was removed and the 1-channel camera-hood was placed on the tip and fixed with tape. A snare was passed through the accessory channel of the hood, and grasping forceps were passed through the accessory channel of the endoscope. We made the grasping forceps catch hold of the snare. The lesion was then strangulated by precisely closing the snare under adequate observation by both CCD cameras of the 1-channel camera-hood and the endoscope. Blend electrosurgical current was used to resect the lesion.




Fig. 7. Multi-camera system using a novel 1-channel camera-hood placed at the top of the scope.

4. ESD

The technique of ESD was introduced to resect large specimens of early gastric cancer in a single piece. ESD can provide precise histological diagnosis and can also reduce the

recurrence rate (Muto et al. 2005). The drawback of ESD lies in the technical difficulty, and this technique is therefore associated with a high rate of complications, the need for advanced endoscopic techniques, and a lengthy procedure time (Oka et al. 2006, Ono et al. 2001).

4.1 Standard ESD

Standard ESD requires special cutting knives, such as a needle knife (Hirano et al. 1988), an insulation-tipped electrosurgical (IT) knife (Ono et al. 2001, Ohkuwa et al. 2001, Miyamoto et al. 2002, Rösch et al. 2004, Gotoda et al. 2005), a hook knife (Oyama et al. 2002, 2005), a flex knife (Yahagi et al. 2004), a flush knife (Toyonaga et al. 2007), a triangle-tip (TT) knife (Inoue et al. 2004) and a mucosectome (Kawahara et al. 2007).

Standard ESD is performed with a standard single accessory-channel endoscope. Typical sequences are the following: marking; incision; and submucosal dissection with simultaneous hemostasis. After making several marking dots outside the lesion, various submucosal solutions are injected, including the normal saline solution and epinephrine mixture, glycerol mixture, and hyaluronic acid. A circumferential incision into the mucosa is made using one of the special cutting knives. Direct dissection of the submucosal layer is performed with one of the specified knives until complete removal is achieved. During ESD, the endoscopist performs endoscopic hemostasis with either the knife itself or hemostatic forceps whenever active bleeding is noticed. After ESD, the endoscopist performs preventive endoscopic hemostasis for any oozing or exposed vessels. High-frequency generators (Erbotom ICC200 or VIO 300D; ERBE, Tübingen, Germany) were used for marking, incision of the gastric mucosa, gastric submucosal dissection, and endoscopic hemostasis.

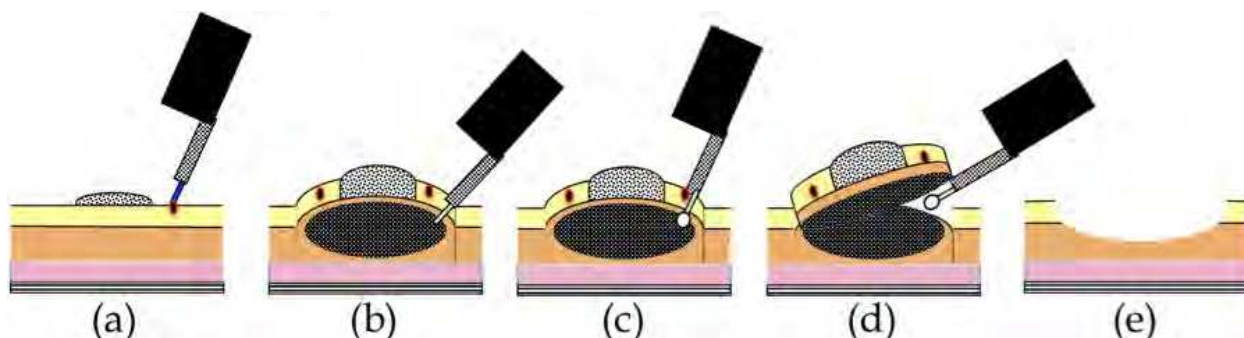


Fig. 8. Technique of standard ESD method: (a) Several marking dots outside the lesion are made, (b) Submucosal solutions are injected. (c) A circumferential incision into the mucosa is made using one of the special cutting knives. (d) Direct dissection of the submucosal layer is performed with one of the specified knives until complete removal is achieved. (e) The specimen is removed.

4.2 Special cutting knives

4.2.1 IT knife

The IT knife consists of a small ceramic ball attached to the tip of a high-frequency needle knife (Ono et al. 2001, Ohkuwa et al. 2001, Miyamoto et al. 2002, Rösch et al. 2004, Gotoda et al. 2005). The ceramic ball functions as an insulator for the tip of the needle knife, so that incision and dissection of the mucosa and submucosa can be performed safely. The insulator

helps to prevent perforation due to accidental cutting of the muscularis propria. A specialized feature of the IT knife is that the portion between the insulator tip and sheath is used for incision, sweeping off the tissue with the blade portion of the knife instead of the tip. This feature makes a pull-cut, whereas the direction of incision is limited, and straight-forward incision is difficult while looking directly at the incision line or submucosa.

4.2.2 Hook knife

The top of the hook-type knife is right-angled, 1 mm in size (Oyama et al. 2002, 2005). Compared to the use of a needle knife, safety is improved because the submucosal tissue is hooked and pulled before incision. This knife has a rotating function so that the operator can select the optimal direction of the hook.

4.2.3 Flex knife

The point of the flex knife is rounded with a twisted wire, like a snare (Yahagi et al. 2004). The sheath is soft and flexible. This knife is less likely to cause perforation when reaching the muscular layer, as the tip is round and the entire knife is soft and flexible. As the tip of the sheath is thick and functions as a stopper, operators can easily control the depth of incision very.

4.2.4 Flash knife (Water jet short needle knife)

The Flush knife is a characteristic knife with a needle 0.4 mm in a diameter and five projecting parts of 1, 1.5, 2, 2.5, and 3 mm in length (Toyonaga et al. 2007). A knife clamp at the tip of the sheath is ceramic for heat insulation. The outer sheath is 2.6 mm in diameter and water emission is possible through the lumen of the sheath by connecting a water pump. The water jet is swiftly activated by pressing a foot pedal on the conduction pump. The conductor of the sheath lumen is insulated to prevent electric current dispersion.

4.2.5 TT knife

The TT knife evolved from the process of ESD, which began with the IT knife (Inoue et al. 2004). The triangular tip of the knife can be used for either cutting or coagulating, and has been designed to operate in any direction.

4.2.6 Mucosectome

The mucosectome is composed of a flexible plastic shaft and cutting wire (Kawahara et al. 2007). By handle operation, the top of this device turns freely, which assists the cutting wire to face the proper direction. The plastic shaft moves the muscular layer aside. Cutting wire moves the mucosal layer aside from the submucosa during ESD, and then the procedure itself can be performed safely.

4.2.7 Grasping type scissor forceps (GSF)

Each step of ESD (circumferential incision, submucosal excision, hemostatic treatment) can be achieved by the following three operations: (1) grasping the targeted tissue (fixation), (2) lifting up the grasped tissue (separation of the grasped tissue from the underlying proper muscle layer) and (3) cutting the grasped tissue (or coagulating the blood vessel) using an electrosurgical current. These operations are simple and as easy as a bite biopsy technique (Akahoshi et al. 2007, 2010).



Fig. 9. Special cutting knives for ESD: (a) IT knife, (b) IT knife 2, (c) Hook knife, (d) Flex knife, (e) Flash knife, (f) TT knife, (g) Mucosectome, (h) Grasping type scissor forceps (GSF).

4.3 Transparent hood

A transparent hood is helpful for better visualization of the operating field. In particular, good visualization of the submucosal tissue with the aid of a small-caliber-tip transparent (ST) hood makes the cutting procedures easy and safe (Yamamoto et al. 2003) (Fujifilm, Tokyo, Japan). ESD using ST hood is a peeling-off method using a needle-knife for mucosal and submucosal incisions.



Fig. 10. Small-caliber-tip transparent (ST) hood.

4.4 Tip hood

4.4.1 Cap knife

The author developed a novel one-third partial transparent hood that facilitates endoscopic hemostatic procedures while simultaneously allowing the irrigation of bleeding (Kume et al. 2004). The one-third partial hood is easily placed on the tip of the endoscope, although the hood has to be fitted to the right side of the endoscope. The hood-knife was fabricated by drilling another side hole in addition to the hole of the irrigation tube at the cap portion of a transparent end hood (Kume et al. 2005). A snare forceps was glued to the exterior surface over the hole and attached using short tubes at the inside of the cap. Based on this prototype, the irrigation cap-knife (cap-knife attachment (Type KUME) with a fixed snare) was developed as shown in Figure 10b (Create Medic, Yokohama, Japan) (Kume et al. 2007).

The ESD procedure using the cap-knife is performed as follows. After the tumor is separated from surrounding normal mucosa by complete incision around the lesion using the IT knife, the endoscope is then removed, and the cap-knife is placed on the tip and fixed with tape. Grasping forceps are passed through accessory channel and push the lesion away from the muscle layer. Submucosal exfoliation was that the cap-knife was only slid with coagulation current on the muscle layer.

4.4.2 Wiper-knife

This device has not yet been used in patients.

The wiper-knife was fabricated by installing a needle-knife in exchange for a snare forceps (Kume et al. 2007). The needle-knife lets a handling wire intersect and fixes it. The handling wire is put through a hole opening at both ends of the hood. A novel wiper-knife was fabricated such that ESD could be performed by moving like a windshield wiper.

ESD using the wiper-knife was performed as follows. A grasping forceps was passed through accessory channel and pushed the lesion away from the muscle layer. The wiper-knife moved like a windshield wiper with coagulation current on the muscle layer to separate submucosal exfoliation from the muscle layer.

4.4.3 B-cap

B-cap is a device in which the snare of the cap knife has been replaced with a bipolar knife (Miyamoto et al. 2007). The direction for use of the B-knife is the same as the cap knife.




Fig. 11. Tip hoods: (a) Irrigation hood knife, (b) Cap-knife attachment (Type KUME) with a fixed snare placed on the tip of the endoscope through grasping forceps, (c) Wiper knife.

4.5 Therapeutic endoscope

4.5.1 Multibending scope

Some tumor locations are difficult to carry out EMR using a conventional scope, including the lesser curvature or posterior wall of the gastric body, and the cardia. To facilitate EMR of tumors at these locations, a two-channel scope with two independently curving segments, that is, a multibending scope (the 'M-scope') was developed (Ishi et al. 2004). The M-scope consists of a distal flexible segment that can bend in any of the four major directions and a proximal flexible segment that can bend in two directions. Combined operation of the segments allows the operator to obtain a variety of visual fields, to randomly approach or recede from the lesions, and to obtain an en face view.

4.5.2 Multibending double-channel therapeutic endoscope

The multibending double-channel therapeutic endoscope (the 'R-scope') has been designed for lifting lesions and for improved dissection with the incorporation of two movable channels (Yonezawa et al. 2006, Neuhaus, et al. 2006). The R-scope has two movable instrument channels: one moves vertically; and the other swings horizontally. The two instruments can be manipulated during the operation with knob and a lever that surrounds the angulation control knobs of the R-scope.

4.5.3 Vibration endoscopy

This device has not yet been used in patients.

The author attempted to increase the efficiency of endoscopic treatment techniques by vibrating the endoscope scope itself. The vibration used must be at a frequency that ensures safety when applied to the body. Examples of inventions that are made effective by adding safe vibration to the body are vibrating oral care devices developed to clean between the teeth and manual multiple-blade shavers with vibration added to increase cutting efficiency. The latter is a commercial product in which vibration successfully raised cutting efficiency without harming the skin, even though the blades cut whiskers in direct contact with the face (M3 Power; Gillette, Japan). An endoscope with an incorporated eccentric motor was therefore developed and used in conducting ESD. The vibration endoscope comprised a modified commercial endoscope (GIF-Q200; Olympus). First, the covering plastic of the tip and the metal mesh were stripped off. After exposing the interior, a vibration motor (J71; Shicoh, Japan) fitted within a cylinder was attached and this section was covered using heat-shrinkable tubing (Kume. 2010).

Among circumferential incisions, submucosal dissection and a total of both, mean procedure durations with vibration at 10,000 rpm were significantly shorter than those without vibration. When performing peripheral incisions and submucosal dissection with a knife in ESD, the time for the procedure can be reduced by adding vibration.




Fig. 12. Therapeutic endoscopes: (a) Multibending double-channel therapeutic endoscope, (b) Vibration endoscope.

4.6 Traction methods

4.6.1 Magnetic anchor system

The magnetic anchor (Pentax, Tokyo, Japan) consists of 3 parts: a hand-made magnetic weight, made of magnetic stainless steel; microforceps; and a connecting thread. A weight is designed to facilitate gastric ESD by use of an extracorporeal hands-free electromagnet, whereby magnetic forces allow a suitable counter-traction for submucosal dissection (Gotoda et al. 2009).

4.6.2 Percutaneous traction

A small snare is introduced into the gastric lumen through a percutaneous gastric port (2-mm diameter) to grasp and pull the lesion away from the muscularis propria to facilitate resection (Kondo et al. 2004).

4.6.3 External grasping forceps

In ESD using an external grasping forceps, oral traction applied with the external forceps can elevate the lesion and make the submucosal layer on the aboral side wider and more visible, thereby facilitating submucosal dissection under direct vision (Imada et al. 2006).

4.6.4 EndoLifter

In ESD using an external grasping forceps through EndoLifter (LA-201, 202. Olympus, Tokyo, Japan), traction applied with the external forceps can elevate the lesion and make the submucosal layer wider and more visible, thereby facilitating submucosal dissection under direct vision.



Fig. 13. EndoLifter.

4.7 Water jet

4.7.1 Water jet endoscope

By washing the bleeding field with the water jet, the bleeding source can be immediately identified and coagulated, although in a small number of cases of erupting venous bleeding, identifying the bleeding source can be difficult.

4.7.2 Irrigation hood

The author developed an end hood that facilitates endoscopic hemostatic procedures while simultaneously allowing irrigation of the hemorrhage site. The end hood piece was fabricated by drilling a side hole in the cap portion of a conventional transparent hood, then the irrigation tube was glued to the exterior surface of the hole (Kume et al. 2003, 2004). The fabricated transparent hood was placed at the tip of the endoscope. Based on this prototype, the irrigation hood (irrigation cap; Type KUME) was developed as shown in Figure 13b (Create Medic, Yokohama, Japan).




Fig. 14. Water jet: (a) Water jet endoscope, (b) Irrigation hood.

4.8 Hemostatic device

4.8.1 Coagula-irrigation hood (CI hood)

The author developed a new type of hood, the "coagula-irrigation hood" (CI hood), which could simultaneously perform both coagulation and irrigation (Kume et al. 2006). The CI hood was fabricated by installing a machined papillotomy knife in exchange for an irrigation tube of irrigation hood. The tip of papillotomy knife was cut off and the tip of a wire was bent into a hoop. A CI hood was fabricated such that ESD and endoscopic hemostasis could be performed while simultaneously applying adequate coagulation and irrigation.

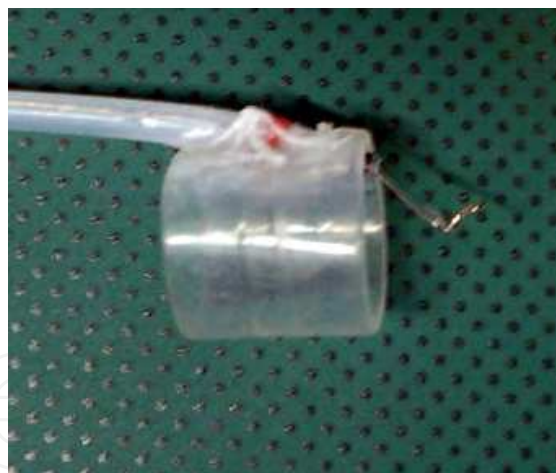

Fig. 15. CI hood.

4.9 Fan devices

This device has not yet been used in patients.

During resection, incision, and detachment using an endoscope, smoke is produced due to electrocautery. Accumulation of this smoke in the gastrointestinal (GI) tract impairs the visual field and makes continuation of the procedure difficult. The author therefore developed two types of new fan device that improve the visual field by circulating air without changing the air volume (Kume. 2009). Both devices were created using a super-micro fan motor (Shiko, Japan). The first works by blowing air, while the second uses ventilation.




Fig. 16. Endoscopic fan device. (a) Blowing type, (b) Ventilation type.

4.10 Injection solutions

4.10.1 Injection solutions for elevation

Two types of solution are used for submucosal injection: isotonic solution (normal saline, hyaluronic acid); and hypertonic solution (hypertonic saline, glucose, Glyceol®)(Yamamoto et al. 2003, 1999, Fujishiro et al. 2006, Uraoka et al. 2005, Akahosh et al. 2006). The advantages of hypertonic solution are better mucosal elevation and better hemostatic effect than normal saline. However, hypertonic solution is more likely to damage tissue in a resection sample, post-resection ulcer, or surrounding mucosa compared with isotonic solution.

Hyaluronic acid solution makes a better long-lasting submucosal cushion without tissue damage than other available solutions (Yamamoto et al. 2003, 1999).

4.10.2 Injection solution for submucosal dissection

The author reported a new method of ESD by submucosal injection of jelly, which obviates the need for submucosal incision with a knife (Yamasaki et al. 2005). As jelly is thick and viscous, the mucosal layer can be dissected from the muscular layer when injected into the submucosal layer.

Sodium carboxymethylcellulose (SCMC) is a water-soluble polymer derived from cellulose. When dissolved in water, it becomes very viscous, like jelly. We used SCMC for ESD in porcine stomachs (Yamasaki et al. 2006). The mucosal layer was dissected from the muscular layer with submucosal injection of 2.5% SCMC.

5. Discussion: EMR vs ESD

In a Japanese multicentre collaborative prospective study of endoscopic treatment for early gastric cancer, if the diagnosis of intramucosal cancer (<20 mm, UL(-)) from the specimen resected at initial EMR was histologically correct, then local cure could be achieved with EMR, including cases of recurrence, with appropriate follow-up and use of concomitant techniques such as piecemeal resection and coagulation therapy (Ida et al. 2004). Therefore, intramucosal gastric cancer less than 20 mm in size and with no ulceration is considered appropriate for EMR.

ESD, which first developed in the stomach, is a new endoluminal therapeutic technique involving the use of cutting devices to permit a larger resection of the tissue over the

muscularis propria. The technique has also spread to other organs in the gastrointestinal tract (Kakushima et al. 2008). In comparison with EMR, ESD needs very experienced hands because of its far more complex procedural sequence. However, the obtained outcomes seem to be more advantageous especially for early-stage neoplasms with a large size or submucosal fibrosis, although long-term data are still lacking. Additionally, by using ESD technique, the resected area can be precisely controlled by the operators, which may not only lead to complete removal of even large lesions, but also to the least non-neoplastic mucosal resection.

ESD time is increased in cases with ulceration, scarring, a large lesion, or location in the upper portion of the stomach (Chung HK et al. 2009). The large upper portion of the stomach region has a large vascular network, resulting in technical difficulty in the approach to dissection or control of bleeding, all of which increases the procedure time. In cases of recurrent lesion or a lesion with an accompanying scar, the endoscopist needs to dissect very carefully, as a thin submucosal cushion and hard fibrotic tissue both make dissection difficult to perform without perforation.

In the colon ESD has some advantages, such as better control of the shape and size of the resected specimen, and the possibility to perform en bloc and R0 resections even for large tumors or tumors that lift poorly due to fibrosis. But ESD does carry some disadvantages too: it is a time consuming procedure, and it carries a higher risk of bleeding and a slightly higher probability of perforation (Fujishiro et al. 2007). Although ESD seems to be a promising technique that is applicable to colorectal epithelial neoplasm, when determining whether colorectal ESD is indicated, it is important to weigh the potential benefits against the risks. This may be different for each endoscopist and for each lesion. Currently, it may be better to resect some large flat colorectal epithelial neoplasms using a method such as piecemeal EMR or colorectal resection when expertise with ESD is still limited (Deprez et al. 2010).

In the esophagus various data with ESD are still lacking, such as the technical difficulty and the risk of complications.

Due to the high level of expertise needed to perform the technique safely, ESD should be performed in a step-up approach after prior experience with conventional EMR, starting with lesions presenting in the distal stomach, then in the proximal stomach, rectum, colon, and finally in the esophagus.

6. References

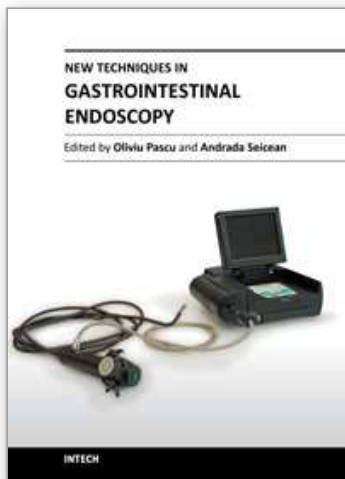
- Niwa H. (1968). Improvement of fibrogastroscope for biopsy and application of color television and high frequent currents for endoscopic biopsy (in Japanese). *Gastroenterol Endosc.* Vol.10: 31.
- Tada M, Shimada M, Murakami F, Shimada M, Mizumachi M, Arima T, Yanai H, Oka S, Shigeeda M, Ogino M, Aibe T, Okazaki Y, Takemoto T, Kinoshita Y, Kinoshita K & Iida Y. (1984). Development of the strip-off biopsy (in Japanese with English abstract). *Gastroenterol Endosc.* Vol.26: 833-839.
- Hirao M, Masuda K, Asanuma T, Naka H, Noda K, Matsuura K, Yamaguchi O & Ueda N. (1988). Endoscopic resection of early gastric cancer and other tumors with local injection of hypertonic saline-epinephrine. *Gastrointest Endosc.* Vol.34: 264-269.
- Muto M, Miyamoto S, Hosokawa A, Doi T, Ohtsu A, Yoshida S, Endo Y, Hosokawa K, Saito D, Shim CS & Gossner L. (2005). Endoscopic mucosal resection in the stomach using the insulated tip needle knife. *Endoscopy.* Vol.37: 178-182.

- Oka S, Tanaka S, Kaneko I, Mouri R, Hirata M, Kawamura T, Yoshihara M & Chayama K. (2006). Advantage of endoscopic submucosal dissection compared with EMR for early gastric cancer. *Gastrointest Endosc.* Vol.64: 877-883.
- Makuuchi H. (1996). Endoscopic mucosal resection for early esophageal cancer: indication and techniques. *Dig Endosc.* Vol. 8: 175-179.
- Oyama T, Tomori A, Hotta K, Morita S, Kominato K, Tanaka M & Miyata Y. (2005). Endoscopic submucosal dissection of early esophageal cancer. *Clin Gastroenterol Hepatol.* Vol. 3: S67-S70.
- Gotoda T. (2007). Endoscopic resection of early gastric cancer. *Gastric cancer.* Vol. 10: 1-10.
- Kitajima K, Fujimori T, Fujii S, Takeda J, Ohkura Y, Kawamata H, Kumamoto T, Ishiguro S, Kato Y, Shimoda T, Iwashita A, Ajioka Y, Watanabe H, Watanabe T, Muto T & Nagasako K. (2004). Correlations between lymph node metastasis and depth of submucosal invasion in submucosal invasive colorectal carcinoma: a Japanese collaborative study. *J Gastroenterol.* Vol. 39: 534-543.
- Uraoka T, Saito Y, Matsuda T, Ikehara H, Gotoda T, Saito D & Fujii T. (2006) Endoscopic indications for endoscopic mucosal resection of laterally spreading tumors in the colorectum. *Gut.* Vol. 55: 1592-1597.
- Soetikno RM, Goto T, Nakanishi Y & Soehendra N. (2003). Endoscopic mucosal resection. *Gastrointest Endosc.* Vol.57: 567-579.
- Tada M, Murakami A, Karita M, Yanai H & Okita K. (1993). Endoscopic resection of early gastric cancer. *Endoscopy.* Vol. 25: 445-450.
- Takekoshi T, Baba Y, Ota H, Kato Y, Yanagisawa A, Takagi K & Noguchi Y. (1994). Endoscopic resection of early gastric carcinoma: Results of a retrospective analysis of 308 cases. *Endoscopy.* Vol. 26: 352-358.
- Karita M, Tada M & Okita K. (1992). The successive strip biopsy partial resection technique for large early gastric and colon cancers. *Gastrointest Endosc.* Vol. 38: 174-178.
- Takeshita K, Hori H, Muraoka Y, Yoneshima H & Endo M. (1993). Endoscopic mucosal resection with a cap-fitted panendoscope for esophagus, stomach, and colon mucosal lesions. *Gastrointest Endosc.* Vol. 39: 58-62.
- Matsuzaki K, Nagao S, A K, Miyazaki J, Yoshida Y, Kitagawa Y, Nakajima H, Kato S, Hokari R, Tsuzuki Y, Itoh K, Niwa H & Miura S. (2003). Newly designed soft pre-looped cap for endoscopic mucosal resection of gastric lesions. *Gastrointest Endosc.* Vol. 57: 242-246.
- Kume K, Yoshikawa I & Otsuki M. (2003). Endoscopic treatment of upper GI hemorrhage with a novel irrigating hood attached to the endoscope. *Gastrointest Endosc.* Vol. 57: 732-735.
- Kume K, Yamasaki M, Yamasaki T, Yoshikawa I & Otsuki M. (2004). Endoscopic hemostatic treatment under irrigation for upper GI hemorrhage: a comparison of one third and total circumference transparent end hoods. *Gastrointest Endosc.* Vol. 59: 712-716.
- Kume K, Yamasaki M, Kanda K, Yoshikawa I & Otsuki M. (2005). Endoscopic procedure under irrigation. *Dig Endosc.* Vol. 17: 241-245.
- Kume K, Yamasaki M, Kubo K, Mitsuoka H, Oto T, Matsuhashi T, Matsuhashi T, Yamasaki T, Yoshikawa I & Otsuki M. (2004). EMR of upper GI lesions when using a novel soft, irrigation, prelooped hood. *Gastrointest Endosc.* Vol. 60: 124-128.
- Kume K, Yamasaki M, Kanda K, Hirakoba M, Matsuhashi T, Santo N, Syukuwa K, Yoshikawa I & Otsuki M. (2006). Grasping forceps-assisted endoscopic mucosal resection of early gastric cancer with a novel 2-channel prelooped hood. *Gastrointest Endosc.* Vol. 64: 108-112.

- Kume K, Yamasaki M, Yoshikawa I & Otsuki M. (2007). Endoscopic aspiration mucosectomy and closure assisted by outside CCD camera. *Endoscopy*. Vol. 39: E214-E215.
- Katayama O, Honda H, Koike T, Uchida Y, Takahata T & Matsumoto T. (2006). Usefulness of oblique hood-fitted panendoscope: mucosal cut and aspiration method. *Endosc Digest*. Vol. 18: 1125-1130 (Japanese with English abstract).
- Torii A, Sakai M, Kajiyama T, Kishimoto H, Kin G, Inoue K, Koizumi T, Ueda S & Okuma M. (1995). Endoscopic aspiration mucosectomy as curative endoscopic surgery: analysis of 24 cases early gastric cancer. *Gastrointest Endosc*. Vol. 42: 475-479.
- Kume K. (2009). Endoscopic aspiration mucosectomy using a novel vibration hood. *Endoscopy*. Vol. 41: E296-E298.
- Makuuchi H, Yoshida T and Ell C. (2004). Four-step endoscopic esophageal mucosal resection (EEMR) tube method of resection early esophageal cancer. *Endoscopy*. Vol. 36: 1013-1018.
- Suzuki Y, Hiraishi H, Kanke K, Watanabe H, Ueno N, Ishida M, Masuyama H & Terano A. (1999). Treatment of gastric tumors by endoscopic mucosal resection with a ligating device. *Gastrointest Endosc*. Vol. 49: 192-199.
- Kume K, Yamasaki M, Yoshikawa I & Otsuki M. (2007). Multi-camera system of the endoscopy: endoscopic mucosal resection for large gastric lesion using a novel 1-channel camera-hood. *Endoscopy*. Vol. 37: E186-E187.
- Ono H, Kondo H, Gotoda T, Shirao K, Yamaguchi H, Saito D, Hosokawa K, Shimoda T & Yoshida S. (2001). Endoscopic mucosal resection for treatment of early gastric cancer. *Gut*. Vol. 48: 225-229.
- Ohkuwa M, Hosokawa K, Boku N, Ohtu A, Tajiri H & Yoshida S. (2001). New endoscopic treatment for intramucosal gastric tumors using an insulated-tip diathermic knife. *Endoscopy*. Vol. 33: 221-226.
- Rösch T, Sarbia M, Schumacher B, Deinert K, Frimberger E, Toerner T, Stolte M & Neuhaus H. (2004). Attempted endoscopic en bloc resection of mucosal and submucosal tumors using insulated-tip knives: a pilot series. *Endoscopy*. Vol. 36: 788-801.
- Gotoda T. (2005). A large endoscopic resection by endoscopic submucosal dissection procedure for early gastric cancer. *Clin Gastroenterol Hepatol*. Vol. 3: S71-S73.
- Oyama T & Kikuchi Y. (2002). Aggressive endoscopic mucosal resection in the upper GI tract-hook knife EMR method. *Minim Invasive Ther Allied Technol*. Vol. 11: 291-295.
- Oyama T, Tomori A, Hotta K, Morita S, Kominato K, Tanaka M & Miyata Y. (2005). Endoscopic submucosal dissection of early esophageal cancer. *Clin Gastroenterol Hepatol*. Vol. 3: S67-S70.
- Yahagi N, Fujishiro M, Kakushima N, Kobayashi K, Hashimoto T, Oka M, Iguchi M, Enomoto S, Ichinose M, Niwa H & Omata M. (2004). Endoscopic submucosal dissection for early gastric cancer using the tip of an electro-sergical snare (thin type). *Dig Endosc*. Vol. 16: 34-38.
- Toyonaga T, Nishino E, Dozaiku T, Ueda C & Hirooka T. (2007). Management to prevent bleeding during endoscopic submucosal dissection using the flush knife for gastric tumor. *Dig Endosc*. Vol. 19: S14-S18.
- Inoue H, Sato Y, Kazawa T, Sugaya S, Usui S, Satodate H & Kudo S. (2004). Endoscopic submucosal dissection-using a triangle tipped knife. (in Japanese) *Sto Int*, Vol. 39; 53-56.
- Kawahara Y, Takenaka R & Okada H. (2007) Risk management to prevent perforation during endoscopic submucosal dissection. *Dig Endosc*. Vol. 19: S9-S13.

- Akahoshi K, Akahane H, Murata A, Akiba H & Oya M. (2007). Endoscopic submucosal dissection using a novel grasping type scissors forceps. *Endoscopy*. Vol. 39: 1103-1105.
- Akahoshi K & Akahane H. (2010). A new breakthrough: ESD using a newly developed grasping type scissor forceps for early gastrointestinal tract neoplasms. *World J Gastrointest Endosc*. Vol. 2: 90-96.
- Yamamoto H, Kawata H, Sunada K, Sasaki A, Nakazawa K, Miyata T, Sekine Y, Yano T, Satoh K, Ido K & Sugano K. (2003). Successful en-bloc resection of large superficial tumors in the stomach and colon using sodium hyaluronate and small-caliber-tip transparent hood. *Endoscopy*. Vol. 35: 690-694.
- Kume K, Yamasaki M, Kanda K, Yoshikawa I & Otsuki M. (2005). Endoscopic submucosal dissection using a novel irrigation hood-knife. *Endoscopy*. Vol. 37: 1030-1031.
- Kume K, Yamasaki M, Kanda K, Yoshikawa I & Otsuki M. (2007) Grasping-forceps-assisted endoscopic submucosal dissection using a novel irrigation cap-knife for large superficial early gastric cancer. *Endoscopy*. Vol. 39: 566-569.
- Kume K, Yamasaki M, Kanda K, Yoshikawa I & Otsuki M. (2007) Endoscopic submucosal dissection using a novel irrigation wiper-knife. *Endoscopy*. Vol. 39: E144.
- Miyamoto S, Aoi T, Morita S, Nitta T, Nishio A & Chiba T. (2007) Endoscopic submucosal dissection using the B-Cap (in Japanese). *Clin Gastroenterol*. Vol. 22: 1263-1265.
- Ishii K, Tajiri H, Fujisaki J, Mochizuki K, Matsuda K, Nakamura Y, Saito N & Narimiya N. (2004). The effectiveness of new multibending scope for endoscopic mucosal resection. *Endoscopy*. Vol. 36: 294-297.
- Yonezawa J, Kaise M, Sumiyama K, Goda K, Arakawa H & Tajiri H. (2006). A novel double-channel therapeutic endoscope ("R-scope") facilitates endoscopic submucosal dissection of superficial gastric neoplasms. *Endoscopy*. Vol. 38: 1011-1015.
- Neuhaus H, Costamagna G, Deviere J, Fockens P, Pouchon T & Rosch T. (2006). Endoscopic submucosal dissection (ESD) of early neoplastic lesions using a new double-channel therapeutic endoscope ("R-scope"). *Endoscopy*. Vol. 38: 1016-1023.
- Kume K. (2010). Endoscopic submucosal dissection using a novel vibration endoscopy. *Hepato Gastroenterol*. Vol. 57: 224-227.
- Gotoda T, Oda I, Tamakawa K, Ueda H, Kobayashi T & Kakizoe T. (2009) Prospective clinical trial of magnetic-anchor-guided endoscopic submucosal dissection for large early gastric cancer (with videos). *Gastrointest Endosc*. Vol. 69: 10-15.
- Kondo H, Gotoda T, Ono H, Oda I, Kozu T, Fujishiro M, Saito D & Yoshida S. (2004). Percutaneous traction-assisted EMR by using an insulation-tipped electrosurgical knife for early stage gastric cancer. *Gastrointest Endosc*. Vol. 59: 284-288.
- Imada H, Iwao Y, Ogata H, Ichikawa H, Mori M, Hosoe N, Masaoka T, Nakashita M, Suzuki H, Inoue N, Aiura K, Nagata H, Kumai K & Hibi K. (2006). A new technique for endoscopic submucosal dissection for early gastric cancer using an external grasping forceps. *Endoscopy*. Vol. 38: 1007-1010.
- Kume K, Yamasaki M, Yoshikawa I & Otsuki M. (2006). New device to perform coagulation and irrigation simultaneously during endoscopic submucosal dissection using an insulation-tipped electrosurgical knife. *Dig Endosc*. Vol. 18: 218-220.
- Kume K. (2009). Endoscopic therapy using novel fan devices. *Endoscopy*, Vol. 41: E236-E237.
- Yamamoto H, Yube T, Isoda N, Sato Y, Sekine Y, Higashizawa T, Ido K, Kimura K & Kanai N. (1999). A novel method of endoscopic mucosal resection using sodium hyaluronate. *Gastrointest Endosc*. Vol. 50: 251-256.
- Fujishiro M, Yahagi N, Nakamura M, Kakushima N, Kodashima S, Ono S, Kobayashi K, Hashimoto T, Yamamichi N, Tateishi A, Shimizu Y, Oka M, Ogura K, Kawabe T,

- Ichinose M & Omata M. (2006). Successful outcomes of a novel endoscopic treatment for GI tumors: endoscopic submucosal dissection with a mixture of high-molecular-weight hyaluronic acid, glycerin, and sugar. *Gastrointest Endosc.* Vol. 63: 243-249.
- Uraoka T, Fujii T, Saito Y, Sumiyoshi T, Emura F, Bhandari P, Matsuda T, Fu KI & Saiti D. (2005). Effectiveness of glycerol as a submucosal injection for EMR. *Gastrointest Endosc.* Vol. 61: 736-740.
- Akahoshi K, Yoshinaga S, Fujimaru T, Kondoh A, Higuchi N, Furuno T & Oya M. (2006). Endoscopic resection with hypertonic saline-solution-epinephrine injection plus band ligation for large pedunculated or semipedunculated gastric polyp. *Gastrointest Endosc.* Vol. 63: 312-316.
- Yamasaki M, Kume K, Kanda K, Yoshikawa I & Otsuki M. (2005). A new method of endoscopic submucosal dissection using submucosal injection of jelly. *Endoscopy.* Vol. 37: 1156-1157.
- Yamasaki M, Kume K, Yoshikawa I & Otsuki M. (2006). A novel method of endoscopic submucosal dissection with blunt abrasion by submucosal injection of sodium carboxymethylcellulose: an animal preliminary study. *Gastrointest Endosc.* Vol. 64: 958-965.
- Ida K, Nakazawa S, Yoshino J, Hiki Y, Akamatsu T, Asaki S, Kurihara H, Shimao H, Tada M, Misumi A, Kato T & Niwa H. (2004). Multicentre collaborative prospective study of endoscopic treatment of early gastric cancer. *Dig Endosc.* Vol. 16: 295-302.
- Kakushima N and Fujishiro M. (2008). Endoscopic submucosal dissection for gastrointestinal neoplasms. *World J Gastroenterol.* Vol. 14: 2962-2967.
- Chung HK, Lee JH, Lee SH, Kim SJ, Cho JY, Cho WY, Hwangbo Y, Keum BR, Park JJ, Chun HJ, Kim HJ, Kim JJ, Ji SR & Seol SY. (2009). Therapeutic outcomes in 1000 cases of endoscopic submucosal dissection for early gastric neoplasm: Korean ESD Study Group multicenter study. *Gastrointest Endosc.* Vol. 69: 1228-1235.
- Fujishiro M, Yahagi N, Kakushima N, Kodashima S, Muraki Y, Ono S, Yamamichi N, Tateishi A, Oka M, Ogura K, Kawabe T, Ichinose M and Omata M. (2007). Outcomes of endoscopic submucosal dissection for colorectal epithelial neoplasms in 200 consecutive cases. *Clin Gastroenterol Hepatol.* Vol. 5: 678-683.
- Deprez PH, Bergman JJ, Meisner S, Ponchon T, Repici A, Ribeiro MD and Haringsma J. (2010). Current practice with endoscopic submucosal dissection in Europe: position statement from a panel of experts. *Endoscopy.* Vol. 42: 853-858.



New Techniques in Gastrointestinal Endoscopy

Edited by Prof. Oliviu Pascu

ISBN 978-953-307-777-2

Hard cover, 310 pages

Publisher InTech

Published online 30, September, 2011

Published in print edition September, 2011

As result of progress, endoscopy has became more complex, using more sophisticated devices and has claimed a special form. In this moment, the gastroenterologist performing endoscopy has to be an expert in macroscopic view of the lesions in the gut, with good skills for using standard endoscopes, with good experience in ultrasound (for performing endoscopic ultrasound), with pathology experience for confocal examination. It is compulsory to get experience and to have patience and attention for the follow-up of thousands of images transmitted during capsule endoscopy or to have knowledge in physics necessary for autofluorescence imaging endoscopy. Therefore, the idea of an endoscopist has changed. Examinations mentioned need a special formation, a superior level of instruction, accessible to those who have already gained enough experience in basic diagnostic endoscopy. This is the reason for what these new issues of endoscopy are presented in this book of New techniques in Gastrointestinal Endoscopy.

How to reference

In order to correctly reference this scholarly work, feel free to copy and paste the following:

Keiichiro Kume (2011). EMR and ESD for Gastrointestinal Neoplasms, New Techniques in Gastrointestinal Endoscopy, Prof. Oliviu Pascu (Ed.), ISBN: 978-953-307-777-2, InTech, Available from:
<http://www.intechopen.com/books/new-techniques-in-gastrointestinal-endoscopy/emr-and-esd-for-gastrointestinal-neoplasms>

INTECH
open science | open minds

InTech Europe

University Campus STeP Ri
Slavka Krautzeka 83/A
51000 Rijeka, Croatia
Phone: +385 (51) 770 447
Fax: +385 (51) 686 166
www.intechopen.com

InTech China

Unit 405, Office Block, Hotel Equatorial Shanghai
No.65, Yan An Road (West), Shanghai, 200040, China
中国上海市延安西路65号上海国际贵都大饭店办公楼405单元
Phone: +86-21-62489820
Fax: +86-21-62489821

© 2011 The Author(s). Licensee IntechOpen. This chapter is distributed under the terms of the [Creative Commons Attribution-NonCommercial-ShareAlike-3.0 License](https://creativecommons.org/licenses/by-nc-sa/3.0/), which permits use, distribution and reproduction for non-commercial purposes, provided the original is properly cited and derivative works building on this content are distributed under the same license.

IntechOpen

IntechOpen