

# We are IntechOpen, the world's leading publisher of Open Access books Built by scientists, for scientists

6,900

Open access books available

186,000

International authors and editors

200M

Downloads

Our authors are among the

154

Countries delivered to

TOP 1%

most cited scientists

12.2%

Contributors from top 500 universities



WEB OF SCIENCE™

Selection of our books indexed in the Book Citation Index  
in Web of Science™ Core Collection (BKCI)

Interested in publishing with us?  
Contact [book.department@intechopen.com](mailto:book.department@intechopen.com)

Numbers displayed above are based on latest data collected.  
For more information visit [www.intechopen.com](http://www.intechopen.com)



## Small Bowel Obstruction After Laparoscopic Roux – En - Y Gastric Bypass

Hugo Sánchez and Miguel F Herrera  
*The Obesity clinic. ABC Medical Center*  
 México

### 1. Introduction

Obesity is an important health problem that has almost reached epidemic proportions. Morbid obesity, defined as body mass index (BMI)  $\geq 40\text{kg/m}^2$  leads to a number of chronic-degenerative diseases with high morbidity, mortality, and costs of health care services. Conservative treatment has an elevated average of failure, being Bariatric surgery the best treatment. Surgical treatment results in sustained weight loss and control of co morbidities. (Sjöström, 2004; Buchwald, 2004). The Laparoscopic Roux-en-Y Gastric Bypass (LRYGB) is one of the most commonly performed bariatric procedures. Although the risk-benefit balance is highly favorable, it is important for the people in the field to be aware, understand and prevent potential complications. The aim of this chapter focuses on one of the potential complications of the LRYGB which is small bowel obstruction (SBO).

### 2. General characteristics of the LRYGB

This procedure was originally described by Masson and cols. in the 60's, based on the observation that patients who underwent gastrectomy presented weight loss. From the beginning it was found that factors such as size of the gastric pouch, diameter of the gastrojejunostomy, and length of the alimentary limb had an impact on the amount of weight loss.

Surgical steps include:

1. Construction of a divided small gastric pouch along the lesser curvature, and
2. A small Roux-en Y gastrojejunostomy and a standard side to side jejunojejunostomy.

Although there are several technical variations, volume of the gastric pouch is intended to be close to 30cc, length of the alimentary limb approximately 1m and length of the biliopancreatic limb  $\leq 50\text{cm}$ .

Physiologic changes involved in the RYGB include:

- Early satiety due to the small size of the gastric pouch and elevation of the PYY in the lower part of the bowel.
- Delay in the gastric emptying as a result of the small diameter of the gastrojejunostomy, resulting in persistent satiety.
- Decrease of appetite as a consequence of reduction of the levels of Ghrelin in the excluded stomach.

- Reduction of the intestinal absorption as a result of the shortening of the small bowel by 1,5m or more.
- Intolerance to meals with high content of carbohydrates and fat.

Among the many advantages of laparoscopic surgery in general, one is the reduction in adhesions which is a known factor for the development of SBO. LRYGB has demonstrated to improve patient recovery, to reduce postoperative pain, to diminish abdominal wall related problems but to increase the number of SBO from internal hernias. (Nguyen ,2004; Champion, 2007). When performing a LRYGB, the alimentary limb can be brought up in an antecolic or retrocolic fashion. In both techniques it is important to realize that there are some potential defects where the small bowel may be introduced producing an internal hernia. As it is shown in Figures 2 and 3, the mesenteric defect at the jejuno-jejunostomy takes place in both techniques, there is also a space between the alimentary limb and the mesocolon in both, and in the retrocolic fashion, the opening at the mesocolon is added as a potential defect.

### 3. Small bowel obstruction from internal hernias

In Figures 4 and 5, the way how a loop of small bowel can herniate through both the mesenteric defect at the jejunojejunostomy and the Petersen's space are shown. As we can presume, the major risk for an internal hernia is to leave the spaces open. However, it has been demonstrated that in some patients after significant weight loss, the intraabdominal fat

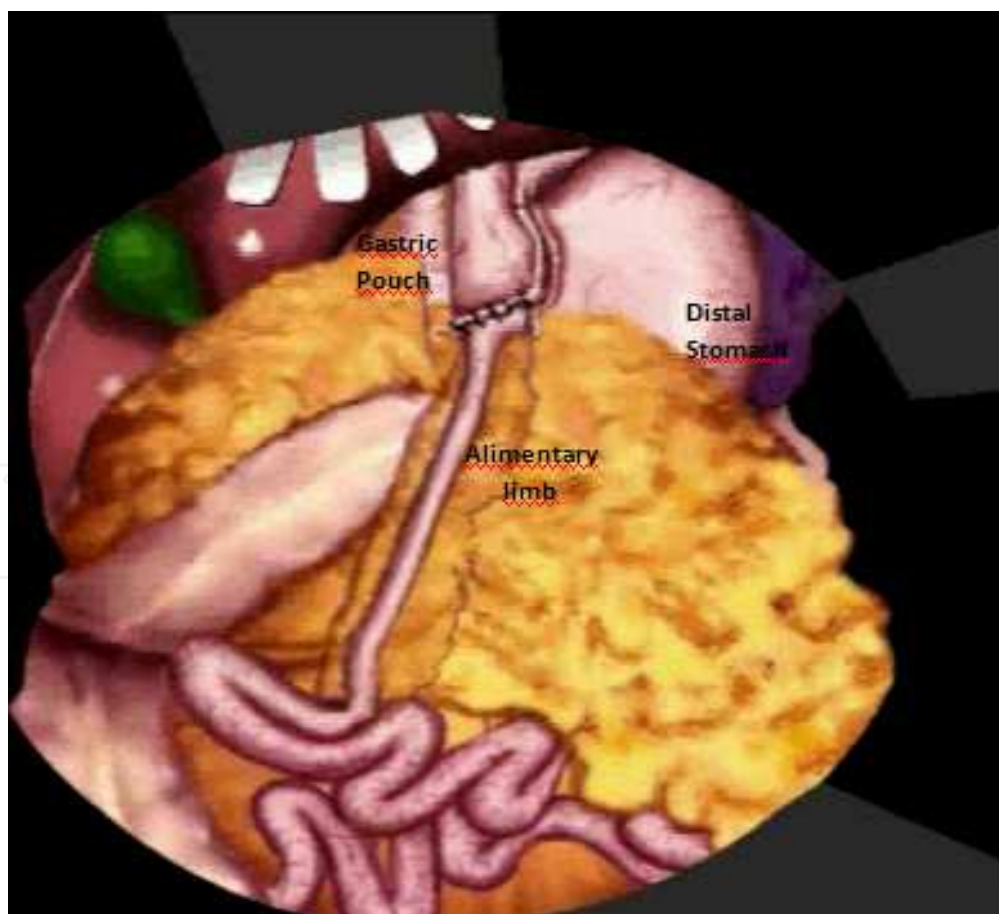


Fig. 1. Antecolic and antegastric LRYGB.

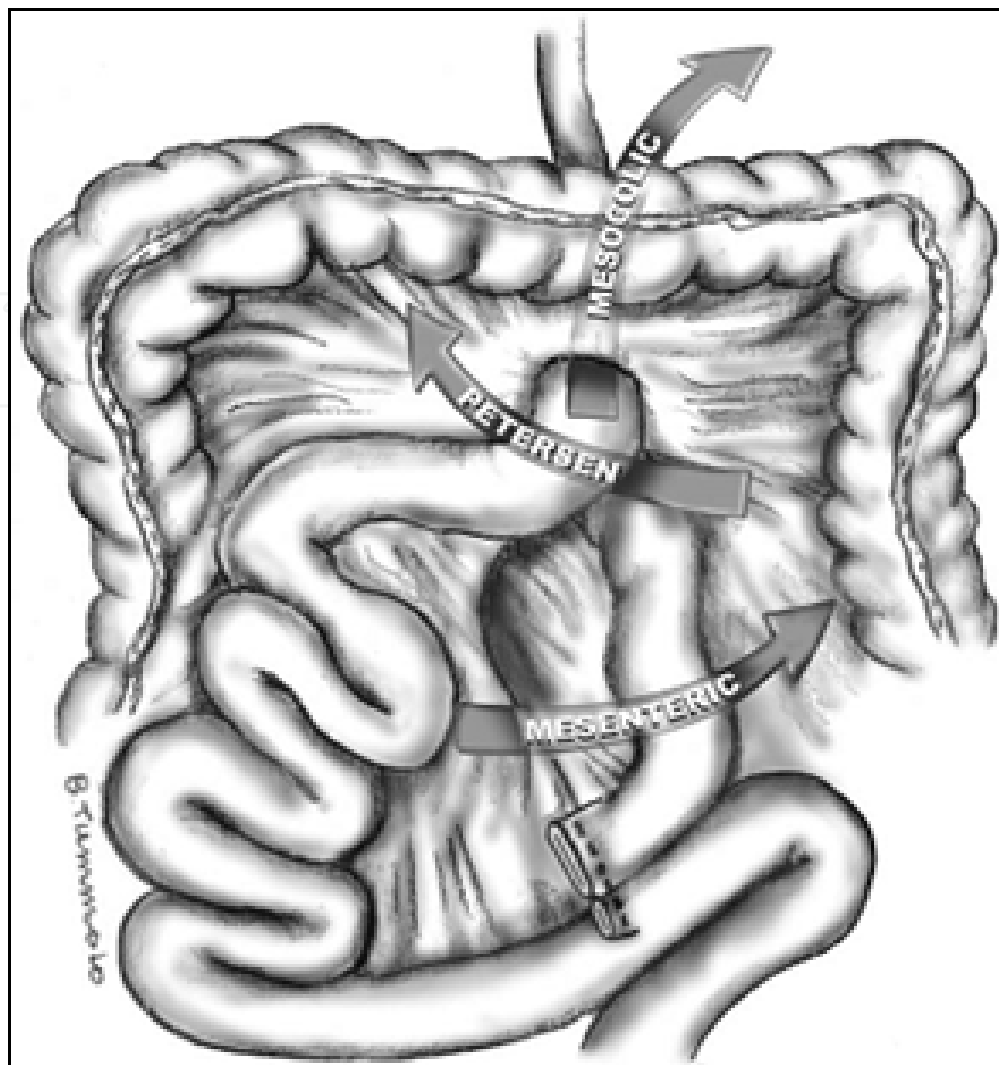


Fig. 2. Mesenteric potential defects. Retrocolic RYGBP (from Capella RF, Lannace VA, Capella JF. Bowel Obstruction after Open and Laparoscopic Gastric Bypass Surgery for Morbid Obesity. *J Am Coll Surg* 2006; 203:328-335.)

tissue is also significantly reduced and the defects may be reopened. Small bowel obstruction in these patients has some peculiarities. Significant amount of small bowel can be introduced in the defect before symptoms appear. In many cases, the clinical feature becomes evident until the jejunojunction passes through the defect. This has as a consequence that patients may experience nonspecific symptoms for long time or that symptomatic periods can be intermittent.

#### 4. Clinical presentation

The most important symptom in patients experiencing small bowel obstruction after a RYGB is severe abdominal pain induced by food intake. Pain is associated to nausea but vomit is very rare. Some patients refer a history of repetitive episodes of abdominal discomfort that are resolved without medical management or with minimum dose of analgesics/antispasmodics. Opposite to the clinical feature of intestinal occlusion in non bariatric patients, bloating is rarely present.

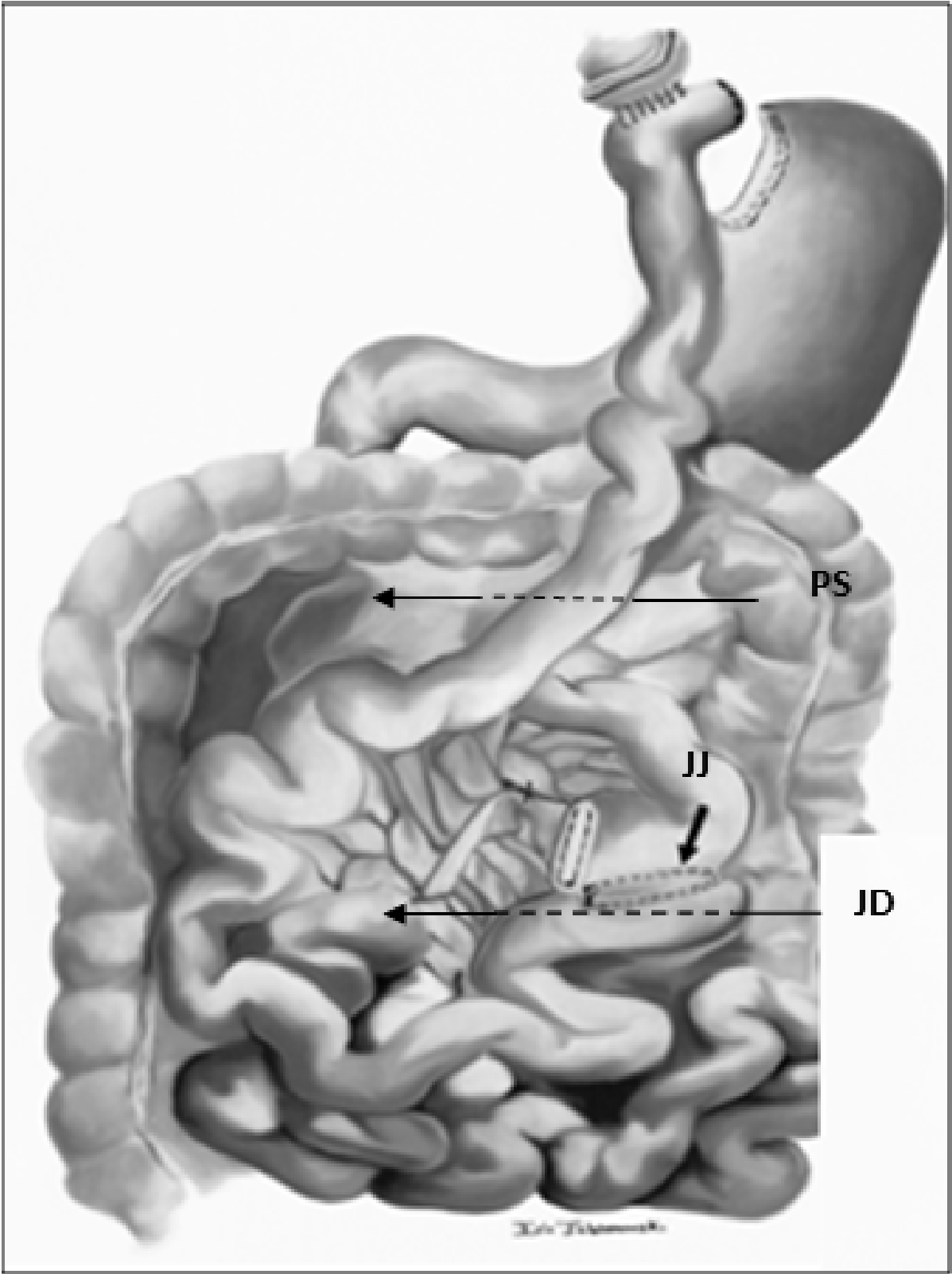


Fig. 3. Mesenteric potential defects. Antecolic RYGBP. PS Petersen´s defect. JJ jejuno-jejunostomy. JD Jejunal mesenteric defect (From Blachar A. Gastrointestinal complications of laparoscopic Roux-en-Y gastric bypass surgery: clinical and imaging findings. Radiology 2002; 223: 625-632)

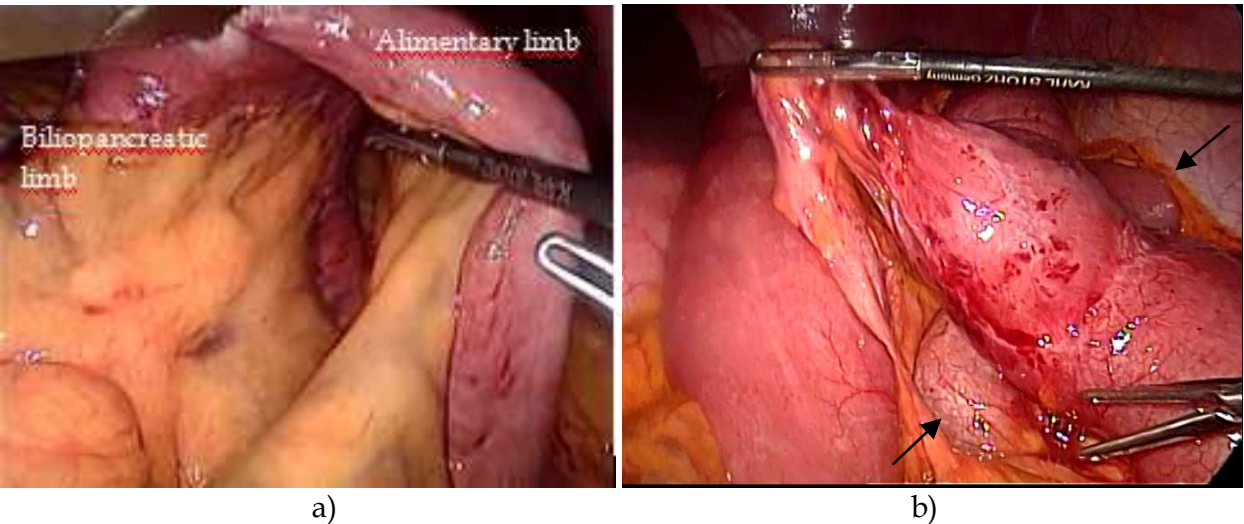


Fig. 4. a. Surgical view of the mesenteric defect at the jejunojejunostomy. b. A loop of the common limb (arrows) is herniated into the mesentery of the jejunojejunostomy

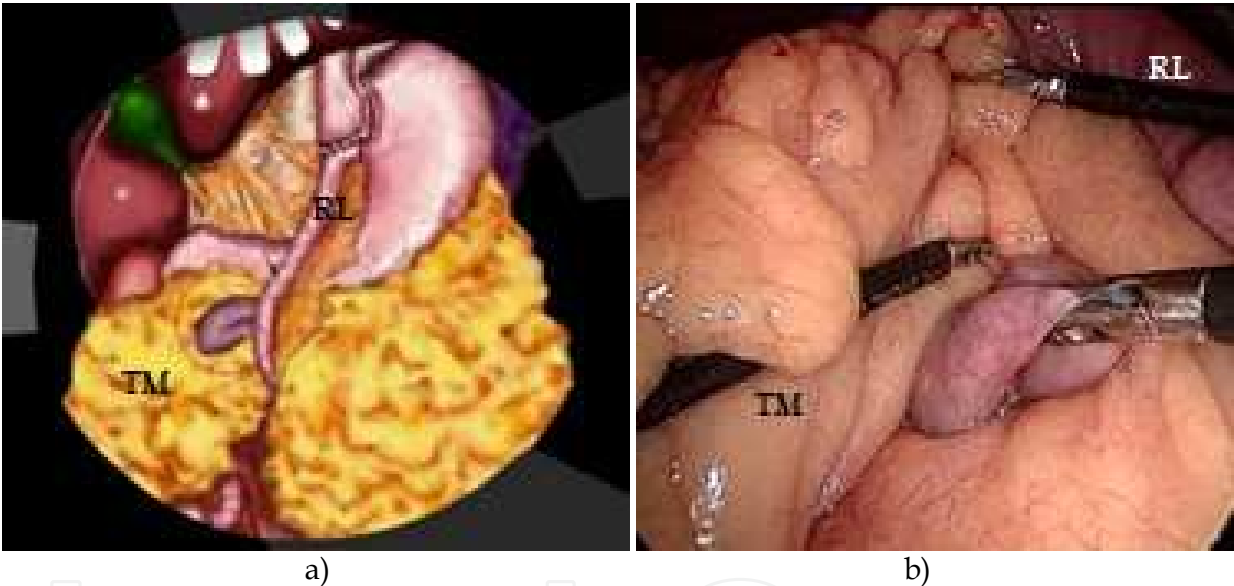


Fig. 5. a and b. A loop of small bowel is herniated through the Petersen's space. (TM Transverse mesocolon, RL Roux limb)

According to the limb that gets obstructed, the clinical characteristics may be different. Cho and colleagues for example have divided SBO into 3 types (Figure 6). In Type I, the intestinal segment blocked is the alimentary limb, and because it is not connected to the bilio-pancreatic fluids, patients vomit only gastric juice and food remnants without bile content. In the Type II, the biliopancreatic limb is obstructed. Clinically there is no abdominal distention and radiological findings rarely show air-fluid levels; a contrast gastrointestinal series shows progression of radiological contrast along the entire small bowel up to the colon. The diagnosis is made on the basis of a high medical suspicion, a big air bubble in the left upper quadrant or by CT scan. Fortunately this type of hernia is very rare. The most common small bowel obstruction is Type III. Obstruction on any segment along the common channel occurs and the clinical picture is very similar to the classic bowel obstruction due to adhesions. The clinical features include abdominal pain, bloating, nausea



and vomiting. Multiple air-fluid levels are seen on X-rays and there is also enlargement of the gastric remnant. The diagnosis is established through the clinical feature and radiological studies including abdominal x-ray, contrasted upper gastrointestinal series and CT scan.

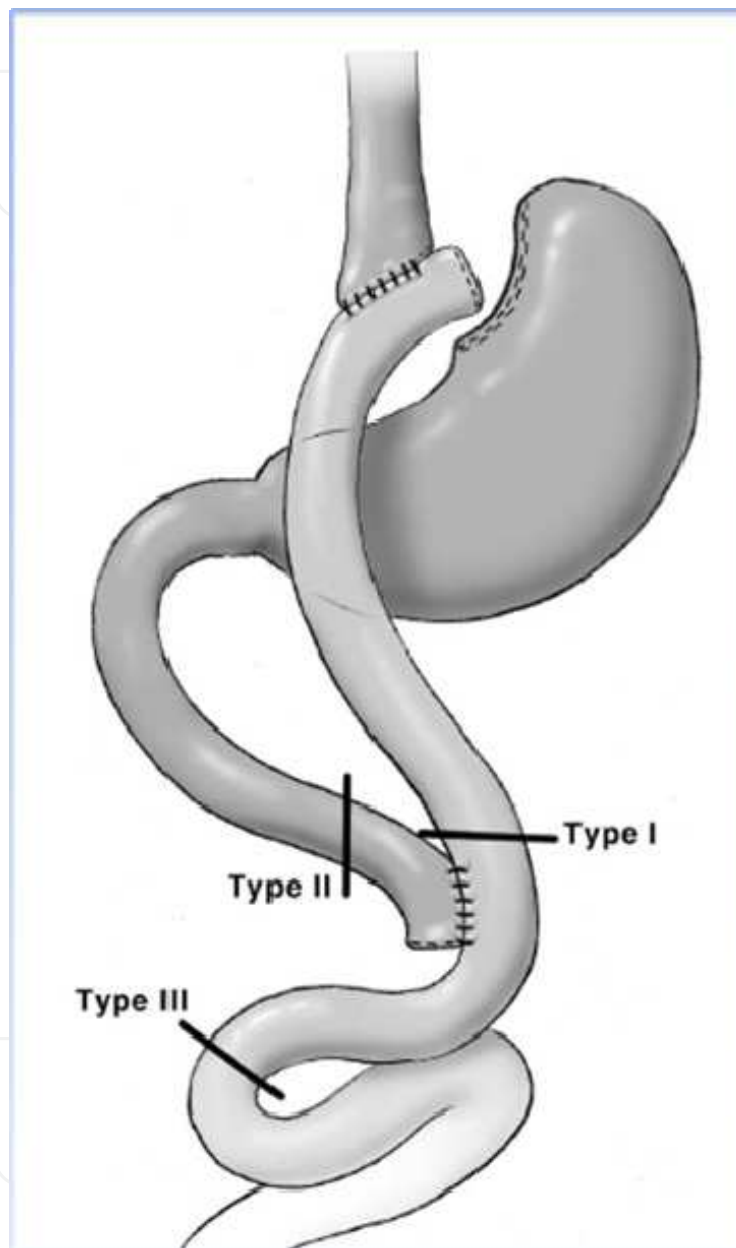


Fig. 6. Sites of intestinal occlusion in a RYGBP. (Reproduced from Cho M, Carrodegua L, Pinto D, et al. Diagnosis and management of partial small bowel obstruction after laparoscopic antecolic antegastric Roux-en-Y gastric bypass for morbid obesity. *J Am Coll Surg.* 2006; 202:262 – 268).

For the diagnosis of SBO it is very important a complete clinical history and physical exam. Patients undergoing a RYGBP may present other medical conditions causing abdominal pain such as gastric ulcer, marginal ulcer, gallstones, irritable bowel syndrome, etc. Once other causes of abdominal pain are ruled out, a plain abdominal X-ray may help with the

diagnosis. In Fig 7, radiological characteristics of SBO are shown. Multiple air-fluid levels and dilation of bowel loops proximal to obstruction are highly suggestive of intestinal obstruction. The most sensitive and specific radiologic test to confirm the diagnosis is an abdominal CT (Iannuccilli, 2009). A gastrographin upper gastrointestinal series may be used as an alternative (Fig 8). It is important to highlight however, that in up to 20% of the patients the diagnosis cannot be established before surgery (Hwang, 2004; Higa, 2003).

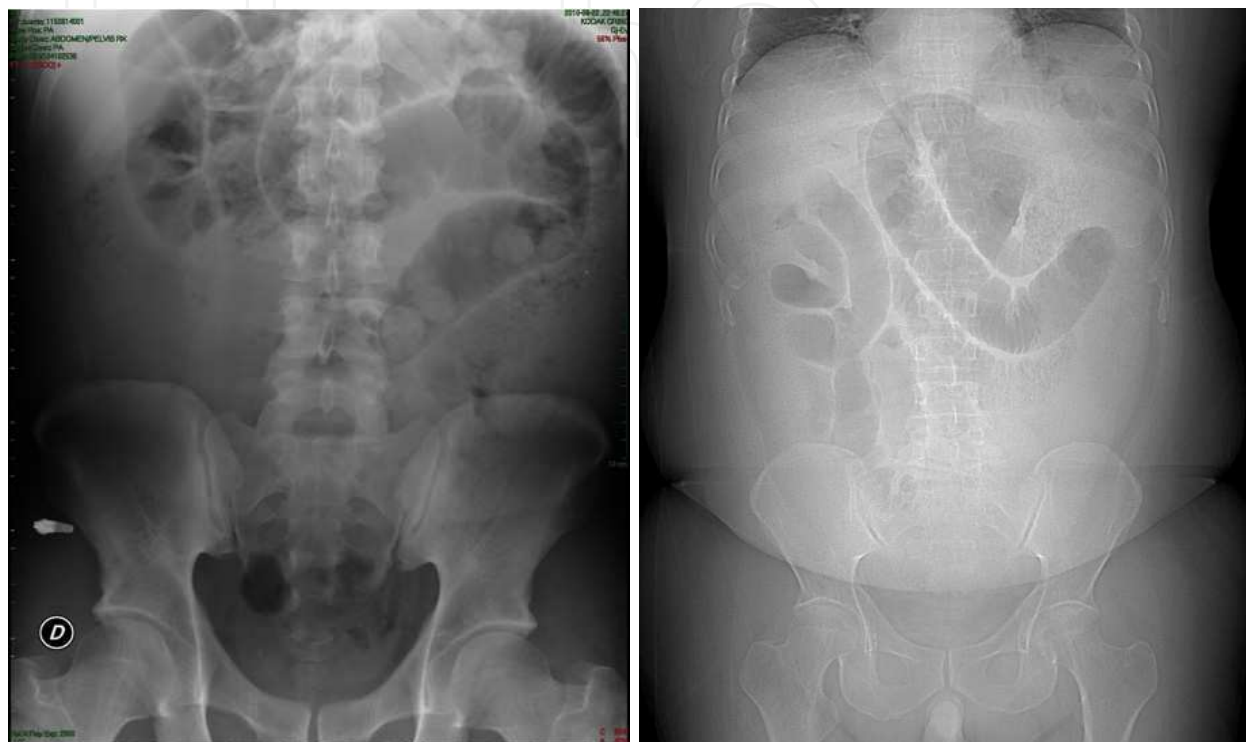


Fig. 7. Plain abdominal X-ray films showing a proximal small bowel obstruction after a LRYGB. An internal hernia at the mesenteric defect of the jejunojejunostomy was confirmed at surgery

Radiological signs of small bowel obstruction on CT are:

- Dilatation of the small bowel proximal to the obstruction with multiple air-fluid levels.
- Normal or collapsed bowel distal to the obstruction.
- The “mushroom sign” which is the result of the herniated mesenteric root through the jejunojejunostomy defect, bordered by the superior mesenteric artery and distal mesenteric branches. (Fig 9a)
- The mesenteric swirl sign. Due to twisting of mesenteric vessels and fat around the mesenteric artery.
- A jejunojejunostomy displaced to the right side of the midline which suggests torsion of the mesenteric root. (In the normal situation the jejunojejunostomy is located on the left side of the abdomen. (Fig 9b)
- Loops of small bowel clustered at the left lower quadrant.
- The hurricane eye sign created by mesenteric fat surrounded by tightly packed bowel loops. (Fig 10 a)
- Multiple enlarged lymph nodes clustered together within the mesentery around a central vascular axis. (Fig 10 b)



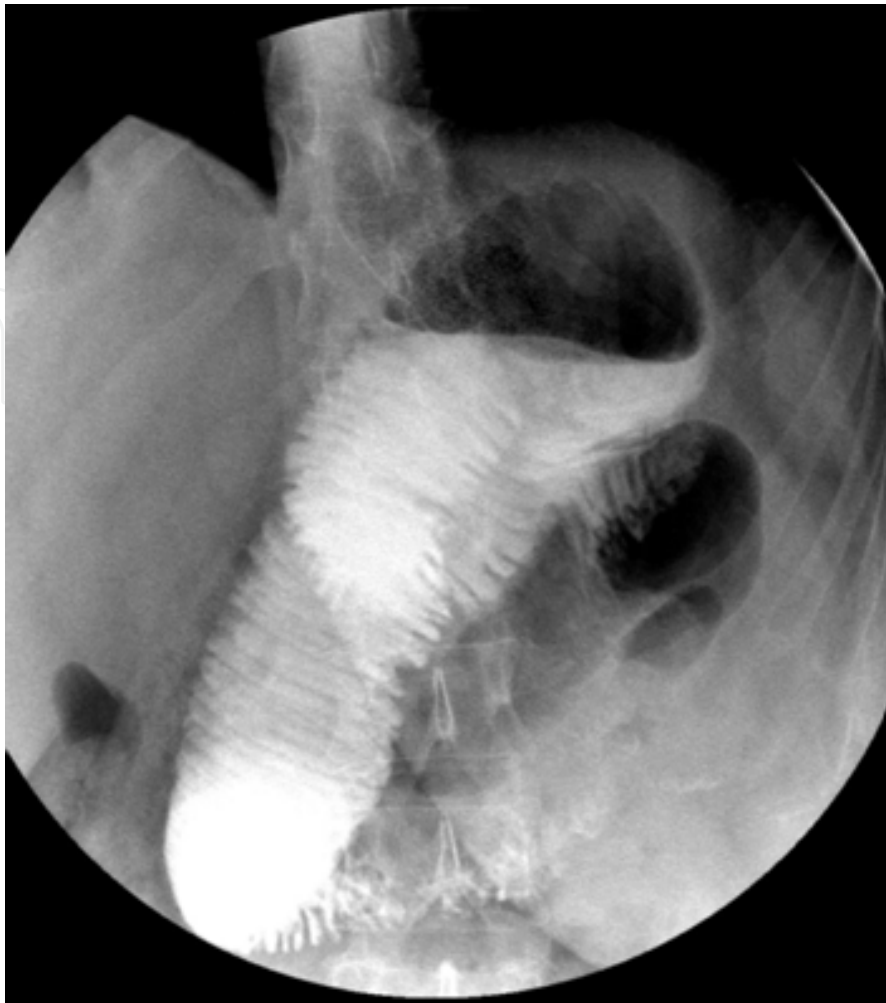

Fig. 8. Gastrographin upper gastrointestinal study showing small bowel obstruction in a patient with internal hernia at the jejunojunostomy

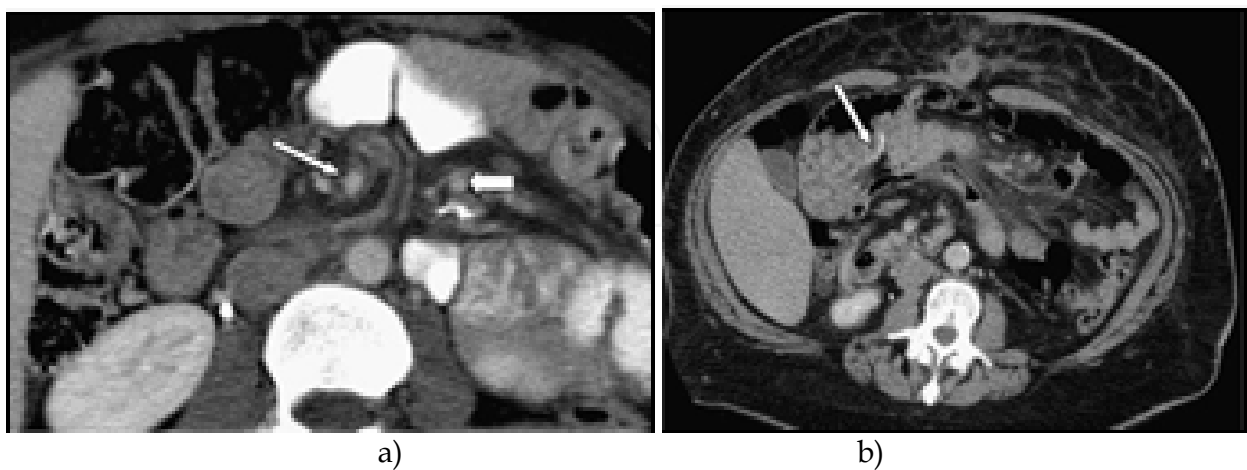


Fig. 9. Signs of SBO on CT. a) The mushroom sign. Note the mesenteric root passing through the jejuno-jejunosomy defect, bordered by the superior mesenteric artery (thin arrow) and the distal mesenteric branches (thick arrow). b) The jejunojejunosomy is displaced to the right side of the abdomen. (arrow)

(Reproduced from Iannuccilli J, Grand D, Murphy B et al. Sensitivity and specificity of eight CT signs in the preoperative diagnosis of internal mesenteric hernia following Roux-en-Y gastric bypass surgery. *Clinical Radiology* 2009; 64: 373-380. )

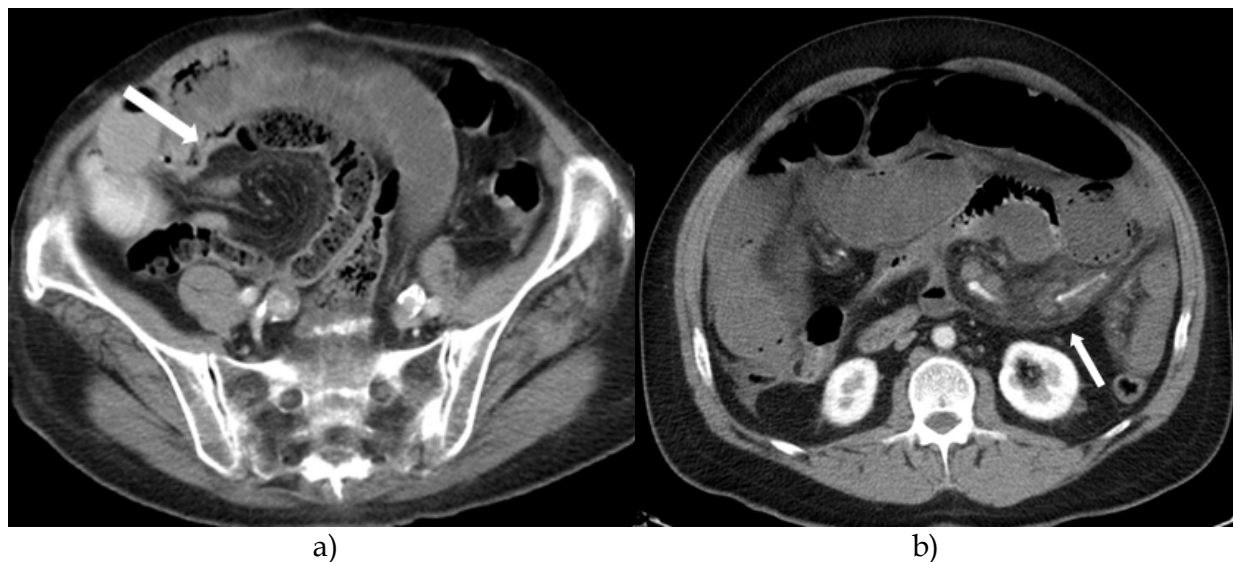


Fig. 10. CT scans showing a) the Hurricane sign (arrow) and b) enlargement of lymph nodes (arrow)

In a patient with history of a RYGBP who present with abdominal pain associated to abdominal bloating, nausea, vomiting and radiological findings suggestive of small bowel obstruction, the diagnosis is very easy. However, patients with episodic abdominal pain and no radiological findings may represent a real challenge. Because untreated internal hernias have a potentially high risk of complications, diagnostic by laparoscopy is recommended in those patients. (Pitt, 2008)

## 5. Management

Initial management of patients with SBO includes proper assessment and reposition of fluids and electrolytes. A nasojejunale tube may be needed for decompression in order to ameliorate the pain and to reduce the risk of bronchial aspiration at the time for surgery. Prophylactic antibiotics are highly recommended to prevent infections from bacterial translocation.

Once the diagnosis is established, surgical management is the only therapeutic option. The time between the diagnosis and surgery must be just the necessary to stabilize the patient, to get pain control and take care of additional problems that may be present such as severe hyperglycemia in diabetics.

Most patients may be treated by laparoscopy. Rapid sequence intubation is preferred in most patients. In the authors experience (Rodriguez & Herrera, 2010) the first step during the systematic surgical exploration is to explore Petersen's space by lifting the mesocolon on the right side of the alimentary limb. A loop of bowel protruding behind the alimentary limb makes the diagnosis of a Petersen's hernia. To assess the jejunojejunostomy, identification of the distal ileum is recommended. Once the ileocecal valve is identified, the small bowel is run between forceps all the way up. A cluster of dilated small bowel loops above the mesocolon in a patients in whom the RYGP was performed retrocolic, makes the

diagnosis of hernia through the mesocolic defect. Any bowel herniation must be reduced by gentle traction using atraumatic forceps and the defects should be closed using non-absorbable sutures. All potential sites for obstruction should be explored and all open defects must be closed even in the absence of an overt hernia. Figure 10 shows a hernia through the Petersen's space and proper closure of the defect after the hernia was reduced. In figure 11, a hernia through the mesentery at the jejunojejunostomy is shown as well as the space after closure

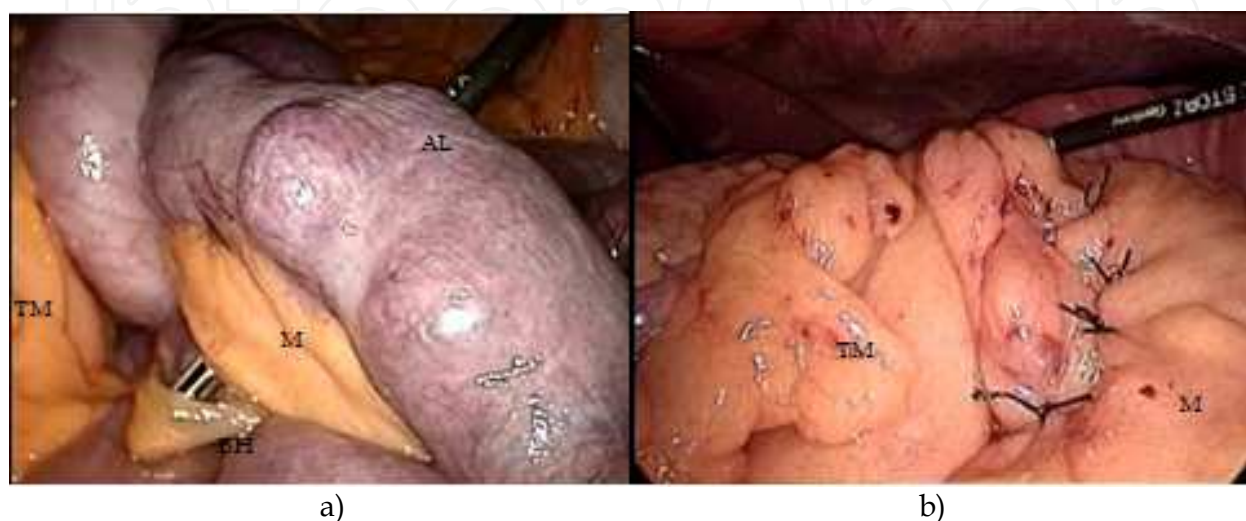


Fig. 10. a) Hernia through the Petersen's space and b) Petersen's space properly closed. TM transverse mesocolon, M mesentery, AL alimentary limb, BH bowel herniated.

Intestinal function usually recovers soon after surgery and patients are able to take liquid diet on the 1<sup>st</sup> postoperative day. Prokinetics may help in the process. Many patients can be discharged from the hospital within 24 hrs.

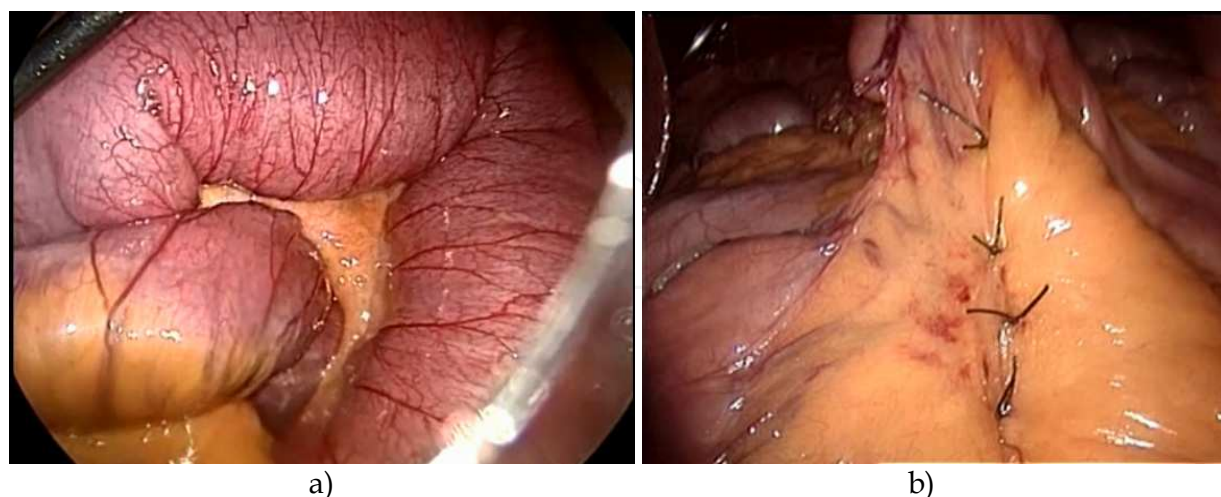


Fig. 11. a) Internal hernia through the Jejunal mesenteric defect and b) The mesenteric defect has been closed

The reported incidence of SBO from internal hernias has important variations in the surgical literature. In our experience, proper closure of all potential defects with non

absorbable sutures significantly reduces the incidence of internal hernias. (Rodriguez, 2010). In a recent study two different techniques in patients undergoing an antecolic and antegastric RYGB were comparatively analyzed. In the first group, the surgical technique included a wide opening of the mesentery at the level of the jejunojejunostomy and the Petersen’s space was left open. In the second group, only a small mesenteric window at the jejunojejunostomy was opened and both, the Petersen’s space and the mesenteric folds at the jejunojejunostomy were meticulously closed. The incidence of internal hernia was excessively high in the first group and it significantly dropped in the second group. Just as in an abdominal wall defect, mesenteric defects are potential sites of SBO. Because of the peristaltic and random movement of the intestine, it is feasible that at some point a loop of small bowel may get into the defect and become obstructed. Table 1 shows the comparative analysis of SBO in different series

1 <sup>st</sup> Author, year	Total No. Patients	SBO No (%)	Roux limb fashion	Internal Hernia No (%)	Jejunal defect	Petersen’s space	Trans mesocoli c defect
Higa 2003	2000	-	Retrocolic	63 (3.1)	14	5	44
Champion 2003	711	13 (1.8)	Both	6 (0.8)	1	1	4
Hwang 2004	1715	55 (3.2)	Both	17 (0.9)	8	-	9
Nguyen 2004	225	9 (4)	Retrocolic	4 (1.7)	2	-	2
Cho 2006	1400	21 (1.5)	Antecolic	3 (0.21)	-	-	-
Authors 2010	187¶	-	Antecolic	27 (14.4)	17	10	-
	172§	-	Antrecolic	2 (1.1)	2	0	-

\* Transverse mesocolic hernia  
¶Wide opening of jejunal mesentery and without closure of the Petersen’s defect.  
§ Without wide opening of jejunal mesentery and closure of the Petersen’s defect.

Table 1. Comparative results of revision from SBO after laparoscopic gastric bypass

It is important to mention that there are other sources of SBO after LRYGB such as kinking or narrowing of the intestinal anastomosis, intussuception and adhesions. Since internal hernias are more prevalent in these patients we decided to focus on the pathogenesis, diagnosis and treatment of internal hernias. Most surgeons agree that jejunojejunostomy should be performed using at least a 45 mm stappler. In order to reduce the risk of stenosis we recommend a 60mm anastomosis with manual closure of the common enterotomy or even a larger anastomosis (90mm using double firing of a 45mm stapler) when the common opening is also stapled. In the experience of the authors the most common site of an internal hernia when all defects were closed at the initial operation is the jejunojejunostomy.

6. Conclusions


SBO is a common complication after antecolic and antegastric LRYGB if mesenteric defects are not closed. Clinical presentation may be nonspecific, and the diagnosis frequently requires contrast imaging studies. Internal hernias can be successfully treated by



laparoscopy in most patients. The occurrence of internal hernias can be significantly reduced by careful closure of the mesenteric defects.

## 7. References

- Buchwald H, Avidor Y, Braunwald E, et al. (2004). Bariatric Surgery. A systematic review and meta-analysis. *JAMA*, vol 292, No.14, (October 2004), pp. 1724-37.
- Sjöström L, Lindroos A, Peltonen M, et al. (2004). Lifestyle, Diabetes and Cardiovascular Risk Factors After Bariatric Surgery. *N Engl J Med*, vol 351, No. 26 (December 2004), pp. 2683-93.
- Scopinaro N, Papadia F, Camerini G, et al. (2008) A comparison of a personal series of biliopancreatic diversion and literature data on gastric bypass help to explain the mechanisms of resolution of type 2 diabetes by the two operations. *Obes surg*, Vol 18, No.8, (August 2008), pp. 1035-8.
- Buchwald H, Estok R, Fahrbach K, et al. (2009). Weight and Type 2 Diabetes after Bariatric Surgery: Systematic Review and Meta-analysis. *Am J Med* vol 122, No. 3, (March 2009), pp. 248-56.
- Wittgrove AC, Clark GW. (1994) Laparoscopic gastric bypass, Roux-en-Y: preliminary report of five cases. *Obes Surg*; vol 4 No.4 (april 1994) pp 353-7.
- Nguyen N, Huerta S, Gelfand D, et al. (2004). Bowel obstruction after laparoscopic Roux-en-Y gastric bypass. *Obes Surg*, Vol 14, No. 2, (February 2004), pp. 190-6.
- Champion JK, Williams M. (2003) Small bowel obstruction and internal hernias after laparoscopic Roux-en-Y gastric bypass. *Obes Surg*, vol 13 No.4 (april 2003) pp 596-600.
- Hwang RF, Swartz DE, Felix EL. (2004) Causes of small bowel obstruction after laparoscopic gastric bypass. *Surg Endosc*. vol.18 No 11 ( November 2004) pp1631-1635.
- Higa KD, Tienchin H, Boone KB. (2003) Internal hernias after laparoscopic Roux-en-Y gastric bypass: incidence, treatment and prevention. *Obes Surg* vol 13 No. 3 (march 2003) pp350-4.
- Cho M, Carrodegua L, Pinto D, et al. (2006) Diagnosis and management of partial small bowel obstruction after laparoscopic antecolic antegastric Roux-en-Y gastric bypass for morbid obesity. *J Am Coll Surg*. vol. 202 No. 2 (February 2006) pp 262 - 268.
- Rogers A, Ionescu A, Pauli E et al. (2008) When is a Petersen's hernia not a Petersen's hernia. *J Am Coll Surg*. Vol 207 No 1 (January 2008) pp 121-4.
- Iannuccilli J, Grand D, Murphy B et al. (2009) Sensitivity and specificity of eight CT signs in the preoperative diagnosis of internal mesenteric hernia following Roux-en-Y gastric bypass surgery. *Clinical Radiology* vol. 64, no. 4 (april 2009) pp373-380.
- Gunabushanam G, Shankar S, Donald R et al. 2009 Small-Bowel Obstruction After Laparoscopic Roux-en-Y Gastric Bypass Surgery. *J Comput Assist Tomogr* vol 33 No.3 (march 2009) pp 369 - 375.
- Pitt T, Brethauer S, Sherman V et al. (2008) Diagnostic laparoscopy for chronic abdominal pain after gastric bypass. *Surg Obes Related Dis* 2008 vol, 4 No 3 pp 394-398.
- Rodriguez A, Mosti M, Herrera MF et al. (2010) Small Bowel Obstruction After Antecolic and Antegastric Laparoscopic Roux-en-Y Gastric Bypass: Could the Incidence be Reduced? *Obes Surg* vol 20, no. 1 (November 2010) pp 1380-1384.



### **Advanced Laparoscopy**

Edited by Prof. Ali Shamsa

ISBN 978-953-307-674-4

Hard cover, 190 pages

**Publisher** InTech

**Published online** 30, September, 2011

**Published in print edition** September, 2011

The present book, published by InTech, has been written by a number of highly outstanding authors from all over the world. Every author provides information concerning treatment of different diseases based on his or her knowledge, experience and skills. The chapters are very useful and innovative. This book is not merely devoted to urology sciences. There are also clear results and conclusions on the treatment of many diseases, for example well-differentiated papillary mesothelioma. We should not forget nor neglect that laparoscopy is in use more extensively than before, and in the future new subjects such as use of laparoscopy in treatment of kidney cysts, simple nephrectomy, pyeloplasty, donor nephrectomy and even robotic laparoscopy will be researched further.

### **How to reference**

In order to correctly reference this scholarly work, feel free to copy and paste the following:

Hugo Sánchez and Miguel F Herrera (2011). Small Bowel Obstruction After Laparoscopic Roux – En - Y Gastric Bypass, Advanced Laparoscopy, Prof. Ali Shamsa (Ed.), ISBN: 978-953-307-674-4, InTech, Available from: <http://www.intechopen.com/books/advanced-laparoscopy/small-bowel-obstruction-after-laparoscopic-roux-en-y-gastric-bypass>

**INTech**  
open science | open minds

### **InTech Europe**

University Campus STeP Ri  
Slavka Krautzeka 83/A  
51000 Rijeka, Croatia  
Phone: +385 (51) 770 447  
Fax: +385 (51) 686 166  
[www.intechopen.com](http://www.intechopen.com)

### **InTech China**

Unit 405, Office Block, Hotel Equatorial Shanghai  
No.65, Yan An Road (West), Shanghai, 200040, China  
中国上海市延安西路65号上海国际贵都大饭店办公楼405单元  
Phone: +86-21-62489820  
Fax: +86-21-62489821



© 2011 The Author(s). Licensee IntechOpen. This chapter is distributed under the terms of the [Creative Commons Attribution-NonCommercial-ShareAlike-3.0 License](https://creativecommons.org/licenses/by-nc-sa/3.0/), which permits use, distribution and reproduction for non-commercial purposes, provided the original is properly cited and derivative works building on this content are distributed under the same license.

IntechOpen

IntechOpen