

# We are IntechOpen, the world's leading publisher of Open Access books Built by scientists, for scientists

6,900

Open access books available

186,000

International authors and editors

200M

Downloads

Our authors are among the

154

Countries delivered to

TOP 1%

most cited scientists

12.2%

Contributors from top 500 universities



WEB OF SCIENCE™

Selection of our books indexed in the Book Citation Index  
in Web of Science™ Core Collection (BKCI)

Interested in publishing with us?  
Contact [book.department@intechopen.com](mailto:book.department@intechopen.com)

Numbers displayed above are based on latest data collected.  
For more information visit [www.intechopen.com](http://www.intechopen.com)



# Transubilical Laparoscopically Assisted Pediatric Surgery

Stjepan Visnjic

*Children's hospital Zagreb, KBCSM  
Medical school University of Zagreb  
Croatia*

## 1. Introduction

Endoscopic surgery has revolutionized pediatric surgery in the past twenty years. Number of operations that were previously performed through abdominal wall incisions can now be completed using endoscopic surgical techniques. The degree to which pediatric surgeons have incorporated minimally invasive surgery into their daily practice is amazing as well as the range of performed procedures. By the end of the year 2010, more than 43000 papers have been published in prereviewed medical literature with the title containing words minimally invasive or laparoscopy. Among them, more than 3500 were in the field of pediatric surgery. Around seventy procedures have been described and one quarter of them has wide acceptance as the treatment of choice.

Continuous efforts to minimize scarring from surgery led surgeons to explore new innovative and even less invasive solutions. Laparoscopic surgery using instruments in reduced sizes (mini & microlaparoscopy), two-port endoscopic surgery and less visible port laparoscopy (suprapubic and lateral –“hidden incisions”) were described as initial attempts. NOTES natural orifice transluminal endoscopic surgery as a completely non visible scar procedure advocated by some general surgeons hasn't found supporters among pediatric surgeons. Idea of an endoscope passing through a natural orifice and then a internal incision in the stomach, vagina, bladder or colon, thus avoiding any external incisions or scars to perform surgery has numerous limitations. Question whether the improved cosmesis is worth the risk of visceral injury is the basic complaint about NOTES.

So for the vast majority of surgeons the most promising less invasive endoscopic surgery concept is a single incision laparoscopic surgery. This is a broad concept of single entry port surgery, applicable in abdomen, pelvis and thorax, performed by laparoscopes, scopes with working channels and endoscopes with flexible tips, and completed intraabdominally or partly extracorporeally. Plenty of terms and acronyms exist to describe broad concept of single incision surgery. Laparoendoscopic single-site surgery consortium for assessment and research (LESCAR), a multidisciplinary group of experts of various specialties, has recently reached a consensus on nomenclature and advocate the term laparoendoscopic single-site surgery (LESS).

This concept has gained immense popularity throughout the world within the past few years. General surgeons as well as pediatric surgeons perform LESS in wide range of indications and volume of procedures inclines steadily.

In pediatric surgery, two basic concepts of single incision surgery exist and appropriate terminology for some of the procedures performed is still missing. One group of procedures is single site laparoscopic surgery using multiports and the set of LESS- adjusted instruments. Multiports (Endocone, X-cone, TriPort, UNI-X, SSL3P) are specially designed ports based on the principle of one-entry-multiple-working channel devices. Some instead of multiports use one large caliber and two adjacent trocars through the single fascia incision. Surgery was performed using two or three specially adjusted, highly maneuverable instruments (S-shaped, bent or articulating instruments) in the manner similar or very much alike conventional laparoscopy. LESS performed by multiports provide independence of instrument movements and a steady field of vision. Traction and triangulation of tissue prior to dissection are in limited extent but still sufficient to fulfill basic requirements of laparoscopic operative technique.

Another concept is single port laparoscopic surgery with the use of a operative laparoscope. These scopes reduce the number of ports placed during minimally invasive operations by providing both visualization and a operative channel. Surgeons use laparoscopic instruments and operate through the working channel of the operative endoscope. Procedures could be completed intraabdominally or a part of the surgery could be done in the manner of open surgery extracorporeally. The group of procedures which combines laparoscopy and extracorporeal open surgery is the most known as transumbilical laparoscopically assisted surgery- TULA surgery. Completion of procedure extracorporeally in the manner of conventional surgery eliminates need for expensive devices; staplers cartridges, endoloops and clips, consequently TULA gained additional popularity because of low expenses. Some authors report favorable results of TULA in term of operative time comparing to open and conventional laparoscopy. The reported advantages of TULAA as a technique that reduces the cost of laparoscopy, while preserving all the benefits of laparoscopic surgery made this technique widely popular in developing countries. This is an update of the possible uses of TULA for the anomalies and conditions encountered in infants and children.

## 2. Basic principles of operative technique

A traditional laparoscopic procedure involves three trocars and requires three separate incisions. One port is placed for the laparoscope, and two additional ports are placed for retraction and dissection. Surgeons use instruments freely while the field of vision is steady and visualization could even be improved as the assistant rotates 30 or 45 degree scopes.

TULA is basically a single port technique. In some cases an accessory port is placed to assist in retraction. What makes this procedure specific for use is the fact that all intraabdominal dissection that needs to be done is made with an instrument which passes through the working channel of the telescope. Therefore, special equipments are necessary, including a telescope with a working channel and long shaft 420-430 mm instruments (Figure 1). Standard set of long shaft 420-ø5mm instruments include; a Maryland dissector, fine grasping forceps, a hook-cautery, curved scissors and a aspiration catheter because standard suction devices usually can not pass through the working channel of the scope or the length of the suction device is not sufficient. The approach can sometimes be demanding because of the unsteady field of vision. Movements of the instrument change the position of the laparoscope and produce sliding of the operated substrate out of the field of vision. Another problem concerning visibility is the parallax of working instruments and the field of vision. Therefore, an adjusted operative technique using minimal and gentle movements is required.




Fig. 1. Telescope with a working channel and long shaft 420-430 mm instruments

Basic preoperative considerations include thorough explanation of the procedure to the patient and parents. As with any surgical procedure, the patient will be required to sign a consent form. Proper selection of patients that are not seriously compromised would be wise choice during the learning curve. Precise procedure planning based on accurate preoperative diagnostic is necessary.

Operative room set up and instrumentation check up are mandatory. Compatibility of instruments and accessories is of utmost importance because most commercially available suction devices are too short for usage through the working channel of the scope. All suction activities need to be done by suction catheters. Procedure should be understood by all team members to reduce confusion during procedure and reduce operative time.

All procedures are performed under general anesthesia, with endotracheal intubation, assisted ventilation, muscle relaxants and proper analgesia. Nasogastric tube decompression and bladder catheterization are done routinely. Single perioperative dose of antibiotic can be administered.

Transumbilically assisted procedures usually have four main steps. Target organ is freed from intraabdominal adhesions. Exposition of the operative substrate onto the abdominal surface with precautions of slippage and spillage is the next step. Removal of substrate by open technique is the third part. Finally, the scope is reinserted to check the condition of the stump, exclude bleeding and perform final washings.

While several port reinsertions are frequently necessary to complete the operative procedure, creation of an appropriate easy-entry abdominal approach is recommendable. The 12 mm port is inserted through the umbilical incision by open technique. Some procedures could be accomplished through 5 mm ports and a small diameter scope, but these scopes provide poor visibility, mostly due to the instrument's optics and the fact that part of the screen is obstructed by the grasper. The open insertion of the first port could be sometimes time consuming, but much safer, especially in neonates with elastic abdominal wall, proximity of vital structures and potentially still patent umbilical vessels. The

possibility of patent umbilical vessels in neonates is not a reason to abandon umbilical placement of the laparoscopic port as it is feasible to identify and avoid these structures by meticulous preparation. Once, the incision in the midline is done, traction sutures on the both ends will help to manipulate with the abdominal wall, help to reduce accidental air leakage by approximating incision edges and help to reinsert the port in the case of substrate slippage during extraction. Pneumoperitoneum of 8 mmHg is standard for neonatal laparoscopy and usually sufficient to enable excellent visualization of the whole abdomen and pelvis. Visualization could be further improved by a cranio-caudal slope and an additional abdominal wall lifting by traction sutures on the edges of the incision site. Adjusted intraabdominal pressures are necessary with increasing age. For preschool and school children, pressure up to 10mmHg is usually sufficient, while for adolescents, pressures could reach values for mature population.

Gentle synchronous movement of the camera and instruments provide sufficient visibility and exposure. Caution should be focused on coagulation while thermal injury is a threatening complication in a very limited working space.

After the port removal, fascia is closed by interrupted absorbable sutures and a single anchorage skin suture umbilicoplasty is performed to restore the shape of the umbilicus.

Finally, it is important to stress out three tips which enable safer and simpler procedure. Traction sutures on edges of fascia incision enable easier port reinsertion and wound closure at the end of procedure. Testing mobility of the operative substrate intraabdominally prevents substrate slippage during extraction and tears of the mesentery and adhesions, so in this way serious bleeding can be prevented. Finally, inspection of the abdominal cavity at the end of the procedure can be performed equally well in number of cases with manual abdominal wall lifting, so there is no need for CO<sub>2</sub> reinsufflation and time can be saved.

### 3. Indications

In a particular condition, several important facts will determine the indication for TULA. The clinical status and the overall patient condition, previous experience in endoscopic surgery, available technology and willingness of hospital management to afford special telescope and adjusted set of instruments, the availability of OR, support from other staff and legislative. However, for some conditions widely accepted for conventional laparoscopy, TULA is suitable. TULA is for simple appendicitis, as the most common pediatric emergency, a diagnostic and a therapeutic approach with potentially numerous advantages. At the same time, TULA is suitable for various elective pediatric surgical procedures as follows; nonpalpable testis, exploration for abdominal pain, diagnostic and staging lymph node biopsies, ovarian cysts, biopsies for Hirschsprung's disease and leveling colostomy creation, urachal remnants surgery, gastrostomy and treatment of empyema. Although feasibility has been demonstrated in some procedures such as lung wedge resection and inguinal hernia repair, I prefer to use other than TULA approach.

#### 3.1 Simple appendicitis

Transumbilical laparoscopically assisted appendectomy is the most common single-port operation performed in pediatric surgery. Procedure begins with universal steps; operative creation of easy-entry abdominal access, pneumoperitoneum and insertion of the working



scope. The omentum should be moved away and appendix properly exposed. Sometimes, cranial retraction of the cecum helps. Rarely an additional port for traction is necessary. Once located; the appendix is freed from adhesions with a dissector, then grasped at the tip and extracted onto the abdominal surface via the umbilical port, with simultaneous release of the pneumoperitoneum. All three tools; port, scope and instrument should be brought out of abdomen together with appendix (figure 2) for this maneuver. The appendix is skeletonized off its mesenteric supply and divided at its base as in the open technique. The covering of the stump with the peritoneum is described, but it is not clear whether peritonealization has any particular benefit in reducing frequency of intra abdominal infections. Majority of surgeons advocate exposed appendiceal stump as in conventional laparoscopy. The stump is dropped back into the peritoneal cavity and the umbilical port is replaced. Manual lifting of the abdominal wall usually enables sufficient working space and eliminates need for reestablishing of pneumoperitoneum. Then, the scope is reinserted to ascertain stump condition and check up for bleeding. Eventually, washout of the abdominal cavity is undertaken. Method is suitable even during infancy. According to currently published reports, TULA appendectomy technique seems to result in more complications but this difference is not statistically significant. Complications were minor port-site wound infections successfully treated with wound care and sometimes antibiotics. Complication rate may be explained by the technique of drawing the inflamed appendix through the umbilical wound. The absence of intraoperative complications and the minimal conversion

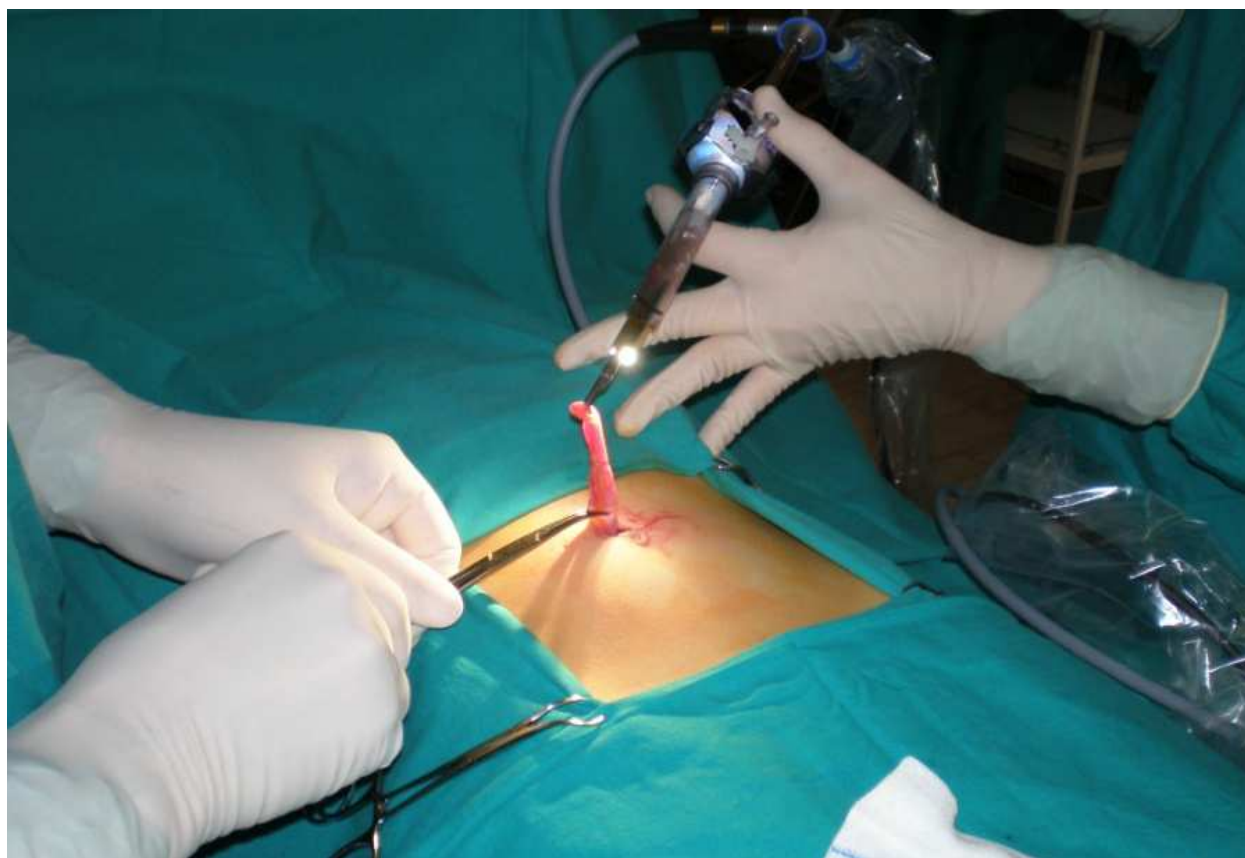

Fig. 2. Port, scope and instrument should be brought out of abdomen together with appendix

rates confirm the safety of the technique. Reduced number and length of incisions lead to better cosmesis. Reduced cost is an additional advantage of TULAA. It is shown that higher cost of conventional laparoscopy is solely attributable to the purchase price of the used supplies. In limited resources, saving achieved by TULAA could be significant.

### **3.2 Exploration for abdominal pain**

Almost all diagnosis and conditions clinically indistinguishable from appendicitis could be verified by operative scope and a vast majority of verified conditions could be solved in very similar manner as TULAA. The same principles as for appendectomy can be applied to any operation in which the operative telescope is used for acute abdominal pain. Mesenteric adenitis and inflammatory conditions of the terminal ileum can be verified and extension of the inflamed bowel can be accurately measured. The terminal loop of inflamed bowel can be brought outside for biopsies and enlarged mesenteric lymph nodes can be taken for histology. Omental torsion can be clearly indentified, infracted omentum can be brought extracorporeally and partial or subtotal omentectomy can be done very easily, followed by peritoneal washings and control of haemostasis at the end of the operation. Meckel diverticulum could produce pain secondary to ulceration or inflammation. Other omphaloenteric duct remnant; sinus or band can produce pain due to mechanical obstruction. In the presence of Meckel diverticula, exposure on the umbilical incision and extraabdominal resection of the diverticula is feasible. Wedge excision or total resection and end to end anastomosis is possible. If an end to end anastomosis is performed, the bowel might be congested and it may be extremely difficult to reduce bowel loop back in to the abdomen. Incision should be enlarged at the beginning of procedure to prevent vascular bowel injury during surgery. Fibrous bands or other Vitelline duct remnants can be brought outside and resected. If coagulation and dissection is performed intraabdominally, the same principles as for adhesion release after previous abdominal operations should be applied. Idiopathic intussusception can be noticed and gently reduced by traction but sometimes additional port for counter traction is necessary. Gonadal pathology and ovarian torsion can be found even in infancy and prompt reaction and detorsion could prevent infarction and rupture of the ovary and definitive lost of gonadal tissue.

### **3.3 Diagnostic biopsies, tumor staging and lymph node sampling**

#### **3.2.1 Diagnostic biopsies for uncertain benign conditions**

Biopsies could help in differentiation in the cases of persistent hepatomegaly and splenomegaly of uncertain etiology, whether it is infective, metabolic or malignant. The hepatosplenic form of Cat scratch disease is a rare occurrence among children with intact immune system, and we previously published personal experience with laparoscopy. Liver and splenic masses of unknown origin, giant granulomas or tiny nodules could be precisely collected and analyzed.

#### **3.3.2 Lymph node sampling**

Patients who require mesenteric or pelvic lymph node sampling or lymphadenectomy are candidates for single-port laparoscopy. It is especially applicable for pediatric hematologic malignancies with primary abdominal presentation; lymph node involvement, wide dissemination and malignant ascites. In juvenile myelomonocytic leukemia abdominal symptoms could last over a period of weeks or months. The primary

indication for diagnostic laparoscopy in pediatric hematological malignancies and lymphomas is a tissue diagnosis through biopsy of intraabdominal lymph nodes in the absence of peripheral lymphadenopathy, particularly when percutaneous core needle biopsy has been nondiagnostic. Procedures were performed through a single umbilical incision using an operative scope. Lymph node could be extracted or enucleated from bulking sites by meticulous preparation. For single nodules, problems could arise in the yield of adequate nodal counts. Another possibility is mesenteric nodules sampling. Exposure of a bowel loop on the umbilical incision and extracorporeal lymph node dissections could be the simplest solution.

### **3.3.3 Biopsies for abdominal masses**

An abdominal mass in an infant or a child is a challenging diagnostic problem. It includes a spectrum of lesions of diverse origin and significance. Beyond the newborn period, there is a significant increase in malignant tumors. Therefore, all soft-tissue lumps that persist or grow should be biopsied. Biopsy is the only reliable way to determine or exclude malignancy. If needle biopsy fails to obtain sufficient or appropriate sample, tissue can be obtained via surgical biopsy. Although port site metastases are now reported less frequently, this serious complication of laparoscopic cancer surgery can still occur. Another serious complication is peritoneal seeding due to malignant spillage and tumor implantation. However, same complication can occur in open surgery. We prefer laparoscopic guidance for needle biopsies and active hemostasis in cases of persistent bleeding on biopsy site. For identification of the most appropriate puncture site operative scope could play a crucial role. Natural topography or adhered organs can make an obstacle for proper puncture so they should be gently removed by a grasper or a dissector to provide most appropriate biopsy samples.

### **3.3.4 Staging**

Indications for staging laparoscopy in pediatric surgery are rare. Staging laparoscopy is indicated for primary staging or even restaging of Hodgkin's lymphoma when accurate staging affects decisions for appropriate treatment and prognosis. Single port laparoscopy with operative scope is a worthily attempt and additional port could be a reasonable spare solution. Gynecologists tend to expand the role of laparoscopy in the treatment of more gynecological malignancies. There are reports of single-site staging surgery for oncologic procedures. Potential benefits remain to be assessed in comparison with more conventional minimally invasive approaches. Pre-treatment laparoscopic staging in early-stage disease for therapeutic strategies planning and the laparoscopic second-look procedures in disease status assessment at the completion of adjuvant chemotherapy could be done in selected patients.

### **3.4 Nonpalpable testis – Fowler-Stephen procedure stage I**

The length of testicular vessels is the main limiting factor in the descent of the testes in the scrotum. Since Fowler and Stephen proposed the division of testicular vessels, high and as far from the testes as possible to maintain collateral blood supply, this approach became standard in the treatment of high intra-abdominal testes, although testicular atrophy as a potential complication exists. Cortesi introduced the diagnostic laparoscopy and Jorden first completed a laparoscopic orchidopexy. Further investigations proved laparoscopic transection of the testicular vessels as safe in boys with high abdominal testes that do not reach the scrotum after laparoscopic high retroperitoneal dissection. Two-stage Fowler-



Stephens orchiopexy appears to carry a higher rate of success than the single stage approach. First step in the treatment of nonpalpable testes is abdominal exploration by an operative scope. The decision to perform a staged Fowler-Stephen orchidopexy was based on the distance of the testis from the deep inguinal ring on laparoscopy. If the distance was more than three centimeters, we proceeded to a staged Fowler-Stephen orchidopexy. In the first stage, performed completely as single port, opening in the parietal peritoneum is created by 430-ø5mm scissors connected to diathermy for minor coagulation. Dissector is used for vascular plexus mobilization and testicular vessels are finally cauterized by a hook cautery. This procedure yields a fair success rate. The magnification and wide mobilization of laparoscopy probably allows better preservation of the collateral vascular supply than open exploration. Transsection of the vessels by diathermy is a very safe, cost-effective method.

### 3.5 Gastrostomy

Gastrostomy may be indicated in numerous situations. For all children with conductible esophagus PEG (percutaneous endoscopic gastrostomy) is the treatment of choice according to less invasiveness. The principle is endoscopic approximation of the stomach and peritoneum followed by percutaneous entrance into the stomach by cannula. Percutaneous cannula insertion is guided by transillumination. However, the morbidity of PEG placement still remains around or slightly less than 10%, due to injury to the intestine, colon or esophagus.

For those children whose esophagus is not passable for flexible endoscopy, e.g. refracter strictures, epidermolysis bullosa, (Figure 3) etc, endoscopic guidance by transstomach illumination is not possible. Then, gastrostomy made by an operative laparoscope placed trough the umbilical port could be one of the options. The stomach and abdominal wall can be visualized directly thus limiting the chance of inadvertent injuries. Stomach is fixed by a fine grasper and approximated to the abdominal wall. Two percutaneous sutures are placed and PEG cannula can be inserted into the stomach as in endoscopic PEG placement, but now

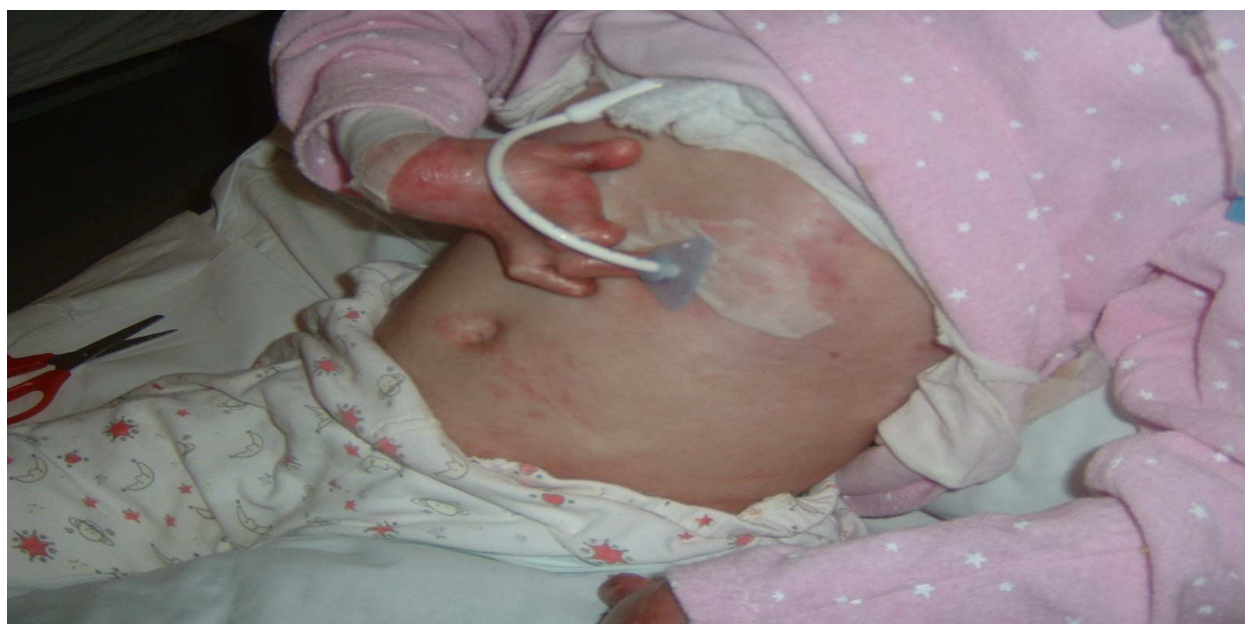

Fig. 3. Laparoscopic gastrostomy in epidermolysis bullosa

under visual control. Rest of the procedure is very much alike PEG procedure (Russell introducer technique). A guidewire is inserted through the cannula and dilation of ostomy channel is performed using dilators from PEG set. A series of dilators are used to increase the size of the gastric opening. Once sufficient width is achieved, PEG tube is inserted over the wire into the stomach under visual control and catheter balloon is insufflated with fluid. The fixation plate is then placed ensuring that sutures pass through the holes of fixation plate. Finally, knot tying anchorages fixation plate and stomach. This type of laparoscopic gastrostomy involves two skin incisions an umbilical and a stoma site incision.

Some authors prefer gastrostomy with a single incision performed on stoma site. After introduction of port and operative scope, the stomach is indentified by the instrument which passes through the scope working channel. Greater curvature is grasped at the appropriate location and brought out through the trocar site. The gastrostomy is then sutured to the fascia and a primary gastrostomy button is placed.

### 3.6 Urachal remnants

Urachal defects are rare with urachal cysts, being the most common anomaly occurring in approximately 1/5,000 births. Urachal cyst, embryological remnant of the allantois originally communicates with the vertex of the bladder. Symptoms could be infection or less often recurrent umbilical secretion. Excision is curative. Abdominal exploration by usage of an operative scope provides clear insight in retropubic Retzius space and as a diagnostic procedure should be advocated in all cases of umbilical secretion when routine imaging techniques fail to show pathologic substrate. Procedure provides reliable diagnosis and enables safe and efficient treatment of pathology as single port. The dissection is performed on the anterior peritoneal wall. Cyst or urachal bend can be grabbed and exposed together with the vertex of the bladder on umbilical port. Cyst should be excised and the vertex of the bladder sutured with sutures in two layers. Bladder decompression by a catheter is mandatory. Laparoscopic approach shown in the previous case made it possible to minimize a long vertical incisional scar and related complications.

### 3.7 Biopsies and leveling colostomy for Hirschsprung's disease

Once the diagnosis of Hirschsprung disease is established by rectal biopsy, primary pull through is the treatment of choice. The presence of associated anomalies may dictate a staged approach. Immediate operation should be undertaken if irrigations are ineffective and leveling colostomy should be performed.

By the use of the operative scope, mobile parts of the colon can be exposed on the umbilical incision and serial full thickness biopsies can be made in order to identify the most distal segment of the bowel with ganglion cells. In spite of the fact that gross appearance of the colon can suggest a transition zone it is smart to perform biopsies on at least four locations of the colon. We recommend biopsies on the rectosigmoid, the sigmodescendent flexure, the splenic flexure, and the hepatic flexure. All these segments can be easily brought to the umbilical incision and biopsies can be performed as in open surgery with full thickness sampling and closure of the biopsy sites by sutures. The transition zone should be identified with a frozen section biopsy. A colostomy above the transition zone in such cases is life protecting and should be performed in the same act. Additional trocar should be inserted at the place of the ostomy creation and the appropriate segment of the colon marked by sutures during biopsies should be brought out through the trocar site. A loop of bowel is secured by sutures to the incision in the abdominal wall. Colostomy is then finished in the traditional way. By this approach it is possible to create colostomy on all levels of colon, sigmoid, splenic or hepatic flexure (Figure4).

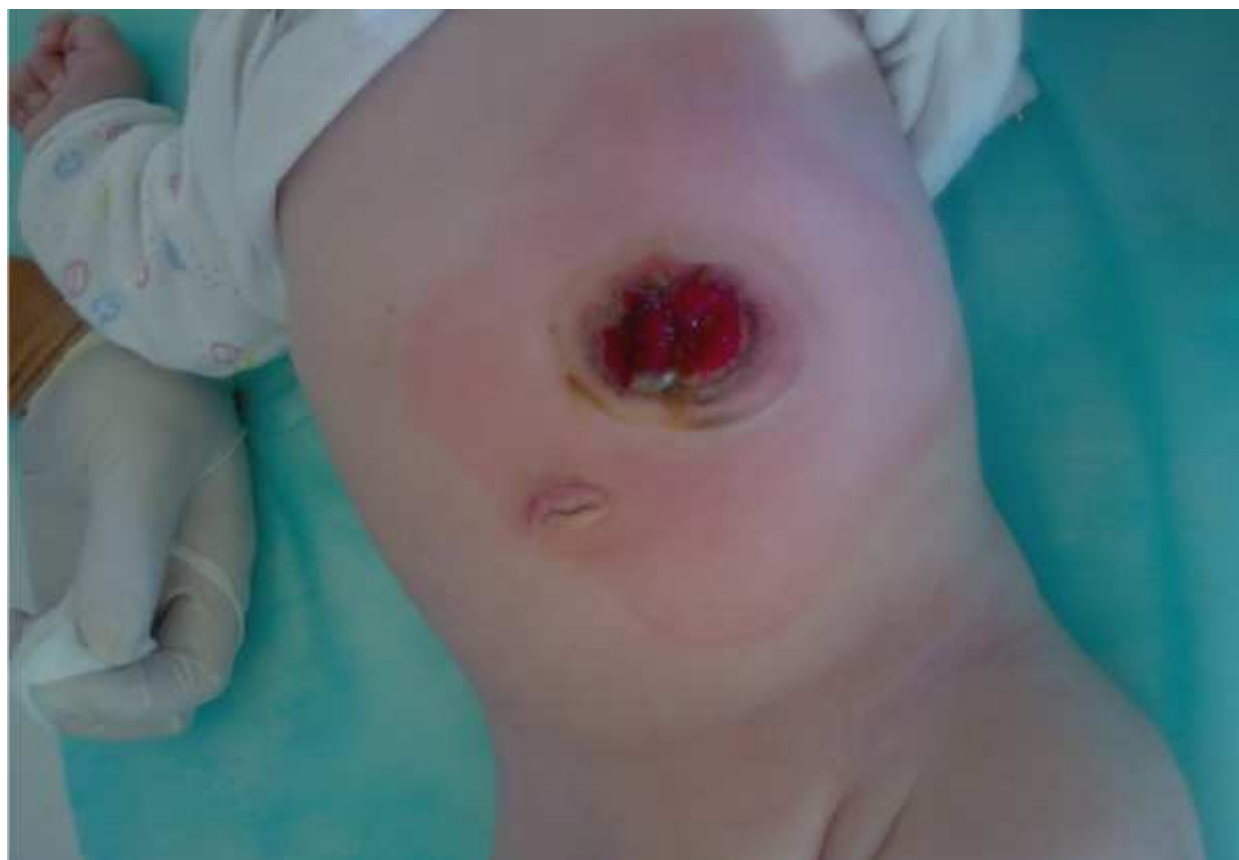

Fig. 4. Single port leveling colostomy after serial biopsies

### 3.8 Ovarian cyst torsion, infarction and amputation

Due to the stimulation by maternal hormones, cystic changes in fetal ovaries can be noticed in as much as one third of all female newborns. Hormonal imbalance during puberty is the reason for another peak of incidence among adolescents. The routine ultrasound scan as well as the improved US resolution have increased detection of cysts and allied gonadal pathology. Ultrasound patterns and cyst size have a prognostic value. Simple cysts greater than 5 cm in diameter have a greater chance of complications such as enlargement, rupture, bleeding and torsion. Shift from simple to a complex US pattern during follow up and verified debris, septation and solid component suggest complications. High incidence of complications is an argument in favor of surgical intervention regardless of symptoms or age of the patient.

Author prefers two basic approaches. For simple cysts larger than 5 cm, laparoscopic decompression can be done. Cyst is identified and drained percutaneously by a suction needle.

For complicated cysts, partial decompression and size reduction is done as the initial procedure by a puncture of the cyst. Second step is cyst exposure through the usage of a instrument and a operative scope on the umbilical incision. Incision enlargement is done if necessary. Rest of the cyst is removed on the abdominal wall as a open technique either by free cyst wall resection or by deflated cyst enucleation and if possible, ovary sparing surgery and tunica albuginea reconstruction.

Three major issues exist with single port laparoscopy during infancy and puberty considering dissection, elimination and puncture needle manipulation.

If the cyst wall is attached to the parietal peritoneum, dissection is necessary. By pushing cyst forward, loose adhesions are exposed. Dissection of adhesions can be done by scissors' tip (curved tip scissors) as close as possible to the peritoneal side in order to preserve the integrity of cyst wall until the whole cyst is completely freed and mobile (Figure 5).

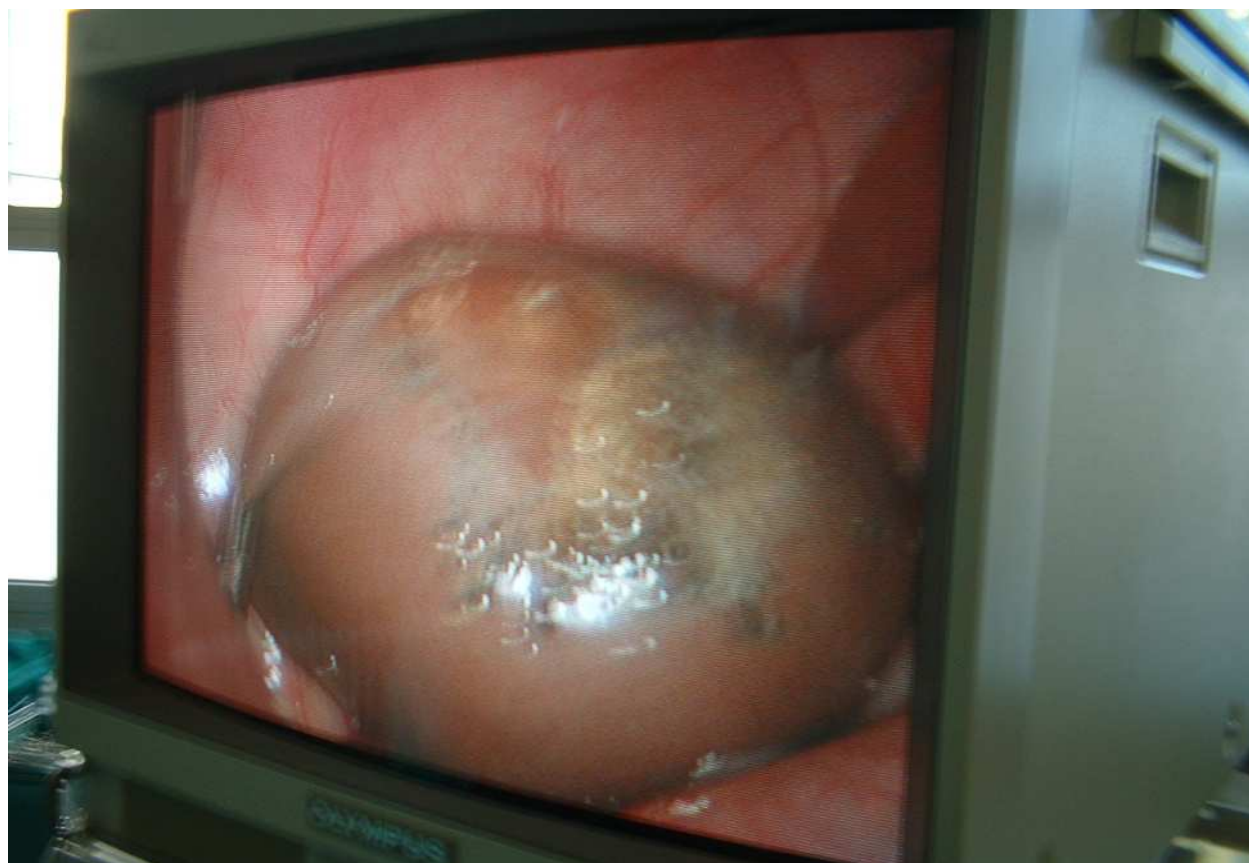

Fig. 5. Preserved integrity of the cyst after laparoscopic mobilization

If the ovary has undergone irreversible changes, elimination of bulky necrotic tissue can be a problem. Two possible solutions are available and decision should be made on case to case basis. The cyst could be suctioned to fit the size of the umbilical port and removed combined with incision enlargement, or it could be brought to the umbilical incision, capsule incised, solid component enucleated and then removed in reduced size as gall bladder removal for cholelithiasis.

Finally, some tips regarding manipulation with puncture needle. It has been previously reported that the suction needle has a tendency to slide on the cyst and to cause an injury of adjacent organs in the presence of negative pressure. Visualization of the puncture site by camera and cyst fixation during puncture by the instrument which passes through the scope working channel minimizes the risk of slippage. Once puncture is done, a grasper placed on the puncture site around puncture needle solves the problem of potential fluid leakage and needle slip-out and enables manipulation with decompression needle inside the cyst in the cases of septation.

### 3.9 Treatment of empyema

Inflammatory fluid and debris in the pleural space as result of ongoing infection usually resolves after therapy. Some effusions do not resolve in spite of prolonged antibiotic



therapy. Inflammatory response can proceed until adhesive bands form. The infected fluid becomes loculated pus in the pleural space. No clear consensus has been reached concerning the optimal therapeutic strategy for advanced empyema. We consider thoracoscopy may be indicated only if chest tube drainage is inadequate and ineffective because of tube clogging and multiple loculations. Prior thoracoscopy, serial ultrasound examinations should be performed on daily basis in the patient in a sitting position. Ultrasonography may provide information about the size, position and the viscosity of the lesion. Ultrasonography may also reliably demonstrate septa in the pleural fluid collection but the most important sonography could determine trocar insertion level. Scope insertion should be planned at least two intercostals space under or above the locus of empyema collection determined by ultrasound. Intrathoracic pressure up to 5 mmHg will collapse or partially collapse the lungs and improve visualization. Decortication and fluid aspiration are procedure goals. Decortication and release of the lung is a delicate procedure and can result in serious bleeding. Therefore, it is not clear whether total decortication is necessary or only partial decortication could be sufficient, especially having in mind the high incidence of readhesions. Limited experience showed that division of adhesion is possible using a Maryland grasper through the scope. Dissection should be done as close as possible to the parietal pleura and the chest wall while preserving pulmonary tissue. We found no need for a complete excision of all adhesions but only resection of the septa and a conversion of multilocular lesion to a single volume process. Sufficient size chest tube insertion should be done on the lowest point to enable sufficient drainage.

#### 4. Conclusion

Single-port surgery has evolved significantly in the past few years and has been shown to be valuable, safe and effective alternative to traditional laparoscopy in the performance of minimally invasive operations. Pelosi in 1992 published first appendectomy, done through a puncture on the umbilicus incision. An idea to apply principles and strategies of both procedures, laparoscopy and open surgery and thus compile advantages, resulted in development of laparoscopically assisted techniques- TULA for various indications. This approach represents a natural progression of minimal access surgery towards less invasive approach and is now a significant portion of LESS. Elastic abdominal wall and relatively short abdominal distances to the umbilicus made transumbilical laparoscopically assisted surgery especially feasible during infancy and childhood.

Clear advantages of TULA are fewer incisions and decreasing costs. Fewer incisions minimize scars from surgery and lead to improved cosmesis. But, fewer incisions also slightly reduce operative time concerning time needed for insertion and closure of additional port sites and some authors reported statistically significant time saving for TULA-appendectomy in comparison to conventional laparoscopy. Finally, single incision eliminates most frequent complications associated with additional port insertion like hemorrhage due to injury of the inferior epigastric vessels, gastrointestinal lesion or ureter injury.

In spite of reported decline in cost of laparoscopic instruments and supplies during time, laparoscopic operative procedures are still more expensive than open surgery. Cost-effectiveness of laparoscopic surgery is based on the fact that the operative cost surplus is outnumbered by secondary savings associated with decreased hospital stay and earlier resumption to normal activities. In TULA, cost of operative procedure usually equals cost of

open surgery and operative cost surplus of laparoscopy is eliminated. At the same time, TULA procedure provides clinical benefits and secondary savings associated with laparoscopy.

Some authors report improved patient outcomes like decreased pain and quicker recovery as additional advantages but controlled randomized trials to confirm that data are still missing.

However, this technique, although very popular, has certain limitations. Little or no formal guidance, training or structured protocols exist at the moment. Therefore, a significant role in maximizing patient safety is setting threshold for conversion to conventional three port laparoscopy or even open surgery appropriately low. Some argue that TULA may lead to an increase in umbilical wound infections. Further investigations and bigger series of cases are necessary to give us clear picture in the incidence of these infections. Some reported difficulties when performing TULA in larger adolescents, but with certain precaution measures, surgery is done routinely in adult population too. Finally, one instrument is not sufficient for more complex and demanding surgery, but operative scope enables creative solutions for various surgical situations even in the complex MIS procedures.

To have a complete insight into problem maybe the fact that PUBMED search for words- transumbilical single port laparoscopy gives 519 results, and if filter age is added; All Child: 0-18 years- result is 96 published papers. 72 of 96 papers were published in the last five years, and thus provide a proof how challenging and vibrant part of surgery TULA is. Simplicity of most TULA procedures and low complication rate reported so far amplified reported benefits of transumbilically assisted approach. It makes TULA potent alternative to traditional MIS.


## 5. References

- Aziz O, Athanasiou T, Tekkis PP, Purkayastha S, Haddow J, Malinovski V, Paraskeva P, Darzi A 2006 Laparoscopic versus open appendectomy in children: a meta-analysis. *Ann Surg* 243:17-27
- D'Alessio A, Piro E, Tadini B, Beretta F 2002. One-trocar transumbilical laparoscopic-assisted appendectomy in children: our experience. *Eur J Pediatr Surg* 12:24-7
- Dutta S. 2009. Early experience with single incision laparoscopic surgery: eliminating the scar from abdominal operations. *J Pediatr Surg*. Sep;44(9):1741-5.
- Jones VS, Cohen RC. 2008. Two decades of minimally invasive pediatric surgery *Pediatr Surg. Sep*;43(9):1653-9.
- Marietti S, DeCambre M, Fairbanks T, Kling K, Chiang G. 2010. Early experience with laparoendoscopic single-site surgery in the pediatric urology patient population. *J Endourol. Aug*;24(8):1321-4.
- Koontz CS, Smith LA, Burkholder HC, Higdon K, Aderhold R, Carr M 2006. Video- assisted transumbilical appendectomy in children. *J Pediatr Surg* 41:710-2
- Little DC, Custer MD, May BH, Blalock SE, Cooney DR 2002. Laparoscopic appendectomy: An unnecessary and expensive procedure in children? *J Pediatr Surg* 37:310-7
- Pelosi MA 1992. Laparoscopic appendectomy using single umbilical puncture (minilaparotomy). *J Reprod Med* 37:588-594
- Saxena A., Hollwarth M; 2009. *Essentials of Pediatric Endoscopic Surgery*. Springer verlag Berlin

- Visnjic S. 2008. Transumbilical laparoscopically assisted appendectomy in children: high-tech low-budget surgery. *Surg Endosc.* Jul;22(7):1667-71. Epub 2007 Dec 11.
- Višnjić S, Popović L, Župančić B 2006. Laparoscopically assisted appendectomy. *Eur Surg* 38:374-375

IntechOpen

IntechOpen



### **Advanced Laparoscopy**

Edited by Prof. Ali Shamsa

ISBN 978-953-307-674-4

Hard cover, 190 pages

**Publisher** InTech

**Published online** 30, September, 2011

**Published in print edition** September, 2011

The present book, published by InTech, has been written by a number of highly outstanding authors from all over the world. Every author provides information concerning treatment of different diseases based on his or her knowledge, experience and skills. The chapters are very useful and innovative. This book is not merely devoted to urology sciences. There are also clear results and conclusions on the treatment of many diseases, for example well-differentiated papillary mesothelioma. We should not forget nor neglect that laparoscopy is in use more extensively than before, and in the future new subjects such as use of laparoscopy in treatment of kidney cysts, simple nephrectomy, pyeloplasty, donor nephrectomy and even robotic laparoscopy will be researched further.

### **How to reference**

In order to correctly reference this scholarly work, feel free to copy and paste the following:

Stjepan Visnjic (2011). Transubilical Laparoscopically Assisted Pediatric Surgery, Advanced Laparoscopy, Prof. Ali Shamsa (Ed.), ISBN: 978-953-307-674-4, InTech, Available from:  
<http://www.intechopen.com/books/advanced-laparoscopy/transubilical-laparoscopically-assisted-pediatric-surgery>

**INTech**  
open science | open minds

### **InTech Europe**

University Campus STeP Ri  
Slavka Krautzeka 83/A  
51000 Rijeka, Croatia  
Phone: +385 (51) 770 447  
Fax: +385 (51) 686 166  
[www.intechopen.com](http://www.intechopen.com)

### **InTech China**

Unit 405, Office Block, Hotel Equatorial Shanghai  
No.65, Yan An Road (West), Shanghai, 200040, China  
中国上海市延安西路65号上海国际贵都大饭店办公楼405单元  
Phone: +86-21-62489820  
Fax: +86-21-62489821



© 2011 The Author(s). Licensee IntechOpen. This chapter is distributed under the terms of the [Creative Commons Attribution-NonCommercial-ShareAlike-3.0 License](https://creativecommons.org/licenses/by-nc-sa/3.0/), which permits use, distribution and reproduction for non-commercial purposes, provided the original is properly cited and derivative works building on this content are distributed under the same license.

IntechOpen

IntechOpen