

We are IntechOpen, the world's leading publisher of Open Access books Built by scientists, for scientists

6,900

Open access books available

185,000

International authors and editors

200M

Downloads

Our authors are among the

154

Countries delivered to

TOP 1%

most cited scientists

12.2%

Contributors from top 500 universities



WEB OF SCIENCE™

Selection of our books indexed in the Book Citation Index
in Web of Science™ Core Collection (BKCI)

Interested in publishing with us?
Contact book.department@intechopen.com

Numbers displayed above are based on latest data collected.
For more information visit www.intechopen.com



Computed Tomography of Osteolysis Related to Total Ankle Replacement

Ia Kohonen², Helka Koivu¹, Kimmo Mattila² and Hannu Tiusanen¹

¹*Department of Internal Medicine, Rheumaorthopaedic Unit,*

²*The Medical Imaging Centre of Southwest Finland, Turku University Hospital,*

¹*Turku*

²*Finland*

1. Introduction

Increasing number of patients come to computed tomography (CT) imaging with orthopaedic hardware including total ankle replacement (TAR). These patients have either implant related complaints, or they are imaged due to other medical causes with the prosthesis in the imaged body area. Inventions in CT; first helical computed tomography and later, multidetector computed tomography (MDCT) have made imaging of bones and joints extremely fast and precise, resulting in less motion artifacts and thinner sections (Lee et al., 2007; Ohashi et al., 2005; West et al., 2009). With modern scanners image data is routinely obtained as isotropic or near isotropic voxels. This allows image reconstruction in any arbitrary plane without losing image quality and also 3D volume rendered images (West et al., 2009).

CT is useful when imaging ankle after TAR especially in the situations when the patient has implant related symptoms or periprosthetic osteolysis is suspected and the radiographs cannot determine the condition. Cahir et al. (2007) and Keogh et al. (2003) have shown the usefulness of CT in imaging painful hip after total hip replacement. Periprosthetic osteolysis and aseptic loosening are common complications after TAR (Berquist, 2006; Besse et al., 2009; Koivu et al., 2009; Kokkonen et al., 2011; Rodriguez et al., 2010). CT reveals osteolytic changes around prosthesis components in ankle better than radiographs (Besse et al., 2009; Hanna et al., 2007; Koivu et al., 2009; Rodriguez et al., 2009). CT may also be useful in other total ankle replacement related conditions, e.g. periprosthetic fracture, subluxation and dislocation of prosthesis components, infection, impingement and heterotopic ossification.

This article is not a comprehensive encyclopedic review of CT scanning of total ankle prostheses. Our aim was to review previous literature of CT in osteolysis related to total ankle prosthesis. This article also contains short description of total ankle replacements.

2. Periprosthetic osteolysis

Periprosthetic osteolysis is a common problem with total joint replacements. The exact pathogenesis of osteolysis still remains unclear, but both biological and mechanical factors

likely contribute (Jacobs et al., 2001; Konttinen et al., 2005; Saleh et al., 2004; Purdue et al., 2006). Osteolysis in hip arthroplasty has been widely studied and was originally described as cement disease (Jones & Hungerford 1987). Currently it is commonly regarded as a foreign body reaction due to cement, polyethylene or metallic wear particles (Dumbleton et al., 2002; Harris, 1995; Jacobs et al., 2001; Konttinen et al., 2005; Saleh et al., 2004; Santavirta, 2005; Purdue et al. 2006). Numerous proinflammatory cytokines participate to the process in response to implant-derived wear particles and recent studies have shown that RANK/RANKL/OPG pathway might have a crucial role in osteoclastogenesis and osteolysis (Holt et al., 2007; Purdue et al., 2006; Saleh et al., 2004). Wear particles are considered the single most important factor in development of osteolysis, but the specific nature of this process is likely dependent of numerous parameters, including patterns of wear, type of prosthesis and host factors (Dumbleton et al., 2002; Jacobs et al., 2001; Purdue et al., 2006).

Previous studies on total hip replacement have shown that radiographs underestimate the size of periprosthetic osteolytic lesions (Puri et al., 2002; Walde et al., 2005) and some of the existing lesions may even remain undetected on radiographs (Looney et al., 2002). The hip prosthesis studies have demonstrated mean time-interval from total hip replacement to detectable osteolytic lesions on radiographs to vary between five and ten years (Park et al., 2004; Puri et al., 2002). Looney et al. (2002) found correlation between osteolysis and polyethylene wear. However, in another study (Puri et al., 2002) correlation between volumetric bone loss and linear wear of the polyethylene was not established.

Patients with periprosthetic osteolysis may remain asymptomatic for a long time despite of the lesions around prosthesis components. Because osteolysis is a progressive phenomenon (Purdue et al., 2006) and probably results finally in component failure, it is important to detect these lesions around prosthesis components as early as possible. CT may be useful in monitoring the progress of these lesions around components.

3. Total ankle replacement

Total ankle replacement has emerged since the introduction of the third generation total ankle implants. The first generation total ankle replacements from 1970s and 1980s were non-anatomical and did not respect ankle kinematics, therefore due to unsatisfactory results they were abandoned several years ago (Bonasia et al., 2010; DiDomenico et al., 2010; van den Heuvel et al., 2010). Nowadays TAR implants are non-cemented, two- or three-component, semi-constrained designs with mobile bearing polyethylene (Figure 1.). As short-term and intermediate-term results seem to be acceptable (Besse et al., 2010; Bonnin et al., 2004; Bonnin et al., 2010; Buechel et al., 2004; Doets et al., 2006; Fevang et al., 2007; Haddad et al., 2007; Henricson et al., 2007; Henricson et al., 2010; Hintermann et al., 2004; Hosman et al., 2007; Knecht et al., 2004; Kofoed, 2004; Pyevich et al., 1998; Su et al., 2004; Valderrabano et al., 2004; Wood & Deakin, 2003) it is according to many authors challenging the position of ankle arthrodesis as a gold standard in the treatment of painful ankle arthritis. Koefod and Stirrup (1994) showed in series of 26 patients that results of total ankle replacement were better than ankle arthrodesis.

3.1 Survival of total ankle replacement

Despite acceptable survival reports there are concerns regarding the long-term implant survival as the results of total ankle arthroplasty are generally considered to be inferior compared to total hip or knee arthroplasty. Some centers have reported 5-year survival rates



Fig. 1. Ankle Evolutive System (AES) total ankle implant (picture from Biomet Finland Oy) and Scandinavian Total Ankle Replacement (STAR) implant (picture from Anderson, T., Montgomery, F. & Carlsson, Å. (2003). Uncemented STAR total ankle prosthesis: Three to eight-year follow-up of fifty-one consecutive ankles. *J Bone Joint Surg Am.* Vol. 85, No. 7, (July 2003), pp. 1321-1329, 1535-1386).

of 70 % to 93 % (Anderson et al., 2003; Doets et al., 2006; Knecht et al., 2004; San Giovanni et al., 2006; Spirt et al., 2004; Wood et al., 2008; Wood et al., 2009) and 10- to 12-year survival rates even from 85 to 95 % (Bonnin et al., 2010; Buechel et al., 2004; Knecht et al., 2004; Kofoed, 2004). Results from Swedish, Norwegian and Finnish national registries have been slightly inferior with survival rates of 78% to 89% at five years and 62% to 72% at ten years (Fevang et al., 2007; Henricson et al., 2007; Skytta et al., 2010). In studies based on these registers with over 1300 patients altogether, aseptic loosening has been the most frequent reason for revision (31 - 48 %) (Fevang et al., 2007; Henricson et al., 2007; Skytta et al., 2010).

3.2 Total ankle replacement and osteolysis

In Finland the most used TAR implant has been Ankle Evolutive System (AES) (Transystème, Nimes, France), which has a tibial component with stem and a mobile bearing polyethylene. Before AES the most commonly used TAR implant in Finland was Scandinavian Total Ankle Replacement (STAR) (Waldemar Link, Hamburg, Germany), which has no stem on the tibial component. At 2008 the sale of the AES implant was prohibited in France due to alarming findings regarding osteolytic lesions beside the implant. Therefore our own TAR patients were analyzed and a large amount of osteolysis with AES implants was found. The results were published in Journal of Bone and Joint Surgery British version at 2009 (Koivu et al. 2009). Other reports with similar findings have been published afterwards (Besse et al., 2009; Besse et al., 2010; Kokkonen et al., 2011; Rodriguez et al., 2010).

Alarming percentage of osteolysis has been reported with total ankle arthroplasty before (Doets et al., 2006; Knecht et al., 2004; Pyevich et al., 1998; Schutte & Louwerens, 2008; Su et al., 2004; Valderrabano et al., 2004; Wood & Deakin, 2003). On the other hand, some authors

have reported the opposite and bone mineral density has been shown to increase adjacent to hydroxyapatite coated ankle arthroplasty (Zerahn et al., 2000, Zerahn & Kofoed, 2004). Knecht et al. (2004) detected osteolytic lesions in up to 76 % with the Agility Ankle implant (DePuy, Warsaw, IN). However, most of the lesions in their study were small and stable; progression was obtainable in approximately 12 % of all lytic lesions. The authors defined lytic lesions into two different categories by their nature, “expansile” and “mechanical”, of which the latter has previously been called “ballooning” lysis (Pyevich et al., 1998). It has been characterised as early-onset and usually non-progressive lesion, when in turn expansile lysis was characterised as late-onset, progressive lesion due to implant wear. In our study the lesions were both early-onset, as first lesions were seen on radiographs one to two years after the operation, and rapidly progressive (Koivu et al., 2009).

3.2.1 Revision surgery for osteolysis

In hip and knee arthroplasty, the implants may be well fixed despite large aggressive granulomatous lesions around the implants (Eskola et al., 1990; Jasty et al., 1986; Nolan and Bucknill, 1992; Santavirta et al., 1990; Tallroth et al., 1989) and some authors consider these lesions and aseptic loosening as different conditions (Santavirta et al., 1990). Few findings in the literature (Knecht et al., 2004; Valderrabano et al., 2004; Wood & Deakin, 2003) and our own results support this theory also in ankle arthroplasty (Koivu et al., 2009). Most of our patients with osteolysis were clinically asymptomatic and the implants have been steadily fixed in revision. To prevent the loosening of the implants, all ankles with marked osteolytic lesions have been revised as has also been suggested by other authors (Besse et al., 2009). At revision surgery, a débridement, allogeneous spongy bone grafting and exchange of polyethylene inlay if necessary has been done. Large lytic cavities containing brownish grey granulomatous necrotic material were found around the components, but there was no metallosis in surrounding tissues. In most ankles both tibial and talar components were stable. The histology of the samples of all patients was identical and was interpreted as foreign body reaction. These findings were consistent with previous studies regarding periprosthetic osteolytic lesions (Jasty et al., 1986; Santavirta et al., 1990, Tallroth et al., 1989).

4. CT of osteolysis related to total ankle replacement

Traditionally patients with total ankle prosthesis are monitored only using radiographs. Anteroposterior (AP) and lateral radiographs are obtained usually at each clinical control visit, in standing position whenever possible (Figure 2.). On radiographs osteolysis has been defined as a new or expanding sharply demarcated lucency adjacent to prosthesis components (Puri et al., 2002). Alarming reports regarding osteolytic lesions around AES total ankle prosthesis (Besse et al., 2009; Besse et al., 2010; Koivu et al., 2009; Kokkonen et al., 2011, Rodriguez et al., 2009) have increased interest in computed tomography in follow-up of total ankle prostheses.

4.1 Methods for decreasing metal artifacts on CT

Every metal implant causes artifacts on CT distorting the normally excellent image quality (Barret & Keat, 2004). The factors that affect artifacts include the composition of the and, orientation of the hardware, acquisition parameters (peak voltage, tube charge, collimation and acquired section thickness), and reconstruction parameters (Lee et al., 2007).

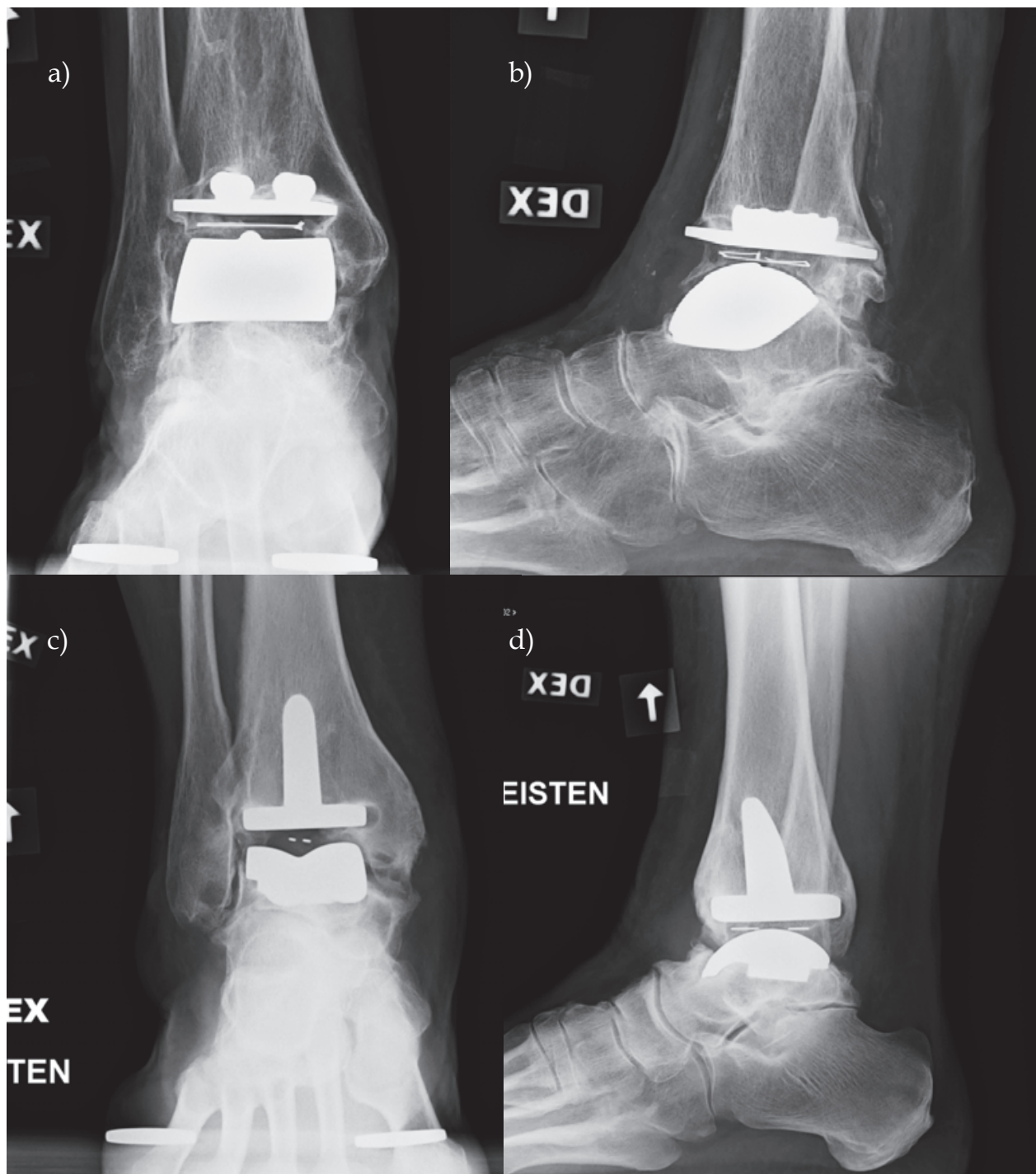


Fig. 2. Radiographs of STAR (a and b) and AES prostheses (c and d) in standing position.

Metal composition, as well as geometry of metal implant and cross-sectional area of the hardware affects the amount of artifacts produced. Titanium causes less artifacts than stainless steel and cobalt-chrome (Lee et al., 2007; Stradiotti et al., 2009). Large metallic components cause bigger artifact than smaller and thinner ones (Lee et al., 2007). To minimize artifacts during scanning the implant should be positioned so that the X-ray beam traverses the smallest possible cross-sectional area of it (Lee et al., 2007; Stradiotti et al., 2009). Artifacts produced can also be reduced by optimizing imaging parameters. A higher

X-ray peak kilovoltage (kVp), a higher tube current (mAs) and lower pitch settings have been shown to diminish artifacts (Lee et al., 2007). Additionally, narrowing collimation reduces metal artifacts. In modern scanners extended CT scale technique (ECTS) can be used when imaging areas with metal implants. This technique allows expansion of the Hounsfield scale from a standard maximum window of 4000 HU to 40 000 HU. This technique is based on the fact that metals have high linear attenuation coefficients that are outside the normal range of reconstructed CT numbers (Lee et al., 2007; Link et al., 2000).

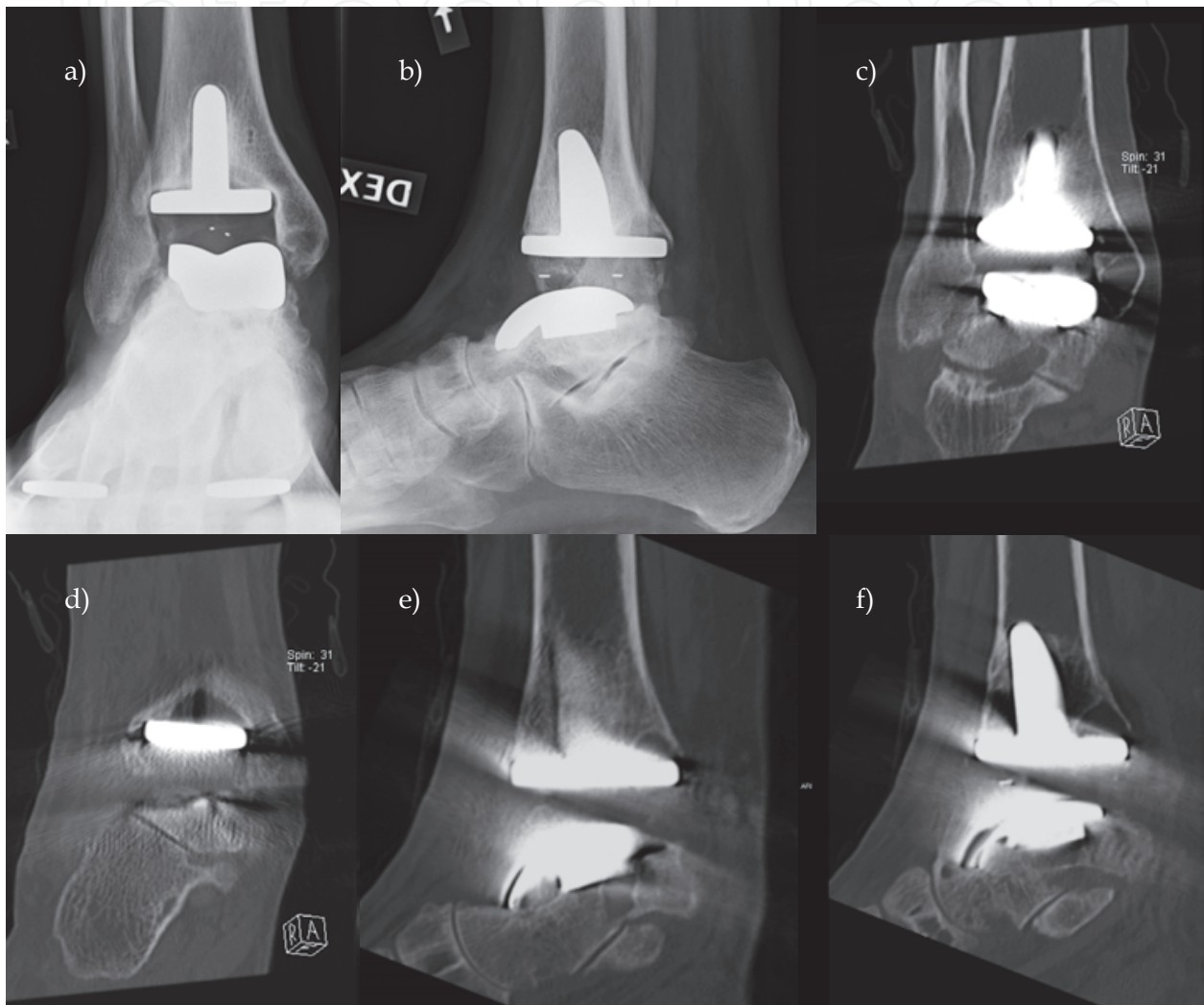


Fig. 3. 47 year-old male with rheumatoid arthritis. Radiographs 14 months after AES TAR (a and b) with osteolytic lesions at least in tibia. Several lesions on CT both in distal tibia and talus 2 years after operation (c-f).

The amount of metal artifacts may be further decreased in the post-processing phase when reconstructing images at workstation. Partial volume artifacts are usually best avoided by acquiring thinner sections (Lee et al., 2007), however, the drawback of increased information is increased image noise. During image reconstruction, combining several thin sections to get thicker ones are routinely used to reduce image noise. The increased thickness of the reformatted sections dramatically affects image quality, decreasing the noise and also severity of metal-related artifacts (Lee et al., 2007). Thicker reconstructed images with use of

standard or smooth reconstruction filter (kernel) diminish metal artifacts and visible noise on the images (Lee et al., 2007). A novel metal artifact reduction (MAR) image reconstruction algorithm has been tested in some studies with promising results (Liu et al., 2009; Watzke & Kalender, 2004). However, the processing time needed for image reconstruction using this method was 2 to 4 hours for each examination, and therefore at least now this program is not suitable for standard clinical use (Liu et al., 2009).

To allow good image quality and possibility to reformat images in any arbitrary plane ankles with metal prostheses need to be imaged using MDCT. During scanning patients are lying supine on a table. The scanned area should cover the whole implant, starting proximal to the tibial component and ending distal to the talar component. In some studies (Hanna et al., 2007; Puri et al., 2002) high kilovoltage (140 kVp) has been used to reduce implant-related artifacts. However, it has also been estimated that there is no additional value attained in using settings more than 120 kVp (Lee et al., 2007). We have used a scan protocol of 120 kVp, metal-artifact reducing extended CT scale algorithm and 0.6 mm slice thickness with 0.4 mm recon increments. Coronal, sagittal and axial images are routinely reformatted from the original data with 2 to 3 mm slice thickness. On CT osteolytic lesions have been defined as well demarcated, periprosthetic lucencies without detectable osseous trabeculae (Hanna et al., 2007). Figures 3 – 6 show examples of TAR implants on CT.

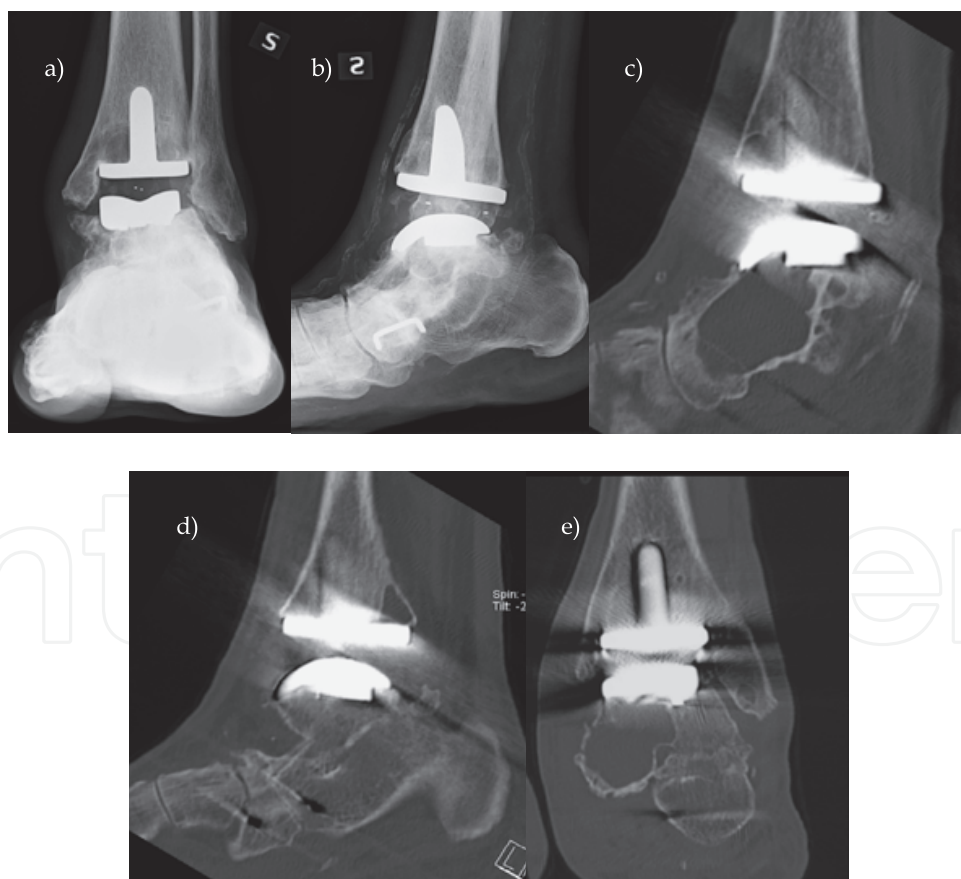


Fig. 4. 67 year-old male with rheumatoid arthritis. 2 years after total ankle replacement osteolytic lesions in distal tibia and suspicion of osteolysis also in talus on radiographs (a and b). On CT images 3 years after AES TAR (c-e) several osteolytic lesions in tibia and one huge lesion with cortical disruption in talus.

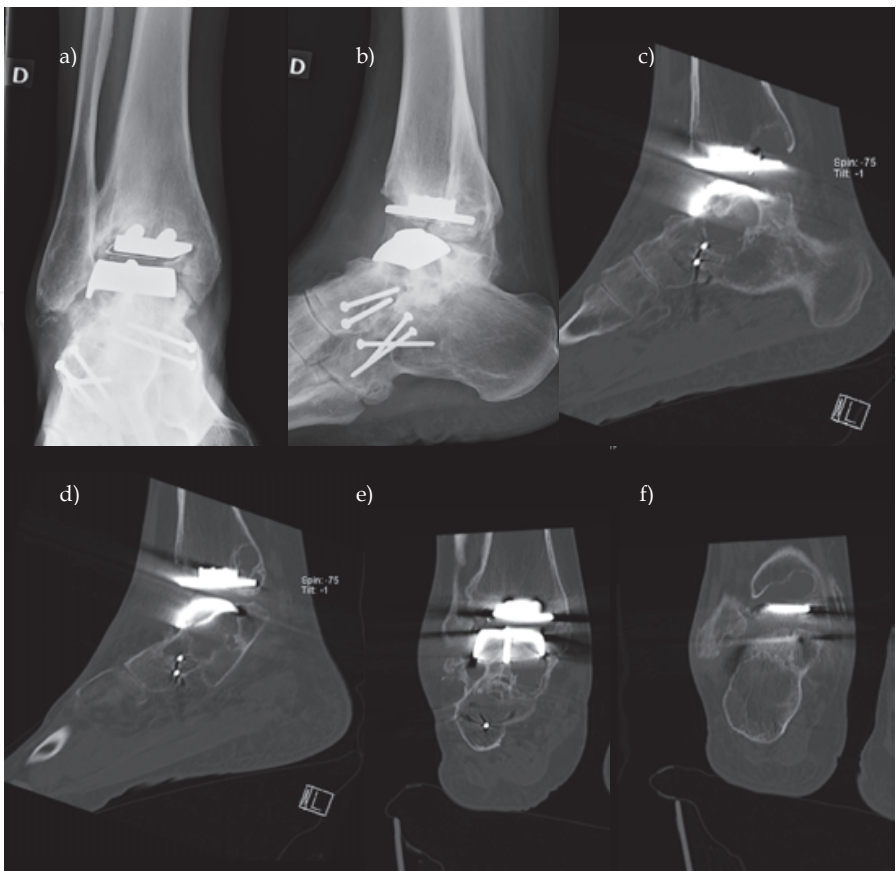


Fig. 5. 32 year-old female with rheumatoid arthritis. Radiographs 8 years after STAR total ankle replacement (a and b). Small osteolytic lesions in distal tibia and suspicion of osteolysis under talar component. On CT (c-f) 7 months after radiographs there were several lesions in tibia and also large lesions in talus.

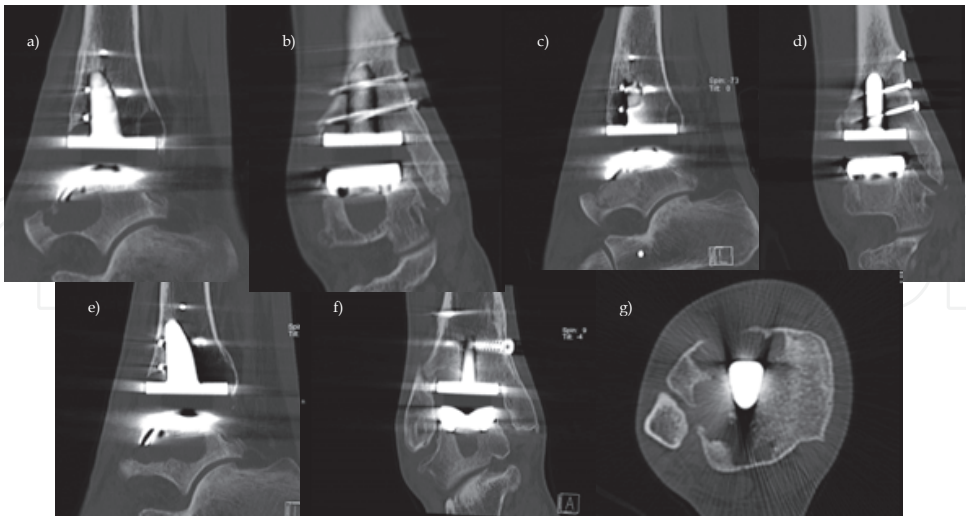


Fig. 6. 53 year-old male with post-traumatic osteoarthritis. On CT (a and b) several osteolytic lesions around AES prosthesis in distal tibia and one large lesion in talus, corrective osteotomy had also been performed. 2 years after TAR large lesion in talus and also one lesion in tibia were filled with allogeneous bone grafting (c and d). At one year follow-up there is no visible bone grafting on CT and the osteolytic lesions have enlarged dramatically (e-g).

4.2 Reported appearance of osteolysis on CT

To our knowledge, the first study of total ankle replacement associated osteolysis and CT is where Hanna et al. (2007) studied 17 patients (19 ankles). The implant used in the study was Agility Ankle implant (DePuy, Warsaw, IN) the only second generation prosthesis fully approved by the FDA at that time. Unique to this implant is that fusion of the distal tibiofibular syndesmosis is required to stabilize the tibial component. In this study osteolytic lesions only in distal tibia and fibula were studied. More lesions were detected on CT than on radiographs. The mean size of the lesions on CT was over three times larger than the size on radiographs (Hanna et al., 2007).

Few studies have been published concerning CT of osteolysis related to AES prosthesis (Besse et al., 2009; Rodriquez et al., 2009). In one study with 18 ankles osteolysis was depicted on radiographs in 14 ankles (77 %) while all ankles had osteolytic lesions on CT. In addition, CT was more sensitive to osteolysis than radiographs especially around talar component (Rodriquez et al., 2009). The mean follow-up time in that study was 39.4 months. In another prospective study fifty AES implants in 47 patients were examined. The main cause for ankle replacement was post-traumatic osteoarthritis (50 %). The mean follow-up was 40 months. The clinical results in this study were good in spite of high amount of osteolytic lesions at bone-prosthesis interface. There were tibial osteolytic lesions in 62 % and talar lesions in 43 % of ankles. This study established that radiographs underestimate the size and number of osteolytic lesions when comparing to computed tomography (Besse et al., 2009).

5. Conclusion

Although total ankle replacement has become a noteworthy alternative to arthrodesis in the treatment of destructed upper ankle joint there are still concerns about stability of total ankle prosthesis in long-term follow-up. For example, the medium and long term results are not comparable to total hip and knee replacements. Common complications after total ankle replacement are osteolysis and aseptic loosening (Berquist, 2006; Fevang et al., 2007; Henricson et al., 2007; Pyevich et al., 1998; Skytta et al., 2010; Spirt et al., 2004). More studies of materials and designs of total ankle prosthesis are needed to improve survival of these prostheses.

Previous studies have shown that radiographs give limited information of osteolytic lesions around prosthesis components (Besse et al., 2009; Hanna et al., 2007; Rodriquez et al., 2009). Computed tomography is more accurate method for assessing the presence and extent of osteolytic lesions around TAR (Besse et al., 2009; Hanna et al., 2007; Koivu et al., 2009; Rodriquez et al., 2009). Furthermore, CT should be considered before total ankle replacement to determine the presence of any degenerative cysts or geodes in distal tibia, fibula or talus avoiding to misinterpretation these lesions later as osteolysis (Figure 7.). In addition, CT is highly useful defining the exact locations of osteolytic lesions in preoperative planning of revision surgery for the failed TAR. We conclude that it is extremely important to remember that patients can have progressing osteolysis without visible osteolytic lesions on radiographs. CT should be included in every TAR patient follow-up scheme to detect these lesions as early as possible.

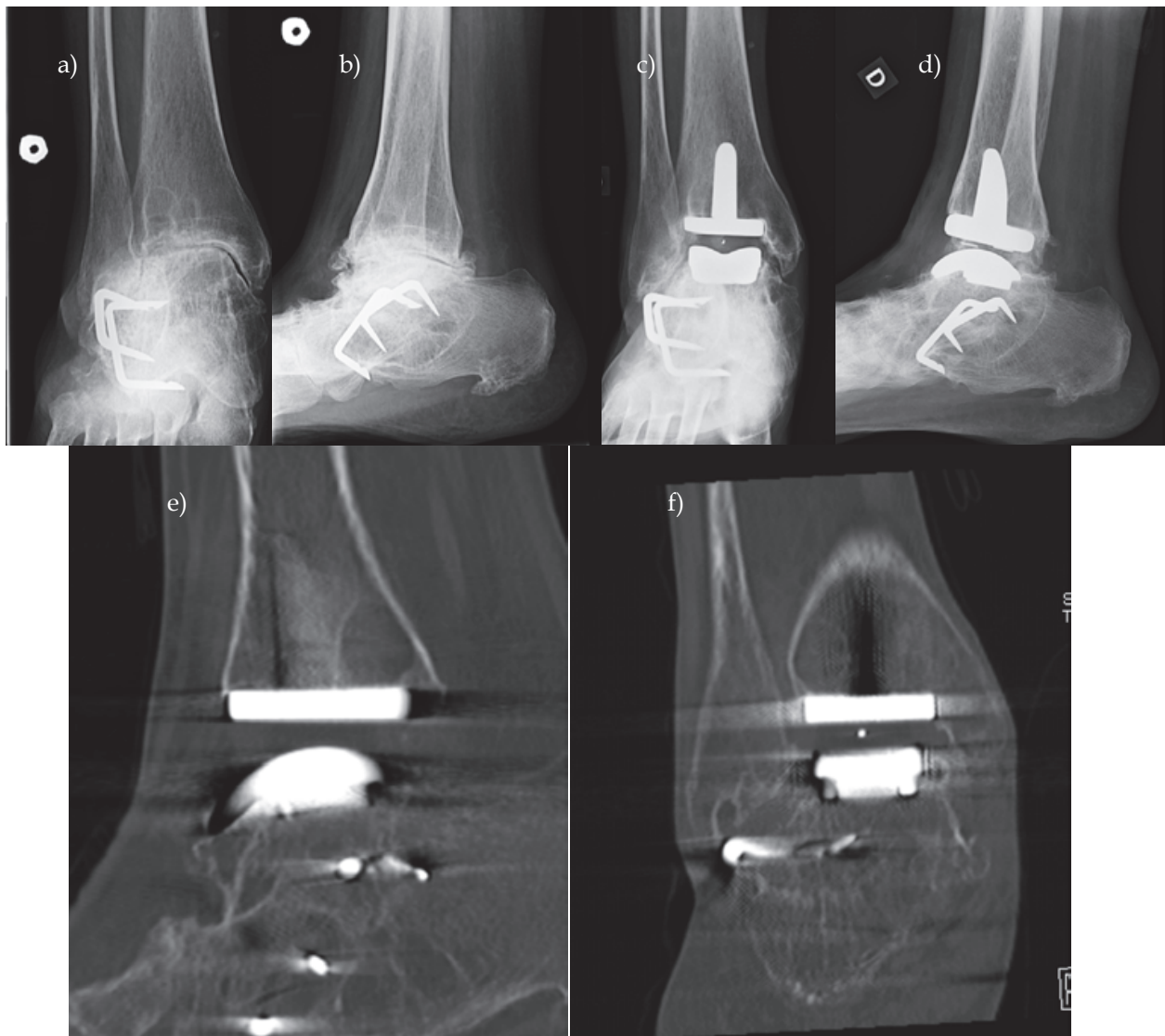


Fig. 7. 58 year-old female with rheumatoid arthritis. Radiographs before (a and b) and after AES TAR (c and d). CT images (e and f) 7 years after TAR. The lesion in postero-lateral tibia was considered as a geode, because it was visible already on preoperative radiographs.

6. References


- Anderson, T.; Montgomery, F. & Carlsson, Å. (2003). Uncemented STAR total ankle prosthesis: Three to eight-year follow-up of fifty-one consecutive ankles. *J Bone Joint Surg Am.* Vol. 85, No. 7, (July 2003), pp. 1321-1329, 1535-1386
- Barret, J. & Keat, N. (2004). Artifacts in CT: Recognition and Avoidance. *RadioGraphics*, 24, 6, pp. 1679-1691, 0271-5333
- Berquist, T. (2006). Imaging of Joint Replacement Procedures. *Radiol Clin N Am*, 44, pp. 419-437, 0033-8389
- Besse, J.; Brito, N. & Lienhart, C. (2009). Clinical evaluation and radiographic assessment of bone lysis of the AES total ankle replacement. *Foot Ankle Int.* Vol. 30, No. 10, (October 2009), pp. 964-975, 1071-1007

- Besse, J.; Colombier, J; Asencio, J; Bonnin, M; Gaudot, F; Jarde, O; Judet, T; Maestro, M; Lemrijse, T; Leonardi, C; Toullec E & l'AFCP (2010). Total ankle arthroplasty in France. *Orthop Traumatol Surg Res*. Vol. 96, No. 3, (May 2010), 291-303, 1877-0568
- Bonasia, D.; Dettoni, F.; Femino, J.; Phisitkul, P.; Germano, M. & Amendola, A. (2010). Total ankle replacement: why, when and how? *Iowa Orthop J*. Vol. 30, pp. 119-130, 1541-5457
- Bonnin, M.; Gaudot, F.; Laurent, J.; Ellis, S.; Colombier, J. & Judet T. (2011). The Salto total ankle arthroplasty: survivorship and analysis of failures at 7 to 11 years. *Clin Orthop Relat Res*. Vol. 469, No. 1, (January 2009), pp. 225-236, 0009-921X
- Bonnin, M.; Judet, T.; Colombier, J.; Buscayret, F.; Gravelleau, N. & Piriou, P. (2004). Midterm results of the Salto Total Ankle Prosthesis. *Clin Orthop Relat Res*. 2004 Vol. 424, (July 2004), pp. 6-18, 0009-921X
- Buckwalter, K.; Parr, J.; Choplin, R. & Capello, W. (2006). Multichannel CT Imaging of Orthopedic Hardware and Implants. *Semin Musculoskelet Radiol*, 10, 1, pp. 86-97, 1089-7860
- Buechel, F. Sr.; Buechel, F. Jr. & Pappas, M. (2004). Twenty-year evaluation of cementless mobile-bearing total ankle replacements. *Clin Orthop Relat Res*. 2004 Vol. 424, (July 2004), pp. 19-26, 0009-921X
- Cahir, J.; Toms, A.; Marshall, T.; Wimhurst, J. & Nolan, J. (2007). CT and MRI of hip arthroplasty. *Clinical Radiology*, 62, pp. 1163-1171, 0009-9260
- DiDomenico, L.; Treadwell, J. & Cain, L. (2010). Total ankle arthroplasty in the rheumatoid patient. *Clin Podiatr Med Surg*. 2010 Vol. 27, 2, (April 2010), pp. 295-311, 1558-2302
- Doets, H.; Brand, R. & Nelissen R. (2006). Total ankle arthroplasty in inflammatory joint disease with use of two mobile-bearing designs. *J Bone Joint Surg Am*. Vol. 88, No. 6, (June 2006), pp. 1272-1284, 1535-1386
- Dumbleton, J.; Manley, M. & Edidin, A. (2002). A literature review of the association between wear rate and osteolysis in total hip arthroplasty. *J Arthroplasty*. Vol 17, No. 5, (August 2002), pp. 649-661, 0883-5403
- Eskola, A.; Santavirta, S.; Kontinen, Y.; Hoikka V.; Tallroth, K. & Lindholm, T. (1990). Cementless revision of aggressive granulomatous lesions in hip replacement. *J Bone Joint Surg Br*. Vol. 72, No. 2, (March 1990), pp. 212-216, 1535-1386
- Fevang, B., Lie, S.; Havelin, L.; Brun, J.; Skredderstuen, A. & Furnes, O. (2007). 257 ankle arthroplasties performed in Norway between 1994 and 2005. *Acta Orthop*. Vol. 78, No. 5, (January 2007), pp. 575-583, 1745-3674
- Haddad, S., Coetzee, J., Estok, R., Fahrbach, K., Banel, D. & Nalysnyk, L. (2007). Intermediate and long-term outcomes of total ankle arthroplasty and ankle arthrodesis. A systematic review of the literature. *J Bone Joint Surg Am*. Vol. 89, No. 9, (September 2007), pp. 1899-1905, 1535-1386
- Hanna, R.; Haddad, S. & Lazarus, M. (2007). Evaluation of Periprosthetic Lucency After Total Ankle Arthroplasty: Helical CT Versus Conventional Radiography. *Foot Ankle Int.*, 28, 8, pp. 921-926, 1071-1007
- Harris, W. (1995). The problem is osteolysis. *Clin Orthop*. Vol. 311, (February 1995), pp. 46-53, 0095-8654
- Henricson, A., Knutson, K., Lindahl, J. & Rydholm, U. (2010). The AES total ankle replacement: A mid-term analysis of 93 cases. *Foot Ankle Surg*. Vol. 16, No. 2, (June 2010), pp. 61-64, 1268-7731

- Henricson, A., Skoog, A. & Carlsson, Å. (2007). The Swedish Ankle Arthroplasty Register. An analysis of 531 arthroplasties between 1993 and 2005. *Acta Orthop*. Vol. 78, No. 5, (January 2007), pp. 569-574, 1745-3674
- Hintermann, B., Valderrabano, V., Dereymaker, G. & Dick, W. (2004). The HINTEGRA ankle: rationale and short-term results of 122 consecutive ankles. *Clin Orthop Rel Res*. Vol. 424, (July 2004), pp. 57-68, 0009-921X
- Holt, G., Murnaghan, C., Reilly, J. & Meek, R. (2007). The biology of aseptic osteolysis. *Clin Orthop Rel Res*. Vol. 460, (July 2007), pp. 240-252, 0009-921X
- Holt, G.; Murnaghan, C.; Reilly, J. & Meek, R. (2007). The Biology of Aseptic Osteolysis. *Clin Orthop*, 460, pp. 240-252, 0095-8654
- Hosman, A., Mason, R., Hobbs, T. & Rothwell, A. (2007). A New Zealand national joint registry review of 202 total ankle replacements followed up to 6 years. *Acta Orthop*. Vol. 78, No. 5, (January 2007), pp. 584-591, 1745-3674
- Jacobs, J., Roebuck, K., Archibek, M., Hallab, N. & Glant, T. (2001). Osteolysis: Basic science. *Clin Orthop Rel Res*. Vol. 393, (December 2001), pp. 71-77, 0009-921X
- Jasty, M., Floyd, W 3rd., Schiller, A., Goldring, S. & Harris W. (1986). Localized osteolysis in stable, non-septic total hip replacement. *J Bone Joint Surg Am*. Vol. 68, No. 6, (July 1986), pp. 912-919, 1535-1386
- Jones, L. & Hungerford, D. (1987). Cement disease. *Clin Orthop Rel Res*. Vol. 225, (December 1987), pp.192-206, 0009-921X
- Keogh, C.; Munk, P.; Gee, R.; Chan, L. & Marchinkow, L. (2003). Imaging of the Painful Hip Arthroplasty. *AJR*, 180, pp. 115-120, 0361-803X
- Knecht, S., Estin, M., Callaghan, J., Zimmerman, M., Alliman, K., Alvine, F. & Saltzman, C. (2004). The Agility total ankle arthroplasty. Seven to sixteen-year follow-up. *J Bone Joint Surg Am*. Vol. 86-A, No. 6, (June 2004), pp. :1161-1171, 1535-1386
- Kofoed, H. & Stirrup, J. (1994). Comparison of ankle arthroplasty and arthrodesis. *The Foot*. Vol. 4, No. 1, (March 1994), pp. 6-9, 0958-2592
- Kofoed, H. (2004). Scandinavian Total Ankle Replacement (STAR). *Clin Orthop Relat Res*. Vol. 424, (July 2004), pp. 73-79, 0009-921X
- Koivu, H., Kohonen, I., Sipola, E., Alanen, K., Vahlberg, T. & Tiisanen, H. (2009). Severe periprosthetic osteolytic lesions after the Ankle Evolutive System total ankle replacement. *J Bone Joint Surg Br*. Vol. 91, No. 7, (July 2009), pp. 907-14, 1535-1386
- Kokkonen, A., Ikavalko, M., Tiihonen, R., Kautiainen, H. & Belt, E. (2011). High rate of osteolytic lesions in medium-term followup after the AES total ankle replacement. *Foot Ankle Int*. Vol. 32, No. 2, (February 2011), pp. 168-175, 1071-1007
- Konttinen, Y., Zhao, D., Beklen, A., Ma, G., Takagi, M., Kivela-Rajamaki, M., Ashammakhi, N. & Santavirta S. (2005). The microenvironment around total hip replacement prostheses. *Clin Orthop Rel Res*. Vol. 430, (January 2005), pp.28-38, 0009-921X
- Lee, M.; Kim, S.; Lee, S.; Song, H.; Huh, Y.; Kim, D.; Han, S. & Suh, J. (2007). Overcoming Artifacts from Metallic Orthopedic Implants at High-Field-Strength MR Imaging and Multidetector CT. *RadioGraphics*, 27, 3, pp. 791-803, 0271-5333
- Link, T.; Berning, W; Scherf, S.; Joosten, U.; Joist, A.; Engelke, K. & Daldrup-Link, H. (2000). CT of Metal Implants: Reduction of Artifacts Using an Extended CT Scale Technique. *J Comput Assist Tomogr*, 24, 1, pp. 165-172, 0363-8715

- Liu, P.; Pavlicek, W.; Peter, M.; Spangehl, M.; Roberts, C. & Paden, R. (2009). Metal artifact reduction image reconstruction algorithm for CT of implanted metal orthopedic devices: a work in progress. *Skeletal Radiol*, 38, pp. 797-802, 0364-2348
- Looney, R.; Boyd, A.; Totterman, S.; Seo, G.; Tamez-Pena, J.; Campbell, D.; Novotny, L.; Olcott, C.; Martell, J.; Hayes, F.; O'Keefe, R. & Schwarz, E. (2002). Volumetric computerized tomography as a measurement of periprosthetic acetabular osteolysis and its correlation with wear. *Arthritis Res*, 4, pp. 59-63, 1465-9905
- Nolan, J & Bucknill, T. (1992). Aggressive granulomatosis from polyethylene failure in an uncemented knee replacement. *J Bone Joint Surg Br*. Vol. 74, No. 1, (January 1992), pp. 23-24, 1535-1386
- Ohashi, K.; El-Khoury, G.; Bennet, D.; Restrepo, J. & Berbaum, K. (2005). Orthopedic Hardware Complications Diagnosed with Multi-Detector Row CT. *Radiology*, 237, 2, pp. 570-577, 0033-8419
- Park, J.; Ryu, K.; Hong, H.; Park, Y.; Chun, Y. & Yoo, M. (2004). Focal osteolysis in total hip replacement: CT findings. *Skeletal Radiol*, 33, pp. 632-640, 0364-2348
- Purdue, P., Koulouvaris, P., Nestor, B. & Sculco, T. (2006). The central role of wear debris in periprosthetic osteolysis. *HSSJ*. Vol 2, No. 2, (September 2006), pp. 102-113, 1818-4960
- Puri, L.; Wixson, R.; Stern, S.; Kohli, J.; Hendrix, R. & Stulberg, S. (2002). Use of Helical Computed Tomography for the Assessment of Acetabular Osteolysis After Total Hip Arthroplasty. *J Bone Joint Surg Am.*, 84, 4, pp. 609-614, 1535-1386
- Pyeovich, M., Saltzman, C., Callaghan, J. & Alvine F. (1998). Total ankle arthroplasty: a unique design. Two to twelve-year follow-up. *J Bone Joint Surg Am*. Vol. 80, No. 10, (October 1998), pp. 1410-1420, 1535-1386
- Rodriguez, D., Bevernage, B., Maldague, P., Deleu, P., Tribak, K. & Leemrijse, T. (2010). Medium term follow-up of the AES ankle prosthesis: High rate of asymptomatic osteolysis. *Foot Ankle Surg*. Vol. 16, No. 2, (June 2010), pp. 54-60, 1268-7731
- Saleh, K., Thongtrangan, I. & Schwarz, E. (2004). Osteolysis: medical and surgical approaches. *Clin Orthop Rel Res*. Vol. 427, (October 2004), pp. 138-147, 0009-921X
- San Giovanni, T., Keblish, D., Thomas, W. & Wilson, M. (2006). Eight-year results of a minimally constrained total ankle arthroplasty. *Foot Ankle Int*. Vol. 27, No. 6, (June 2006), pp. 418-26, 1071-1007
- Santavirta, S. (2005). Biotribology. *Acta Orthop*. 2005 Oct;Vol. 76, No. 5, (October 2005), pp. 613, 1745-3674
- Santavirta, S., Hoikka, V., Eskola, A., Konttinen, Y., Paavilainen, T. & Tallroth, K. (1990). Aggressive granulomatous. *J Bone Joint Surg Br*. Vol. 72, No. 6, (November 1990), pp. 980-984, 1535-1386
- Schutte, B. & Louwerens, J. (2008). Short-term results of our first Scandinavian total ankle replacements (STAR). *Foot Ankle Int*. Vol. 29, No. 2, (February 2008), pp. 124-127, 1071-1007
- Skytta, E., Koivu, H., Eskelinen, A., Ikävalko, M., Paavolainen, P. & Remes, V. (2010). Total ankle replacement: a population-based study of 515 cases from the Finnish Arthroplasty Register. *Acta Orthop*. Vol. 81, No. 1, (February 2010), pp. 114-118, 1745-3674
- Spirt, A., Assal, M. & Hansen, S Jr. (2004). Complications and failure after total ankle arthroplasty. *J Bone Joint Surg Am*. Vol. 86-A, No. 6, (June 2004), pp. 1172-1178, 1535-1386

- Stradiotti, P.; Curti, A.; Castellazzi, G. & Zerbi, A. (2009). Metal-related artefacts in instrumented spine. *Eur Spine J*, 18 (Suppl 1), pp. 102-108, 0940-6719
- Su, E., Kahn, B. & Figgie, M. (2004). Total ankle replacement in patients with rheumatoid arthritis. *Clin Orthop Relat Res*. Vol. 424, (July 2004), pp. 32-38, 0009-921X
- Tallroth, K., Eskola, A., Santavirta, S., Konttinen, Y. & Lindholm, T. (1989). Aggressive granulomatous lesion after hip arthroplasty. *J Bone Joint Surg Br*. Vol. 71, No. 4, (August 1989), pp. 571-575, 1535-1386
- Valderrabano, V., Hintermann, B. & Dick, W. (2004). Scandinavian total ankle replacement: a 3.7-year average followup of 65 patients. *Clin Orthop Rel Res*. Vol. 424, (July 2004), pp. 47-56, 0009-921X
- van den Heuvel, A., Van Bouwel, S. & Dereymaeker, G. (2010). Total ankle replacement. Design evolution and results. *Acta Orthop Belg*. Vol. 76, No. 2, (April 2010), pp. 150-61, 0001-6462
- Walde, T.; Weiland, D.; Leung, S.; Kitamura, N.; Sychterz, C.; Engh, C. Jr.; Claus, A.; Potter, H. & Engh, C. Sr. (2005) Comparison of CT, MRI and Radiographs in Assessing Pelvic Osteolysis. *Clin Orthop*, 437, pp. 138-144, 0095-8654
- Watzke, O. & Kalender, W. (2004). A pragmatic approach to metal artifact reduction in CT: merging of metal artifact reduced images. *Eur Radiol*, 14, pp. 849-856, 1756-1175
- West, A.; Marshall, T. & Bearcroft, P. (2009). CT of the musculoskeletal system: What is left is the days of MRI? *Eur Radiol*, 19, pp. 152-164, 1756-1175
- Wood, P. & Deakin, S. (2003). Total ankle replacement. The results in 200 ankles. *J Bone Joint Surg Br*. Vol.85, No. 3, (April 2003), pp. 334-341, 1535-1386
- Wood, P., Prem, H. & Sutton, C. (2008). Total ankle replacement: medium-term results in 200 Scandinavian total ankle replacements. *J Bone Joint Surg Br*. 2008 Vol 90, No. 5, (May 2008), pp. 605-609, 1535-1386
- Wood, P., Sutton, C., Mishra, V. & Suneja, R. (2009). A randomised, controlled trial of two mobile-bearing total ankle replacements. *J Bone Joint Surg Br*. Vol. 91-B, No. 1, (January 2009), pp. 69-74, 1535-1386
- Zerahn, B. & Kofoed, H.(2004). Bone mineral density, gait analysis, and patient satisfaction, before and after ankle arthroplasty. *Foot Ankle Int*. Vol. 25, No. 4, (April 2004), pp. 208-214, 1071-1007
- Zerahn, B., Kofoed, H. & Borgwardt A. (2000). Increased bone mineral density adjacent to hydroxyl-apatite-coated ankle arthroplasty. *Foot Ankle Int*. Vol. 21, No. 4, (April 2000), pp. 285-289, 1071-1007



CT Scanning - Techniques and Applications

Edited by Dr. Karupppasamy Subburaj

ISBN 978-953-307-943-1

Hard cover, 348 pages

Publisher InTech

Published online 30, September, 2011

Published in print edition September, 2011

Since its introduction in 1972, X-ray computed tomography (CT) has evolved into an essential diagnostic imaging tool for a continually increasing variety of clinical applications. The goal of this book was not simply to summarize currently available CT imaging techniques but also to provide clinical perspectives, advances in hybrid technologies, new applications other than medicine and an outlook on future developments. Major experts in this growing field contributed to this book, which is geared to radiologists, orthopedic surgeons, engineers, and clinical and basic researchers. We believe that CT scanning is an effective and essential tools in treatment planning, basic understanding of physiology, and and tackling the ever-increasing challenge of diagnosis in our society.

How to reference

In order to correctly reference this scholarly work, feel free to copy and paste the following:

Ia Kohonen, Helka Koivu, Kimmo Mattilaand Hannu Tiusanen (2011). Computed Tomography of Osteolysis Related to Total Ankle Replacement, CT Scanning - Techniques and Applications, Dr. Karupppasamy Subburaj (Ed.), ISBN: 978-953-307-943-1, InTech, Available from: <http://www.intechopen.com/books/ct-scanning-techniques-and-applications/computed-tomography-of-osteolysis-related-to-total-ankle-replacement>

INTECH
open science | open minds

InTech Europe

University Campus STeP Ri
Slavka Krautzeka 83/A
51000 Rijeka, Croatia
Phone: +385 (51) 770 447
Fax: +385 (51) 686 166
www.intechopen.com

InTech China

Unit 405, Office Block, Hotel Equatorial Shanghai
No.65, Yan An Road (West), Shanghai, 200040, China
中国上海市延安西路65号上海国际贵都大饭店办公楼405单元
Phone: +86-21-62489820
Fax: +86-21-62489821

© 2011 The Author(s). Licensee IntechOpen. This chapter is distributed under the terms of the [Creative Commons Attribution-NonCommercial-ShareAlike-3.0 License](https://creativecommons.org/licenses/by-nc-sa/3.0/), which permits use, distribution and reproduction for non-commercial purposes, provided the original is properly cited and derivative works building on this content are distributed under the same license.

IntechOpen

IntechOpen