

We are IntechOpen, the world's leading publisher of Open Access books Built by scientists, for scientists

6,900

Open access books available

185,000

International authors and editors

200M

Downloads

Our authors are among the

154

Countries delivered to

TOP 1%

most cited scientists

12.2%

Contributors from top 500 universities



WEB OF SCIENCE™

Selection of our books indexed in the Book Citation Index
in Web of Science™ Core Collection (BKCI)

Interested in publishing with us?
Contact book.department@intechopen.com

Numbers displayed above are based on latest data collected.
For more information visit www.intechopen.com



Distraction Osteogenesis of the Maxillofacial Skeleton: Clinical and Radiological Evaluation

Mehmet Cemal Akay

*Ege University, Faculty of Dentistry,
Department of Oral and Maxillofacial Surgery,
Turkey*

1. Introduction

Bimaxillary deficiencies (BMD) are frequently observed in adult patients and an increasingly recognized major orthodontic problem. Transverse skeletal deficiency (TSD) is a common clinical problem associated with narrow basal and dentoalveolar bone. An adequate transversal dimension is an important factor of stable occlusion and it positively effects facial esthetics and mastication. Narrow and V-shaped dental arch, dental crowding, posterior cross-bite, unesthetic black buccal corridors upon smiling and BMD are generally interrelated (Matteini & Mommaerts, 2001; Mommaerts, 1999; Mommaerts et al., 2004a; Proffit et al., 1996; Ramieri et al., 2005; Vanarsdall, 1999). Additionally, mouth breathing results in many clinical problems such as, xerostomia, an increased caries incidence and recurrent upper air way infections in these cases. Ideal functional reconstruction should achieve sufficient alveolar height and thickness, allowing for permanent restoration of dentition, maxillo-mandibular occlusion, mastication, deglutition, mandibular continuity, sensibility of the mucosa, lip competence and speech. The general aim of oral reconstruction is to restore both normal physiology and facial esthetics. Attention to the transverse deficiencies is vital in planning treatment for a patient who requires an increase in the lateral dimension of the mandible or maxilla.

2. Traditional treatment modalities for BMD

Traditional treatment options include compensating orthodontics, functional appliances, and orthopedic devices. Arch wire expansion, Schwarz plates, and proclination can all produce alveolar expansion. When these patients are treated using classical orthodontic appliances, the duration of the treatments increase and risks such as root resorption, undesired movements of anchorage teeth, and relapse occur. These therapies show relatively stable results for younger patients, particularly those who presented with lingually tipped teeth that need to be decompensated (Mommaerts, 1999; Neyt et al., 2002). Orthognathic surgery techniques for the treatment of BMD are used for many years. However, in these methods, mucosa can not adopt to rapid movement of bone fragments after the osteotomies. Therefore, in the postoperative period, relapse, functional and esthetic

problems occur (Guerrero et al., 1997; Little & Riedel, 1989; Mommaerts & Vande Vannet, 2004). Distraction osteogenesis technique (DO) offers a solution for these problems.

3. Distraction osteogenesis

Distraction osteogenesis, also called callus distraction, callotaxis, osteodistraction and distraction histogenesis is a surgical process used to reconstruct skeletal deformities and lengthen the long bones of the body (Ilizarov, 1989a, 1989b). The human body possesses an enormous regenerative capacity. DO takes advantage of this regenerative potential to induce the regeneration and remodeling of bone, cartilage, nerve, muscle, blood vessels, and skin. DO is defined as the creation of neoformed bone and adjacent soft tissue after the gradual and controlled displacement of a bone fragment obtained by surgical osteotomy. With this procedure, bone volume can be increased by gradual traction of a fracture callus formed between osteotomized bony segments. When the desired or possible length is reached, a consolidation phase follows in which the bone is allowed to keep healing. DO has the benefit of simultaneously increasing bone length and the volume of surrounding soft tissues. Clinically, this offers a distinct advantage because several craniofacial anomalies have soft tissue hypoplasia in addition to deficient bony structures. Neurovascular elements contained within distracted bony segments are also stimulated to regenerate. Experimental studies in dogs demonstrate regeneration of the mandibular canal containing both neural and vascular elements. However, the functional level of the regenerated neurovascular structures is less than normal (Imola et al., 2002; Imola et al., 2008).

3.1 History of DO technique

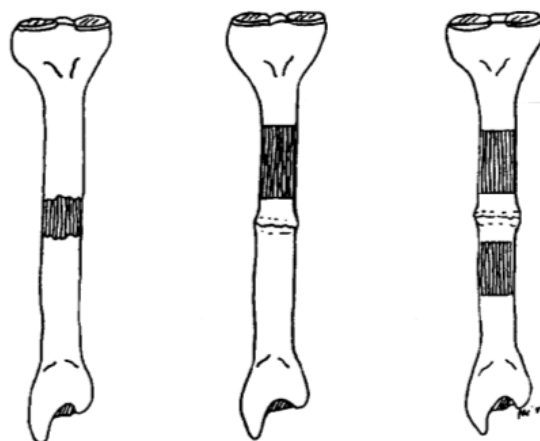
However, bone distraction is not a new concept, DO of the craniofacial skeleton has become increasingly popular as an alternative to many conventional orthognathic surgical procedures. For patients with mild to severe abnormalities of the craniofacial skeleton, distraction techniques have increased the number of treatment alternatives. DO initially used in orthopedic surgery by Codivilla in 1905. Abbott (1927) contributed in the improvement of Codivilla method by incorporating pins instead of casts used by Codivilla. Allan (1948) was the first to incorporate a screw device to control the rate of distraction. Research into osteogenic distraction originated in the fields of orthopedics and traumatology. However, the complication rate remained high and the technique was not understood until Gavriel Ilizarov, a Russian orthopedic surgeon, performed detailed studies in 1952. Ilizarov found that successful distraction depends of the stability of fixation, the rate of daily distraction, and the preservation of the local soft tissue envelope and vascular supply. Mandibular lengthening by gradual distraction was reported in 1973 by Synder et al. who used an extraoral device in a canine study; new bone formation at the elongated site was demonstrated later by Karp et al. (1990). The first clinical results of craniofacial DO were reported in 1992 by McCarthy et al. in a small series of patients with congenital mandible deformities. Authors successfully elongated the mandible by up to 24 mm. Interest in craniofacial distraction was slow to grow initially, with sporadic experimental reports appearing throughout the ensuing 2 decades. However, in the early 1990s, experimental investigation intensified following reports that examined lengthening canine mandibles and the use of DO to successfully close canine segmental lower jaw defects. Thereafter, several studies demonstrated the ability to apply DO at several different sites,

including the mandible, lower maxilla, midface, and cranial vault, within a variety of animal models. Since then, several larger series with longer follow-up periods have appeared. More recently, the technique has been successfully used for midface and upper craniofacial skeletal defects. DO is particularly useful for treating cases of severe bony hypoplasia where the surgical movement required to correct the malocclusion is outside the range predictably achievable with routine orthognathic surgery techniques.

Orthognathic surgery and DO have three steps in common. Both techniques require osteotomies, mobilization of segments, and a period of stabilization. The only difference between these two techniques is that, in distraction, the bone segments are slowly moved over time to their final position, whereas in conventional orthognathic surgery, this movement is immediate and it is accomplished intraoperatively. In DO, many tissues besides bone have been observed to form under tension stress, including mucosa, skin, muscle, tendon, cartilage, blood vessels, and peripheral nerves.

3.2 Types of DO technique

DO has been categorized into monofocal, bifocal, and trifocal types, depending on the number of foci at which osteogenesis occurs (Figure 1A-C). Monofocal elongation DO currently represents most of the clinical applications in the craniofacial skeleton.



A: Monofocal distraction is used to lengthen abnormally shortened bones and involves separation of 2 bone segments across a single osteotomy.

B: Bifocal distraction is used to repair a segmental defect and requires creation of a transport disk, which is then distracted across the defect until it docks with the opposing bony segment.

C: Trifocal distraction is similar to bifocal distraction attempts to halve the distraction time by transporting 2 disks from opposite ends of a defect to dock in the middle. Arrows indicate distraction vectors; large arrow heads, distraction regenerate; and small arrow heads, docking site.

Fig. 1. Three types of distraction osteogenesis have been described: Monofocal, bifocal, and trifocal. (Reprinted from Costantino et al. (p543)

3.3 Types of distractors: internal and external

One of the primary planning considerations in maxillofacial distraction osteogenesis is the use of either an external distraction framework or an internal device. Critical to this decision is an evaluation of the goals of the distraction process (McCarthy et al. 1996, 1998). The external devices have the powerful advantages of allowing bone distraction in three planes

and allowing the surgeon to alter the direction, or vector, of the distraction process while the distraction is proceeding. The external distractors allow for easier adjustment of the direction of the distraction. However, the longer the distance from the axial screw of the distractor to the callus, the less effective the distraction. Pensler et al. (1995) first reported this principle of “molding the regenerate” in 1995. The “molding” takes advantage of the ability to manipulate the semisolid state of the nonmineralized, and hence nonrigid, bone in the distraction gap. This allows for “fine-tuning” of the distraction process while the distraction is proceeding, and thus permits dental relationships to be adjusted before the patient enters the consolidation phase of bone healing (Luchs et al. 2002). The external framework also allows greater amounts of ultimate expansion length. Expansions of 40 mm or greater have been reliably obtained. The disadvantages of an external frame distractor are the creation of a facial scar and the increased distance from the body of the distractor to the bone surface, leading to a longer “moment arm” at the pin-bone interface and an increased possibility of pin loosening. In addition, there is the need for “pin care” by the patient at the percutaneous pin sites (Gosain et al. 2002). The goal of distraction with internal devices is generally more modest, in the range of 25 mm or less. This is a consequence of the constraints placed on the physical size of the device and the ability to fit it within the mouth. In addition, the direction of the distraction cannot be altered after the device is placed. Development of miniature, internal distraction devices have made this clinically feasible and practical.

3.4 Physiologic process of DO

Several factors influence the physiologic process of DO, and these can be separated into 2 basic groups: bone healing factors and distraction factors as Table 1:

| Local Bone-Healing Factors | Systemic Bone-Healing Factors | Distraction Factors |
|----------------------------|-------------------------------|-------------------------------|
| Osteoprogenitor supply | Age | Rate of distraction |
| Blood supply | Metabolic disorders | Frequency of distraction |
| Infection | Vitamin D deficiency | Latency period |
| Soft tissue scarring | Connective tissue disease | Rigidity of fixation |
| Bone stock | Steroid therapy | Adequate consolidation period |
| Prior radiation therapy | Calcium deficiency | Length of regenerate |

Table 1. Factors that affect physiologic process of DO (Imola et al. 2002, 2008)

Factors that affect bone healing can be local or systemic in nature. Viability of osteocytes and osteoblasts is essential to provide an adequate source of osteogenic activity at the distraction site. Hence, careful surgical technique should be used to minimize thermal or mechanical injury to the periosteum and endosteum, which are the main sources of osteoblast precursors. Similarly, an adequate blood supply to the distraction site is critical to osteogenesis. Arterial insufficiency may lead to ischemic fibrogenesis within the regenerate, yielding a loose, irregular collagen network instead of the desirable dense, regular collagen pattern. Venous outflow obstruction has been associated with cystic degeneration of the regenerate. The clinician, therefore, needs to ensure that the soft tissues that surround the site of the proposed distraction are well vascularized. Early studies in long bones concluded that both an intact

periosteum and endosteum were critical to successful osteogenesis; therefore, many advocated that a corticotomy be performed only through a minimal periosteal opening. More recently, however, investigators have demonstrated that the periosteum alone can provide sufficient osteogenic capacity for a healthy regenerate, and this is especially true in the well-vascularized membranous bone of the craniofacial skeleton. Prior radiation therapy to the distraction site has been shown to not adversely influence the results of distraction in the canine model, and when using DO to repair segmental defects, the status of the surrounding soft tissues will likely be the key factor that influences outcome (Gantous et al. 1994).

3.5 Distraction phases

DO is divided into 3 distinct phases, namely the latency phase, the distraction (activation) phase, and the consolidation phase. Of these, the 2 early phases are of relatively short duration and are not associated with substantial morbidity or complications. The consolidation phase, however, entails a prolonged period of immobilization, which may result in serious complications.

Latency is that period immediately following the osteotomy and application of distractor; it ranges from 1 to 7 days. In most cases, the osteotomy creates an initial defect of approximately 1.0 mm. The basic principles of using new fresh burrs, using constant irrigation during the drilling process, and minimizing thermal injury to the bone must be strictly followed in this technique. Furthermore, the actual placement of the pins and/or screws should be meticulous. If a pin or screw needs to be backed out, it is often better to drill a new hole and place the pin/screw with a fresh placement than to risk unstable and inadequate fixation that will loosen and lead to failure of the distraction process. After the latency phase is the activation phase. To achieve targeted bone growth, a rigid stretching device delivers tensile force to the developing callus at the site of the bone cut. During this phase, the distraction device is activated by turning some type of axial screw, usually at 1 mm/day in four equal increments of 0.25 mm each. Once activation is complete, the third and final phase is the consolidation phase (Fig. 2). Typically, the consolidation phase is twice as long as the time required for activation (Ilizarov, 1988). Today, many different devices are being used clinically, with many different distraction protocols.

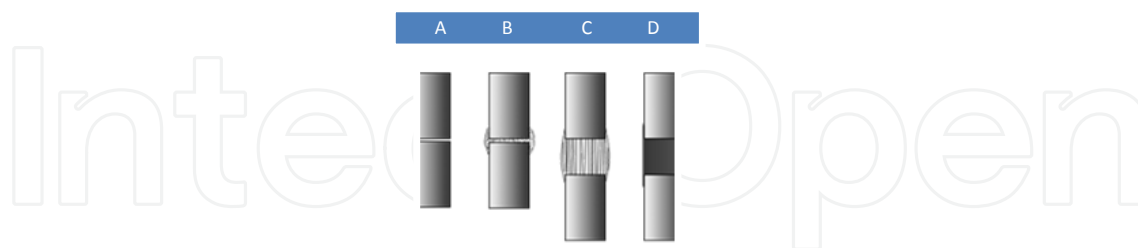


Fig. 2. Distraction phases: A) Osteotomy, B) Latency period, C) Distraction period, D) Consolidation period

In younger patients, distraction using the corticotomy of the external cortex is possible because the bone is very soft and pliable. However, in adults it is possible that the distraction device could deviate or distraction could fail due to resistance because the internal cortex does not fracture. Latency, rate, and rhythm of distraction are variables that influence the quality of the regenerate. Of these factors, the effect of latency is the most controversial (Aronson, 1994; Chin, 1999; Chin & Toth, 1996). Most craniofacial surgeons

have empirically applied the conclusions from long bone studies and recommend waiting periods of 4 to 7 days following osteotomy and before initiating the distraction process. In younger children, the high rate of bone metabolism favors a shorter waiting period. Some clinicians, however, use a zero latency period and begin distracting right at the time of appliance insertion. They claim no adverse effects on outcome while substantially shortening the treatment period (Chin & Toth, 1996; Toth et al. 1998). Waiting too long before distraction (beyond 10 to 14 days) substantially increases the risk of premature bone union. In contrast to latency, the rate and rhythm (frequency) of distraction are believed to be important factors (Aronson, 1994). If widening of the osteotomy site occurs too rapidly (>2 mm per day), then a fibrous nonunion will result, whereas if the rate is too slow (<0.5 mm per day), premature bony union prevents lengthening to the desired dimension. These findings in long bones have been empirically applied to the craniofacial skeleton, and most studies have described a rate of 1.0 mm per day. According to Ilizarov's work in long bones, the ideal rhythm of DO is a continuous steady-state separation of the bone fragments (Ilizarov, 1971, 1988, 1989a, 1989b). However, this is impractical from a clinical standpoint, and therefore, most reports recommend distraction frequencies of 1 or 2 times daily. A 1-mm/day rate of distraction (2×0.5 mm) and a 5- to 7-day latency seem to be generally accepted as the gold standards in the field of craniofacial distraction osteogenesis (Guerrero et al. 1997; Bell et al. 1999; Mommaerts, 1999; Braun et al. 2002; El-Hakim et al. 2004; Iseri & Malkoc, 2005; Gunbay et al. 2008a; Gunbay et al. 2008b; Gunbay et al. 2009). In the craniofacial skeleton, most authors advocate 4 to 8 weeks, with the general rule that the consolidation period should be at least twice the duration of the distraction phase (Aronson, 1994; Chin & Toth, 1996; Polley & Figueroa, 1998; Shetye et al. 2010). Distraction in load-bearing bones, such as the mandible, is an indication for a longer consolidation time. Appliance rigidity during distraction and consolidation is a critical element to ensure that bending or shearing forces do not result in microfractures of the immature columns of new bone within the regenerate, which lead to focal hemorrhage and cartilage interposition (Aronson, 1994).

The histophysiology of DO is based on the slow steady traction of tissues, which causes them to become metabolically activated, resulting in an increase in the proliferative and biosynthetic functions. The premise then is that the newly generated bone between distracted bony ends will result in a stable lengthening and behave as "new" bone, appropriately responding and adapting to the regional environmental loads placed on it.

DO takes place primarily through intramembranous ossification. Histological studies identified 4 stages that result in the eventual formation of mature bone.

Stage I: The intervening gap initially is composed of fibrous tissue (longitudinally oriented collagen with spindle-shaped fibroblasts within a mesenchymal matrix of undifferentiated cells).

Stage II: Slender trabeculae of bone are observed extending from the bony edges. Early bone formation advances along collagen fibers with osteoblasts on the surface of these early bony spicules laying down bone matrix. Histochemically, significantly increased levels of alkaline phosphatase, pyruvic acid, and lactic acid are noted.

Stage III: Remodeling begins with advancing zones of bone apposition and resorption and an increase in the number of osteoclasts.

Stage IV: Early compact cortical bone is formed adjacent to the mature bone of the sectioned bone ends, with increasingly less longitudinally oriented bony spicules; this resembles the normal architecture.

As the bone undergoes lengthening, each of these stages are observed to overlap from the central zone of primarily fibrous tissue to the zone of increasingly mature bone adjacent to the bony edges. By 8 months, the intervening bone within the distraction zone achieves 90% of the normal bony architecture. It is believed that the architecture is maintained and that the bone responds to normally applied functional loads (Imola et al. 2008).

3.6 Indications of DO

Current usage falls into 3 broad groups as follows:

a. Lower face (mandible)

- Unilateral distraction of the ramus, angle, or posterior body for hemifacial microsomia
- Bilateral advancement of the body for severe micrognathia, particularly in infants and children with airway obstruction as observed in the Pierre Robin syndrome
- Vertical distraction of alveolar segments to correct an uneven occlusal plane or to facilitate implantation into edentulous zones
- Horizontal distraction across the midline to correct crossbite deformities or to improve arch form

b. Mid face (maxilla, orbits)

- Advance the lower maxilla at the LeFort I level
- Complete midfacial advancement at the LeFort III level
- Closure of alveolar bony gaps associated with cleft lip and palate deformities
- Upper face (fronto-orbital, cranial vault)
- Advancement of the fronto-orbital bandeau, alone or in combination with the mid face as a monobloc or facial bipartition
- New use of distraction as a means of cranial vault remodeling by gradual separation across resected stenotic sutures

Established indications for craniofacial DO include the following:

a. Congenital indications

- Nonsyndromic Craniofacial Syndrome - Coronal (bilateral or unilateral) or sagittal
- Syndromic Craniofacial Syndrome (Apert, Crouzon, and Pfeiffer syndromes)
- Facial clefts, cleft lip and palate
- Patients with severe severe sleep apnea
- Hemifacial microsomia
- Severe retrognathia associated with a syndrome (eg, Pierre Robin syndrome, Treacher Collins syndrome, Goldenhar syndrome, Brodie Syndrome), especially in infants and children who are not candidates for traditional osteotomies
- Bimaxillary crowding with anterior-posterior deformity
- Bimaxillary deficiencies (Lengthening and widening)
- Asymmetry
- Mandibular hypoplasia due to trauma and/or ankylosis of the temporomandibular joint

b. Acquired indications

- Reconstruction of posttraumatic deformities (midfacial retrusion or mandibular collapse)
- Insufficient alveolar height and/or width (Maxillary or mandibular alveolar distraction)
- Reconstruction of oncologic and/or aggressive cystic jaws defects

- Previously failed bone graft sites
- Insufficient soft tissue coverage
- Patient is not a candidate for a bone graft

3.7 Advantages and disadvantages of DO

Generally, facial deformities have been corrected by conventional osteotomy of the jaws and bone grafting. Conventional osteotomy has some advantages, such as the possibility of shorter hospital stays and obtaining precise preferable occlusion. However, despite these advantages the amount of mobilization may be limited and is determined by the preoperative orthodontic treatment obtaining a stable occlusal relationship between the maxilla and mandible. In addition, operative blood loss may be massive, occasionally requiring blood transfusion, with an autogenous bone graft being mandatory when rigid fixation materials are used. Intermaxillary fixation is required for 2 to 4 weeks after the operation. Relapse by absorption of the grafted bone is unclear. The advantages of distraction osteogenesis compared with conventional osteotomy are that it reduces operative times and blood loss, bone grafts are naturally unnecessary, and bone is distracted in conjunction with the surrounding soft tissues and nerves. These adaptive changes in the soft tissues decrease the relapse risk and allow the treatment of severe facial deformities. In addition, the length of distraction can be set freely and regulated within the limits of the device. Comparatively small relapses are another major advantage of distraction. Distraction also offers enormous advantages in jaw bones because they are covered with special fixed mucosa gingiva. Distraction in the maxillofacial area also has several merits because intermaxillary fixation is not necessary, no temporomandibular dysfunction is left, and fine adjustment of occlusion is possible. However, distraction osteogenesis has some disadvantages such as technique sensitive surgery, equipment sensitive surgery, possible need of second surgery to remove distraction devices and patient compliance. From a surgical standpoint, an adequate bone stock is necessary to accept the distraction appliances and to provide suitable opposing surfaces capable of generating a healing callus. Therefore, in patients who have undergone several craniofacial procedures in the past, the facial skeleton may exist in several small discontinuous fragments unsuitable for distraction. In these cases, bone grafting the gaps first may be possible, followed by distraction on a delayed basis.

3.8 Complications of DO

Complications can be divided into 3 groups: A) Intraoperative, B) Intradistraction, and C) Postdistraction complications.

- The intraoperative complications concern the surgical procedure (eg, malfracturing, incomplete fracture, nerve damage, and excessive bleeding) and device-related problems (eg, fracture and unstable placement).
- Intradistraction complications concern those arising during distraction (eg, infection, device problems, pain, malnutrition, and premature consolidation).
- Postdistraction complications concern the late problems arising during the period of splinting and after removal of the distraction devices (eg, malunion, relapse, and persistent nerve damage (Samchukov et al. 2001).

The infection rate associated with distraction osteogenesis in general is reported as varying between 5% and 30% (Samchukov et al. 2001). However, these complications are mainly

related to the application of external distraction devices. Infection is nevertheless mentioned as the most common complication during distraction. Notwithstanding that bacterial contamination is possible during the weeks of distraction and consolidation, the preventive administration of antibiotics during both the placement and the removal of the devices, along with good oral hygiene, appear to be sufficient to reduce the infection rate to an acceptable level.

4. Distraction osteogenesis for maxillofacial application

4.1 Alveolar Distraction Osteogenesis (ADO)

Insufficient bone height leads to overloading of osseointegrated implants and jeopardizes the longevity of the prosthetic restoration. A common pattern for vertical bone deficiency in this location is the loss of bone due to periodontitis or to trauma or subsequent to dental extraction. If socket preservation is not done, the alveolus narrows and alveolar vertical dimension is often reduced. (Froum et al. 2002; Vance et al. 2004) Vertical regeneration of resorbed alveolar ridges is still a challenging surgical procedure, especially in case of extensive bone atrophy. Several augmentation techniques have been proposed, even in cases with limited bone support and inadequate nourishment. These procedures often involve the use of bone substitutes or the harvesting of autogenous bone from a donor site. Autogenous bone is believed to be the most effective bone graft material and is still regarded as the “gold standard” for augmentation procedures because of its osteogenic potential. However, this graft has a limited availability; furthermore, the surgical harvesting procedures might cause additional morbidity. (Cricchio & Lundgren, 2003; Nkenke et al. 2002; Sasso et al. 2005)

Difficulties have been encountered to simultaneously augment the width and height of the deficient ridge. Crestal split technique is efficient in lateral widening but not vertical augmentation (Palti, 2003). Onlay bone graft or guided bone regeneration technique is especially useful for augmenting the ridge width but, to some extent, has limited advantages in increasing the ridge height (Nkenke et al. 2002; Simion et al. 1994). The interpositional bone graft procedure also has technical difficulty in a limited edentulous ridge. Additionally autogenous bone graft this graft has a limited availability; furthermore, the surgical harvesting procedures might cause additional morbidity. (Cricchio & Lundgren, 2003; Sasso et al. 2005). The various bone graft techniques can lead to wound dehiscence, infection, and possibly total failure of bone graft because of lack of appropriate soft tissue coverage in those traumatized areas. In addition, early membrane exposure may cause infection that may compromise the final outcome of the rehabilitation. This technique has been mainly applied to limited defects with vertical bone gains ranging from 2 to 7 mm, on average (Jovanovic et al. 1995; Simion et al. 1994).

ADO is a process used for vertical and horizontal distraction of the atrophic mandibular and maxillary alveolar ridges. This technique provides a very good quality of the neogenerated bone, with adequate characteristics for implant osseointegration. Alveolar distractors may be classified as intraosseous (endosseous) or extraosseous (subperiosteal) according to their insertion techniques (Fig.3-Fig.9). Extraosseous distractors are placed over the buccal surface of the alveolus subperiosteally, whereas intraosseous ones are placed through the transport segment and fixed to the basal segment by microplates toward the vector of distraction. The first devices used for distraction surgery of the upper & lower jaws were large and

protruded through the patient's skin. The results were often satisfactory, but the facial scars and esthetic compromise of such devices made the process an option for only the more extreme cases. In the last few years the technology of distraction devices has progressed to the point where the distraction devices are all intraoral; thus avoiding the unsightly facial scars. Recently, new distraction devices have been developed to permit this nascent technique to be employed in the growth of bone for dental implants. In such cases a small section of the jaw bone is surgically cut and then gently distracted to grow both height or width of bone. After a short healing period dental implants can be placed. In alveolar distraction, the vertical bone gain may reach more than 15 mm, it is obtained in amore 'physiologic' way, with no need of bone transplantation, thus reducing morbidity. Another main advantage may include a progressive elongation of the surrounding soft tissues with very limited risk of wound dehiscence and bone exposure. In most distraction cases the need for extensive bone grafting is eliminated. The final result, be it advancement of the jaws or the growing of bone for implants, is often reached in less time than with grafting, with superior results, and less patient discomfort (Gunbay et al. 2008b; Uckan et al. 2002). ADO is not an uncomplicated procedure, and the occurrence of relapse of the distracted segment seems to necessitate an overcorrection of 15–20%. Survival of dental implants inserted into distracted areas has been shown to be satisfactory.

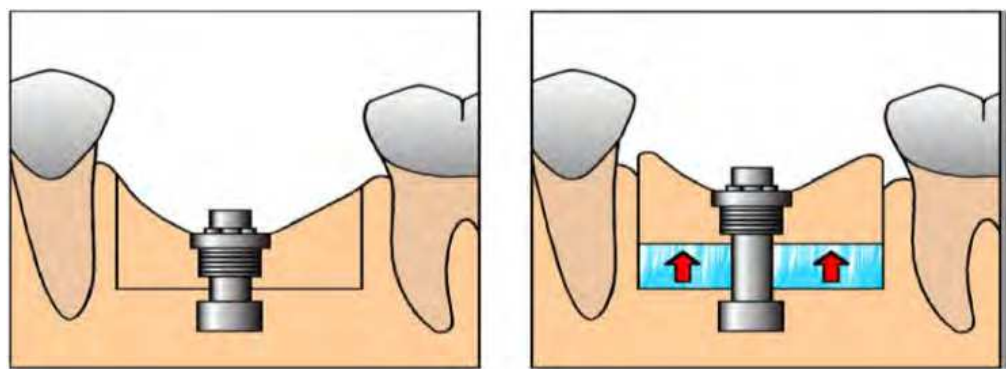


Fig. 3. OsteoGenic Distractor System

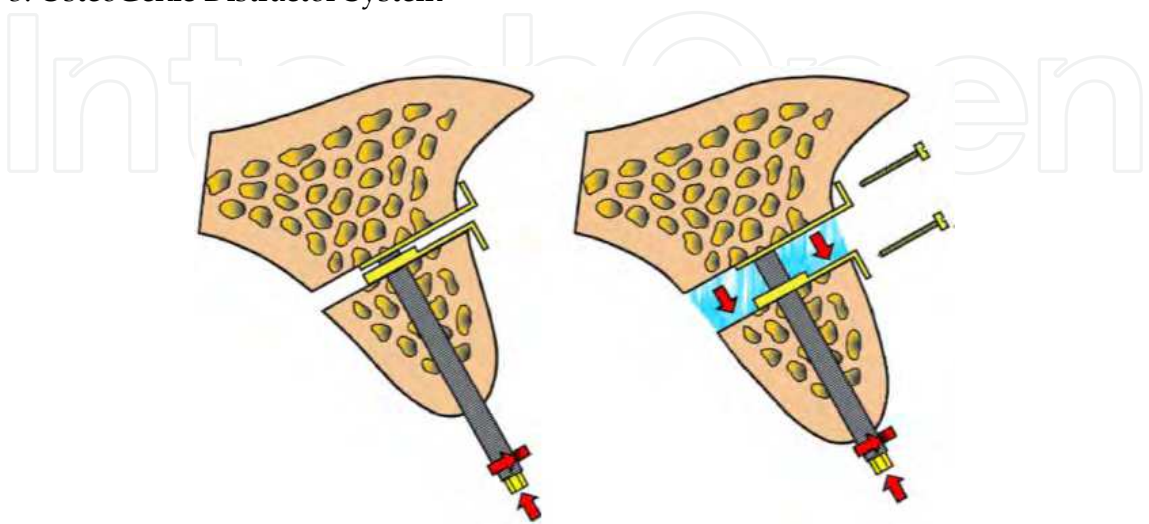


Fig. 4. LEAD Distractor System

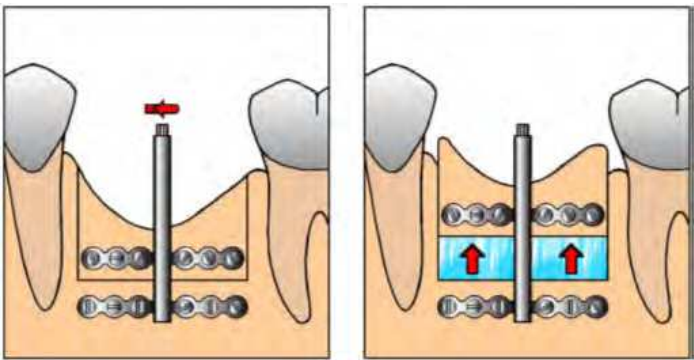


Fig. 5. TRACK 1.0 Distractor

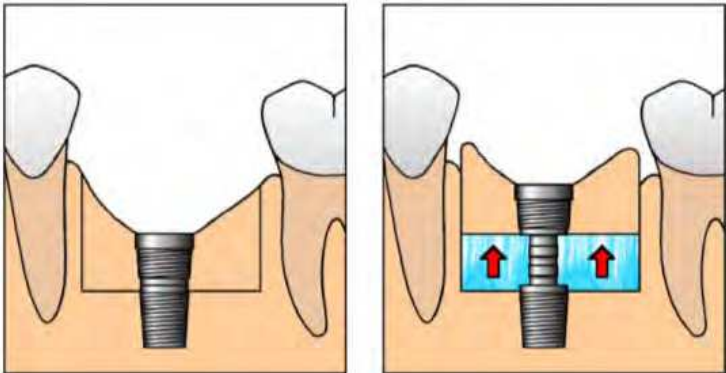


Fig. 6. DISSIS Distractor-Implant.

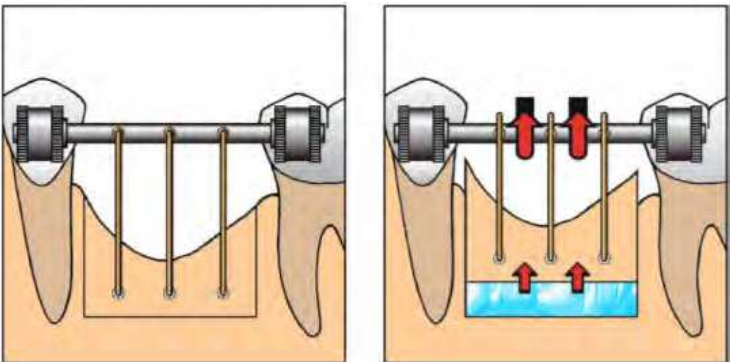


Fig. 7. ROD5 Distractor.

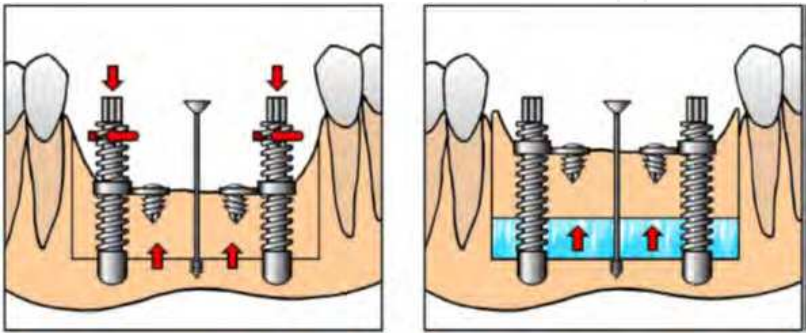


Fig. 8. GDD Distractor. (Fig.3-Fig.8 Reprinted from Cano et al. 2006)



Fig. 9. The Endodistraction Implant System: The cortical screw is placed inside a hollow Implant, which rests on top of the shoulder of the threaded rod. A silicon seal inside the hollow implant prevents contact of saliva to bone (Krenkel and Grunert, 2007)

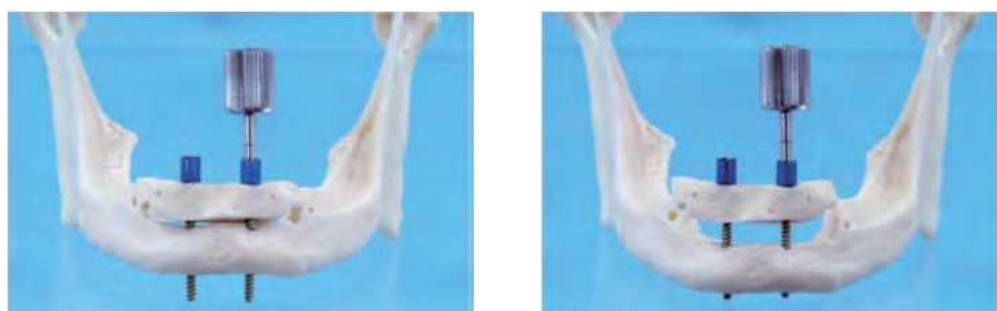


Fig. 9.a.b. Endodistraction Implant before (a) and after (b) distraction (Krenkel & Grunert, 2007).

An ideal distraction device for the edentulous jaws should include the following characteristics:

1. Minimal trauma for tissues and blood vessels during application
2. Maximal comfort for the patient during speaking and eating
3. Not compromising aesthetics
4. Guarantee for reaching the planned height and direction of augmentation of the alveolar ridge
5. Minimal risk of infection
6. Chance for continuing distraction in case of problems or pitfalls during the primary distraction period
7. Minimal invasive removal
8. Perfect stabilization of the new formed bone when placing implants
9. No limitations for using any type of dental implants

Complications of alveolar distraction and possible solutions

Infection of distraction chamber. Prevent by prophylactic antibiotic treatment and adequate mucosal covering. Treatment: Antibiotics.

Fractures of transported or basal bone. Prevent by the use of very fine blades in the osteotomy and avoiding expansion of the bone. Treatment: Suspend the distraction and treat with osteosynthesis.

Premature consolidation. Prevent by performing a complete osteotomy and using the appropriate distraction rate and distraction vector. Treatment: Repeat osteotomy.

Consolidation delay and absence of fibrous union. Prevent with a correct stabilization of the distractor. Treatment: Delay distractor withdrawal until consolidation; in absence of fibrous union, carry out debridement of the area and reconstruct using other regeneration techniques.

Slight resorption of the transported fragment. Prevent with an overcorrection of the defect of around 2 mm.

Wound dehiscence. Prevent by smoothing the sharp edges of the transported fragment. Treatment: Resuture soft tissues to prevent infection of the distraction chamber.

Distractor instability. Prevent by prior evaluation of the bone density and distractor model used. Treatment: Specific, depending on the distractor design.

Deviations from the correct distraction vector. Prevent with prior evaluation of the thickness of the mucosa and vestibular and lingual muscle insertions. Treatment: Early correction with acrylic plates or orthodontic corrective devices.

Neurological alterations. Prevent with correct localization of osteotomy and placement of retention screws. Treatment: Immediate withdrawal of screws; microsurgery.

Distractor fractures. Prevent with evaluation of the occlusion and avoidance of interferences. Treatment: Immediate withdrawal of fractured fragments and their repositioning according to the phase of the process.

High cost of distractors.

Need for the collaboration of the patient or family member for activation of the distractor. (Cano et al. 2006)

4.2 Transpalatal Distraction Osteogenesis (TPDO)

Transverse maxillary deficiency is frequently observed in adult patients and may be responsible for unilateral or bilateral posterior cross-bite and anterior teeth crowding. This defect may be associated with a sagittal or vertical jaw discrepancy. In some cases, the transverse deficiency is apparent (relative) and resolves with jaw repositioning, but in all other cases it is essential to include transverse augmentation in the treatment plan, in order to achieve stable, satisfactory occlusion. Different approaches can be considered for correction. Orthodontic devices may move the teeth buccally, but do not augment bone transversally. Consequently, they can only be applied to small discrepancies. Since the comprehensive fundamental clinical investigations carried out by Derichsweiler in 1956, rapid expansion of the midpalatal suture has become an established, proven method for treating children and adolescents with severe transverse maxillary deficiencies combined with crossbite. Generally, non-surgical expansion is indicated in patients under the age of 12 years and is associated with complications when used in skeletally mature patients (Mommaerts, 1999). In adults, this technique has frequently led to complications such as buccal tipping, extrusions, root resorption and fenestrations of the alveolar process at the supporting teeth absorbing the force (Mommaerts, 1999; Moss, 1968; Neyt et al. 2002).

For many years, maxillary width discrepancies have been corrected in pediatric patients solely by orthodontic therapies, such as slow orthodontic expansion (SOE) and rapid palatal expansion (RPE), and in adult patients by surgical treatments such as surgically assisted rapid palatal expansion (SARPE) and 2-segment Le Fort I-type osteotomy with expansion (LFI-E). Although commonly performed, these therapies present some problems related to the tooth-borne appliances (ie, SOE, RPE, SARPE), including alveolar bone bending, periodontal membrane compression, root reabsorption and lateral tooth displacement and extrusion (Glassman et al., 1984). Longterm stability remains problematic as well (Haas

1980). Relapse is the main problem after a LFI-E maxillary osteotomy combined with a midpalatal osteotomy (Koudstaal et al. 2005), probably due to the lack of a palatal retention appliance, fibrous scar retraction, and palatal fibromucosal traction (Matteini & Mommaerts, 2001). An increment in the transverse diameter obtained entirely via bone formation, with no dental compensation, the absence of dental or osseous relapse, and no dental or periodontal damage, represents the ideal goal in treating the narrow maxilla. DO has been proven to ensure new bone formation at the osteotomy site without fibrous scarring in the maxillofacial skeleton (Nocini et al. 2002). TPDO is a new method for treating transversal maxillary deficiency using the DO procedure, which has proven very valuable in other surgical fields (Mommaerts, 1999). Transpalatal distraction device is a bone-borne appliance that directs the forces mainly to the palatal helvices close to the center of resistance of the maxillary bone without tooth movement; it also leaves all of the crowns clear for orthodontic access (Mommaerts et al., 1999). Additionally, most of the maxillary expansion is orthopaedic (Aras et al. 2011; Koudstaal et al. 2006). TPDO is an effective and largely painless technique for maxillary expansion free of complications and relapses. Since no teeth are used for distractor fixation but the alveolar processes undergo bodily lateral distraction below the osteotomy lines, all problems induced by forces acting upon anchorage teeth are eliminated (Fig.10-11). Moreover, the use of these appliances is not dependent on the number of anchorage teeth available. TPDO has been used extensively in the expansion of maxillary collapse in non-congenital defects (Gunbay et al. 2008a; Koudstaal et al. 2006; Mommaerts, 1999). Recurrence of the collapse and alveolar bone effects are among the reported complications (Gunbay et al. 2008a; Mommaerts, 1999; Suri & Taneja, 2008). Transverse maxillary expansion with a bone-borne transpalatal distractor has been used with favourable results in congenital and acquired transverse maxillary deficiency (Gunbay et al. 2008a; Koudstaal et al., 2006; Mommaerts, 1999; Suri & Taneja, 2008; Vyas et al. 2009). In many studies, effects of transversal expansion have been examined by posteroanterior cephalometric measurements in dentoalveolar, maxillary base and nasal regions. Innovation of computed tomography (CT) technology, now makes it possible to acquire radiographic images with high resolution and diagnostic reliability that allow investigators to evaluate the changes at different levels of maxilla and nasal cavity (Aras et al. 2011; Garrett et al. 2008; Gunbay et al. 2008a; Phatouros & Goonewardene, 2008; Podesser et al. 2007). Considering the problems encountered, no major surgical complications are expected from transpalatal distraction, except for the potential damage to the periodontal tissues adjacent to the midline osteotomy. In TPDO technique, especially vertical osteotomy is very important because this can damage dental structures. Close root proximity between the maxillary central incisors presents a problem in the surgical management of a maxillary palatal expansion. If the roots of the teeth are too close together in the area of the planned interdental osteotomy, the roots must be diverged to create adequate room for the bone cut. Vertical osteotomy must be done carefully. Any incorrect placement of a TPD may also damage the surrounding blood vessels and premolar or molar roots. Bony anchorage can bring about a number of complications, which have not been studied so far. In the searched TPD literature, wound infection, epistaxis, haematoma in cheek, maxillary sinusitis, infraorbital hypoaesthesia, palatal ulceration, displacement or loosening of transpalatal modules and abutment plates, extrusion of osteosynthesis screws, segmental tilting and dental complications due to vertical osteotomy were mentioned (Aras et al. 2011; Gunbay et al. 2008a). Minor difficulties that result from mechanical failure of TPD device might be eliminated with refinement of the instrumentation.

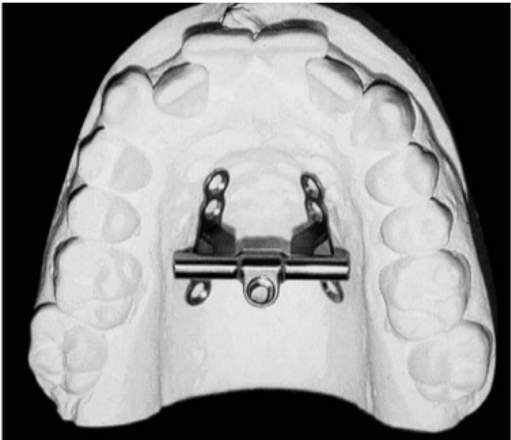


Fig. 10. Palatal distractor on a dental cast (Reprinted from Gerlach & Zahl 2003).

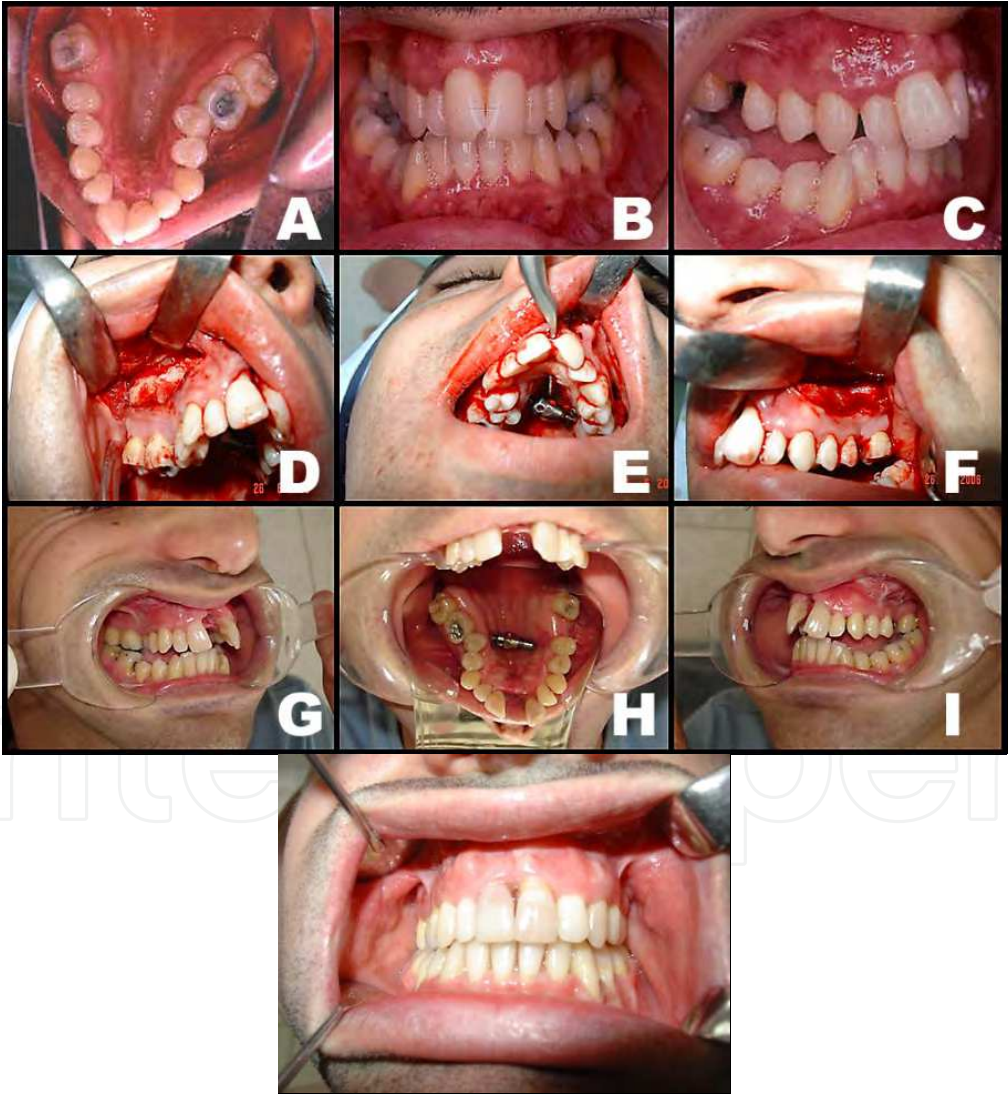


Fig. 11. Clinical appearance of our 1.case with severe maxillary deficiency, before treatment (A-C), of osteotomies (D-F), and in postdistraction period (G-I). Clinical appearance of the patient - 7 years after orthodontic treatment)

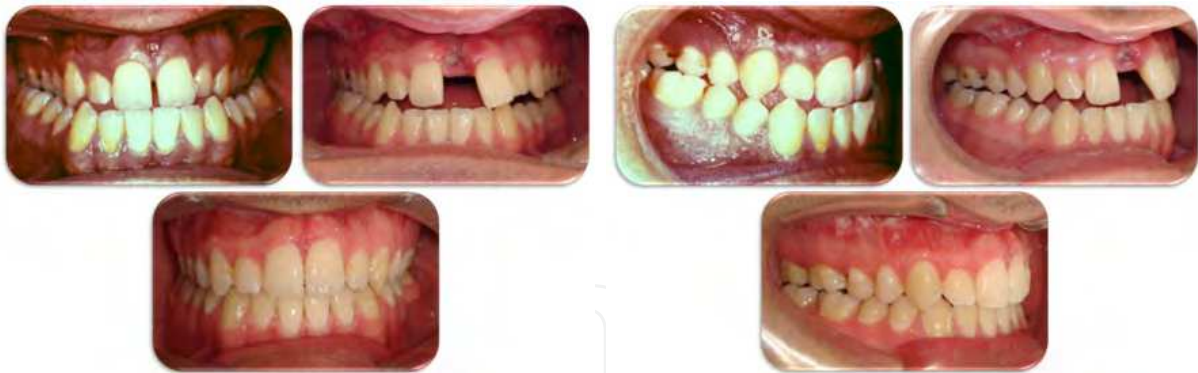

Fig. 12. A. Clinical appearance of our 2. case, the pretreatment, postdistraction period and after orthodontic treatment

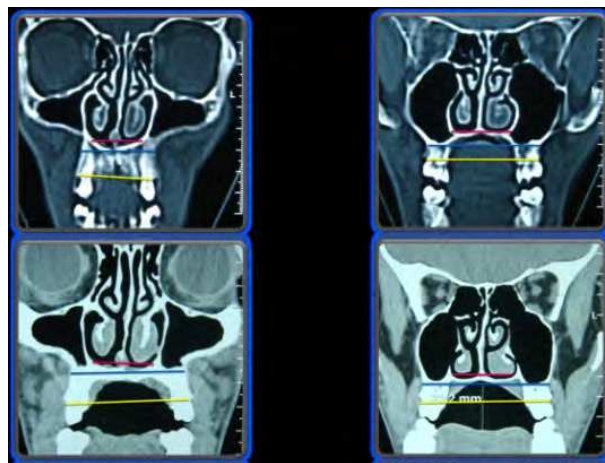


Fig. 12. B. CT measurements at the maxillary canine and first molar region-Pre and postdistraction period.

4.3 Transmandibular Distraction Osteogenesis (TMDO)

Mandibular transverse deficiency (MTD) and crowding of the anterior teeth are problems shared by most orthodontic patients. MTD is a common clinical problem associated with narrow basal and dentoalveolar bone (Del Santo et al. 2000, 2002; Guerrero et al. 1990). Attention to the transverse deficiencies is vital in planning treatment for a patient who requires an increase in the lateral dimension of the mandible. The conventional approaches for correcting mandibular crowding are extraction of teeth, dentoalveolar expansion or interproximal enamel reduction. Orthodontic treatment options include functional appliances, and orthopedic devices. MTD in mix dentition stage are commonly treated with orthodontic expansion using lip bumpers, Schwarz's device, or functional devices. These therapies Show relatively stable results for younger patients, particularly those who presented with lingually tipped teeth that need to be decompensated (McNamara & Brudon, 1993). But mandibular expansion or incisor protrusion in the anterior area is generally unstable and tends to relapse toward the original dimension and with a compromised periodontium created by moving teeth out of their supporting alveolar bone in the long term (Blake & Bibby, 1998; Guerrero et al. 1997; Herberger, 1981). Previously in adult patients, the sole correction technique of symphyseal osteotomy has been proposed as a

solution for treatment of MTD. However, this surgical procedure has not been well accepted because of lack of rigid fixation, need to use bone grafts, risk of periodontal problems that may occur when the bone segments are rapidly and excessively separated and increased risk of relapse (Conley & Legan, 2003). The mandible was the initial site of application of distraction osteogenesis in the face. The mandible's structure is similar to the tubular structure of the long bones of the skeleton. Principles learned by orthopedic surgeons over the previous 80 years from distraction of the long bones of the lower extremity were rapidly adapted to this new location (Synder et al. 1973; Michieli & Miotti, 1977). Since first described by McCarthy et al. in 1992, DO of craniofacial bones has increasingly become a mainstay in bone regeneration. DO has provided a powerful tool for treatment of many mandibular deformities that previously could not be successfully treated by the conventional methods of orthognathic surgery, free tissue transfer, or nonvascularized bone grafts (Havlik & Bartlett, 1994; McCarthy et al. 1996, 1998).

Transmandibular symphyseal distraction (TMSD) technique solve rapidly MTD problems. TMSD can be performed to increase the transverse dimension of the mandibular basal bone if the aim is to correct arch length deficiency by expanding the basal bone (Guerrero et al. 1997; Gunbay et al., 2009; Mommaerts et al. 2005, 2008; Uckan et al. 2005, 2006). With this clinical procedure, the mandibular geometry is definitively changed. Theoretically, greater stability could be expected if the expansion is performed slowly, allowing better adaptation of the soft tissues, and allowing bone to grow in the osteotomy site. Guerrero et al. (1990) pioneered the use of rapid surgical mandibular expansion for correcting MTD. Although vertical midsymphyseal osteotomy technique for treatment of MTD is used for many years, many investigators reported that in this method, mucosa and periodontal ligaments can not adopt to rapid movement of bone fragments after osteotomy. Compared with distraction osteogenesis, vertical midsymphyseal osteotomy is a more extensive surgical procedure involving a higher risk of relapse, a longer operative time, the requirement of bone grafts and internal fixation (Guerrero et al. 1997; Martin, 1998).

TMSD is a successful surgical alternative to orthodontic dental compensation, removal of tooth mass by interproximal stripping, or extractions in cases of transverse anterior mandibular discrepancy (Guerrero et al. 1990, 1997; Gunbay et al., 2009; Mommaerts, 2001; Mommaerts et al., 2004a, 2004b; Mommaerts & Vande Vannet, 2004; Mommaerts et al., 2005). Several authors have proven the efficacy of this technique in animal experiments (Bell et al. 1999; El-Hakim et al. 2004) and in small clinical series (Kewitt & Van Sickels, 1999; Weil et al. 1997). The distraction device itself can be tooth-borne (Alkan et al. 2006; Braun et al. 2002; Del Santo et al. 2000, 2002; Guerrero et al. 1997; Iseri & Malkoc, 2005; Orhan et al. 2003; Tae et al. 2006), bone-borne (Bell et al. 1999; Braun et al. 2002; El-Hakim et al. 2004; Gunbay et al. 2009; Iseri & Malkoc, 2005; Mommaerts, 2001), or a combination of both (Duran et al., 2006; Uckan et al. 2005, 2006). There are some conflicts on the use of different types of symphyseal distractor. Toothborne distractors have some serious disadvantages such as periodontal problems, buccal root resorption and cortical fenestration, segmental tipping and anchorage-tooth tipping, loss of anchorage. In TMSD technique, the forces act directly on symphyseal bone region. Therefore no tooth tipping and other unwellcome dental effects are expected and most of the mandibular expansion is orthopaedic. Many authors state that the bone-borne devices applied directly to the symphysis lead to greater skeletal effect than dental effects.

One of the most important potential side effects of TMSD is alteration of temporomandibular joint function. Harper et al. (1997) studied the impact of a tooth-borne

appliance for mandibular symphyseal DO in monkey's mandibular condyle. They found that the histologic changes in the condyles were minor, limited to atypical morphology. Using computer modeling, Samchukov et al. (1998) showed lateral rotational movement of the condyles subsequent to mandibular widening, and reported 0.34-degree condylar rotation for every 1 mm of widening at the mandibular midline. Fortunately, the human temporomandibular condyle is known to have some degree of physiologic adaptability (Gunbay et al. 2009; Uckan et al. 2006)

The location of the TMD device are another important issue. This is critical because this may affect the ratio of skeletal/dental expansion. An obliquely positioned distractor may result in asymmetric expansion (Basciftci et al. 2004; Orhan et al. 2003).

Complications at the level of the periodontal and endodontal status of the incisors and at the Temporomandibular Joints (TMJ) have been reported in another study (Mommaerts et al. 2005). Gunbay et al. (2009) reported that, the follow-up cephalograms and CT scans showed the transverse skeletal stability of the distraction procedure and no permanent temporomandibular dysfunction. The effect of the procedure on the condyle was 2.5 degrees to 3 degrees of distolateral rotation as calculated using the CT scans. The authors think that moderate symphyseal expansion will not cause clinical problems in the TMJ area. On the other hand, bony anchorage can bring about a number of complications, which have not been studied so far. In the TMSD literature some complications such as seriously hemorrhage and infection, damage to the inferior alveolar nerve and dental structures, pseudoarthrosis, jaw fractures and breakage of distractor device were reported (Bayram et al. 2007; Del Santo et al 2002; Gunbay et al., 2009; Kewitt & Van Sickels 1999; Uckan et al, 2006). Alkan et al. (2007) reported some complications of bone-borne distractors such as high cost, long operation time, and need for removal distractor in a second operation. The main problem during symphyseal transverse DO with the bone-borne Transmandibular Distractor device appears to be high local infection rates and patient discomfort due to delayed union. (Mommaerts et al. 2008; Gunbay et al. 2009) Mommaerts et al. (2008) suggested that in order to prevent late local infections, the device could be removed at the end of the distraction period and replaced by titanium or resorbable osteosynthesis plates. Because of the design of the TMSD, food remnants are easily stuck on activation rods and leads to chronic hyperplastic gingival infections. Therefore patients must be instructed to clean the device thoroughly on a daily bases and a regular visit to an oral hygienist should be arranged. The main advantage of the TMSD is that the device is located intraorally and preferred by the patients. Due to the design the TMSD is easily placed and activated. The use of this appliance is not dependent on the number of anchorage teeth available. Moreover, orthodontic appliances can be installed at an earlier date than when tooth-borne expanders are used. There is no need for dental anchorage that might cause damage to the dentition or dental tipping.

Although TMSD has become an extremely alternative technique for the maxillofacial surgeons, there is no consensus in literature regarding osteotomy techniques used in distraction osteogenesis procedure, type of distractor used, effects of the distraction loads on TMJ, dental and skeletal structures, cause and amount of relapse and whether or not overcorrection is necessary. In TMSD technique, especially vertical osteotomy is very important because this can damage dental structures. Close root proximity between the mandibular central incisors presents a problem in the surgical management of a TMSD. If the roots of the teeth are too close together in the area of the planned interdental osteotomy,

the roots must be diverged to create adequate room for the bone cut. Vertical osteotomy must be done carefully and accurately. From the surgical point of view, treatment planning should include analysis of a recent periapical radiograph of the incisor roots to determine the need for orthodontic root separation before surgery. 3–5 mm space between the apices of the central teeth is necessary to safely perform an interdental vertical osteotomy, without compromising periodontal health or tooth vitality. Removing bone and damaging the periodontal ligament along the root surfaces of adjacent teeth can result in periodontal defects or ankylosis of the involved lower central teeth during the following years. In cases of severe dental crowding on the midline, Mommaerts et al. (2008) currently prefer to place the interdental osteotomy at a site where there is a natural diastema at the apical level, which is frequently between the canine and lateral incisor. To prevent deviation of the chin, a vertical osteotomy is performed in the midline to 5 mm below the apices of the incisors. The two vertical osteotomy lines are then connected with an oblique subapical osteotomy. Mussa & Smith (2003) suggested creating a diastema pre-operatively using orthodontics. However, since severe crowding is the primary indication for symphyseal widening, nonextraction orthodontic widening is very difficult.

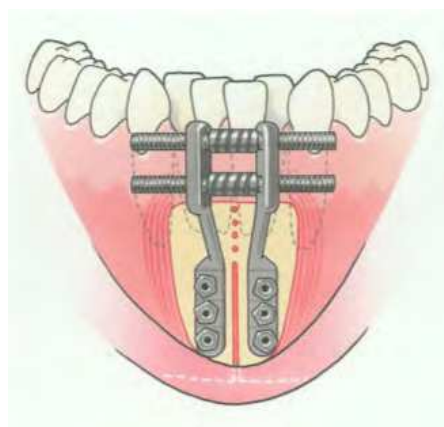


Fig. 13. Symphyseal vertical midline osteotomy, avoiding the mentalis muscles but endangering the apices of the central incisors when these are juxtaposed (Mommaerts et al. 2008).

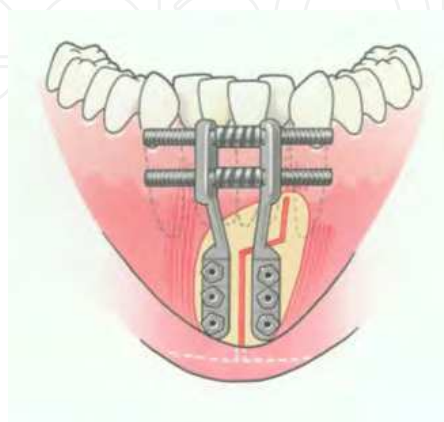


Fig. 14. Step osteotomy in the symphysis. The alveolus between the canine and lateral incisor is often much wider than between the central incisors (Mommaerts et al. 2008).

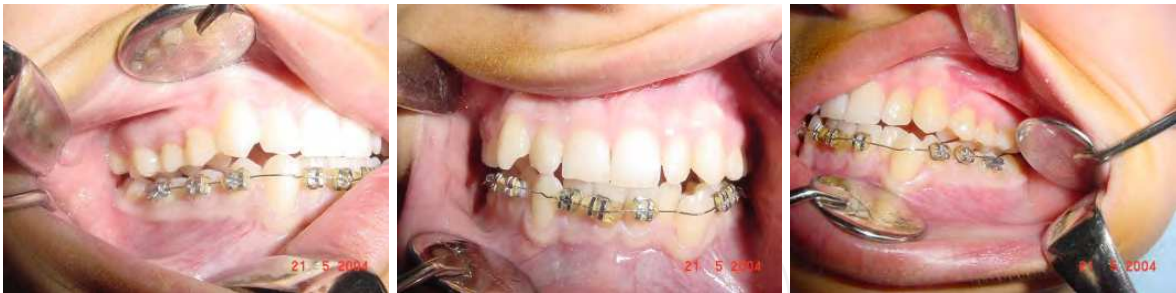

Fig. 15. A. Our case 3. Clinical appearance before TMSD treatment

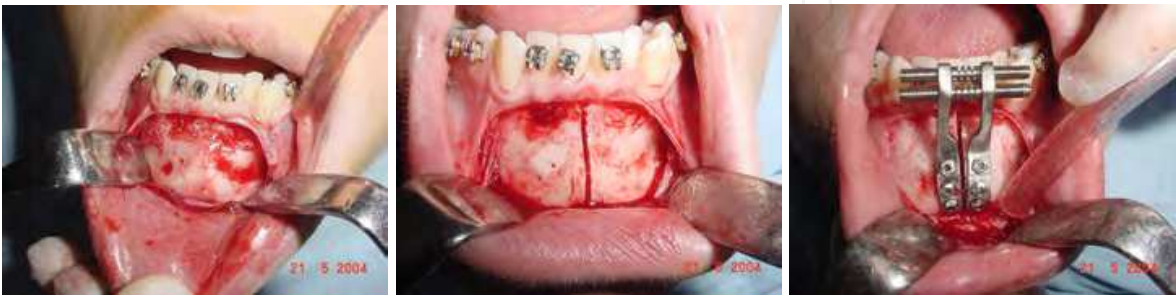

Fig. 15. B. Our case 3. Clinical appearance of osteotomies and predistractor period

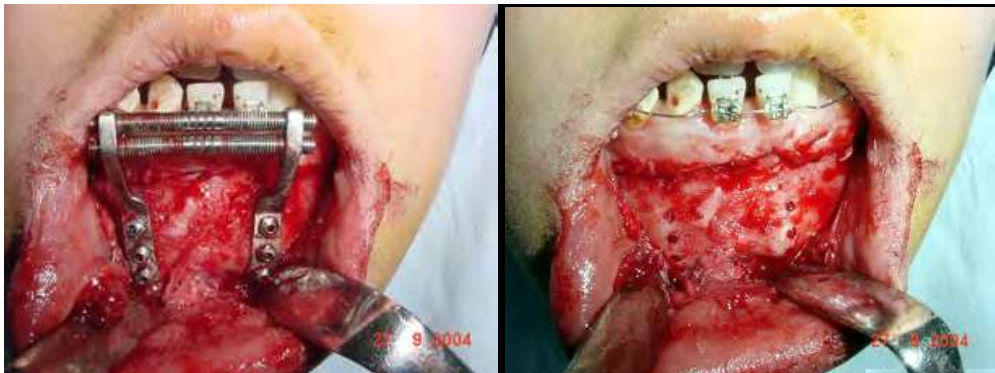

Fig. 15. C. Clinical appearance of new regenerated bone in postconsolidation period

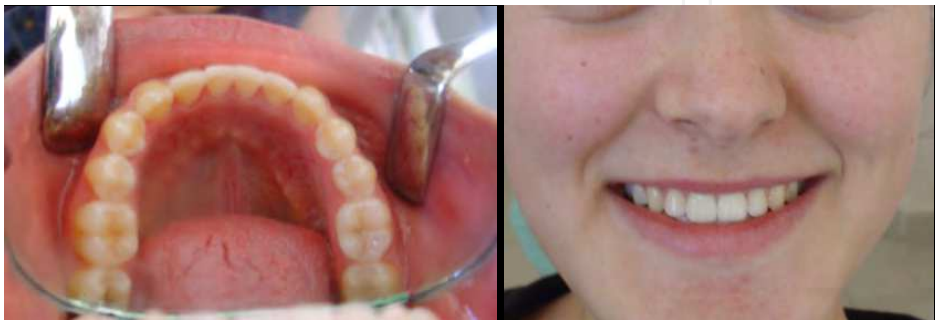

Fig. 15. D. Clinical appearance of postorthodontic treatment period

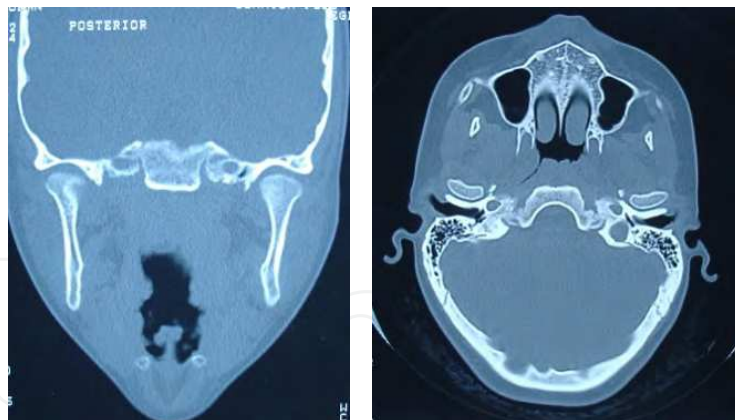


Fig. 15. E. CT imaging. In predistracton and postorthodontic treatment period

5. Conclusion

There are different treatment modalities for bimaxillary deficiencies in the recent literatures. Many surgeons find it difficult to decide which technique offers better results, and are also uncertain about the factors which might influence their techniques of choice. Distraction osteogenesis of the craniofacial skeleton has become increasingly popular as an alternative to many conventional orthognathic surgical procedures. For patients with mild to severe abnormalities of the craniofacial skeleton, distraction techniques have increased the number of treatment alternatives. Many of the adult distraction cases are significantly compromised, requiring a multidisciplinary approach to treatment. It is very important to consider surgical and dental concerns during distraction osteogenesis treatment planning. These concerns include predistracton orthodontics, osteotomy design and location, selection of the distraction device, distraction vector orientation, duration of the latency period, the rate and rhythm of distraction, duration of the consolidation period, postdistracton orthodontics and functional loading of the regenerate bone. DO represents an exciting new development in craniofacial surgery with several potential benefits, including less invasive surgery, the ability for earlier intervention, and the potential for correction of more severe deformities with improved posttreatment stability. The exact role of distraction osteogenesis relative to conventional techniques requires ongoing assessment. Improvement of the technique and of the devices used, with an adjusted protocol, could lead to a reduction in the number of complications. In the presented chapter, advantages and disadvantages of DO techniques are discussed under the light of the current literatures.

6. References

- Abbott, J.S., (1927) Letters to the Editor. *Am J Public Health* (NY), Vol. 17, No.12, pp: 1256- 1257
- Alkan, A., Arici S. & Sato S., (2006) Bite force and occlusal contact area changes following mandibular widening using distraction osteogenesis. *Oral Surg Oral Med Oral Pathol Oral Radiol Endod*, Vol.101, pp: 432-436
- Alkan, A., Ozer M. & Bas B. Et al., (2007) Mandibular symphyseal distraction osteogenesis: review of three techniques. *Int J Oral Maxillofac Surg* Vol.36, pp: 111-117
- Allan, F.G., (1948) Bone lengthening. *J Bone Joint Surg Br*, Vol.30B, No.3,: 490-505


- Aras, A., Akay M.C. & Cukurova I., et al., (2010) Dimensional changes of the nasal cavity after transpalatal distraction using bone-borne distractor: An acoustic rhinometry and computed tomography evaluation. *J Oral Maxillofac Surg*, Vol.68, No. 7, pp: 1487-1497
- Aronson, J., (1994) Experimental and clinical experience with distraction osteogenesis. *Cleft Palate Craniofac J* Vol. 31, pp: 473-482.
- Basciftci, F.A., Korkmaz H.H. & Iseri H., et al., (2004) Biomechanical evaluation of mandibular midline distraction osteogenesis by using the finite element method. *Am J Orthod Dentofacial Orthop*, Vol.125, pp: 706-715
- Bayram, M., Ozer M. & Alkan. A., (2006) Mandibular symphyseal distraction osteogenesis using a bone-supported distractor. *Anle Orthod*, Vol. 70, No.5, pp: 20-27
- Bell, W.H., Gonzalez M. & Samchukov M.L., et al., (1999) Intraoral widening and lengthening of the mandible in baboons by distraction osteogenesis. *J Oral Maxillofac Surg*, Vol. 57, No. 5, pp: 548-562
- Blake, M. & Bibby K., (1998) Retention and stability: A review of the literature. *Am J Orthod Dentofacial Orthop* Vol.114, pp: 299-306
- Braun, S., Bottrel A. & Legan H.L., (2002) Condylar displacement related to mandibular symphyseal distraction. *Am J Orthod Dentofacial Orthop*, Vol.121, pp: 162-165
- Cano, J., Campo, J. & Moreno, L.A., et al., (2006) Osteogenic alveolar distraction: A review of the literature. *Oral Surg Oral Med Oral Pathol Oral Radiol Endod*, Vol.101, pp: 11-28
- Chin, M. & Toth B.A., (1996) Distraction osteogenesis in maxillofacial surgery using internal devices: Review in five cases. *J Oral Maxillofac Surg*, Vol.54, pp: 45-53
- Chin, M., (1999) Distraction osteogenesis for dental implants. *Atlas Oral Maxillofac Surg Clin North Am* Vol. 7, pp: 41-63
- Codvilla, A., (1905) On the means of lengthening in the lower limbs, the muscles and tissues which are shortened through deformity. *Am J Orthop Surg*, Vol.2, pp: 353-369
- Conley, R. & Legan H., (2003) Mandibular symphyseal distraction osteogenesis: diagnosis and treatment planning considerations. *Angle Orthod*, Vol. 73, pp: 3-11
- Costantino, P.D., Shybut G. & Friedman C.D., et al. , (1990) Segmental mandibular regeneration by distraction osteogenesis. *Arch Otolaryngol Head Neck Surg*, Vol.116, pp: 535-545
- Cricchio, G. & Lundgren S., (2003) Donor site morbidity in two different approaches to anterior iliac crest bone harvesting. *Clin Implant Dent Relat Res* Vol.5, No.3, pp:161-9
- Del Santo, M., English J.D. & Wolford L.M., et al., (2002) Midsymphyseal distraction osteogenesis for correcting transverse mandibular discrepancies. *Am J Orthod Dentofacial Orthop*, Vol.121, pp: 629-638
- Del Santo, M., Guerrero C.A. & Buschang P.H., et al., (2000) Long-term skeletal and dental effects of mandibular symphyseal distraction osteogenesis. *Am J Orthod Dentofacial Orthop* Vol.118, pp: 485-493
- Duran, I., Malkoc S. & Iseri H., et al., (2006) Microscopic evaluation of mandibular symphyseal distraction. *Angle Orthod* Vol.76, pp: 369-374
- El-Hakim I.E., Azim A.M. & El-Hassan M.F., et al. (2004). Preliminary investigation into the effects of electrical stimulation on mandibular distraction osteogenesis in goats. *Int J Oral Maxillofac Surg*, Vol. 33, No.1, pp: 42-47
- Froum, S., Cho S.C. & Rosenberg E. et al., (2002) Histological comparison of healing extraction sockets implanted with bioactive glass or demineralized freeze-dried bone allograft: a pilot study. *J Periodontol*, Vol.73, No.1, pp: 94-102

- Gantous, A., Phillips J.H. & Catton P., et al., (1994) Distraction osteogenesis in the irradiated canine mandible. *Plast Reconstr Surg*, Vol. 93, pp: 164-170
- Garrett, B.J., Caruso J.M. & Rungcharassaeng K, et al. (2008) Skeletal effects to the maxilla after rapid maxillary expansion assessed with cone-beam computed tomography. *Am J Orthod Dentofacial Orthop*, Vol. 134, pp: 8.e1-8.e11
- Gerlach K.L. & Zahl C., (2003) Transversal palatal expansion using a palatal distractor. *J Orofac Orthop*, Vol. 64, pp: 443-449
- Glassman, A.S., Nahigian S.J. & Medway J.M., et al., (1984) Conservative surgical orthodontic adult rapid palatal expansion: Sixteen cases. *Am J Orthod Dentofacial Orthop*, Vol.86, pp: 207-213
- Gosain, A.K., Santoro T.D. & Havlik R.J. et al., (2002) Midface distraction following Le Fort III and monobloc osteotomies: problems and solutions. *Plast Reconstr Surg*, Vol.109, No. 6, pp: 1797-1808
- Guerrero, C.A., (1990) Rapid mandibular expansion. *Rev Venez Orthod*, Vol.48, pp: 1-9
- Guererero, C.A, Bell W.H. & Contasti G.I., et al., (1997) Mandibular widening by intraoral distraction osteogenesis. *Br J Oral Maxillofac Surg*, Vol.35, pp: 383-392
- Guerrero, C.A., Bell W.H. & Contasti G.I., et al., (1999) Intraoral mandibular distraction osteogenesis. *Semin Orthod*, Vol. 5, pp: 35-40
- Gunbay, T., Akay M.C. & Gunbay S., et al., (2008) Transpalatal distraction using bone-borne distractor: clinical observations and dental and skeletal changes. *J Oral Maxillofac Surg*, Vol. 66, pp: 2503-2514
- Gunbay, T., Ozveri Koyuncu B. & Akay M.C. et al., (2008) Results and complications of alveolar distraction osteogenesis to enhance vertical bone height. *Oral Surg Oral Med Oral Pathol Oral Radiol Endod*, Vol.105, pp: e7-e13
- Gunbay, T., Akay, M.C. & Aras A., et al. (2009) Effects of transmandibular symphyseal distraction on teeth, bone, and temporomandibular joint. *J Oral Maxillofac Surg*, Vol.67, No. 10, pp: 2254-2265
- Haas, A.J., (1980) The treatment of maxillary deficiency by opening the mid-palatal suture. *Angle Orthod*, Vol. 50, pp: 189-217
- Harper, R.P., Bell W.H. & Hinton R.J., et al., (1997) Reactive changes in the temporomandibular joint after mandibular midline osteodistraction. *Br J Oral Maxillofac Surg*, Vol. 35, pp: 20-25
- Havlik, R. & Bartlett, S.P., (1994) Mandibular distraction lengthening in the severely hypoplastic mandible: A problematic case with tongue aplasia. *J Craniofac Surg*, Vol. 5, pp: 305
- Herberger, R.J., (1981) Stability of mandibular intercuspid width after long periods of retention. *Angle Orthod*, Vol. 51, pp: 78-83
- Ilizarov, G.A., (1971) Basic principles of transosseous compression and distraction osteosynthesis. *Orthop Travmatol Protez*, Vol. 32, pp: 7-15.
- Ilizarov, G.A., (1988) The principles of the Ilizarov method. *Bull Hosp Jt Dis Orthop Inst*. 48:1-12.
- Ilizarov, G.A., (1989a) The tension-stress effect on the genesis and growth of tissues. Part I. The influence of stability of fixation and soft-tissue preservation. *Clin Orthop Relat Res*, Vol. 238, pp: 249-281
- Ilizarov, G.A., (1989b) The tension-stress effect on the genesis and growth of tissues: Part II. The influence of the rate and frequency of distraction. *Clin Orthop Relat Res*, Vol. 239, pp: 263-285

- Imola, M.J., Hamlar D.D. & Thatcher G., et al., (2002) The versatility of distraction osteogenesis in craniofacial surgery. *Int J Oral Maxillofac Surg*, Vol. 34, No.4, pp: 357-363
- Imola, M.J., Ducic Y. & Adelson R.T., (2008) The secondary correction of posttraumatic craniofacial deformities. *Otolaryngol Head Neck Surg*, Vol.39, No.5, pp: 654-660
- Iseri, H. & Malkoc S., (2005) Long-term skeletal effects of mandibular symphyseal distraction osteogenesis. An implant study. *Eur J Orthod*, Vol. 27, pp : 512-517
- Jovanovic, S.A., Schenk, R.K. & Orsini M., et al., (1995) Supracrestal bone formation around dental implants: an experimental dog study. *International Journal of Oral and Maxillofacial Implants*, Vol. 10, pp: 23-31
- Karp, N.S., Thorne C.H. & McCarthy J.G., et al., (1990) Bone lengthening in the craniofacial skeleton. *Ann Plast Surg*, Vol. 24, No. 3, pp: 231-237
- Karp, N.S., McCarthy J.G. & Schreiber J.S., et al., (1992) Membranous bone lengthening: a serial histological study. *Ann Plast Surg*, Vol. 29, pp: 2-7
- Kewitt, G.F. & Van Sickels J.E., (1999) Long-term effect of mandibular midline distraction osteogenesis on the status of the temporomandibular joint, teeth, periodontal structures, and neurosensory function. *J Oral Maxillofac Surg*, Vol. 57, pp: 1419-1425
- Koudstaal, M.J., Poort L.J. & van der Wal K.G.H., et al., (2005) Surgically assisted rapid maxillary expansion (SARME): a review of the literature. *Int J Oral Maxillofac Surg*, Vol. 34, pp: 709-714
- Koudstaal, M.J., van der Wal K.G.H. & Wolvius E.B., et al., (2006) The Rotterdam Palatal Distractor: Introduction of the new bone-borne device and report of the pilot study. *Int J Oral Maxillofac Surg*, Vol.35, pp: 31-35
- Krenkel, Ch. & Grunert I., (2007) A new callus distraction technique using the Endodistractor Implant in severely atrophic mandibles – long-term results of 18 patients. Press Conference, KRENKEL Endo-Distractor, Salzburg, Austria.
- Little, R.M. & Riedel R.A. (1989) Postretention evaluation of stability and relapse-mandibular arches with generalized spacing. *Am J Orthod Dentofacial Orthop*, Vol. 95, No.1, pp: 37-41
- Luchs, J.S., Stelnicki E.J. & Rowe N.M., et al., (1992) Molding of the regenerate in mandibular distraction: Part 1: Laboratory study. *J Craniofac Surg*, Vol. 13, No. 2, pp: 205-211
- Martin, D.L., (1998) Transverse stability of multi-segmented Le Fort I expansion procedures (Master's thesis). Dallas: Baylor College of Dentistry
- Matteini, C. & Mommaerts M.Y., (2001) Posterior transpalatal distraction with pterygoid disjunction: A short-term model study. *Am J Orthod Dentofacial Orthop*, Vol. 120, No. 5, pp: 498-502
- McCarthy, J.G., Schreiber J. & Karp N, et al., (1992) Lengthening of the human mandible by gradual distraction. *Plast Reconstr Surg*, Vol.89, pp: 1-12
- McCarthy, J.G., (1996) Distraction of the mandible and craniofacial skeleton. *J Craniomaxillofac Surg*, Vol. 24, pp: 193-199
- McCarthy, J.G., Williams J.K. & Grayson B.H., (1998) Controlled multiplanar distraction of the mandible: device development and clinical application. *J Craniofac Surg*, Vol. 9, pp: 322-329
- McNamara, J.A. & Brudon, W.L., (1993) Orthodontic and Orthopedic Treatment in the Mix Dentition. Ann Arbor, Mich: Needham Press; pp: 171-178
- Michieli, S. & Miotti, B., (1977) Lengthening of mandibular body by gradual surgical-orthodontic distraction. *J Oral Surg*, Vol. 35, pp: 187

- Mommaerts, M.Y., (1999) Transpalatal distraction as a method of maxillary expansion. *Br J Oral Maxillofac Surg*, Vol. 37, No. 4, pp: 268-272
- Mommaerts, M., Ali, N. & Correia, P., (2004a) The concept of bimaxillary transverse osteodistraction: a paradigm shift? *Mund Kiefer Gesichtschir*, Vol. 8, pp: 211-216
- Mommaerts, M., Steyaert, L. & Polsbroek R., et al., (2004b) Correlation between ultrasound and radiographic data for assessment of symphyseal bony callus maturation after distraction. *Rev Stomatol Chir Maxillofac*, Vol. 105, pp: 19-22
- Mommaerts, M.Y. & Vande Vannet B. (2004) Bimaxillary transverse distraction osteogenesis. *Ned Tijdschr Tandheelkd*, Vol. 111, pp: 40-43
- Mommaerts, M., Polsbroek R. & Santler G., et al., (2005) Anterior transmandibular osteodistraction: clinical and model observations. *J Craniomaxillofac Surg*, Vol. 33, No. 5, pp: 318-325
- Mommaerts, M.Y., Spaey Y.J.E. & Soares Correia P.E.G., et al. (2008) Morbidity related to transmandibular distraction osteogenesis for patients with developmental deformities. *J Craniomaxillofac Surg*, Vol. 36, No. 4, pp: 192-197
- Mommaerts, M.Y., (2001) Bone anchored intraoral device for transmandibular distraction. *Br J Oral Maxillofac Surg*, Vol. 39, pp: 8-12
- Moss, J.P., (1968) Rapid expansion of the maxillary arch. II. Indications for rapid expansion. *J Pract Orthod*, Vol. 2, pp: 215-223
- Mussa, R. & Smith J., (2003) Mandibular symphyseal distraction osteogenesis. A case report. *J Clin Orthod*, Vol. 37, pp: 13-18
- Neyt, N., Mommaerts, M. & Abeloos J., et al., (2002) Problems, obstacles and complications in transpalatal distraction in non-congenital deformities. *J Craniomaxillofac Surg*, Vol. 30, pp: 139-143
- Nkenke, E., Radespiel-Tröger, M. & Wiltfang J., et al., (2002) Morbidity of harvesting of retromolar bone grafts: A prospective study. *Clin Oral Implants Res*, Vol.13, No.5, pp: 514-21
- Nocini, P.F., Albanese M. & Wangerin K. (2002) Distraction osteogenesis of the mandible: evaluation of callus distraction by B-scan ultrasonography. *Journal of Cranio-Maxillofacial Surgery*, Vol. 30, pp: 286-291
- Orhan, M., Malkoc, S. & Usumez S. (2003) Mandibular symphyseal distraction and its geometrical evaluation: report of a case. *Angle Orthod*, Vol. 73, pp: 194-200
- Palti, A., (2003) Primary stability of implants in the posterior maxilla with autogenous bone rings harvested in the mandible. *Dent Implantol Update*, Vol. 14, No. 9, pp: 65-71
- Pensler, J.M., Goldberg D.P. & Lindell B., et al., (1995) Skeletal distraction of the hypoplastic mandible. *Ann Plast Surg*, Vol.134, No.2, pp: 130-136
- Phatouros, A. & Goonewardene, M.S. (2008) Morphologic changes of the palate after rapid maxillary expansion: A 3-dimensional computed tomography evaluation. *Am J Orthod Dentofacial Orthop*, Vol. 134, pp: 117-124
- Podesser, B., Williams, S. & Chrismani A.G., et al., (2007) Evaluation of the effects of rapid maxillary expansion in growing children using computer tomography scanning: A pilot study. *Eur J Orthod*, Vol. 29, pp: 37-44
- Polley, J.W. & Figueroa A.A., (1998) Rigid external distraction: Its application in cleft maxillary deformities. *Plast Reconstr Surg*, Vol.102, pp: 1360-1372
- Proffit, W.R., Turvey T.A. & Phillips C., (1996) Orthognathic surgery: A hierarchy of stability. *Int J Adult Orthod Orthognath Surg*, Vol.11, pp: 191-204

- Ramieri G.A., Spada M.C. & Austa M., et al. (2005) Transverse maxillary distraction with a bone-anchored appliance: dento-periodontal effects and clinical and radiological results. *Int J Oral Maxillofac Surg*, Vol.34, pp: 357-363
- Samchukov, M.L., Cope, J.B. & Harper, R.P., et al., (1998). Biomechanical considerations of mandibular lengthening and widening by gradual distraction using a computer model. *J Oral Maxillofac Surg*, Vol. 56, No. 1, pp: 51-59
- Samchukov, M.L., Cope, J.B. Cherkashin A.M., (2001) The biomechanical effects of distraction device orientation during mandibular lengthening and widening. In: Samchukov, M.L., Cope, J.B., Cherkashin, A.M. (Eds.), *Craniofacial Distraction Osteogenesis*. Mosby, St. Louis, pp. 131-146
- Sasso, R.C., LeHuec, J.C. & Shaffrey, C., (2005) Spine Interbody Research Group. Iliac crest bone graft donor site pain after anterior lumbar interbody fusion: a prospective patient satisfaction outcome assessment. *J Spinal Disord Tech*. 18 Suppl: S77-81
- Shetye, P.R., Davidson E.H. & Sorkin, M., et al., (2010). Evaluation of three surgical techniques for advancement of the midface in growing children with syndromic craniosynostosis. *Plast Reconstr Surg*, Vol.126, No.3, pp: 982-994
- Simion, M., Trisi, P. & Piattelli, A., (1994) Vertical ridge augmentation using a membrane technique associated with osseointegrated implants. *International Journal of Periodontics and Restorative Dentistry*, Vol.14, pp: 497-511
- Snyder, C.C., Levine, G.A. & Swanson H.M., et al., (1973) Mandibular lengthening by gradual distraction. Preliminary report. *Plast Reconstr Surg*, Vol.51, No.5, pp: 506-8
- Suri, L & Taneja P., (2008) Surgically assisted rapid maxillary expansion. A literature review. *Am J Orthod Dentofacial Orthop*, Vol.133, pp: 290-302
- Tae, K.C., Kang, K.W. & Kim, S.C., et al., (2006) Mandibular symphyseal distraction osteogenesis with stepwise osteotomy in adult skeletal class III patient. *Int J Oral Maxillofac Surg*, Vol. 35, pp: 556-558
- Toth, B.A., Kim, J.W. & Chin, M., et al., (1998) Distraction osteogenesis and its application to the midface and bony orbit in craniosynostosis syndromes. *J Craniofac Surg*, Vol.9, No.2, pp: 100-113
- Uckan, S., Haydar, S.G. & Dolanmaz, D., (2002) Alveolar distraction: analysis of 10 cases. *Oral Surg Oral Med Oral Pathol Oral Radiol Endod*, Vol. 94, pp: 561-565
- Uckan, S., Guler, N. & Arman, A., et al., (2005). Mandibular midline distraction using a simple device. *Oral Surg Oral Med Oral Pathol Oral Radiol Endod*, Vol.100, pp: 85-91
- Uckan, S., Guler, N. & Arman, A., et al., (2006) Mandibular midline distraction using a simple device. *Oral Surg Oral Med Oral Pathol Oral Radiol Endod*, Vol.101, pp:711-717
- Vanarsdall, R.L., (1999) Transverse dimension and long-term stability. *Semin Orthod*, Vol.5, No.3, pp: 171-80
- Vance, G.S., Greenwell, H. & Miller R.L., et al., (2004) Comparison of an allograft in an experimental putty carrier and a bovine-derived xenograft used in ridge preservation: a clinical and histologic study in humans. *Int J Oral Maxillofac Implants*, Vol. 19, No. 4, pp: 491-497
- Vyas, R.M. & Jarrahy, R., (2009) Bone-borne palatal distraction to correct the constricted cleft maxilla. *J Craniofac Surg*, Vol. 20, pp: 733-736
- Weil, T.S., Van Sickels, J.E. & Payne, C.J., (1997) Distraction osteogenesis for correction of transverse mandibular deficiency: A preliminary report. *J Oral Maxillofac Surg*, Vol.55, pp: 953-960



CT Scanning - Techniques and Applications

Edited by Dr. Karupppasamy Subburaj

ISBN 978-953-307-943-1

Hard cover, 348 pages

Publisher InTech

Published online 30, September, 2011

Published in print edition September, 2011

Since its introduction in 1972, X-ray computed tomography (CT) has evolved into an essential diagnostic imaging tool for a continually increasing variety of clinical applications. The goal of this book was not simply to summarize currently available CT imaging techniques but also to provide clinical perspectives, advances in hybrid technologies, new applications other than medicine and an outlook on future developments. Major experts in this growing field contributed to this book, which is geared to radiologists, orthopedic surgeons, engineers, and clinical and basic researchers. We believe that CT scanning is an effective and essential tools in treatment planning, basic understanding of physiology, and and tackling the ever-increasing challenge of diagnosis in our society.

How to reference

In order to correctly reference this scholarly work, feel free to copy and paste the following:

Mehmet Cemal Akay (2011). Distraction Osteogenesis of the Maxillofacial Skeleton: Clinical and Radiological Evaluation, CT Scanning - Techniques and Applications, Dr. Karupppasamy Subburaj (Ed.), ISBN: 978-953-307-943-1, InTech, Available from: <http://www.intechopen.com/books/ct-scanning-techniques-and-applications/distraction-osteogenesis-of-the-maxillofacial-skeleton-clinical-and-radiological-evaluation>

INTECH
open science | open minds

InTech Europe

University Campus STeP Ri
Slavka Krautzeka 83/A
51000 Rijeka, Croatia
Phone: +385 (51) 770 447
Fax: +385 (51) 686 166
www.intechopen.com

InTech China

Unit 405, Office Block, Hotel Equatorial Shanghai
No.65, Yan An Road (West), Shanghai, 200040, China
中国上海市延安西路65号上海国际贵都大饭店办公楼405单元
Phone: +86-21-62489820
Fax: +86-21-62489821

© 2011 The Author(s). Licensee IntechOpen. This chapter is distributed under the terms of the [Creative Commons Attribution-NonCommercial-ShareAlike-3.0 License](https://creativecommons.org/licenses/by-nc-sa/3.0/), which permits use, distribution and reproduction for non-commercial purposes, provided the original is properly cited and derivative works building on this content are distributed under the same license.

IntechOpen

IntechOpen