

# We are IntechOpen, the world's leading publisher of Open Access books Built by scientists, for scientists

6,900

Open access books available

185,000

International authors and editors

200M

Downloads

Our authors are among the

154

Countries delivered to

TOP 1%

most cited scientists

12.2%

Contributors from top 500 universities



WEB OF SCIENCE™

Selection of our books indexed in the Book Citation Index  
in Web of Science™ Core Collection (BKCI)

Interested in publishing with us?  
Contact [book.department@intechopen.com](mailto:book.department@intechopen.com)

Numbers displayed above are based on latest data collected.  
For more information visit [www.intechopen.com](http://www.intechopen.com)



# Brain Tumor and Seizures: Incidence, Pathophysiology, Diagnosis and Treatment

Elysia James and Panayiotis N. Varelas  
*Henry Ford Hospital, Detroit  
 United States*

## 1. Introduction

Seizures can arise as a complication of a number of disease states such as metabolic abnormalities, intoxication or withdrawal from drugs, acute trauma, infection; the list is exhaustive (Delanty, Vaughan et al. 1998). One of the most common causes of seizures is indeed the presence of a brain tumor. Seizures present a preventative, diagnostic and management challenge for a number of reasons in this situation. The drugs used for treatment may interfere with chemotherapy, may produce untoward cognitive or medical side effects, and may not even reach the intended target since the blood brain barrier may be pathologic in the abnormal environment of the tumor. The many genetic and pathological variations in tumor type may further impact therapies aimed at treating seizures in this setting. Further complicating this scenario is the post-operative management of these patients, which may occur in an ICU most complex environment. This chapter will review contemporary issues in pathophysiology, clinical presentation, complications, treatment, and outcomes of seizures associated with brain tumors.

## 2. Incidence

Overall, the incidence of brain tumors is 4% in patients with epilepsy (van Breemen, Wilms et al. 2007). On the other hand, seizures complicate the natural history in 30-70% of patients with a primary tumor. (LeBlanc 1974; McKeran 1980; Cascino 1990; Bartolomei 1997). About 40% of all the patients with metastatic brain tumors will have a seizure during their disease (Simonescu 1960; Cohen 1988). Half of these seizures will be simple or partial complex seizures and the other half secondary generalized seizures (Ketz 1974; Moots 1995). Some tumors, like DNETs and gangliogliomas, with significantly higher seizure frequencies, have been associated with intrinsic epileptogenic properties. Among the primary brain tumors, the higher incidence of seizures is found in patients with oligodendroglioma (92%) and dysembryoplastic neuroectodermal tumors (DNET, 100%) (van Breemen, Wilms et al. 2007). Melanoma, choriocarcinoma, lung cancer and breast cancer are tumors frequently metastasizing to the brain and associated with hemorrhage and seizures. Among metastatic tumors, melanoma seems to have the highest incidence of seizures. Conversely, based on a study from the Cleveland Clinic, among patients with intractable chronic epilepsy the most common types of tumors discovered are ganglioglioma [in 49/127 (39%) of cases] and low grade astrocytoma [in 48/127 (38%) of cases] (Morris 1996). Pleomorphic

xanthoastrocytoma, dysembryoplastic neuroectodermal tumors, and oligodendroglioma are also tumors frequently associated with chronic epilepsy. Overall, it seems likely that low grade, well-differentiated gliomas have higher incidence of seizures than more aggressive glioblastomas or anaplastic astrocytomas (Beaumont 2000; van Breemen, Wilms et al. 2007). The location of the brain tumor also plays a role in the incidence of seizures, because different brain areas are characterized by varying susceptibility to seizures. For example, among patients with gliomas, seizures occur in 59% of frontal tumors, 42% of parietal tumors, 35% of temporal tumors and 33% of occipital tumors (Scott 1980). Similar observations suggest that the limbic and temporal lobe, primary and supplementary motor (M-I, M-II) areas, primary and secondary somatosensory (S-I, S-II opercula and insula) areas have the lowest thresholds for seizures (Beaumont 2000). In contrast to the other lobes, the occipital lobe has a much higher threshold and lower incidence of seizures (Mahaley 1981). Tumors in the subcortical areas, such as thalamus and posterior fossa, are much less epileptogenic as well.

### 3. Pathophysiology of seizures in the context of a brain tumor

Although the pathogenic mechanism of epileptogenesis in patients with brain tumors has not been fully elucidated (Beaumont 2000), it can be traced to the cellular workings and intercellular connections within the nervous system. A better understanding of these processes may provide new therapeutic targets not just for tumors, but for improved seizure control. There are many theories behind the cause of seizures in patients with brain tumors. To complicate the matter, different types of tumors may cause seizures through different mechanisms. In the late 1950's Echlin proposed that brain tumors cause partial isolation and deafferentation of the cerebral cortex, resulting in denervation hypersensitivity (Echlin 1959). More recent studies have focused on molecular pathobiology and pathophysiology that underlie these lesions and differentiate them from normal tissue. There are differences in the ion channel profile between normal glial cell types (Patt 1996). Patt et.al used these differences in their study in order to further categorize the properties of oligiodendrogliomas and mixed oligiodendrogliomas in eight patients. Using patch clamp techniques, he postulated that oligiodendrogliomas are dominated by action potential generating cells (Patt 1996). Sodium channels in tumor cells may play a role in epileptogenesis, since these channels are responsible for generating action potentials more frequently than others (Patt 1996; Labrakakis 1997). Normal glial cells have a limited number of sodium channels. It is not difficult to imagine that a tumor with a mixed cellular profile would produce enough sodium channels to allow excitatory circuitry to become the dominant player (Beaumont 2000). There are differences in the pathophysiology between temporal epilepsy and epilepsy in the temporal lobe secondary to seizure kindling (Beaumont 2000). Changes in the extracellular environment, changes in the regulation of inhibitory and excitatory amino acids, responses to amino acids, alterations in glial gap junctions have all been implicated in epileptogenesis (Beaumont 2000). Tumors that tend to cause hemorrhage, necrosis, inflammation and ischemia have a higher incidence of seizures. Focal hypoxia, mass effect and edema, altered levels of excitatory amino acids, all have been postulated to play a role in epileptogenesis. Derangements in the blood-brain barrier (BBB) and its constituents may be another factor that impacts the development and treatment of seizures in brain tumors. Although Marchi et. al in their study using acute disruption of the blood brain barrier (Marchi, Angelov et al. 2007) did not find that the presence of tumor

determined the onset of the seizure in their cohort, BBB disruption may be another contribution to an already unstable and pathologic state. The multidrug-resistance gene MDR1 (ABCB1, P-glycoprotein) and multidrug-resistance-related protein (MRP, ABCC1) are expressed in the cells forming many blood-brain and blood-CSF barriers. These genes and proteins contribute to decreased entry of multiple AEDs to the brain parenchyma such as phenytoin, carbamazepine, phenobarbital, lamotrigine and felbamate. These proteins are over-expressed in the cells of patients with glioma (Calatozzolo, Gelati et al. 2005), focal cortical dysplasia and ganglioglioma (Aronica, Gorter et al. 2003). The genetic characteristics of the tumor play a substantial role in their treatment, thereby impacting the treatment of seizures too. Loci 1p and 19q have been implicated in the prognosis of oligiodendrogliomas in a number of studies. (Hata, Shono et al. 2007; Ramirez, Bowman et al. 2010). Despite the advances in research in these key areas of molecular biology, genetics and ion channel function, estimating the individual's susceptibility to the above alterations is still an elusive target.

In addition to primary brain neoplasms, systemic cancer can metastasize to the brain and produce seizures as their first manifestation. The intracranial metastases usually originate from embolization of neoplastic cells to the brain, commonly in terminal arterial supply territories, such as the gray white matter junction. Systemic cancer may induce seizures through additional non-invasive mechanisms: coagulopathy and stroke (sinus thrombosis), non-bacterial thrombotic endocarditis with cerebral emboli, systemic metabolic derangements, such as hypomagnesemia (van de Loosdrecht, Gietema et al. 2000) or hyponatremia (McDonald and Dubose 1993), opportunistic infections after chemotherapy or direct toxicity of chemotherapeutic agents to the brain (Meropol, Creaven et al. 1995; Delanty, Vaughan et al. 1998). Paraneoplastic syndromes, such as limbic encephalopathy with anti Hu antibodies can be associated with seizures preceding the diagnosis of cancer (Dalmau, Graus et al. 1992). EEG or continuous video-EEG may be necessary to evaluate these patients and reach the correct diagnosis (Figure 1).

#### 4. Clinical presentation

Seizures are one of the most common presentations in patients with brain tumors. A first, unprovoked seizure in an adult is always suggestive of an intracranial tumor, until proven otherwise (Ropper 2009). As a sign, seizures may accompany other vague, non-localizing symptoms such as apathy, irritability, altered mental status, dizziness (Ropper 2009), as well as signs of increased intracranial pressure, such as diplopia, nausea, headache and decreased visual acuity.

Several seizure types have been reported and mainly reflect the location of the lesion. Parasagittal meningiomas may present with generalized seizures when located in the anterior one third of the sagittal sinus, whereas meningiomas of the middle third usually present with focal seizures, at times following a Jacksonian marching pattern. Simple or partial seizures characterized by olfactory, gustatory and epigastric auras, depersonalization, feelings of fear or pleasure, are usually an indication of temporal lobe pathology. Complex partial seizures with repetitive psychomotor movements, impairment of consciousness or déjà-vu phenomena are also associated with the temporal lobe. Delusions and psychotic behaviour have been reported with frontal lobe tumors (Sato, Takeichi et al. 1993). Lesions involving the frontal eye fields are associated with turning of the eyes and head to one side (contraversive or ipsiversive, depending on the side of turning

compared to the lesion and the timing of the observation, ie ictal vs interictal). Parietal lobe tumors are associated with sensory seizures and occipital lobe tumors can cause seizures with lights, colors, and geometric patterns (Ropper 2009). Even non-neoplastic mass lesions may have seizures as a part of their clinical presentation. The classic example is gelastic seizures in hypothalamic hamartomas (Addas, Sherman et al. 2008; Striano, Striano et al. 2009).

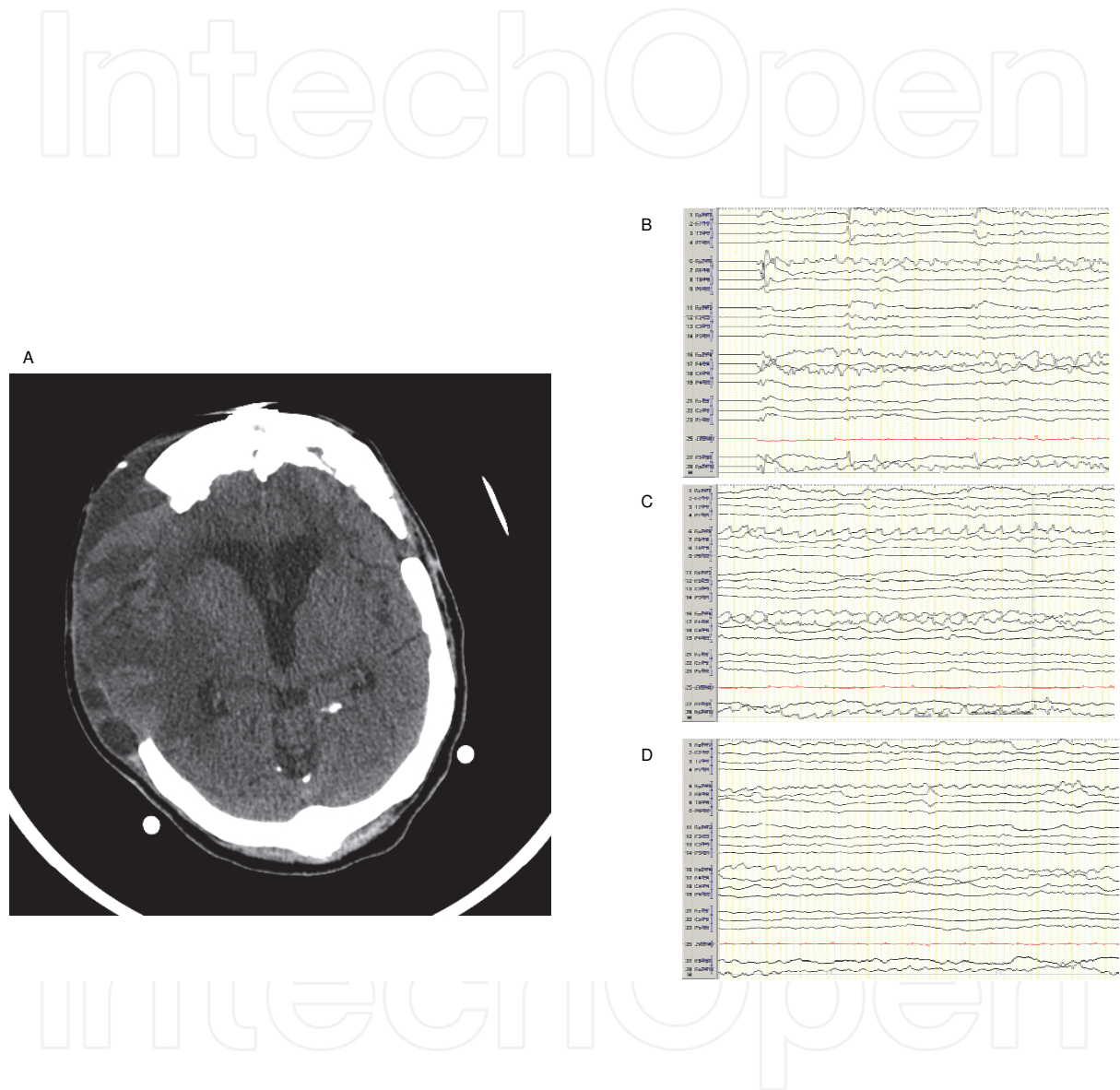


Fig. 1. 57 year old woman, history of multiple resections of reccuren right frontal meningioma, with altered mental status, in non-convulsive status epilepticus. The seizures were treated successfully with multiple anti-epileptic medications including a midazolam drip. (a) CT brain without contrast, evidence of encephalomalacia in the resection cavity with increased edema. (b) start of ictal activity in the frontal derivations (F2, F4, F8) consistent with the region of the prior meningioma resection (c) evolution of the ictal activity into non-convulsive status epilepticus (d) end of ictal activity.



#### 4.1 Status epilepticus

Status epilepticus (SE) can also occur in patients with brain tumors, either convulsive or non-convulsive. In a recent study from the University of Virginia, 555 patients were admitted with a diagnosis of SE over a 7-year period. Fifty patients had a concurrent diagnosis of cancer, 28 (5%) of whom had SE related to the tumor or its treatment (Cavaliere, Farace et al. 2006). SE occurs either at the time of tumor diagnosis (29%) or during tumor progression (23%). However, an almost equal percentage of SE occurred while the tumor was stable (23%) in a recent study (Cavaliere, Farace et al. 2006). Because some tumors present with non-convulsive seizures or non-convulsive status epilepticus (NCSE), a clinical presentation of decreased or altered mental status, should not be primarily attributed to the tumor. An evaluation with EEG should be undertaken to exclude NCSE, that may be amenable to treatment. Drislane reported 6 patients with systemic cancer, whose EEGs showed NCSE. Three patients were confused, and the other three were stuporous or comatose. The possibility of paraneoplastic encephalopathy was raised in 3 of them. Antiepileptic treatment led to an improved mental status in four of these patients (Drislane 1994). Five patients out of 84 (6%) with cancer and altered mental status (coma or delirium) were found to be on NCSE by EEG in another study from Italy. None of these patients had brain metastases: one was aphasic, 2 patients treated with ifosfamide had absence and 2 patients treated with cisplatin complex partial status epilepticus. All had rapid recovery after antiepileptic treatment (Cocito, Audenino et al. 2001). In a recent study, four patients never diagnosed before with metastatic CNS disease presented with altered mental status. All patients had abnormal neuroimaging of the brain, were in NCSE by EEG and were treated with fosphenytoin IV. In 2 patients the NCSE resolved, but in the other two, despite an initial mental status improvement, status recurred and both eventually died after 5 and 20 days, respectively (Blitshteyn and Jaeckle 2006).

### 5. Diagnosis

In most cases, seizures can be easily diagnosed, if they present as convulsions. However, other paroxysmal or repetitive movements can occur in patients with intracranial pathology, such as extrapyramidal tremor, clonus, blepharospasm, fasciculations, shivering or posturing and occasionally this may lead to confusion, especially if a physician or nurse is not present during their occurrence. On the other hand, many epileptic phenomena are non-convulsive and can present with a pleiade of symptoms and signs, including confusion, blank staring, fugue, subtle (and frequently unnoticeable) twitching of the face or eyelids or nystagmus. The routine electroencephalogram may not catch any of these events or may be compromised by movement artifacts. In this case of uncertainty, we recommend a continuous video-EEG monitoring lasting for few hours to a day. If the events are recorded and are not epileptic in nature, then the test should be discontinued, otherwise should be extended until a conclusion is reached.

Neuroimaging is also paramount, especially in cases of refractory seizures, to exclude additional pathology than the tumor per se (new bleed, infarction, sinus thrombosis or infection, which can occur in patients undergoing chemotherapy or radiation). A magnetic resonance imaging is considered a better test than computed tomography, since it can reveal smaller anatomical details and differentiate faster between a new stroke vs paralysis due to

Todd's phenomenon. If the patient is actively having seizures or SE, the diffusion-weighted imaging sequence can reveal restricted diffusion in the cortical mantle, where the seizures emanate from. Lastly, a lumbar puncture, performed if there are no signs of hydrocephalus or midline shift, can also infrequently contribute to the diagnosis, by revealing leptomeningeal extension of the tumor, measuring the opening pressure or identifying an infectious agent.

## 6. Treatment - Issues in management

### 6.1 Use of anti-epileptic medications

There are several important details regarding the management of these complex patients. One main theme is the understanding that surgical management supersedes medical management. Studies have shown that resection of the epileptogenic zone due to brain tumors may lead to seizure freedom or significant control of seizures in 70-90% of patients (Britton, Cascino et al. 1994; Zentner, Hufnagel et al. 1997).

Medication interactions are a very important problem and can lead to difficulties in compliance, tolerance and side effects. Most patients are on a regimen of antiepileptic drugs (AEDs), radiation therapy and chemotherapy. Antiepileptics, especially those affecting the cytochrome P450 system, may affect the metabolism of chemotherapeutic agents. These agents have a narrow therapeutic window and real potential for toxicity or lethal side effects. Usually, the addition of phenytoin, carbamazepine, phenobarbital and other inducers, reduces the levels or efficacy of cyclophosphamide, methotrexate, adriamycin, nitrosoureas, paclitaxel, etoposide, topotecan, irinotecan, thiotepa and corticosteroids (Glantz, Cole et al. 2000; Patsalos, Froscher et al. 2002). Valproic acid, being an inhibitor, can have the opposite effect and increase the chemotherapeutic agents' levels. In addition, competition for binding to plasma proteins may be important with several of those medications. Choosing an appropriate anti-epileptic for patients with brain tumors involves more than adequate control of seizures. The appropriate use of certain AEDs can alleviate other symptoms of brain neoplasm, including pain, depression, anxiety, and weight gain. Because of their intrinsic mechanism of action, AED may be uniquely qualified to address these additional symptoms. There are multiple studies in both the Psychiatric and Neuroncology literature to support the use of AEDs for symptoms related to depression, anxiety, and pain (Thompson, Takeshita et al. 2006).

An interesting aspect of the antiepileptic drug use in patients with cancer is their potential for antineoplastic or immunosuppressive effect (Bardana, Gabourel et al. 1983; Kikuchi, McCormick et al. 1984; Blaheta and Cinatl 2002). Valproate exhibits inherent antitumor activity through inhibition of histone deacetylase. In the treatment of medulloblastoma in children, Li et. al concluded that valproic acid possesses potent in vitro and in vivo antimedulloblastoma activities correlating with induction of histone hyperacetylation and regulation of pathways critical for maintaining growth inhibition and cell cycle arrest (Li, Shu et al. 2005). Pregabalin, a newer agent was found in a small study to be effective as monotherapy, encouraging the study authors to do a larger prospective study (Novy, Stupp et al. 2009). Gabapentin in another small study was postulated to interact with a leucine binding site to reduce seizures in a group of 14 patients (Perry and Sawka 1996). Anti-epileptic medications, and their many applications, are a unique area of further research in the world of brain tumors. This is an area where individualized treatment is of paramount importance. One should take into account the histopathology of the tumor, the location of

the mass, the presence of pre-existing epilepsy, the extent of additional injury incurred by craniotomy, the involvement of other important organs metabolizing the drugs, the nutritional state of the patient, the pharmacological interactions between the agents and the ability of the patient to tolerate side effects of the treatment.

## 6.2 Side effects of antiepileptic medications

The adverse interactions between AEDs and chemotherapy are often related to enzyme induction by the former (Pursche, Schleyer et al. 2008). Major offenders include carbamazepine, phenytoin, phenobarbital, primidone, and valproic acid (Ruggiero, Rizzo et al. 2010). Interaction between antiepileptics and irradiation treatment offered to the brain or spine may lead to dermatologic complications. Skin rash in patients treated with phenytoin and brain irradiation may herald Stevens-Johnson syndrome (Cockey, Amann et al. 1996; Eralp, Aydiner et al. 2001). One retrospective study, however, of 289 patients with brain tumors treated with antiepileptics and radiation found only one (0.3%) patient who developed erythema multiforme. Phenytoin was associated with milder rashes in 22% of patients, a higher incidence than the usual 5-10%. These rashes did not appear to have a temporal relation to radiation, because they usually occurred before its initiation (Mamon, Wen et al. 1999). Valproic acid has been implicated in Rowell's syndrome - lupus erythematosus associated with erythema multiforme-like lesions (Esteve, Favre et al. 2002).

## 6.3 Prophylactic treatment with antiepileptic medications

The issue of prophylactic treatment of patients with brain tumors is very complex. If a seizure has already occurred, there is little doubt for the value of antiepileptics (Glantz, Cole et al. 2000), but when the patient has never exhibited epileptic phenomena, such a treatment becomes more controversial. Efficacy of the treatment has to be balanced with adverse events associated with the chosen drugs. Despite the best efforts, a significant percentage of patients still have breakthrough seizures and the response to the treatment is very unpredictable. Several reasons have to be considered: (1) inability of the AED to address or correct the vast range of physiologic derangements induced by brain tumors, (2) difficulty maintaining appropriate antiepileptic levels and (Lee, Wen et al.) tumor progression or recurrence (Beaumont 2000; Schaller and Ruegg 2003). Therefore, it is not surprising that there is conflicting literature regarding the use of anticonvulsants in this clinical setting. The design of the study (prospective or retrospective, randomized and blinded or not), the uniformity of the tumors studied (AEDs against a certain type of tumor or against tumors of various pathologies and locations), the drugs used (older or newer AEDs), the comparison arm (placebo vs another AED), the dose utilized (with or without a loading dose, based on ideal or unadjusted patient weight), the timing of the administration (pre-, intra- or postoperatively), the adjustment of the dose based on AED levels (total or free, depending on levels of albumin and their binding to it), the concurrent administration of other medications that can affect the AED levels (such as chemotherapy or steroids), all these are factors that play a role in the results and conclusions and contribute to the confusion. Early studies were in agreement that prophylaxis against seizure was very important. In the 80's, Kvam et al. from Columbia Presbyterian Hospital in New York, reported only 5 patients having preoperative seizures out of 538 who underwent craniotomy. The authors suggested a preoperative loading dose of 10mg/kg of phenytoin, followed by a postoperative dose of 5mg/kg/day (Kvam 1983). In a double-blind, randomized study of phenytoin (100 mg tid)



vs placebo in 281 post-craniotomy patients, the phenytoin group had significantly less seizures (12.9% vs 18.4%) and highest protection was present between days 7 and 72. Routine prophylaxis with phenytoin (in a dosage of 5 to 6 mg/kg/day) was recommended by the authors in high-risk patients post craniotomy. They also recommended that treatment should be started 1 week preoperatively and therapeutic levels of phenytoin should be maintained (North, Penhall et al. 1983). In another study, 374 patients post-craniotomy were randomized to receive phenytoin (15 mg/kg IV during surgery, followed by 3-6 mg/kg/day for 3 days) or placebo (Lee 1989). The group receiving phenytoin had two early postoperative seizures and the placebo nine, but the difference was not statistically significant. Eighty percent of the seizures occurred within twenty minutes after surgery. Thus, the authors recommended that prophylactic anticonvulsant medication be given at least 20 minutes before completion of wound closure. In a subsequent Italian study, 65/128 (51%) patients with supratentorial brain tumors had preoperative seizures and were treated with antiepileptic drugs. Those without preoperative seizures, were randomized to receive phenobarbital or phenytoin as prophylactic treatment or no treatment. No significant difference in seizure incidence was found between patients treated (7%) and those not treated (18%). The authors suggested short-term preventive antiepileptic treatment after surgery in patients without preoperative seizures and continuation of postoperative treatment in patients with preoperative epilepsy (Franceschetti, Binelli et al. 1990). This view was not shared by the authors of a subsequent large study, who did not recommend prophylactic antiepileptics after supratentorial craniotomy. In this study, 276 post-craniotomy patients were randomized to receive carbamazepine or phenytoin for six or 24 months, or no treatment (Foy, Chadwick et al. 1992). The three treatment groups did not overall differ in the risk of seizures, but there was a non-significant 10% reduction of seizures in the two groups which received antiepileptic medications. Meningiomas had the highest risk for seizures (75% by 4 years) and pituitary tumors the lowest (21% by 4 years). Longer operations, those associated with dissection of the lesion away from the surface of the brain and left-sided or bilateral lesions also carried a higher risk. Early seizures (within one week) after craniotomy did not increase the likelihood of late epilepsy. Based on these data, prophylactic anticonvulsants could not be recommended by the authors routinely following supratentorial craniotomy. Additional conflicting data comes from the results of a prospective, stratified, randomised, double-blind Dutch study, comparing 300 mg phenytoin/day to 1500 mg valproate/day given for 1 year in one hundred post craniotomy patients. Fourteen patients had postoperative seizures, but there was no difference in seizure incidence between the two groups (Beenen, Lindeboom et al. 1999). Finally, a meta-analysis of six controlled studies addressing the issue showed a tendency of prophylactic antiepileptics to prevent postoperative convulsions in patients without pre-existing seizures, but this effect did not reach statistical significance. (Kuijlen, Teernstra et al. 1996).

There are also studies looking at anti-epileptics other than phenytoin. Glantz et al. conducted a well designed randomized, double-blind, placebo-controlled study comparing the incidence of first seizures in 74 valproate and placebo-treated patients with newly diagnosed supratentorial brain tumors. The drug and placebo groups did not differ significantly in the incidence of seizures [35% in the valproate and 24% in the placebo treated group (odds ratio 1.7, 95% CI 0.6-4.6,  $p = 0.3$ )]. Based on these results no prophylactic treatment with valproate could be recommended (Glantz, Cole et al. 1996). In a large retrospective analysis of 195 patients with metastatic brain tumors, Cohen et al. reported that 18% of patients presented with seizures. Of the remaining seizure-free

patients, 40% were treated prophylactically with antiepileptics (phenytoin in > 90%). In a follow-up period of up to 59 weeks, 10% of patients developed late seizures. The incidence of seizures did not differ between treated (13.1%) and untreated (11.1%) groups. However, this study is flawed by the fact that two third of patients with seizures had sub-therapeutic antiepileptic levels. The authors did not advocate antiepileptic use, unless the patient has the first seizure (Cohen 1988). More recently, a meta-analysis evaluated 5 trials with the following inclusion criteria: (1) patients with a neoplasm, (2) either primary glial tumors, cerebral metastases or meningiomas, (3) no history of epilepsy. These patients were randomized to either an antiepileptic drug or placebo. The three antiepileptics studied were phenobarbital, phenytoin, and valproic acid. This meta-analysis confirmed the lack of antiepileptic benefit at one week and at six months of follow-up. In addition, the antiepileptics had no effect on seizure prevention for specific tumor pathology (Sirven, 2004 #83). Moreover, there is growing evidence supporting increased frequency and severity of side effects from antiepileptics in this population: in a meta-analysis of studies examining prophylactic treatment in patients with newly diagnosed brain tumors, 23.8% (range 5-38%) of treated patients experienced side-effects that were severe enough to lead to change or discontinuation of the medications. This incidence is higher than that in the general population and should make physicians skeptical regarding use in this setting (Glantz, Cole et al. 2000).

Other important factors frequently playing a role are personal preference, previous training or experience in the decision to prescribe anti-epileptic medications. According to a study conducted in Rhode Island, 55% of participating physicians gave antiepileptic prophylaxis, but the percentage differed according to the subspecialty: 33% of radiation oncologists, 50% of oncologists, 53% of neurologists and 81% of neurosurgeons (Glantz, Cole et al. 1996; Glantz, Cole et al. 2000). One of the most authoritative reports on this subject is the Quality Standards Subcommittee of the American Academy of Neurology, who published a meta-analysis of 12 studies, which had addressed the issue of prophylactic antiepileptic treatment for newly diagnosed brain tumor patients. Four were randomized and 8 were cohorts. Only one study showed significant difference between treated and untreated groups and, actually, favored the untreated. The overall odds ratio from the randomized trials was 1.09, 95% CI 0.63–1.89 ( $P = 0.8$ ) for seizure incidence and 1.03, 0.74-1.44 ( $P = 0.9$ ) for seizure-free survival. Therefore, the Subcommittee recommended no prophylactic use of antiepileptics on patients with newly diagnosed brain tumors. Although not excluding the possibility that some subgroups of brain tumor patients may be at a higher risk for seizures (melanoma, hemorrhagic or multiple metastatic lesions, tumors located near the Rolandic fissure, slow-growing primary CNS tumors), the Subcommittee did not find any reason for prophylaxis in those patients (Glantz, Cole et al. 2000). In the contemporary literature, there are still no concrete answers. A recent review (Kargiotis, Markoula et al. 2011) recommend that short-term anticonvulsant prophylaxis after surgical excision since they found that up to 13% of the patients may experience seizures within the first postoperative week, irrespective of the presence of preoperative seizure history or not. Alternatively guidelines from the American Association of Neurological Surgeons (AANS) and the Congress of Neurological Surgeons (CNS) do not recommend the prophylactic use of antiepileptic drugs to prevent seizures in brain metastases (Mikkelsen, Paleologos et al. 2010).

## 7. Post-operative complications

Seizures may present at two distinct periods of time in the course of the disease. They can present as one of the initial symptoms or later in the course of the disease during chemotherapy or after surgical intervention (Kargiotis, Markoula et al. 2011). What is the current risk of postoperative seizures in patients with neoplasm? There are no current prospective trials looking at this issue. In the aforementioned study by Kvam et al., 538 patients underwent elective craniotomy. Only 23 of these patients had a post operative seizure. They concluded that in this case-series, the most common risk factor for post-operative seizure was inadequate anticonvulsant prophylaxis. Patients in this series were also noted to have serum sodium level less than 130, which may have played a role in reducing the seizure threshold and is not uncommon in postoperative neurosurgical patients (Kvam 1983). In a case series by Fukamachi, risk factors for post-operative seizures included pre-operative seizures, sites of the lesion, and subtherapeutic anti-convulsants (Fukamachi 1985). In more contemporary studies post-operative seizures are reported in complications for new techniques (Kassam, Engh et al. 2009), and seizure rates retrospectively in specific tumor types (Lwu, Hamilton et al. 2010). Surgical approaches can also determine the risk of post-operative seizures. In a study conducted in Mayo clinic, Milligan et. al, retrospectively analyzed 197 patients comparing transcallosal approach to a transcortical approach for resection of an intraventricular lesion. They found that patients undergoing the transcallosal approach had a 4.4 fold increase in the risk of seizure (Milligan and Meyer 2010).

Seizures may also compromise the airway, cause limb injuries or structural brain injury, possibly predisposing the patient to more seizures or even status epilepticus (Deutschman 1985). Seizures can also cause cerebral acidosis, cerebral edema and further elevations of the intracranial pressure (which may already be elevated), all of them challenging the compensatory mechanisms of the brain (Lee 1989). Metabolic disturbances, such as hyponatremia or hypernatremia, hypoxia, pain-induced hyperventilation and hyperglycemia that are frequently noted postoperatively may also contribute to increased seizure frequency and should be treated aggressively.

## 8. Outcomes

Against easy assumptions, there is data supporting a better outcome in patients with brain tumors and seizures (Beaumont 2000). Despite complicating the course of the disease process in a brain neoplasm, seizures are actually among the factors that may improve patient outcome (Chandana, Movva et al. 2008), although this view may not be shared by all experts. In a retrospective analysis of 560 patients with primary supratentorial tumors, the median survival of the 164 (29%) patients presenting with epilepsy was 37 months compared to 6 months of those presenting with other symptoms ( $P < 0.0001$ ) (Smith, Hutton et al. 1991). In the study by Whittle and Beaumont of 34 supratentorial oligodendrogliomas, 17% of patients who presented with seizures and 67% of those who presented with other symptoms had died in the follow-up. However, in a multivariate model, young age and not epilepsy was a favorable independent predictor (Whittle 1995). In a recent study of 35 patients with SE, 8 (23%) died within 30 days after the status. More patients with systemic cancer (50%) than with primary brain tumors (14%) died within 30 days, implying that the tumor histology is a more important factor for mortality than SE (Cavaliere, Farace et al. 2006).

## 9. Conclusions

Anti-epileptic medications, and their many applications, are a unique area of further research in the world of brain tumors. This is an area where individualized treatment is of paramount importance. One should take into account the histopathology of the tumor, the location of the mass, the presence of pre-existing epilepsy, the extent of additional injury incurred by craniotomy, the involvement of other important organs metabolizing the drugs, the nutritional state of the patient, the pharmacological interactions between the agents and the ability of the patient to tolerate side effects of the treatment. Future areas of research include pain control, synergistic interplay between anti-epileptics and chemotherapeutic agents, and mood stabilization.

## 10. Abbreviations

DNET - dysembryoplastic neuroepithelial/neuroectodermal Tumor

MDR - multi-drug resistant

AED - anti-epileptic drug

EEG - Electroencephalogram

SE - status epilepticus

NCSE - non-convulsive status epilepticus

CNS - central nervous system

## 11. References

- Addas, B., E. M. Sherman, et al. (2008). Surgical management of hypothalamic hamartomas in patients with gelastic epilepsy. *Neurosurg Focus* 25(3): E8.
- Aronica, E., J. A. Gorter, et al. (2003). Expression and cellular distribution of multidrug transporter proteins in two major causes of medically intractable epilepsy: focal cortical dysplasia and glioneuronal tumors. *Neuroscience* 118(2): 417-429.
- Bardana, E. J., Jr., J. D. Gabourel, et al. (1983). Effects of phenytoin on man's immunity. Evaluation of changes in serum immunoglobulins, complement, and antinuclear antibody. *Am J Med* 74(2): 289-296.
- Bartolomei, J., Christopher, S, Vives, K, Spencer, DD, Piepmeier, JM (1997). Low grade gliomas of chronic epilepsy: a distinct clinical and pathological entity. *J Neurooncol* 34: 79-84.
- Beaumont, A., Whittle,IR (2000). The pathogenesis of tumor associated epilepsy. *Acta Neurochir* 142: 1-15.
- Beenen, L. F., J. Lindeboom, et al. (1999). Comparative double blind clinical trial of phenytoin and sodium valproate as anticonvulsant prophylaxis after craniotomy: efficacy, tolerability, and cognitive effects. *J Neurol Neurosurg Psychiatry* 67(4): 474-480.
- Blaheta, R. A. and J. Cinatl, Jr. (2002). Anti-tumor mechanisms of valproate: a novel role for an old drug. *Med Res Rev* 22(5): 492-511.
- Blitshteyn, S. and K. A. Jaeckle (2006). Nonconvulsive status epilepticus in metastatic CNS disease. *Neurology* 66(8): 1261-1263.
- Britton, J. W., G. D. Cascino, et al. (1994). Low-grade glial neoplasms and intractable partial epilepsy: efficacy of surgical treatment. *Epilepsia* 35(6): 1130-1135.

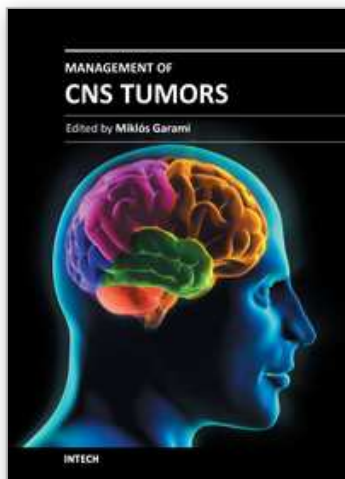


- Calatozzolo, C., M. Gelati, et al. (2005). Expression of drug resistance proteins Pgp, MRP1, MRP3, MRP5 and GST-pi in human glioma. *J Neurooncol* 74(2): 113-121.
- Cascino, G. (1990). Epilepsy and Brain Tumors: implications to treatment. *Epilepsia* 31(Suppl 3): S37-44.
- Cavaliere, R., E. Farace, et al. (2006). Clinical implications of status epilepticus in patients with neoplasms. *Arch Neurol* 63(12): 1746-1749.
- Chandana, S. R., S. Movva, et al. (2008). Primary brain tumors in adults. *Am Fam Physician* 77(10): 1423-1430.
- Cocito, L., D. Audenino, et al. (2001). Altered mental state and nonconvulsive status epilepticus in patients with cancer. *Arch Neurol* 58(8): 1310.
- Cockey, G. H., S. T. Amann, et al. (1996). Stevens-Johnson syndrome resulting from whole-brain radiation and phenytoin. *Am J Clin Oncol* 19(1): 32-34.
- Cohen, N., Strauss, G., Lew, R., Silver, R., Recht, L (1988). Should prophylactic anticonvulsants be administered to patients with newly diagnosed cerebral metastases? A retrospective analysis. *J Clin Oncol* 6: 1621-1624.
- Dalmau, J., F. Graus, et al. (1992). Anti-Hu--associated paraneoplastic encephalomyelitis/sensory neuronopathy. A clinical study of 71 patients. *Medicine (Baltimore)* 71(2): 59-72.
- Delanty, N., C. J. Vaughan, et al. (1998). Medical causes of seizures. *Lancet* 352(9125): 383-390.
- Deutschman, C., Haines, S.J (1985). Anticonvulsant prophylaxis in neurological surgery. *Neurosurgery* 17: 510-516.
- Drislane, F. W. (1994). Nonconvulsive status epilepticus in patients with cancer. *Clin Neurol Neurosurg* 96(4): 314-318.
- Echlin, F. (1959). The supersensitivity of chronically isolated cerebral cortex as a mechanism in focal epilepsy. *Electroencephalog Clin Neurophysiol* 11: 697-732.
- Eralp, Y., A. Aydinler, et al. (2001). Stevens-Johnson syndrome in a patient receiving anticonvulsant therapy during cranial irradiation. *Am J Clin Oncol* 24(4): 347-350.
- Esteve, E., A. Favre, et al. (2002). [Post-radiotherapy eruption in a patient treated with valproic acid. Rowell's syndrome?]. *Ann Dermatol Venereol* 129(6-7): 901-903.
- Foy, P. M., D. W. Chadwick, et al. (1992). Do prophylactic anticonvulsant drugs alter the pattern of seizures after craniotomy? *J Neurol Neurosurg Psychiatry* 55(9): 753-757.
- Franceschetti, S., S. Binelli, et al. (1990). Influence of surgery and antiepileptic drugs on seizures symptomatic of cerebral tumors. *Acta Neurochir (Wien)* 103(1-2): 47-51.
- Fukamachi, A., Koizumi, H., Nukui, H (1985). Immediate postoperative seizures - incidence and computed tomographic findings. *Surg Neurol* 24: 671-676.
- Glantz, M. J., B. F. Cole, et al. (2000). Practice parameter: anticonvulsant prophylaxis in patients with newly diagnosed brain tumors. Report of the Quality Standards Subcommittee of the American Academy of Neurology. *Neurology* 54(10): 1886-1893.
- Glantz, M. J., B. F. Cole, et al. (1996). A randomized, blinded, placebo-controlled trial of divalproex sodium prophylaxis in adults with newly diagnosed brain tumors. *Neurology* 46(4): 985-991.
- Hata, N., T. Shono, et al. (2007). Loss of heterozygosity analysis in an anaplastic oligodendroglioma arising after radiation therapy. *Neurol Res* 29(7): 723-726.
- Kargiotis, O., S. Markoula, et al. (2011). Epilepsy in the cancer patient. *Cancer Chemother Pharmacol* 67(3): 489-501.



- Kassam, A. B., J. A. Engh, et al. (2009). Completely endoscopic resection of intraparenchymal brain tumors. *J Neurosurg* 110(1): 116-123.
- Ketz, E. (1974). Brain tumors and Epilepsy. *Handbook of Clinical Neurology*. P. Vinken, Bruyn, GW. Amsterdam: 254-269.
- Kikuchi, K., C. I. McCormick, et al. (1984). Immunosuppression by phenytoin: implication for altered immune competence in brain-tumor patients. *J Neurosurg* 61(6): 1085-1090.
- Kuijlen, J. M., O. P. Teernstra, et al. (1996). Effectiveness of antiepileptic prophylaxis used with supratentorial craniotomies: a meta-analysis. *Seizure* 5(4): 291-298.
- Kvam, D., Loftus, CM, Copeland, B, Quest, DO (1983). Seizures during the immediate postoperative period. *Neurosurgery* 12: 14-17.
- Labrakakis, C., Patt, S, Weydt, P, et al (1997). Action potential generating cells in human glioblastoma. *J Neuropath Exp Neurol* 56: 243-254.
- LeBlanc, F., Rasmussen, T (1974). Cerebral Seizures and Brain Tumors. *Handbook of Clinical Neurology*. B. G. Vinken PJ. Amsterdam: 295-301.
- Lee, J. W., P. Y. Wen, et al. (2010). Morphological characteristics of brain tumors causing seizures. *Arch Neurol* 67(3): 336-342.
- Lee, S., Lui, TN, Chang, CN, Cheng, WC, Wang, DJ, Heimburger, RF, Lin, CG (1989). Prophylactic anticonvulsants for prevention of immediate and early postcraniotomy seizures. *Surg Neurol* 31: 361-364.
- Li, X. N., Q. Shu, et al. (2005). Valproic acid induces growth arrest, apoptosis, and senescence in medulloblastomas by increasing histone hyperacetylation and regulating expression of p21Cip1, CDK4, and CMYC. *Mol Cancer Ther* 4(12): 1912-1922.
- Lwu, S., M. G. Hamilton, et al. (2010). Use of peri-operative anti-epileptic drugs in patients with newly diagnosed high grade malignant glioma: a single center experience. *J Neurooncol* 96(3): 403-408.
- Mahaley, M. J., Dudka, L (1981). The role of anticonvulsant medications in the management of patients with anaplastic gliomas. *Surg Neurol* 16: 399-401.
- Mamon, H. J., P. Y. Wen, et al. (1999). Allergic skin reactions to anticonvulsant medications in patients receiving cranial radiation therapy. *Epilepsia* 40(3): 341-344.
- Marchi, N., L. Angelov, et al. (2007). Seizure-promoting effect of blood-brain barrier disruption. *Epilepsia* 48(4): 732-742.
- McDonald, G. A. and T. D. Dubose, Jr. (1993). Hyponatremia in the cancer patient. *Oncology (Huntingt)* 7(9): 55-64; discussion 67-58; 70-51.
- McKeran, R., Thomas, DGT (1980). The clinical study of gliomas. *Brain tumors: scientific basis, clinical investigation and current therapy*. D. Thomas, Graham, DL. Baltimore: 194-230.
- Meropol, N. J., P. J. Creaven, et al. (1995). Seizures associated with leucovorin administration in cancer patients. *J Natl Cancer Inst* 87(1): 56-58.
- Mikkelsen, T., N. A. Paleologos, et al. (2010). The role of prophylactic anticonvulsants in the management of brain metastases: a systematic review and evidence-based clinical practice guideline. *J Neurooncol* 96(1): 97-102.
- Milligan, B. D. and F. B. Meyer (2010). Morbidity of transcallosal and transcortical approaches to lesions in and around the lateral and third ventricles: a single-institution experience. *Neurosurgery* 67(6): 1483-1496; discussion 1496.
- Moots, P., Maciunas, RJ, Eisert, DR, Parker, RA, Laporte, K, Abou-Khalil, B (1995). The course of seizure disorders in patients with malignant gliomas. *Arch Neurol* 52: 717-724.

- Morris, H., Estes, ML, Prayson, RA, et al (1996). Frequency of different tumor types encountered in the Cleveland Clinic epilepsy surgery program. *Epilepsia* 37(suppl.5): 96.
- North, J. B., R. K. Penhall, et al. (1983). Phenytoin and postoperative epilepsy- a double blind study. *J Neurosurg* 58: 672-677.
- Novy, J., R. Stupp, et al. (2009). Pregabalin in patients with primary brain tumors and seizures: a preliminary observation. *Clin Neurol Neurosurg* 111(2): 171-173.
- Patsalos, P. N., W. Froscher, et al. (2002). The importance of drug interactions in epilepsy therapy. *Epilepsia* 43(4): 365-385.
- Patt, S., Labrakakis, C, Bernstein, M, et al (1996). Neuron-like physiological properties of cells from human oligodendroglial tumors. *Neuroscience* 71: 601-611.
- Perry, J. R. and C. Sawka (1996). Add-on gabapentin for refractory seizures in patients with brain tumors. *Can J Neurol Sci* 23(2): 128-131.
- Pursche, S., E. Schleyer, et al. (2008). Influence of enzyme-inducing antiepileptic drugs on trough level of imatinib in glioblastoma patients. *Curr Clin Pharmacol* 3(3): 198-203.
- Ramirez, C., C. Bowman, et al. (2010). Loss of 1p, 19q, and 10q heterozygosity prospectively predicts prognosis of oligodendroglial tumors--towards individualized tumor treatment? *Neuro Oncol* 12(5): 490-499.
- Ropper, A. H. (2009). *Adams and Victor's Principles of Neurology*, The McGraw-Hill Companies, Inc.
- Ruggiero, A., D. Rizzo, et al. (2010). Interactions between antiepileptic and chemotherapeutic drugs in children with brain tumors: is it time to change treatment? *Pediatr Blood Cancer* 54(2): 193-198.
- Sato, T., M. Takeichi, et al. (1993). Frontal lobe tumor associated with late-onset seizure and psychosis: a case report. *Jpn J Psychiatry Neurol* 47(3): 541-544.
- Schaller, B. and S. J. Ruegg (2003). Brain tumor and seizures: pathophysiology and its implications for treatment revisited. *Epilepsia* 44(9): 1223-1232.
- Scott, G., Gibberd, FB (1980). Epilepsy and other factors in the prognosis of gliomas. *Acta Neurologica Scandinavica* 61: 227-239.
- Simonescu, M. (1960). Metastatic tumors of the brain. A follow-up study of 195 patients with neurosurgical considerations. *J Neurosurg* 17: 361-373.
- Smith, D. F., J. L. Hutton, et al. (1991). The prognosis of primary intracerebral tumors presenting with epilepsy: the outcome of medical and surgical management. *J Neurol Neurosurg Psychiatry* 54(10): 915-920.
- Striano, S., P. Striano, et al. (2009). The syndrome gelastic seizures-hypothalamic hamartoma: severe, potentially reversible encephalopathy. *Epilepsia* 50 Suppl 5: 62-65.
- Thompson, D., J. Takeshita, et al. (2006). Selecting antiepileptic drugs for symptomatic patients with brain tumors. *J Support Oncol* 4(8): 411-416.
- van Breemen, M. S., E. B. Wilms, et al. (2007). Epilepsy in patients with brain tumors: epidemiology, mechanisms, and management. *Lancet Neurol* 6(5): 421-430.
- van de Loosdrecht, A. A., J. A. Gietema, et al. (2000). Seizures in a patient with disseminated testicular cancer due to cisplatin-induced hypomagnesaemia. *Acta Oncol* 39(2): 239-240.
- Whittle, I., Beaumont, A (1995). Seizures in patients with supratentorial oligodendroglial tumors; clinicopathological features and management considerations. *Acta Neurochir* 135: 19-24.
- Zentner, J., A. Hufnagel, et al. (1997). Surgical treatment of neoplasms associated with medically intractable epilepsy. *Neurosurgery* 41(2): 378-386; discussion 386-377.



## Management of CNS Tumors

Edited by Dr. Miklos Garami

ISBN 978-953-307-646-1

Hard cover, 464 pages

**Publisher** InTech

**Published online** 22, September, 2011

**Published in print edition** September, 2011

Management of CNS Tumors is a selected review of Central Nervous System (CNS) tumors with particular emphasis on pathological classification and complex treatment algorithms for each common tumor type. Additional detailed information is provided on selected CNS tumor associated disorders.

### How to reference

In order to correctly reference this scholarly work, feel free to copy and paste the following:

Elysia James and Panayiotis N. Varelas (2011). Brain Tumor and Seizures: Incidence, Pathophysiology, Diagnosis and Treatment, Management of CNS Tumors, Dr. Miklos Garami (Ed.), ISBN: 978-953-307-646-1, InTech, Available from: <http://www.intechopen.com/books/management-of-cns-tumors/brain-tumor-and-seizures-incidence-pathophysiology-diagnosis-and-treatment>

**INTECH**  
open science | open minds

### InTech Europe

University Campus STeP Ri  
Slavka Krautzeka 83/A  
51000 Rijeka, Croatia  
Phone: +385 (51) 770 447  
Fax: +385 (51) 686 166  
[www.intechopen.com](http://www.intechopen.com)

### InTech China

Unit 405, Office Block, Hotel Equatorial Shanghai  
No.65, Yan An Road (West), Shanghai, 200040, China  
中国上海市延安西路65号上海国际贵都大饭店办公楼405单元  
Phone: +86-21-62489820  
Fax: +86-21-62489821

© 2011 The Author(s). Licensee IntechOpen. This chapter is distributed under the terms of the [Creative Commons Attribution-NonCommercial-ShareAlike-3.0 License](https://creativecommons.org/licenses/by-nc-sa/3.0/), which permits use, distribution and reproduction for non-commercial purposes, provided the original is properly cited and derivative works building on this content are distributed under the same license.

IntechOpen

IntechOpen