

We are IntechOpen, the world's leading publisher of Open Access books Built by scientists, for scientists

6,900

Open access books available

186,000

International authors and editors

200M

Downloads

Our authors are among the

154

Countries delivered to

TOP 1%

most cited scientists

12.2%

Contributors from top 500 universities



WEB OF SCIENCE™

Selection of our books indexed in the Book Citation Index
in Web of Science™ Core Collection (BKCI)

Interested in publishing with us?
Contact book.department@intechopen.com

Numbers displayed above are based on latest data collected.
For more information visit www.intechopen.com



Intraoperative Photodynamic Diagnosis of Brain Tumors Using 5-Aminolevulinic Acid

Satoshi Utsuki, Hidehiro Oka and Kiyotaka Fujii

*Department of Neurosurgery, Kitasato University School of Medicine
Japan*

1. Introduction

Glioma is a type of invasive brain tumor, and the properties of the center region of the tumor differ from those of normal brain tissue. Accordingly, the macroscopic differences from normal brain tissue or differences in terms of properties such as hardness allow one to recognize that the glioma is, in fact, tumor tissue. The difference from normal brain tissue in the periphery of the tumor, i.e., the tumor's region of infiltration, does not show glioma to be as evident, making it difficult to make any objective determination as to whether there is any tumor infiltration. The margin between the normal brain tissue and tumor tissue is not clearly discernible in the band of infiltration around the malignant brain tissue, often preventing the gross-total resection (GTR) of a malignant brain tumor. Researches have shown that GTR of a malignant brain tumor has a significant impact on patient survival (Filippini et al., 2006; Gorlia et al., 2006). Accordingly, any surgery on malignant glioma is performed for the purpose of GTR, and objectively determining the region of infiltration to perform GTR on malignant glioma is necessary to significantly affect patient survival. Photodynamic diagnosis (PDD) using 5-aminolevulinic acid (5-ALA) has enabled the objective assessment of tumor infiltration whenever surgery on glioma is to be performed (Stummer et al., 1998a, 1998b). When 5-ALA is administered, protoporphyrin IX (PpIX), which is a metabolite of 5-ALA, accumulates to a greater extent in the tumor cells than in normal brain cells. The PpIX used in the procedure reacts to light within the UV range, and emits a red fluorescent hue. Irradiation of tumor-infiltrated regions with UV-range light results in the regions appearing fluorescent red if tumor cells containing an accumulation of PpIX have infiltrated. This effectively allows for an objective assessment of tumor infiltration. Resection utilizing the fluorescence of the glioma after administration of 5-ALA has been shown to assist in the visualization of the tumor tissue during surgery. As a result, the use of 5-ALA is currently being praised as a new approach that allows for a significant increase in the potential to successfully perform GTR of malignant brain tumors (Stummer et al., 1998a, 1998b, 2006, 2011).

This chapter will cover the principles of PDD using 5-ALA and provide commentary on the usefulness of this procedure for brain tumors. This will be followed by further commentary on the potential for PDD in regard to brain tumors, and finally a synopsis on the current limitations of and perspectives on this promising technique.

2. 5-ALA metabolic pathway

2.1 5-ALA metabolism in normal cells

5-ALA is a substance that naturally exists in the body. In the first stage, 5-Ala is produced via the condensation of glycine and succinyl-CoA by ALA synthetase (ALAS) in the mitochondria. This process receives negative feedback from heme, which is the end-product. 5-ALA is actively transported via cytoplasm. In the next step, porphobilinogen (PBG) is created from ALA via ALA dehydratase. The actions of PBG deaminase (PBGD) and uroporphyrinogen III synthase compress 4 PBG molecules, effectively cyclizing a tetrapyrrole chain and producing uroporphyrinogen III. Uroporphyrinogen III is converted by uroporphyrinogen decarboxylase into coproporphyrinogen III, which is exposed to coproporphyrinogen oxidase in the mitochondrial intermembrane space. Decarboxylation and oxidation of the propionic side chains of the vinyl groups' rings A and B ultimately form protoporphyrinogen IX in the cell nucleus. PpIX is synthesized from protoporphyrinogen IX via protoporphyrinogen oxidase activity, and heme is synthesized via the uptake of iron into the tetrapyrrole structure by ferrochelatase in the mitochondrial membrane (Fig. 1). Regarding mitochondrial ferrochelatase, all of the enzymes in the heme pathway that are dependent on mitochondrial energy generation display irreversibleactions and are partially adjusted via ALAS feedback control (Rimington & Riley, 1993). ALAS has the next lowest level of activity after PBGD, as the other enzymes display much high degrees of activity. When administered, 5-ALA is incorporated into cells. PBGD

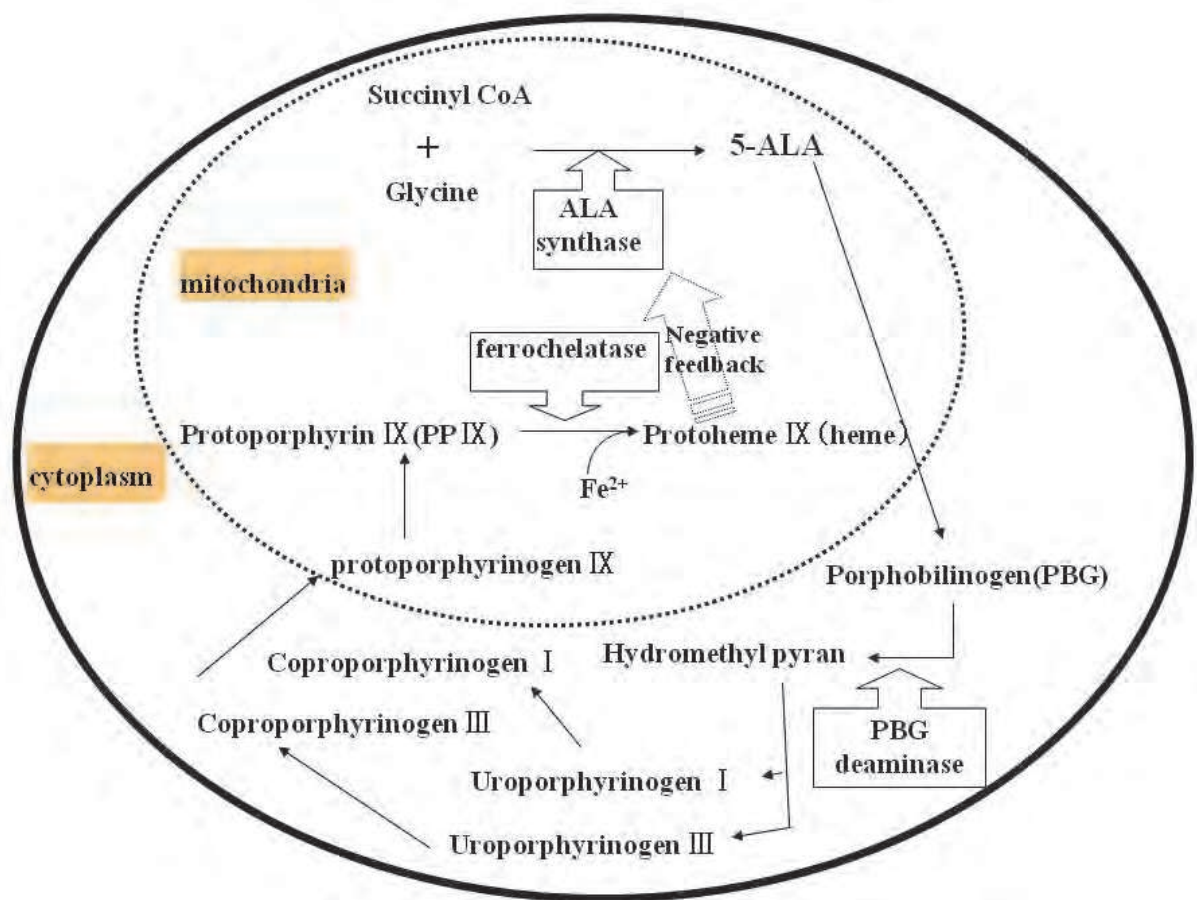


Fig. 1. Simplified metabolic pathway of 5-ALA-induced heme in cells

however, is rate-limiting, and the reactions do not proceed any further. Excessive 5-ALA is not metabolized and ALAS feedback control occurs, effectively controlling even the synthesis of 5-ALA in the cell. The resulting physiological state does not allow for synthesis of significant volumes of porphyrin or heme. External administration of a large volume of 5-ALA, however, prevents feedback control from having any additional effect and results in generation of more porphyrin than normal. The level of activity is lowest after that of PBGD, however, so extremely excessive generation of porphyrin does not occur (Mustajoki P et al., 1992).

2.2 5-ALA metabolism in tumor cells

5-ALA synthesis is the same in tumor cells as in normal cells, however, differences in enzyme activity, have been cited. In tumor cells, PBGD is not rate-controlling and metabolism is increased, so more heme is synthesized than in normal cells. Moreover, tumor cells show a relatively decreased level of ferrochelatase activity (Kaneko, 2008). Accordingly, administration of a large volume of extrinsic 5-ALA results in the 5-ALA being incorporated into tumor cells, progression of metabolism beyond PBG, and more porphyrin being produced than in normal cells (Utsuki et al., 2009).

It has been reported that in patients whose normal brain cells do not display PpIX fluorescence, glioblastoma tissue, which displays intense PpIX fluorescence, shows an increase in all porphyrins from 5-ALA to PpIX (Kaneko, 2008). However, ferrochelatase is rate-limiting, so the PpIX is not converted to heme and excessively accumulates in the tumor cells. Actually, the only enzyme activity from 5-ALA to PpIX that has a negative correlation with PpIX is the ferrochelatase activity (Kaneko, 2008). These processes show that abnormal growth of malignant glioma cells causes increased cellular uptake of 5-ALA, resulting in an increase in heme intermediate metabolites containing PpIX and a decrease in heme-synthesizing enzymes; particularly enzymes such as ferrochelatase. Accordingly, administration of 5-ALA results in increased concentration and accumulation of PpIX in tumor cells, making it an effective substance for photosensitivity (El-Sharabasy et al., 1992).

The details concerning why ferrochelatase activity is relatively low in tumor cells are unknown. Downregulation of ferrochelatase mRNA expression has been identified in tumor tissue (Teng et al., 2011). Moreover, it is also known that generation of nitric oxide in tumor cells reduces ferrochelatase in the mitochondria and increases PpIX accumulation (Yamamoto et al., 2007). These processes likely represent the cause for the relatively low ferrochelatase activity in tumor cells.

3. PDD using 5-ALA

PDD using 5-ALA was used by the authors at Kitasato University Hospital on 204 patients with brain tumor or suspected of brain tumor. 5-ALA was administered after approval by the IRB. Approval was obtained to administer 5-ALA to all patients prior to surgery. It was administered in 78 cases with glioblastoma (including 22 relapse cases), 25 cases with glioma grade III (including 6 relapse cases), 18 cases with glioma grade II (10 astrocytomas, 8 oligodendrogliomas), 2 cases with pilocytic astrocytoma, 2 cases with ependymoma, 2 cases with subependymal giant cell astrocytoma (SEGA), 1 case with choroid plexus papilloma, 1 case with atypical teratoid/rhabdoid tumor (AT/RT), 1 case with central neurocytoma, 9 cases with hemangioblastoma, 6 cases with germinoma, 20 cases with malignant lymphoma, 6 cases with pituitary adenoma, 10 cases with meningioma, 4 cases with neurilemmoma, 15 cases with metastatic brain tumor, and 4 cases with pseudotumor.

3.1 Administration of the 5-ALA

When 5-ALA is orally administered, PpIX begins to accumulate at the lesion 1 hour later. The accumulation peaks 4 to 6 hours after administration, declining afterwards. To enable accumulation of PpIX within the tumor to a peak level 1 hour after anesthesia and coincide with initiation of tumor excision, each patient was orally administered 1 g of 5-ALA (5-ALA hydrochloride, Cosmo Bio Co., Ltd., Tokyo, Japan) that was dissolved in 20 ml of 5% glucose solution 2 hours prior to initiation of the anesthesia. Regarding steroid administration, betamethasone (8-16 mg) was administered 1 hour prior to initiation of the anesthesia only in cases of severe cerebral edema.

3.2 Excitation light and fluorescent observation

PpIX reacts to UV light by displaying a red fluorescent hue. To explain, irradiation of the PpIX with excitation light results in absorption of light energy and a change from a ground state to a singlet excited state. Then, fluorescence is emitted when there is the shift from the singlet excited state to the ground state. The more PpIX in a tissue and the more intense the excitation light, the stronger the display of fluorescence by PpIX. Among the wavelengths that excite PpIX are 410 nm, 510 nm, 545 nm, 580 nm, and 630 nm. PpIX is most intensely excited by light around of ~405 nm. We used a semiconductor laser device (VLD-V1 version 2 M & M Co., Ltd., Tokyo, Japan) to provide the excitation light. This device was used to irradiate the tumor tissue via optical fiber as close to the tumor as possible with excitation light at a wavelength of 405 nm and an output of 120 mW (Fig. 2). This was observed using a cut-off filter that blocks the transmission of light at a wavelength < 430 nm and is attached to a microscope. The wavelengths included in the microscope's irradiation light near 400 nm are blocked, which lowers the PpIX photobleaching effect of the irradiation light. It blocks the excitation light, allowing for easier observation of PpIX fluorescence.

A neurosurgical microscope for fluorescence incorporated into a microscope system was developed to irradiate with excitation light, and was the principal instrument used. The device could switch from conventional white light to violet-blue excitation light and was very convenient to use (Stummer et al., 1998a). This system also provided a favorable contrast because, after image processing, it displayed fluorescence which was detected via a CCD camera.

One advantage of these methods compared to the laser method is that they allow for detection of fluorescence over the entire area observed by the microscope. When irradiating excitation light with a laser, the scope of irradiation is narrow and allows for detection of fluorescence only within the narrow area observed by the microscope (Haj-Hosseini et al., 2010; Utsuki et al, 2006). Laser methods, however, do have benefits over systems incorporated into microscopes. The biggest advantage is that use of this technology allows for excitation of fluorescence even with a low PpIX level. When excitation light is irradiated from a microscope, the distance to the target tumor tissue increases, effectively weakening the power of the excitation light that reaches the tumor tissue and resulting in weaker fluorescence. When optical fibers are used to irradiate with laser, the optical fiber is brought to a spot very near the tumor tissue, and this allows for irradiation of excitation light on the target tissue with a strong output. Also, even if this results in a low level of PpIX accumulation, the irradiation by strong excitation light allows for detection of fluorescence with a low level of PpIX.

3.3 Fluorescent analysis

PpIX reacts to light in the UV field, emitting fluorescence at two bimodal peaks, i.e., 636 nm and 704 nm. We perceive blood to be red, and may not be able to differentiate blood from the red coloring of PpIX. We usually perceive wavelengths between 610 and 750 nm to be red. Oxyhemoglobin has an absorption spectrum of 400 - 630 nm. This differs from that of PpIX, so they can be differentiated via wavelength analysis. Moreover, if the PpIX level is low, the fluorescence can be confirmed macroscopically. Also, wavelength analysis allows for detection of minute levels of PpIX fluorescence that cannot be observed macroscopically. We used a spectrometer and accessory software (BW-Spec V3.09; B & W TEK, Inc., Newark, Del., U.S.A.) to analyze the spectrum waveform via PC (Fig. 2). Wavelength analysis when performing PDD is necessary to make objective determinations regarding PpIX fluorescence and to detect minute levels of PpIX fluorescence (Utsuki et al, 2006).

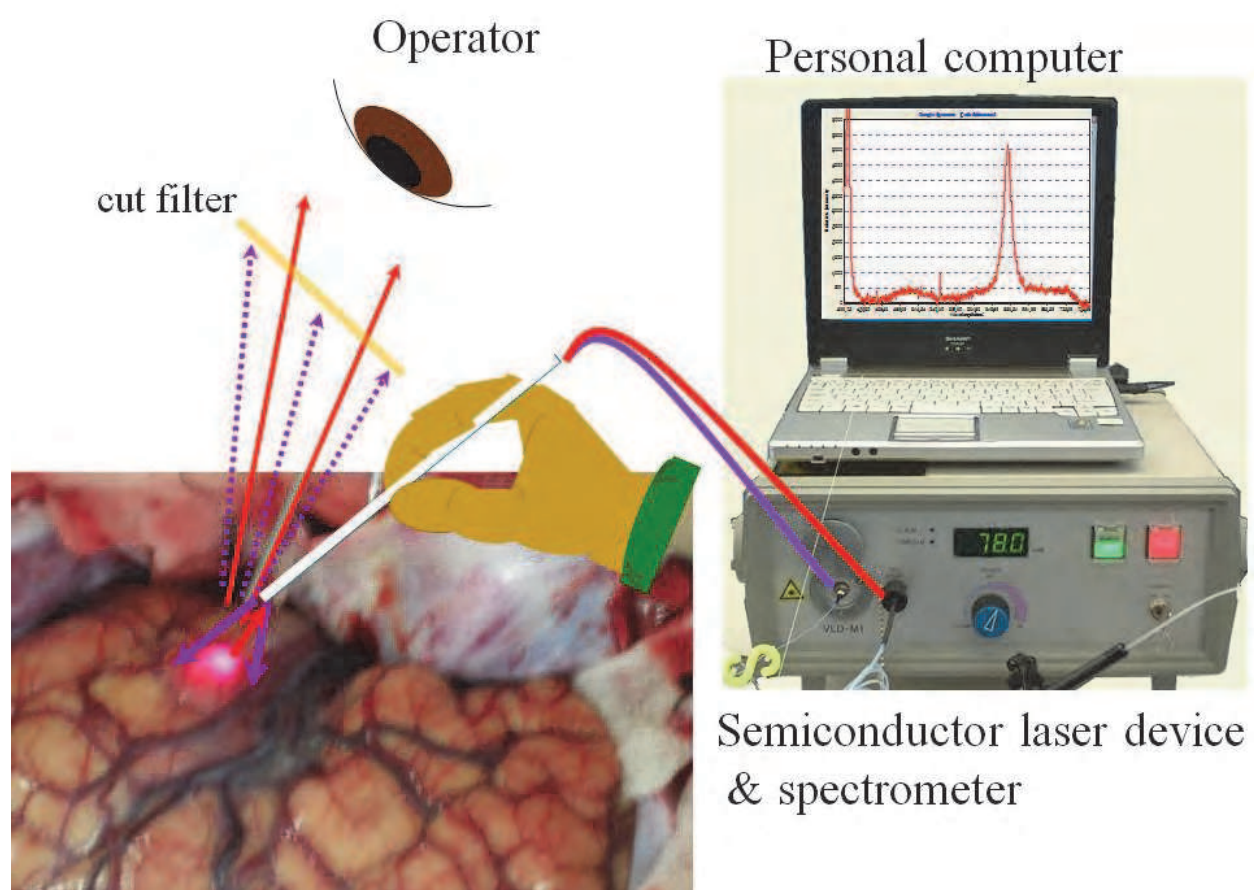


Fig. 2. Photo of intraoperative brain tumor fluorescence using a semiconductor laser device. The tumor emits red fluorescence upon exposure to a laser light with peak wavelength of 405 nm and a light output of 120 mW through optical fiber. Tumor emissions were analyzed by personal computer via spectrometer through a second optical fiber in parallel. PpIX-specific fluorescence and relative intensity were measured. The surgeons made observations via cut-off filter, so were unable to see the irradiated 405 nm blue light (blue arrows), yet the red hue of the PpIX was enhanced (red arrows).

3.4 Results of PDD for brain tumors

The strength of the perceived PpIX fluorescence is correlated with the relative strength measured with a spectrometer. When strong PpIX fluorescence is perceived, a bimodal spectrum for PpIX can be observed and the height of the 636 nm peak is at least 3,000. Weak PpIX fluorescence was observed at a height of 636 nm (the peak) between strengths of 3,000 and 1,000. Strong PpIX fluorescence was observed in 76 cases with glioblastoma (including all recurrent cases), 15 cases with glioma grade III (including all recurrent cases), 5 cases with glioma grade II (1 astrocytoma, 4 oligodendrogliomas), 2 cases with pilocytic astrocytoma, 2 cases with ependymoma, 1 case with SEGA, 1 case with choroid plexus papilloma, 1 case with AT/RT, 1 case with central neurocytoma, 9 cases with hemangioblastoma, 5 cases with germinoma, 12 cases with malignant lymphoma, 8 cases with meningioma, and 1 case with pseudotumor. Moreover, weak PpIX fluorescence was observed in 4 cases with glioma grade III, 6 cases with glioma grade II (3 astrocytomas, 3 oligodendrogliomas), 1 case with SEGA, 1 case with germinoma, 4 cases with malignant lymphoma, 1 case with meningioma, 11 cases with metastatic brain tumor, and 3 cases with pseudotumor. A clear enhancing effect of the entire/part of the tumor was observed in the magnetic resonance images (MRIs) in all of these cases except 4 cases with glioma grade II (3 astrocytomas, 1 oligodendroglioma).

PpIX fluorescence could not be macroscopically observed in 2 cases with glioblastoma, 6 cases with glioma grade III, 7 cases with glioma grade II (6 astrocytomas, 1 oligodendroglioma), 4 cases with malignant lymphoma, 6 cases with pituitary adenoma, 1 case with meningioma, 4 cases with neurilemmoma, or 4 cases with metastatic brain tumor. PpIX fluorescence was not observed even if there was a clear enhancing effect on the MRI in 2/74 cases with glioblastoma (not including 2 cases in which there was not an enhancing effect), 3/22 cases with glioma grade III (not including 3 cases in which there was not an enhancing effect), 4/18 cases with malignant lymphoma (not including 2 cases in which there was not an enhancing effect), 6/6 cases with pituitary adenoma, 1/6 cases with meningioma, 4/4 cases with neurilemmoma, and 4/15 cases with metastatic brain tumor. This said, among the cases in which the above mentioned PpIX fluorescence could not be macroscopically confirmed, it was possible to detect fluorescence of PpIX with a 636 nm peak using a spectrometer in 4 cases with glioma grade II (3 astrocytomas, 1 oligodendroglioma), 3 cases with malignant lymphoma, 1 case with meningioma, and 1 case with metastatic brain tumor.

These findings show that there may be some tumors (even benign tumors) that allow for PPD using 5-ALA in cases in which there is an enhancing effect on the MRI, but it may be difficult to use PDD with 5-ALA for pituitary adenoma or neurilemmoma, even if the MRI shows an enhancing effect.

4. The role of PDD in brain tumors

4.1 Tumor confirmation: Assisting tumor resection of invasive tumors

Glioma surgery probably receives the most benefits from PDD using 5-ALA. Even if the central region of a tumor in a malignant glioma case clearly displays different properties from normal brain cells, the peripheral region cannot be differentiated (normal brain from tumor). Also, even if there is an enhancing effect on MRI in that region, it can be difficult to determine whether there is tumor infiltration during surgery. A randomized controlled multicenter phase III trial on malignant gliomas showed a significantly higher percentage of GTR (gross-total resection) of the regions for which there was an enhancing effect on MRI among those who underwent surgery after PDD using 5-ALA, vs. those for whom 5-ALA

was not used (Stummer et al., 2006). Accordingly, the 6-month progression-free survival (PFS) in the group in which 5-ALA was used was 46% as opposed to 28% in the control group, i.e., PFS in the group in which 5-ALA was used was significantly longer (Stummer et al., 2011). Moreover, the group in which 5-ALA was used showed lower cumulative reoperation rates. PDD using 5-ALA is very helpful in glioma surgery in order to determine tumor infiltration and for an objective determination on where (what region) to resect.

In the same patients, PpIX fluorescence and tumor cell density are roughly proportionate to each other. We will show you one example of our experience. In a case of anaplastic oligodendroglioma, tumor cells with heteromorphic nuclei proliferated in a sheet-like manner in the tumor's central region (Fig. 3 B). The distinct red fluorescence of PpIX was observed in this region (Fig. 3 A, in circle) and a PpIX spectrum with a relatively high peak of 636 nm was displayed (Fig. 3 A). The Ki-67 staining index (SI) for this region was 14% (Fig. 3 C). In the tumor's region of infiltration (Fig. 4 B), weak red fluorescence of the PpIX (Fig. 4 A, in circle) and a PpIX spectrum with a low peak at 636 nm were observed (Fig. 4 A). The Ki-67 SI of this region was 3% (Fig. 4 C). Moreover, in the peripheral region, infiltration of a very small number of tumor cells with heteromorphic nuclei on an edema-like background was observed (Figure 5 C) yet PpIX red fluorescence was not observed (Figure 5 B). However, a PpIX spectrum with a very low peak was observed at 636 nm (Figure 5 A). In this region, the PpIX fluorescence could not be confirmed macroscopically, but it was a region in which PpIX could be confirmed in the spectrum only.

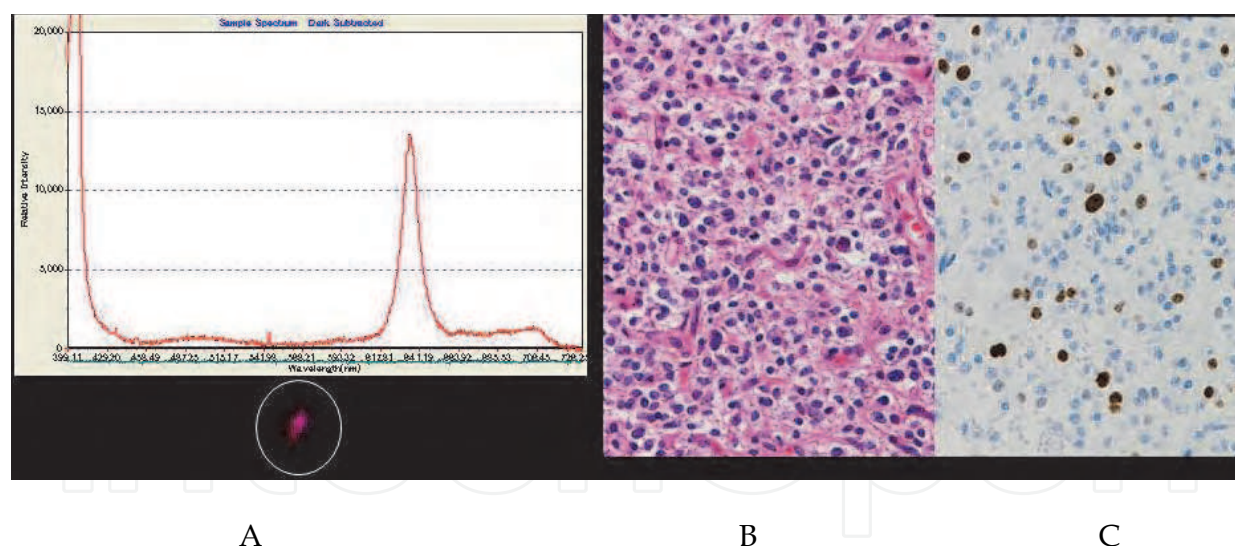


Fig. 3. Image of tissue from the central region of a tumor, the PpIX fluorescence for the region, and the fluorescence analysis results via spectrometer. It shows a proliferation of heteromorphic tumor cells with a halo around the nucleus (B, HE staining, original magnification X200). Irradiation of this region with laser showed a strong PpIX fluorescence (A, in circle). This spectrum of fluorescence featured a peak at 636 nm, indicating PpIX fluorescence (A). The relative intensity of this peak was 14000. At 14%, the Ki-67 staining index (SI) of this region was relatively high (C, Ki-67 staining, original magnification X200).

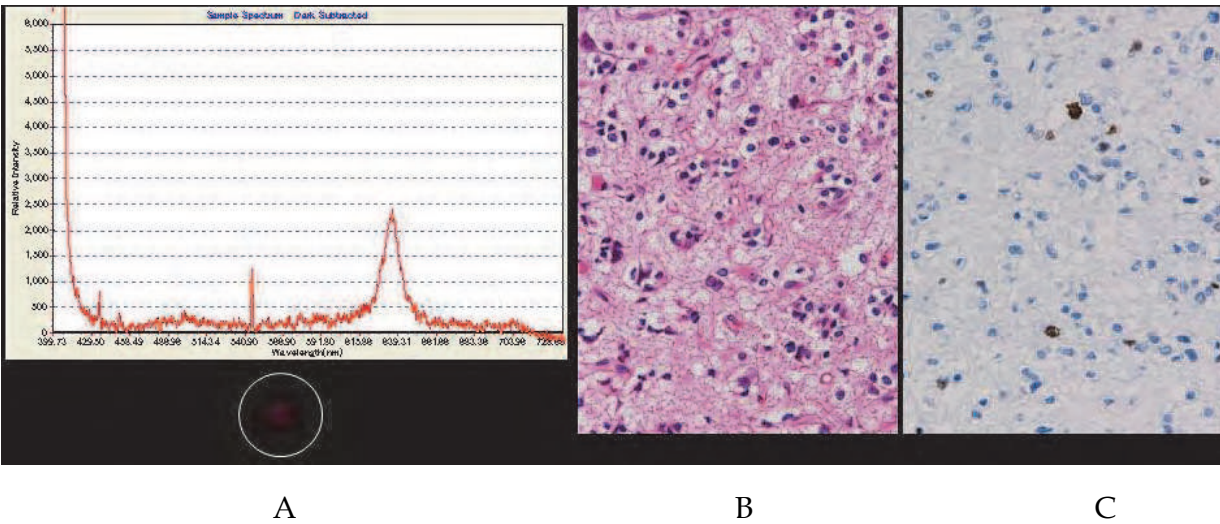


Fig. 4. Image of tissue from the region of infiltration into the brain around the tumor, the PpIX fluorescence for the region, and the fluorescence analysis results via spectrometer. Normal brain cells can be seen between the infiltrating tumor cells, so the tumor density is lower than in Fig. 3 (B, HE staining, original magnification X200). Weak PpIX fluorescence was observed (A, in circle) after irradiation of the region with a laser. The fluorescence spectrum peaks at 636 nm, with the relative intensity of the peak at 2500 (A). The Ki-67 staining index (SI) of this region was 3% (C, Ki-67 staining, original magnification X200).

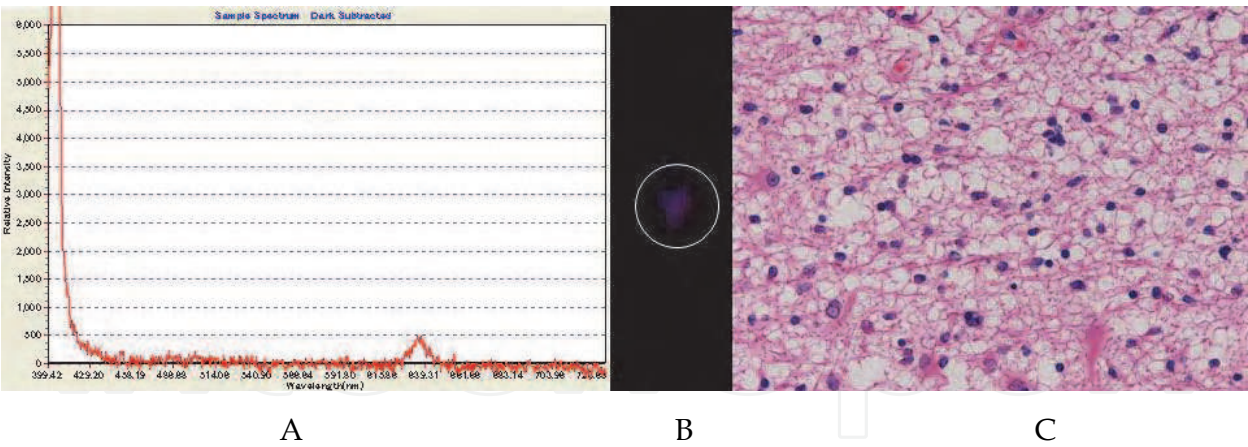


Fig. 5. Image of tissue featuring more of the peripheral region than in Fig. 3, the PpIX fluorescence for the region, and the fluorescence analysis results via spectrometer. A small number of tumor cells with heteromorphous nuclei have infiltrated edema-like brain cells, and disperse reactive astrocyte can also be seen (C, HE staining, original magnification X200). Irradiation of this region with laser did not allow for observation of the red fluorescence of PpIX (B). This fluorescence spectrum peaks at 636 nm, with fluorescence of a slight level of PpIX likely detected. The relative intensity of the peak was 500 (A).

Glioma surgery in eloquent areas is conducted using sensory-evoked potential (SEP), motor-evoked potential (MEP), awake surgery, and other methods. Cortical and subcortical stimulation must be conducted to identify the cortical pathway of the functional field/lesion periphery and determine the scope of resection. For example, if the permanent decrease in MEP amplitude obtained via transcranial electronic stimulation is at least 50% compared to baseline, tumor resection should be removed as an option. (Feigl et al., 2010). This is because once this occurs; continuing with excision of the tumor significantly increases the percentage of post-surgical neuropathy and lowers patients' quality of life (QOL). However, there are limitations to the scope of identification for these monitoring. In particular, if tumor resection is the primary measure in a case where the eloquent areas and tumor body are proximal, it facilitates worsening of patient QOL, and excessive concern about post-surgical dysfunction can result in much of the tumor remaining after surgery. In such a case, if the strength of the PpIX fluorescence, even in the regions considered to have function differs, more detailed examination of the scope of the function of the region can enable additional resection of the region(s) with strong PpIX fluorescence (region with significant tumor infiltration) and increase the glioma excision rate.

4.2 Identification of tumor's malignant regions: Determination of glioma grading

Tissue heterogeneity is normal in diffuse infiltrating glioma (Coons et al., 1993; Paulus & Peiffer, 1989). One of the reasons is that genetic mutation occurs in a portion of the tumor, and this is also one reason for it becoming malignant. To accurately ascertain how malignant a tumor is, the region that has become malignant must be left as a specimen. Moreover, whether a tumor has become malignant in that region or not has an impact on the decision regarding the scope of surgical excision if the tumor is in the vicinity of eloquent areas. Contrast-enhanced MRI and image diagnostics such as positron emission tomography (PET) using an amino acid (e.g., methionine or 18F-F-fluoroethyl-L: -tyrosine) tracer represent examples of pre-surgical image diagnostics that can be used to determine the malignant regions of the tumor. Contrast-enhanced MRI often does not show an image of WHO grade II glioma, but it does display a "patchy and faint" enhancing effect and the tumor's most active cells may exist in this region (Pallud et al, 2009). In PET diagnosis, the region with the highest accumulation of tracer represents the region in which the tumor cell metabolism activity is highest (Goldman et al., 1997; Sadeghi et al., 2007). It is difficult to identify these regions during surgery. This is because even if a navigation system is used, craniotomy, brain shift due to CSF loss/gravity, as well as cerebral edema can result in targeted deviation. PDD using 5-ALA is useful for determining this factor (Widhalm et al., 2010). Fluorescence is observed in WHO grade III glioma regions with high cell mitotic activity, but less so in regions tantamount to WHO grade II glioma with low cell mitotic activity (Ishihara et al, 2007). It has been reported that the higher the grade of glioma, the higher the PpIX concentration tends to be in tissue (Kaneko , 2008; Johansson et al., 2010). The post-surgical treatment regimen changes according to whether or not the WHO grade III glioma region remains as a specimen. Those patients are initiated on radiation therapy and chemotherapy immediately after surgery if diagnosed with WHO grade III glioma. However, if those patients are diagnosed with WHO grade II glioma, watchful waiting without any treatment may be a temporary option (Mittal et al., 2008; van den Bent et al., 2005). This is because even if irradiation is used immediately after surgery, it has been shown that there is no significant difference in total survival if it is used when the patient's post-surgical status has worsened (van den Bent et al., 2005). Considering that use of

irradiation immediately after surgery results in a significantly longer PFS, when a cell group with high mitotic activity in a very small portion of the tumor is likely turning malignant, it is possible that worsening of progressive neurological deficit may immediately be observed. Accordingly, such a case legitimizes use of irradiation immediately after surgery. In this way, PDD using 5-ALA is useful for determining detailed treatment regimens for WHO grade II to III glioma.

4.3 Confirmation of tumor resection region: Confirmation of validity of biopsy region

If the targeted lesion is small when conducting a biopsy, a minute error can prevent accurate diagnosis. This makes it necessary to confirm whether the target region is being excised. CT or MRI during or after surgery can be used to confirm whether the targeted region has been removed, but this requires time and effort. In such a case, PDD with 5-ALA can be used on a real-time basis to confirm whether the targeted region has been excised. If PpIX fluorescence can be detected from the excised tissue sample, it allows for confirmation that the targeted lesion area has been excised.

Here, we will present an actual example of this. We used the Leksell Stereotactic System (Elekta, Stockholm, Sweden) under MRI-guidance to conduct biopsy, and used a side cut biopsy needle kit (Elekta, Stockholm, Sweden) as biopsy forceps. This forceps can excise specimens up to 1.4 mm in diameter and 10 mm of length. Prior to surgery, this was a suspected case of malignant lymphoma. We planned to obtain a biopsy of a 7mm lesion in the right-frontal lobe (Fig. 6 A). Irradiation of the tissue excised with forceps using a 405 nm laser allowed for observation of the red PpIX fluorescence in a portion of the tissue (Fig. 6 B). Tumor cell infiltration can be seen in the region of the tissue sample in which PpIX fluorescence was observed (Fig. 6 C). Moreover, the regions in which no PpIX fluorescence was observed did not show any tumor cell infiltration. Naturally, not all lesions allow for observation of PpIX fluorescence, so this method is not effective in lesions in which there is no PpIX accumulation. In such a case, image diagnostics after biopsy becomes necessary.

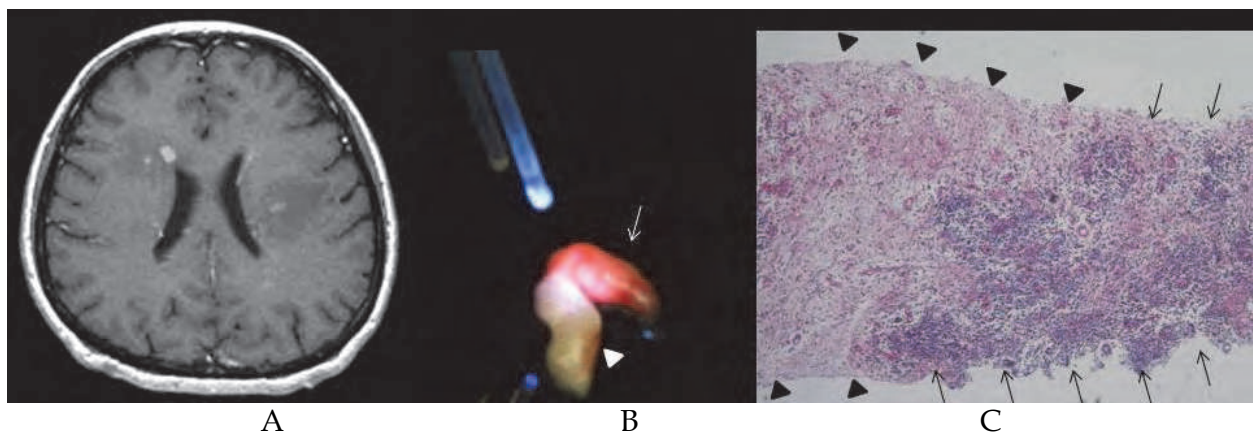


Fig. 6. Image shows a gadolinium-enhanced axial MRI image (A). A 7 mm lesion with a uniform enhancing effect can be seen proximal to the anterior horn of the lateral ventricle in the right frontal lobe. Irradiation with a 405 nm laser on the excised tissue showed the red fluorescence of PpIX over half of the tissue (arrow), but no fluorescence on the remaining of half (arrowhead) (B). The tissue image shows a clear distinction between the region infiltrated with tumor cells (arrow) and those not infiltrated (arrowhead) (C, HE staining, original magnification X40). In these regions, the portion showing PpIX fluorescence and that showing the tumor's region of infiltration concurred.

4.4 Significance of PDD using 5-ALA for benign tumor: Confirmation of remaining tumor

Recurrence is possible in benign brain tumors whereby the boundary with the periphery brain tissue is clear-cut. As is the case of meningioma, there are times in which GTR cannot be conducted in order to maintain the blood vessels/nerves in the region and within the tumor. However, there are cases of recurrence even after a surgeon has conducted GTR. The biggest reason for recurrence/relapse in such tumors is tumor remaining after excision. PDD using 5-ALA can be utilized to check for any remaining tumor after GTR procedures (Shimizu et al., 2006; Utsuki et al., 2008). PDD using 5-ALA can be used in most cases of meningioma, hemangioblastoma, and pilocytic astrocytoma, etc., because it serves as a useful detection method in such types of tumors (Coluccia et al., 2010).

Tumors in meningioma cases are mostly benign with a clear-cut boundary between the tumor and the brain, but there can be subpial infiltration even if WHO grade I, and this is quite common in recurrent cases. There are also some cases in which these tumors infiltrate bone and dura mater, creating difficulties in the resected region. If tumor infiltration into the skull base is detected, there are times in which the tumor will be left, because it cannot be adequately detached. In such cases, PDD using 5-ALA can be useful in meningioma in order to diagnose the tumor infiltration region (Kajimoto et al., 2007). In meningioma cases, dural tail sign can be observed in regions in which tumor is attached. These regions can show tumor infiltration, but also dilated blood vessels and inflammation (Rokni-Yazdi et al., 2009). Here, we have used PDD with 5-ALA to determine whether the meningioma has infiltrated the dura mater. If it has, PpIX fluorescence can be observed (Fig. 7 A). Tumor infiltration into this region can also be confirmed histologically (Fig. 7 B).

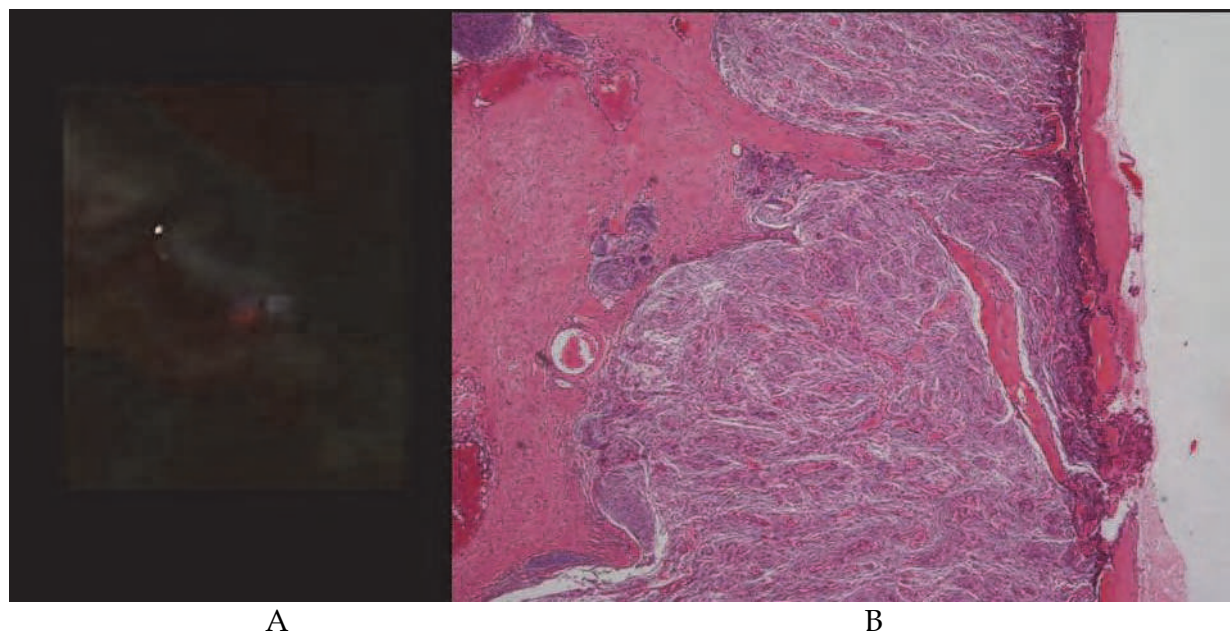


Fig. 7. Image shows PDD during surgery on region of infiltration in a dura mater in a case of meningioma. In the tumor's region of infiltration into the dura mater, the PpIX in the tumor reacted to the laser, allowing for observation of fluorescence (A). The tissue sample from this region shows a tumor mass inside a thin layer of dura mater, indicating that the tumor has infiltrated the dura mater (B, HE staining, original magnification X40).

Hemangioblastoma is a type of cancer featuring benign tumors with frequent recurrence even after GTR. A part of recurrent hemangioblastoma cases include to occur by a genetic problem. Some recurrent cases in regard to the tumor can be due to the inability to resect tumor cells that have infiltrated brain parenchyma or a cyst wall accompanying the tumor (Bishop et al., 2008). Also, PDD using 5-ALA can be useful in diagnosing residual tumor, even when it is difficult to ascertain (Utsuki et al., 2010).

5. Precautions in regard to PDD using 5-ALA

5.1 Photobleaching effect

There is great variance in tumor excision rates among surgeons even when using PDD with 5-ALA, the same device, or the same reagents. This is largely because this technique depends on the skill level of the surgeon. While tumors can be visualized on an objective basis, there likely are many aspects that depend on a surgeon's knowledge and experience when it comes to the detailed regions. Also, one factor involves the characteristics of the device being used. Another is the PpIX photobleaching effect due to the relative light exposure (Stummer et al., 1998b). Light-sensitive substances such as PpIX absorb light energy when exposed to light for a certain period of time, causing a change from a ground state to a singlet excited state. PDD has been used so that light-sensitive substances in a singlet excited state emit a fluorescent hue and shift to a ground state. This process does not always occur however, e.g., a substance in a singlet excited state can be transformed into a triplet excited state, generating free radicals, radical ions, and singlet oxygen, and effectively damaging the periphery cells. Photodynamic therapy (PDT) has used this. In this situation, PpIX (the light-sensitive substance) is not visible. The lower the level of PpIX, the earlier photobleaching occurs, although, this tends not to occur very often in the central region of the tumor where the PpIX level is high. In a tumor's region of infiltration, the fluorescence of the PpIX fades before anybody notices due to the low PpIX level (Utsuki et al., 2007a). Light in the UV field does not reach deep areas, so there may be PpIX remaining in the tissue directly below the region in which photobleaching has occurred. To avoid overlooking fluorescence because of photobleaching, and particularly in the region of infiltration of an invasive tumor, when checking for residual tumor, it is necessary to remove a small amount of surface tissue to check for any PpIX fluorescence in the newly appearing tissue.

5.2 Pseudonegative fluorescence

Stummer et al have reported some cases of malignant glioma not showing PpIX fluorescence even after showing a gadolinium-enhancing effect in an MRI (Stummer et al., 1998b). The blood brain barrier (BBB) is one of the problems. Deterioration of the BBB is an important factor required to allow 5-ALA to reach tumor cells. If there is a tumor around which the BBB has not deteriorated, 5-ALA tends not to reach the tumor cells, preventing successful use of PDD (Miyatake et al., 2007). Moreover, steroids are often used on edema accompanying brain tumor. A tightening effect caused by the steroids makes it difficult for 5-ALA to leak from deteriorated BBB around the tumor, possibly resulting in a lower supply of 5-ALA to the tumor cells (Grabb & Gilbert, 1995). The extent of steroid use that impacts the BBB permeability to 5-ALA has yet to be identified. Dexamethasone (12 mg / daily) does not appear to impact 5-ALA permeability (Stummer et al., 2006). This said, there are some cases in which the tumor does not show PpIX fluorescence after 5-ALA, even in non-brain

tumors (Hoda & Popken, 2009). This indicates that the BBB is not the only reason for failure of PDD using 5-ALA. Another cause may be in the tumor, but it must be noted that there are some cases in which PpIX fluorescence is not observed in tumors that normally should allow for PDD.

Moreover, the excitation light used when conducting PDD is light in the UV field, so PDD can usually only be used for the surface tissue. If necrotic tissue is on the surface, or a tumor is in a brain ventricle covered by brain ventricle ependyma, etc., there are cases in which tumor PpIX cannot be detected. If so, this tissue should be removed to conduct PPD.

5.3 Psudopositive fluorescence

PpIX fluorescence is observed in some cases even if a brain tumor is not present. Based on our experience, PpIX fluorescence is observed even when there are no tumor cells, for example, in cases with brain abscess, multiple sclerosis, or remarkable infiltration of reactive astrocytes and macrophages in relapsed tumors (Miyatake et al., 2007; Utsuki et al., 2007b). PpIX fluorescence is observed even in cases of radiation necrosis without tumor recurrence (Miyatake et al., 2007) or a metastatic brain tumor's edema field (Utsuki et al., 2007a). For whatever reason, PpIX fluorescence is observed even outside the brain in cases of strong inflammatory cell infiltration (Filbeck et al.; 1999). A gadolinium-enhancing effect on MRI often occurs in regions of inflammatory cell infiltration. There are also positive findings in regards to PET using L-[methyl-11C] methionine, which tends not accumulate in non-neoplastic brain lesions or be impacted by local inflammatory reaction, and the metabolism increases due to the inflammatory cells (Kawai et al., 2010). In such regions, heme synthesis is very common, as is the production of PpIX, which likely results in fluorescence being observed with PDD. Moreover, the PpIX produced by the tumor leaks to the periphery, resulting in PpIX being observed in the tumor's peripheral region, even if there is not tumor infiltration (Utsuki et al., 2007a). When employing PDD using 5-ALA, it is necessary to conduct surgery with the knowledge that tumor cells may not be present even if PpIX fluorescence is observed.

5.4 Toxicity and side effects of 5-ALA

5-ALA is an endogenous substance synthesized in the body, and is very safe. The only type of patients absolutely contraindicated for 5-ALA is porphyria patients. The most common side effect of oral administration of 5-ALA is temporary hepatic dysfunction (25%), with the incidence of nausea/vomiting being slightly lower. It causes virtually no other side effects, and there are no serious side effects as long as the oral dose of 5-ALA does not exceed 60 mg/kg and IV dose, 30 mg/kg (Mustajoki et al., 1992; Webber et al., 1997a). Erythema, edema, hyperpigmentation, etc occur in rare occasions, and require respective attention (Steinbauer et al., 2009). Excessively administered 5-ALA is completely excreted from the kidneys in 24 hours, but slower if the patient suffers from renal dysfunction (Webber et al., 1997b). Some 5-ALA is metabolized in the liver. If a patient suffers from renal dysfunction or hepatic dysfunction, the potential for phototoxicity may rise unless the dose of 5-ALA is either reduced or administration is discontinued.

Past research has shown that administration of ALA once or several times results in a high concentration of serum porphyrin among cancer patients or healthy volunteers, but no symptoms of porphyria (Mustajoki et al., 1992; Utsuki et al., 2009). Moreover, the porphyrin

level was observed to be higher than the level that causes attacks among porphyria patients. Accordingly, even if administration of 5-ALA causes a high concentration of porphyrin, it will not result in symptoms often observed in cases of porphyria.

6. Conclusions and future directions

Utilization of PDD with 5-ALA in cases of invasive brain tumor increases the rate of GTR and promises improved prognosis. It allows for confirmation of residual tumor even in cases with a benign tumor, so PDD may be helpful in the reduction of recurrence. The extent of fluorescence in PDD differs according to the level of PpIX and the strength of excitation light. Moreover, measurement of the spectrum of fluorescence allows for detection of PpIX fluorescence that cannot be observed macroscopically. When performing PDD using 5-ALA, the surgeon must know to perform surgery, about the possibility of the photobleaching effect, pseudopositive, and pseudonegative, etc.

Further studies should focus on identifying tumors in which PpIX does not accumulate and the mechanism as well as the development of methods to enhance PpIX accumulation in benign glioma in which PpIX does not tend to accumulate. Moreover, a certain degree of success has been achieved from in vitro experiments on PDT using PpIX, so there is anticipation that it can be used as a part of therapy on tumors that are difficult to excise.

7. References

- Coluccia, D., Fandino, J.; Fujioka, M.; Cordovi, S.; Muroi, C. & Landolt, H. (2010). Intraoperative 5-aminolevulinic-acid-induced fluorescence in meningiomas. *Acta Neurochir (Wien)*, Vol.152, No.10, pp. 1711-1719, ISSN 0001-6268
- Coons, S.W. & Johnson, P.C. (1993). Regional heterogeneity in the proliferative activity of human gliomas as measured by the Ki-67 labeling index. *J Neuropathol Exp Neurol*, Vol.52, No.6, pp. 609-618, ISSN 0022-3069
- El-Sharabasy, M.M.H.; El-Waseef, A.M.; Hafez, M.M. & Salim, S.A. (1992). Porphyrin metabolism in some malignant diseases. *Br J Cancer*, Vol.65, No.3, pp. 409 - 412, ISSN 0007-0920
- Feigl, G.C.; Ritz, R.; Moraes, M.; Klein, J.; Ramina, K.; Gharabaghi, A.; Krischek, B.; Danz, S.; Bornemann, A.; Liebsch, M. & Tatagiba, M.S. (2010). Resection of malignant brain tumors in eloquent cortical areas: a new multimodal approach combining 5-aminolevulinic acid and intraoperative monitoring. *J Neurosurg*, Vol.113, No.2, pp. 352-357, ISSN: 0022-3085
- Filbeck, T.; Roessler, W.; Knuechel, R.; Straub, M.; Kiel, H.J. & Wieland, W.F. (1999). 5-aminolevulinic acid-induced fluorescence endoscopy applied at secondary transurethral resection after conventional resection of primary superficial bladder tumors. *Urology*, Vol.53, No.1, pp. 77-81, ISSN 0090-4295
- Filippini, G.; Falcone, C.; Boiardi, A.; Broggi, G.; Bruzzone, M.G.; Caldiroli, D.; Farina, R.; Farinotti, M.; Fariselli, L.; Finocchiaro, G.; Giombini, S.; Pollo, B.; Savoiardo, M.; Solero, C.L. & Valsecchi, M.G.; Brain Cancer Register of the Fondazione IRCCS (Istituto Ricovero e Cura a Carattere Scientifico) Istituto Neurologico Carlo Besta. (2008). Prognostic factors for survival in 676 consecutive patients with newly

- diagnosed primary glioblastoma. *Neuro-oncol*, Vol.10, No.1, pp. 79-87, ISSN 1522-8517
- Goldman, S.; Levivier, M.; Pirotte, B.; Brucher, J.M.; Wikler, D.; Damhaut, P.; Dethy, S.; Brotchi, J. & Hildebrand, J. (1997). Regional methionine and glucose uptake in high-grade gliomas: a comparative study on PET-guided stereotactic biopsy. *J Nucl Med*, Vol.38, No.9, pp. 1459-1462, ISSN 0161-5505
- Gorlia, T.; van den Bent, M.J.; Hegi, M.E.; Mirimanoff, R.O.; Weller, M.; Cairncross, J.G.; Eisenhauer, E.; Belanger, K.; Brandes, A.A.; Allgeier, A.; Lacombe, D. & Stupp, R. (2008). Nomograms for predicting survival of patients with newly diagnosed glioblastoma: prognostic factor analysis of EORTC and NCIC trial 26981-22981/CE.3. *Lancet Oncol*, Vol.9, No.1, pp. 29-38, ISSN 1470-2045
- Grabb, P.A. & Gilbert, M.R. (1995). Neoplastic and pharmacological influence on the permeability of an in vitro blood-brain barrier. *J Neurosurg*, Vol.82, No.6, pp. 1053-1058, ISSN: 0022-3085
- Haj-Hosseini, N.; Richter, J.; Andersson-Engels, S. & Wårdell K. (2010). Optical touch pointer for fluorescence guided glioblastoma resection using 5-aminolevulinic acid. *Lasers Surg Med*, Vol.42, No.1, pp. 9-14, ISSN 0196-8092
- Hoda, M.R. & Popken, G. (2009). Surgical outcomes of fluorescence-guided laparoscopic partial nephrectomy using 5-aminolevulinic acid-induced protoporphyrin IX. *J Surg Res*, Vol.154, No.2, pp. 220-225, ISSN 0022-4804
- Ishihara, R.; Katayama, Y.; Watanabe, T.; Yoshino, A.; Fukushima, T. & Sakatani, K. (2007). Quantitative spectroscopic analysis of 5-aminolevulinic acid-induced protoporphyrin IX fluorescence intensity in diffusely infiltrating astrocytomas. *Neurol Med Chir (Tokyo)*, Vol.47, No.2, pp. 53-57, ISSN 0470-8105
- Johansson, A.; Palte, G.; Schnell, O.; Tonn, J.C.; Herms, J. & Stepp, H. (2010). 5-Aminolevulinic acid-induced protoporphyrin IX levels in tissue of human malignant brain tumors. *Photochem Photobiol*, Vol.86, No.6, pp. 1373-1378, ISSN 0031-8655
- Kajimoto, Y.; Kuroiwa, T.; Miyatake, S.; Ichioka, T.; Miyashita, M.; Tanaka, H. & Tsuji, M. (2007). Use of 5-aminolevulinic acid in fluorescence-guided resection of meningioma with high risk of recurrence. Case report. *J Neurosurg*, Vol.106, No.6, pp. 1070-1074, ISSN 0022-3085
- Kaneko, S. (2008). A current overview: photodynamic diagnosis and photodynamic therapy using 5-aminolevulinic acid in neurosurgery. *J Jpn Soc Laser Surg Med*, Vol.29, No.2, pp. 135-146, ISSN 0288-6200
- Kawai, N.; Okauchi, M.; Miyake, K.; Sasakawa, Y.; Yamamoto, Y.; Nishiyama, Y. & Tamiya, T. (2010). ¹¹C-methionine positron emission tomography in nontumorous brain lesions. *No Shinkei Geka*, Vol.38, No.11, pp. 985-995, ISSN 0301-2603
- Mittal, S.; Szlachetky, M.C., & Barger, G.R. (2008). Low-grade gliomas in adults. *Curr Treat Options Neurol*, Vol.10, No.4, pp. 271-284, ISSN 1092-8480
- Miyatake, S.; Kuroiwa, T.; Kajimoto, Y.; Miyashita, M.; Tanaka, H. & Tsuji, M. (2007). Fluorescence of non-neoplastic, magnetic resonance imaging-enhancing tissue by 5-aminolevulinic acid: case report. *Neurosurgery*, Vol.61, No.5, pp. E1101-E1104, ISSN 0148-396X

- Mustajoki, P.; Timonen, K.; Gorchein, A.; Seppäläinen, A.M.; Matikainen, E. & Tenhunen, R. (1992). Sustained high plasma 5-aminolaevulinic acid concentration in a volunteer, no porphyric symptoms. *Eur J Clin Invest*, Vol.22, No.6, pp. 407-411, ISSN 0014-2972
- Pallud, J.; Capelle, L.; Taillandier, L.; Fontaine, D.; Mandonnet, E.; Guillemin, R.; Bauchet, L.; Peruzzi, P.; Laigle-Donadey, F.; Kujas, M.; Guyotat, J.; Baron, M.H.; Mokhtari, K. & Duffau, H. (2009). Prognostic significance of imaging contrast enhancement for WHO grade II gliomas. *Neuro Oncol*, Vol.11, No.2, pp. 176-182, ISSN 1522-8517
- Paulus, W. & Peiffer, J. (1989). Intratumoral histologic heterogeneity of gliomas. A quantitative study. *Cancer*. Vol.64No.2, pp. 442-447, ISSN 0008-543X
- Rimington, C. & Riley, P.A. (1993). The biochemical approach to cancer therapy: a short essay. *Int J Biochem*, Vol.25, No.10, pp. 1385 - 1393, ISSN 0020-7114
- Roberts, D.W.; Valdes, P.A.; Harris, B.T.; Fontaine, K.M.; Hartov, A.; Fan, X.; Ji, S.; Lollis, S.S.; Pogue, B.W.; Leblond, F.; Tosteson, T.D.; Wilson, B.C. & Paulsen, K.D. (2011). Coregistered fluorescence-enhanced tumor resection of malignant glioma: relationships between δ -aminolevulinic acid-induced protoporphyrin IX fluorescence, magnetic resonance imaging enhancement, and neuropathological parameters. *J Neurosurg*, Vol.114, No.3, pp. 595-603, ISSN: 0022-3085
- Rokni-Yazdi, H.; Azmoudeh Ardalan, F.; Asadzandi, Z.; Sotoudeh, H.; Shakiba, M.; Adibi, A.; Ayatollahi, H. & Rahmani, M. (2009). Pathologic significance of the "dural tail sign". *Eur J Radiol*. Vol.70, No.1, pp. 10-16, ISSN 0720-048X
- Sadeghi, N.; Salmon, I.; Decaestecker, C.; Levivier, M.; Metens, T.; Wikler, D.; Denolin, V.; Rorive, S.; Massager, N.; Baleriaux, D. & Goldman, S. (2007). Stereotactic comparison among cerebral blood volume, methionine uptake, and histopathology in brain glioma. *AJNR Am J Neuroradiol*, Vol.28, No.10, pp. 455-461, ISSN 0195-6108
- Shimizu, S.; Utsuki, S.; Sato, K.; Oka, H.; Fujii, K. & Mii, K. (2006). Photodynamic diagnosis in surgery for spinal ependymoma. Case illustration. *J Neurosurg Spine*, Vol.5, No.4, pp. 380-380, ISSN 1547-5654
- Steinbauer, J., Schreml, S.; Karrer, S.; Ackermann, G.; Babilas, P.; Landthaler, M. & Szeimies, R.M. (2009). Phototoxic reactions in healthy volunteers following photodynamic therapy with methylaminolevulinate cream or with cream containing 5-aminolevulinic acid: a phase II, randomized study. *Photodermatol Photoimmunol Photomed*, Vol.25, No.5, pp. 270-275, ISSN 0905-4383
- Stummer, W.; Stepp, H.; Moller, G.; Ehrhardt, A.; Leonhard, M. & Reulen, H.J. (1998a). Technical principles for protoporphyrin-IX fluorescence guided microsurgical resection of malignant Glioma tissue. *Acta Neurochir (Wien)*, Vol.140, No.10, pp. 995-1000, ISSN 0001-6268
- Stummer, W.; Stocker, S.; Wagner, S.; Stepp, H.; Fritsch, C.; Goetz, C.; Goetz, A.E.; Kieffmann, R. & Reulen, H.J. (1998b). Intraoperative detection of malignant gliomas by 5-aminolevulinic acid-induced porphyrin fluorescence. *Neurosurgery*, Vol.42, No.3 pp. 518-526, ISSN 0148-396X
- Stummer, W.; Pichlmeier, U.; Meinel, T.; Wiestler, O.D.; Zanella, F. & Reulen, H.J. (2006). Fluorescence-guided surgery with 5-aminolevulinic acid for resection of malignant glioma: a randomised controlled multicentre phase III trial. *Lancet Oncol*, Vol.7, No.5, pp. 392-401, ISSN 1470-2045

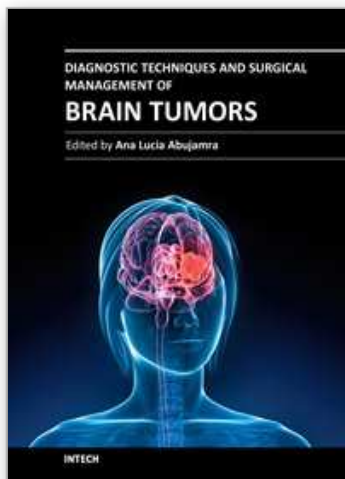
- Stummer, W.; Tonn, J.C.; Mehdorn, H.M.; Nestler, U.; Franz, K.; Goetz, C.; Bink, A. & Pichlmeier, U.; on behalf of the ALA-Glioma Study Group. (2011). Counterbalancing risks and gains from extended resections in malignant glioma surgery: a supplemental analysis from the randomized 5-aminolevulinic acid glioma resection study. *J Neurosurg*, Vol.114, No.3, pp. 613–623, ISSN: 0022-3085
- Teng, L.; Nakada, M.; Zhao, S.G.; Endo, Y.; Furuyama, N.; Nambu, E.; Pyko, I.V.; Hayashi, Y. & Hamada, J.I. (2011). Silencing of ferrochelatase enhances 5-aminolevulinic acid-based fluorescence and photodynamic therapy efficacy. *Br J Cancer*, Vol.104, No.5, pp. 798-807, ISSN 0007-0920
- Utsuki, S.; Oka, H.; Sato, S.; Suzuki, S.; Shimizu, S.; Tanaka, S. & Fujii, K. (2006). Possibility of using laser spectroscopy for the intraoperative detection of nonfluorescing brain tumors and the boundaries of brain tumor infiltrates. Technical note. *J Neurosurg*, Vol.104, No.4, pp. 618-620, ISSN 0022-3085
- Utsuki, S.; Miyoshi, N.; Oka, H.; Miyajima, Y.; Shimizu, S.; Suzuki, S. & Fujii, K. (2007a). Fluorescence-guided resection of metastatic brain tumors using 5-aminolevulinic acid-induced porphyrins - pathological study. *Brain Tumor Pathol*, Vol.24, No.2, pp. 53-55, ISSN 1433-7398
- Utsuki, S.; Oka, H.; Sato, S.; Shimizu, S.; Suzuki, S.; Tanizaki, Y.; Kondo, K.; Miyajima, Y. & Fujii, K. (2007b). Histological examination of false positive tissue resection using 5-aminolevulinic acid-induced fluorescence guidance. *Neurol Med Chir (Tokyo)*, Vol.47, No.5, pp. 210-214, ISSN 0470-8105
- Utsuki, S.; Oka, H.; Miyajima, Y.; Shimizu, S.; Suzuki, S. & Fujii, K. (2008). Auditory alert system for fluorescence-guided resection of gliomas. Technical Note. *Neurol Med Chir (Tokyo)*, Vol.48, No.2, pp. 95-98, ISSN 0470-8105
- Utsuki, S.; Oka, H.; Suzuki, S.; Sato, S.; Mabuti, I.; Kijima, C. & Fujii, K. (2009). Significance of porphyrins in blood and urine of brain tumor patients that underwent 5-ALA administration. *Neuro Oncol*, Vol.11, No.6, pp. 920-920, ISSN 1522-8517
- Utsuki, S.; Oka, H.; Sato, K.; Shimizu, S.; Suzuki, S. & Fujii, K. (2010). Fluorescence diagnosis of tumor cells in hemangioblastoma cysts with 5-aminolevulinic acid. *J Neurosurg*, Vol.112, No.1, pp.130-132, ISSN 0022-3085
- van den Bent, M.J.; Afra, D.; de Witte, O.; Ben Hassel, M.; Schraub, S.; Hoang-Xuan, K.; Malmstrom, P.O.; Collette, L.; Pierart, M.; Mirimanoff, R. & Karim, A.B.; EORTC Radiotherapy and Brain Tumor Groups and the UK Medical Research Council. (2005). Long-term efficacy of early versus delayed radiotherapy for low-grade astrocytoma and oligodendroglioma in adults: the EORTC 22845 randomised trial. *Lancet*. Vol.366, No.9490, pp. 985-990, ISSN 0140-6736
- Webber, J.; Kessel, D. & Fromm, D. (1997a). Side effects and photosensitization of human tissues after aminolevulinic acid. *J Surg Res*, Vol.68, No.1, pp. 31-37, ISSN 0022-4804
- Webber, J.; Kessel, D. & Fromm, D. (1997b). Plasma levels of protoporphyrin IX in humans after oral administration of 5-aminolevulinic acid. *J Photochem Photobiol B*, Vol.37, No.1-2, pp. 151-153, ISSN 1011-1344
- Widhalm, G.; Wolfsberger, S.; Minchev, G.; Woehrer, A.; Krssak, M.; Czech, T.; Prayer, D.; Asenbaum, S.; Hainfellner, J.A. & Knosp, E. (2010). 5-Aminolevulinic acid is a promising marker for detection of anaplastic foci in diffusely infiltrating gliomas

with nonsignificant contrast enhancement. *Cancer*, Vol.116, No.6, pp. 1545-1552, ISSN 0008-543X

Yamamoto, F.; Ohgari, Y.; Yamaki, N.; Kitajima, S., Shimokawa, O.; Matsui, H. & Taketani, S. (2007) The role of nitric oxide in delta-aminolevulinic acid (ALA)-induced photosensitivity of cancerous cells. *Biochem Biophys Res Commun*, Vol.353, No.3, pp. 541-546, ISSN 0006-291X

IntechOpen

IntechOpen



Diagnostic Techniques and Surgical Management of Brain Tumors

Edited by Dr. Ana Lucia Abujamra

ISBN 978-953-307-589-1

Hard cover, 544 pages

Publisher InTech

Published online 22, September, 2011

Published in print edition September, 2011

The focus of the book *Diagnostic Techniques and Surgical Management of Brain Tumors* is on describing the established and newly-arising techniques to diagnose central nervous system tumors, with a special focus on neuroimaging, followed by a discussion on the neurosurgical guidelines and techniques to manage and treat this disease. Each chapter in the *Diagnostic Techniques and Surgical Management of Brain Tumors* is authored by international experts with extensive experience in the areas covered.

How to reference

In order to correctly reference this scholarly work, feel free to copy and paste the following:

Satoshi Utsuki, Hidehiro Oka and Kiyotaka Fujii (2011). Intraoperative Photodynamic Diagnosis of Brain Tumors Using 5-Aminolevulinic Acid, *Diagnostic Techniques and Surgical Management of Brain Tumors*, Dr. Ana Lucia Abujamra (Ed.), ISBN: 978-953-307-589-1, InTech, Available from:
<http://www.intechopen.com/books/diagnostic-techniques-and-surgical-management-of-brain-tumors/intraoperative-photodynamic-diagnosis-of-brain-tumors-using-5-aminolevulinic-acid>

INTECH
open science | open minds

InTech Europe

University Campus STeP Ri
Slavka Krautzeka 83/A
51000 Rijeka, Croatia
Phone: +385 (51) 770 447
Fax: +385 (51) 686 166
www.intechopen.com

InTech China

Unit 405, Office Block, Hotel Equatorial Shanghai
No.65, Yan An Road (West), Shanghai, 200040, China
中国上海市延安西路65号上海国际贵都大饭店办公楼405单元
Phone: +86-21-62489820
Fax: +86-21-62489821

© 2011 The Author(s). Licensee IntechOpen. This chapter is distributed under the terms of the [Creative Commons Attribution-NonCommercial-ShareAlike-3.0 License](https://creativecommons.org/licenses/by-nc-sa/3.0/), which permits use, distribution and reproduction for non-commercial purposes, provided the original is properly cited and derivative works building on this content are distributed under the same license.

IntechOpen

IntechOpen