

# We are IntechOpen, the world's leading publisher of Open Access books Built by scientists, for scientists

6,900

Open access books available

185,000

International authors and editors

200M

Downloads

Our authors are among the

154

Countries delivered to

TOP 1%

most cited scientists

12.2%

Contributors from top 500 universities



WEB OF SCIENCE™

Selection of our books indexed in the Book Citation Index  
in Web of Science™ Core Collection (BKCI)

Interested in publishing with us?  
Contact [book.department@intechopen.com](mailto:book.department@intechopen.com)

Numbers displayed above are based on latest data collected.  
For more information visit [www.intechopen.com](http://www.intechopen.com)



## Myositis and Cancer

Sergio Prieto-González<sup>1</sup>, Vladimir Lazo<sup>1</sup>, Ernesto Trallero-Araguás<sup>2</sup>,  
Albert Selva-O'Callaghan<sup>2</sup> and Josep M Grau<sup>1</sup>

<sup>1</sup>*Muscle Research Unit, Internal Medicine Department, Hospital Clínic,  
Barcelona, Universitat de Barcelona and CIBERER,*

<sup>2</sup>*Internal Medicine Department, Hospital Vall d'Hebrón, Barcelona,  
Spain*

### 1. Introduction

The idiopathic inflammatory myopathies (IIM), classically dermatomyositis (DM), polymyositis (PM), and inclusion body myositis (IBM), are acquired systemic autoimmune disorders defined by chronic muscle weakness and inflammation of unknown aetiology. The combination of clinical, laboratory, electromyographic, and histological features is the basis of diagnosis, as well as exclusion of several mimicking conditions (Bohan & Peter, 1975; Dalakas & Hohlfeld, 2003; Mann et al, 2010; Mastaglia & Phillips, 2002). IIM are the most common causes of acquired muscle disease in adults, but are still rare conditions with an estimated overall prevalence of 50 to 100 cases per million (Oddis et al., 1990; Prieto & Grau 2010; Wilson et al., 2008).

In recent years, taking into account additional clinical, immunological and histological features, new phenotypes among IIM, such as antisynthetase syndrome, autoimmune necrotizing myopathy, connective tissue disorder-associated myositis, or cancer-associated myositis (CAM), have been described (Cox et al., 2010; Dalakas, 2010; Dimachkie, 2011; Rider & Miller, 2011; Targoff, 2008).

The association between cancer and IIM has been widely reported in the medical literature, particularly in DM patients (Buchbinder et al., 2001; Sigurgeirsson et al., 1992). Cancer screening is a common practice in patients recently diagnosed with IIM, but there is not consensus about how, and how often screening should be performed. The aim of this chapter is to describe the epidemiological, clinical, laboratory, and histological reported features about CAM, to analyze the current potentially approach to preclude malignancy in IIM, and to provide an advisable algorithm in the diagnosis of occult cancer in myositis.

### 2. Background

The association between IIM and malignancy has been appreciated for nearly a century. From the first case reports in 1916 (Kankeleit, 1916; Stertz, 1916), large, retrospective studies and reviews examining this association have been subsequently published (Airio et al., 1995; Antiochos et al., 2009; Barnes & Mawr 1976; Buchbinder et al, 2001; Chow et al., 1995; Fardet et al., 2009; Hill et al., 2001; Huang et al., 2009; Madan et al., 2009; Sigurgeirsson et al., 1992;

Stockton et al., 2001; Wakata et al., 2002; Williams Jr., 1959; Zantos et al., 1994). Although the frequency in case reports showed a very wide range from 3 to 60%, population-based cohort studies have demonstrate that cancer is detected in approximately 30% of DM and 15% of PM patients, and both groups have increased cancer risks compared with the general population (Table 1) (Zampieri et al., 2010). In recent years, relevant progress has been made in understanding the link between cancer and myositis, providing accurate description about their temporal relationship and the rationale about their pathophysiological mechanisms.

Myositis patients number		CAM number and (%)		Reference
DM	PM	DM	PM	
392	396	94 (24)	58 (15)	Sigurgeisson (14)
618	914	198 (32)	137 (15)	Hill (22)
85	321	36 (42)	58 (18)	Buchbinder (13)
286	419	77 (27)	71 (17)	Stockton (21)
28	64	10 (36)	2 (3)	Wakata (23)
103	109	15 (15)	6 (6)	Chinoy (55)
1059	661	136 (13)	46 (7)	Huang (25)
121	NE	29 (24)	NE	Fardet (24)

CAM: cancer associated myositis; DM: dermatomyositis; PM: polymyositis; NE: not evaluated.

Table 1. Summary of reported CAM case series (adapted from Zampieri et al, 2010).

3. Other neuromuscular paraneoplastic conditions

Paraneoplastic syndromes (PS) are a group of conditions caused by an underlying immune response to cancer, thus not related to nutritional abnormalities, amyloid deposition, or adverse effects of treatment (Braik et al., 2010). Specific PS involving the neurological system (PNS) are rare, affecting 0,01% of patients with cancer and with overall incidence of about 1-10 per 10,000. Only Lambert-Eaton myasthenic syndrome (LEMS) is relatively common, affecting 1% of patients with small cell lung cancer. The most common forms of PNS are the paraneoplastic sensory neuronopathy (3-7 per 1,000), the paraneoplastic encephalitis (3 per 1,000), and the cerebellar degeneration (2 per 1,000). It is important to remark that these data may be underestimated because positive autoantibodies as a diagnostic criterium in these series were required (Graus & Dalmau, 2007; Honnorat & Antoine, 2007). PNS may affect the central nervous system (CNS), the neuromuscular junction, and the peripheral nervous system. Cognitive disorders, personality changes, ataxia, cranial nerve paralysis, weakness, numbness, and jerks are the main described symptoms. Clinical and laboratory features of the most frequent PNS are described in Table 2. Onconeural antibodies are the basis of the PNS pathogenesis, produced by an immune cross reaction between tumor and CNS cells (Didelot & Honnorat, 2009). PNS may be classified into classical and non-classical disorders, being the first group more often associated with cancer (Table 3).

Paraneoplastic neurological syndromes			
PNS	Clinical Presentation	Associated cancer	Antibodies
LEMS	Lower limbs proximal muscle weakness	SCLC	Anti-VGCC, anti-SOX
Paraneoplastic cerebellar degeneration	Ataxia, diplopia, dysphagia, dysarthria	Ovary, breast, SCLC, Hodgkin's disease	Anti-Yo, anti-Hu, anti-CV2, anti-Ma, anti-Tr
Opsoclonus-myoclonus	Dyskinetic shakes and myoclonic jerks of trunk and extremities	Neuroblastoma, breast, lung	Anti-Hu, anti-Ri
Sensory neuronopathy	Paresthesias/pain followed by ataxia	SCLC	Anti-Hu, anti-CV2
Limbic encephalitis	Mood changes, hallucinations, memory loss, seizures	SCLC, testicular	Anti-Hu, anti-CV2, anti-Ma, anti-amphiphysin

PNS: Paraneoplastic neurological syndrome; LEMS: Lambert-Eaton myasthenic syndrome; SCLC: smal cell lung cancer.

Table 2. Main features of most common PNS (modified from Braik et al., 2010; Didelot & Honnorat 2009; Graus et al., 2010).

Paraneoplastic neurological syndromes	
Classical	Non-classical
Encephalomyelitis	Optic neuritis
Limbic encephalitis	Cancer associated retinopathy
Subacute cerebellar degeneration	Melanoma associated retinopathy
Opsoclonus-myoclonus	Stiff person syndrome
Subacute sensory neuronopathy	Necrotising myelopathy
Chronic gastrointestinal pseudo-obstruction	Motor neuron diseases
Lambert-Eaton myasthenic syndrome	Acute sensorimotor neuropathy : - Guillain-Barré syndrome - Brachial neuritis
Dermatomyositis	Subacute/chronic sensorimotor neuropathies
	Neuropathy and paraproteinaemia
	Neuropathy with vasculitis
	Autonomic neuropathies
	Myasthenia gravis
	Acquired neuromyotonia
	Acute necrotising myopathy

PNS: Paraneoplastic neurological syndrome.

Table 3. Classical and non-classical PNS (modified from Graus et al., 2004)

The presence of a PNS may offer the possibility of early diagnosis of cancer, since PNS occurs in up to 50 to 80% of cases without any other malignancy signs. Diagnosis should be made in 3 steps:

1. To exclude other diagnosis: other conditions that may mimic PNS should be ruled out . These include: vascular diseases, connective tissue disorders, infections, nutritional disorders, adverse drug reactions, and exposure to toxins;
2. To search for cancer: comprehensive medical history, physical examination, laboratory, and imaging techniques should be performed;
3. To establish the diagnosis of PNS: this may require blood tests, imaging studies, electroencephalogram, nerve conduction studies, electromyography, and CSF examination. Onconeural antibodies may be positive in serum and/or CSF in 30% of patients (Braik et al., 2010). Table 4 summarizes the situations defined as definite or possible diagnosis of PNS.

PNS Diagnostic Criteria	
Definite PNS	Possible PNS
<div><div>1. Classical syndrome and cancer that develop within five years of the diagnosis of the neurological disorder.</div><div>2. Non-classical syndrome that resolves or significantly improves after cancer treatment without concomitant immunotherapy, provided that the syndrome is not susceptible to spontaneous remission.</div><div>3. Non-classical syndrome with onconeural antibodies (well characterized or not) and cancer that develop within five years of the diagnosis of the neurological disorder.</div><div>4. Neurological syndrome (classical or not) with well characterized onconeural antibodies (anti-Hu, Yo, CV2, Ri, Ma2, or amphiphysin) and no cancer evidence.</div></div>	<div><div>1. Classical syndrome, no onconeural antibodies, no cancer but at high risk to have an underlying tumour.</div><div>2. Neurological syndrome (classical or not) with partially characterized onconeural antibodies and no cancer.</div><div>3. Non-classical syndrome, no onconeural antibodies, and cancer present within two years of diagnosis.</div></div>

*Well characterized onconeural antibodies included: Anti-Hu, Yo, CV2, Ri, Ma2, amphiphysin. Partially characterized onconeural antibodies: anti-Tr, ANNA3, PCA2, Zic4, mGluR1.*

Table 4. PNS diagnostic criteria.

4. Myositis as paraneoplastic process

Taken into account the aforementioned epidemiological and clinical data, as well as temporal relationship, it is important to note the possibility that many cases of the IIM represent autoimmune paraneoplastic processes related to solid tumor oncogenesis, indicating an immune-mediated destruction of muscle and skin as response to cancer antigens. This observation has been extensively described in the autoimmune PNS, in which severe, immune-mediated neuronal damage occurs in the setting of solid tumours whose primary sites are outside of the central nervous system (Albert & Darnell, 2004). The serological hallmark of this associated group of disorders is the association of stereotypical

autoantibody profiles with specific clinical phenotypes; furthermore, although the tumours are not neuronal in origin, they express high levels of protein antigens that are also highly expressed in neuronal tissue (Albert & Darnell, 2004; Furneaux et al., 1990).

With regard to CAM, the underlying pathogenetic molecular mechanisms are still unknown, but some findings leading to better understanding have been reported. It is published that some tumours (breast, lung adenocarcinoma, hepatocellular carcinoma), but not the corresponding normal tissues, do express high levels of myositis autoantigens (Casciola-Rosen et al., 2005); moreover, it has been reported that regenerating myoblasts overexpress myositis specific autoantigens in affected muscles from myositis patients, as well as tumor cells, indicating an immune response directed against cancer cells, cross-reacting with immature myoblasts in genetically predisposed individuals (Casciola-Rosen et al., 2005; Levine, 2006; Zampieri et al., 2010).

## 5. Cancer chronopathology

The temporal relationship between myopathy and cancer can widely vary. Malignancy may occur following the IIM diagnosis, be concurrently detected, or develop before. Despite this heterogeneous presentation, what is known is that cancer is usually recognized within 2-3 years of diagnosis of IIM, with most cases within 12 months.

## 6. Clinical, laboratory and pathological features

Older age, male sex, severe skin manifestations, such as cutaneous necrosis, distal muscle involvement, as well as dysphagia or diaphragmatic involvement are more frequent among patients with CAM. Specific capillaroscopic patterns and refractory or recurrent disease have also been related to this association (Andras et al., 2008; Chen et al., 2001; Fardet et al., 2009; Selva-O'Callaghan et al., 2010; Selva-O'Callaghan et al., 2002). Contrary to classical thought, case series suggest that cancer can also be present in the antisynthetase syndrome, indicating that the presence of antisynthetase antibodies does not rule out the CAM diagnosis (Buchbinder et al., 2001; Dugar et al., 2010; Legault et al., 2008; Mileti et al., 2009).

Among the laboratory parameters, the role of raised creatine kinase is controversial. It can be normal or slightly elevated, but highly elevations in CAM have been reported. Low levels of complement factor 4 have been published as a risk factor to occult cancer, whereas low baseline lymphocyte count and the presence of antinuclear antibodies have been reported as a protective features (Andras et al., 2008; Fardet et al., 2009).

Although no definite pathological features have been reported in CAM, the presence of a necrotizing myopathy, type of myopathy with severe necrosis with almost complete absence of inflammation (Amato & Barohn 2009; Dalakas 2011; Wegener et al., 2010), a higher number of fibers with internally located nuclei (Zampieri et al., 2010), and the identification of the neural cell adhesion molecules (Jensen & Berthold 2007; Zampieri et al., 2010) has been associated with cancer.

## 7. Screening approach

There is no doubt that an individually tailored screening for cancer in IIM patients is recommended according to age, sex, ethnicity, and subset of IIM, although, to date, there are no evidence-based recommendations. Moreover, continued surveillance is needed during the follow-up since cancer risk remains elevated for years after the diagnosis of IIM.



7.1 Standard work-up

An advisable approach include a careful history-taking and physical examination, blood tests with full blood count, erythrocyte sedimentation rate, routine biochemistry, chest RX, urinary cytology, fecal occult test, whole-body computed tomography scanning, and mammography, gynaecological examination, and pelvic ultrasonography in female patients, as well as prostate examination in men.

7.2 Immunoserological testing

Autoantibodies, including myositis-associated (MAA) and myositis-specific (MSA), are found in about 40% of patients with IIM. MAA include PM-Scl, Ku, snRNP, Ro60/SSA, Ro52, and La/SSB. MSA antibodies are highly specific for IIM, defining clinical and immunogenetics subsets of patients that may show different response to therapy and prognosis (Danko et al., 2009, 21; Love et al., 1991, 70; Rider & Miller, 2011), such as antisynthetases, anti-signal recognition particle (SRP), anti-Mi-2, and recently, anti-155/140. Classically, a negative association between the presence of antisynthetase antibodies was accepted, but, in recent years, scarce cases and small series of patients with antisynthetase syndrome and cancer have been published (Dugar et al., 2010; Legault et al., 2008; Miletì et al., 2009). Cancer relevance of anti-Mi-2 antibodies is unknown since only two studies have explored this issue with opposite results (Hengstman et al., 2006; O'Hanlon et al., 2006). Anti p155, autoantibody against a 155kDa protein identified as transcriptional intermediary factor 1- $\gamma$  (TIF1- $\gamma$ ), was first defined by Targoff in 2006 (Targoff et al., 2006) as an autoantibody associated with DM and CAM. The association between antip155 and malignancy has subsequently been confirmed by other investigators, reinforcing this link (Table 5) (Chinoy et al., 2009, 21; Fujikawa et al., 2009, 38; Gunawardena et al., 2008, 47; Kaji et al., 2007; Trallero-Araguas et al., 2010). The interest of antip155 autoantibody lies in its high negative predictive value or, in other words, its capacity to reasonable rule out the presence of occult cancer in patients with DM. An unpublished meta-analysis of the reported studies on this subject performed by the authors (Selva-O'Callaghan et al., 2010) to determine the overall accuracy of this autoantibody in DM reveals a specificity of 89% [95% CI 85-93] and sensitivity of 70% [95% CI 56-82], with a negative predictive value of 93% and a diagnostic odds ratio of 18 [95% 8-40], this means a 18-fold higher risk of cancer in patients with positive testing to p155.

N	CAM (Ab)*	No CAM (Ab)**	NPV	PPV	Reference
45	6 (6)	39 (8)	100	42,9	Targoff et al.
20	3 (3)	17 (3)	100	50	Gunawardena et al.
52	10 (5)	42 (2)	88,9	71,4	Kaji et al.
103	15 (8)	88 (11)	91,6	42,1	Chinoy et al.
30	5 (5)	25 (0)	100	100	Fujikawa et al.
65	14 (10)	51 (5)	92	66,7	Trallero-Araguás et al.

Ab, antibody; CAM, cancer-associated myositis; N, number of patients; NPV, negative predictive value; PPV, positive predictive value.  
\*Number of patients with CAM (number of those who are antibody-positive).  
\*\*Number of patients without CAM (number of those who are antibody-positive).

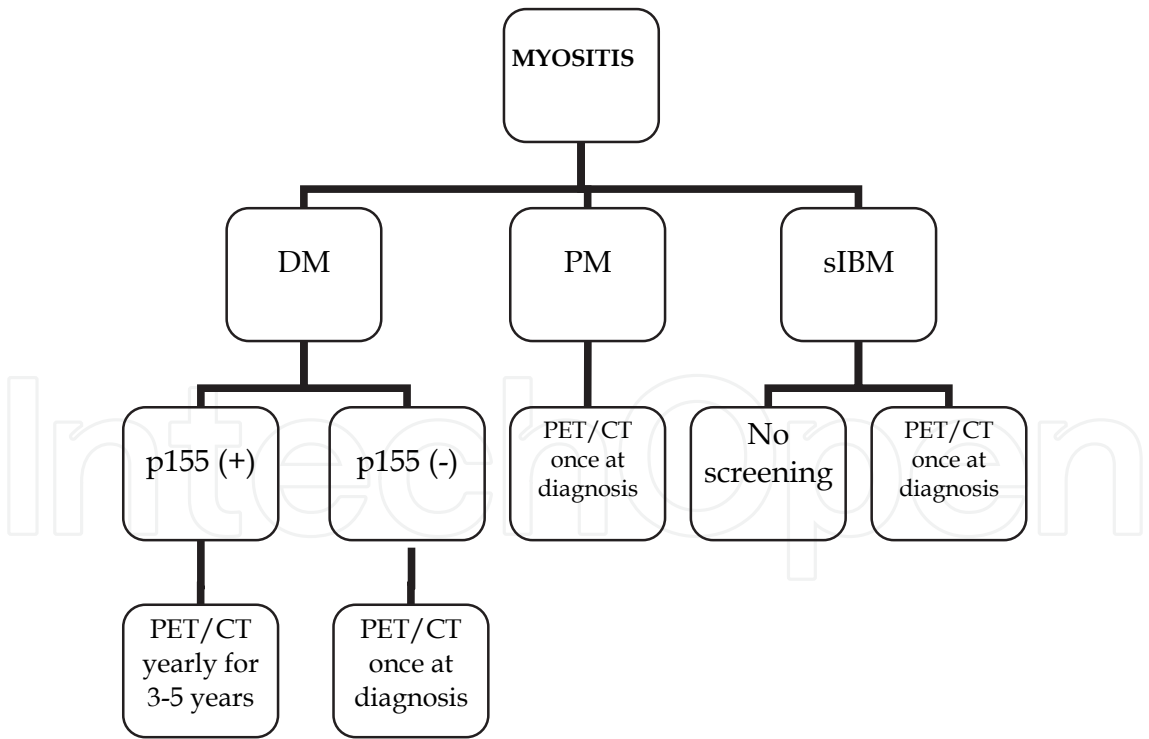
Table 5. Antip155 and CAM in DM (Selva-O'Callaghan et al., 2010).

7.3 Positron emission tomography

Positron emission tomography (PET) using [<sup>18</sup>F] fluorodeoxyglucose (FDG), and more recently, combined FDG-PET/computed tomography (FDG-PET/CT), is one of the most sensitive imaging techniques to diagnose malignant disorders, successfully used in other paraneoplastic conditions (Hadjivassiliou et al., 2009; Patel et al., 2008). Our group performed a multicenter, prospective study including 55 consecutive DM/PM patients, diagnosed over a three-year period, to compare conventional cancer screening as mentioned above, with whole-body FDG-PET/CT (Selva-O'Callaghan et al., 2010). A sensitivity and specificity of both approaches were similar in excluding an occult malignancy, as well as false-positive and false-negative results; furthermore, a combination of two methods did not significantly increase the predictive value. From these results we suggest that FDG-PET/CT may be a good alternative to broad conventional malignancy screening, with the added advantage that a single imaging technique is more convenient for both the patient and the physician.

8. Clinical practice

Given the mentioned results of immunological (antip155 antibodies) and imaging (FDG-PET/CT) tests, we propose a reasonable approach for ruling out occult cancer in myositis (Fig.1) (Selva-O'Callaghan et al., 2010).



DM: dermatomyositis; PM: polymyositis; sIBM: sporadic inclusion body myositis, PET: positron emission tomography; CT: computed tomography.

Fig. 1. Algorithm for diagnosis of occult cancer in inflammatory myopathies (Selva-O'Callaghan et al., 2010).

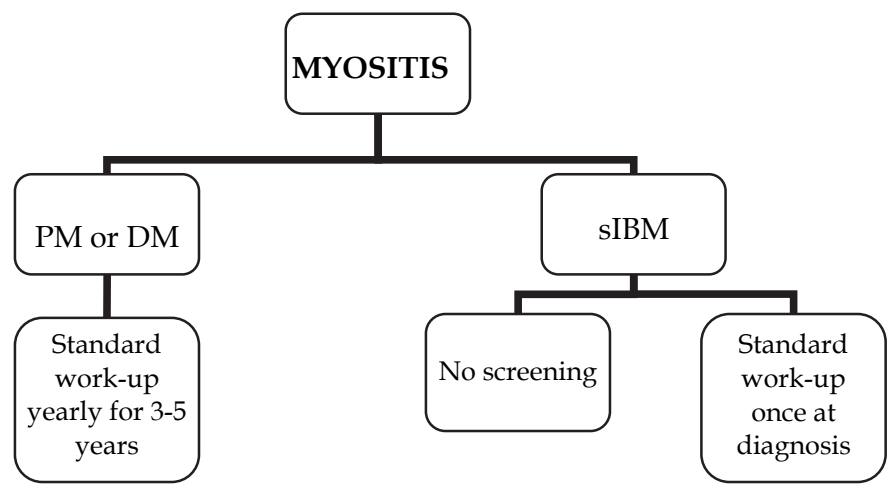


After unequivocal diagnosis of IIM (especially in PM), a careful history-taking and physical examination, and standard laboratory testing should be performed in all patients.

- In IBM patients, given that the risk of cancer is extremely low, no screening or a single FDG-PET/CT is recommended.
- In PM patients, a population with moderate risk, yearly FDG-PET/CT for 3-5 years would be reasonable. Antip155 test is not useful because it is rarely present in this IIM subset.
- In DM patients, we recommend an initial antip155 determination. When the test is negative, a single FDG-PET/CT would be enough to preclude malignancy. However, in patients with DM and positive antip155 test, yearly FDG-PET/CT for, at least, 3-5 years is warranted.

Considering that test for detecting antip155 antibodies and FDG-PET/CT are available at only a few hospitals, as well as the high cost of the imaging technique, we propose a more straightforward alternative guideline to rule out cancer in myositis patients (Fig.2):

- In IBM patients, no screening or a single standard work-up (see above).
- In PM patients, yearly standard work-up for 3-5 years.
- In DM patients, yearly standard work-up for 3-5 years.



DM: dermatomyositis; PM: polymyositis; sIBM: sporadic inclusion body myositis.

Fig. 2. Alternative algorithm for diagnosis of occult cancer in inflammatory myopathies.

9. References

Airio, A., E. Pukkala, and H. Isomaki. 1995. Elevated cancer incidence in patients with dermatomyositis: a population based study. *J.Rheumatol.* 22, no. 7:1300-1303.

Albert, M. L. and R. B. Darnell. 2004. Paraneoplastic neurological degenerations: keys to tumour immunity. *Nat.Rev.Cancer.* 4, no. 1:36-44.

Amato, A. A. and R. J. Barohn. 2009. Evaluation and treatment of inflammatory myopathies. *J.Neurol.Neurosurg.Psychiatry.* 80, no. 10:1060-1068.

Andras, C., A. Ponyi, T. Constantin, Z. Csiki, E. Szekanecz, P. Szodoray, and K. Danko. 2008. Dermatomyositis and polymyositis associated with malignancy: a 21-year retrospective study. *J.Rheumatol.* 35, no. 3:438-444.


- Antiochos, B. B., L. A. Brown, Z. Li, T. D. Tosteson, R. L. Wortmann, and W. F. Rigby. 2009. Malignancy is associated with dermatomyositis but not polymyositis in Northern New England, USA. *J.Rheumatol.* 36, no. 12:2704-2710.
- Barnes, B. E. and B. Mawr. 1976. Dermatomyositis and malignancy. A review of the literature. *Ann.Intern.Med.* 84, no. 1:68-76.
- Bohan, A. and J. B. Peter. 1975. Polymyositis and dermatomyositis (first of two parts). *N.Engl.J.Med.* 292, no. 7:344-347.
- Braik, T., A. T. Evans, M. Telfer, and S. McDunn. 2010. Paraneoplastic neurological syndromes: unusual presentations of cancer. A practical review. *Am.J.Med.Sci.* 340, no. 4:301-308.
- Buchbinder, R., A. Forbes, S. Hall, X. Dennett, and G. Giles. 2001. Incidence of malignant disease in biopsy-proven inflammatory myopathy. A population-based cohort study. *Ann.Intern.Med.* 134, no. 12:1087-1095.
- Casciola-Rosen, L., K. Nagaraju, P. Plotz, K. Wang, S. Levine, E. Gabrielson, A. Corse, and A. Rosen. 2005. Enhanced autoantigen expression in regenerating muscle cells in idiopathic inflammatory myopathy. *J.Exp.Med.* 201, no. 4:591-601.
- Chen, Y. J., C. Y. Wu, and J. L. Shen. 2001. Predicting factors of malignancy in dermatomyositis and polymyositis: a case-control study. *Br.J.Dermatol.* 144, no. 4:825-831.
- Chinoy, H., J. A. Lamb, W. E. Ollier, and R. G. Cooper. 2009. An update on the immunogenetics of idiopathic inflammatory myopathies: major histocompatibility complex and beyond. *Curr.Opin.Rheumatol.* 21, no. 6:588-593.
- Chow, W. H., G. Gridley, L. Møller, J. K. McLaughlin, J. H. Olsen, and J. F. Fraumeni, Jr. 1995. Cancer risk following polymyositis and dermatomyositis: a nationwide cohort study in Denmark. *Cancer Causes Control.* 6, no. 1:9-13.
- Cox, S., V. Limaye, C. Hill, P. Blumbergs, and P. Roberts-Thomson. 2010. Idiopathic inflammatory myopathies: diagnostic criteria, classification and epidemiological features. *Int.J.Rheum.Dis.* 13, no. 2:117-124.
- Dalakas, M. C. 2010. Immunotherapy of myositis: issues, concerns and future prospects. *Nat.Rev.Rheumatol.* 6, no. 3:129-137.
- Dalakas, 2011. Review: An update on inflammatory and autoimmune myopathies. *Neuropathol.Appl.Neurobiol.* 37, no. 3:226-242.
- Dalakas, M. C. and R. Hohlfeld. 2003. Polymyositis and dermatomyositis. *Lancet.* 362, no. 9388:971-982.
- Danko, K., A. Ponyi, A. P. Molnar, C. Andras, and T. Constantin. 2009. Paraneoplastic myopathy. *Curr.Opin.Rheumatol.* 21, no. 6:594-598.
- Didelot, A. and J. Honnorat. 2009. Update on paraneoplastic neurological syndromes. *Curr.Opin.Oncol.* 21, no. 6:566-572.
- Dimachkie, M. M. 2011. Idiopathic inflammatory myopathies. *J.Neuroimmunol.* 231, no. 1-2:32-42.
- Dugar, M., S. Cox, V. Limaye, P. Blumbergs, and P. J. Roberts-Thomson. 2010. Clinical heterogeneity and prognostic features of South Australian patients with anti-synthetase autoantibodies. *Intern.Med.J.*
- Fardet, L., A. Dupuy, M. Gain, A. Kettaneh, P. Cherin, H. Bachelez, L. Dubertret et al. 2009. Factors associated with underlying malignancy in a retrospective cohort of 121 patients with dermatomyositis. *Medicine (Baltimore).* 88, no. 2:91-97.

- Fujikawa, K., A. Kawakami, K. Kaji, M. Fujimoto, S. Kawashiri, N. Iwamoto, T. Aramaki et al. 2009. Association of distinct clinical subsets with myositis-specific autoantibodies towards anti-155/140-kDa polypeptides, anti-140-kDa polypeptides, and anti-aminoacyl tRNA synthetases in Japanese patients with dermatomyositis: a single-centre, cross-sectional study. *Scand.J.Rheumatol.* 38, no. 4:263-267.
- Furneau, H. M., M. K. Rosenblum, J. Dalmau, E. Wong, P. Woodruff, F. Graus, and J. B. Posner. 1990. Selective expression of Purkinje-cell antigens in tumor tissue from patients with paraneoplastic cerebellar degeneration. *N.Engl.J.Med.* 322, no. 26:1844-1851.
- Graus, F. and J. Dalmau. 2007. Paraneoplastic neurological syndromes: diagnosis and treatment. *Curr.Opin.Neurol.* 20, no. 6:732-737.
- Graus, F., J. Y. Delattre, J. C. Antoine, J. Dalmau, B. Giometto, W. Grisold, J. Honnorat et al. 2004. Recommended diagnostic criteria for paraneoplastic neurological syndromes. *J.Neurol.Neurosurg.Psychiatry.* 75, no. 8:1135-1140.
- Graus, F., A. Saiz, and J. Dalmau. 2010. Antibodies and neuronal autoimmune disorders of the CNS. *J.Neurol.* 257, no. 4:509-517.
- Gunawardena, H., L. R. Wedderburn, J. North, Z. Betteridge, J. Dunphy, H. Chinoy, J. E. Davidson, R. G. Cooper, and N. J. McHugh. 2008. Clinical associations of autoantibodies to a p155/140 kDa doublet protein in juvenile dermatomyositis. *Rheumatology.(Oxford).* 47, no. 3:324-328.
- Hadjivassiliou, M., S. J. Alder, E. J. Van Beek, M. B. Hanney, E. Lorenz, D. G. Rao, B. Sharrack, and W. B. Tindale. 2009. PET scan in clinically suspected paraneoplastic neurological syndromes: a 6-year prospective study in a regional neuroscience unit. *Acta Neurol.Scand.* 119, no. 3:186-193.
- Hengstman, G. J., W. T. Vree Egberts, H. P. Seelig, I. E. Lundberg, H. M. Moutsopoulos, A. Doria, M. Mosca et al. 2006. Clinical characteristics of patients with myositis and autoantibodies to different fragments of the Mi-2 beta antigen. *Ann.Rheum.Dis.* 65, no. 2:242-245.
- Hill, C. L., Y. Zhang, B. Sigurgeirsson, E. Pukkala, L. Mellemkjaer, A. Airio, S. R. Evans, and D. T. Felson. 2001. Frequency of specific cancer types in dermatomyositis and polymyositis: a population-based study. *Lancet.* 357, no. 9250:96-100.
- Honorat, J. and J. C. Antoine. 2007. Paraneoplastic neurological syndromes. *Orphanet.J.Rare.Dis.* 2:22.:22.
- Huang, Y. L., Y. J. Chen, M. W. Lin, C. Y. Wu, P. C. Liu, T. J. Chen, Y. C. Chen et al. 2009. Malignancies associated with dermatomyositis and polymyositis in Taiwan: a nationwide population-based study. *Br.J.Dermatol.* 161, no. 4:854-860.
- Jensen, M. and F. Berthold. 2007. Targeting the neural cell adhesion molecule in cancer. *Cancer Lett.* 258, no. 1:9-21.
- Kaji, K., M. Fujimoto, M. Hasegawa, M. Kondo, Y. Saito, K. Komura, T. Matsushita et al. 2007. Identification of a novel autoantibody reactive with 155 and 140 kDa nuclear proteins in patients with dermatomyositis: an association with malignancy. *Rheumatology.(Oxford).* 46, no. 1:25-28.
- Kankeleit, H. 1916. Über primäre nichteitrige polymyositis. *Dtschch.Arch.Klin.Med* 120:335-349.

- Legault, D., J. McDermott, A. M. Crous-Tsanaclis, and G. Boire. 2008. Cancer-associated myositis in the presence of anti-Jo1 autoantibodies and the antisynthetase syndrome. *J.Rheumatol.* 35, no. 1:169-171.
- Levine, S. M. 2006. Cancer and myositis: new insights into an old association. *Curr.Opin.Rheumatol.* 18, no. 6:620-624.
- Love, L. A., R. L. Leff, D. D. Fraser, I. N. Targoff, M. Dalakas, P. H. Plotz, and F. W. Miller. 1991. A new approach to the classification of idiopathic inflammatory myopathy: myositis-specific autoantibodies define useful homogeneous patient groups. *Medicine (Baltimore)*. 70, no. 6:360-374.
- Madan, V., H. Chinoy, C. E. Griffiths, and R. G. Cooper. 2009. Defining cancer risk in dermatomyositis. Part II. Assessing diagnostic usefulness of myositis serology. *Clin.Exp.Dermatol.* 34, no. 5:561-565.
- Mann, H. F., J. Vencovsky, and I. E. Lundberg. 2010. Treatment-resistant inflammatory myopathy. *Best.Pract.Res.Clin.Rheumatol.* 24, no. 3:427-440.
- Mastaglia, F. L. and B. A. Phillips. 2002. Idiopathic inflammatory myopathies: epidemiology, classification, and diagnostic criteria. *Rheum.Dis.Clin.North Am.* 28, no. 4:723-741.
- Mileti, L. M., M. E. Strek, T. B. Niewold, J. J. Curran, and N. J. Sweiss. 2009. Clinical characteristics of patients with anti-Jo-1 antibodies: a single center experience. *J.Clin.Rheumatol.* 15, no. 5:254-255.
- O'Hanlon, T. P., L. G. Rider, G. Mamyrova, I. N. Targoff, F. C. Arnett, J. D. Reveille, M. Carrington et al. 2006. HLA polymorphisms in African Americans with idiopathic inflammatory myopathy: allelic profiles distinguish patients with different clinical phenotypes and myositis autoantibodies. *Arthritis Rheum.* 54, no. 11:3670-3681.
- Oddis, C. V., C. G. Conte, V. D. Steen, and T. A. Medsger, Jr. 1990. Incidence of polymyositis-dermatomyositis: a 20-year study of hospital diagnosed cases in Allegheny County, PA 1963-1982. *J.Rheumatol.* 17, no. 10:1329-1334.
- Patel, R. R., R. M. Subramaniam, J. N. Mandrekar, J. E. Hammack, V. J. Lowe, and J. R. Jett. 2008. Occult malignancy in patients with suspected paraneoplastic neurologic syndromes: value of positron emission tomography in diagnosis. *Mayo Clin.Proc.* 83, no. 8:917-922.
- Prieto, S. and J. M. Grau. 2010. The geoepidemiology of autoimmune muscle disease. *Autoimmun.Rev.* 9, no. 5:A330-A334.
- Rider, L. G. and F. W. Miller. 2011. Deciphering the clinical presentations, pathogenesis, and treatment of the idiopathic inflammatory myopathies. *JAMA.* 305, no. 2:183-190.
- Selva-O'Callaghan, A., V. Fonollosa-Pla, E. Trallero-Araguas, X. Martinez-Gomez, C. P. Simeon-Aznar, M. Labrador-Horrillo, and M. Vilardell-Tarres. 2010. Nailfold capillary microscopy in adults with inflammatory myopathy. *Semin.Arthritis Rheum.* 39, no. 5:398-404.
- Selva-O'Callaghan, A., J. M. Grau, C. Gamez-Cenzano, A. Vidaller-Palacin, X. Martinez-Gomez, E. Trallero-Araguas, E. Buendia-Navarro, and M. Vilardell-Tarres. 2010. Conventional cancer screening versus PET/CT in dermatomyositis/polymyositis. *Am.J.Med.* 123, no. 6:558-562.
- Selva-O'Callaghan, A., T. Mijares-Boeckh-Behrens, R. Solans-Laue, M. Labrador-Horrillo, E. Romero-Merino, J. M. Sopena-Sisquella, and M. Vilardell-Tarres. 2002. The neural network as a predictor of cancer in patients with inflammatory myopathies. *Arthritis Rheum.* 46, no. 9:2547-2548.

- Selva-O'Callaghan, A., E. Trallero-Araguas, J. M. Grau-Junyent, and M. Labrador-Horrillo. 2010. Malignancy and myositis: novel autoantibodies and new insights. *Curr.Opin.Rheumatol.* 22, no. 6:627-632.
- Sigurgeirsson, B., B. Lindelof, O. Edhag, and E. Allander. 1992. Risk of cancer in patients with dermatomyositis or polymyositis. A population-based study. *N.Engl.J.Med.* 326, no. 6:363-367.
- Stertz, G. 1916. Polymyositis. *Berl.Klin.Wochenschr.* 53:489.
- Stockton, D., V. R. Doherty, and D. H. Brewster. 2001. Risk of cancer in patients with dermatomyositis or polymyositis, and follow-up implications: a Scottish population-based cohort study. *Br.J.Cancer.* 85, no. 1:41-45.
- Targoff, I. N. 2008. Autoantibodies and their significance in myositis. *Curr.Rheumatol.Rep.* 10, no. 4:333-340.
- Targoff, I. N., G. Mamyrova, E. P. Trieu, O. Perurena, B. Koneru, T. P. O'Hanlon, F. W. Miller, and L. G. Rider. 2006. A novel autoantibody to a 155-kd protein is associated with dermatomyositis. *Arthritis Rheum.* 54, no. 11:3682-3689.
- Trallero-Araguas, E., M. Labrador-Horrillo, A. Selva-O'Callaghan, M. A. Martinez, X. Martinez-Gomez, E. Palou, J. L. Rodriguez-Sanchez, and M. Vilardell-Tarres. 2010. Cancer-associated myositis and anti-p155 autoantibody in a series of 85 patients with idiopathic inflammatory myopathy. *Medicine (Baltimore).* 89, no. 1:47-52.
- Wakata, N., T. Kurihara, E. Saito, and M. Kinoshita. 2002. Polymyositis and dermatomyositis associated with malignancy: a 30-year retrospective study. *Int.J.Dermatol.* 41, no. 11:729-734.
- Wegener, S., J. Bremer, P. Komminoth, H. H. Jung, and M. Weller. 2010. Paraneoplastic Necrotizing Myopathy with a Mild Inflammatory Component: A Case Report and Review of the Literature. *Case.Rep.Oncol.* 3, no. 1:88-92.
- Williams, R. C., Jr. 1959. Dermatomyositis and malignancy: a review of the literature. *Ann.Intern.Med.* 50, no. 5:1174-1181.
- Wilson, F. C., S. R. Ytterberg, J. L. St Sauver, and A. M. Reed. 2008. Epidemiology of sporadic inclusion body myositis and polymyositis in Olmsted County, Minnesota. *J.Rheumatol.* 35, no. 3:445-447.
- Zampieri, S., M. Valente, N. Adami, D. Biral, A. Ghirardello, M. E. Rampudda, M. Vecchiato et al. 2010. Polymyositis, dermatomyositis and malignancy: a further intriguing link. *Autoimmun.Rev.* 9, no. 6:449-453.
- Zantos, D., Y. Zhang, and D. Felson. 1994. The overall and temporal association of cancer with polymyositis and dermatomyositis. *J.Rheumatol.* 21, no. 10:1855-1859.





## **Idiopathic Inflammatory Myopathies - Recent Developments**

Edited by Prof. Jan Tore Gran

ISBN 978-953-307-694-2

Hard cover, 212 pages

**Publisher** InTech

**Published online** 15, September, 2011

**Published in print edition** September, 2011

The term "myositis" covers a variety of disorders often designated "idiopathic inflammatory myopathies". Although they are rather rare compared to other rheumatic diseases, they often cause severe disability and not infrequently increased mortality. The additional involvement of important internal organs such as the heart and lungs, is not uncommon. Thus, there is a great need for a better understanding of the etiopathogenesis of myositis, which may lead to improved treatment and care for these patients. Major advances regarding research and medical treatment have been made during recent years. Of particular importance is the discovery of the Myositis specific autoantibodies, linking immunological and pathological profiles to distinct clinical disease entities. A wide range of aspects of myopathies is covered in the book presented by highly qualified authors, all internationally known for their expertise on inflammatory muscle diseases. The book covers diagnostic, pathological, immunological and therapeutic aspects of myositis.

### **How to reference**

In order to correctly reference this scholarly work, feel free to copy and paste the following:

Sergio Prieto-González, Vladimir Lazo, Ernesto Trallero-Araguás, Albert Selva-O'Callaghan and Josep M Grau (2011). Myositis and Cancer, Idiopathic Inflammatory Myopathies - Recent Developments, Prof. Jan Tore Gran (Ed.), ISBN: 978-953-307-694-2, InTech, Available from: <http://www.intechopen.com/books/idiopathic-inflammatory-myopathies-recent-developments/myositis-and-cancer>

**INTECH**  
open science | open minds

### **InTech Europe**

University Campus STeP Ri  
Slavka Krautzeka 83/A  
51000 Rijeka, Croatia  
Phone: +385 (51) 770 447  
Fax: +385 (51) 686 166  
[www.intechopen.com](http://www.intechopen.com)

### **InTech China**

Unit 405, Office Block, Hotel Equatorial Shanghai  
No.65, Yan An Road (West), Shanghai, 200040, China  
中国上海市延安西路65号上海国际贵都大饭店办公楼405单元  
Phone: +86-21-62489820  
Fax: +86-21-62489821



© 2011 The Author(s). Licensee IntechOpen. This chapter is distributed under the terms of the [Creative Commons Attribution-NonCommercial-ShareAlike-3.0 License](https://creativecommons.org/licenses/by-nc-sa/3.0/), which permits use, distribution and reproduction for non-commercial purposes, provided the original is properly cited and derivative works building on this content are distributed under the same license.

IntechOpen

IntechOpen