

We are IntechOpen, the world's leading publisher of Open Access books Built by scientists, for scientists

6,900

Open access books available

185,000

International authors and editors

200M

Downloads

Our authors are among the

154

Countries delivered to

TOP 1%

most cited scientists

12.2%

Contributors from top 500 universities



WEB OF SCIENCE™

Selection of our books indexed in the Book Citation Index
in Web of Science™ Core Collection (BKCI)

Interested in publishing with us?
Contact book.department@intechopen.com

Numbers displayed above are based on latest data collected.
For more information visit www.intechopen.com



Interstitial Lung Disease Associated with Clinically Amyopathic Dermatomyositis

Toshinori Takada¹, Eiichi Suzuki² and Ichiei Narita¹

¹*Division of Respiratory Medicine, Graduate School of Medical and Dental Sciences, Niigata University*

²*Department of General Medicine, Niigata University Medical and Dental Hospital
Japan*

1. Introduction

Polymyositis and dermatomyositis (PM-DM) are forms of idiopathic inflammatory myositis (Bohan & Peter, 1975, Dalakas & Hohlfeld, 2003). The diagnosis of DM is definite if the myopathy is accompanied by the characteristic rash and histopathology. If patients with DM has the typical rashes but little (hypomyopathic DM) or no (amyopathic DM) evidence of myositis for 6 months or longer, the condition is termed "clinically amyopathic DM" (Euwer & Sontheimer, 1991, Gerami et al., 2006). Although muscle strength is apparently normal, many patients with clinically amyopathic dermatomyositis have some evidence of muscle inflammation upon testing. Some clinically amyopathic dermatomyositis patients also have been observed to develop overt proximal muscle weakness years after onset of their DM skin disease. Among patients with DM or PM, interstitial lung disease is a major cause of morbidity and mortality (Fathi et al., 2008, Love et al., 1991, Marie et al., 2002). In particular, patients with clinically amyopathic dermatomyositis sometimes develop rapidly progressive interstitial lung disease that remains unresponsive to intensive immunosuppressive therapy (Mukae et al., 2009).

2. Polymyositis and dermatomyositis

2.1 Diagnostic criteria

Three sets of classification criteria have been developed for DM-PM. The original criteria formulated in 1975 by Bohan and Peter included the following features: symmetric proximal muscle weakness, characteristic electromyographic changes, elevation of serum levels of muscle-associated enzymes, evidence of chronic inflammation in muscle biopsy, and characteristic rashes of DM (Bohan & Peter, 1975). However, when these criteria were formulated, testing for myositis-specific autoantibodies was not available. In addition, inclusion body myositis was not recognized until the 1980s (Griggs et al., 1995). Thus, patients classified as DM or PM according to these criteria may have some other disorder. To address this problem, two alternative criteria have been suggested since 2004 (Hoogendijk et al., 2004, Troyanov et al., 2005). One criterion classifies patients according to a "clinicoserologic" approach relying on extensive testing for autoantibodies. Excluding inclusion body myositis, four categories of inflammatory myopathy were recognized: pure

PM, pure DM, overlap myositis, and cancer-associated myositis (Trojanov et al., 2005). The second criterion has nine categories based on clinical, histopathologic, and laboratory findings with autoantibody tests, which include amyopathic DM also called dermatomyositis sine myositis (Hoogendijk et al., 2004).

2.2 Clinically amyopathic dermatomyositis

Clinically amyopathic dermatomyositis is an umbrella designation used to refer to DM with no myositis (amyopathic DM) or DM with little myositis (hypomyopathic DM), i.e. clinically amyopathic DM = amyopathic DM + hypomyopathic DM. Patients with amyopathic DM have hallmark inflammatory skin changes of DM but no clinical evidence of proximal muscle weakness and no serum muscle enzyme abnormalities for 6 months or longer. If more extensive muscle testing is carried out, the results should be within normal limits. While, hypomyopathic DM is a condition of cutaneous DM and no clinical evidence of muscle weakness. Although muscle strength is apparently normal, patients with hypomyopathic DM have some evidence of muscle inflammation on laboratory (eg, muscle enzyme elevations), electrophysiologic, and/or radiologic evaluation. Hypomyopathic DM could also be classified into 2 groups according to degree of skeletal muscle involvement: no subjective muscle weakness but abnormalities detected by objective tests and subjective muscle weakness but no objective evidence of myopathy (el-Azhary & Pakzad, 2002). Some patients with clinically amyopathic dermatomyositis eventually develop overt proximal muscle weakness years after onset of their skin disease; however, muscle involvement may not be seen as long as six years after disease onset (Euwer & Sontheimer, 1991, Gerami et al., 2006, Stonecipher et al., 1993).

3. Interstitial lung disease associated with polymyositis and dermatomyositis

3.1 Clinical manifestations

Pulmonary involvement in PM-DM includes respiratory muscle weakness, aspiration pneumonia, infection, drug-induced pneumonia, and interstitial lung disease (Miller, 2004). Interstitial lung disease occurs approximately 40 percent of patients with PM-DM. It is increasingly recognized as a serious complication and a major cause of death in this disease (Douglas et al., 2001, Fathi et al., 2008, Marie et al., 2002). High-resolution computerized tomography in combination with pulmonary function tests provides sensitive tools to detect early signs of interstitial lung disease (Selva-O'Callaghan et al., 2005). The clinical presentation of interstitial lung disease includes progressive dyspnea on exertion, nonproductive cough, and basilar rales, and a rapidly progressive syndrome (Hamman-Rich) may also occur. A rapidly progressive interstitial lung disease characterized by diffuse alveolar damage (DAD) often causes fatal respiratory failure. According to the 2002 ATS/ERS consensus classification of IIPs (2002), several histologic patterns of interstitial lung disease are associated with PM-DM; nonspecific interstitial pneumonia (NSIP) is most often found and DAD, organizing pneumonia (OP), and usual interstitial pneumonia (UIP) are also present (Douglas et al., 2001, Kang et al., 2005, Marie et al., 2002, Tansey et al., 2004, Tazelaar et al., 1990).

3.2 Treatment of interstitial lung disease associated with polymyositis and dermatomyositis

Controlled trials on the effect of different treatments for interstitial lung disease in PM-DM have not been published. Thus, the optimal treatment program for the disease has not been

established. Available information on the efficacy of treatment is based on retrospective case collections or open trials.

3.2.1 Glucocorticoids

Prednisolone is considered the first-line drug for PM-DM patients with interstitial lung disease (Douglas et al., 2001, Grau et al., 1996, Hirakata & Nagai, 2000, Marie et al., 1998, Nawata et al., 1999, Oddis, 2000). It usually is started with 1 mg/kg/day or more for 4-6 weeks. Another option is to start treatment with intravenous methylprednisolone (1g/day for 3 days, if necessary repeated after 1-2 weeks) and to continue treatment with oral prednisolone. Prednisolone in the 1mg/kg/day range seems effective in suppressing the PM-DM within a few weeks in most patients, but the lung disease usually is slower to respond to therapy than is the myositis and may require treatment over several months. High doses of prednisolone may lead to serious steroid side-effects, therefore, prednisolone is gradually tapered with careful monitoring of creatine kinase, chest radiographs, and pulmonary function.

3.2.2 Immunosuppressive drugs

Although most patients respond to some degree, corticosteroid treatment as a single agent is often not sufficient to obtain improvement of interstitial lung disease. Furthermore, the high doses required over a long period are often associated with severe side-effects and the addition of an immunosuppressive drugs becomes necessary as steroid sparing agents. Selection of immunosuppressive drugs remains empirical and depends on personal experience and the relative efficacy/safety ratio (Dalakas, 1994, Oddis, 2002). Favorable outcome with immunosuppressive therapy in patients who failed to respond to steroids alone has been reported previously (Nawata et al., 1999, Shinohara et al., 1997). However, a second immunosuppressive agent is added without waiting for a response to glucocorticoid therapy or a failure of tapering (Takada et al., 2007), in particular for patients with clinically amyopathic dermatomyositis because of the high frequency of progressive interstitial lung disease.

Azathioprine (Douglas et al., 2001), or mycophenolate mofetil are often used and the comparative efficacy of these drugs is not known. Cyclophosphamide is an alternative if the patient has impending respiratory failure due to rapidly progressive interstitial lung disease with high dose glucocorticoids. Calcineurin inhibitors, cyclosporine and tacrolimus have been used in patients with inflammatory myopathy complicated by interstitial lung disease. In particular, cyclosporine has been reported to be effective to corticosteroid-resistant interstitial lung disease in PM-DM or clinically amyopathic dermatomyositis (Kameda et al., 2005, Miyake et al., 2002).

3.3 Prognostic factors associated with poor outcome of interstitial lung disease in polymyositis and dermatomyositis

Various parameters related to interstitial lung disease poor outcome in PM-DM were identified as follows: DM subtype, Hamman-Rich type presentation, initial FVC less than 60%, neutrophil alveolitis, histologic UIP, and features of clinically amyopathic dermatomyositis (Fujisawa et al., 2005, Kang et al., 2005, Marie et al., 2002). Schnabel et al. identified progressive disease, featuring ground-glass opacities on high resolution CT, and an inflammatory bronchoalveolar lavage (bronchoalveolar lavage) cell profile as indicators for intensive immunosuppressive therapy (Schnabel et al., 2003). Poor prognosis of patients

with UIP was confirmed in studies with lung histology (Marie et al., 2002, Tazelaar et al., 1990). NSIP observed in PM-DM patients means the better survival compared with patients with idiopathic pulmonary fibrosis (Douglas et al., 2001) and mortality is similar to that seen in idiopathic NSIP (Tansey et al., 2004). In interstitial lung disease with clinically amyopathic dermatomyositis, although the most common finding is NSIP (Suda et al., 2006), the interstitial lung disease often takes an aggressive course even when the radiological and histological features are consistent with NSIP (Miyazaki et al., 2005). Tiju et al. reported that digital infarcts with microangiopathy may be a useful indicator for early intervention in interstitial lung disease associated with DM (Tjiu et al., 2004).

4. Interstitial lung disease associated with clinically amyopathic dermatomyositis

Patients with clinically amyopathic dermatomyositis sometimes develop rapidly progressive interstitial lung disease. It has been reported predominantly in Asia, including Japan, Hong Kong, and Taiwan (Lee et al., 2002, Mukae et al., 2009) and is often resistant to intensive therapy including high dose corticosteroids and immunosuppressive agents, resulting in fatal respiratory failure.

4.1 A case with rapidly progressive interstitial lung disease in clinically amyopathic dermatomyositis

A 46-year-old Japanese woman was admitted to a hospital because of eruption on arms to shoulders, erythema and swelling of hand joint, and dry cough for four weeks. The patient was diagnosed as dermatomyositis because of characteristic skin lesions. Chest radiograph and computed tomography on admission showed slight interstitial lung disease (Fig1A, D). Her respiratory function deteriorated in two weeks with progression of infiltrative shadow in chest radiograph and consolidation in particular around bronchovascular bundle in computed tomography (Fig1B, E). The patient was given methylprednisolone 1000mg intravenously daily for three days (pulse treatment) and transferred to our hospital.

Blood gas analysis revealed PaO₂ 54.4 torr while she was breathing 3l/min oxygen by nasal plugs. Pulse treatment was followed by daily oral prednisolone 60 mg. Respiratory dysfunction became worse and finally fatal in two weeks after transfer in spite of repeated pulse treatment two more times (Fig1C). A second immunosuppressive agent was not added during hospitalization.

4.2 A case with interstitial lung disease in clinically amyopathic dermatomyositis successfully treated by corticosteroid and cyclosporin

A 31-year-old Japanese man developed bilateral hand erythema followed by fever (temperatures of more than 38°C) and hand and foot stiffness. The patient was admitted to a hospital suspected as dermatomyositis because of characteristic skin lesions. A chest radiograph and computed tomography on admission revealed reticular opacities in lower lobes (Fig2A, E). Interstitial lung disease progressed with remittent fever in three weeks. The patient was given methylprednisolone 1000mg intravenously daily for three days (pulse treatment) and transferred to our hospital.

On examination, the temperature was 38.1°C, the blood pressure 118/78 torr, the pulse 80 beats per minute, and the oxygen saturation 98% while he was breathing ambient air. The physical examination showed Gottron signs on fingers and fine crackles in bilateral back but

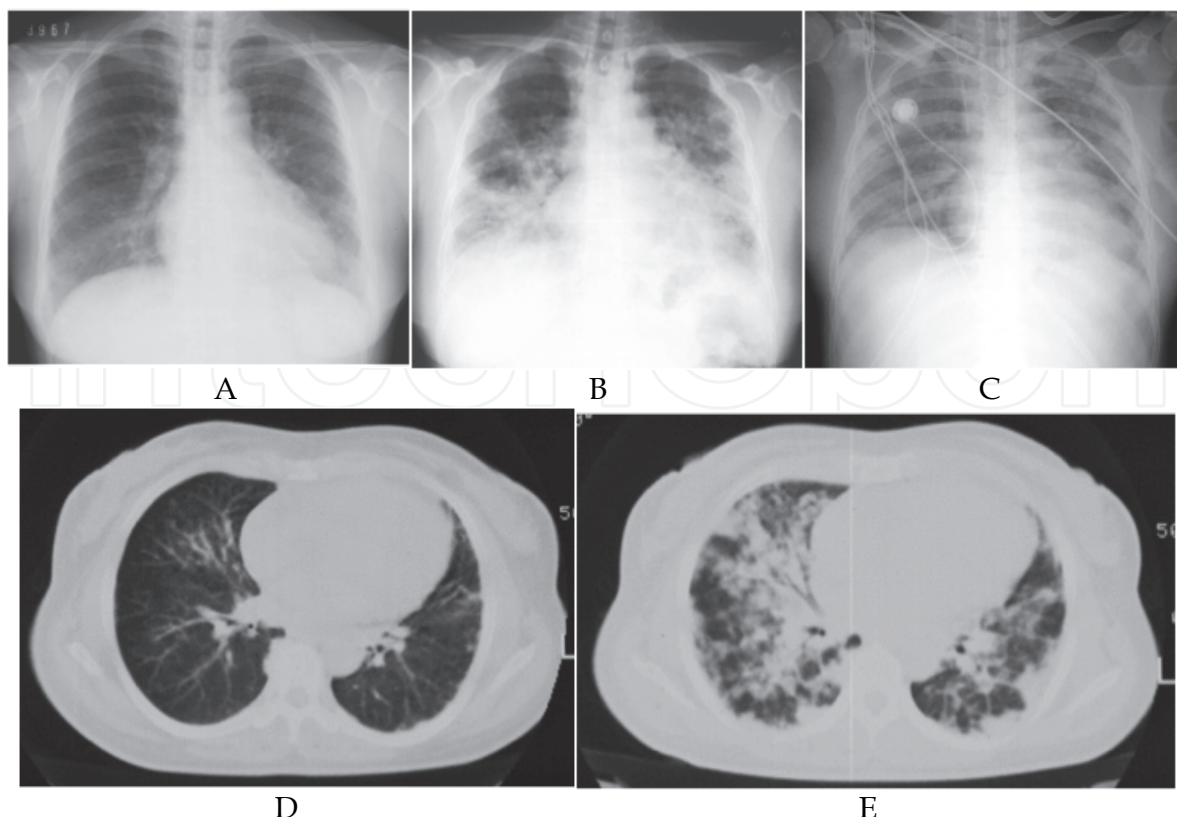


Fig. 1. Chest radiographs and computed tomography of a case with rapidly progressive interstitial lung disease associated with clinically amyopathic dermatomyositis. Very slight interstitial lung disease (A, D) deteriorated to be fatal in three months despite high dose corticosteroid treatment (B, C, E).

no muscle weakness. Interstitial lung disease deteriorated on his chest radiograph and computed tomography (Fig2B, F). The patient was diagnosed as clinically amyopathic dermatomyositis because of slight elevation of creatinin kinase (551 IU/L), mild myopathic change in electromyography, and skin diseases. Pulse treatment was repeated two more times with daily oral predonisone 60 mg and cyclosporine of maximum dose 5 mg/kg/day. Although pneumomediastinum developed during tapering of prednisolone (Fig2C, G), interstitial lung disease gradually ameliorated with only linear opacities left in the lower lobes (Fig2D, H).

4.3 A case with interstitial lung disease in clinically amyopathic dermatomyositis resistant to corticosteroid and cyclosporin

A 56-year-old Japanese woman developed finger erythema. The erythema extended to her eyelids and then body in three weeks. Being suspected as dermatomyositis, she was referred and admitted to the hospital. On examination, the temperature was 37.0°C, the blood pressure 100/70 torr, the pulse 89 beats per minute, and the oxygen saturation 94% while she was breathing ambient air. The physical examination showed heliotrope erythema on eyelids, Gottron signs on fingers, and slight fine crackles in right back but no muscle weakness. A chest radiograph and computed tomography on admission revealed consolidation with reticular opacities in lower lobes (Fig3A, D). The patient was diagnosed as clinically amyopathic dermatomyositis because of slight elevation of creatine kinase (149 IU/L), mild myopathic change in electromyography, and skin diseases.

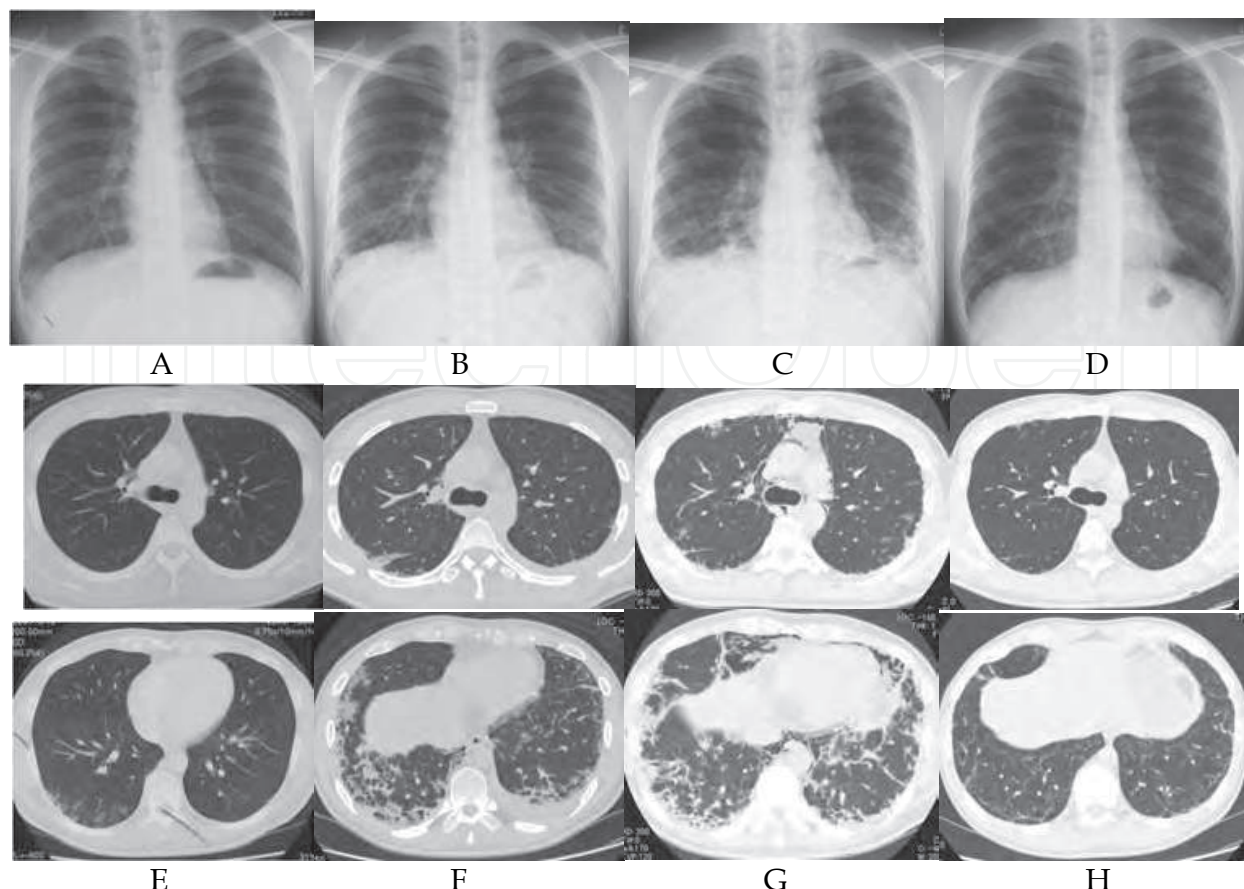


Fig. 2. Chest radiographs and computed tomography of a case with interstitial lung disease associated with clinically amyopathic dermatomyositis successfully treated by corticosteroid and cyclosporin. Interstitial lung disease progressed (A, B, E, F) with pneumomediastinum complicated (C, G), however, was finally improved (D, H).

The patient was given methylprednisolone 1000mg intravenously daily for three days (pulse treatment) followed by daily oral prednisolone 60 mg. Although respiratory functions with regard to AaDO₂ and consolidation in lower lobes improved by prednisolone 60 mg for a month, reticular and ground-glass opacities appeared and progressed in upper lobes with worsening of AaDO₂ when prednisolone was tapered to 50 mg/day (Fig3B, E). Cyclosporine of maximum dose 5 mg/kg/day and two more time pulse treatment were added with daily oral prednisolone 50 mg for another month. Interstitial lung disease gradually deteriorated in spite of the immunosuppressive therapy (Fig3C, F) and respiratory failure finally progressed to fatal in a week.

5. Characteristics of patients with interstitial lung disease in polymyositis-dermatomyositis resistant to prednisolone and cyclosporine

Cyclosporine is sometimes effective to Japanese patients with corticosteroid-resistant interstitial lung disease in PM-DM or clinically amyopathic dermatomyositis (Kameda et al., 2005, Miyake et al., 2002). However, the efficacy of cyclosporine remains limited and some patients still develop fatal respiratory failure. To clarify characteristics of fatal interstitial lung disease in PM-DM including clinically amyopathic dermatomyositis, we reviewed clinical records of PM-DM patients with interstitial lung disease.

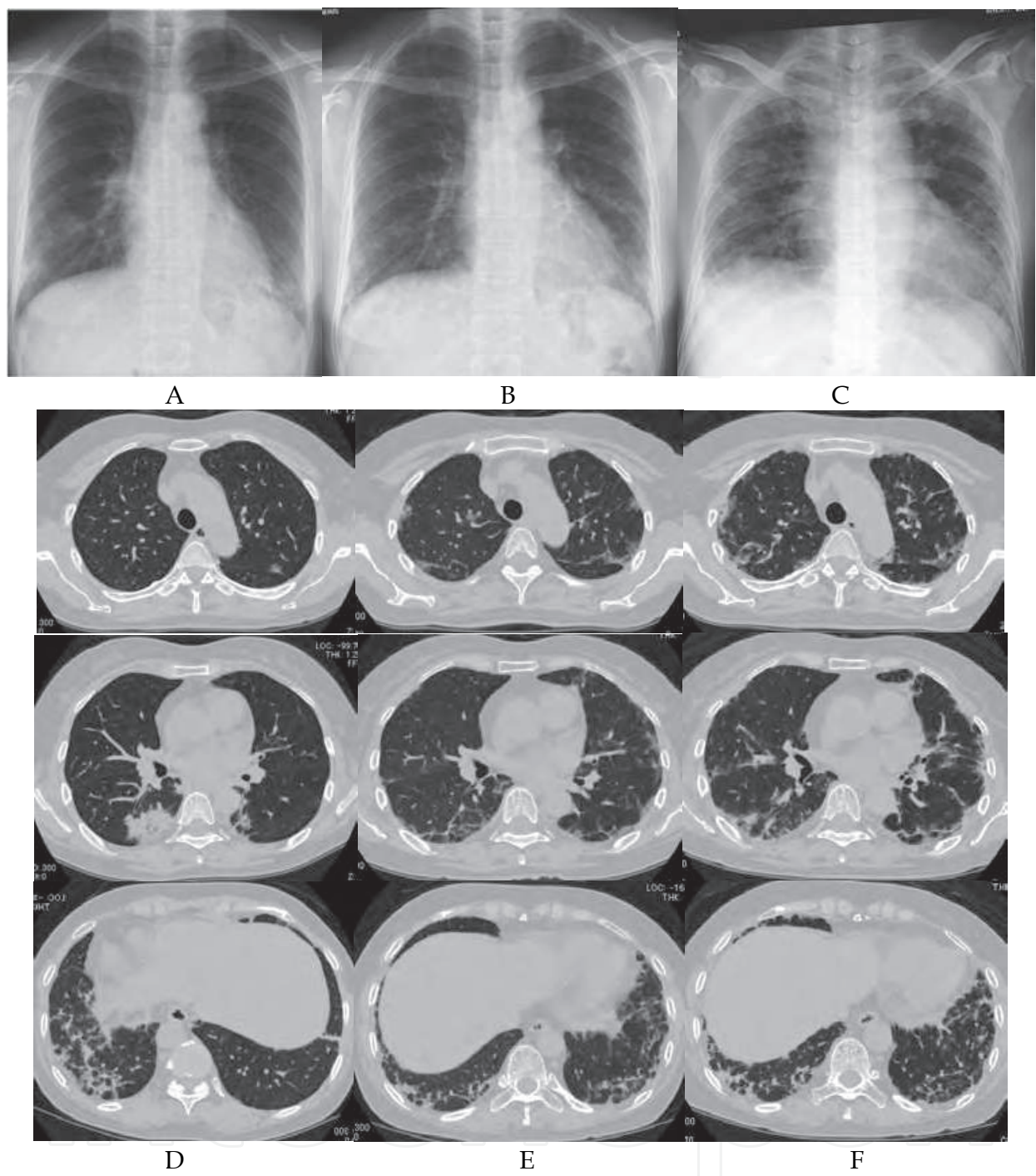


Fig. 3. Chest radiographs and computed tomography of a case with interstitial lung disease associated with clinically amyopathic dermatomyositis resistant to treatment of corticosteroid and cyclosporin. Consolidation in lower lobes was improved by corticosteroid (A, B, D, E), but reticular and ground-glass opacities appeared and progressed in upper lobes to be fatal in spite of addition of cyclosporin (C, F).

5.1 Study design

Consecutive 26 PM-DM patients with interstitial lung disease underwent initial treatment in Niigata University Medical and Dental Hospital from January 1997 to June 2006. Diagnosis

of PM-DM was made according to the criteria of Bohan and Peter (Bohan & Peter, 1975). intestinal lung disease was diagnosed based on the presence of clinical symptoms, respiratory functions, and high-resolution computed tomography of the chest. Diagnosis of clinically amyopathic dermatomyositis was confirmed based on modified Euwer’s criteria (Euwer & Sontheimer, 1993) as follows: 1) characteristic dermatological manifestations of classic DM, including a heliotrope rash and Gottron’s papules; 2) no muscle weakness; and 3) no increases in serum muscle enzymes during the observation period. All patients received oral prednisolone 1.0mg/kg/day for initial therapy. Corticosteroid pulse therapy (methyl prednisolone, 1000mg, 3days) was added when the worsening of respiratory function was observed under the treatment of 1.0mg/kg/day prednisolone. Effect of the treatment for intestinal lung disease was evaluated two weeks later by symptoms, blood gas analysis, chest X ray, and chest high resolution CT findings. We thought intestinal lung disease steroid-resistant when three of the above four findings were not improved and added cyclosporine to prednisolone keeping a trough level of 100 to 150ng/ml. Since 2002, cyclosporine dose has been increased to achieve a trough level of 300 ng/ml for up to 4 weeks to expect the maximal immunosuppressive effect without adverse effects. Five of 26 were excluded from this study because they had received cyclosporine before the evaluation of intestinal lung disease to have a sparing effect for high dose prednisolone. Finally 21 patients with intestinal lung disease associated with PM-DM were enrolled in this study. Medical records were reviewed to obtain clinical data including history, treatment, and laboratory findings.

5.2 Demographic data of patients

Characteristics of 21 patients are shown in Table 1. Thirteen patients (61.9%) was effectively treated by corticosteroids alone. Cyclosporine was added to the other eight patients because of deterioration of intestinal lung disease even under steroid therapy. Out of these 8 steroid-resistant cases, 4 patients (19.0%) improved by addition of cyclosporine, and the other 4 patients (19.0%) showed no response to cyclosporine resulting in fatal respiratory failure. Finally, 17 patients survived and four died of respiratory failure due to progression of intestinal lung disease. All of the dead patients were diagnosed as clinically amyopathic dermatomyositis.

	Steroid-effective cases	Steroid-resistant cases	
		Cyclosporine-effective	Cyclosporine-resistant
Number of cases	13 (61.9%)	4 (19.0%)	4 (19.0%)
Sex (M/F)	2/11	3/1	2/2
Age (mean±SD)	54.5±14.3	52.0±17.7	58.8±5.1
Diagnosis			
PM	0	1	0
DM	9	2	0
CADM	4	1	4

Abbreviations: PM, polymyositis; DM, dermatomyositis; CADM, clinically amyopathic dermatomyositis

Table 1. Demographic characteristics of PM-DM with intestinal lung disease patients.

5.3 Summary of treatment

Treatment in details is shown in Table 2. All the patients initially had 1mg/kg/day prednisolone. Steroid pulse therapy (methyl prednisolone 1000mg/day, three days) was given to 11 patients. Cyclosporine was added to 7 of 11 patients. Initial trough level of cyclosporine was usually maintained at 250 to 300 ng/ml to obtain maximal immunosuppressive effect.

	Steroid-effective cases (n=13)	Steroid-resistant cases	
		Cyclosporine-effective (n=4)	Cyclosporine-resistant (n=4)
Initial dose of PS (mg/ day, mean±SD)	46.2±11.2	60.0±0.0	57.5±5.0
Additional treatment			
m PSL pulse	4	0	0
cyclosporine	0	1	0
mPSL pulse, cyclosporine	0	3	4
cyclosporine trough level			
100~150ng/ml	NA	1	0
250~300ng/ml	NA	3	4

Abbreviations: PSL, prednisolone

Table 2. Treatment of PM-DM with intestinal lung disease patients.

	Steroid-effective cases (n=13)	Steroid-resistant cases	
		Cyclosporine-effective (n=4)	Cyclosporine-resistant (n=4)
WBC (/μl)	6292.3±1790.3	4 (19.0%)	4 (19.0%)
CRP (mg/ dl)	0.8±1.7	4.3±4.9*	1.7±1.8
CK (IU/L)	1013.4±1272.5	2192.8±3084.4	158.5±54.2
LDH (IU/L)	679.2±362.9	733.0±795.3	499.5±81.5
AST (IU/L)	53.1±35.2	106.3±105.9	188.7±202.3
ALT (IU/L)	38.4±28.5	65.0±48.0	157.8±203.8
TP (g/ dl)	6.8±0.6	6.5±0.4	6.7±0.4
Alb (g/ dl)	3.6±0.6	3.0±0.3	1 (25.0)
ANA positive (%)	9 (69.2)	3 (75.0)	1 (25.0)
Jo-1 positive (%)	2 (15.4)	2 (50.0)	1 (25.0)
KL-6 (U/ ml)	1127.8±454.1	769.3±570.9	797.0±180.5
BGA (torr, room air)			
PaO ₂	81.8±8.8	82.7±14.1	63.4±8.6*
PaCO ₂	41.5±3.8	36.2±4.1	37.1±1.2
AaDO ₂ (torr)	16.4±9.0	22.1±18.6	40.3±8.0*

*P<0.01 against steroid effective group.

Table 3. Comparison of laboratory data on admission.

5.4 Laboratory findings

Laboratory findings on admission are presented in Table 3. Serum CRP level of cyclosporine-effective group was higher than that of steroid-effective group. There were no significant differences in the levels of peripheral leukocyte count, serum CK, LDH, AST, ALT, total protein, albumin, and KL-6 among thee groups. PaO₂ on admission was significantly decreased with an increase of AaDO₂. in cyclosporine-resistant group. We often experience deterioration of interstitial lung disease associated with PM-DM when we perform laboratory, radiological, and neurological tests to make diagnosis of the disease. To evaluate progression of the disease during test period, we then compared changes in peripheral leukocyte count, serum CRP, CK, LDH, albumin, and AaDO₂ from admission to administration of prednisolone. In cyclosporine-effective group, the level of serum CRP, CK, LDH, and AaDO₂ significantly elevated during test period, while significant decrease of serum albumin and rapid progression of respiratory dysfunction indicated as AaDO₂ were observed in cyclosporine-resistant group compared with steroid-effective group (Table 4).

	Steroid-effective cases (n=13)	Steroid-resistant cases	
		Cyclosporine-effective (n=3)	Cyclosporine-resistant (n=3)
Δ WBC	-582.3±818.4	1335.0±3014.4	-516.7±692.1
Δ CRP	0.4±0.9	5.2±3.0*	0.7±0.8
Δ CK	-67.5±466.8	2076.3±2008.9*	-3.0±71.0
Δ LDH	-25.8±136.2	398.7±355.4*	-70.3±85.0 [§]
Δ Alb	-0.2±0.4	-0.5±0.1	-1.0±0.3 ^{§§}
Δ AaDO ₂	-1.4±6.8	22.0±5.0*	53.7±34.4*

Δ =(value on admission)-(value on initial treatment)
*P<0.05 against steroid-effective group, [§]P<0.05 against cyclosporine-effective group.

Table 4. Changes of laboratory values from admission to initial treatment.

5.5 Bronchoalveolar lavage analysis

Bronchoalveolar lavage findings before treatment are available in 18 patients. Although there were no differences in total cell counts and frequency of alveolar macrophages, lymphocytes, and eosinophils in bronchoalveolar lavage fluid, frequency of neutrophils in cyclosporine-effective group was significantly higher than that in other two groups. In cyclosporine-resistant group, CD4/CD8 ratio was significantly higher compared with other groups (Table 5).

	Steroid-effective cases (n=12)	Steroid-resistant cases	
		Cyclosporine-effective (n=4)	Cyclosporine-resistant (n=4)
TCC (×10 ⁵ /ml)	3.2±1.4	5.5±2.8	5.6±2.4
AM (%)	51.2±20.6	49.5±31.2	61.1±23.5
Lym (%)	41.0±22.5	38.2±31.1	35.2±21.8
Neut (%)	4.2±5.1	11.2±6.1 ^{**§}	1.6±2.6
Eo (%)	3.6±6.0	1.4±0.9	0.6±0.5
CD4/CD8 ratio	0.44±0.53	0.70±0.6	1.9±0.9*

*P<0.01 against steroid-effective group, **P<0.05 against steroid-effective group, [§]P<0.05 against cyclosporine-resistant group.

Table 5. Comparison of bronchoalveolar lavage findings.

5.6 Characteristics of patients with interstitial lung disease in polymyositis-dermatomyositis resistant to prednisolone and cyclosporine

Cyclosporin binds to cyclophilin, then the complex inhibits calcineurin phosphatase and T-cell activation (Clipstone & Crabtree, 1992). Because activated T lymphocytes, in particular CD8⁺ T cells, may play essential roles in interstitial lung disease associated with PM-DM (Enomoto et al., 2003, Kourakata et al., 1999, Kurasawa et al., 2002), immunosuppressive therapy targeting CD8⁺ cells should be reasonable. However, CD4/8 ratio in bronchoalveolar lavage fluid was significantly increased in cyclosporine-resistant cases compared to alive ones. Suda et al. also described that the ratio of CD4/8 lymphocytes was higher in acute/subacute interstitial lung disease than chronic interstitial lung disease in clinically amyopathic dermatomyositis, but the difference was not statistically significant (Suda et al., 2006). Increased CD4/8 ratio in bronchoalveolar lavage fluid suggests that CD8⁺ T cells may not be major pulmonary inflammatory cells causing lung injury in PM-DM.

In this study, all of the cyclosporine-resistant cases were diagnosed as clinically amyopathic dermatomyositis and died of respiratory failure. While, five of nine patients with interstitial lung disease in clinically amyopathic dermatomyositis survived without progression of respiratory failure. Cottin et al. also described a benign form of interstitial lung disease in clinically amyopathic dermatomyositis (Cottin et al., 2003). Clinically amyopathic dermatomyositis with fatal interstitial lung disease may be a distinct clinical entity with unique clinical features.

5.7 Salvage therapy to interstitial lung disease in polymyositis-dermatomyositis

For patients with progressive interstitial lung disease in spite of the combination of glucocorticoids and a second agent, a third immunosuppressive agent may be added. High dose glucocorticoids, monthly intravenous cyclophosphamide, and cyclosporine may be used in combination for patients with interstitial lung disease in clinically amyopathic dermatomyositis, even when the interstitial lung disease is still mild. Primary intensive approach by starting immunosuppressive agents simultaneously with corticosteroids was associated with better survival than step-up approach by adding them sequentially in initial treatment for active interstitial lung disease in PM-DM (Takada et al., 2007).

In spite of the combination therapies with glucocorticoids and immunosuppressive agents, respiratory dysfunction of PM-DM patients with interstitial lung disease sometimes progresses. Although options for salvage therapy including rituximab, intravenous immune globulin, and lung transplantation are reported (Labirua & Lundberg, 2010, Shoji et al., 2010, Suzuki et al., 2009), the effects of these therapies are still unknown or limited. Recently, a case with rapidly progressive interstitial pneumonia associated with clinically amyopathic dermatomyositis successfully treated with polymyxin B-immobilized fiber column (PMX) hemoperfusion was reported (Kakugawa et al., 2008). PMX might improve oxygenation in patients with acute lung injury/ acute respiratory distress syndrome or with acute exacerbation of idiopathic pulmonary fibrosis (Kushi et al., 2005, Seo et al., 2006). This could be another option for interstitial lung disease in clinically amyopathic dermatomyositis resistant to immunosuppressive treatment.

6. Myositis-associated autoantibodies

About 30 percent of patients with DM or PM have myositis-associated autoantibodies with clinical findings of the relatively acute disease onset, constitutional symptoms, Raynaud's

phenomenon, mechanic's hands, arthritis, and interstitial lung disease. Three major categories of myositis-specific autoantibodies are reported: anti-aminoacyl-tRNA synthetase antibodies, anti-SRP antibodies, and anti-Mi-2 antibodies. The presence of individual myositis antibodies may play a role in determining the disease manifestations.

6.1 Anti-aminoacyl-tRNA synthetase antibodies

A group of myositis-associated autoantibodies is strongly linked to the development of interstitial lung disease (Grau et al., 1996, Targoff, 2008). These antibodies are directed against aminoacyl-tRNA synthetase (aaRS). The most common, anti-aaRS specific for histidine (anti-Jo-1), is found in approximately 29% of patients with DM and is found even more frequently in cases with interstitial lung disease (Botha & Carney, 1999, Climent-Albaladejo et al., 2002). Others have been labeled anti-PL-7 (for threonine), anti-PL-12 (alanine), anti-EJ (glycine), anti-KS (asparagine), anti-OJ (isoleucine), and anti-Zo (phenylalanine) (Betteridge et al., 2007). Each of these antibodies has been associated with antisynthetase syndrome marked by a high frequency of interstitial lung disease compared with PM-DM without such antibodies (Targoff, 2008). Selva-O'Callaghan et al. reported that anti-aaRS negative patients with acute interstitial lung disease and pneumomediastinum had an unfavorable prognosis (Selva-O'Callaghan et al., 2005).

6.2 Anti-SRP and anti-Mi-2 antibodies

The signal recognition particle (SRP) is involved in the translocation of newly synthesized proteins into the endoplasmic reticulum. Anti-SRP antibodies are present in 4 to 6 percent of patients with acquired inflammatory and/or necrotizing myopathies (Hengstman et al., 2006). They are associated with aggressive disease with heart and lung involvement and resistance to high-dose glucocorticoids and adjunct immunosuppressive agents (Arlet et al., 2006). Anti-Mi-2 antibodies are directed against a helicase involved in transcriptional activation. They are present in 10–30% of patients with DM (Ghirardello et al., 2005) and associated with severer cutaneous manifestations but a better response to steroid therapy (Hengstman et al., 2006).

6.3 Anti-CADM-140 antibody

A novel autoantibody associated with PM-DM was identified by screening with immunoprecipitation in 298 serum samples from patients with various connective tissue diseases or idiopathic pulmonary fibrosis. Eight out of 298 sera recognized a polypeptide of approximately 140 kd by immunoprecipitation and immunoblotting. Interestingly, all 8 patients with the antibodies had clinically amyopathic dermatomyositis and rapidly progressive interstitial lung disease with significantly higher frequency (Sato et al., 2005). Furthermore, the antibody, termed “anti-CADM-140 antibody” recognizes an antigen identified to be an RNA helicase encoded by melanoma differentiation-associated gene 5 (MDA-5) (Sato et al., 2009). RNA helicase encoded by MDA-5 is a critical molecule involved in the innate immune defense against viruses and viral infection. Although a role of anti-CADM-140 antibody in developing rapidly progressive interstitial lung disease in clinically amyopathic dermatomyositis is still unknown, this may provide a clue about the pathogenesis of the disease and lead to novel effective treatment for the disease.

6.4 A case with clinically amyopathic dermatomyositis with anti-CADM-140 antibody positive

A 45-year-old Japanese woman had complained of itchy erythema, finger joint pain, Raynaud phenomenon, and facial rash for 6 months. She was admitted to the hospital being suspected as dermatomyositis because of skin lesions, but not diagnosed definitely. Chest radiograph and computed tomography showed very slight interstitial lung disease (Fig4A, B). Although daily oral prednisolone 20mg relieved her symptoms, her skin lesions and joint pain recurred during prednisolone tapering in 10 months.

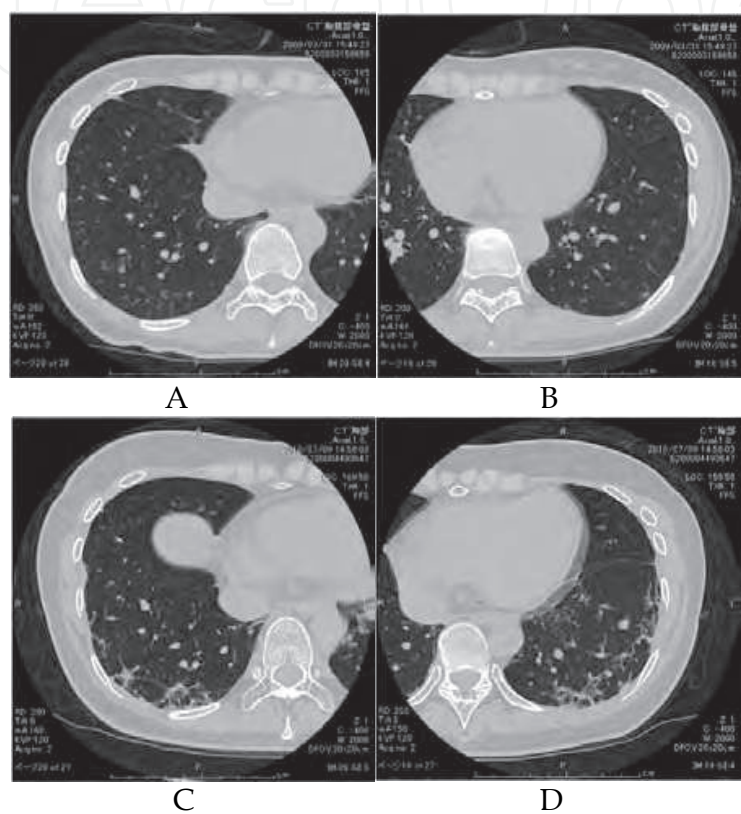


Fig. 4. Chest computed tomography of a case with interstitial lung disease associated with clinically amyopathic dermatomyositis with anti-CADM-140 antibody positive. Chest computed tomography on the first admission (A, B) and the second admission about one year later (C, D) indicated progression of interstitial lung disease in spite of daily oral prednisolone 20mg.

The patient was admitted to the hospital again. On examination, the temperature was 37.1°C, the blood pressure 101/74 torr, the pulse 89 beats per minute, and the oxygen saturation 98% while she was breathing ambient air. The physical examination showed Gottron signs on fingers, hand skin sclerosis, and Raynaud phenomenon, but no fine crackles auscultated or muscle weakness. Chest computed tomography revealed marked reticular and ground-glass opacities in lower lobes (Fig4C, D). The patient was suspected as clinically amyopathic dermatomyositis because of characteristic skin diseases. Surgical lung biopsy was performed to pathologically evaluate lung diseases. Specimens from right S2 segment contained fibrotic lesions distributed at subpleural and perivenous area and wide fibrosis extending from subpleural area with alveolar collapse (Fig5A, original magnification, x 5). Mild to moderate lymphocyte infiltration with lymph follicles in the

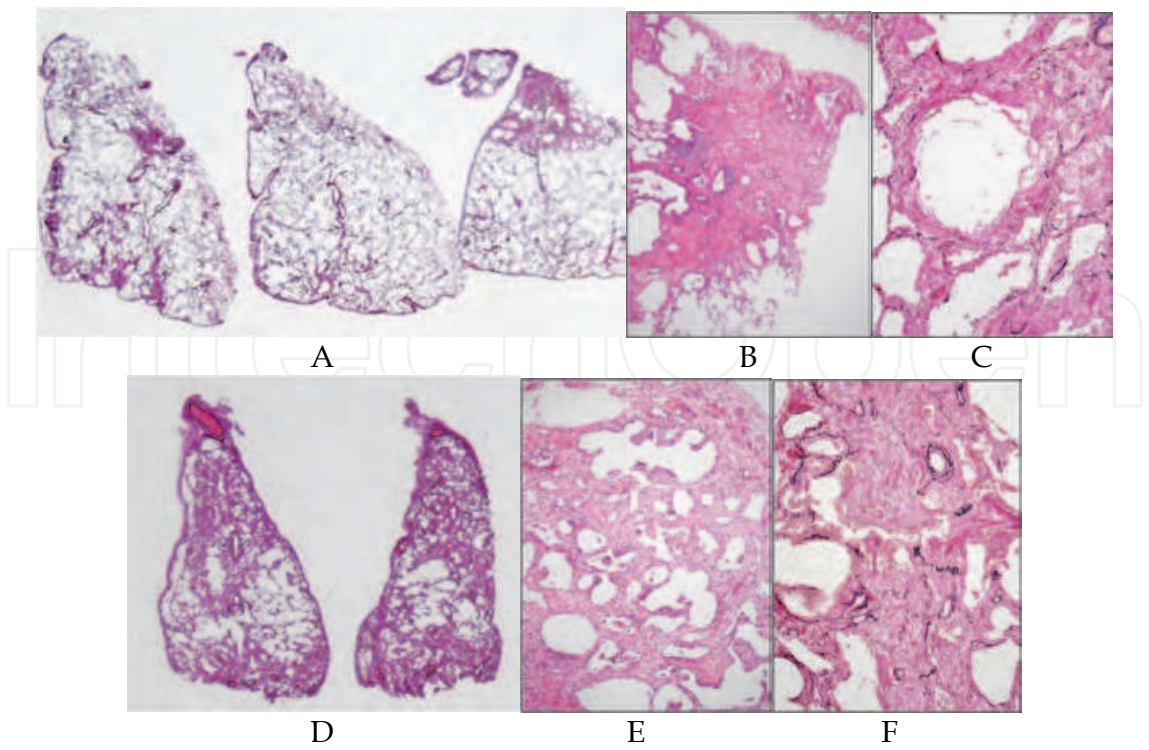


Fig. 5. Light microscopic findings of the lung specimen from a case with anti-CADM-140 antibody. Patchy fibrosing lesions were seen in the upper lobe specimens (A, B, C), while fibrotic nonspecific interstitial pneumonia (fNSIP) pattern was recognized in the specimens from lower lobe (D, E, F).

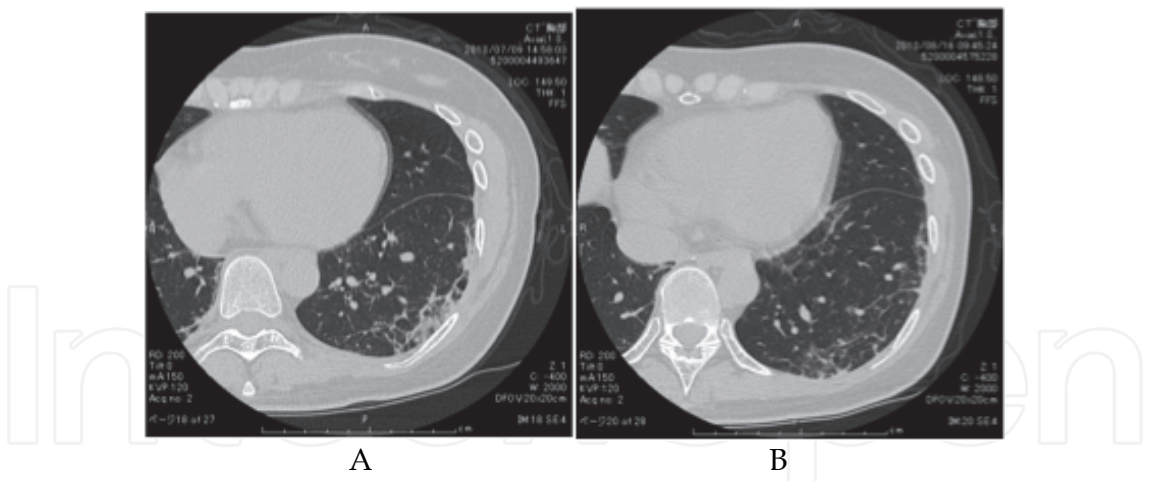


Fig. 6. Chest computed tomography of a case with interstitial lung disease associated with clinically amyopathic dermatomyositis with anti-CADM-140 antibody. Chest computed tomography on admission (A) and in treatment (B) were shown. Interstitial lung disease improved by daily intravenous methylprednisolone 500mg three days followed by daily oral prednisolone and cyclosporine for 14 days.

fibrotic lesions and ring fibrosis connecting alveolar orifices at the rim of collapsing fibrosis were seen (Fig5B, C, original magnification, x 20). Specimens from right S10 segment revealed homogenously distributed fibrotic lesions (Fig5D, original magnification, x 5). Alveolar walls were thickened by fibrosis with simplified alveolar construction and

polypoid tissue protruding into alveolar spaces was also seen (Fig5E, F, original magnification, x 20).

The patient was given methylprednisolone 500mg intravenously daily for three days followed by daily oral prednisolone 40 mg and cyclosporine of 100 to 150 mg /day. Anti-CADM-140 antibody was proven to be positive during the treatment of prednisolone and cyclosporine. Interstitial lung disease gradually ameliorated by prednisolone (Fig6A, B).

7. Conclusion

Clinically amyopathic dermatomyositis is a condition which includes the characteristic rash but little or no evidence of myositis. Patients with PM-DM, in particular clinically amyopathic dermatomyositis sometimes develop rapidly progressive interstitial lung disease. The disease is often resistant to intensive therapy including high dose corticosteroids and immunosuppressive agents, resulting in fatal respiratory failure. Although cyclophosphamide, cyclosporin, and tacrolimus were reported to be effective in treatment of refractory interstitial lung disease in PM-DM, the effect of these drugs were still limited. Our retrospective study suggested that features of glucocorticoid/cyclosporin-resistant interstitial lung disease associated with PM-DM might be 1) a subtype of clinically amyopathic dermatomyositis, 2) hypoxemia on admission and further progression of respiratory dysfunction, 3) progression of hypoalbuminemia before treatment, and 4) elevated CD4/8 ratio in bronchoalveolar lavage fluid.

A variety of serum autoantibodies are specifically detected in patients with PM-DM, including antibodies reactive with aminoacyl-transfer RNA synthetase. These autoantibodies are associated with distinct clinical subsets of PM-DM. Recently a novel PM-DM associated autoantibody, termed “anti-CADM-140 antibody” is reported. This antibody is strongly associated with clinically amyopathic dermatomyositis, in particular rapidly progressive interstitial lung disease complicated. This may provide a clue about the pathogenesis of the disease and lead to novel effective treatment for the disease.

8. Acknowledgment

The authors thank Dr. Ran Nakashima and Dr. Tsuneyo Mimori for measuring anti-CADM-140 antibody. The authors also offer special thanks to Dr. Junichi Narita for useful discussion.

9. References

- (2002) American Thoracic Society/European Respiratory Society International Multidisciplinary Consensus Classification of the Idiopathic Interstitial Pneumonias. This joint statement of the American Thoracic Society (ATS), and the European Respiratory Society (ERS) was adopted by the ATS board of directors, June 2001 and by the ERS Executive Committee, June 2001. *Am J Respir Crit Care Med*. Vol. 165, No. 2: pp. 277-304
- Arlet, J.B., Dimitri, D., Pagnoux, C., Boyer, O., Maisonobe, T., Authier, F.J., Bloch-Queyrat, C., Goulvestre, C., Heshmati, F., Atassi, M., Guillevin, L., Herson, S., Benveniste, O., & Mouthon, L., (2006) Marked efficacy of a therapeutic strategy associating prednisone and plasma exchange followed by rituximab in two patients with

- refractory myopathy associated with antibodies to the signal recognition particle (SRP). *Neuromuscul Disord.* Vol. 16, No. 5: pp. 334-336
- Betteridge, Z., Gunawardena, H., North, J., Slinn, J., & McHugh, N., (2007) Anti-synthetase syndrome: a new autoantibody to phenylalanyl transfer RNA synthetase (anti-Zo) associated with polymyositis and interstitial pneumonia. *Rheumatology (Oxford)*. Vol. 46, No. 6: pp. 1005-1008
- Bohan, A. & Peter, J.B., (1975) Polymyositis and dermatomyositis (first of two parts). *N Engl J Med.* Vol. 292, No. 7: pp. 344-347.
- Botha, J.A. & Carney, I.K., (1999) A 59-year-old female with increasing dyspnoea, an unusual rash and myalgia. Diagnosis: dermatomyositis with associated interstitial lung disease. *Respiration.* Vol. 66, No. 4: pp. 377-379
- Clement-Albaladejo, A., Saiz-Cuenca, E., Rosique-Roman, J., Caballero-Rodriguez, J., & Galvez-Munoz, J., (2002) Dermatomyositis sine myositis and antisynthetase syndrome. *Joint Bone Spine.* Vol. 69, No. 1: pp. 72-75
- Clipstone, N.A. & Crabtree, G.R., (1992) Identification of calcineurin as a key signalling enzyme in T-lymphocyte activation. *Nature.* Vol. 357, No. 6380: pp. 695-697
- Cottin, V., Thivolet-Bejui, F., Reynaud-Gaubert, M., Cadranel, J., Delaval, P., Ternamian, P.J., & Cordier, J.F., (2003) Interstitial lung disease in amyopathic dermatomyositis, dermatomyositis and polymyositis. *Eur Respir J.* Vol. 22, No. 2: pp. 245-250
- Dalakas, M.C., (1994) How to diagnose and treat the inflammatory myopathies. *Semin Neurol.* Vol. 14, No. 2: pp. 137-145
- Dalakas, M.C. & Hohlfeld, R., (2003) Polymyositis and dermatomyositis. *Lancet.* Vol. 362, No. 9388: pp. 971-982
- Douglas, W.W., Tazelaar, H.D., Hartman, T.E., Hartman, R.P., Decker, P.A., Schroeder, D.R., & Ryu, J.H., (2001) Polymyositis-dermatomyositis-associated interstitial lung disease. *Am J Respir Crit Care Med.* Vol. 164, No. 7: pp. 1182-1185.
- el-Azhary, R.A. & Pakzad, S.Y., (2002) Amyopathic dermatomyositis: retrospective review of 37 cases. *J Am Acad Dermatol.* Vol. 46, No. 4: pp. 560-565
- Enomoto, K., Takada, T., Suzuki, E., Ishida, T., Moriyama, H., Ooi, H., Hasegawa, T., Tsukada, H., Nakano, M., & Gejyo, F., (2003) Bronchoalveolar lavage fluid cells in mixed connective tissue disease. *Respirology.* Vol. 8, No. 2: pp. 149-156
- Euwer, R.L. & Sontheimer, R.D., (1991) Amyopathic dermatomyositis (dermatomyositis sine myositis). Presentation of six new cases and review of the literature. *J Am Acad Dermatol.* Vol. 24, No. 6 Pt 1: pp. 959-966
- Euwer, R.L. & Sontheimer, R.D., (1993) Amyopathic dermatomyositis: a review. *J Invest Dermatol.* Vol. 100, No. 1: pp. 124S-127S
- Fathi, M., Vikgren, J., Boijesen, M., Tylen, U., Jorfeldt, L., Tornling, G., & Lundberg, I.E., (2008) Interstitial lung disease in polymyositis and dermatomyositis: longitudinal evaluation by pulmonary function and radiology. *Arthritis Rheum.* Vol. 59, No. 5: pp. 677-685
- Fujisawa, T., Suda, T., Nakamura, Y., Enomoto, N., Ide, K., Toyoshima, M., Uchiyama, H., Tamura, R., Ida, M., Yagi, T., Yasuda, K., Genma, H., Hayakawa, H., Chida, K., & Nakamura, H., (2005) Differences in clinical features and prognosis of interstitial lung diseases between polymyositis and dermatomyositis. *J Rheumatol.* Vol. 32, No. 1: pp. 58-64


- Gerami, P., Schope, J.M., McDonald, L., Walling, H.W., & Sontheimer, R.D., (2006) A systematic review of adult-onset clinically amyopathic dermatomyositis (dermatomyositis sine myositis): a missing link within the spectrum of the idiopathic inflammatory myopathies. *J Am Acad Dermatol*. Vol. 54, No. 4: pp. 597-613
- Ghirardello, A., Zampieri, S., Iaccarino, L., Tarricone, E., Bendo, R., Gambari, P.F., & Doria, A., (2005) Anti-Mi-2 antibodies. *Autoimmunity*. Vol. 38, No. 1: pp. 79-83
- Grau, J.M., Miro, O., Pedrol, E., Casademont, J., Masanes, F., Herrero, C., Haussman, G., & Urbano-Marquez, A., (1996) Interstitial lung disease related to dermatomyositis. Comparative study with patients without lung involvement. *J Rheumatol*. Vol. 23, No. 11: pp. 1921-1926
- Griggs, R.C., Askanas, V., DiMauro, S., Engel, A., Karpati, G., Mendell, J.R., & Rowland, L.P., (1995) Inclusion body myositis and myopathies. *Ann Neurol*. Vol. 38, No. 5: pp. 705-713
- Hengstman, G.J., ter Laak, H.J., Vree Egberts, W.T., Lundberg, I.E., Moutsopoulos, H.M., Vencovsky, J., Doria, A., Mosca, M., van Venrooij, W.J., & van Engelen, B.G., (2006) Anti-signal recognition particle autoantibodies: marker of a necrotising myopathy. *Ann Rheum Dis*. Vol. 65, No. 12: pp. 1635-1638
- Hengstman, G.J., Vree Egberts, W.T., Seelig, H.P., Lundberg, I.E., Moutsopoulos, H.M., Doria, A., Mosca, M., Vencovsky, J., van Venrooij, W.J., & van Engelen, B.G., (2006) Clinical characteristics of patients with myositis and autoantibodies to different fragments of the Mi-2 beta antigen. *Ann Rheum Dis*. Vol. 65, No. 2: pp. 242-245
- Hirakata, M. & Nagai, S., (2000) Interstitial lung disease in polymyositis and dermatomyositis. *Curr Opin Rheumatol*. Vol. 12, No. 6: pp. 501-508.
- Hoogendijk, J.E., Amato, A.A., Lecky, B.R., Choy, E.H., Lundberg, I.E., Rose, M.R., Vencovsky, J., de Visser, M., & Hughes, R.A., (2004) 119th ENMC international workshop: trial design in adult idiopathic inflammatory myopathies, with the exception of inclusion body myositis, 10-12 October 2003, Naarden, The Netherlands. *Neuromuscul Disord*. Vol. 14, No. 5: pp. 337-345
- Kakugawa, T., Mukae, H., Saito, M., Ishii, K., Ishimoto, H., Sakamoto, N., Takazono, T., Fukuda, Y., Ooe, N., & Kohno, S., (2008) Rapidly progressive interstitial pneumonia associated with clinically amyopathic dermatomyositis successfully treated with polymyxin B-immobilized fiber column hemoperfusion. *Intern Med*. Vol. 47, No. 8: pp. 785-790
- Kameda, H., Nagasawa, H., Ogawa, H., Sekiguchi, N., Takei, H., Tokuhira, M., Amano, K., & Takeuchi, T., (2005) Combination therapy with corticosteroids, cyclosporin A, and intravenous pulse cyclophosphamide for acute/subacute interstitial pneumonia in patients with dermatomyositis. *J Rheumatol*. Vol. 32, No. 9: pp. 1719-1726
- Kang, E.H., Lee, E.B., Shin, K.C., Im, C.H., Chung, D.H., Han, S.K., & Song, Y.W., (2005) Interstitial lung disease in patients with polymyositis, dermatomyositis and amyopathic dermatomyositis. *Rheumatology (Oxford)*. Vol. 44, No. 10: pp. 1282-1286
- Kourakata, H., Takada, T., Suzuki, E., Enomoto, K., Saito, I., Taguchi, Y., Tsukada, H., Nakano, M., & Arakawa, M., (1999) Flowcytometric analysis of bronchoalveolar lavage fluid cells in polymyositis/dermatomyositis with interstitial pneumonia. *Respirology*. Vol. 4, No. 3: pp. 223-228

- Kurasawa, K., Nawata, Y., Takabayashi, K., Kumano, K., Kita, Y., Takiguchi, Y., Kuriyama, T., Sueishi, M., Saito, Y., & Iwamoto, I., (2002) Activation of pulmonary T cells in corticosteroid-resistant and -sensitive interstitial pneumonitis in dermatomyositis/polymyositis. *Clin Exp Immunol*. Vol. 129, No. 3: pp. 541-548
- Kushi, H., Miki, T., Okamoto, K., Nakahara, J., Saito, T., & Tanjoh, K., (2005) Early hemoperfusion with an immobilized polymyxin B fiber column eliminates humoral mediators and improves pulmonary oxygenation. *Crit Care*. Vol. 9, No. 6: pp. R653-661
- Labirua, A. & Lundberg, I.E., (2010) Interstitial lung disease and idiopathic inflammatory myopathies: progress and pitfalls. *Curr Opin Rheumatol*. Vol. 22, No. 6: pp. 633-638
- Lee, C.S., Chen, T.L., Tzen, C.Y., Lin, F.J., Peng, M.J., Wu, C.L., & Chen, P.J., (2002) Idiopathic inflammatory myopathy with diffuse alveolar damage. *Clin Rheumatol*. Vol. 21, No. 5: pp. 391-396
- Love, L.A., Leff, R.L., Fraser, D.D., Targoff, I.N., Dalakas, M., Plotz, P.H., & Miller, F.W., (1991) A new approach to the classification of idiopathic inflammatory myopathy: myositis-specific autoantibodies define useful homogeneous patient groups. *Medicine (Baltimore)*. Vol. 70, No. 6: pp. 360-374
- Marie, I., Hachulla, E., Cherin, P., Dominique, S., Hatron, P.Y., Hellot, M.F., Devulder, B., Herson, S., Levesque, H., & Courtois, H., (2002) Interstitial lung disease in polymyositis and dermatomyositis. *Arthritis Rheum*. Vol. 47, No. 6: pp. 614-622
- Marie, I., Hatron, P.Y., Hachulla, E., Wallaert, B., Michon-Pasturel, U., & Devulder, B., (1998) Pulmonary involvement in polymyositis and in dermatomyositis. *J Rheumatol*. Vol. 25, No. 7: pp. 1336-1343
- Miller, F.W., *Polymyositis and dermatomyositis*, in *Cecil textbook of medicine*. 22nd edn., A.D. Goldman L, Editor. 2004, Saunders: Philadelphia. p. 1680-1684.
- Miyake, S., Ohtani, Y., Sawada, M., Inase, N., Miyazaki, Y., Takano, S., Miyasaka, N., & Yoshizawa, Y., (2002) Usefulness of cyclosporine A on rapidly progressive interstitial pneumonia in dermatomyositis. *Sarcoidosis Vasc Diffuse Lung Dis*. Vol. 19, No. 2: pp. 128-133
- Miyazaki, E., Ando, M., Muramatsu, T., Fukami, T., Matsuno, O., Nureki, S.I., Ueno, T., Tsuda, T., & Kumamoto, T., (2005) Early assessment of rapidly progressive interstitial pneumonia associated with amyopathic dermatomyositis. *Clin Rheumatol*. Vol., No.: pp. 1-4
- Mukae, H., Ishimoto, H., Sakamoto, N., Hara, S., Kakugawa, T., Nakayama, S., Ishimatsu, Y., Kawakami, A., Eguchi, K., & Kohno, S., (2009) Clinical differences between interstitial lung disease associated with clinically amyopathic dermatomyositis and classic dermatomyositis. *Chest*. Vol. 136, No. 5: pp. 1341-1347
- Nawata, Y., Kurasawa, K., Takabayashi, K., Miike, S., Watanabe, N., Hiraguri, M., Kita, Y., Kawai, M., Saito, Y., & Iwamoto, I., (1999) Corticosteroid resistant interstitial pneumonitis in dermatomyositis/polymyositis: prediction and treatment with cyclosporine. *J Rheumatol*. Vol. 26, No. 7: pp. 1527-1533
- Oddis, C.V., (2000) Current approach to the treatment of polymyositis and dermatomyositis. *Curr Opin Rheumatol*. Vol. 12, No. 6: pp. 492-497
- Oddis, C.V., (2002) Idiopathic inflammatory myopathy: management and prognosis. *Rheum Dis Clin North Am*. Vol. 28, No. 4: pp. 979-1001

- Sato, S., Hirakata, M., Kuwana, M., Suwa, A., Inada, S., Mimori, T., Nishikawa, T., Oddis, C.V., & Ikeda, Y., (2005) Autoantibodies to a 140-kd polypeptide, CADM-140, in Japanese patients with clinically amyopathic dermatomyositis. *Arthritis Rheum.* Vol. 52, No. 5: pp. 1571-1576
- Sato, S., Hoshino, K., Satoh, T., Fujita, T., Kawakami, Y., & Kuwana, M., (2009) RNA helicase encoded by melanoma differentiation-associated gene 5 is a major autoantigen in patients with clinically amyopathic dermatomyositis: Association with rapidly progressive interstitial lung disease. *Arthritis Rheum.* Vol. 60, No. 7: pp. 2193-2200
- Schnabel, A., Reuter, M., Biederer, J., Richter, C., & Gross, W.L., (2003) Interstitial lung disease in polymyositis and dermatomyositis: clinical course and response to treatment. *Semin Arthritis Rheum.* Vol. 32, No. 5: pp. 273-284
- Selva-O'Callaghan, A., Labrador-Horrillo, M., Munoz-Gall, X., Martinez-Gomez, X., Majo-Masferrer, J., Solans-Laque, R., Simeon-Aznar, C.P., Morell-Brotard, F., & Vilardell-Tarres, M., (2005) Polymyositis/dermatomyositis-associated lung disease: analysis of a series of 81 patients. *Lupus.* Vol. 14, No. 7: pp. 534-542
- Seo, Y., Abe, S., Kurahara, M., Okada, D., Saito, Y., Usuki, J., Azuma, A., Koizumi, K., & Kudoh, S., (2006) Beneficial effect of polymyxin B-immobilized fiber column (PMX) hemoperfusion treatment on acute exacerbation of idiopathic pulmonary fibrosis. *Intern Med.* Vol. 45, No. 18: pp. 1033-1038
- Shinohara, T., Hidaka, T., Matsuki, Y., Ishizuka, T., Takamizawa, M., Kawakami, M., Kikuma, H., Suzuki, K., & Nakamura, H., (1997) Rapidly progressive interstitial lung disease associated with dermatomyositis responding to intravenous cyclophosphamide pulse therapy. *Intern Med.* Vol. 36, No. 7: pp. 519-523
- Shoji, T., Bando, T., Fujinaga, T., Okubo, K., Yukawa, N., Mimori, T., & Date, H., (2010) Living-donor lobar lung transplantation for interstitial pneumonia associated with dermatomyositis. *Transpl Int.* Vol. 23, No. 5: pp. e10-11
- Stonecipher, M.R., Jorizzo, J.L., White, W.L., Walker, F.O., & Prichard, E., (1993) Cutaneous changes of dermatomyositis in patients with normal muscle enzymes: dermatomyositis sine myositis? *J Am Acad Dermatol.* Vol. 28, No. 6: pp. 951-956
- Suda, T., Fujisawa, T., Enomoto, N., Nakamura, Y., Inui, N., Naito, T., Hashimoto, D., Sato, J., Toyoshima, M., Hashizume, H., & Chida, K., (2006) Interstitial lung diseases associated with amyopathic dermatomyositis. *Eur Respir J.* Vol. 28, No. 5: pp. 1005-1012
- Suzuki, Y., Hayakawa, H., Miwa, S., Shirai, M., Fujii, M., Gemma, H., Suda, T., & Chida, K., (2009) Intravenous immunoglobulin therapy for refractory interstitial lung disease associated with polymyositis/dermatomyositis. *Lung.* Vol. 187, No. 3: pp. 201-206
- Takada, K., Kishi, J., & Miyasaka, N., (2007) Step-up versus primary intensive approach to the treatment of interstitial pneumonia associated with dermatomyositis/polymyositis: a retrospective study. *Mod Rheumatol.* Vol. 17, No. 2: pp. 123-130
- Tansey, D., Wells, A.U., Colby, T.V., Ip, S., Nikolakoupolou, A., du Bois, R.M., Hansell, D.M., & Nicholson, A.G., (2004) Variations in histological patterns of interstitial pneumonia between connective tissue disorders and their relationship to prognosis. *Histopathology.* Vol. 44, No. 6: pp. 585-596
- Targoff, I.N., (2008) Autoantibodies and their significance in myositis. *Curr Rheumatol Rep.* Vol. 10, No. 4: pp. 333-340

- Tazelaar, H.D., Viggiano, R.W., Pickersgill, J., & Colby, T.V., (1990) Interstitial lung disease in polymyositis and dermatomyositis. Clinical features and prognosis as correlated with histologic findings. *Am Rev Respir Dis*. Vol. 141, No. 3: pp. 727-733
- Tjiu, J.W., Lin, S.J., Wang, L.F., Shih, J.Y., Yu, C.J., Liang, C.W., & Chu, C.Y., (2004) Digital infarcts showing microangiopathy in adult dermatomyositis suggest severe pulmonary involvement and poor prognosis. *Br J Dermatol*. Vol. 150, No. 6: pp. 1214-1216
- Trojanov, Y., Targoff, I.N., Tremblay, J.L., Goulet, J.R., Raymond, Y., & Senecal, J.L., (2005) Novel classification of idiopathic inflammatory myopathies based on overlap syndrome features and autoantibodies: analysis of 100 French Canadian patients. *Medicine (Baltimore)*. Vol. 84, No. 4: pp. 231-249

IntechOpen



Idiopathic Inflammatory Myopathies - Recent Developments

Edited by Prof. Jan Tore Gran

ISBN 978-953-307-694-2

Hard cover, 212 pages

Publisher InTech

Published online 15, September, 2011

Published in print edition September, 2011

The term "myositis" covers a variety of disorders often designated "idiopathic inflammatory myopathies". Although they are rather rare compared to other rheumatic diseases, they often cause severe disability and not infrequently increased mortality. The additional involvement of important internal organs such as the heart and lungs, is not uncommon. Thus, there is a great need for a better understanding of the etiopathogenesis of myositis, which may lead to improved treatment and care for these patients. Major advances regarding research and medical treatment have been made during recent years. Of particular importance is the discovery of the Myositis specific autoantibodies, linking immunological and pathological profiles to distinct clinical disease entities. A wide range of aspects of myopathies is covered in the book presented by highly qualified authors, all internationally known for their expertise on inflammatory muscle diseases. The book covers diagnostic, pathological, immunological and therapeutic aspects of myositis.

How to reference

In order to correctly reference this scholarly work, feel free to copy and paste the following:

Toshinori Takada, Eiichi Suzuki and Ichiei Narita (2011). Interstitial Lung Disease Associated with Clinically Amyopathic Dermatomyositis, Idiopathic Inflammatory Myopathies - Recent Developments, Prof. Jan Tore Gran (Ed.), ISBN: 978-953-307-694-2, InTech, Available from: <http://www.intechopen.com/books/idiopathic-inflammatory-myopathies-recent-developments/interstitial-lung-disease-associated-with-clinically-amyopathic-dermatomyositis>

INTECH
open science | open minds

InTech Europe

University Campus STeP Ri
Slavka Krautzeka 83/A
51000 Rijeka, Croatia
Phone: +385 (51) 770 447
Fax: +385 (51) 686 166
www.intechopen.com

InTech China

Unit 405, Office Block, Hotel Equatorial Shanghai
No.65, Yan An Road (West), Shanghai, 200040, China
中国上海市延安西路65号上海国际贵都大饭店办公楼405单元
Phone: +86-21-62489820
Fax: +86-21-62489821

© 2011 The Author(s). Licensee IntechOpen. This chapter is distributed under the terms of the [Creative Commons Attribution-NonCommercial-ShareAlike-3.0 License](https://creativecommons.org/licenses/by-nc-sa/3.0/), which permits use, distribution and reproduction for non-commercial purposes, provided the original is properly cited and derivative works building on this content are distributed under the same license.

IntechOpen

IntechOpen