

We are IntechOpen, the world's leading publisher of Open Access books Built by scientists, for scientists

6,900

Open access books available

185,000

International authors and editors

200M

Downloads

Our authors are among the

154

Countries delivered to

TOP 1%

most cited scientists

12.2%

Contributors from top 500 universities



WEB OF SCIENCE™

Selection of our books indexed in the Book Citation Index
in Web of Science™ Core Collection (BKCI)

Interested in publishing with us?
Contact book.department@intechopen.com

Numbers displayed above are based on latest data collected.
For more information visit www.intechopen.com



Melanoma During Pregnancy

Lazar Popovic¹, Zorka Grgic² and Milica Popovic²

¹*Oncology Institute of Vojvodina, Sremska Kamenica,*

²*Clinical Centre of Vojvodina, Novi Sad, Serbia*

1. Introduction

Melanoma is the most malignant cutaneous tumor. The incidence of melanoma accounts for the sixth place among malignant diseases, 5% of malignancies among men and 4% of malignancies among women; it stands for 1.4% of deaths caused by malignant disease (Fisher et al., 2008). The incidence of malignant melanoma has constantly been increasing and it has reached 3% per year in the last several years. At the beginning of the 20th century, the population risk for malignant melanoma was in the ratio 1:500 but today 1:73 of women and 1:49 of men are at risk (Fisher et al., 2008). It is anticipated that there will be 68,130 newly diagnose cases of melanoma and approximately 8,700 deaths from the disease in the USA (Jamal et al., 2010). Among the population aged between 20 to 39 years malignant melanoma is on the second place by incidence. Although the disease is more frequent among men, its incidence during the reproductive period is higher among women. In Great Britain, the third of all diagnosed melanomas arise before 50 years of age and about 30% to 35% develop during the reproductive period of women (Anonymus, 2003; Cancer Research UK 2006). The actual incidence of melanoma during pregnancy is unknown. Smith and Randall (Smith RS & Randall, 1969) gave the first reports based on the source documents of a small non-reference Plattsburg Air Force Base Hospital, New York. The incidence of melanoma was 2.8 per 1000 deliveries but studies that are more recent showed that it is between 2.8 and 5 per 100,000 of pregnancies; the registry of German Dermatological Society shows that 1% of female patients affected with melanoma is pregnant (Dillman et al., 1996; Garbe, 1993). A group of Swedish authors analyzed the period from 1973 to 1984 and reported that melanoma is the most common cancer appearing in pregnancy and accounts for 24.5% of cancer cases in pregnant women (Matthiasen & Berg, 1989). From 1958 to 1999, 19,337 women with melanoma were included in the most extensive epidemiology study based on Swedish and regional registries; 0.9% of malignant melanomas were diagnosed during the pregnancy. Of all included patients, 5,533 of women were in reproductive age and 185 (3.3%) of them were diagnosed with melanoma during the pregnancy (Lens et al., 2004.). The prognostic features for melanoma depend on the stage it has been diagnosed. Although the 5-year survival for stage IV melanoma is still less than 5%, overall mortality from melanoma has a decreasing tendency (Rigel et al., 1996). The effect of pregnancy to the course of melanoma has been a researching issue for years. The results of uncontrolled studies conducted from 1950 to 1980 show that pregnancy is an unfavorable prognostic factor in

patients' survival (Pack & Scharnagel, 1951; Sutherland et al., 1983; Trapeznikov et al., 1987), but the reports of recent controlled studies oppose this finding (Lens et al., 2004; Reintgen et al., 1985; McManamny et al., 1989; Wong et al., 1989; Slingluff et al., 1990; MacKie et al., 1991). The most recent population studies demonstrate equal survival among women with the same melanoma stage regardless they are pregnant or not (Lens et al., 2004; O'Meara et al., 2005). Overall survival rate in both pregnant and nonpregnant patients was 82% (Lens et al., 2004).

2. The influence of sex hormones on melanoma

Sun exposure and excessive tanning are the main risk factors for melanoma developing (Katsambas et al., 1996; Lazovich et al., 2010). Because the appearance of malignant melanoma in reproductive period is more often in women than in men (Cancer research UK 2006), the influence of sex hormones, exogenous hormones, and reproductive factors is a broadly investigated topic in the pathogenesis of melanoma (Osterlind et al., 1988; Smith MA et al., 1998; Karagas et al., 2002; Pfahlberg et al., 1997; Durvasula et al., 2002; Elwood & Coldman, 1978).

2.1 The influence of reproductive factors and exogenous hormones

The length of exposure to female sex hormones has no influence on the risk of melanoma development. Osterlind et al. (Osterlind et al., 1988) included in their case-control study 280 patients with melanoma and 536 patients in the control group. They showed that age of menarche, the length of reproductive period, the age of natural menopause appearance, the age of first pregnancy, the number of pregnancies, the number of live newborn infants, and the number of abortions has no influence on melanoma development. In addition, the results of the same study demonstrated that there is no correlation between melanoma appearance and the use of oral contraceptives, their type or time of usage. According to study mentioned above, the use of hormone-replacement therapy does not increase the risk of melanoma development. Smith et al. (Smith MA et al., 1998) included in their study 308 women with malignant melanoma and 233 patients in the control group. They investigated the influence of previous pregnancies, the age of the first pregnancy, the use of hormone-replacement therapy, the use of oral contraceptives, and the age when first contraceptive was taken; they found that neither of these parameters had any influence on the increase of the risk of melanoma development. Menopause and body mass index did not have any specific effect to the risk of melanoma development but the incidence of melanoma was three times higher in obese postmenopausal women than in premenopausal women of average weight. This study also reported that multiple pregnancies could partly have protective influence on the development of melanoma. Two meta-analyses of case-control studies found no risk of melanoma development among women who used oral contraceptives. The age when first contraceptive was used, duration of contraceptive use, the length of the period from the first and the last use of contraceptives, and the type of contraceptives did not increase the risk of melanoma development (Karagas et al., 2002; Pfahlberg et al., 1997). The conclusion of Durvasula et al. (Durvasula et al., 2002) study is that there is no need to stop hormone-replacement therapy in patients treated of malignant melanoma because there is no evidence of the negative influence of this therapy to the patients' survival. Although several studies demonstrated the protective effect of multiple pregnancies on melanoma development (Smith MA et al., 1998; Karagas et al., 2006), the

results of the last case-control study conducted by Lea et al. (Lea, 2007) are opposite: women with multiple pregnancies are at higher risk for malignant melanoma.

2.2 Estrogen receptors

Estrogen effects are expressed by the activation of two estrogen receptors: ER α and ER β . Up to the discovery of ER β in 1995, no immunohistochemical analysis pointed to the influence of ER in pathogenesis of malignant melanoma. Contrary to ER α , which is predominant in breast tissue, ER β is characteristic for skin and other tissues that are not estrogen-dependant, such as prostate, colon, and brain (de Giorgi et al., 2011). ER β distribution in skin depends on the sex and age of a person. Men have lower ER β level in skin than women in whom the level of this receptor decreases after menopause because of positive estrogen feedback loosening (Stevenson & Thornton, 2007). Immunohistochemical and real-time polymerase chain reaction (PCR) analyses of ER β in the tissue of melanoma (de Giorgi et al., 2009; Schmidt et al., 2006) showed that expression of ER β is reversely proportional to Breslow thickness, which is a significant prognostic factor for survival from melanoma (Rigel et al., 1996). De Giorgi et al. found lower ER β concentration in thicker and more invasive melanomas and concluded that ER β had an antiproliferative effect; hence their explanation for the failure of tamoxifen in the treatment of malignant melanoma (Lens et al., 2003). The authors believe that tamoxifen inhibits ER α and ER β nonselectively and in this way, although it inhibits ER α proliferative effect, it inhibits antiproliferative effect of ER β (de Giorgi et al., 2011). The influence of estrogen receptors in melanoma pathogenesis is still to be cleared up in future.

2.3 The impact of pregnancy

The impact of pregnancies and other reproductive and hormonal factors on melanoma development has been described in previous chapters. Melanomas are relatively often diagnosed during pregnancies; it has led to the speculation that certain hormone effects and immunosuppression in pregnancy may induce malignant transformation (Sadoff et al., 1973; Cochran et al., 1982). However, none of the studies showed that the risk for melanoma occurring is higher during pregnancy. Perhaps, diagnosis of melanoma is more frequent because patients visits the physicians more regular. According to the Connecticut Tumor Registry, the percent of melanoma that are diagnosed among pregnant women equals the one among the general female population (Houghton et al., 1981). In addition, the percent of melanoma arisen by the transformation of existing nevus is from 62% to 68% in pregnant women (Houghton et al., 1981; Colbourn et al., 1989), which is similar to 65% found among general female population (George et al., 1960; Friedman et al., 1985).

3. Diagnosis

Diagnosis of melanoma in pregnancy does not differ from the diagnosis in other population and it comprises clinical examination, tumor excision or biopsy, and pathological examination. The classic ABCD system for melanoma detection was developed in 1985 by the American Cancer Society and it is the basis of clinical examination (Friedman et al., 1985). ABCD is a simple method for early detection of malignant melanoma and its differentiation from benign nevi and other skin changes. The mnemonic ABCD is formed from the initial letters of the words *Asymmetry*, *Border irregularity*, *Color variety*, and *Diameter* greater than 6 mm (Figure 1).

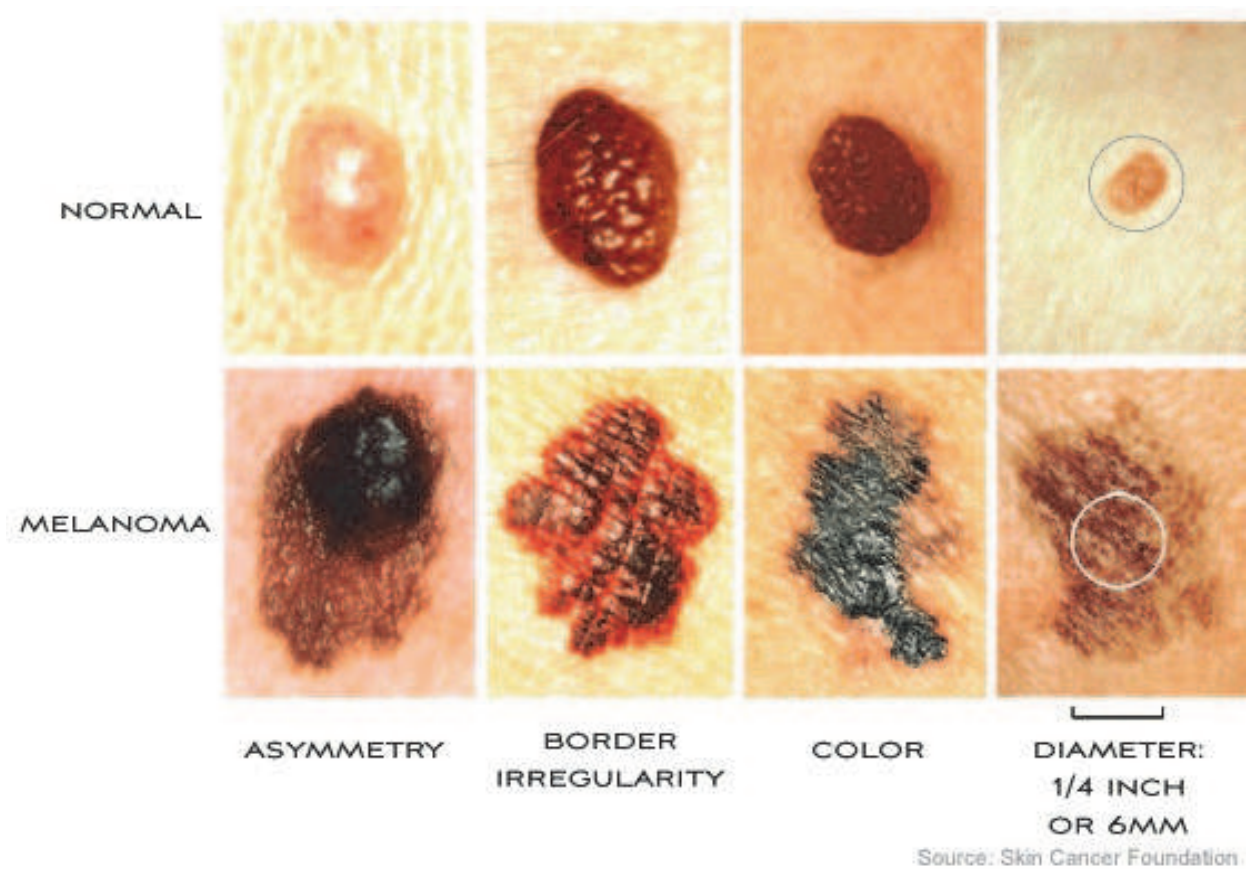


Fig. 1. ABCD diagnostic criteria

The presentation of newly formed or preexisting lesion is of great importance in early detection of melanoma; therefore, the letter E, which stands for *Evolving*, has been added to the ABCD system. The introduction of ABCD criteria has drastically increased the number of melanoma diagnosed in its early, curable stage, without ulceration and with lower Breslow thickness (Rigel et al., 2010). Because of its complexity, Glasgow 7-point checklist (MacKie, 1990) is rarely used, contrary to *Ugly Duckling Sign*. This method is used to mark the nevus that deviate from surrounding lesions and require further examination for suspected malignancy (Scope et al., 2008).

3.1 Skin self-examination

The method of skin self-examination should be performed by whole population, especially individuals that are at higher risk for melanoma developing. Melanomas are most often detected by the patients themselves (Rigel et al., 2010). Patients who performed skin self-examination have thinner melanoma than those who did not practice this approach (Pollitt et al., 2009). In addition to the good knowledge of the criteria for melanoma diagnosis by gynecologists and obstetricians, it is of great importance to perform regular skin self-examination during pregnancy.

3.2 Problems in pregnancy

Pregnancy triggers a number of physiological changes, skin pigmentation is intensified, and nevi often became darker and bigger (Lens, 2008). These changes complicate the

establishment of melanoma diagnosis in pregnancy and physician in charge of a pregnant woman should not assign changed nevus only to physiology mechanisms in pregnancy. Each change of existing or appearance of new nevus should be followed carefully by gynecologist at each patient visit and biopsy should be indicated in case of each suspected lesion. A number of studies report that women diagnosed with melanoma during pregnancy present thicker tumors (Lens et al., 2004, MacKie et al., 1991, Travers et al., 1995.). In Lens study tumor thickness was 1.28 mm in pregnant and 1.07 mm in non-pregnant patients. Same observation was made by Travers et al. (2.28mm vs 1.22 mm). The authors explain this by the impact of hormones and growth factors, and delayed diagnosis compared to general population (Lens et al., 2004). Tumor thickness was independent factor for survival, but once tumor thickness was controlled for survival rate was the same in pregnant and non-pregnant patients.

3.3 Excision and pathological examination

Final diagnosis of melanoma is based on excisional biopsy and histopathology analysis. Each lesion suspected for melanoma should be completely removed with free margins. Lidocaine should be used as local anesthetic in pregnant women; epinephrine, usually used for better control hemostasis and prolongation of lidocaine effect, is not recommended because it belongs to group C according to Food and Drug Administration (Lawrence, 1996). A clinician has to provide pathologist with all relevant information about the patient; these information should include: the history of melanoma appearance among the family, the size and the location of excised lesion and its morphological characteristics. Pathological report should include: the type of melanoma, dimensions, status of the margins, disease stage according to Breslow and Clarke, the existence of ulceration, presence of vascular and/or lymphatic invasion, mitotic index, and the growing phase (Lens, 2008).

4. Staging

Staging system used for melanoma is based on Union Internationale Contre la Cancer/American Joint Committee on Cancer Staging (UICC/AJCC) guidelines (Balch et al., 2009) (Table 1 and Table 2.). Melanoma staging implies the use of histopathological procedures for measuring the depth of tumor invasion (Breslow thickness), sentinel node, radiology and nuclear medicine procedures. Some of those procedures are contraindicated in pregnancy.

4.1 Sentinel node

No locoregional recurrence will occur after local excision without lymphadenectomy in about 80% to 85% of patients with melanomas less than 4 mm thick (Breslow thickness). However, the rest of 15% to 20% of patients will experience locoregional recurrence (Hoekstra, 2008). In order to improve these results a number of authors have tried to routinely perform lymphadenectomy after the excision of primary tumor. Sim et al. (Sim et al., 1986) analyzed the survival of 171 patients with localized malignant melanoma; they performed an early lymphadenectomy, delayed lymphadenectomy, or no lymphadenectomy at all. No statistically significant difference was found in either metastasis-free survival (MFS) or overall survival (OS). Cascinelli et al. (Cascinelli et al., 1998) examined 255 patients with melanoma located on the trunk and thicker than 1.5 mm.

They found no statistically significant difference in survival between patients with early lymphadenectomy and patients with lymphadenectomy performed after the diagnosis of lymph node metastases. Balch et al. (Balch et al, 1996) obtained similar results in comparing early lymphadenectomy with only follow-up. However, their extensive study showed certain benefits of lymphadenectomy in case of patients under 60 year of age and those with tumor thickness of 1 mm to 2 mm and no ulceration. Although no statistically significant difference was confirmed, the results of the above-mentioned studies show clearly that there are benefits from early lymphadenectomy for some patients. In 1992, Morton et al. developed the method of sentinel node biopsy (Morton et al., 1992). This technique combine ^{99m}Tc and blue dye for mapping of affected lymph nodes. When metastases are confirmed by this method, surgeon perform complete lymph node resection in that area. Gershenwald (Gershenwald et al., 1999) and de Vries (de Vries et al., 2005) in their studies have pointed to the importance of sentinel node biopsy in the prognosis of melanoma patients. In addition, Morton (Morton et al., 2006) reports the results of Multicenter Selective Lymphadenectomy Trial I (MSLT I) regarding the sentinel node biopsy in patients with medium thick melanoma of (1.2 mm to 3.5 mm); they show better 5-year survival in patients with early lymphadenectomy than in case of patients with lymphadenectomy after confirmation of metastases development (72.3% vs. 52.4%, p=0.04). Beside, limphoedemas were more frequent in patients with delayed lymphadenectomy (20.4 vs 12.4%, p= 0,04) (Faries et al., 2010) After all these results, sentinel node biopsy has become a standard in the treatment of melanoma (Valsecchi et al., 2011; Balch et al., 2009; Dummer et al., 2008).

T classification		
T1	≤ 1.0 mm	A: without ulceration
T1		B: with ulceration or Clarks' level IV or V
T2	1.01-2.0 mm	A: without ulceration
T2		B: with ulceration
T3	2.01-4.0 mm	A: without ulceration
T3		B: with ulceration
T4	>4.0 mm	A: without ulceration
T4		B: with ulceration
N classification		
N1	One lymph node	A: micrometastasis ^a B: macrometastasis ^b
N2	2-3 lymph nodes	A: micrometastasis ^a B: macrometastasis ^b C: in-transit met(s)/satellites(s) without metastatic lymph nodes
N3	4 or more metastatic lymph nodes, matted lymph nodes, or combinations of in-transit met(s)/satellite(s), or ulcerated melanoma and metastatic lymph node(s)	
M classification		
M1	Distant skin, sub-Q, or lymph node mets	Normal LDH
M2	Lung mets	Normal LDH
M3	All other visceral or any distant mets	Normal LDH Elevated LDH with any M

Table 1. UICC/ AJCC TNM staging system

Clinical Staging ^a				Pathologic Staging ^b			
0	Tis	N0	M0	0	Tis	N0	M0
IA	T1a	N0	M0	IA	T1a	N0	M0
IB	T1b	N0	M0	IB	T1b	N0	M0
	T2a	N0	M0		T2a	N0	M0
IIA	T2b	N0	M0	IIA	T2b	N0	M0
	T3a	N0	M0		T3a	N0	M0
IIB	T3b	N0	M0	IIB	T3b	N0	M0
	T4a	M0	M0		T4a	N0	M0
IIC	T4b	N0	M0	IIC	T4b	N0	M0
IIIA	Any T1-4a	N1b	M0	IIIA	T1-4a	N1a	M0
IIIB	Any T1-4a	N2b	M0	IIIB	T1-4a	N1b	M0
					T1-4a	N2a	
IIIC	Any T	N2c	M0	IIIC	Any T	N2b,N2c	M0
	Any T	N3	M0		Any T	N3	
IV	Any T	Any N	Any M	IV	Any T	Any N	Any M

Table 2. UICC/ AJCC TNM staging system

4.1.1 Sentinel node mapping during pregnancy

In spite of being a standard treatment in large healthcare centers sentinel node biopsy has generated a considerably controversy in case of pregnant patients. Because blue dye is contraindicated in pregnant women and ^{99m}Tc is a radioactive some surgeons avoid this procedure (Squatrino & Harlow, 2008). The results of at least five studies examined safety of the procedure for fetus in pregnant patients affected with melanoma or breast cancer. Gentilini et al. (Gentilini et al., 2004) have indirectly estimated the possible fetus exposure after application of radiopharmaceutical and its distribution in 26 premenopausal nonpregnant patients. They concluded that fetus exposure would be minimal and therefore the procedure could be safe for application in pregnant patients. Similar study has been performed by Keleher et al (Keleher et al., 2004). Mondi et al. (Mondi et al., 2007) presented the first report on sentinel node biopsy during pregnancy. The procedure has been performed in nine pregnant patients – six patients with melanoma and three with breast cancer. All patients had delivery at term and there were no harms for fetus. A retrospective study conducted in H. Lee Moffitt Cancer Center, Tampa, Florida, USA (Mondi et al., 2007) analyse the results of sentinel node biopsy in 5,563 breast cancer patients. Ten of these patients were pregnant. Median duration of pregnancy was 15.8 weeks. Nine patients delivered a healthy child and one patient had intentional abortion. Another study was performed by Gentilini et al and its results were published last year (Gentilini et al., 2010). The study covered sentinel node biopsy in breast cancer patients applying radiophramaceutical only. Eleven of 12 patients delivered a healthy baby and in case of one

baby, ventricular septal defect was operated in the third month of pregnancy. Small number of patients, the fact that most patients had a breast cancer, results from indirect studies, and the studies in which blue dye was not applied refer that sentinel node biopsy has not been proved as a safety procedure yet. Pregnant patients must be warned to both benefits and possible harmfulness of this procedure.

4.2 Radiology procedures in melanoma staging

In case of low risk melanoma (tumor thickness less than 1 mm), detailed physical examination is enough and no further radiological procedures are required (Dummer et al., 2008). In patients with locally advanced disease and lymph node involvement, optimal staging is indicated because of the probability for detection of distant metastases (Hoekstra, 2008; Dummer et al., 2008). It is important to identify solitary operable metastases, which increase the chances for cure (Wasif et al., 2011). Ultrasound examination of abdomen and chest X ray are preferable in pregnancy because fetal exposure is minimal (Orecchia et al., 2008). CT scan should be avoided in pregnant patients because of higher radiation doses. If ultrasound and X ray examination reveal suspected metastases that may have effects to further treatment course, CT scan may be used with strict respect of all procedures for fetus protection. Additional imaging examination with contrast medium should be avoided and low-dose protocols and minimal number of slices should be used (Orecchia et al., 2008). Magnetic resonance imaging may replace X-ray based techniques, but it is contraindicated in the first trimester (Campbell FA & Campbell C, 2006).

4.3 Nuclear medicine procedures

The use of positron-emission tomography (PET/CT) may change the stage of the disease and thus the change in treatment decision-making (Bastiaannet et al., 2006 a). Standard uptake value is a good prognostic factor of the recurrence in melanoma patients (Bastiaannet et al., 2006 b). On the other hand, PET/CT fails to detect distant metastases within the initial staging of patients with positive sentinel node biopsy (Wagner et al., 2011). Because PET/CT examination is contraindicated during pregnancy, it will not be discussed in this chapter.

5. Prognosis

The above chapters deal with the impact of earlier pregnancies and reproductive parameters to the development of malignant melanoma. This chapter presents studies that demonstrate the impact of pregnancy to treatment outcome and occurrence of transplacental metastasis

5.1 Impact of pregnancy to melanoma prognosis

From the '50s of the last century to present time, there have been many studies of the impact of pregnancy to melanoma prognosis. Most of these studies and meta-analyses show that malignant melanoma in pregnancy has no influence on patients survival. However, because the conclusions of these studies are inconsistent, it is still unclear whether pregnancy has impact to rapid tumor growth, more rapid occurrence of metastases, and poorer survival of patients (Sampson et al., 1998; Karagas et al., 2002). From the first report on this issue, which was published in 1951 (Pack & Scharnagel, 1983), up to the '80s of the last century almost all studies demonstrate poorer survival rate from melanoma diagnose during pregnancy (Pack et al., 1951; Sutherland et al., 1983; Trapeznikov et al., 1987; Reintgen et al.,

1085; McManamny et al., 1989; Wong et al., 1989; Slingluff et al., 1990; MacKie et al., 1991; O'Meara et al., 2005; Katsambas et al., 1996; Lazovich et al., 2010; Osterlind et al., 1988; Smith MA et al., 1998; Shiu et al., 1976; Houghton et al., 1981). These findings were mostly the consequence of diagnosing tumors in their higher stages during the pregnancy than in case of tumor diagnosis in nonpregnant women of the same age (Shiu et al., 1976; Houghton et al., 1981; Landthaler & Braun-Falco, 1985), and frequent appearance of trunk melanoma (Houghton et al., 1981). The first study that demonstrated no difference in the overall survival rate was the one published by Wong et al. in 1989 (Wong et al., 1989). The authors compared the survival of 66 pregnant patients in stage I melanoma with 619 nonpregnant patients of the same age and found no difference in the 5-year survival. In the study of Slingluff et al. (Slingluff et al., 1990) there was no difference in the survival time, but pregnant patients were presented with a larger number of involved lymph nodes (39% versus 26%, $p=0.053$) at diagnosis, lymph node metastases appeared in shorter interval after the diagnosis of stage I disease ($p=0.021$), and shorter disease free survival (DFS). The results of following studies have not reported difference in survival among pregnant patients (MacKie et al., 1991; Stein et al., 1990; Driscoll et al., 1993; Travers et al., 1995; Grin et al., 1996; Daryanani et al., 2003), but in some a caution has been stressed to the diagnosis of thicker melanoma in pregnancy (MacKie et al., 1991; Travers et al., 1995). In already mentioned Lens et al. study (Lens et al., 2004) (Figure 2.), the results of investigate cohort of 5,533 women (185 of them were pregnant) showed no difference in survival time between pregnant patients and general population with melanoma diagnosis.

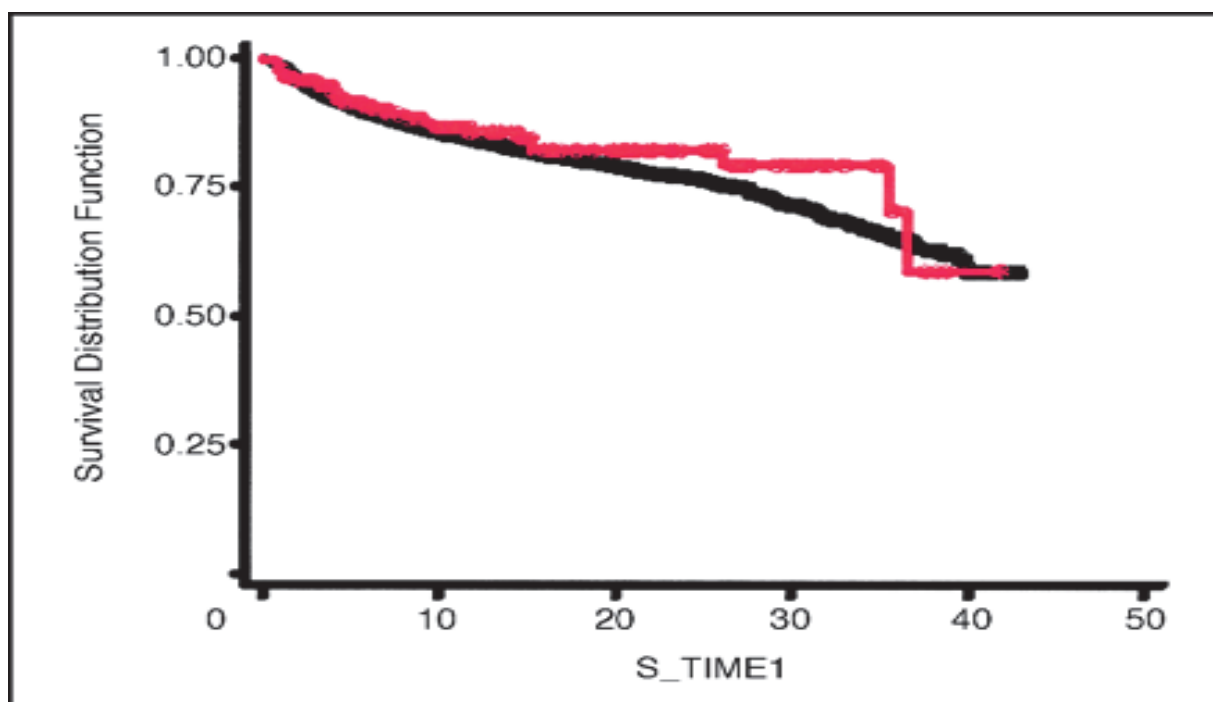


Fig. 2. Kaplan-Meier curve of the survival in pregnant patients with melanoma compared women in generative period (Lens et al., 2004)

Another influential study is a meta-analysis by Karagas et al. (Karagas et al., 2006), which include results obtained in ten case-control studies. Their analysis also did not give evidence for the survival difference between pregnant and nonpregnant melanoma patients. After this study, the general opinion is that there is no difference in the survival between these

two patient groups. Yet, the last study that was conducted with a smaller group of patients gave opposite results (Miller et al., 2010) and points out that not all issues in this sphere has been cleared up.

5.2 Transplacental metastases and risk for fetus

The occurrence of transplacental metastases in fetus is rare and when it occurs, the most common neoplasm is melanoma. Sporadic case reports can be found in current literature. The study, which particularly dealt with this phenomenon in melanoma, was conducted by Alexander et al. They analyzed MEDLINE database for the period 1966-2002 and found 87 patients with placental metastases. Twenty-seven (31%) of these patients were diagnosed with metastatic melanoma and the rest of cases were breast and lung cancer, leukemia, and lymphoma. The involvement of fetus was found in six of 27 patients with placental metastases from melanoma. Five of six newborn infants died. Because occurrence of melanoma in newborn infant is rare, no diagnostic standards exist. Some recommendations regarding the follow-up include complete skin examination, abdominal ultrasound, and screening for melanocytic proteins in urine (Alexander et al., 2003).

5.3 Pregnancy after treatment of melanoma

Contrary to the studies, that analyzed the impact of pregnancy to the treatment outcome of melanoma, the results of the studies that analyse the safety of pregnancy after melanoma diagnosis and treatment are more consistent. The results of all studies show that pregnancy after the treatment of melanoma is safe (Lens et al., 2004; Sutherland et al., 1983; Reintgen et al., 1985; Wong et al., 1989; MacKie et al., 1991; 71 28, Driscoll et al., 1993; o'Meara et al., 2005; Driscoll & Grant-Kels, 2008). The risk of disease recurrence is mainly associated with the stage of the disease before the diagnosis and thus the opinion that the patient's decision regarding the pregnancy should be based on the level of that risk (MacKie et al., 1991). There are authors that advice patients to avoid pregnancy during first two or three years after the treatment of melanoma (Lens et al., 2004, McManamny et al., 1989). Also, there is a report of successful pregnancy with no disease recurrence after the treatment of metastatic melanoma (Nikolin et al., 2005).

6. Treatment

Treatment of melanoma in pregnancy does not greatly differ from the treatment of melanoma in general population. However, certain problems such as somewhat more difficult inguinal lymphadenectomy in late pregnancy, as well as the application of some teratogenic medications, complicate the optimal treatment of pregnant women.

6.1 Surgical treatment

6.1.1 Excision of primary lesion

More than hundred years ago, it was observed that the skin tumors spread in a star-like shape and that malignant cells exist even a few centimeters away from the visible tumor margins. However, many years later, it was proved that the probability of the surrounding spread depends on the size of the primary tumor. Initially, for all melanomas, regardless the tumor size, a technique that included 5 cm width of healthy tissue around the tumor was applied. With this kind of surgery, skin grafts were transplanted for most of the operations (Brady et al., 2009). After that, a large number of studies were performed, which proved that

for tumors of smaller size, it is not necessary for the margin to be so wide. Today's recommendation of the sufficient margin for in situ melanomas is 0.5 cm, for those with the Breslow thickness less than 2 mm, it is 1 cm, while larger melanomas require the margin of more than 2 cm. In an early stage of the disease, there are no specificities related to pregnancy. If it is not possible to achieve a sufficiently wide excision, it is possible to use a skin graft, while the transfers of any deeper tissues are not recommendable because they postpone diagnosis of a local relapse (Hoekstra, 2008). Sentinel node biopsy is described earlier in this chapter.

6.1.2 Regional lymphadenectomy

Patients with, clinically observed, enlarged regional lymph nodes without any evidence of distant metastases, should be treated with regional lymphadenectomy. In some specific cases of enlarged lymph nodes, prior to this procedure, a fine needle aspiration should be performed (FNA) (Brady et al., 2009). In patients where lymph nodes are not enlarged, the performance of lymphadenectomy depends on the results of sentinel node biopsy, which is today a standard in melanoma staging (Valsecchi et al., 2011; Balch et al., 2009; Dummer et al., 2008). After a positive sentinel node biopsy, a regional lymphadenectomy is performed (Brady et al., 2009). This procedure may be more difficult due to pregnancy if it is a group of deep groin and loin lymph nodes. In case of late pregnancy, it is allowed to postpone lymphadenectomy after the childbirth (Hoekstra, 2008).

6.1.3 Ocular melanoma

Ocular melanoma mostly occurs in choroidea, although it may occur in the iris or ciliary body as well. When less than 3 mm, it usually does not have any symptoms, although, as the tumor grows, the patient notices a brown or a yellow spot in his visual field. In certain number of cases, melanoma causes an increase of intraocular pressure, and sometimes pain (Grgic et al., 2009). As an eye does not have any lymphatic vessels, melanoma does not have lymphogenous metastases, surgical postulates for cutaneous melanomas could not be applied. Some small and peripheral lesions can be excised with minimal loss of vision. Such melanomas can also be treated with the laser photocoagulation, transpupillary thermotherapy, and radiotherapy. However, the radiotherapy possibilities in pregnancy are limited. In the largest number of cases, it is necessary to perform enucleation, and sometimes the exenteration of the orbit. Besides that, the COMSG randomized study showed that implantation of the radioactive gold plaque behind the tumor, gives survival results similar to enucleation, with eye preservation, but again, there are no experiences with this method during the pregnancy (Brady et al., 2009; Grgic et al., 2009).

6.1.4 Surgery of locoregional recurrences

Locoregional metastases (satellite metastases, in-transit metastases) represent the recurrence of melanoma in the area between the primary lesion and the local lymph nodes. They are the consequence of intralymphatic spread outside the excision area (Heenan & Ghaznawie, 1999). It is necessary to treat them like thick primary melanoma, because in this way the patient could be cured. Nevertheless, such treatment is not always possible and it depends on the number, location, and size of the lesions. The treatment is directed towards excision with healthy margins, while the amputation of the extremity is not indicated, because it does not increase survival. Besides, it is possible to treat small lesions with laser ablation (Testori et al., 2009). Certain studies proved successful the treatment with isolated extremity

perfusion by melphalan and tumor necrosis factor α (TNF α) (Lienard et al., 1992; Grunhagen et al., 2004). However, as there is no experience in this procedure during pregnancy, some authors consider it contraindicated for the time being (Hoekstra, 2008), while others consider that in specific situations it can be applied due to minimal systemic absorption (Dummer et al., 2008).

6.1.5 Surgery in stage IV disease

Some studies showed that resection of single metastasis is related to the prolonged survival (Sarnaik et al., 2007; McLoughlin et al., 2008). However, there are no studies that compared surgical and conservative treatment of single metastasis. Most of authors advise metastasis resection in such a case (Testori et al., 2009). This recommendation is surely the safest and the most efficient in pregnant patients.

6.2 Radiotherapy

Because surgical treatment of cutaneous melanoma achieves good results, the use radiotherapy in the treatment of primary melanoma does not have its place (Testori et al., 2009). Vongtama et al. showed certain efficacy of radiotherapy in desmoplastic melanoma, when the clean margins after surgery could not be achieved (Vongtama et al., 2003). On the other hand, radiotherapy of the primary melanoma of the nasal cavity and the paranasal sinuses is successfully applied because melanoma of this region has tendency of more often local than systemic relapse and it is sometimes very difficult to access this region for complete surgery (Testori et al., 2009). Furthermore, seems like postoperative therapy gives better results than surgery alone in melanoma of this region (Stevens & McKay, 2006; Kirova et al., 1999). However, there are no randomized studies, which could support this. Depending on the number, size and localization of the lymph nodes, local relapse after lymphadenectomy is found in 20%-50% of cases (Calabro et al., 1989). Since such relapse is very difficult for treatment, there were attempts to obtain better results with postoperative radiotherapy. Although some phase II studies showed certain efficacy (Testori et al., 2009), the only randomized study did not show any difference, neither in DFS, nor in OS (Creagan et al., 1978). Radiotherapy in metastatic melanoma is especially significant for symptoms palliation, primarily of pain due to bone metastases (Testori et al., 2009). In pregnancy, such treatment would be theoretically possible if the metastases are not located in the area of lower thoraces and lumbar vertebrae, which shall be discussed later. The greatest significance of radiotherapy in metastatic melanoma is the treatment of brain metastases. CNS metastases occur in 10%-40% of melanoma patients (Douglas & Margolin, 2002). A median survival without treatment is about 1 month. A whole brain radiotherapy treatment (WBRT) in 60%-70% of patients reduces the symptoms, improves neurological status, and prolongs survival up to 6 months (Patchell, 2003). Furthermore, in solitary metastases, WBRT after surgery prolongs survival when compared to surgery alone (Tarhini & Agarwala, 2004). In addition, stereotactic radiosurgery (e.g. gamma knife), irradiation by linear accelerator (Linac) and surgery, have equal results in treatment of one operable metastasis (Grob et al., 1998).

6.2.1 Radiotherapy of melanoma in pregnancy

Due to risk of death or heavy malformation of the fetus, radiotherapy in pregnancy was the subject of controversies due to the necessary balance between the benefits for the mother and the harmful effect to the fetus (Kal & Struikmans, 2005). Some authors postpone

irradiation therapy of breast carcinoma during the pregnancy (Pavlidis, 2002; Gwyn 2000), while the others recommend the termination of pregnancy if the doses received by the fetus are larger than 0.05-0.1 Gy (Greer et al., 1997). There is no doubt that high X-ray doses are extremely harmful for the fetus, but more current approaches show that irradiation therapy can be safely applied in most of the cases (Kal & Struikmans, 2005). During the earliest pregnancy, doses above 0.1-0.2 Gy lead to the death of the embryo; in weeks 2 to 8 of organogenesis they may cause heavy anomalies, while in the later period of CNS development hinder development of intelligence and cause consequential mental retardation consequentially. The occurrence of neoplasms in children is more frequent to some extent (Kal & Struikmans, 2005). Regardless these data, the greatest number of irradiation therapies outside the pelvis can be safely applied. The first prerequisite for this is a careful planning, a properly functioning device that does not dissipate irradiation and an adequate protection of abdomen and pelvis of a pregnant woman. Van der Giesen et al. calculated the doses for breast cancer irradiation, which are received by the fetus during the standard therapy of 50 Gy (Van der Giessen 1997). Namely, the dosage was 0.03 Gy in week 8, 0.2 Gy in week 24, and 1.43 Gy in week 36 because the fetus is larger and thus closer to the irradiation source. Several cases of births of healthy children after the irradiation therapy of breast carcinoma are reported. A large number of series of irradiation therapy of supradiaphragmally localized Hodgkin lymphoma in pregnant women, who gave birth to healthy children, is also presented in literature (Zucali et al., 1981; Mazonakis et al., 2003; Lishner et al., 1992). Fetal dose in brain irradiation with 54 Gy at Varian accelerator is about 0.22 Gy, and even without any shielding, the fetus dosage almost never exceeds 0.1 Gy (Haba et al., 2004; Mazonakis et al., 1999). There was one case of a pregnant patient who underwent a gamma-knife treatment due to melanoma metastases without any consequences upon her child (Yu et al., 2003). A case of a pregnant patient irradiated with 66 Gy for head and neck tumor was also presented (Podgorsak et al., 1999). In melanoma treatment during pregnancy, the benefits and the harmfulness of the radiotherapeutic treatment should be properly balanced. A possible irradiation of some distant regions postoperatively, due to positive margins, could be taken into consideration. Sinusoidal melanoma irradiation was proved useful and it is safe for the fetus. Adjuvant irradiation after lymphadenectomy proved no benefit in a randomized study (Creagan et al., 1978), so it should be avoided in pregnancy. A specific question is when to irradiate a pregnant patient with metastatic melanoma. In our opinion, palliative irradiation of the lower thoracic and lumbar vertebrae should be avoided. In the case of brain metastases, the fetus receives a minimal dosage of irradiation, which sometimes could be useful for patient's prolongation of life and ending of pregnancy in a due term. Indications for pregnancy termination in irradiated patients, who were not aware of being pregnant at the moment of irradiation, are the doses over 0.5 Gy upon the fetus, because that would almost certainly lead to fetus malformation, while the doses of 0.2 Gy bear the risk of mental retardation of a child (Kal & Struikmans, 2005).

6.3 Systemic treatment

6.3.1 Adjuvant therapy

Adjuvant treatment, for stage II/III melanoma is a subject of controversy. The reason is a large number of studies, which tested various agents, chemotherapy, immunomodulators, and therapeutic vaccines with more or less success (Eggermont et al., 2009). Although Wheatley et al. (Wheatley et al., 2007) and Mocellina et al. (Mocellina et al., 2010),

demonstrated a prolonged DFS and OS in meta-analyses of interferon α (IFN α) studies, such therapy did not become a standard because neither the optimal dose of IFN α nor the optimal duration of treatment is still known. It is considered that the control arm, used in clinical trials, should be just follow up after the complete surgery (Wheatley et al., 2007). The EORTC 18991 study, in which high doses of a pegylated IFN α were used, demonstrated a prolonged DFS ($p=0.01$), but without any effect either to distant-metastasis-free survival (DMFS), or to OS. The greatest benefit was observed in patients with micrometastases detected by the sentinel node biopsy, while the patients with palpable lymph nodes did not have any benefits (Eggermont et al., 2008). Several studies with small doses of IFN α showed the effect to DFS (Grob et al., 1998; Pehamberger et al., 1998; Cameron et al., 2001; Kirkwood et al., 2000; Hancock et al., 2004), of which, only one showed significant importance for OS (Grob et al., 1998). On the other hand, the WHO-16 study, which tested low doses of IFN α in duration of 3 years in patients in stadiums IIIB and IIIC, did not show any significant effect to DFS or OS (Cascinelli et al., 2001). Some other drugs were tested in combination with IFN α , although dacarbazine (Garbe et al., 2008), Melacine (Mitchell et al., 2007), IL-2 (Hauschild et al., 2003), or isotretinoin (Richtig et al., 2005) did not show any difference in comparison to IFN α alone. As the results of various studies are very different, there is a question if an adjuvant therapy should be applied, especially in the case of a pregnant patient. On the one side toxicity and a possible teratogenicity of drugs that would be used are opposed to higher aggressiveness of melanoma in pregnancy, observed in several studies (Shiu et al., 1976; 73 36; Landthaler & Braun-Falco, 1985). There are no sufficient data on IFN α safety during pregnancy. One study of a smaller scope did not observe any defects in the fetuses after their birth although the patients were treated with IFN α (Egberts et al., 2006). However, IFN α was used during pregnancy in some other indications. In 14 patients with immune thrombocytopenia, 2 of which were in their first trimester, there were no observed changes in the fetus (Vantroyen & Vanstraelen, 2002). However, in the study where the patients were treated from a chronic hepatitis or myeloproliferative syndrome (6 were in the first trimester), there were 4 cases of a premature childbirth and 6 cases of intrauterine growth retardation (Hiratsuka et al., 2002).

6.3.2 Metastatic disease

Median 5-year survival of the melanoma patients in stage IV is less than 5% (Rigel et al., 1996). Until two years ago, there was no drug that prolongs survival in patients with distant melanoma metastases. For the purpose of palliation, the most frequently used drug was dacarbazine with small RR and the median survival, not longer than the natural survival duration in melanoma patients. A large number of different drugs, alone or in combination with dacarbazine did not show any difference in relation to RR, DFS, or OS (Brady et al., 2009). Thus, a major question rises, whether to administer dacarbazine to pregnant patients with a metastatic disease, having in mind the risk, which it carries for the fetus and its minimal benefit for the patient. However, some patients demand treatment and some physicians think that it would be unethical if they do not try a cytotoxic therapy. There are certain experiences in administration of dacarbazine-based therapy in pregnancy. Thirty-six patients were administered dacarbazine during pregnancy, 8 of them during their first and 28 of them during their second and third trimesters. Malformations were observed in two fetuses exposed to chemotherapy during the first trimester. In one fetus, a microrphthalmus with secondary heavy hypermetropia was observed, while the other experienced floating thumb malformation. In administration of chemotherapy after the first trimester, one fetus

died in utero, while in the other one a syndactyly was observed. Other fetuses were born without any malformations and after a short follow up of 14 months, they were still healthy. In the last two cases, a polychemotherapy was used (Pages et al., 2010). Intensive research in metastatic melanoma treatment achieved significant results in the past few years. Several new drugs proved to be better than standard dacarbazine therapy. Immunotherapy based treatment has been tested for decades and is used in melanoma treatment. Ipilimumab and tremelimumab are monoclonal antibodies, which bind to cytotoxic T-lymphocyte-associated antigen (CTLA4). Under natural conditions, this receptor binds to receptor B7 at the antigen presenting cells and thus, prevents connecting of molecule CD28 that binds to this receptor and conditions the T-cells activation. Under normal conditions, this reaction induces self-tolerance. By blockage of CTLA4 receptors, an undisturbed connecting of CD28 and B7 occurs, and induction of antitumor effect of T-cells to melanoma cells (Schadendorf et al., 2009). In the largest study published until now, median overall survival was 10.1 months (Hodi et al., 2010). Some other immunomodular drugs were tested in metastatic melanoma: human anti-CD137 antibody, anti-integrin antibodies volociximab and etaracizumab, as well as various vaccines: MAGE-3, dendritic, peptide vaccines, etc. (Schadendorf et al., 2009). These agents are mostly in phase I or II of clinical trials and the results are expected in the following period. Cell signal transition inhibitors take very important role in oncology in the last decade. RAF/RAS/MEK signaling pathway is very important in melanoma because it participates in proliferation induction and apoptosis inhibition. A large number of inhibitors of this signaling pathway are in different phase of clinical trials: sorafenib, AZD6244, tipifarnib, (Hersey et al., 2009). A most remarkable result in treatment was achieved with direct B-Raf inhibitor PLX4032 (Flaherty et al., 2010). In the phase I/II study 32 patients with V600 BRAF mutation, 24 partial and two complete remissions were achieved, with DFS of over 7 months. Besides that, the inhibitors of some other signaling pathways are also intensively tested. They include various inhibitors like tyrosine kinase, PI3K, Akt, mTOR, Stat3 inhibitors, and many other agents (Hersey et al., 2009). Since these drugs are mostly present in clinical trials, and in most of the trials, pregnancy is an exclusion criteria, there is no experience in treatment of childbearing women. A drug, which would most likely be the first to enter regular clinical practice, ipilimumab, causes autoimmunity (Schadendorf et al., 2009), which may be expressed through a syndrome, similar to lupus or antiphospholipid syndrome, which may be fatal both for the fetus and the mother. Experience with imatinib in chronic myeloid leukemia in pregnant patients shows that imatinib is teratogenous (Apperley, 2009). Nevertheless, there was a case where the patient was treated with dasatinib and two cases of treatment with nilotinib where healthy children were born (Conchon et al., 2010; Conchon et al., 2009).

7. Future remarks

Since etiology and the connection between the hormones, pregnancy and melanoma is not entirely clarified, and the results of metastatic melanoma treatment are poor, there are still many unanswered questions related to the etiology, but also to the treatment of melanoma. Huu et al. (Huu et al., 2009) tested the presence of fetal cells in human melanomas, diagnosed during pregnancy. They found that the fetal cells were present in 63% of melanoma, 12% of nevus during pregnancy and 0% in healthy skin. Since fetal cells are capable of developing in various tissues and since they precipitate angiogenesis, it remains to be seen, whether they have any, and what their role in melanoma development during pregnancy is. Estrogen receptors, their relationship, and the possibility of the hormone

therapy in melanoma shall also be the subject of further research. Namely, relationship between ER α and ER β is probably of the key significance for the response to the hormone therapy (de Giorgi et al., 2011). Efficacy and safety of the new drugs' administration in pregnancy is still to be seen.

8. References

- Abbasi NR, Shaw HM, Rigel DS, et al. (2004) Early diagnosis of cutaneous melanoma: revisiting the ABCD criteria. *JAMA*. 2004; 292:2771-2776
- Alexander A, Samlowski WE, Grossman D, et al. (2003) Metastatic melanoma in pregnancy: risk of transplacental metastases in the infant. *J Clin Oncol* 2003; 21(11): 2179–2186
- Anonymous (2003) Stat bite: incidence of and mortality from melanoma of the skin, 1975–2000. *J Natl Cancer Inst* 2003; 95(13): 933
- Antypas C, Sandilos P, Kouvaris J, et al. (1998) Fetal dose evaluation during breast cancer radiotherapy. *Int J Radiat Oncol Biol Phys* 1998; 40: 995–99.
- Apperley J. (2009) Issues of imatinib and pregnancy outcome *J Natl Compr Canc Netw* 2009; 7(10): 1050-8
- Balch CM, Gershenwald JE, Soong SJ, et al. (2009) Final version of 2009 AJCC melanoma staging and classification. *J Clin Oncol*. 2009 Dec 20;27(36):6199-206
- Balch CM, Morton DL, Gershenwald JE, et al.(2009) Sentinel node biopsy and standard of care for melanoma.*J Am Acad Dermatol*. 2009 May;60(5):872-5
- Balch CM, Soong SJ, Bartolucci AA, et al.(1996) Efficacy of an elective regional lymph node dissection of 1 to 4 mm thick melanomas for patients 60 years of age and younger. *Ann Surg* 1996; 224: 255–263
- Bastiaannet E, Hoekstra OS, Oyen WJ, et al. (2006). Level of fluorodeoxyglucose uptake predicts risk for recurrence in melanoma patients presenting with lymph node metastases.*Ann Surg Oncol*. 2006 Jul;13(7):919-26
- Bastiaannet E, Oyen WJ, Meijer S, Hoekstra OS,et al. (2006). Impact of [18F]fluorodeoxyglucose positron emission tomography on surgical management of melanoma patients. *Br J Surg*. 2006 Feb;93(2):243-9
- Brady M, Kaushal A, Ko C. et al. (2009) Melanoma and other skin cancers In: *CancerManagement: A Multidisciplinary Approach 12th Edition*, Pazdur M, Wagman L, Camphausen K et al. CMP Healthcare Media LLC
- Calabro A, Singletary SE, Balch CM. (1989) Patterns of relapse in 1001 consecutive patients with melanoma nodal metastases. *Arch Surg* 1989; 124: 1051–1055.
- Cameron DA, Cornbleet MC, Mackie RM et al. (2001) Adjuvant interferon alpha 2b in high risk melanoma – the Scottish study. *Br J Cancer* 2001; 84: 1146–1149.
- Campbell FA, Campbell C. Magnetic resonance imaging for stage IV melanoma during pregnancy. (2006) *Arch Dermatol* 2006;142:393
- Cancer Research UK Malignant melanoma factsheet May 2006. Available at: www.info.cancerresearchuk.org. Accessed November 9, 2006
- Cascinelli N, Belli F, MacKie RM et al. (2001) Effect of long-term adjuvant therapy with interferon alpha-2a in patients with regional node metastases from cutaneous melanoma: a randomised trial. *Lancet* 2001; 358: 866–869.
- Cascinelli N, Morabito A, Santinami M, et al. (1998) Immediate or delayed dissection of regional nodes in patients with melanoma of the trunk: a randomized trial. WHO Melanoma Programme. *Lancet* 1998; 351: 793–796

- Cochran AJ, Todd G, Hart DM, et al. (1982) Reaction of the leukocytes of melanoma patients and control donors, including pregnant women, with melanoma and fetus-derived materials. *Cancer Immunol Immunother* 1982; 14:78-81
- Colbourn DS, Nathanson L, Belilos E (1989) Pregnancy and malignant melanoma. *Semin Oncol* 1989; 16:377-387
- Conchon M, Sanabani SS, Bendit I, et al. (2009) Two successful pregnancies in a woman with chronic myeloid leukemia exposed to nilotinib during the first trimester of her second pregnancy: case study *J Hematol Oncol* 2009 Oct;2:42
- Conchon M, Sanabani SS, Serpa M, et al. (2010) Successful pregnancy and delivery in a patient with chronic myeloid leukemia while on dasatinib therapy *Adv Hematol* 2010 Epub Mar 7
- Creagan ET, Cupps RE, Ivins JC et al. (1978) Adjuvant radiation therapy for regional nodal metastases from malignant melanoma: a randomized, prospective study. *Cancer* 1978; 42: 2206-2210.
- Daryanani D, Plukker JT, De Hullu JA, et al. (2003). Pregnancy and early-stage melanoma. *Cancer* 2003 May 1;97(9):2248-53
- de Giorgi V, Mavilia C, Massi D, et al (2009) Estrogen receptor expression in cutaneous melanoma: A real-time reverse transcriptase-polymerase chain reaction and immunohistochemical study. *Arch Dermatol* 2009;145:30-36
- de Giorgi V, Gori A, Alfaioli B, et al. (2011) .Influence of sex hormones on melanoma. *J Clin Oncol*. 2011 Feb 1;29(4):e94-5
- de Vries M, Jager PL, Suurmeijer AJ, et al. (2005) .Sentinel lymph node biopsy for melanoma: prognostic value and disadvantages in 300 patients *Ned Tijdschr Geneesk*. 2005 Aug 13;149(33):1845-51
- Dillman RO, Vandermolen LA, Barth NM, et al. (1996) Malignant melanoma and pregnancy. *West J Med* 1996;164: 156-161
- Douglas JG, Margolin K. (2002) The treatment of brain metastases from malignant melanoma. *Semin Oncol* 2002; 29: 518-524.
- Driscoll MS, Grant-Kels JM. (2008) Melanoma and pregnancy. *G Ital Dermatol Venereol*. 2008 Aug;143(4):251-7
- Driscoll MS, Grin-Jorgensen CM, Grant-Kels JM. (1993) Does pregnancy influence the prognosis of malignant melanoma? *J Am Acad Dermatol*. 1993 Oct;29(4):619-30.
- Dummer R, Hauschild A, Jost L; (2008) ESMO Guidelines Working Group Cutaneous malignant melanoma: ESMO clinical recommendations for diagnosis, treatment and follow-up. *Ann Oncol*. 2008 May;19 Suppl 2:ii86-8.
- Durvasula R, Ahmed SM, Vashisht A, et al. (2002) Hormone replacement therapy and malignant melanoma: to prescribe or not to prescribe? *Climacteric* 2002; 5(2): 197-200
- Egberts F, Lischner S, Russo P, et al. (2006) Diagnostic and therapeutic procedures for management of melanoma during pregnancy: risks for the fetus? *J Dtsch Dermatol Ges*. 2006 Sep;4(9):717-20
- Eggermont AM, Suci S, Santinami M et al. (2008) Adjuvant therapy with pegylated interferon alpha-2b versus observation alone in resected stage III melanoma: final results of EORTC 18991, a randomised phase III trial. *Lancet* 2008; 372: 117-126.
- Eggermont AM, Testori A, Marsden J, et al. (2009) Utility of adjuvant systemic therapy in melanoma. *Ann Oncol*. 2009 Aug;20 Suppl 6:vi30-4.
- Elwood JM, Coldman AJ (1978) Previous pregnancy and melanoma prognosis. *Lancet* 1978; 2(8097): 1000-1001
- Faries MB, Thompson JF, Cochran A, et al. (2010) The impact on morbidity and length of stay of early versus delayed complete lymphadenectomy in melanoma: results of the


- Multicenter Selective Lymphadenectomy Trial (I) *Ann Surg Oncol*. 2010 Dec;17(12):3324-9
- Fisher D, Kwong L, Chin L (2008) Molecular Biology of Cutaneous Melanoma In De Vita, Hellman, Rosberg *Cancer: Principle and Practice of Oncology* LWW 2008: 1889-1897
- Flaherty K, Puzanov I, Kim K, et al. (2010) Inhibition of Mutated, Activated BRAF in Metastatic Melanoma *N Engl J Med* 2010; 363:809-819
- Friedman RJ, Rigel DS, Kopf AW (1985) Early detection of malignant melanoma: the role of physician examination and self-examination of the skin. *CA Cancer J Clin* 1985; 35: 130-151
- Garbe C (1993) Pregnancy, hormone preparations and malignant melanoma *Hautarzt* 1993;44: 347-352
- Garbe C, Radny P, Linse R et al. (2008) Adjuvant low-dose interferon α 2a with or without dacarbazine compared with surgery alone: a prospective-randomized phase III DeCOG trial in melanoma patients with regional lymph node metastasis. *Ann Oncol* 2008; 19: 1195-1201.
- Gentilini O, Cremonesi M, Toesca A, et al. (2010) Sentinel lymph node biopsy in pregnant patients with breast cancer. *Eur J Nucl Med Mol Imaging*. 2010 Jan;37(1):78-83
- Gentilini O, Cremonesi M, Trifirò G, et al. (2004) Safety of sentinel node biopsy in pregnant patients with breast cancer. *Ann Oncol*. 2004 Sep;15(9):1348-51
- George PA, Fortner JG, Pack GT (1960) Melanoma with pregnancy. *Cancer* 1960; 13:854-859
- Gershenwald JE, Thompson W, Mansfield PF, et al. (1999) Multi-institutional melanoma lymphatic mapping experience: the prognostic value of sentinel lymph node status in 612 stage I or II melanoma patients *J Clin Oncol* 1999 Mar;17(3):976-83
- Greer BE, Goff BA, Koh W. (1997) Cancer in the pregnant patient. In Hoskins WJ, Perez CA, Young RC, eds. *Principles and practice of gynecologic oncology*, 2nd edn. New York: Lippincott Raven, 1997: 463-70.
- Grgic Z, Oros A, Rasic D, Popovic L, Popovic M (2009) Ocular malignant melanoma in pregnancy: Is a happy ending possible? *Arch Oncol* 2009; 17: 83-85
- Grin CM, Driscoll MS, Grant-Kels JM (1996) Pregnancy and the prognosis of malignant melanoma *Semin Oncol*. 1996 Dec;23(6):734-6.
- Grob JJ, Dreno B. de la Salmonie` re P et al.(1998) Randomised trial of interferon alpha- 2a as adjuvant therapy in resected primary melanoma thicker than 1.5 mm without clinically detectable node metastases. *Lancet* 1998; 351: 1905-1910.
- Grob JJ, Regis J, Laurans R et al. (1998) Radiosurgery without whole brain radiotherapy in melanoma brain metastases. Club de Cancerologie Cutanee. *Eur J Cancer* 1998; 34: 1187-1192.
- Grunhagen DJ, Brunstein F, Graveland WJ et al. (2004) One hundred consecutive isolated limb perfusions with TNF- α and melphalan in melanoma patients with multiple in-transit metastases. *Ann Surg* 2004; 240: 939-948.
- Gwyn KM, Theriault RL.(2000) Breast cancer during pregnancy. *Curr Treat Options Oncol* 2000; 1: 239-43.
- Haba Y, Twyman N, Thomas SJ, et al. (2004) Radiotherapy for glioma during pregnancy: fetal dose estimates, risk assessment and clinical management. *Clin Oncol (R Coll Radiol)* 2004; 16: 210-14.
- Hancock BW, Wheatley K, Harris S et al. (2004) Adjuvant interferon in high-risk melanoma: the AIM HIGH Study-United Kingdom Coordinating Committee on Cancer Research randomized study of adjuvant low-dose extended-duration interferon α -2a in high-risk resected malignant melanoma. *J Clin Oncol* 2004; 22: 53-61.

- Hauschild A, Weichenthal M, Balda BR et al. (2003) Prospective randomized trial of interferon alfa-2b and interleukin-2 as adjuvant treatment for resected intermediate- and high-risk primary melanoma without clinically detectable node metastasis. *J Clin Oncol* 2003; 21: 2883–2888.
- Heenan PJ, Ghaznawie M. (1999) The pathogenesis of local recurrence of melanoma at the primary excision site. *Br J Plast Surg* 1999; 52: 209–213.
- Hersey P, Bastholt L, Charion-Sileni V, et al. (2009) Small molecules and targeted therapies in distant metastatic disease *Ann Oncol* 2009 Aug;20 Suppl 6: vi35-vi40
- Hiratsuka M, Minakami H, Koshizuka S, et al. (2002) Administration of interferon-alpha during pregnancy: effects on fetus. *J Perinat Med* 2002; 28: 372–376
- Hodi S, O'Day S, McDermott D, et al. (2010) Improved Survival with Ipilimumab in Patients with Metastatic Melanoma *N Engl J Med* 2010; 363:711-723
- Hoekstra HJ Melanoma during pregnancy: Therapeutic Management and Outcome In Surbone A., Peccatori F, Pavlidis N *Cancer and Pregnancy Recent Results in Cancer Research* vol. 178; Springer 2008: 175-181
- Houghton AN, Flannery J, Viola MV (1981) Malignant melanoma of the skin occurring during pregnancy. *Cancer* 1981; 48:407-410
- Huu SN, Oster M, Avril MF, et al. (2009) Fetal microchimeric cells participate in tumour angiogenesis in melanomas occurring during pregnancy *Am J Pathol* 2009; 174 (2): 630-7
- Jemal A, Siegel R, Xu J, et al. (2010) Cancer Statistics, 2010 *CA Cancer J Clin* 2010; 60:277-300
- Karagas MR, Stukel TA, Dykes J, et al. (2002) A pooled analysis of 10 case-control studies of melanoma and oral contraceptive use. *Br J Cancer* 2002; 86(7):1085–1092
- Karagas MR, Zens MS, Stukel TA, et al. (2006) Pregnancy history and incidence of melanoma in women: a pooled analysis. *Cancer Causes Control* 2006; 17(1): 11–1929.
- Kal H, Struikmans H (2005) Radiotherapy during pregnancy: fact and fiction *Lancet Oncol* 2005;6:328-33
- Katsambas A, Nicolaidou E (1996) Cutaneous malignant melanoma and sun exposure. Recent developments in epidemiology. *Arch Dermatol.* 1996 Apr;132(4):444-50
- Lawrence C. (1996) Drug management in skin surgery. *Drugs* 1996;52:805-17.
- Keleher A, Wendt R, Delpassand E, et al. (2004) The safety of lymphatic mapping in pregnant breast cancer patients using Tc-99m sulfur colloid. *Breast J* 2004;10:492-5
- Landthaler M, Braun-Falco O. (1985) Malignant melanomas in pregnancy. *Dtsch Med Wochenschr.* 1985 Aug 30;110(35):1319-23
- Khera SY, Kiluk JV, Hasson DM, et al. (2008) Pregnancy-associated breast cancer patient can safely undergo lymphatic mapping *Breast J* 2008; 14(3):250-4
- Kirkwood JM, Ibrahim JG, Sondak VK et al. (2000) High- and low-dose interferon alfa-2b in high-risk melanoma: first analysis of intergroup trial E1690/S9111/C9190. *J Clin Oncol* 2000; 18: 2444–2458.
- Kirova YM, Chen J, Rabarjaona LI et al. (1999) Radiotherapy as palliative treatment for metastatic melanoma. *Melanoma Res* 1999; 9: 611–613.
- Lazovich D, Vogel RI, Berwick M, et al (2010) Indoor tanning and risk of melanoma: A case-control study in a highly exposed population. *Cancer Epidemiol Biomarkers Prev* 2010; 19:1557-1568
- Lea CS, Holly EA, Hartge P et al. (2007) Reproductive risk factors for cutaneous melanoma in woman: a case-control study *Am J Epidemiol* 2007; 165(5): 505-513
- Lens MB, Melanoma during pregnancy: epidemiology, diagnosis, staging, clinical picture In Surbone A., Peccatori F, Pavlidis N *Cancer and Pregnancy Recent Results in Cancer Research* vol. 178; Springer 2008:165-174

- Lens MB, Reiman T, Husain AF (2003) Use of tamoxifen in the treatment of malignant melanoma. *Cancer* 2003; 98:1355-1361
- Lens MB, Rosdahl I, Ahlbom A, et al. Effect of pregnancy on survival in women with cutaneous malignant melanoma. *J Clin Oncol* 2004; 22(21): 4369-4375
- Lienard D, Ewalenko P, Delmotte JJ et al. (1992) High-dose recombinant tumor necrosis factor alpha in combination with interferon gamma and melphalan in isolation perfusion of the limbs for melanoma and sarcoma. *J Clin Oncol* 1992; 10: 52-60.
- Lishner M, Zemlickis D, Degendorfer P, et al. (1992) Maternal and foetal outcome following Hodgkin's disease in pregnancy. *Br J Cancer* 1992; 65: 114-17
- MacKie RM. (1990) Clinical recognition of early invasive malignant melanoma. *BMJ*. 1990;301:1005-1006
- MacKie RM, Bufalino R, Morabito A, et al. (1991) Lack of effect of pregnancy on outcome of melanoma – The World Health Organisation Melanoma Programme. *Lancet* 1991; 337:653-655
- Matthiasen L, Berg G (1989) Malignant melanoma, the most common cancer type, first appearing during pregnancy. *Läkartidningen* 1989;86:2845-2848
- Mazonakis M, Damilakis J, Theoharopoulos N, et al. (1999) Brain radiotherapy during pregnancy: an analysis of conceptus dose using anthropomorphic phantoms. *Br J Radiol* 1999; 72: 274-78.
- Mazonakis M, Varveris H, Fasoulaki M, et al. (2003) Radiotherapy of Hodgkin's disease in early pregnancy: embryo dose measurements. *Radiother Oncol* 2003; 66: 333-39.
- McLoughlin JM, Zager JS, Sondak VK, et al. (2008) Treatment options for limited or symptomatic metastatic melanoma. *Cancer Control* 2008; 15: 239-247.
- McManamny DS, Moss ALH, Pocock PV, et al. (1989) Melanoma and pregnancy: a long-term follow-up. *Br J Obstet Gynaecol* 1989; 96: 1419-1423
- Miller E, Barnea Y, Gur E, et al. (2010) Malignant melanoma and pregnancy: second thoughts. *J Plast Reconstr Aesthet Surg*. 2010 Jul;63(7):1163-8.
- Mitchell MS, Abrams J, Thompson JA et al. (2007) Randomized trial of an allogeneic melanoma lysate vaccine with low-dose interferon alfa-2b compared with highdose interferon alfa-2b for resected stage III cutaneous melanoma. *J Clin Oncol* 2007; 25: 2078-2085.
- Mocellin S, Pasquali S, Rossi D, et al. (2010) Interferon alpha adjuvant therapy in patients with high-risk melanoma: a systematic review and meta-analysis *J Natl Cancer Inst* 2010; 102: 493-501120.
- Mondi MM, Cuenca RE, Ollila DW, et al. (2007) Sentinel lymph node biopsy during pregnancy: initial clinical experience. *Ann Surg Oncol* 2007;14 (1):218-21
- Morton DL, Thompson JF, Cochran AJ, et al. (2006) Sentinel-node biopsy or nodal observation in melanoma. *N Engl J Med* 2006; 355: 1307-1317
- Morton DL, Wen DR, Wong JH, et al. (1992) Technical details of intraoperative lymphatic mapping for early stage melanoma. *Arch Surg* 1992; 127: 392-399
- Ngu SL, Duval P, Collins C. (1992) Foetal radiation dose in radiotherapy for breast cancer. *Australas Radiol* 1992; 36: 321-22.
- Nikolin B, Sveljo O. (2005) Metastatic melanoma in pregnancy *Arch Oncol* 2005;13(1):31-4
- O'Meara AT, Cress R, Xing G, et al. (2005) Malignant melanoma in pregnancy. A population-based evaluation. *Cancer* 2005; 103(6):1217-1226
- Orecchia R, Lucignani G, Tosi G Prenatal irradiation and pregnancy: the effects of diagnostic imaging and radiation therapy In Surbone A., Peccatori F, Pavlidis N *Cancer and Pregnancy Recent Results in Cancer Research* vol. 178; Springer 2008: 3-20

- Osterlind A, Tucker MA, Stone BJ, et al. (1998) The Danish case-control study of cutaneous malignant melanoma. III. Hormonal and reproductive factors in women. *Int J Cancer* 1988; 42(6): 821-824
- Pack GT, Scharnagel IM (1951) Prognosis of malignant melanoma in pregnant women. *Cancer* 1951; 4:324-334
- Pages C, Robert C, Thomas L, et al. (2010) Management and outcome of metastatic melanoma during pregnancy *Br J Dermatol* 2010; 162: 274-81
- Patchell RA. (2003) The management of brain metastases. *Cancer Treat Rev* 2003; 29: 533-540.
- Pavlidis NA. (2002) Coexistence of pregnancy and malignancy. *Oncologist* 2002; 7: 279-87.
- Pehamberger H, Soyer HP, Steiner A et al. (1998) Adjuvant interferon alfa-2a treatment in resected primary stage II cutaneous melanoma. Austrian Malignant Melanoma Cooperative Group. *J Clin Oncol* 1998; 16: 1425-1429.
- Pfahlberg A, Hassan K, Wille L, et al. (1997) Systematic review of case-control studies: oral contraceptives show no effect on melanoma risk. *Publ Health Rev* 1997; 25: 309-315
- Podgorsak MB, Meiler RJ, Kowal H, et al. (1999) Technical management of a pregnant patient undergoing radiation therapy to the head and neck. *Med Dosim* 1999; 24: 121-28.
- Pollitt RA, Geller AC, Brooks DR, et al. (2009) Efficacy of skin self-examination practices for early melanoma detection. *Cancer Epidemiol Biomarkers Prev.* 2009;18:3018-3023
- Reintgen DS, McCarty KS Jr, Vollmer R, et al. (1985) Malignant melanoma and pregnancy. *Cancer* 1985; 55: 1340-1344
- Richtig E, Soyer HP, Posch M et al. (2005) Prospective, randomized, multicenter, double-blind placebo-controlled trial comparing adjuvant interferon alfa and isotretinoin with interferon alfa alone in stage IIA and IIB melanoma: European Cooperative Adjuvant Melanoma Treatment Study Group. *J Clin Oncol* 2005; 23:8655-8663.
- Rigel DS, Friedman RJ, Kopf AW et al. (1996) The incidence of malignant melanoma in the United States: Issues as we approach the 21st century. *J Am Acad Dermatol* 1996; 34: 839-847
- Rigel DS, Russak J, Friedman R (2010) The evolution of melanoma diagnosis: 25 years beyond the ABCDs. *CA Cancer J Clin.* 2010 Sep-Oct;60(5):301-16
- Sadoff L, Winkley J, Tyson S (1998) Is malignant melanoma an endocrinedependent tumor? *Oncology* 1973; 27:244-257
- Sampson JH, Carter JH Jr, Friedman AH, et al. (1998) Demographics, prognosis, and therapy in 702 patients with brain metastases from malignant melanoma. *J Neurosurg* 1998; 88: 11-20.
- Sarnaik AA, Zager JS, Sondak VK. (2007) Multidisciplinary management of special melanoma situations: oligometastatic disease and bulky nodal sites. *Curr Oncol Rep* 2007; 9: 417-427.
- Schadendorf D, Algarra SM, Bastholt L, et al. (2009) Immunotherapy of distant metastatic disease *Ann Oncol* 2009 Aug;20 Suppl 6: vi41-vi50
- Schmidt AN, Nanney LB, Boyd AS, et al (2006) Oestrogen receptor-beta expression in melanocytic lesions. *Exp Dermatol* 2006;15:971-980
- Scope A, Dusza SW, Halpern AC, et al. (2008) The “ugly duckling” sign: agreement between observers. *Arch Dermatol.* 2008;144:58-64
- Shiu MH, Schottenfeld D, Maclean B, et al. (1976) Adverse effect of pregnancy on melanoma: a reappraisal *Cancer.* 1976 Jan;37(1):181-7.
- Sim FH, Taylor WF, Pritchard DJ, et al. (1986) Lymphadenectomy in the management of stage I malignant melanoma: a prospective randomized study. 1986; *Mayo Clin Proc* 61: 697-705
- Slingluff CL Jr, Reintgen DS, Volmer RT, et al. (1990) Malignant melanoma arising during pregnancy – a study of 100 patients. *Ann Surg* 1990; 211: 552-559

- Smith MA, Fine JA, Barnhill RL, et al. (1998) Hormonal and reproductive influences and risk of melanoma in women. *Int J Epidemiol* 1998; 27(5): 751–757
- Smith RS, Randall P (1969) Melanoma during pregnancy. *Obstet Gynecol* 1969;34: 825–829
- Squatraro RC, Harlow SP. (1998) Melanoma complicating pregnancy. *Obstet Gynecol Clin North Am* 1998;25:407-16
- Stein M, Fried G, Borovik R, et al. (1990). Malignant melanoma occurring during pregnancy: a report of the Northern Israel Oncology Center (1968-1988). *J Surg Oncol.* 1990 Oct;45(2):117-20
- Stevens G, McKay MJ. (2006) Dispelling the myths surrounding radiotherapy for treatment of cutaneous melanoma. *Lancet Oncol* 2006; 7: 575–583.
- Stevenson S, Thornton J (2007) Effect of estrogens on skin aging and the potential role of SERMs. *Clin Interv Aging* 2007;2:283-297
- Sutherland CM, Loutfi A, Mather FJ, et al. (1983) Effect of pregnancy upon malignant melanoma. *Surg Gynecol Obstet* 1983; 157:443–446
- Tarhini AA, Agarwala SS. (2004) Management of brain metastases in patients with melanoma. *Curr Opin Oncol* 2004; 16: 161–166.
- Testori A, Rutkowski P, Marsden J, et al. (2009) Surgery and radiotherapy in the treatment of cutaneous melanoma. *Ann Oncol.* 2009 Aug;20 Suppl 6:vi22-9.
- Trapeznikov NN, Khasanov SR, Iavorskii VV (1987) Melanoma of the skin and pregnancy. *Voprosy Onkologii* 1987;33: 40–46
- Travers RL, Sober AJ, Berwick M, et al. (1995) Increased thickness of pregnancy-associated melanoma. *Br J Dermatol.* 1995 Jun;132(6):876-83.
- Valsecchi ME, Silberman D, de Rosa N, et al. (2011). Lymphatic Mapping and Sentinel Lymph Node Biopsy in Patients With Melanoma: A Meta-Analysis. *J Clin Oncol.* 2011 Mar 7. [Epub ahead of print]
- Van der Giessen PH. (1997) Measurement of the peripheral dose for the tangential breast treatment technique with Co-60 gamma radiation and high energy X-rays. *Radiother Oncol* 1997; 42: 257–64.
- Vantroyen B, Vanstraelen D (2002) Management of essential thrombocythemia during pregnancy with aspirin, interferon alpha-2a and no treatment. A comparative analysis of literature. *Acta Haematol* 2002; 107: 158–169
- Vongtama R, Safa A, Gallardo D et al. (2003) Efficacy of radiation therapy in the local control of desmoplastic malignant melanoma. *Head Neck* 2003; 25: 423–428.
- Wagner T, Meyer N, Zerdoud S, et al. (2011) FDG PET fails to detect distant metastases at initial staging of melanoma patients with metastatic involvement of sentinel lymph node. *Br J Dermatol.* 2011 Feb 17.. [Epub ahead of print]
- Wasif N, Bagaria SP, Ray P, et al. (2011) Does metastasectomy improve survival in patients with stage IV melanoma? a cancer registry analysis of outcomes. *J Surg Oncol.* 2011 Mar 4. [Epub ahead of print]
- Wheatley K, Ives N, Eggermont AM et al. (2007) Interferon-a as adjuvant therapy for melanoma: An individual patient data meta-analysis of randomised trials. 2007 ASCO Annual Meeting Proceedings Part I. *J Clin Oncol* 2007: 25 Abstr 8526.
- Wong JH, Sterns EE, Kopald KH, et al. (1989) Prognostic significance of pregnancy in stage I melanoma. *Arch Surg* 1989; 124: 1227–1231
- Yu C, Jozsef G, Apuzzo ML, et al. (2003) Fetal radiation doses for model C gamma knife radiosurgery. *Neurosurgery* 2003; 52: 687–93.
- Zucali R, Marchesini R, De Palo G.(1981) Abdominal dosimetry for supradiaphragmatic irradiation of Hodgkin's disease in pregnancy: experimental data and clinical considerations. *Tumori* 1981; 67: 203–08.



Advances in Malignant Melanoma - Clinical and Research Perspectives

Edited by Dr. April Armstrong

ISBN 978-953-307-575-4

Hard cover, 252 pages

Publisher InTech

Published online 22, September, 2011

Published in print edition September, 2011

This book titled *Advances in Malignant Melanoma - Clinical and Research Perspectives* represents an international effort to highlight advances in our understanding of malignant melanoma from both clinical and research perspectives. The authors for this book consist of an international group of recognized leaders in melanoma research and patient care, and they share their unique perspectives regarding melanoma epidemiology, risk factors, diagnostic and prognostic tools, phenotypes, treatment, and future research directions. The book is divided into four sections: (1) Epidemiology and Risk Factors of Melanoma, (2) Clinical Phenotypes of Melanoma, (3) Investigational Treatments for Melanoma and Pigmentary Disorders, and (4) Advances in Melanoma Translational Research. This book does not attempt to exhaustively cover all aspects of the aforementioned topics. Rather, it is a compilation of our authors'™ pearls and unique perspectives on the relevant advances in melanoma during the recent years.

How to reference

In order to correctly reference this scholarly work, feel free to copy and paste the following:

Lazar Popovic, Zorka Grgic and Milica Popovic (2011). Melanoma During Pregnancy, *Advances in Malignant Melanoma - Clinical and Research Perspectives*, Dr. April Armstrong (Ed.), ISBN: 978-953-307-575-4, InTech, Available from: <http://www.intechopen.com/books/advances-in-malignant-melanoma-clinical-and-research-perspectives/melanoma-during-pregnancy>

INTECH
open science | open minds

InTech Europe

University Campus STeP Ri
Slavka Krautzeka 83/A
51000 Rijeka, Croatia
Phone: +385 (51) 770 447
Fax: +385 (51) 686 166
www.intechopen.com

InTech China

Unit 405, Office Block, Hotel Equatorial Shanghai
No.65, Yan An Road (West), Shanghai, 200040, China
中国上海市延安西路65号上海国际贵都大饭店办公楼405单元
Phone: +86-21-62489820
Fax: +86-21-62489821

© 2011 The Author(s). Licensee IntechOpen. This chapter is distributed under the terms of the [Creative Commons Attribution-NonCommercial-ShareAlike-3.0 License](https://creativecommons.org/licenses/by-nc-sa/3.0/), which permits use, distribution and reproduction for non-commercial purposes, provided the original is properly cited and derivative works building on this content are distributed under the same license.

IntechOpen

IntechOpen