

We are IntechOpen, the world's leading publisher of Open Access books Built by scientists, for scientists

6,900

Open access books available

185,000

International authors and editors

200M

Downloads

Our authors are among the

154

Countries delivered to

TOP 1%

most cited scientists

12.2%

Contributors from top 500 universities



WEB OF SCIENCE™

Selection of our books indexed in the Book Citation Index
in Web of Science™ Core Collection (BKCI)

Interested in publishing with us?
Contact book.department@intechopen.com

Numbers displayed above are based on latest data collected.
For more information visit www.intechopen.com



Laparoscopic Extraperitoneal Approach for Urinary Bladder Stones Removal – A New Operative Technique

Tsvetin Genadiev
*University Hospital Lozenetz
 Bulgaria*

1. Introduction

The classical operative treatment methods of urinary bladder stones are open suprapubic operation or transurethral lithotripsy. Alternative methods are suprapubic endoscopic extraction of bladder stones and combined transurethral and suprapubic technique. In the present work we describe a novel endoscopic method for urinary bladder stones removal. The urethral trauma is the main reason against the transurethral access for large or multiple bladder stones.

After the pub med investigation according to the key words laparoscopy, endoscopic extraction bladder stones, retroperitoneoscopic urinary bladder stones removal, endoscopic sectio alta, there are no results similar to our technique.

To the best of our knowledge, this is the first description of this technique. This novel method we named Endoscopic Sectio Alta - ESAL.

1.1 History of urinary bladder stones treatment

The bladder stones are about 5% of all urinary stones. The forming reasons are urinary infection, corpus alienum in bladder, obstruction or previous prostatic operation (Schwartz BF& Stoller ML, 2000).

According to Ellis H. 1979 the first surgical operation to remove bladder stones is perineal lithotomy described by Aulus Celsus in first century AD. In 1561, Pierre Franco made suprapubic vesicotomy – the so called High operation. In 1719 John Douglas, a brother of the famous surgeon James Douglas, described surgical technique based on opening the bladder after filling it with water without opening the peritoneum. This procedure made the High operation even more popular (H. Ellis, 1979). The open technique is currently applied successfully on aged patients and children (Chow & Chou, 2008). Nowadays the progress in medical techniques and technology has lead to a number of endoscopic methods such as transurethral lithotomy, percutaneous suprapubic cystolithotripsy and a combination of both methods – transurethral and percutaneous (Holman et al., 2004; Tugcu et al.; 2009 Wollin et al., 1994).

2. Operative technique

2.1 Patient selection

The patient selection for ESAL is based on the number and the size of the stones. Suitable for ESAL are patients with single large (more than three centimeters) bladder stone, without residual urine. Usually those are the stones, which have migrated from the kidney. Another group of appropriate candidates are patients with multiple (more than five) bladder stones with size ranging between one and two centimeters. There were no uric acid stones treated in this study.

2.2 Patients

Five male patients, all of which having urinary bladder stones and aged between 52 and 58 years underwent Endoscopic Sectio Alta in our clinic. One of the cases is with a single 4 centimeters large stone and the others are with multiple four to five stones with sizes between 1 and 1.5 centimeters. All stones were x-ray positive. The patients underwent abdominal ultrasound of the urinary bladder and plain x-ray film on kidney, ureter and bladder (KUB). Middle prostatic size was 45 cubic centimeters on the abdominal ultrasound. There were no cases with residual urine. All patients wanted prostate sparing methods and were informed and agreed with our technique.

2.3 Contraindications

The contraindications to ESAL are those conditions that are contradictory to any laparoscopy, such as severe haemostatic disorder or cardiopulmonary disease. Patients with previous operations such as inguinal hernioplasty or appendectomy are not contraindicated. Patients after open urinary bladder surgery for prostatic adenomectomy or for another reason have relatively contraindicated for ESAL.

2.4 Preoperative preparation

The patients were given laxative suppository in the evening before operative day and again 2 hours before operation. Suprapubic area was shaved up to the umbilicus and compressive stockings were placed on the legs.

2.5 Anesthesia

General endotracheal anesthesia is usually preferable for laparoscopy. This anesthesia was used in all cases.

2.6 Intraoperative patient preparation

The patient is in the horizontal supine position with shoulders support for Trendelenburg position. The legs are in slight abduction. A nasogastric tube is not necessary because of the short operative time and the extraperitoneal access. The Foley catheter is placed in a sterile fashion after the draping was completed.

2.7 Operative team

The operative team consists of a surgeon, an assistant and a nurse. The surgeon stands on the patient's left side while the assistant stands on the patient's right side. A laparoscopic tower and a single monitor are placed between the patient's legs.

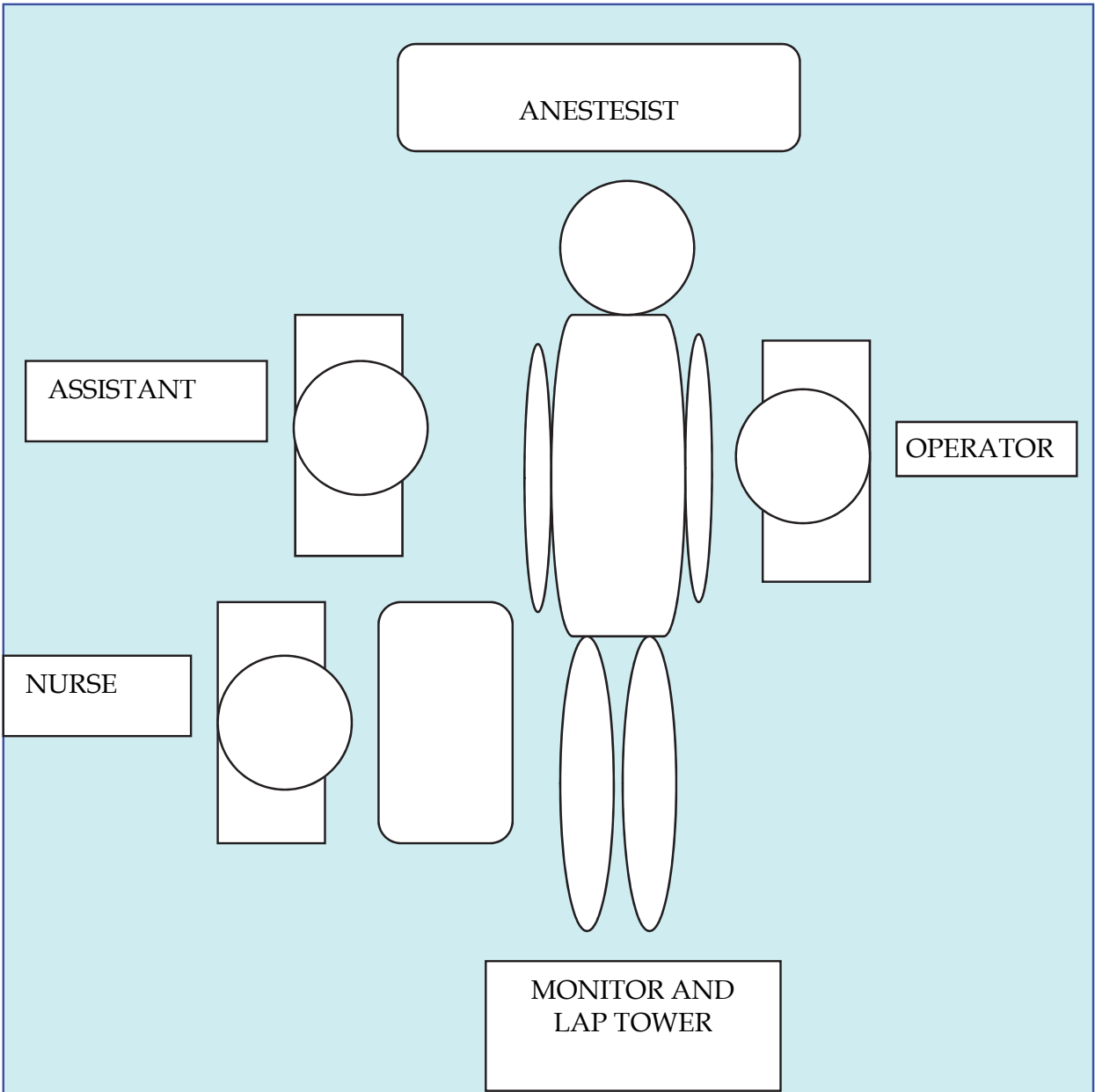


Fig. 1. Schematic of the operative team placement.

2.8 Instruments

We used the standard equipment for laparoscopic operation comprised of monitor, insufflator, electrosurgical monopolar and bipolar device, suction-irrigation device, xenon light source, and 10 mm, 0-degree lens laparoscope. Four trocars were placed – two of them were 10 mm long and were used for a camera and the operator, two were 5 mm long for the operator and one were 5 mm long for the assistant. Bipolar and monopolar dissectors, monopolar scissors, suction-irrigation canula, needleholders, endobag were also employed.

3. Primary access

The operation started with retroperitoneoscopic praeperitoneal and praevesical space made following the Endoscopic Extraperitoneal Radical Prostatectomy (EERPE) technique,

described by J-U Stolzenburg (Stolzenburg JU, 2002). The operative access started with a 2 centimeters wide periumbilical skin incision above right musculus rectus abdominis – figure 2. After that, the anterior rectus fascia was transversally incised – figure 3.

The balloon trocar was insufflated carefully and gradually with a small volume of CO₂ until the anterior abdominal wall became slightly prominent above the umbilicus level.



Fig. 2. Periumbilical skin incision above the right musculus rectus abdominis



Fig. 3. The picture shows transversal incision of the anterior rectus fascia.

Attention should be paid not to damage the vasa epigastria.

Two lateral sutures of the rectus fascia were made in order to keep in place the conical camera trocar.

3.1 Trocar placement

Trocar placement was similar to the endoscopic extraperitoneal access only without the second trocar in the right side.

The camera trocar was with conical shape, 10-mm in size and was placed on the paraumbilical right side. On the left side lateral of the patient was placed 10-mm trocar and a medial 5-mm trocar. On the assistant side there was only one 5-mm trocar – figure 4.

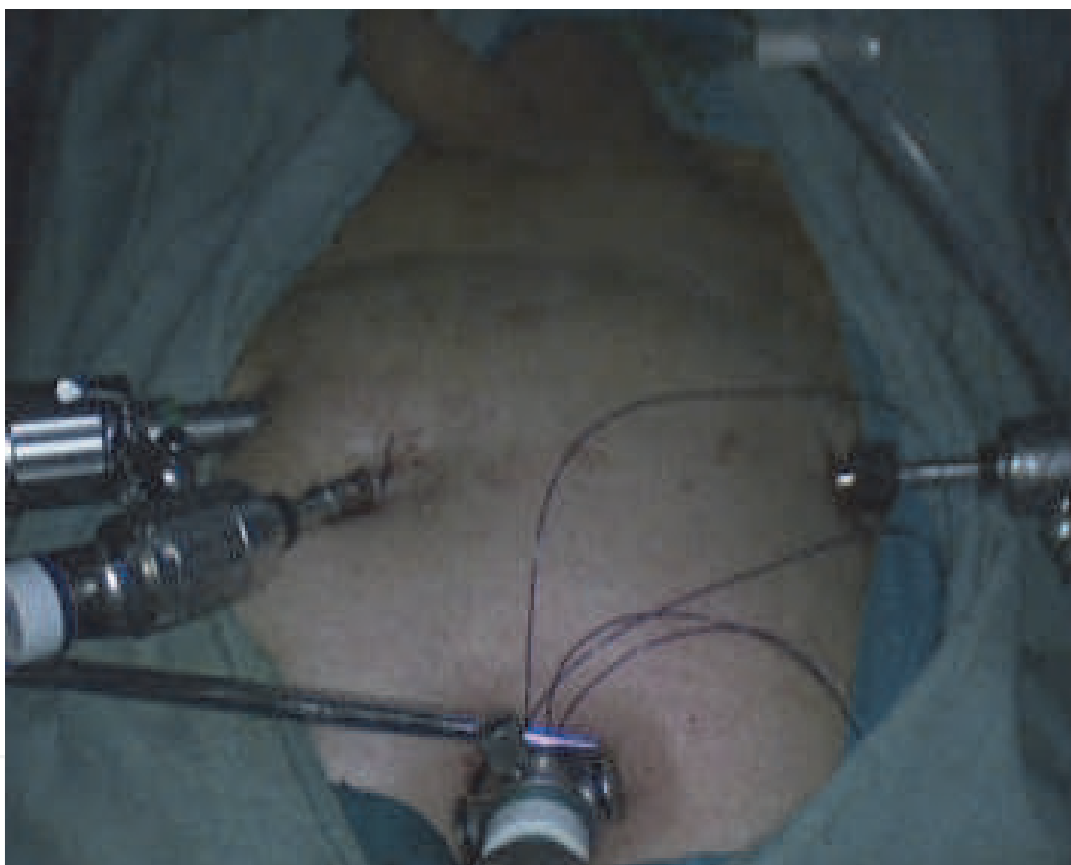

Fig. 4. The picture shows trocar placement – 10-mm conical camera trocar, fixed with fascial sutures. At the left side lateral there is a 10-mm trocar and the medial is 5-mm. At the right side there is one 5-mm trocar.

3.2 Operative technique

The working CO₂ pressure was between 12 and 14 mmHg. The urinary bladder was inflated with 150 milliliters saline water to locate its front side. The anterior bladder wall was laterally sutured with two 2/0 stitches in a distance of about 3 to 4 centimeters and was lifted – as shown on figure 5. Vesicotomy was performed at two centimeters between the stitches with monopolar scissors – figure 6. The bladder was inspected for damages and residual stones – figure 7.

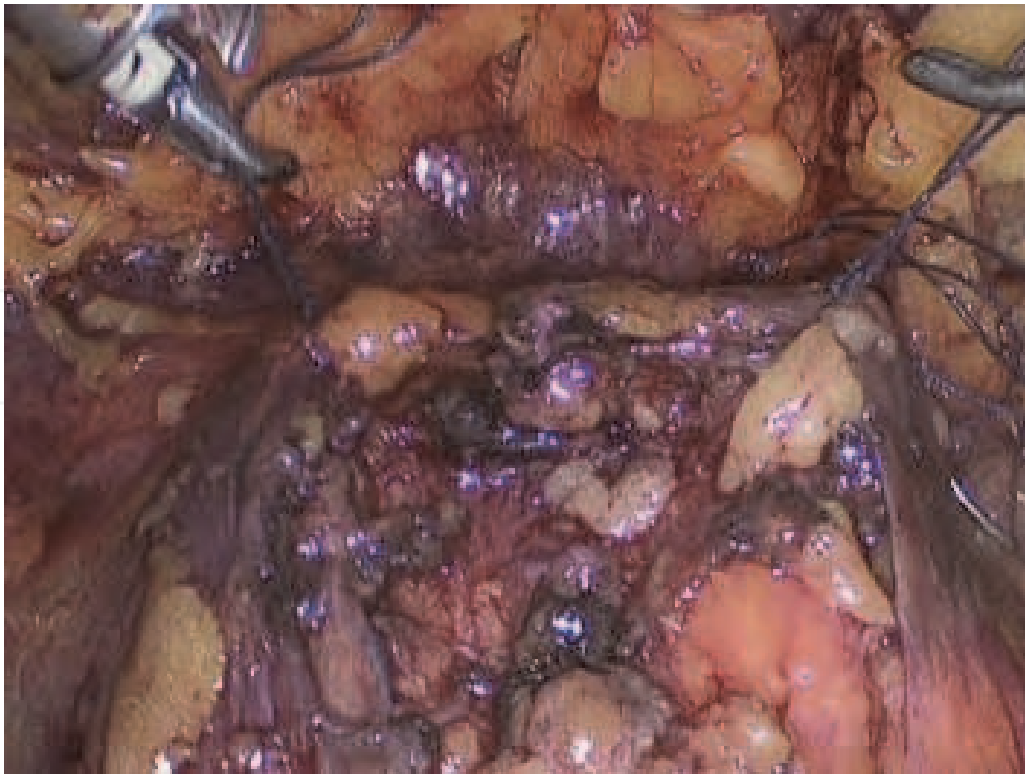


Fig. 5. The picture shows the anterior lateral bladder wall sutured with two 2/0 stitches. Retzius space remains closed for minimally operative trauma and against stone migration.

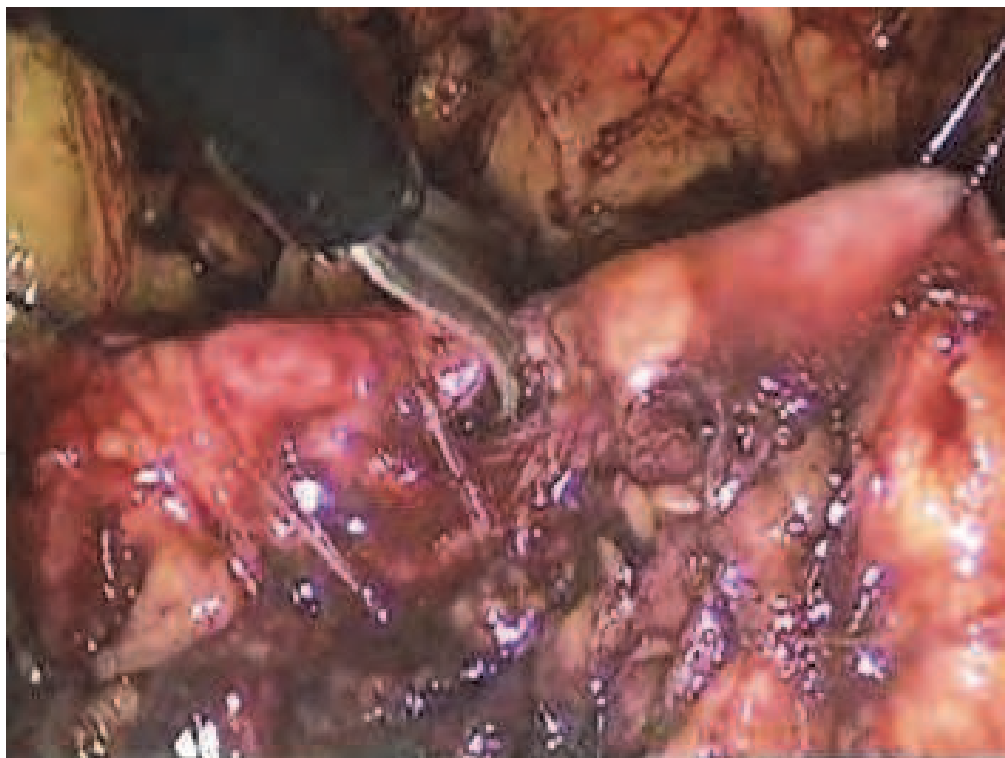


Fig. 6. The picture shows vesicotomy performed at 2 centimeters between the stitches with monopolar scissors.

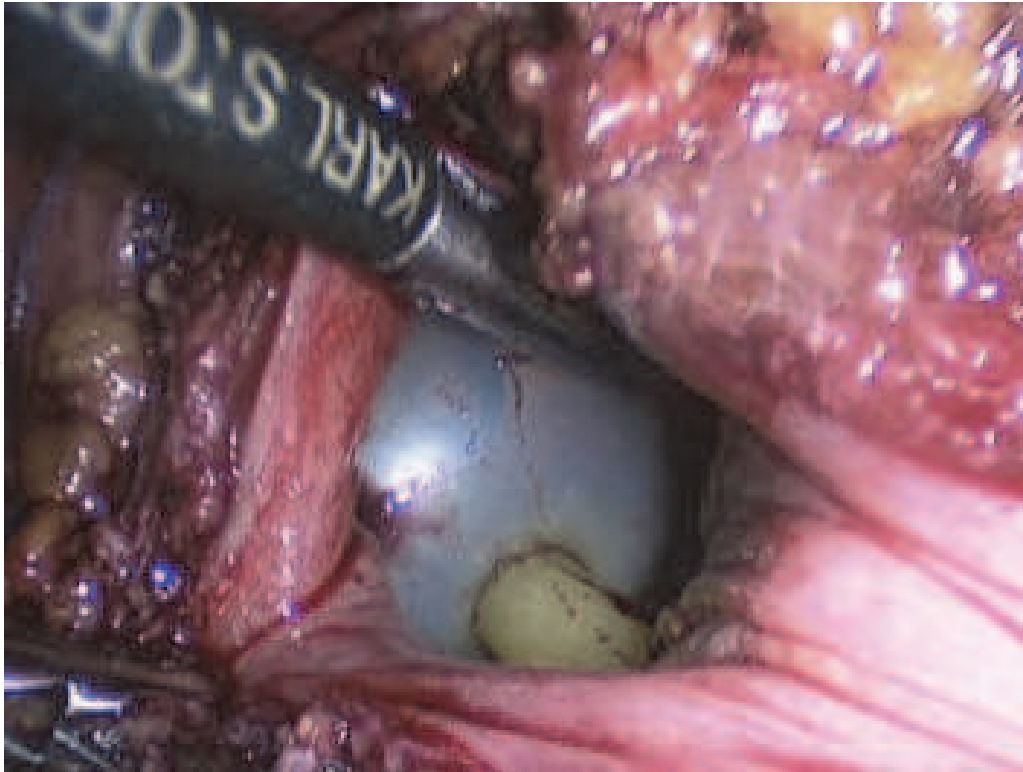


Fig. 7. The picture shows inspection inside bladder.

After the bladder inspection, the stones were extracted and put into the endobag – figure 8.

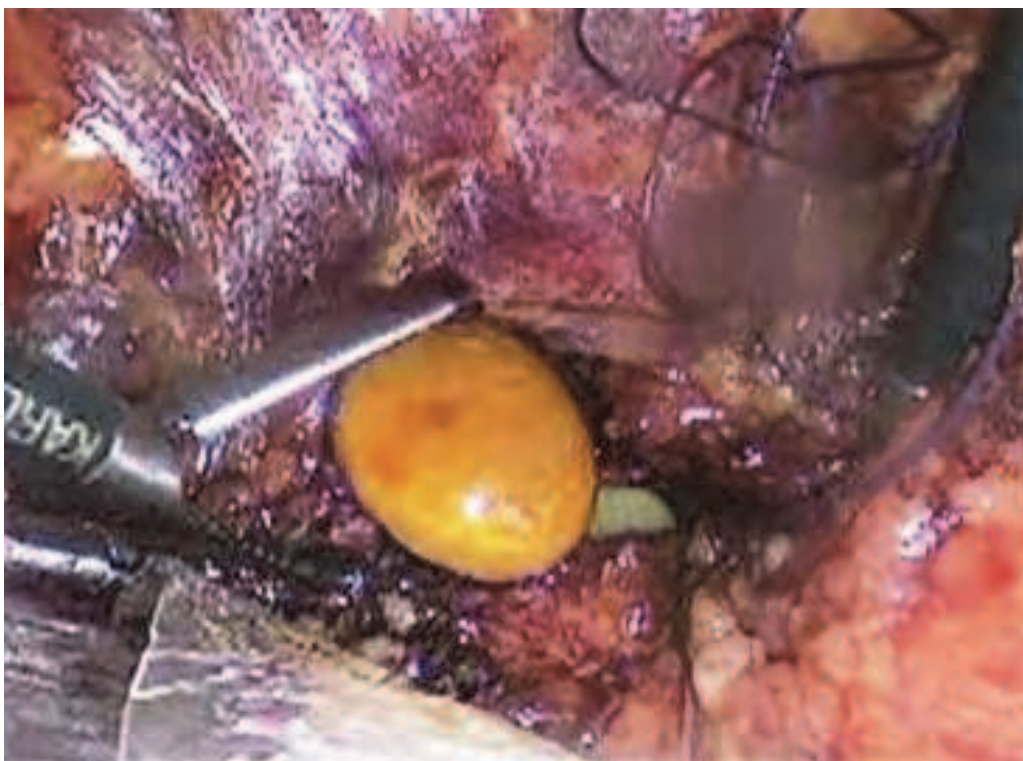

Fig. 8. The picture shows the extraction of the stones and put them into the endobag.

The bladder wall is sutured with running suture 2/0 resorbable suture – figure 9.

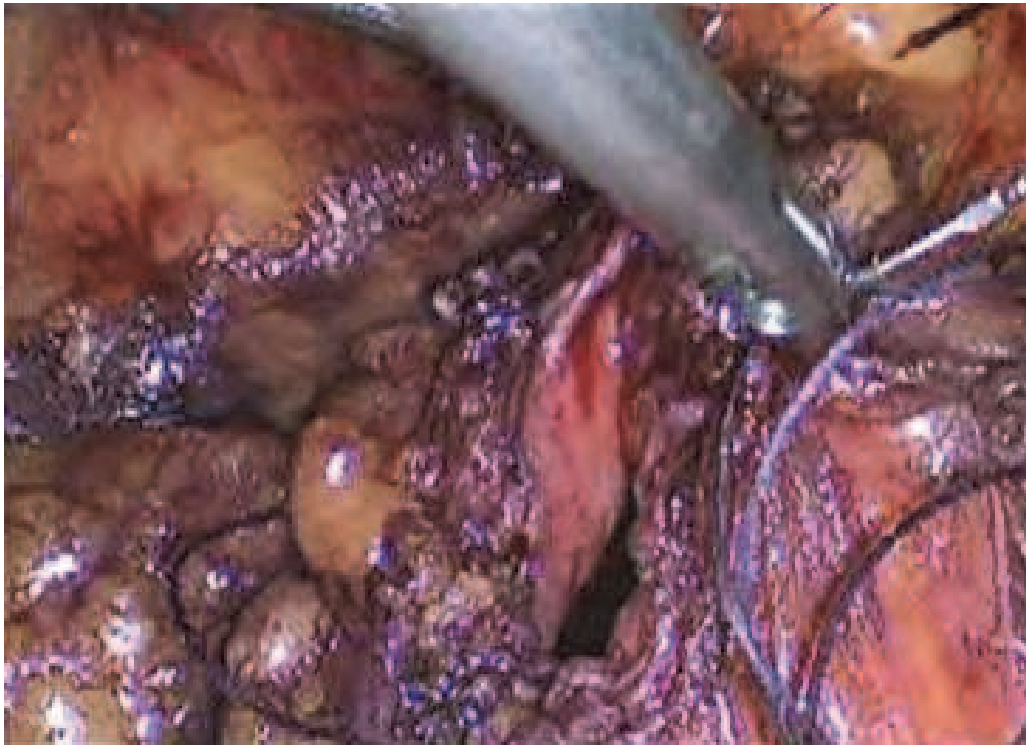


Fig. 9. The picture shows closure the bladder wall with running suture 2/0 resorbable suture.

The endobag was extracted through the camera port. Praevesical tube drainage was placed for 24 hours. The fascia at the camera port and the skin incisions were closed.

3.3 Postoperative care and results

Prophylactic with a third generation cephalosporin and low molecular heparin was usually performed. The Foley catheter was kept in place for 3 days. There was no postoperative severe pain. The drainage was kept until second postoperative day. The patients were able to move and drink water in several hours after the operation. Hospital stay was between 3 and 4 days. There were no cases of conversion or operative revision.

3.4 Complications

There were no major intraoperative or postoperative complications. In one case during the operation, we performed cystoscopy because of the small number of extracted stones. On the postoperative x-ray plain film, was registered one stone, which has probably migrated outside the bladder. One month later, the patient was in good condition, without stones in the urinary bladder. One year later the same patient has two stones in the urinary bladder. We offered him a second operation – transurethral stones lithotripsy and prostate resection. There is one case of subcutaneous hematomas probably due to early drainage removing – figure 10.

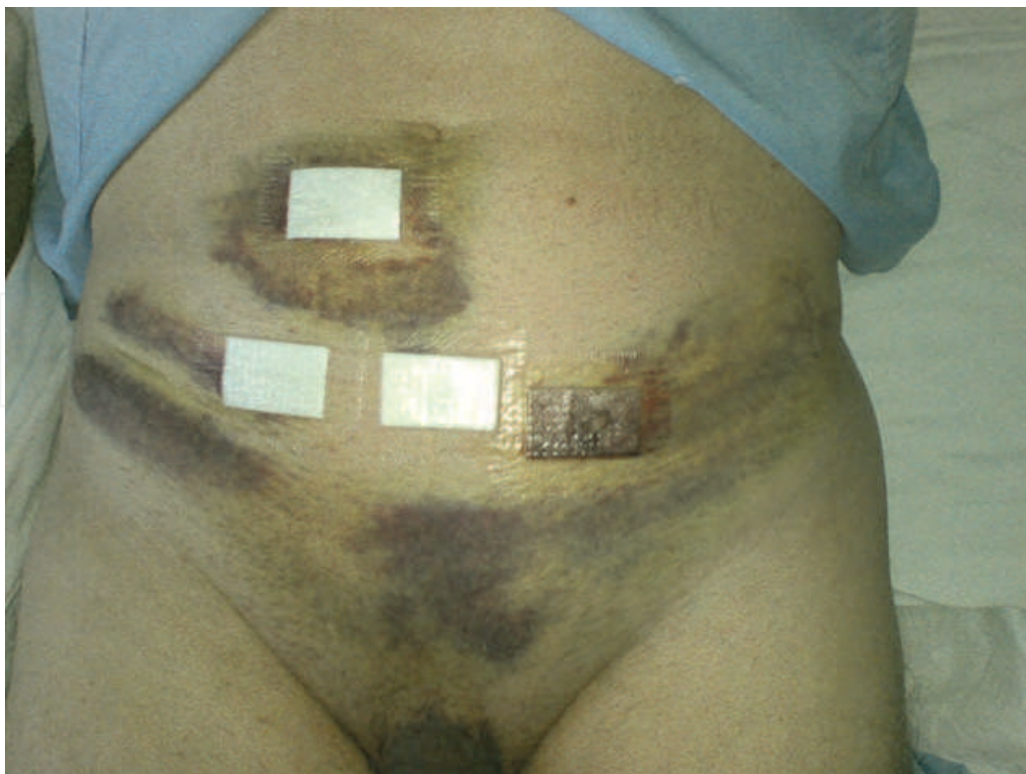

Fig. 10. The picture shows the patient after ESAL with subcutaneous hematomas probably due to early drainage removing.

4. Discussion

Al-Marhoon MS et al. performed an open cystolithotomy, endourological transurethral, and percutaneous litholapaxy of vesicle stones in children. They concluded that an open and endourological management of vesical stones in children is efficient, with low incidence of complications, but an open cystolithotomy seems to be safer (Al-Marhoon et al., 2009). Wollin TA et al. performed a percutaneous suprapubic cystolithotomy in cases of bladder stones larger than 3 cm or multiple stones with 1 cm size. They used nephroscope and pneumatic lithotripter (Wollin et al., 1999).

Miller DC et Park JM described a percutaneous approach for treatment of the stone in an augmented bladder. They inserted a laparoscopic trocar and via endobag extracted the stone without lithotripsy (Miller & Park, 2003). Segarra J. et al. inserting a Hasson trocar through the 1.5 cm suprapubic incision were able via the trocar to disintegrate and extract the stone fragments (Segarra et al., 2001). Some authors report laparoscopic resection in rear cases of urachal cyst containing stones employ a laparoscopic transabdominal approach with or without bladder wall resection (Ansari & Hemal, 2002; Okegawa, 2006; Pust, 2007; Yohannes 2003). Colegate-Stone TJ et al. reported a case of bladder wall injury and bladder stone formation after inguinal herniorrhaphy, treated laparoscopically (Colegate-Stone et al., 2008). Ingber MS et al. reported a novel technique for removal of intravesical polypropylene mesh through a single laparoscopic port directly from the bladder (Ingber MS et al., 2009). Reddy BS and Daniel RD described a new technique for extraction of complex foreign bodies from the urinary bladder using cystoscopy while the bladder remains insufflated with carbon dioxide (Reddy & Daniel, 2004). Eradi B and Shenoy MU. describing the similar

procedures and named it laparoscopic. Actually they used a laparoscopic trocar, but not the laparoscopic method (Eradi & Shenoy, 2008).

Author	Operative Technique	Indications	Number of cases
Al-Marhoon MS et al 2009	open cystolithotomy, endourological transurethral, and percutaneous litholapaxy	vesicle stones in children	107 Open – 53 Endoscopic – 54 (23 transurethral and 24 suprapubic)
Wollin et al., 1999	percutaneous suprapubic cystolithotomy with nephroscope and pneumatic lithotripter	bladder stones larger than 3 cm or multiple stones with 1 cm size	15
Miller & Park , 2003	percutaneous approach in augmented bladder with laparoscopic trocar and via endobag. Extraction of the stones without lithotripsy.	treatment of the stones in augmented urinary bladder	4 (one case conversion)
Segarra et al., 2001	Disintegrating and extracting the fragments from the stones via the Hasson trocar through the 1.5 cm suprapubic incision	stones in urinary bladder	20
Ansari & Hemal, 2002; Okegawa, 2006; Pust, 2007	laparoscopic resection of urachal cyst	urachal cyst containing stones	6
Yohannes P et al. 2003	laparoscopic resection of urachal cyst	urachal cyst without stones	1
Colegate-Stone et al., 2008	Laparoscopy extraction from urinary bladder	bladder stone formation after inguinal herniorrhaphy	1
Reddy & Daniel, 2004	cystoscopy and optical device through the urethra, a 10-mm laparoscopic port introduced suprapubically for extraction of complex foreign bodies	foreign bodies in urinary bladder	1
Ingber MS et al. 2009	Single port suprapubic extraction of foreign bodies in urinary bladder	foreign bodies in urinary bladder	2

Table 1. Data showing operative techniques, indications and number of cases for treatment of urinary bladder stones from different authors

5. Conclusion

There are two main methods for surgical treatment of urinary bladder stones – open suprapubic cystolithotomy and transurethral lithotripsy with litholapaxy. These two methods are combined by many authors, others perform endoscopic techniques using laparoscopic instruments or laparoscopy as operative method. Our endoscopic method is based on the principles of the open cystolithotomy, but completely laparoendoscopic extraperitoneally. Because of this we named our technique Endoscopic Sectio Alta. To the best of our knowledge this is the first application of such a technique.

In conclusion, Endoscopic Sectio Alta for urinary bladder stones treatment is simple and safe laparoscopic technique, which has not been described until now. The procedure avoids urethral damage and prevents the patient from open procedures. In selected cases of men without residual urine, who do not want prostate surgery, our technique is the treatment method of choice, especially in a laparoscopic clinic. In addition, this simple technique may be very useful as a training procedure in laparoscopy. Further cases are necessary for better results and indications.

6. Acknowledgement


This work has been supported by the Bulgarian ministry of education, youth and science under grant number DDVU-02-105/2010.

7. References

- Al-Marhoon MS, Sarhan OM, Awad BA et al. 2009. Comparison of endourological and open cystolithotomy in the management of bladder stones in children. *J Urol.* Jun;181(6):2684-7;
- Ansari MS, Hemal AK. 2002. A rare case of urachovesical calculus: a diagnostic dilemma and endo-laparoscopic management. *J Laparoendosc Adv Surg Tech A.* Aug;12(4):281-3.
- Chow KS, Chou CY. 2008. A boy with a large bladder stone. *Pediatr Neonatol.* Aug;49(4):150-3
- Colegate-Stone TJ, Raymond T, Khot U et al. 2008. Laparoscopic management of iatrogenic bladder injury and bladder stone formation following laparoscopic inguinal herniorrhaphy. *Hernia.* Aug;12(4):429-30.
- Eradi B, Shenoy MU. 2008. Laparoscopic extraction of the awkward intravesical foreign body: a point of technique. *Surg Laparosc Endosc Percutan Tech.* Feb;18(1):75-6.
- H Ellis. A history of bladder stone. 1979. *J R Soc Med.* April; 72(4): 248–25
- Holman E, Khan AM, Flasko T et al. 2004. Endoscopic management of pediatric urolithiasis in a developing country. *Urology.* Jan;63(1):159-62.
- Ingber MS, Stein RJ, Rackley RR et al. 2009. Single-port Transvesical Excision of Foreign Body in the Bladder. *Urology.* Dec;74(6):1347-50.
- Miller DC, Park JM. 2003. Percutaneous cystolithotomy using a laparoscopic entrapment sac. *Urology.* Aug;62(2):333-6.
- Okegawa T, Odagane A, Nutahara K et al. 2006. Laparoscopic management of urachal remnants in adulthood. *Int J Urol.*;13:1466–1469.

- Pust A, Ovenbeck R, Erbersdobler A et al. 2007. Laparoscopic management of patent urachus in an adult man. *Urol Int.*;79(2):184-6.
- Reddy BS, Daniel RD. 2004. A novel laparoscopic technique for removal of foreign bodies from the urinary bladder using carbon dioxide insufflation. *Surg Laparosc Endosc Percutan Tech.* Aug;14(4):238-9.
- Segarra J, Palou J, Montlleó M et al. 2001. Hasson's laparoscopic trocar in percutaneous bladder stone lithotripsy. *Int Urol Nephrol.*;33(4):625-6.
- Seo IY, Han DY, Oh SJ et al. 2008. Laparoscopic excision of a urachal cyst containing large stones in an adult. *Yonsei Med J.* Oct 31;49(5):869-71.
- Schwartz BF, Stoller ML. 2000. The vesical calculus. *Urol Clin North Am.* May;27(2):333-46.
- Stolzenburg JU, Do M, Pfeiffer H et al. 2002. The endoscopic extraperitoneal radical prostatectomy (EERPE): technique and initial experience. *World J Urol.* May;20(1):48-55.
- Tugcu V, Polat H, Ozbay B et al. 2009. Percutaneous versus transurethral cystolithotripsy. *J Endourol.* Feb;23(2):237-41.
- Wollin TA, Singal RK, Whelan T et al. 1999. Percutaneous suprapubic cystolithotripsy for treatment of large bladder calculi. *J Endourol.* Dec;13(10):739-44.
- Yohannes P, Bruno T, Pathan M et al. 2003. Laparoscopic radical excision of urachal sinus. *J Endourol.* Sep;17(7):475-9.

IntechOpen



Laparoscopy - An Interdisciplinary Approach

Edited by Dr. Ivo Meinhold-Heerlein

ISBN 978-953-307-299-9

Hard cover, 146 pages

Publisher InTech

Published online 12, September, 2011

Published in print edition September, 2011

Over the last decades an enormous amount of technical advances was achieved in the field of laparoscopy. Many surgeons with surgical, urological, or gynaecological background have contributed to the improvement of this surgical approach which today has an important and fixed place in the daily routine. It is therefore comprehensible to compose a book entitled laparoscopy serving as a reference book for all three disciplines. Experts of each field have written informative chapters which give practical information about certain procedures, indication of surgery, complications and postoperative outcome. Wherever necessary, the appropriate chapter is illustrated by drawings or photographs. This book is advisable for both beginner and advanced surgeon and should find its place in the libraries of all specialties – surgery, urology, and gynecology.

How to reference

In order to correctly reference this scholarly work, feel free to copy and paste the following:

Tsvetin Genadiev (2011). Laparoscopic Extraperitoneal Approach for Urinary Bladder Stones Removal – A New Operative Technique, Laparoscopy - An Interdisciplinary Approach, Dr. Ivo Meinhold-Heerlein (Ed.), ISBN: 978-953-307-299-9, InTech, Available from: <http://www.intechopen.com/books/laparoscopy-an-interdisciplinary-approach/laparoscopic-extraperitoneal-approach-for-urinary-bladder-stones-removal-a-new-operative-technique>

INTech
open science | open minds

InTech Europe

University Campus STeP Ri
Slavka Krautzeka 83/A
51000 Rijeka, Croatia
Phone: +385 (51) 770 447
Fax: +385 (51) 686 166
www.intechopen.com

InTech China

Unit 405, Office Block, Hotel Equatorial Shanghai
No.65, Yan An Road (West), Shanghai, 200040, China
中国上海市延安西路65号上海国际贵都大饭店办公楼405单元
Phone: +86-21-62489820
Fax: +86-21-62489821

© 2011 The Author(s). Licensee IntechOpen. This chapter is distributed under the terms of the [Creative Commons Attribution-NonCommercial-ShareAlike-3.0 License](https://creativecommons.org/licenses/by-nc-sa/3.0/), which permits use, distribution and reproduction for non-commercial purposes, provided the original is properly cited and derivative works building on this content are distributed under the same license.

IntechOpen

IntechOpen