

# We are IntechOpen, the world's leading publisher of Open Access books Built by scientists, for scientists

6,900

Open access books available

186,000

International authors and editors

200M

Downloads

Our authors are among the

154

Countries delivered to

TOP 1%

most cited scientists

12.2%

Contributors from top 500 universities



WEB OF SCIENCE™

Selection of our books indexed in the Book Citation Index  
in Web of Science™ Core Collection (BKCI)

Interested in publishing with us?  
Contact [book.department@intechopen.com](mailto:book.department@intechopen.com)

Numbers displayed above are based on latest data collected.  
For more information visit [www.intechopen.com](http://www.intechopen.com)



# Concomitant Abdominal Aortic Aneurysm and Malignancy: Simultaneous Minimally Invasive Repair

Gabriele Piffaretti<sup>1</sup>, Luigi Boni<sup>2</sup>, Matteo Tozzi<sup>1</sup>,  
Nicola Rivolta<sup>1</sup>, Giovanni Mariscalco<sup>3</sup> and Patrizio Castelli<sup>1</sup>

<sup>1</sup>*Vascular Surgery – Department of Surgical Sciences,  
University of Insubria School of Medicine, Varese*

<sup>2</sup>*General Surgery 1 – Department of Surgical Sciences,  
University of Insubria School of Medicine, Varese*

<sup>3</sup>*Cardiac Surgery – Department of Surgical Sciences,  
University of Insubria School of Medicine, Varese,  
Italy*

## 1. Introduction

Concomitant diseases were defined as those detected during the preoperative diagnostic evaluation for symptomatic abdominal aortic aneurysm (AAA) or occasional finding during oncological staging and/or follow-up, or as an intraoperative unsuspected findings at laparotomy. Malignancies presenting synchronously with AAA more frequently include primary or metastatic cancer of the gastrointestinal or genitor-urinary systems; more anecdotally, lung or endocrine cancers have been reported to be treated with AAA repair.

The association of AAA and malignancies is rare. In fact, although the true incidence of concomitant malignancy and AAA is difficult to establish, most centers report a low incidence of co-existence: discrepancy in incidence between the various studies probably depends on whether all aneurysms are included or just those operated on, and also whether only simultaneously diagnosed malignancies are included or all malignancies associated with a patient with an AAA (Jibawi et al., 2011). Malignancies were found in 4% of AAA cases in an extensive experience that covered 22 years (Szilagyi et al.). In the UK in 1995 there were approximately 7000 elective and emergency operations for AAA, giving an estimated annual incidence of concomitant colorectal malignancy of between 35 and 105 (Morris et al. 1998).

Since the milestone report of Szilagyi's four decades ago (Szilagyi et al.), surgical procedures for synchronous AAA and tumors have been constantly performed but reports have been mainly represented by single case series with small numbers. More recently, the advent of mini-invasive technology have (potentially) widened the indication to treat both lesions more extensively. A simultaneous minimally invasive treatment should be intended as the single-stage operation that couples an endovascular treatment to exclude the AAA and an additional minimally invasive technique to treat or excise the concomitant malignant lesion.

## 2. Radiologic work-up and patient selection

Regardless of the type of tumor, a multidisciplinary team help to direct the work-up and choose the type of imaging studies to determine AAA repair as well as the resectability of the cancer.

The goals of the radiologic work-up are the following items:

- to confirm the diagnosis and specify the morphology and sizing of the AAA
- define the local extent of the malignancy and the presence of metastases

When possible, preoperative evaluation should be carried out following a specific protocol, performing routine preoperative blood test, chest X-rays, ECG transthoracic echocardiography, plethysmography, and thoraco-abdominal CT-angiography (Fig. 1).

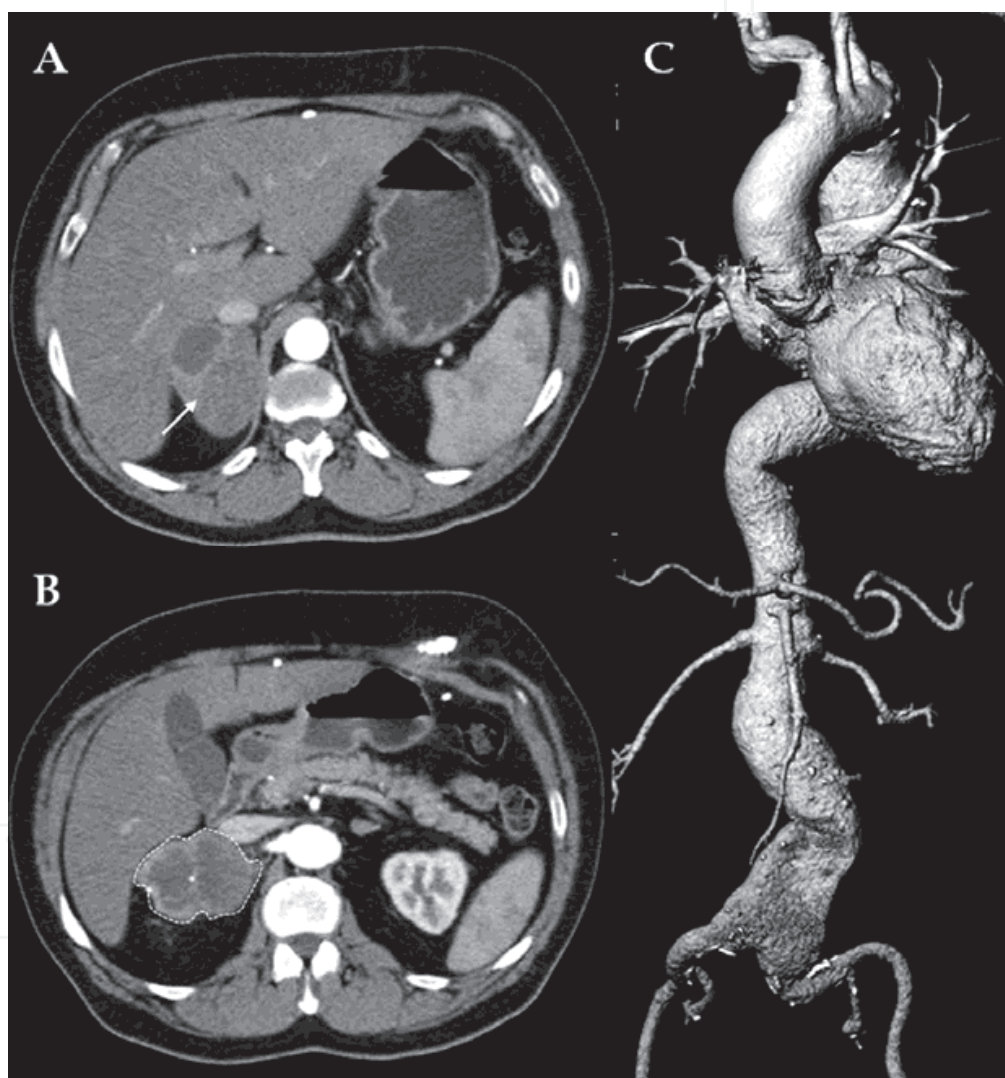


Fig. 1. Preliminary CT-angiography showing the presence of a mass (A, *arrow*) protruding from the upper portion of the right kidney (B, *dotted line*) and a huge 6.5cm fusiform infrarenal AAA (C)

Esofagogastroscopy and/or flexible colonoscopy, liver ultrasound and other staging examinations were performed depending on the location of the tumor. The combination of these studies is needed to determine surgical resectability and to plan the type of

reconstruction, and therefore to guide the type of surgical approach and to assess the feasibility of the mini-invasive approaches.

Pathologic tumor staging should be classified according to the most recent TNM system. Post-operative follow-up should be scheduled at periodic intervals (generally, 1, 6 and 12 months) coupling clinical visit, serological tests using oncologic markers, and CT-angiography to confirm the technical success or detect any type of complications (Fig. 2).

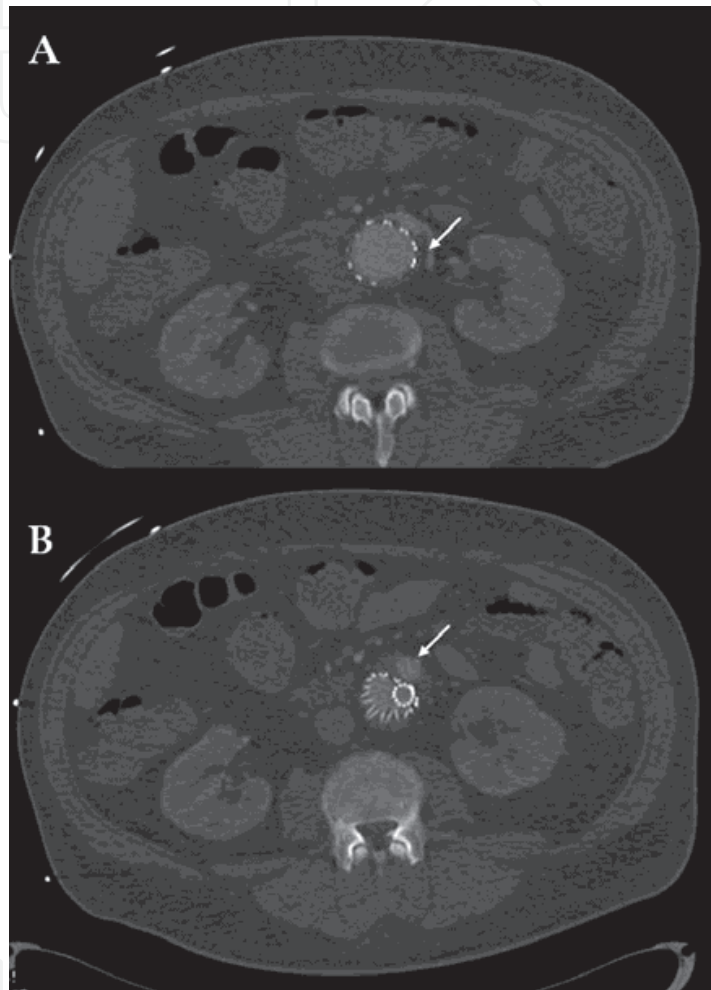


Fig. 2. Follow-up CT-angiography detecting an early type 2 endoleak (B, *arrows*) because of the inverted flow into the inferior mesenteric artery (A)

For decades, surgical intervention were rarely performed for several reasons: many cancers presented in advanced stage and carried poor prognosis, extent of the procedure especially for debilitated patients who had associated co-morbidities that placed them at high operative risk, many patients had undergone previous attempts of surgical resection or received adjuvant chemotherapy or radiation therapy that increased technical difficulties. More recently, improvements in preoperative imaging studies, surgical techniques, intraoperative anesthetic management, postoperative care, and the success of prosthetic grafts have burdened the impetus for a more aggressive surgical approach in selected patients. Nowadays, those patients with localized tumor, few co-morbidities (e.g. renal, liver, cardiopulmonary), and a good performance status could be considered candidates for operation. Careful patient evaluation is critical to outcome; a

multidisciplinary approach to the evaluation and treatment of these patients is an integral component for patient selection involving both the medical evaluation of the candidate along with a precise assessment of both AAA and tumor extension. Dealing with a similar clinical challenge, such as the combination of liver resection with caval vascular reconstruction, a patient's performance status could be determined using general criteria which provides an assessment of the patient's physical conditioning and has been a useful measure of functional quality of life for patients with malignant disease in that situation (Bower et al, 2000).

### 3. Indication

All agree that definitive treatment of both processes confers the best overall prognosis; nevertheless, concerns still remain toward decision-making strategy, whether it is better to treat both diseases simultaneously or as staged procedures. Clinical consensus is to treat the most life-threatening process first: prioritization is determined by the urgency of addressing each of the identified conditions (Kiskinis et al., 2004). In the past, surgical strategy was determined by the patient's general condition, the patient's symptoms, the surgeon's preference, the AAA size, and cancer stage.

Up to date, we have paucity of experiences with small number of cases treated, with wide heterogeneities of the oncologic lesions: hence, because of all these uncertainties, there is no consensus on the best therapeutic approach for patients with simultaneous AAA and malignancy. In addition, detailed management strategies vary however, among different authors with some choosing simultaneous over sequential operations on the basis of cancer type and stage (Oshodi et al., 2000).

The main goal of the single-stage is either to prevent cancer progression or to prevent AAA rupture; the advantages of the simultaneous intervention are clear:

- treating two lethal diseases with a single laparotomy reduces technical difficulties due to scarred or post-attinic tissues;
- the specific risk related to general anaesthesia, particularly high in these patients often affected by significant co-morbidities (vascular, respiratory and metabolic) and the advanced age, it is reduced by treating both condition at one time;
- the risk of cancer progression is kept at minimum since there is no delay between tumour diagnosis and surgical treatment

The main disadvantage of the combined intervention is that single-stage operation carries potential risk of graft infection; in addition, it lengthens the operation time and decreases the bowel perfusion.

The advantages of the delayed intervention are:

- lower risk of graft infection due to the reduced risk of septic disease
- it reduces splanchnic ischemia (reduces potential leakages of the gastrointestinal or genitor-urinary anastomosis)
- it allows a definitive and specific staging of the oncologic disease

The main disadvantage of the two-stage intervention is that when AAA repair is performed first, the physiological immunosuppression effect can lead to cancer progression, whereas it has been demonstrated that, when the malignant tumour is resected first, there is a systemic release of proteolytic enzymes that could lead to the growth and rupture of the aneurysmatic sac (Lin et al., 2008). In addition, it is



unquestionable that the two stage approach is definitively technically more complex due to the presence of peritoneal adhesions that, in some patients, could be extremely hard to dissect.

#### 4. Intervention techniques

Generally, in conventional AAA repair a standard transperitoneal approach using a midline laparotomy has been performed; few Authors suggested a retroperitoneal approach to avoid contamination (Grego et al., 2003). Surgical reconstruction of the AAA have been preferentially performed using Dacron graft: silver or antibiotic-bonded prostheses should be supported in order to reduce the risk of infection in a potentially contaminated fields. Cancer resection was carried out following the main oncological principles (no touch techniques and vessels ligation at their origins).

With the availability of laparoscopic surgery, as well as other minimally invasive therapies such as cryoablation for conditions including renal lesions, endovascular aortic repair (EVAR) nowadays represents an attractive alternative treatment modality with a less traumatic strategy (Porcellini et al., 2007). In addition to the management of primary AAAs, late sequelae of traditional repair such as anastomotic aneurysm, can also be addressed. Endografting confers the benefit of eliminating the need for a second laparotomy and creates flexibility in managing concomitant malignancy in rapid succession or simultaneously (Lee et. al, 2002). The devices can be placed prior to transabdominal resection and thus post-laparotomy rupture can be avoided. Hence, more recently, the single stage approach has been proposed using EVAR: the availability of this minimally invasive treatment strategy has created an alternative therapeutic paradigm, particularly in patients with synchronous challenging settings (Rivolta et. al, 2007). Results are still preliminary, and paucity of documentation exists concerning the application of EVAR to these patients as well as data pertaining to perioperative events.

Very few data have been published on the outcomes of synchronous treatment of AAA and tumors: we should take into account that the different etiology of cancers and the small number of patients preclude definitive conclusions regarding survival for such extensive interventions performed with open surgery. The advent of minimally invasive techniques with their encouraging results have been recently confirmed from different teams; in particular, EVAR intuitively should offer clinical and postoperative survival benefits in those patients at higher risk for conventional open repair. However, concerns remain about the definition of high-risk patient. Is the patient with concomitant diseases at higher risk for mini-invasive operations? In previous clinical experiences, ASA score have been used to identify high-risk patients; this is a variable objectively assessed by an independent auditor (anesthesiologist); it has been reported a 7.8% hospital mortality for ASA class 4, a 15-times higher than the rate for low-risk patients in that center (Verzini et al., 2002). If we consider the results of a large pivotal trial, attempt to identify the predictors of survival we could observe that malignancy was the cause of death in 30% of the patients, overall especially in the second year of that experience (Matsumura et al., 2009). More recently, our results have been in consonance with these data: in the long-term analysis, ASA was an independent factors of mortality but we did not consider the stage of malignant disease in the concept of high-risk patient despite tumors cancer was the second leading cause of death (11%) in our personal series (Lomazzi et al., 2011).

## 5. Literature review

The first ever report of minimally invasive treatment of synchronous malignancy and AAA was reported in 1998 by Herald et al. who performed full rectal wall thickness endoanal local excision of the rectal tumor but delayed the EVAR of the aneurysm three weeks later (Herald et al., 1998). Similarly, Hafez et al. reported 3 cases of combined treatment for kidney tumors and AAA, but again the Authors did go 97 days between the two procedures (Hafez et al., 2000). The most extensive clinical experience in the surgical management of patients with synchronous AAA and colo-rectal cancer have been reported by Lin et al. over 108 cases (Lin et al., 2008). In their data, a total of 92 patients formed the basis of the study: twelve patients underwent EVAR but they were primarily treated for the AAA and then the colo-rectal cancer followed. They had no aortic graft infections, regardless of whether surgical treatment was performed in a staged or simultaneous fashion; however, they stated that despite the reported safety by several researchers about combined surgical repair of these synchronous lesions, we believe such a simultaneous surgical approach should be avoided whenever possible. It reflected the relatively small sample size in each group, rather than the safety of various treatment modalities. They concluded suggesting that: 1) staged open AAA repair followed by colo-rectal excision should be performed with caution because of the higher operative morbidity and mortality rates; 2) although combining rectal resection with EVAR during a single operation may seem to be an attractive option, concerns still remain about the potential endograft infection because of the seeding from the perioperative bacteremia related to the colon resection.

The attractive alternative to repair in a single-stage operation both lesions was brought to the fore by Lee et al. in 5 patients with different malignancies including renal, urinary bladder, esophageal, lung, and prostate (Lee et al., 2002). Endovascular exclusion was successfully accomplished in all cases, and surgical conversions were never needed; the postoperative course was uneventful with mean length of stay was 3.4 days. The Authors concluded that EVAR of either an aneurysm or other aortic pathology in patients with an associated malignancy can be performed safely, but remains an individualized option with a multidisciplinary team necessary to explore this type of approach.

The advantage of EVAR repair in patients with different (colon-rectum, bladder, pancreas, esophagus, prostate, kidney) concomitant abdominal malignancy was finally highlighted in a recent report by Porcellini et al. who compared 14 patients undergoing conventional open AAA repair vs. 11 patients who received endografting (Porcellini et al., 2007). Among those who received conventional open repair, 7 patients had simultaneous operations, with operative mortality and aortic graft infection rates of 14% and 14%, respectively. The overall operative morbidity and mortality rates of those treated with conventional open aneurysm repair were 34% and 21%, respectively. This was in contrast to the EVAR patient cohorts, who suffered no operative mortality and a relatively low operative morbidity rate of 8%. These short-term benefits are extremely important in patients who require further treatment for the concomitant oncologic lesion; even an advantage that was maintained after a mean follow-up of approximately 3 years. Furthermore, it is also likely that improvement of endovascular devices, refined technique, and enhanced operator experience will have an impact on the long-term outcome of EVAR.

## 6. Personal experience

Between august 1989 and December 2010, our overall experience consisted of 31 cases of synchronous repair of AAA and malignancy using the single-stage approach. The single stage minimally invasive approach was performed in 10 cases: we operated 9 males and 1 female, with a median age of 72 years (range 52-79). Most of the patients had comorbidities: hypertension (n = 9), ischemic heart disease with prior cardiac revascularization (n = 4), chronic obstructive pulmonary (FEV<sub>1</sub> < 1lt, n = 4), and mild (creatinine >2mg/dL) chronic renal insufficiency (n = 1). Oncologic lesions included colo-rectal cancer (n = 5), kidney (n = 2), adrenal gland (n = 1), liver metastasis (n = 1), and lung cancer (n = 1). Aortic disease included atherosclerotic fusiform AAA (n = 9), and saccular aneurysm complicating an ulcerated plaque (n = 1). All AAAs were infra-renal with a mean diameter of 58 mm (range, 44-92). Aneurysms were treated using bifurcated (n = 9) or tube (n = 1) endograft (infrarenal n = 8, transrenal n = 2). Oncologic operations included laparoscopic colectomy (left n = 4, right n = 1) for colo-rectal cancers, thermoablation with radiofrequency (n = 3), laparoscopic right nephrectomy (n = 1), and thoracoscopic wedge resection (n = 1). The mean blood loss was 312 ± 54 ml (range 154-400). Intensive care unit was never needed. Two patients had a major postoperative complication: acute on chronic renal insufficiency (n = 1) but hemofiltration or dialysis were not required, and acute pulmonary oedema (n = 1). Hospital mortality was not observed; there was no evidence of perioperative endograft infection. Mean hospitalization was 7 days (range 4-12). All patients were discharged alive and well; no patient was lost to follow-up. Median follow-up was 14 months: endograft infection was never observed, 2 patients died because of disseminated cancer disease (liver) and pulmonary thromboembolism without clinical or radiological signs of recurrency (kidney).

## 7. Comment

While co-existing AAA and malignancy is not a common problem, it presents a challenging dilemma in terms of operative management. Most physicians agree that treatment priority should be focused on the symptomatic or more life threatening lesion (Baxter et al., 2002). But because the majority of these concomitant lesions are asymptomatic at the time of diagnosis, physicians frequently are confronted with a therapeutic dilemma when dealing with this potentially challenging surgical problem. When the vascular surgeon discovers intra-abdominal malignancy before or during laparotomy the main considerations are to treat both lesions effectively, and to minimize the risks of graft infection and of postoperative rupture of the aneurysm.

The simultaneous combined treatment has not been used extensively; Literature lacks of experiences, especially those with long-term follow-up (Table 1).

Less often minimally invasive techniques have been used to treat concomitant lesions in a single-stage intervention. This because it has been considered inappropriate to resect aneurysms less than 50 mm or less in diameter, synchronously with a major gastrointestinal lesion if they are asymptomatic (Matsumoto et al., 1999). However, we should also pointed out that literature reported worse outcomes for patients with larger aneurysms, because they are often associated with a less favorable anatomy for EVAR (Zarins et al., 2006). In contrast, given the excellent results of EVAR in the short-term period in terms of morbidity



and mortality, coupled with the most recent endograft improvement, as well as the shorter life-expectancy of these patients and the need to receive adjuvant therapies for the malignant lesion, a more aggressive management for the AAA could be supported legitimately.

Author	Cases (number)	Aortic disease	K location	K operation	Delay (weeks)	L.O.S. (days)	Follow-up (mean, months)	Complication
Herald et al.	1	aneurysm	colo-rectal	endoanal	3		12	no
Hafezet al.	3	aneurysm	kidney	open	13		57	no
Shoen et al.	1	aneurysm	pancreas	open	1		1	no
Levet al.	5	aneurysm (4)	mainly genitourinary	open	simultaneous	3.4	10.1	no
Chai et al.	2	aneurysm	colo-rectal	open	1		12	endograft thrombosis
Kiskinis et al.	2	aneurysm	colo-rectal	open	simultaneous (1)	8	9	no
Linet al.	12	aneurysm	colo-rectal	open	1		n.r.	no
Porcellini et al.	11	aneurysm	mainly gastrointestinal	open (9)	<1	n.s.	37.7	limb occlusion (2)
Personi*	10	aneurysm	mainly gastrointestinal	video-assisted (7)	simultaneous	7	14	no

The main critic against a synchronous repair has been believed to be the increased risk of graft infection; to tell the truth, several previous papers focused on the outcome of a simultaneous intervention for AAA and cancer finally did not highlighted an increased risk for this type of complication. The risk of direct graft contamination by gut or urinary tract bacterial agents may be reduced by a combination of preoperative and bowel preparation, meticulous surgical technique and antimicrobial therapy with long-term antibiotic prophylaxis. Moreover, endograft placement should theoretically prevent exposure of the graft to an infected or potentially contaminated operative field: in fact, laparotomy is avoided and the aneurysmatic sac potentially protects the endograft from bowel contamination because of contiguity. In addition, septic complications following EVAR has been reported in only 0.43%, still lower than the 0.5-3% of the conventional open repair (Ducasse et al., 2004).

It is unquestionable whether the single-stage intervention using minimally invasive techniques has technically decreased complexity and less traumaticity. Intuitively, it remains desirable but even doubtful that a prospective randomized controlled study with sufficient statistical power will ever take place to definitively formulate a standardized treatment strategy in patients with these concomitant diseases.

8. Conclusion

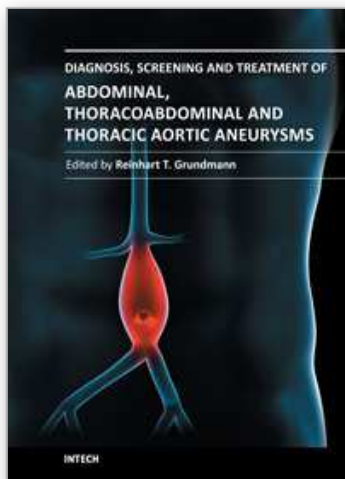
Lacks of extensive series as well as long-term follow-up do not allow to drawn definitive conclusions. Simultaneous AAA repair and malignancy excision using minimally invasive techniques has been rarely reported in a single-stage operation. Nevertheless, the few papers actually available reported encouraging technical and clinical results especially in the short-term period, provided that aortic anatomy is suitable. If this is the case, it may be considered an attractive alternative to standard open repair.

## 9. References

- Baxter NN, Noel AA, Cherry K, & Wolff BG. Management of patients with colorectal cancer and concomitant abdominal aortic aneurysm. *Dis Colon Rectum* 2002;45:165-170
- Bower TC, Nagorney DM, Cherry KJ Jr, Toomey BJ, Hallett JW, Panneton JM, & Gloviczki P. Replacement of the inferior vena cava for malignancy: an update. *J Vasc Surg* 2000;31:270-278
- Chai CY, Lin PH, Bush RL, & Lumsden AB. Aortic endograft thrombosis after colorectal surgery in lithotomy position. *J Vasc Surg* 2004;39:1112-1114
- Ducasse E, Calisti A, Speziale F, Rizzo L, Misuraca M, & Fiorani P. Aortoiliac stent graft infection: current problems and management. *Ann Vasc Surg* 2004;18:521-526
- Grego F, Lepidi S, Bassi P, Tavolini IM, Noventa F, Pagano F, & Deriu GP. Simultaneous surgical treatment of abdominal aortic aneurysm and carcinoma of the bladder. *J Vasc Surg* 2003;37:607-614
- Hafez KS, El Fettouh HA, Novick AC, & Ouriel K. Management of synchronous renal neoplasm and abdominal aortic aneurysm. *J Vasc Surg* 2000;32:1102-1110
- Herald JA, Young CJ, White GH, & Solomon MJ. Endosurgical treatment of synchronous rectal cancer and abdominal aortic aneurysm, without laparotomy. *Surgery* 1998;124:932-933
- Jibawi A, Ahmed I, El-Sakka K, & Yusuf SW. Management of concomitant cancer and abdominal aortic aneurysm. *Cardiol Res Pract* 2011;19:2011:516146
- Kiskinis D, Spanos C, Melas N, Efthimiopoulos G, Saratzis N, Lazaridis I, & Gkinis G. Priority of resection in concomitant abdominal aortic aneurysm (AAA) and colorectal cancer (CRC): review of the literature and experience of our clinic. *Tech Coloproctol* 2004;8:S19-21
- Lee JT, Donayre CE, Walot I, Kopchok GE, & White RA. Endovascular exclusion of abdominal aortic pathology in patients with concomitant malignancy. *Ann Vasc Surg* 2002;16:150-156
- Lin PH, Barshes NR, Albo D, Koungias P, Berger DH, Huynh TT, LeMaire SA, Dardik A, Lee WA, & Coselli JS. Concomitant colorectal cancer and abdominal aortic aneurysm: evolution of treatment paradigm in the endovascular era. *J Am Coll Surg* 2008;206:1065-1073
- Lomazzi C, Mariscalco G, Piffaretti G, Bacuzzi A, Tozzi M, Carrafiello G, & Castelli P. Endovascular treatment of elective abdominal aortic aneurysms: independent predictors of early and late mortality. *Ann Vasc Surg* 2011;25:299-305
- Matsumoto K, Nakamaru M, Obara H, Hayashi S, Harada H, Kitajima M, Shirasugi N, & Nougata K. Surgical strategy for abdominal aortic aneurysm with concurrent symptomatic malignancy. *World J Surg* 1999;23:248-251
- Matsumura JS, Katzen BT, Sullivan TM, Dake MD, & Naftel DC. Excluder Bifurcated Endoprosthesis Investigators. Predictors of survival following open and endovascular repair of abdominal aortic aneurysms. *Ann Vasc Surg* 2009;23:153-158
- Oshodi TO, Abraham JS, Brigg JK, & Kelly JF. Management of co-existing intra-abdominal disease in aortic surgery. *Eur J Vasc Endovasc Surg* 2000;19:43-46
- Piffaretti G, Rivolta N, Mariscalco G, Tozzi M, Maida S, & Castelli P. Aortic endograft infection: A report of 2 cases. *Int J Surg* 2010;8:216-220

- Porcellini M, Nastro P, Bracale U, Brearley S, & Giordano P. Endovascular versus open surgical repair of abdominal aortic aneurysm with concomitant malignancy. *J Vasc Surg* 2007;46:16-23
- Rivolta N, Piffaretti G, Tozzi M, Lomazzi C, Riva F, Alunno A, Boni L, & Castelli P. Management of simultaneous abdominal aortic aneurysm and colorectal cancer: the rationale of mini-invasive approach. *Surg Oncol* 2007;16 Suppl 1:S165-167
- Sheen AJ, Baguneid M, Ellenbogen S, Walker MG, & Siriwardena AK. Sequential endovascular repair and pancreaticoduodenectomy for abdominal aortic aneurysm copresenting with periampullary cancer. *Ann Vasc Surg* 2006;20:114-116
- Szilagyi DE, Elliott JP, & Berguer R. Coincidental malignancy and abdominal aortic aneurysm. Problems of management. *Arch Surg* 1967;95:402-412
- Verzini F, Cao P, Zannetti S, Parlani G, De Rango P, Maselli A, Lupattelli L, & Parente B. Outcome of abdominal aortic endografting in high-risk patients: a 4-year single-center study. *J Endovasc Ther* 2002;9:736-742
- Zarins CK, Crabtree T, Bloch DA, Arko FR, Ouriel K, & White RA. Endovascular aneurysm repair at 5 years: Does aneurysm diameter predict outcome? *J Vasc Surg* 2006;44:920-929

IntechOpen



## **Diagnosis, Screening and Treatment of Abdominal, Thoracoabdominal and Thoracic Aortic Aneurysms**

Edited by Prof. Reinhart Grundmann

ISBN 978-953-307-466-5

Hard cover, 414 pages

**Publisher** InTech

**Published online** 12, September, 2011

**Published in print edition** September, 2011

This book considers mainly diagnosis, screening, surveillance and treatment of abdominal, thoracoabdominal and thoracic aortic aneurysms. It addresses vascular and cardiothoracic surgeons and interventional radiologists, but also anyone engaged in vascular medicine. The high mortality of ruptured aneurysms certainly favors the recommendation of prophylactic repair of asymptomatic aortic aneurysms (AA) and therewith a generous screening. However, the comorbidities of these patients and their age have to be kept in mind if the efficacy and cost effectiveness of screening and prophylactic surgery should not be overestimated. The treatment recommendations which will be outlined here, have to regard on the one hand the natural course of the disease, the risk of rupture, and the life expectancy of the patient, and on the other hand the morbidity and mortality of the prophylactic surgical intervention. The book describes perioperative mortality after endovascular and open repair of AA, long-term outcome after repair, and the cost-effectiveness of treatment.

### **How to reference**

In order to correctly reference this scholarly work, feel free to copy and paste the following:

Gabriele Piffaretti, Luigi Boni, Matteo Tozzi, Nicola Rivolta, Giovanni Mariscalco and Patrizio Castelli (2011). Concomitant Abdominal Aortic Aneurysm and Malignancy: Simultaneous Minimally Invasive Repair, Diagnosis, Screening and Treatment of Abdominal, Thoracoabdominal and Thoracic Aortic Aneurysms, Prof. Reinhart Grundmann (Ed.), ISBN: 978-953-307-466-5, InTech, Available from:  
<http://www.intechopen.com/books/diagnosis-screening-and-treatment-of-abdominal-thoracoabdominal-and-thoracic-aortic-aneurysms/concomitant-abdominal-aortic-aneurysm-and-malignancy-simultaneous-minimally-invasive-repair>

**INTECH**  
open science | open minds

### **InTech Europe**

University Campus STeP Ri  
Slavka Krautzeka 83/A  
51000 Rijeka, Croatia  
Phone: +385 (51) 770 447  
Fax: +385 (51) 686 166  
[www.intechopen.com](http://www.intechopen.com)

### **InTech China**

Unit 405, Office Block, Hotel Equatorial Shanghai  
No.65, Yan An Road (West), Shanghai, 200040, China  
中国上海市延安西路65号上海国际贵都大饭店办公楼405单元  
Phone: +86-21-62489820  
Fax: +86-21-62489821

© 2011 The Author(s). Licensee IntechOpen. This chapter is distributed under the terms of the [Creative Commons Attribution-NonCommercial-ShareAlike-3.0 License](https://creativecommons.org/licenses/by-nc-sa/3.0/), which permits use, distribution and reproduction for non-commercial purposes, provided the original is properly cited and derivative works building on this content are distributed under the same license.

IntechOpen

IntechOpen