

# We are IntechOpen, the world's leading publisher of Open Access books Built by scientists, for scientists

6,900

Open access books available

186,000

International authors and editors

200M

Downloads

Our authors are among the

154

Countries delivered to

TOP 1%

most cited scientists

12.2%

Contributors from top 500 universities



WEB OF SCIENCE™

Selection of our books indexed in the Book Citation Index  
in Web of Science™ Core Collection (BKCI)

Interested in publishing with us?  
Contact [book.department@intechopen.com](mailto:book.department@intechopen.com)

Numbers displayed above are based on latest data collected.  
For more information visit [www.intechopen.com](http://www.intechopen.com)



## Isolated Iliac Artery Aneurysm

Shinichi Hiromatsu, Atsuhisa Tanaka and Kentarou Sawada  
*Kurume University School of Medicine*  
*Japan*

### 1. Introduction

Unlike abdominal and combined aortoiliac artery aneurysms, isolated iliac artery aneurysms (IIAAs) are uncommon. An isolated iliac artery aneurysm is defined as a twofold increase in the diameter of the iliac artery without a coexisting aneurysm at another location. IIAA was encountered infrequently in the past, comprising 0.9% to 4.7% of all intra-abdominal aneurysms according to a review of previous studies; however, in recent times, many asymptomatic IIAAs have been detected incidentally because of the widespread use of abdominal ultrasonography and computed tomography<sup>1-3</sup>. The frequency of IIAA compared to that of abdominal aortic aneurysm (AAA) ranges from 5.1% to 19.4%<sup>4</sup>.

### 2. History

In 1817, Sir Astley Paston Cooper performed the first surgical ligation of the abdominal aorta proximal to the aneurysm for a traumatic external iliac artery (EIA) aneurysm in a 37-year-old man, but the man died 40 hours later<sup>5,6</sup>. In 1827, Valentine Molt performed the first successful ligation of the proximal iliac artery for a common iliac artery aneurysm (CIAA) in a 33-year-old farmer; 18 days later, he found that the aneurysm was nonpulsatile, and he removed the ligature percutaneously<sup>7</sup>. In 1912, Halsted<sup>8</sup> reported that only 5 of 15 (33.3%) patients who underwent iliac artery ligation for aneurysm survived the surgical procedure. In 1913, MacLaren<sup>9</sup> performed a successful ligation for a traumatic internal iliac aneurysm in a young woman. In 1923, more than a century after Cooper's first operation for IIAA, Rudolph Matas<sup>10</sup> performed the first successful proximal aortic ligation for a combined aortoiliac aneurysm in a young man with syphilis, who later died of tuberculosis.

### 3. Etiology and natural progression

The primary etiology is arteriosclerosis; however, IIAA also arises because of other predisposing conditions such as infection, dissection, fibromuscular dysplasia, trauma, and Marfan syndrome<sup>11-13</sup>. If arteriosclerosis causes an arterial bifurcation to become an obtuse rather than an acute angle, which is not morbid, the pulsation waves will be reflected more strongly<sup>14</sup>. This factor may account for the high incidence of abdominal aneurysm, and common and internal iliac artery aneurysms (iIAA's) may readily develop, because pulsation waves are generated very strongly at the common and internal iliac artery

bifurcations owing to shortening of the distance to reflection of the pulse. However, because the EIA does not bifurcate before it becomes the common femoral artery, reflection of a pulsation wave does not readily occur, which may be the reason EIA aneurysms do not develop frequently. Furthermore, because the internal iliac artery branches off the common iliac artery after a short distance, the branch acts as a fulcrum, hindering the extension of an aneurysm along the long axis and expediting the expansion of the short axis diameter, which may facilitate rupture.

#### 4. Incidence of aneurysm

We reviewed the cases of 183 men and 15 women in the literature<sup>15-18</sup>, and our series consisted of 35 men and 6 women; which indicates male predominance. The mean age of the men and women in our series were  $69.8 \pm 10.8$  years and  $73 \pm 7.9$  years, respectively. IIAs comprised 0.9% to 4.7% of all intra-abdominal aneurysms, as per the reports published before the last decade<sup>1,2</sup>. The frequency of IIAA compared to that of AAA was 5.1% to 19.4%, according to the reports published in the last decade, because improvements in diagnostic technology have increased detection of IIAs<sup>3,4</sup>. Over the past 20 years, 41 patients with IIAA presented at the Kurume University School of Medicine. During the same period, 652 patients with AAA underwent surgery, including 52 patients with ruptured AAA (8%); therefore, the relative frequency of IIAA to that of AAA was 6.1% over a 20-year period at our hospital.

**(Location of aneurysm)** In the previous literature, 31 of 198 patients (15.7%) with IIAA had concurrent common and iIAA's, and the incidence was higher than the incidence in our series, which was 7.3% (3/41). The aneurysms were located in the common iliac artery in 31 patients and in the internal iliac artery in 7 (7.1%); EIA aneurysms were not observed. These findings are consistent with those of previous studies, which found that 57.1% (113/198) of IIAs occurred in the common iliac artery, 26.3% (52/198) in the internal iliac artery, and 1.0% (2/198) in the EIA. CIAA was predominant in our series and in the series in the literature<sup>1-4,15-18</sup>.

#### 5. Frequency of rupture

Unlike abdominal aortic aneurysm, the natural progression of IIAA is not well defined. In the literature, the rate of rupture of an IIAA is high. Lowry and Kraft<sup>1</sup> reported that 75% of their patients presented with ruptured aneurysms. Similarly, Schuler and Flanigan reported that 51% of their patients had ruptured aneurysms. In an attempt to define the natural progression of these aneurysms, Schuler and Flanigan also reported the cases of 13 patients with untreated aneurysms. Nine of these patients (69%) died of aneurysm rupture after an average of just over 4 months after diagnosis<sup>19</sup>. In addition, the association between rupture and size is not defined. A threshold size of 3–4 cm was recommended in the era of open surgical repair, with its attendant increased morbidity<sup>20</sup>. In our series, the maximum diameter of the IIAs was 3.2–13 cm (mean,  $6.0 \pm 1.9$  cm). The diameter of the ruptured IIAs was 5.0–13.0 cm (mean,  $6.8 \pm 2.1$  cm), whereas that of nonruptured IIAs was 3.2–7.5 cm (mean,  $4.8 \pm 1.1$  cm). The diameter of the ruptured IIAs was significantly greater than that of nonruptured IIAs. Rupture occurred in 20 patients (48.8%). During the same period, 658 patients with AAA underwent surgery, of which 53 had ruptured aneurysms (8.1%). The frequency of ruptured IIAA was significantly higher than that of ruptured AAA.

The median maximum diameters of ruptured AAAs and ruptured IIAs (measured at preoperative computed tomography [CT] scanning) were  $7.2 \pm 1.6$  cm and  $6.8 \pm 2.1$  cm, respectively.

## 6. Symptoms and diagnosis

IIA may be masked by nonspecific signs and symptoms resulting from pressure on or erosion of adjacent structures, such as hydronephrosis, hematuria, femoral or obturator neurological symptoms, and hemorrhagic stool<sup>14,17,18</sup>, particularly in the absence of a pulsatile mass. If the physician, who encounters orthopedic, urologic, or lower abdominal symptoms, does not consider an aneurysm, the aneurysm may not be detected. Iliac aneurysms can be recognized early if the orthopedic surgeon, urologist, or gynecologist suspects this diagnosis; therefore, it is critical that they are aware of this disease. In the literature, IIA could not be palpated as a pulsatile mass on abdominal examination in the case of 28 of 38 patients. IIA is difficult to appreciate on an abdominal examination when a physician encounters a patient with lower abdominal pain. However, IIAs could be palpated as pulsatile masses on rectal examination in 4 of 6 cases in previous studies<sup>14-18,21-23</sup>. Therefore, rectal examination is useful for the diagnosis of this aneurysm in a patient who complains of lower abdominal pain. In recent times, many asymptomatic IIAs have been detected incidentally because of the widespread use of abdominal ultrasonography and three-dimensional CT.

## 7. Surgical indications and treatment strategies

The relative and absolute surgical indications for IIA are minimum diameters of 3 and 4 cm, respectively. We present the treatment strategy for IIA at our hospital. Most physicians recommend that patients with an IIA of a diameter more than 3 cm, who are otherwise good surgical candidates, undergo elective repair<sup>3</sup>. We believe that IIA has a great impact on the remainder of a patient's life because of a high incidence of rupture and fatality. The natural prognosis of IIA is not clearly understood. However, patients with IIA should undergo surgical repair if the patient is conscious, is not bedridden owing to a decrease in quality of life (QOL), and is not in the terminal stage of a malignant disease.

### 7.1 Surgical procedures

We recommend surgery, even in high-risk patients, because various procedures are available for IIA treatment, depending on patient condition and aneurysm location. In addition, because commercial endografts have become widely available, we have offered endovascular iliac artery aneurysm repair (EVIAR) as an option to all anatomically appropriate patients with IIAs of diameter more than 3–4 cm. The strategy for IIA differs for CIAA and iIAA. Furthermore, each group has 2 categories, i.e., high risk and low risk, and the surgical procedure varies with patient suitability for EVIAR. The exclusion criteria for EVIAR were as follows: unfavorable anatomy (calcification, thrombus-lined aneurysm neck, bilateral common iliac aneurysms, excessive angulation, and iliac occlusive disease), a concomitant procedure, and surgeon preference.

7.1.1 The treatment strategies for CIAA

Figure 1 presents the treatment strategies for CIAA when anatomical characteristics exclude EVIAR. High-risk patients with an ipsilateral CIAA undergo thromboexclusion (TE) by coil or ligation of the proximal aneurysm neck, which necessitates femorofemoral bypass<sup>21, 24</sup>, whereas those at lower risk are treated by aneurysmectomy with a bifurcated or local interposition prosthetic graft. For bilateral CIAAs, high-risk patients undergo TE with a bifurcated interposition prosthetic graft, whereas lower-risk patients are treated by aneurysmectomy with a bifurcated interposition prosthetic graft. When anatomical characteristics favor EVIAR, the treatment strategies for high-risk patients are the same as those for low-risk patients when EVIAR is used. Patients treated via an endovascular approach receive a unilateral iliac endograft if there is sufficient neck (usually 15 mm) present in the proximal common iliac artery. Otherwise, bifurcated aortoiliac stent grafts are used, which usually preserve at least 1 internal iliac artery. In all instances, the endograft limb is extended into the EIA landing zone (usually >20 mm). The ipsilateral internal iliac artery is addressed by covering the ostium with an endograft by coil embolization. Exclusion of the hypogastric artery by coil embolization and extension of the graft limb into the EIA are the most common.

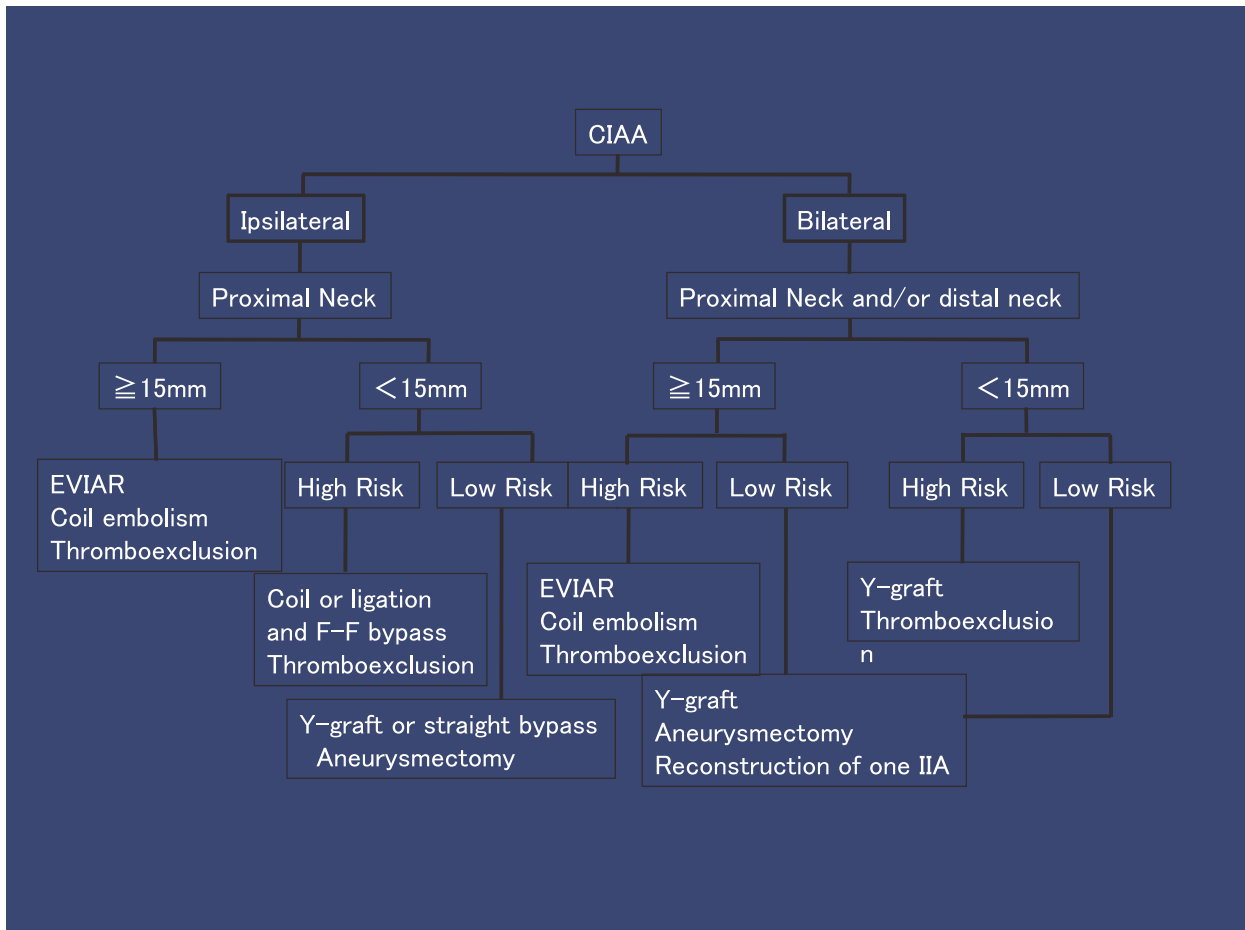


Fig. 1. The treatment strategies for CIAA

7.1.2 The treatment strategies for iIAA

Figure 2 illustrates the strategy for iIAA. High-risk patients with an ipsilateral iIAA undergo TE by coil or ligation of the proximal aneurysm neck, and those at lower risk are treated by endoaneurysmorrhaphy (EA) without reimplantation of the internal iliac artery. For bilateral iIAA, high-risk patients undergo TE by coil or ligation of the proximal aneurysm neck, whereas those at a low risk receive EA with a bifurcated interposition prosthetic graft. Both these procedures require unilateral reimplantation of an internal iliac artery. When EVIAR is used, ipsilateral internal iliac artery aneurysm is coil-embolized, and the branches of the internal iliac artery are individually coil-embolized, if sufficient neck (usually 15 mm) is present in the proximal internal iliac artery. If the neck is short or absent in the proximal internal iliac artery, the proximal side is supported by a stent graft with extension into the EIA, and the branches are coil-embolized. In the case of bilateral internal iliac artery aneurysms, if the proximal aneurysm necks are <15 mm on both the sides, we recommend open surgery to preserve at least 1 internal iliac artery.

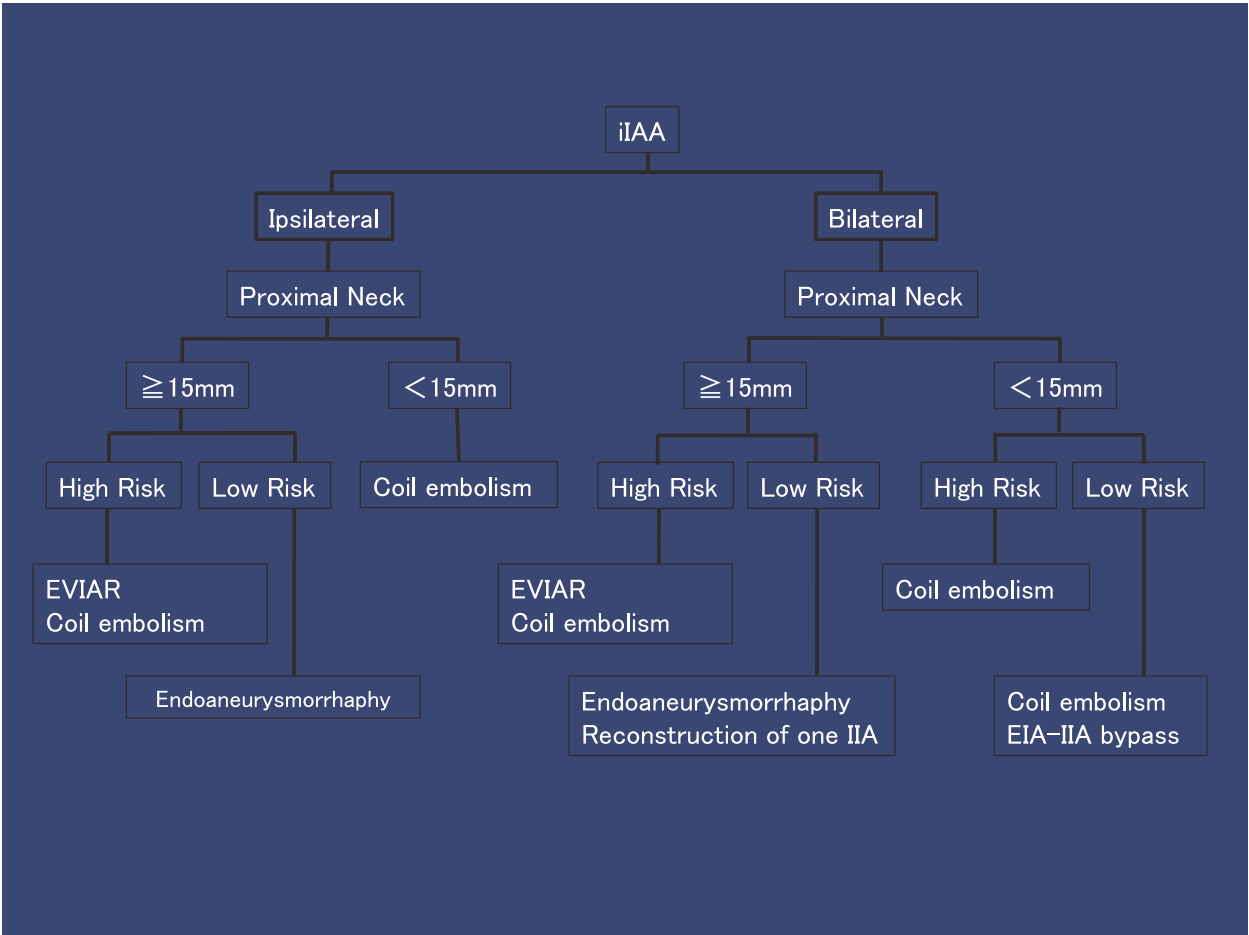


Fig. 2. The treatment strategies for iIAA



## 7.2 Other procedures

Recently, there has been considerable interest in percutaneous endovascular stent-graft repair of IIAA<sup>20,25,26</sup>. We have performed this procedure in 1 patient at our hospital, and the aneurysm was still reduced 5 years after the procedure without re-expansion. Casana et al. reported that endovascular repair of IIAA was initially successful in all the patients, although the median follow-up period was only 18 months<sup>27</sup>. However, Krupski et al. suggested that surgical repair might be more enduring and effective than percutaneous methods, because long-term results are still undetermined<sup>20</sup>.

We believe that stent grafts will become the treatment of choice for IIAA in the future, assuming improvements in equipment and long-term results. When we perform EVIAR for CIAA at our department, we insert a tapered device from the abdominal aorta to the diseased EIA; on the other hand, for the contralateral iliac artery, we fenestrate a stent graft to maintain blood flow. Thus, the indications for EVIAR are as follows: (1) a unilateral common iliac artery aneurysm is present, (2) the aneurysm neck is  $\geq 1$  cm, (3) the diameter of the EIA into which the stent graft will be inserted is  $\geq 8$  mm, and (4) the contralateral internal iliac artery can be preserved. Patients who met all 4 of these criteria were included as subjects in the study. Further, recently we have been considering iIAA treatment with a stent graft, which involves the same surgical procedure for a stent graft for CIAA in addition to coil embolization of the iIAA.

## 8. Early and mid-term results

Several series have shown that 30-day mortality was 6%–7% for elective open procedures and 0% for elective EVIAR. However, 30-day mortality was 17%–50% for emergency open procedures and 33% for emergency EVIAR. The mid-term (36 months) primary graft patency rates in the open group and the EVIAR group were 100% and 95.6%–97%, respectively. In addition, the midterm (36 months) secondary intervention in the 2 groups was 0% and 11%–14%, respectively<sup>28–33</sup>. Endovascular repair for IIAA is safe and has similar intermediate-term outcomes to open repair. However, there are various procedures besides the placement of a bifurcated prosthetic graft for IIAA treatment<sup>34</sup>. Surgery should be performed immediately after IIAA diagnosis owing to the risk of rupture, even if patients are anatomically unsuitable for EVIAR. The IIAA treatment should be tailored to the patient's health status and the aneurysm anatomy.

## 9. Conclusion

Surgery should be performed immediately after IIAA diagnosis owing to the risk of rupture. We undertake surgical management even if the patient has a concomitant disease, because the treatment for IIAA can be performed with MIVS other than the placement of a bifurcated prosthetic graft. The IIAA treatment should be tailored to the patient's health status and the aneurysm anatomy.

## 10. References

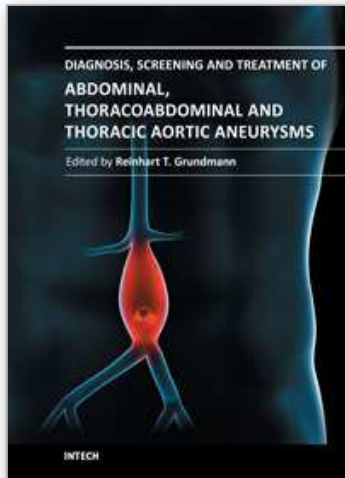
- [1] Lowry SF & Kraft RO. Isolated aneurysms of the iliac artery. *Arch Surg* 1978;113:1289–93.
- [2] McCready RA. Isolated iliac artery aneurysms. *Surgery* 1983;93:688–93.

- [3] Nachbur BH. Isolated iliac aneurysms. *Eur J Vasc Surg* 1991;5:375–81.
- [4] Kasirajan V. Management of isolated common iliac artery aneurysms. *Cardiovasc Surg* 1998;6:171–7.
- [5] Osler W. Remarks on arterio-venous aneurysm. *Lancet* 1915; 2:949.
- [6] Cooper AP. Lectures on the principles and practice of surgery. 2<sup>nd</sup> ed. London: FC Westley; 1830. P. 153-76.
- [7] Hager K. The illustrated history of surgery. New York: Bell Publishing; 1988.
- [8] Halsted WS. The effect of ligature of the common iliac artery on the circulation and function of the lower extremities. *Trans Am Surg Assoc* 1912; 30: 196-200.
- [9] MacLaren A. Aneurysm of the internal iliac artery, probably following a severe instrumental delivery: operation and partial cure. *Ann Surg* 1913; 117:73-7.
- [10] Matas R. Ligation of the abdominal aorta. *Ann Surg* 1925; 457: 457-62.
- [11] Richardson JW, & Greenfield LJ, Natural history and management of iliac aneurysms. *J Vasc Surg* 1998;8:165-71.
- [12] Veith FJ, & Johnston KW. Endovascular treatment of abdominal aortic aneurysms: an innovation in evolution and under evaluation. *J Vasc Surg* 2002; 35: 183.
- [13] Collin J, & Murie JA. Endovascular treatment of abdominal aortic aneurysm: a failed experiment. *Br J Surg* 2001; 88:1281-2.
- [14] Lallemand RC. Role of the bifurcation in atheromatosis of the abdominal aorta. *Surg Gynecol Obstet* 1973; 137:987-90.
- [15] Minato N. Isolated iliac artery aneurysm and its management. *Cardiovasc Surg* 1994; 2: 489-94.
- [16] Shindo S. Inflammatory solitary iliac artery aneurysms: a report of two cases. *Cardiovasc Surg* 2001; 9:615-9.
- [17] Katoh J. Rupture of an isolated internal iliac artery aneurysm into the rectum: report of a case. *Surg Today* 1995; 25:554-6.
- [18] Katagiri M, & Kasuya S. Surgery for an isolated aneurysm of the internal iliac artery. Report of three cases. *J Cardiovasc Surg (Trino)* 1990; 31:118-20.
- [19] Schuler JJ, & Flanigan DP: Iliac artery aneurysms. In Bergan J, Yao JST, editors: *Diagnosis and treatment*. New York, 1982, Grune and Strarron, pp 469-85.
- [20] Krupski WC. Contemporary management of isolated iliac aneurysms. *J Vasc Surg* 1998;28:1–13.
- [21] Boules TN. Endovascular management of isolated iliac artery aneurysms. *J Vasc Surg* 2006;44:29–37.
- [22] Reuter SR, & Carson SN. Thrombosis of common iliac artery aneurysm by selective embolization and extraanatomic bypass. *AJR* 1980;134:1248–50.
- [23] Matsumoto K. Surgical and endovascular procedures for treating isolated iliac artery aneurysms: ten-year experience. *World J Surg* 2004;28:797–800.
- [24] Sahgal A. Diameter changes in isolated iliac artery aneurysms 1 to 6 years after endovascular graft repair. *J Vasc Surg* 2001;33:289–95.
- [25] Chuter TA. Branched stent-grafts for endovascular repair of aortic and iliac aneurysms. *Tech Vasc Interv Radiol* 2005;8:56–60.
- [26] Sanchez LA. Midterm experience with the endovascular treatment of isolated iliac aneurysms. *J Vasc Surg* 1999;30:907–13.
- [27] Casana R. Midterm experience with the endovascular treatment of isolated iliac aneurysms. *Int Angiol* 2003;22:32–5.



- [28] Patel NV. Open vs. endovascular repair of isolated iliac artery aneurysms: A 12-year experience. *J Vasc Surg* 2009;49: 1147-53.
- [29] Pitoulias GA. Isolated iliac artery aneurysms: Endovascular versus open elective repair. *J Vasc Surg* 2007; 46: 648-54.
- [30] Dorigo W. The treatment of isolated iliac artery aneurysm in patients with non-aneurysmal aorta. *Eur J Vasc Endovasc Surg* 2008; 35: 585-89.
- [31] Boules TN. Endovascular management of isolated iliac artery aneurysms. *J Vasc Surg* 2006;44:29-37.
- [32] Char RA. Isolated iliac artery aneurysms: A contemporary comparison of endovascular and open repair. *J Vasc Surg* 2008; 47: 708-13.
- [33] Ferreira J. Isolated iliac artery aneurysms: six-year experience. *Interact Cardio Vasc Thorac Surg* 2010; 10: 245-48.
- [34] Hiromatsu S. Strategy for isolated iliac artery aneurysms. *Asian Cardiovasc Thorac Ann* 2007; 15:280-4.

IntechOpen



## **Diagnosis, Screening and Treatment of Abdominal, Thoracoabdominal and Thoracic Aneurysms**

Edited by Prof. Reinhart Grundmann

ISBN 978-953-307-466-5

Hard cover, 414 pages

**Publisher** InTech

**Published online** 12, September, 2011

**Published in print edition** September, 2011

This book considers mainly diagnosis, screening, surveillance and treatment of abdominal, thoracoabdominal and thoracic aortic aneurysms. It addresses vascular and cardiothoracic surgeons and interventional radiologists, but also anyone engaged in vascular medicine. The high mortality of ruptured aneurysms certainly favors the recommendation of prophylactic repair of asymptomatic aortic aneurysms (AA) and therewith a generous screening. However, the comorbidities of these patients and their age have to be kept in mind if the efficacy and cost effectiveness of screening and prophylactic surgery should not be overestimated. The treatment recommendations which will be outlined here, have to regard on the one hand the natural course of the disease, the risk of rupture, and the life expectancy of the patient, and on the other hand the morbidity and mortality of the prophylactic surgical intervention. The book describes perioperative mortality after endovascular and open repair of AA, long-term outcome after repair, and the cost-effectiveness of treatment.

### **How to reference**

In order to correctly reference this scholarly work, feel free to copy and paste the following:

Shinichi Hiromatsu, Atsuhisa Tanaka and Kentarou Sawada (2011). Isolated Iliac Artery Aneurysm, Diagnosis, Screening and Treatment of Abdominal, Thoracoabdominal and Thoracic Aortic Aneurysms, Prof. Reinhart Grundmann (Ed.), ISBN: 978-953-307-466-5, InTech, Available from:

<http://www.intechopen.com/books/diagnosis-screening-and-treatment-of-abdominal-thoracoabdominal-and-thoracic-aortic-aneurysms/isolated-iliac-artery-aneurysm>

**INTeCH**  
open science | open minds

### **InTech Europe**

University Campus STeP Ri  
Slavka Krautzeka 83/A  
51000 Rijeka, Croatia  
Phone: +385 (51) 770 447  
Fax: +385 (51) 686 166  
[www.intechopen.com](http://www.intechopen.com)

### **InTech China**

Unit 405, Office Block, Hotel Equatorial Shanghai  
No.65, Yan An Road (West), Shanghai, 200040, China  
中国上海市延安西路65号上海国际贵都大饭店办公楼405单元  
Phone: +86-21-62489820  
Fax: +86-21-62489821

© 2011 The Author(s). Licensee IntechOpen. This chapter is distributed under the terms of the [Creative Commons Attribution-NonCommercial-ShareAlike-3.0 License](https://creativecommons.org/licenses/by-nc-sa/3.0/), which permits use, distribution and reproduction for non-commercial purposes, provided the original is properly cited and derivative works building on this content are distributed under the same license.

IntechOpen

IntechOpen